



**HAL**  
open science

# Automatic identification of shoulder landmarks with a single camera

Yoann Blache, Maxime Perek, Félix Lefebvre, Isabelle Rogowski

► **To cite this version:**

Yoann Blache, Maxime Perek, Félix Lefebvre, Isabelle Rogowski. Automatic identification of shoulder landmarks with a single camera. 2024. hal-04737935

**HAL Id: hal-04737935**

**<https://hal.science/hal-04737935v1>**

Preprint submitted on 15 Oct 2024

**HAL** is a multi-disciplinary open access archive for the deposit and dissemination of scientific research documents, whether they are published or not. The documents may come from teaching and research institutions in France or abroad, or from public or private research centers.

L'archive ouverte pluridisciplinaire **HAL**, est destinée au dépôt et à la diffusion de documents scientifiques de niveau recherche, publiés ou non, émanant des établissements d'enseignement et de recherche français ou étrangers, des laboratoires publics ou privés.



Distributed under a Creative Commons Attribution 4.0 International License

# Automatic identification of shoulder landmarks with a single camera

Yoann Blache \*

*Universite Claude Bernard Lyon 1, LIBM,  
Laboratoire Interuniversitaire de Biologie de la  
Motricité, UR 7424, F-69622 Villeurbanne, France.*

Maxime Perek

*Universite Claude Bernard Lyon 1, LIBM,  
Laboratoire Interuniversitaire de Biologie de la  
Motricité, UR 7424, F-69622 Villeurbanne, France.*

Félix Lefebvre

*Universite Claude Bernard Lyon 1, LIBM,  
Laboratoire Interuniversitaire de Biologie de la  
Motricité, UR 7424, F-69622 Villeurbanne, France.*

*TRINOMA, Villefort, France*

Isabelle Rogowski

*Universite Claude Bernard Lyon 1, LIBM,  
Laboratoire Interuniversitaire de Biologie de la  
Motricité, UR 7424, F-69622 Villeurbanne, France.*

**\*Corresponding author.** Email:  
[yoann.blache@univ-lyon1.fr](mailto:yoann.blache@univ-lyon1.fr)

**Keywords:** markerless, kinematics, deep neural network, upper limb

## 1. Introduction

Proper positioning of the scapula during arm movements is crucial to ensure a safe shoulder function (Forthomme, Crielaard, & Croisier, 2008). An alteration of the scapula position or motion is termed as a scapular dyskinesis (Kibler & McMullen, 2003). The later is observed in 57% of symptomatic general orthopedic population and its prevalence increased up to 81% in symptomatic athletes. Nevertheless, 48% of the asymptomatic population display also scapular dyskinesis (Salamh et al., 2023). Although the relationship between scapular dyskinesis and shoulder pathology may not be always straightforward, its assessment remains paramount for patients experiencing shoulder troubles.

Scapular dyskinesis can be assessed qualitatively during arm elevation by assessing the presence or absence of abnormal scapular positioning. However, these approaches exhibit low-to-moderate reliability. In contrast, quantitative methods display excellent reliability (Paraskevopoulos, Papandreou, & Gliatis, 2020). These methods involve identifying anatomical

landmarks of the scapula and thorax, and then quantifying the bilateral differences in their 2D locations. Nevertheless, this method requires the clinician to palpate the patient, and manually conduct measurements, increasing therefore the time required for the procedure. Automatic identification of scapular landmarks would therefore assist clinicians in saving time during the assessment of scapular dyskinesis. This study aimed to develop and validate a deep neural network for 2D identification of shoulder anatomical landmarks with a single video camera.

## 2. Methods

### 2.1 Participants

Fifty healthy participants (18 women, age:  $23.7 \pm 4.1$  yr, height:  $174.8 \pm 9.2$  cm, mass:  $71.3 \pm 9.3$ , body fat:  $17.6 \pm 6.7$  %) signed an informed consent and were included in this study, which was approved by the local ethical committee (CER-UdL n°2022-10-13-002).

### 2.2 Procedure

The participant was asked to hold 13 static postures, usually considered for scapular dyskinesis assessment. The first pose corresponded to a  $90^\circ$  bilateral arm elevation in the sagittal plane with palm hands facing each other and holding a 2 kg barbell in each hand. Then three poses of the lateral scapular slide test were maintained (Kibler, 1998). The last set of poses corresponded to bilateral arm elevations at  $45^\circ$ ,  $90^\circ$  and  $135^\circ$  in the sagittal, frontal and scapular planes. For each pose, an image using a tablet (iPad, Apple, Cupertino USA, 1080x1920) was taken without markers, and a second image was taken with markers placed after having palpated 10 anatomical landmarks: 7<sup>th</sup> cervical vertebra (C7), 8<sup>th</sup> thoracic vertebra (T8), and bilaterally the posterior part of the acromion (AC), trigonum spinae (TS), scapular inferior angle (IA) and lateral epicondyle (EpL). A scale was positioned in the thorax plane for metrics conversions.

### 2.3 Deep neural network training and evaluation

For each image, coordinates of the 10 anatomical landmarks were digitalized with DeepLabCut (Mathis et al., 2018; Nath et al., 2019). Then the coordinates were transferred to the corresponding image without marker using an optical flow algorithm. One shuffle of the DLC ResNet-50 deep neural network (Lauer et al., 2022) was reinforced over 100 000 iterations with 80% of the dataset (316 images), and tested on 20% of the dataset (79 images) selected randomly.

The Euclidian distances were computed for each image and marker by comparing the labeled coordinates to the coordinates predicted by the deep neural network.

## 3. Results and discussion

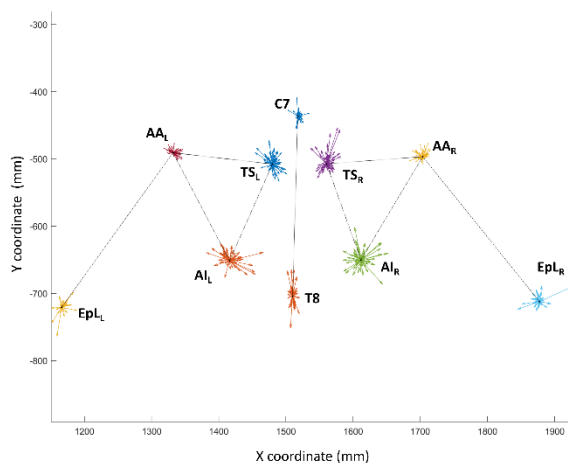
The median errors were inferior to 14mm for all the anatomical landmarks. C7 displayed the smallest median error, whereas AI and TS presented the highest

ones. Maximal errors near 60mm were observed for TS, AI and EpL (Table 1). Errors seemed to be randomly distributed around each anatomical landmark, except for T8 which displayed errors mostly oriented in the cranio-caudal direction (Figure 1). These outcomes highlighted that the greatest errors were found for anatomical landmarks known for presenting the highest soft tissue artefacts (Yoshida et al., 2022). Nevertheless, errors of the deep neural network were lower than those observed with marker-based approaches (Yoshida et al., 2022).

**Table 1.** Euclidian distances in mm between the landmark coordinates obtained with labelling and with the deep neural network  
credit: Blache

	median	min	max
C7	5.5	0.3	31.2
T8	9.8	0.2	52.9
AA <sub>R</sub>	7.5	0.4	24.6
TS <sub>R</sub>	12.6	0.6	62.7
AI <sub>R</sub>	13.5	0.2	55.4
EpL <sub>R</sub>	7.7	0.4	57.2
AA <sub>L</sub>	7.9	0.2	18.4
TS <sub>L</sub>	12.5	1.3	39.6
AI <sub>L</sub>	13.7	0.1	57.5
EpL <sub>L</sub>	5.5	0.1	48.8

R and L for the right and left sides, respectively



**Figure 1.** 2D coordinates of the labeled landmarks (linked by black lines). Arrows represent for each image the error vector between labeled and predicted coordinates  
credit: Blache

#### 4. Conclusions

This study is a first step in the development and validation of a deep neural network for automatic 2D identification of shoulder anatomical landmarks. These findings could serve as a benchmark for future

development, including the addition of new participants for external validation of the deep neural network. In the medium term, once anatomical landmarks will be detected automatically, their coordinates could be used to quantify potential 2D scapular dyskinesis.

#### Acknowledgements

None

#### Funding

None

#### Conflict of Interest Statement

None

#### References

- Forthomme, B., Crielaard, J. M., & Croisier, J. L. (2008). Scapular positioning in athlete's shoulder : particularities, clinical measurements and implications. *Sports Med*, 38(5), 369-386. Retrieved from <https://www.ncbi.nlm.nih.gov/pubmed/18416592>
- Kibler, W. B. (1998). The role of the scapula in athletic shoulder function. *Am J Sports Med*, 26(2), 325-337. doi:10.1177/03635465980260022801
- Kibler, W. B., & McMullen, J. (2003). Scapular dyskinesis and its relation to shoulder pain. *J Am Acad Orthop Surg*, 11(2), 142-151. Retrieved from <http://www.ncbi.nlm.nih.gov/pubmed/12670140>
- Lauer, J., Zhou, M., Ye, S., Menegas, W., Schneider, S., Nath, T., ... Mathis, A. (2022). Multi-animal pose estimation, identification and tracking with DeepLabCut. *Nat Methods*, 19(4), 496-504. doi:10.1038/s41592-022-01443-0
- Mathis, A., Mamidanna, P., Cury, K. M., Abe, T., Murthy, V. N., Mathis, M. W., & Bethge, M. (2018). DeepLabCut: markerless pose estimation of user-defined body parts with deep learning. *Nat Neurosci*, 21(9), 1281-1289. doi:10.1038/s41593-018-0209-y
- Nath, T., Mathis, A., Chen, A. C., Patel, A., Bethge, M., & Mathis, M. W. (2019). Using DeepLabCut for 3D markerless pose estimation across species and behaviors. *Nat Protoc*, 14(7), 2152-2176. doi:10.1038/s41596-019-0176-0
- Paraskevopoulos, E., Papandreou, M., & Gliatis, J. (2020). Reliability of assessment methods for scapular dyskinesis in asymptomatic subjects:

A systematic review. *Acta Orthop Traumatol Turc*, 54(5), 546-556.  
doi:10.5152/j.aott.2020.19088

Salamh, P. A., Hanney, W. J., Boles, T., Holmes, D., McMillan, A., Wagner, A., & Kolber, M. J. (2023). Is it Time to Normalize Scapular Dyskinesia? The Incidence of Scapular Dyskinesia in Those With and Without Symptoms: a Systematic Review of the Literature. *Int J Sports Phys Ther*, 18(3), 558-576. doi:10.26603/001c.74388

Yoshida, Y., Matsumura, N., Yamada, Y., Yamada, M., Yokoyama, Y., Miyamoto, A., . . . Jinzaki, M. (2022). Three-Dimensional Quantitative Evaluation of the Scapular Skin Marker Movements in the Upright Posture. *Sensors*, 22(17). doi:10.3390/s22176502

**Received date:04/04/2024**

**Accepted date: 28/06/2024**

**Published date: XX/XX/2024**

Volume: 1

**Publication year: 2024**