

Lexicon of histological structures found in the ovaries
and during the oogenesis of the megrim,
Lepidorhombus whiffiagonis (Walbaum, 1792)



HEUDE-BERTHELIN Clothilde
KELLNER Kristell
SAUGER Carine

August 2024

Cover photo: Picture of a female megrim (*Lepidorhombus whiffiagonis*). Personal collection.
C. Sauger©

Lexicon of histological structures found in the ovaries and during the oogenesis of the megrim, *Lepidorhombus whiffiagonis* (Walbaum, 1792)

The digital version of this document is available on the Archimer Web site.

The digital version of the reading protocol that accompanies this document is available on the Archimer Web site.

Version	Date	Comments
1.0	March 2020	Conception of the document
1.1	April 2020	First review
1.2	June 2020	Alcian blue review and ldo added
2.0	April 2023	Added last germline cells + Summary sheets
2.1	May 2023	Added aoB
2.2	August 2024	Changed zp (<i>zona pellucida</i>) to zr (<i>zona radiata</i>)

Summary

Abbreviations.....	1
Introduction.....	2
Overall ovarian organization.....	5
Decision Tree.....	7
Follicle Summary Sheet.....	8
Oogonium (og).....	9
Primary oocyte stage 1 (po1).....	10
Primary oocyte stage 2 (po2).....	11
Lipid droplet oocyte (ldo).....	12
Cortical alveoli oocyte (cao).....	13
Oocyte in early vitellogenesis (vtg1).....	15
Oocyte in vitellogenesis stage 2 (vtg2).....	17
Oocyte in hydration (oih).....	19
Hydrated oocyte (ho).....	20
Post-Ovulatory Follicle (POF).....	21
Atresia (aoA & aoB) and Lysis (L).....	22
Connective tissue (ct) & Gonadal wall (gw).....	25
Blood vessel (bv).....	26
Bibliography.....	27

Abbreviations

aoA : undischarged atretic oocyte
aoB : discharged atretic oocyte
bv : blood vessel
CA : cortical alveoli
cao : cortical alveoli oocyte
chr : condensed chromosome
chrom : chromatin
ct : connective tissue
E : unnatural emptiness (from the section's cut)
fc : follicular cell
gw : gonadal wall
ho : hydrated oocyte
Is : Intercellular space
L : lysis
ld : lipid droplet
ldo : lipid droplets oocyte
mc : macrophage cell
N : nucleus
NC : Nucleo-Cytoplasmic
nl : nucleolus
og : oogonium
oih : oocyte in hydration
po1 : primary oocyte stage 1
po2 : primary oocyte stage 2
POF : Post-Ovulatory Follicle
SI : sexually immature
SM : sexually mature
som : somatic cell
T : theca
U : undetermined structure
vd : vitellus droplet
vi : vitellus
vtg1 : oocyte in stage 1 of vitellogenesis
vtg2 : oocyte in stage 2 of vitellogenesis
vtg3 : oocyte in stage 3 of vitellogenesis
zr : *zona radiata*



Introduction

During this study, the terminology used was that of Brown-Peterson *et al.* (2011), following the criteria set by the working groups of the International Council for the Exploration of the Sea (ICES) that described the different maturity phases for European stock species (ICES 2008, 2010, 2012, 2018, 2019).

For the description of the female germinal cells that will become gametes, the terms **oogonia** (before meiosis) or **oocyte** (meiosis has begun) will be used. An oocyte is characterized by an **ooplasm** encased in an **olemma** (plasmic membrane) (Tyler and Sumpter, 1996). A **zona radiata** will also be present once the cell becomes dependent on follicle-stimulating hormone (FSH).

The term **follicle** will be used to designate an oocyte encased in somatic cells: **follicular cells** and **theca cells** (Tyler and Sumpter, 1996).

For the description of geminal cells development, the term **stage** will be used to designate the different gametogenesis stages (Brown-Peterson *et al.*, 2011) :

- Oogonia
- Primary growth oocytes
- Secondary growth oocytes
- Oocyte maturation
- Ovulation stage

The sexual maturity cycle (*Figure 1*) is split into two **states**. The Sexually Immature (**SI**) state and the Sexually Mature (**SM**) state. The terminology **phase** will be used for the gonadal development. The reproduction cycle of fish is divided into seven **phases** (Brown-Peterson *et al.*, 2011; ICES, 2012; 2018).

- Immature
- Developing
- Spawning
- Regressing
- Regenerating
- Omitted spawning
- Abnormal

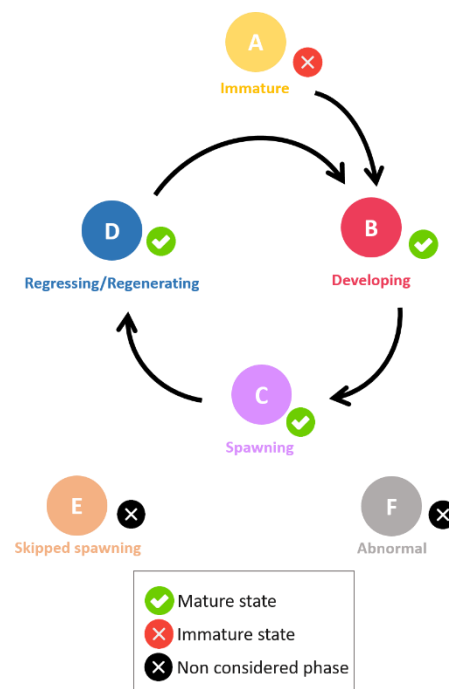


Figure 1 : Different phases found in the teleost maturation cycle, from the ICES (2018). The phases being: Immature (A), Developing (B), Spawning (C), Regressing/Regenerating (D), Skipped spawning (E) and Abnormal (F)

Sub-divisions/Sub-phases (Ba, Bb, Ca, Cb, Da, Db) should be used for specific particularities, meaning that their use is optional and must be evaluated for each species (ICES, 2012).

Table 1 : Macroscopic and microscopic descriptions of the phases in the reproductive cycle of female fish, from Brown-Peterson *et al.* (2011). Timing within each phase is species dependent. Some criteria listed for phases may vary depending on species, reproductive strategy, or water temperature. Subphases that apply to all fishes are listed; additional subphases can be defined by individual researchers. With CA = cortical alveoli, GVBD = germinal vesicle breakdown, GVM = germinal vesicle migration, OM = oocyte maturation, PG = primary growth, POF = post-ovulatory follicle complex, Vtg1 = primary vitellogenic, Vtg2 = secondary vitellogenic and Vtg3 = tertiary vitellogenic

Phase	Previous terminology	Macroscopic and histological features
Immature (never spawned)	Immature, virgin	Small ovaries, often clear, blood vessels indistinct. Only oogonia and PG oocytes present. No atresia or muscle bundles. Thin ovarian wall and little space between oocytes.
Developing (ovaries beginning to develop, but not ready to spawn)	Maturing, early developing, early maturation, mid-maturation, ripening, previtellogenic	Enlarging ovaries, blood vessels becoming more distinct. PG, CA, Vtg1, and Vtg2 oocytes present. No evidence of POFs or Vtg3 oocytes. Some atresia can be present. <i>Early developing subphase</i> : PG and CA oocytes only.
Spawning capable (fish are developmentally and physiologically able to spawn in this cycle)	Mature, late developing, late maturation, late ripening, total maturation, gravid, vitellogenic, ripe, partially spent, fully developed, prespawning, running ripe, final OM, spawning, gravid, ovulated	Large ovaries, blood vessels prominent. Individual oocytes visible macroscopically. Vtg3 oocytes present or POFs present in batch spawners. Atresia of vitellogenic and/or hydrated oocytes may be present. Early stages of OM can be present. <i>Actively spawning subphase</i> : oocytes undergoing late GVM, GVBD, hydration, or ovulation.
Regressing (cessation of spawning)	Spent, regression, postspawning, recovering	Flaccid ovaries, blood vessels prominent. Atresia (any stage) and POFs present. Some CA and/or vitellogenic (Vtg1, Vtg2) oocytes present.
Regenerating (sexually mature, reproductively inactive)	Resting, regressed, recovering, inactive	Small ovaries, blood vessels reduced but present. Only oogonia and PG oocytes present. Muscle bundles, enlarged blood vessels, thick ovarian wall and/or gamma/delta atresia or old, degenerating POFs may be present.

For the histological slides, fresh ovaries were placed in a Davidson solution before their inclusion in paraffin. 3 µm thick sections were cut using a microtome (HM330) and were either trichrome stained with a Prenant-Gabe (Gabe, 1968) solution or Alcian blue stained.

The histological pictures found in this lexicon were taken with a Nikon Eclipse 80i microscope using the NIS-Elements D (v. 5.02.03) software. Mean cell diameters and mean *zona radiata* widths were taken with an Olympus AX70 microscope using the Olympus CellSens© software, on a minimum of 20 oocytes found throughout multiple slides.

As seen in Table 1, different **phases** are correlated with the presence or absence of specific cell types. Following the terminologies and definitions of Brown-Peterson *et al.* (2011) and the ICES (2012; 2018). For the red striped mullet (*Mullus surmuletus*), the different cell types described in this work will be shown in bold (**og**, **po1**, **po2**, **ldo**, **cao**, **vtg1**, **vtg2**, **oih**, **ho**, **POF**) while their matching *Figures* will be indicated in italic.

- Oogonium stage :
 - oogonium (**og**) (*Figure 6 & 7*)
- Primary growth oocytes :
 - Primary stage 1 oocyte (**po1**) (*Figures 8 & 9*)
 - Primary stage 2 oocyte (**po2**) (*Figures 10 & 11*)
 - Lipid droplets oocytes (**ldo**) (*Figure 12*)
- Secondary growth oocytes :
 - cortical alveoli oocytes with lipid droplets (**cao**) (*Figures 13 to 15*)
 - vitellogenic oocytes
 - subphase vtg1 : **vtg1** (*Figures 16 to 18*)
 - subphase vtg2 : **vtg2** (*Figures 19 & 20*)
- Oocyte maturation :
 - nucleus migration :
 - germinal vesicle breakdown : oocyte enters metaphase I of meiosis
 - vitellus coalescence : oocyte in hydration (**oih**) (*Figure 21*)
 - hydration : hydrated oocytes (**ho**) (*Figure 22*)

Ovulation stage : discharge of the hydrated oocytes into the ovary's lumen, leaving behind a post-ovulatory follicle (**POF**) (*Figure 23*)

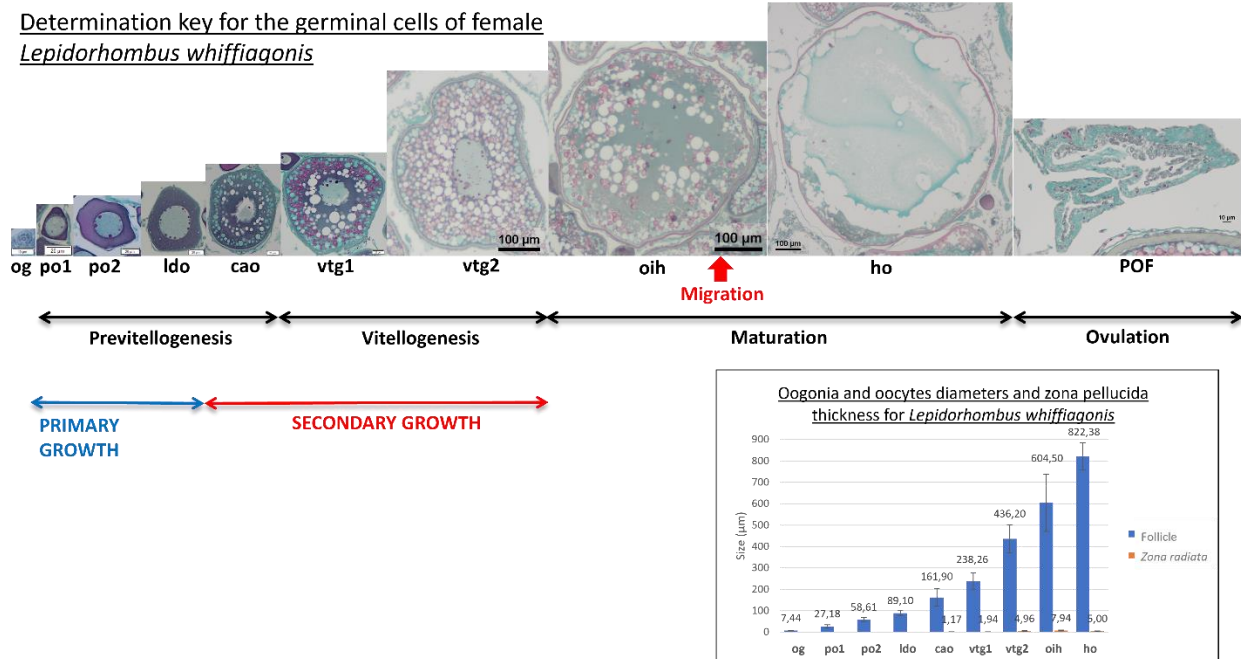


Figure 2 : Determination key of the different female germinal cells that can be found in the ovaries of *Lepidorhombus whiffiagonis* at different oogenesis stages. With average oogonium and oocyte diameters (µm ± standard deviation), and *zona radiata* widths (µm ± standard deviation)



Overall ovarian organization

The megrim is a **total spawner** species, meaning that the females will release all of their oocytes as a unique event during the breeding season.



Figure 3 : Dissected megrim, *Lepidorhombus whiffiagonis*, with the dorsal ovary uncovered

dorsal ovary

Criteria like the gonad wall (**gw**) thickness, connective tissue (**ct**) quantity, gonad vascularization (**bv**) or the surface area of the **lumen**, will depend on the maturity phase the fish is in. The histological cross sections will visually be quite different, with oocytes at various stages of gametogenesis.

Each gonad is organized concentrically (*Figure 4* and *Figure 5*), with the ovarian lamellas delimited by the germinal epithelium. The germinal cells (oogonia and oocytes) are found within these ovarian lamellas, inside follicles, at different stages of ovogenesis. The connective tissue (**ct**) will hold the germinal cells together, and the gonad wall (**gw**) can vary in thickness. Finally, the **lumen** is the naturally empty space found between the germinal epithelium lamellas inside the ovary.

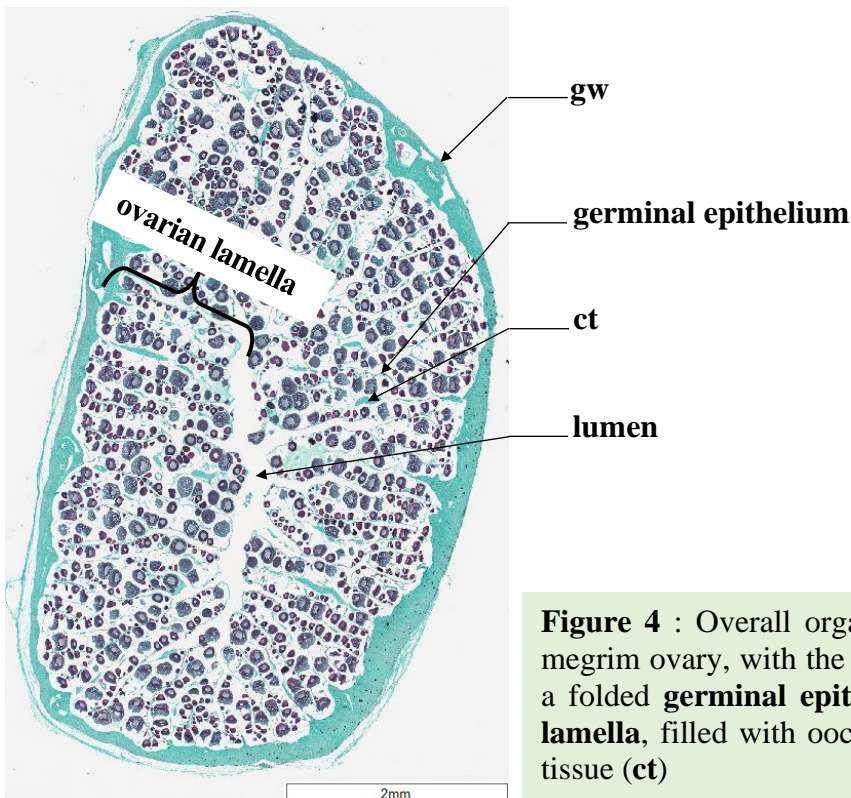


Figure 4 : Overall organization of a cross section of a megrim ovary, with the gonad wall (**gw**), the **lumen**, and a folded **germinal epithelium**, that makes the **ovarian lamella**, filled with oocytes held together by connective tissue (**ct**)

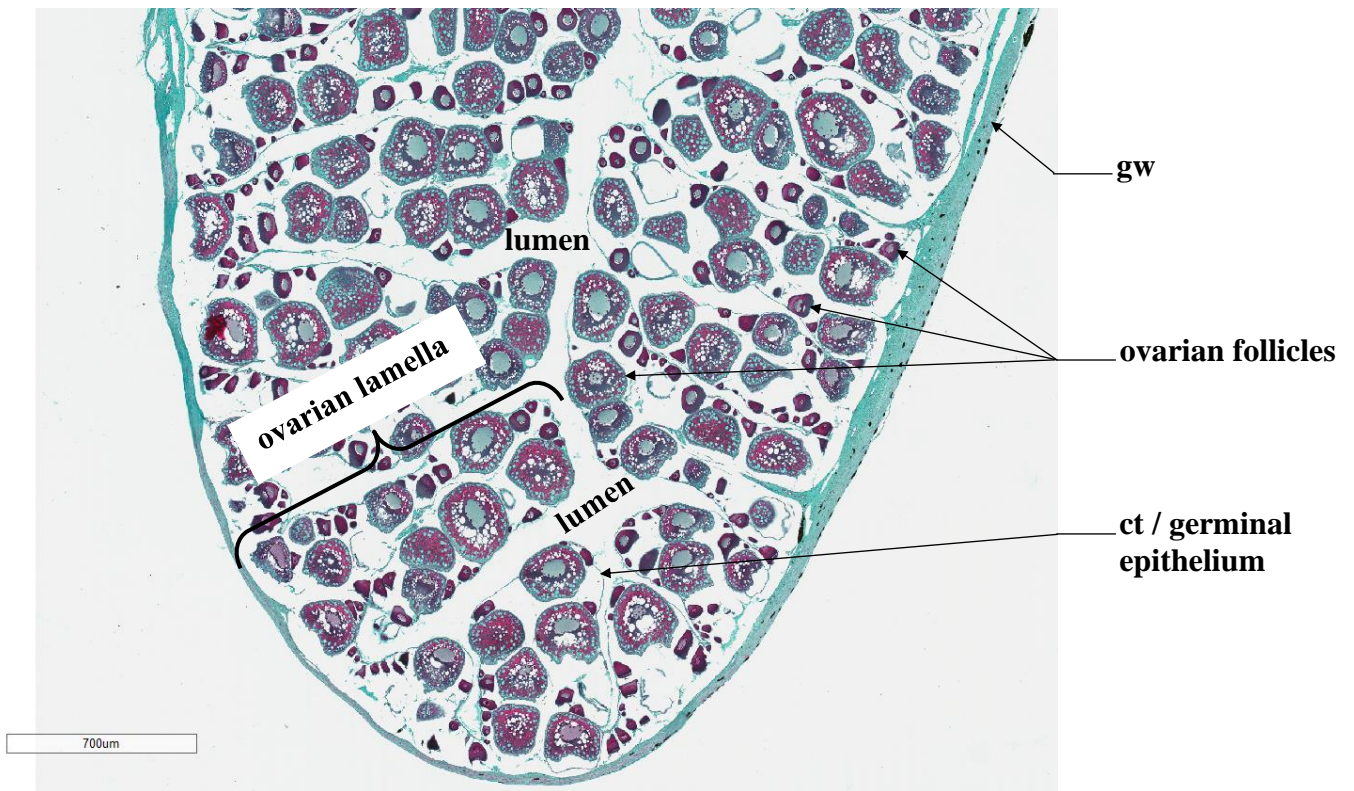
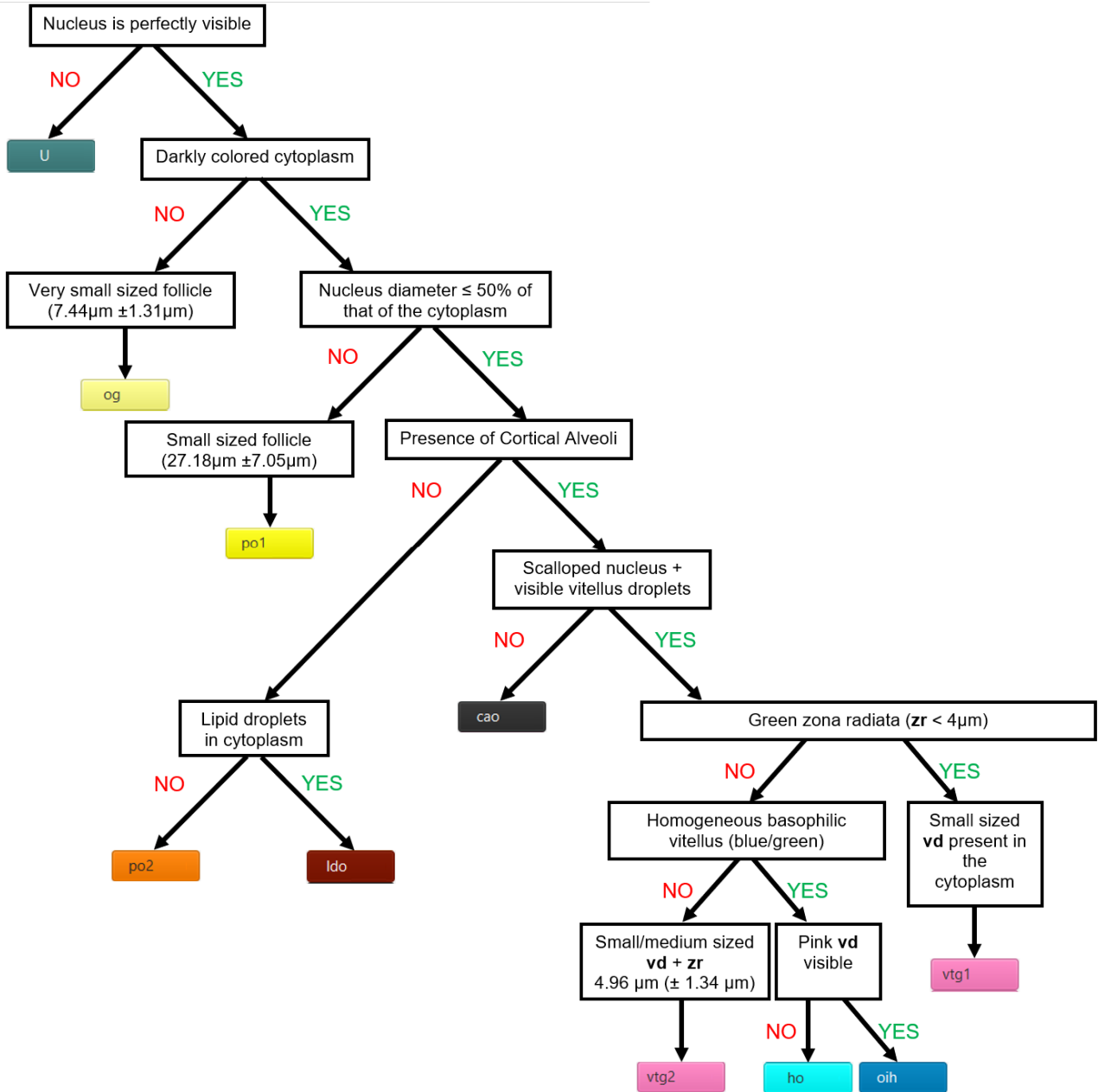


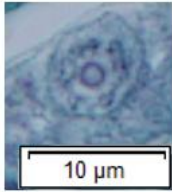
Figure 5 : Partial view of a megrim ovary cross section, with the gonad wall (**gw**), the **lumen**, and oocytes in **follicles** held together by connective tissue (**ct**), organized inside **ovarian lamellas**

Decision Tree



Follicle Summary Sheet

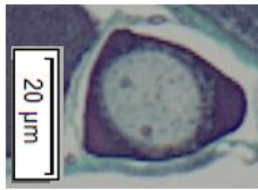
og



7.44μm (±1.31μm)

Light gray nucleus taking most of the space, barely visible light-colored cytoplasm with chromatin. Single nucleolus may be present

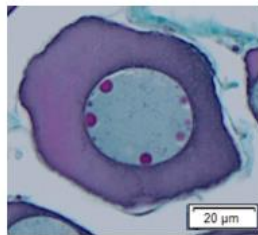
po1



27.18μm (±7.05μm)

Nucleus diameter >50% of the cytoplasm's. Nucleus is visible, smooth and round, one or two nucleoli can be present. Dark colored cytoplasm

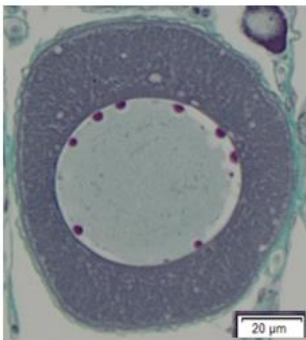
po2



58.61μm (±9.27μm)

Nucleus is visible, smooth and round. Many nucleoli can be present. Dark colored cytoplasm

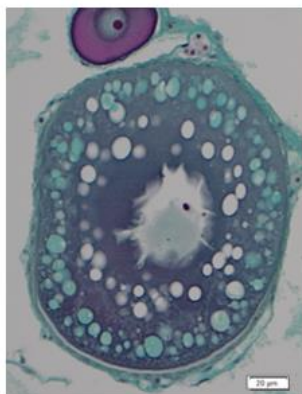
ido



89.10μm (±10.81μm)

Nucleus is visible, smooth, many nucleoli. Dark colored cytoplasm containing white lipid droplets

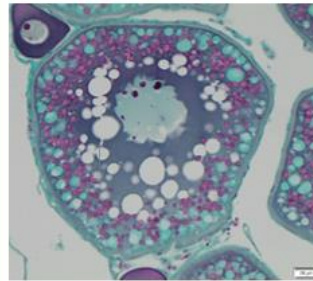
cao



161.90 (±40.21 μm)

Cortical alveoli near the outer periphery, green *zona radiata* (1.17μm±0.29μm), scalloped nucleus with multiple nucleoli, growing white lipid droplets in the cytoplasm

vtg1

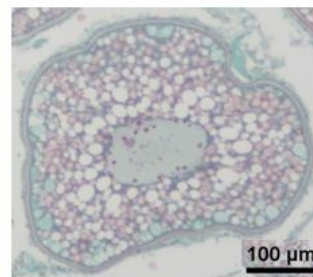


238.36μm (±36.50μm)

First appearance of small pink vitellus droplets amongst the cortical alveoli, under the thin greenish *zona radiata* (1.89μm±0.37μm).

Scalloped nucleus with multiple nucleoli. Large lipid droplets around the nucleus

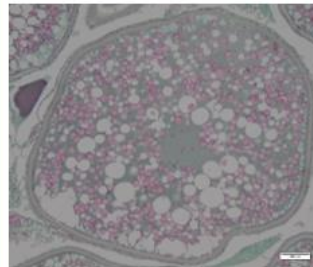
vtg2



436.20μm (±66.51μm)

Zona radiata thickens (4.96μm±1.34μm) and is pink and striated. Large vitellus droplets take up the entire space in the cytoplasm. Lipid droplets fuse and become bigger

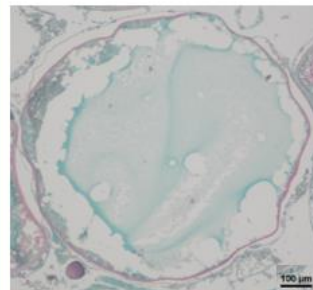
oih



604.50μm (±133.81μm)

Vitellus droplets fuse, giving the cytoplasm a homogenous dark turquoise color. The *zona radiata* (7.94μm±1.76μm) is pink and striated

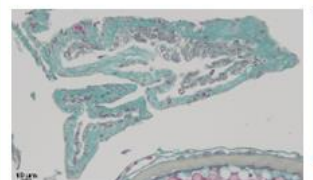
ho



822.38μm (±62.92μm)

Homogeneous basophilic vitellus (turquoise blue areas). *Zona radiata* (5.00μm±0.82μm) pink and striated.

POF



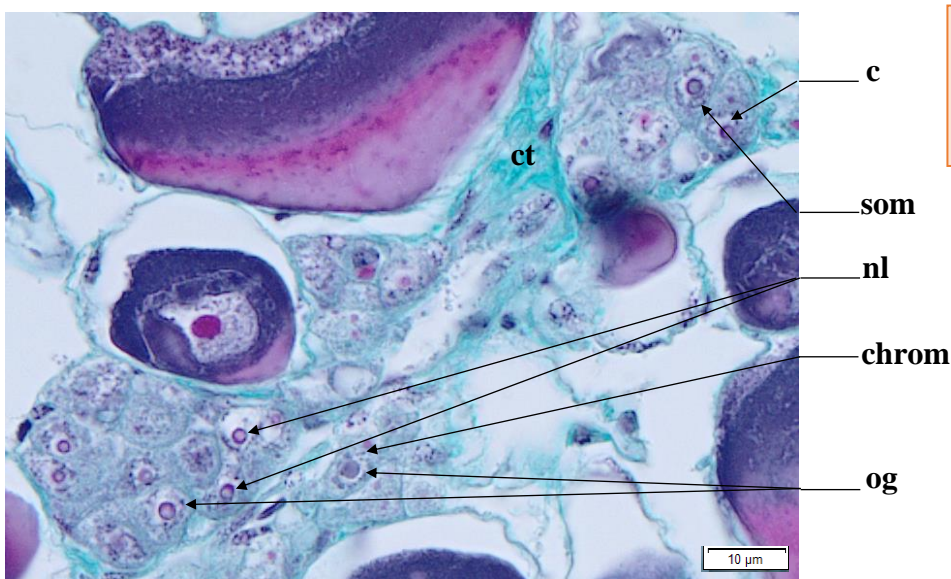
Empty theca, green colored like connective tissue. Macrophage cells may be present. Great variability in size and shape



Oogonium (og)

An oogonium (**og**) has a pale nucleus (**N**), due to low chromosome condensation, and a high nucleo-cytoplasmic (NC) ratio (very little cytoplasm). Chromatin clusters can be seen near the edges of the nucleus. Inside this nucleus, a single large nucleolus can generally be found. The cytoplasm (**c**) is light-colored (*Figure 6*). Oogonia stem from germinal cells through gonial mitosis. They can be found alone or in a germinal niche within the germinal epithelium, accompanied by somatic cells (**som**).

Identification : It is uncommon to fall on this very small sized cell. The **nucleus is light-gray and fully apparent** while the **cytoplasm is barely visible and very light-colored**. A **single light-colored and smooth nucleolus** can be present. The diameter of the nucleus of an oogonium is greater than the surface area of the cytoplasm (>50 %).



Average size
og : 7.44μm (±1.31μm)

Figure 6 : Germinal niche with oogonia (**og**) and their apparent, decondensed, nucleus (**N**) with a single large nucleolus (**nl**) and clusters of chromatin (**chrom**). Light-colored cytoplasm (**c**). Presence of somatic cells (**som**)

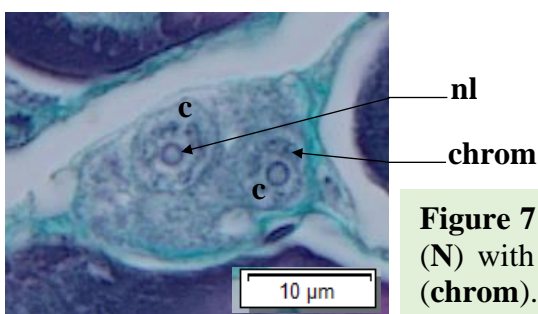
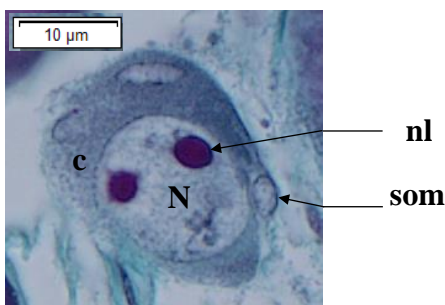


Figure 7 : Oogonia (**og**) and their apparent, decondensed, nucleus (**N**) with a single large nucleolus (**nl**) and clusters of chromatin (**chrom**). Light-colored cytoplasm (**c**).

Primary oocyte stage 1 (po1)

A primary oocyte stage 1 (**po1**) has a darker cytoplasm (**c**) compared to an oogonium (**og**), with a smaller **NC** ratio. The diameter of the cytoplasm is inferior or equal to 50 % of the nucleus' diameter. The nucleus (**N**) is spherical, smooth, with the possibility of one or two visible nucleolus.

Identification : This cell type is slightly bigger than an oogonium, but is still relatively small in size compared to the other cellular structures found inside the ovary. Falling on this follicle in stereology is still uncommon. The **nucleus must be fully visible, smooth**, and the **cytoplasm is darkly-colored**. The nucleus diameter of a **po1** is inferior or equal to 50 % of the cytoplasm's diameter, and can contain up to **2 nucleolus**. If there is a hesitation between a **po1** and a **po2**, the cell size can be taken into consideration.



Average size
po1 : 27.18μm (±7.05μm)

Figure 8 : Primary oocyte stage 1 (**po1**) with a spherical and smooth nucleus (**N**) with two nucleolus (**nl**). The cytoplasm (**c**) is darker compared to that of an oogonium (**og**). Somatic cells (**som**) can be seen

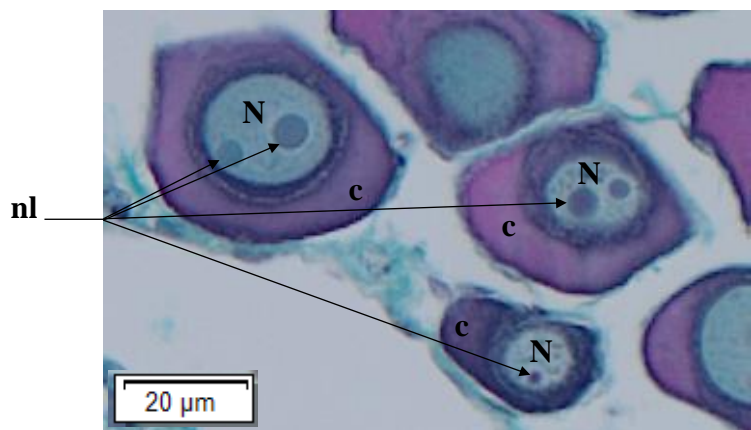


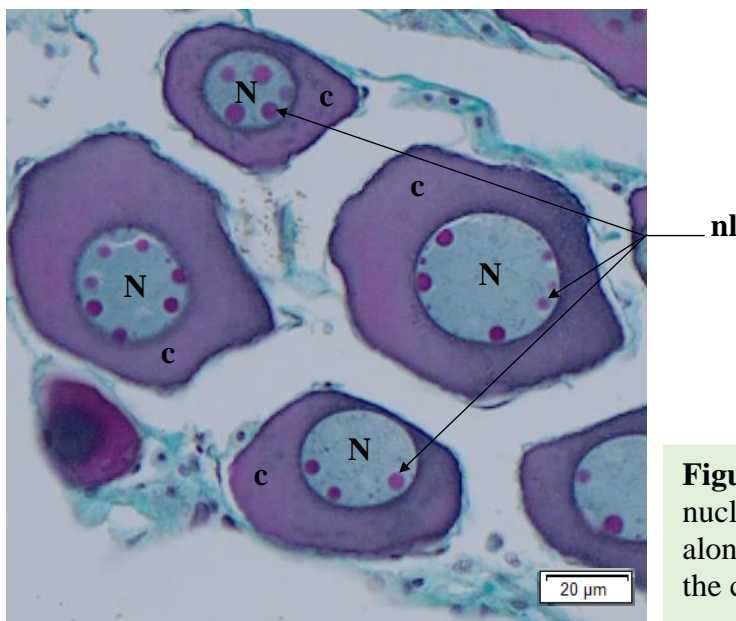
Figure 9 : Three primary oocyte stage 1 (**po1**) with a spherical and smooth nucleus (**N**) with a single, or two, nucleolus (**nl**). The cytoplasm (**c**) is darker compared to an oogonium (**og**)



Primary oocyte stage 2 (po2)

A primary oocyte stage 2 (**po2**) dark cytoplasm (**c**), with a high **NC** ratio. The diameter of the cytoplasm is superior to 50 % of the nucleus' diameter. The nucleus (**N**) is spherical, smooth, with the possibility of more than 3 large visible nucleolus present along the nuclear envelope. It is sometimes possible to see lampbrush chromosomes inside the nucleus, typically found in immature diplotene oocytes.

Identification : This ovarian follicle varies in size, between the **po1** and **cao** stage. The **nucleus must be fully visible, smooth, and the cytoplasm is darkly-colored**. The nucleus diameter of a **po2** is superior to 50 % of the cytoplasm's diameter, and can contain **3 or more large nucleoli** against the nuclear envelope. If there is a hesitation between a **po1** and a **po2**, the cell size can be taken into consideration.



Average size
po2 : 58.61μm (±9.27μm)

Figure 10 : A **po2**, with a spherical and smooth nucleus (**N**) filled with multiple nucleoli (**nl**) along the inside of its nuclear envelope, inside the cytoplasm (**c**)

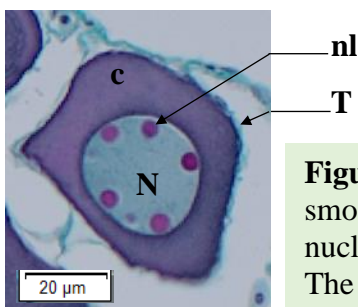


Figure 11 : A **po2**, with a spherical and smooth nucleus (**N**) filled with multiple nucleoli (**nl**) along its nuclear envelope. The theca (**T**) encases the cytoplasm (**c**)

Lipid droplet oocyte (ldo)

Before reaching the cortical alveoli (cao) stage, the follicle will grow in size and accumulate lipid droplets (ld) in its cytoplasm (c). These lipid droplets first appear along the outer periphery of the cytoplasm. They will then gather around the nucleus (N). The nucleus is smooth, round and contains multiple nucleoli (nl) against its nuclear membrane. Staining follicles Alcian blue shows that the vesicles in the cytoplasm are unstained : they do not contain acidic polysaccharides and probably consist in lipid droplets

Identification : A lipid droplet oocyte (ldo) is characterized by a **smooth and round nucleus** with **multiple nucleoli along its nuclear membrane**. **White lipid droplets are present in the cytoplasm**.

Average size

ldo : $89.10\mu\text{m} (\pm 10.81\mu\text{m})$

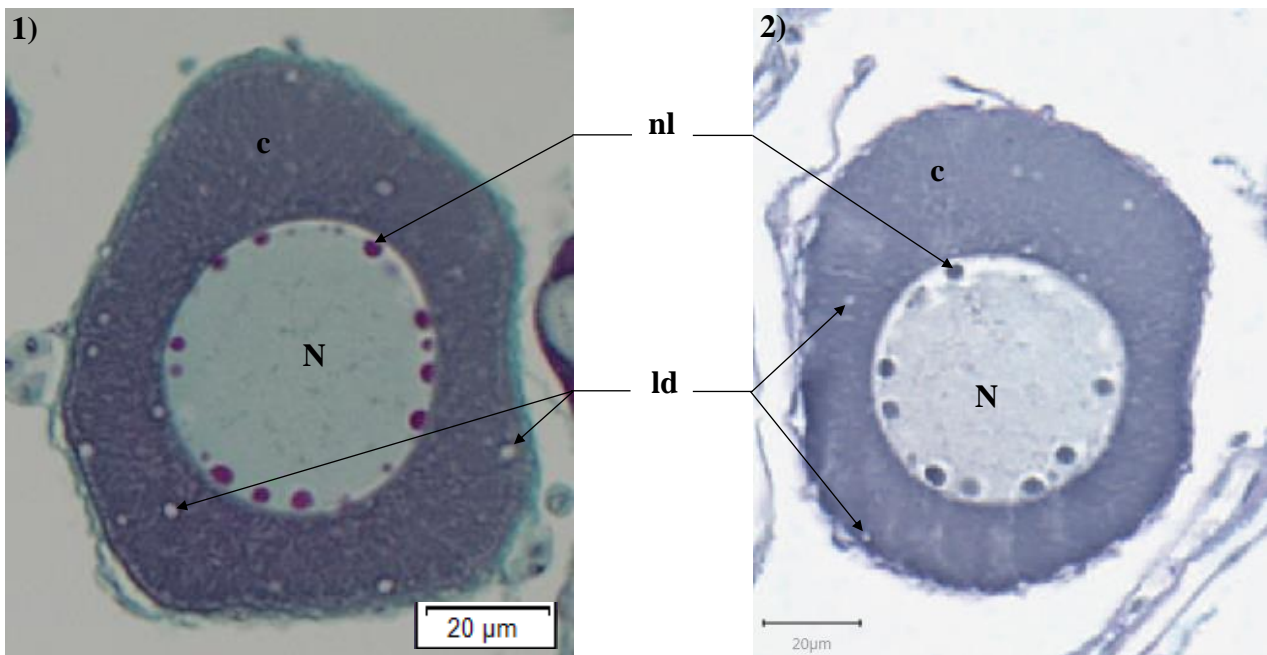


Figure 12 : A lipid droplet oocyte **1)** trichrome stained and **2)** Alcian blue stained. Lipid droplet oocytes (**ldo**) with lipid droplets (**ld**) in the cytoplasm (**c**). The nucleus (**N**) is round and smooth and holds multiple nucleoli (**nl**) along its nuclear envelope

Cortical alveoli oocyte (cao)

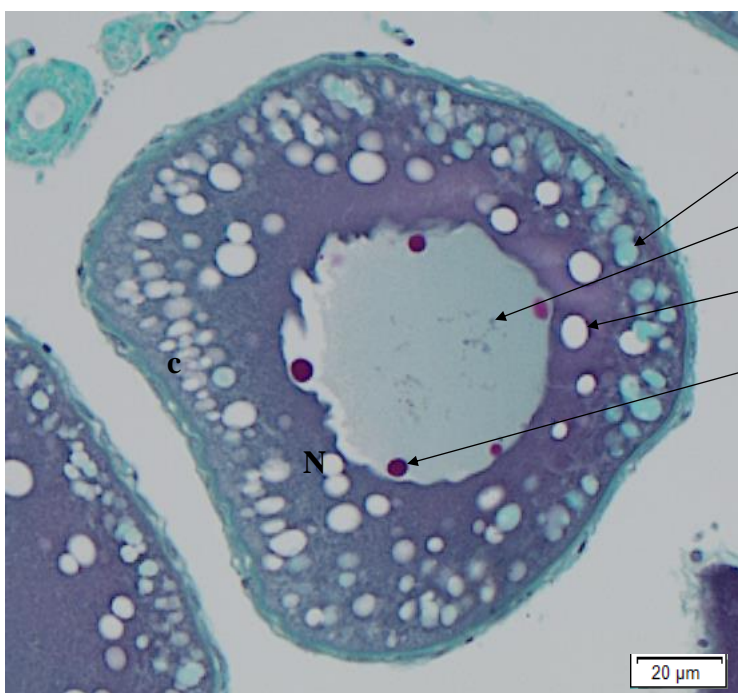
An oocyte with cortical alveoli (**cao**) is defined by a first appearance of cortical alveoli (**CA**) in the cytoplasm (**c**), on the periphery of the oocyte, under the somatic cells layer. The nucleus (**N**) is in the center of the cytoplasmic mass, with a smooth nuclear envelope and multiple nucleoli (**nl**) against it.

As the **cao** matures, the **CA** and lipid droplets (**ld**) will grow in size and take more place inside the cytoplasm, with the **CA** against the outer periphery in the cytoplasm while the **ld** are centered around the nucleus. At this point, the nucleus is scalloped and filled with multiple nucleoli against the nuclear envelope.

The somatic cell layer (**som**) will start to grow and the *zona radiata* (**zr**) will start to form. Sometimes, it is possible to see lampbrush chromosomes (**chr**) inside the nucleus, typically found in immature diplotene oocytes.

The **CA** will take a lot of space inside the cytoplasm and can be mistaken with lipid droplets (Anderson, 1968 ; Tyler et Sumpter, 1996). The **CA** will appear in the outer periphery of the outer cytoplasm. The Alcian blue coloration, as well as the trichrome stain, allows us to differentiate them from lipid droplets. With the trichrome stain, the **CA** will take a mint color, while they will take a purple color with the Alcian blue stain (*cf Figure 14*), revealing the presence of acidic polysaccharides.

Identification : An oocyte with cortical alveoli is primarily defined by the **presence of cortical alveoli in the cytoplasm**, with a first appearance on the outer periphery of the cytoplasm. The **nucleus in the center of the follicle contains multiple nucleoli** along its nuclear envelope, and the **nuclear envelope will become scalloped as the cell approaches the vitellogenic stage**. It is possible to see condensed chromosomes (small irregular dark-gray lines inside the nucleus).



Average size

cao : 161.90μm (±40.21μm)

zr : 1.17μm (±0.29μm)

Figure 13 : Cortical alveoli oocyte (**cao**) with a smooth nucleus (**N**) holding multiple nucleoli (**nl**) and lampbrush chromosomes (**chr**). Cortical alveoli (**CA**) and lipid droplets (**ld**) build-up in the cytoplasm (**c**)

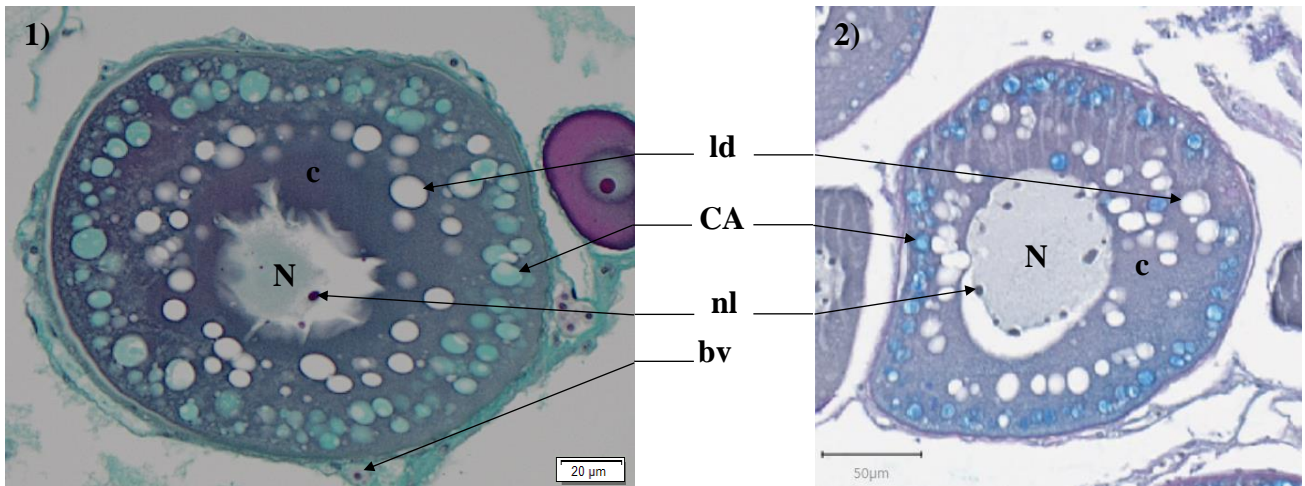


Figure 14 : Cortical alveoli (CA) will come out mint colored with a 1) Gabe trichrome stain, and dark blue with a 2) Alcian blue stain. Here, the cortical alveoli oocytes (cao) have a scalloped nucleus (N) holding multiple nucleoli (nl). Cortical alveoli (CA) build-up in the cytoplasm (c) near the outer periphery of the follicle while lipid droplets (ld) gather around the N. Presence of blood vessels (bv)

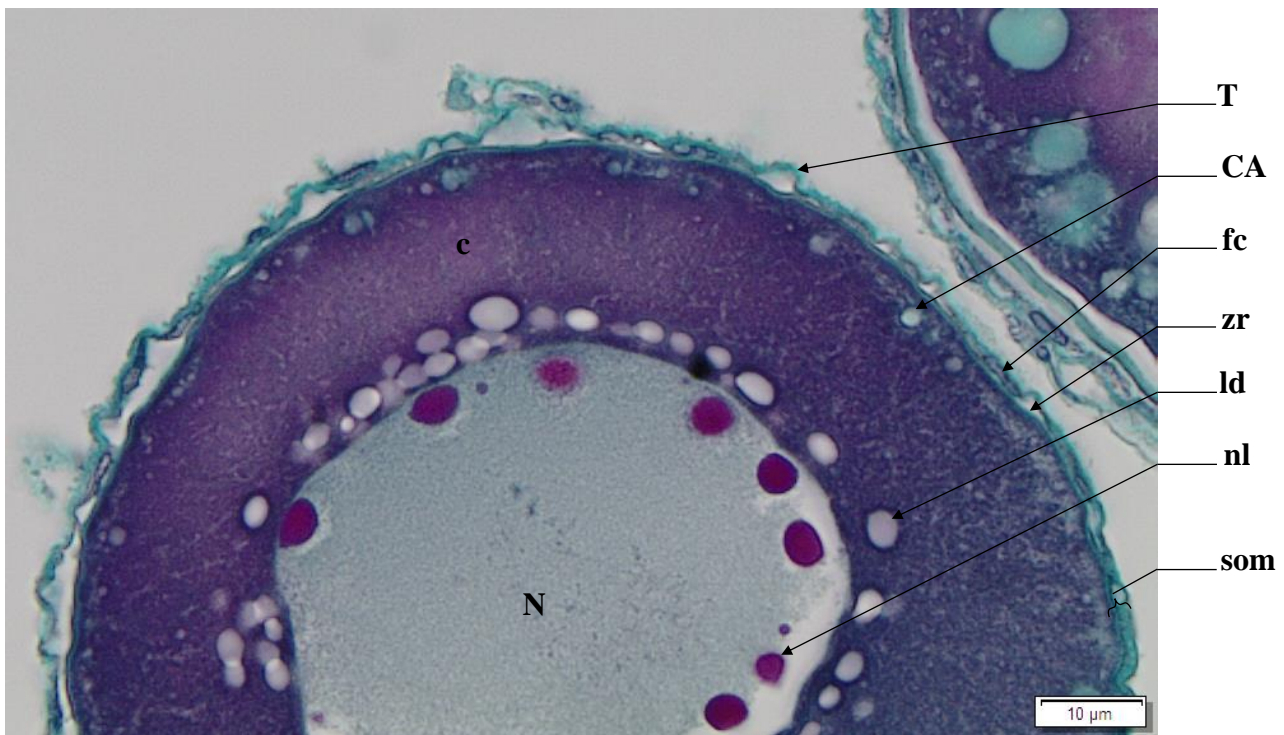


Figure 15 : Cell wall of an oocyte with cortical alveoli (cao) appearing. The nucleus (N) is starting to scallop and contains multiple nucleoli (nl) along its nuclear envelope. Lipid droplets (ld) build-up around the N, in the cytoplasm (c). Cortical alveoli (CA) start to form on the periphery of the cytoplasm, under the somatic cell layer (som) that is beginning to grow, with presence of a green zona radiata (zr) and follicular cells (fc) under the theca (T)



Oocyte in early vitellogenesis (vtg1)

An oocyte at the beginning of the vitellogenic stage (**vtg1**) is defined by the presence of vitellus droplets (**vd**), pink eosinophilic droplets, that form in the periphery of the cytoplasm (**c**), under the somatic cell layer. The *zona radiata* (**zr**) will start developing between the cytoplasm and the follicular cells (**fc**) + theca (**T**). The *zona radiata* (**zr**) is thin and green (not acidophilous). The nucleus (**N**) is still centered in the follicle, with multiple nucleoli (**nl**) along the scalloped nuclear envelope.

As the cell matures, the vitellus droplets (**vd**), lipid droplets (**ld**) and cortical alveoli (**CA**) will grow in size in the cytoplasm (**c**).

Identification : This oocyte in early vitellogenesis is recognizable by the appearance of a **pink vitellus droplets in the outer periphery of the cytoplasm**. At the **first appearance of a vitellus droplet**, the oocyte is considered to be in the **vtg1** stage. The **nucleus is scalloped and centered inside the follicle**, containing multiple the nucleoli. **Vitellus droplets will run along the edge of the inner cell wall, along the *zona radiata* (zr)**. **The *zona radiata* (zr) is small and green**, as it starts to grow under the Theca (**T**). Even if the nucleus is not visible, if vitellus droplets are visible, this follicle should be placed in the **vtg1** category.

Average size

vtg1 : 238.36 μ m (\pm 36.50 μ m)

zr : 1.89 μ m (0.37 \pm μ m)

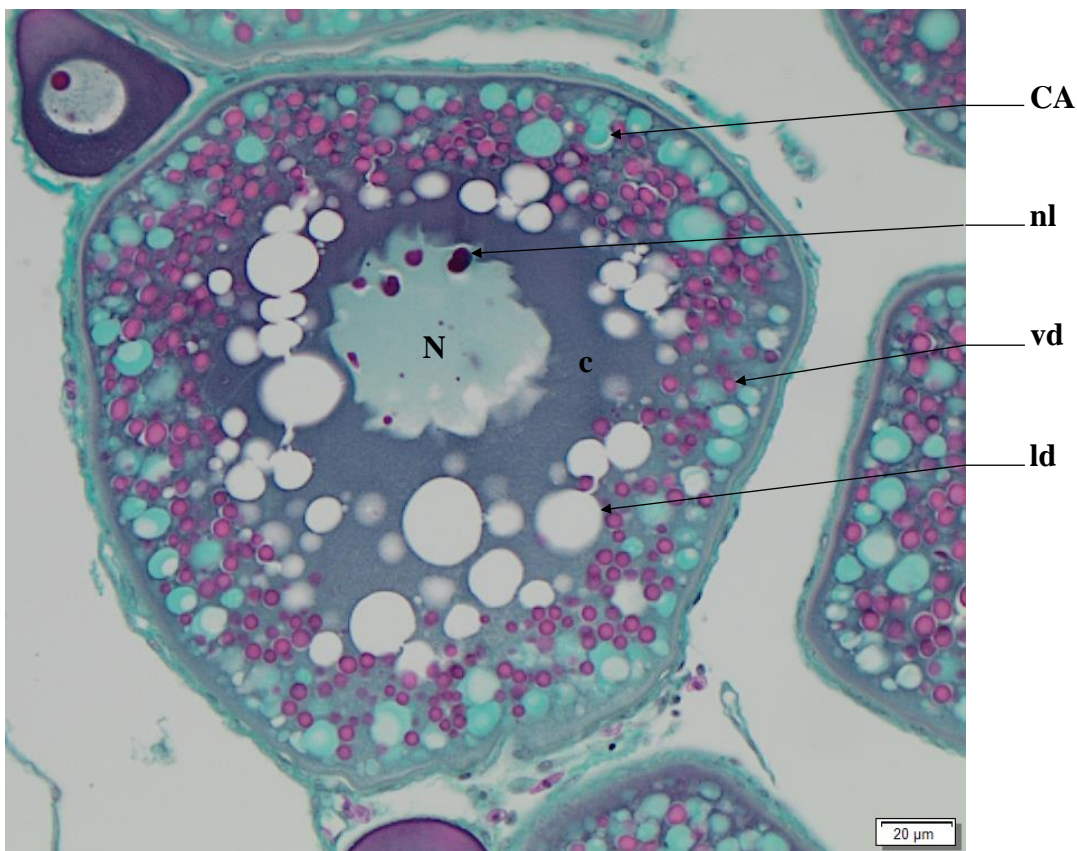


Figure 16 : A stage **vtg1** oocyte, with a scalloped nucleus (**N**) envelope containing multiple nucleoli (**nl**). Vitellus droplets (**vd**) will form on the outer periphery of the cytoplasm (**c**). Large cortical alveoli (**CA**) and lipid droplets (**ld**) are also present. Gabe trichrome stain

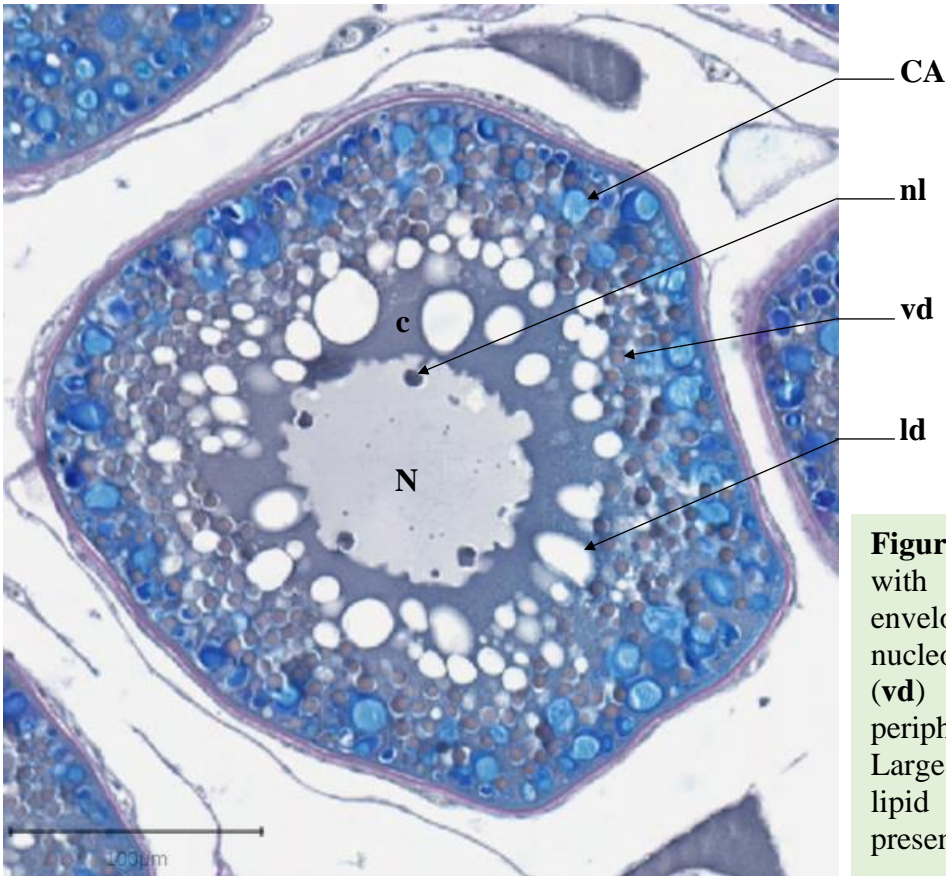


Figure 17 : A stage **vtg1** oocyte, with a scalloped nucleus (**N**) envelope containing multiple nucleoli (**nl**). Vitellus droplets (**vd**) will form on the outer periphery of the cytoplasm (**c**). Large cortical alveoli (**CA**) and lipid droplets (**ld**) are also present. Alcian blue stained

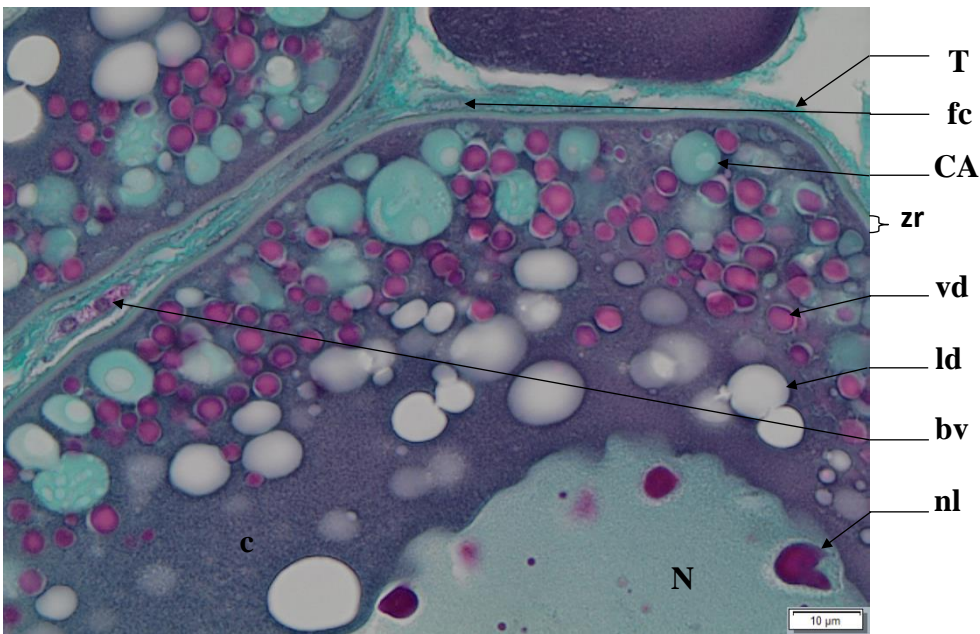


Figure 18 : Cell wall of a **vtg1** oocyte with a scalloped nucleus (**N**) envelope containing multiple nucleoli (**nl**). Vitellus droplets (**vd**) form on the outer periphery of the cytoplasm (**c**), amongst the cortical alveoli (**CA**). Presence of lipid droplets (**ld**) in the **c**. Follicular cells (**fc**) are present in the theca (**T**), with the *zona radiata* (**zr**) under these cell layers. Presence of blood vessels (**bv**) near the **T**



Oocyte in vitellogenesis stage 2 (vtg2)

During the **vtg2** stage, the *zona radiata* (**zr**) thickens and becomes striated as it takes on a pink tinge. The vitellus droplets (**vd**) will take up the entire space inside the follicle as they start to fuse together and grow in size. The lipid droplets (**ld**) fuse together into larger masses. The nucleus (**N**) is still scalloped and contains multiple nucleoli (**nl**).

Identification: A **vtg2** oocyte is defined by a **pink, thick and striated zr**, as well as **small to medium sized vitellus droplets (vd) that take up the entire space inside the follicle**. Lipid droplets (**ld**) have fused into bigger masses. It is preferable, but not mandatory for the nucleus to be visible.

Average size

vtg2 : 436.20 μ m (\pm 66.51 μ m)

zr : 4.96 μ m (\pm 1.34 μ m)

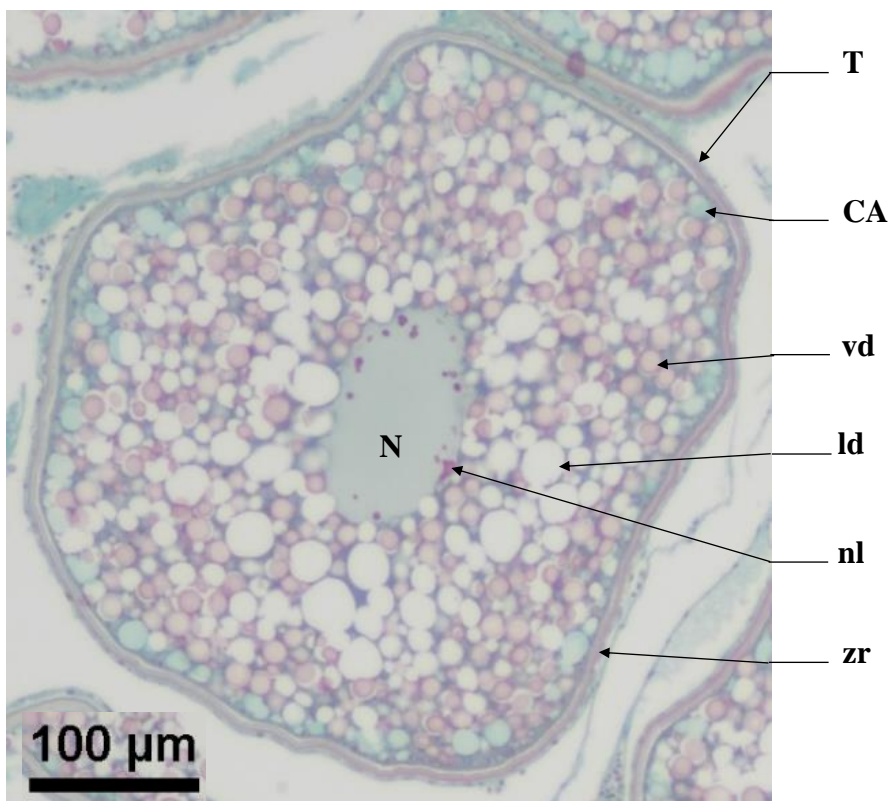


Figure 19 : Stage **vtg2** oocyte in its theca (**T**), with a scalloped nucleus (**N**) containing multiple nucleoli (**nl**). The *zona radiata* (**zr**) is pink. Medium sized vitellus droplets (**vd**) take up the entire space inside the follicle. Large lipid droplets (**ld**) and cortical alveoli (**CA**) are also present

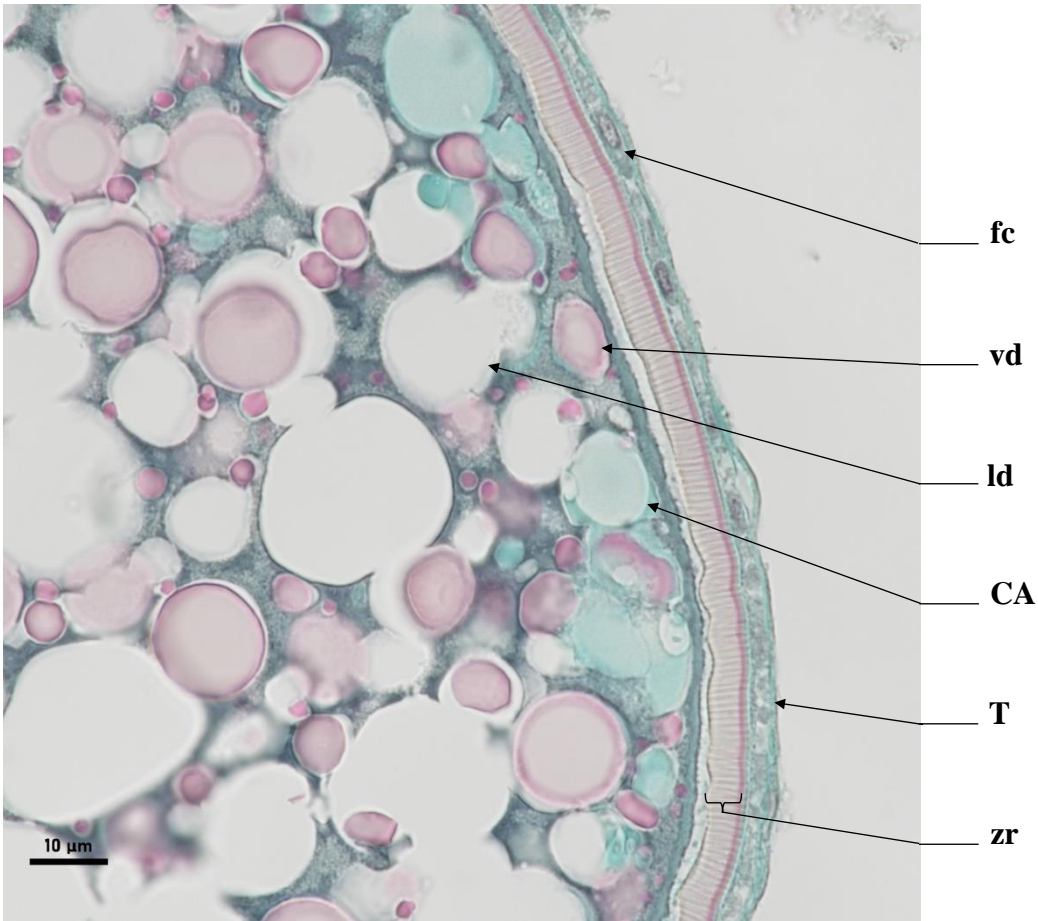


Figure 20 : Cell wall of an oocyte in vitellogenesis stage 2 (**vtg2**). The *zona radiata* (**zr**) is pink and striated, under the theca (**T**) and follicular cells (**fc**). Cortical alveoli (**CA**) grow in size, as well as the lipid droplets (**ld**) and vitellus droplets (**vd**) that take up the entire space within the follicle

Oocyte in hydration (oih)

During the **oih** stage, the nucleus (N) will migrate towards the oocyte's periphery. The lipidic droplets (**ld**) grow in size and are present throughout the entire follicle. Large cortical alveoli (**CA**) are found under the pink and striated *zona radiata* (**zr**). Vitellus droplets (**vd**) will fuse into a homogeneous mass, the basiphilic vitellus (**vi**) taking a dark green-blue tint with the trichrome stain.

Identification : The **vd** fuse into an dark blue-green homogeneous mass, with pink vitellus droplets still present. The *zona radiata* is at its thickest, pink and striated. The nucleus can be seen, but its visibility is not mandatory for the identification of this stage.

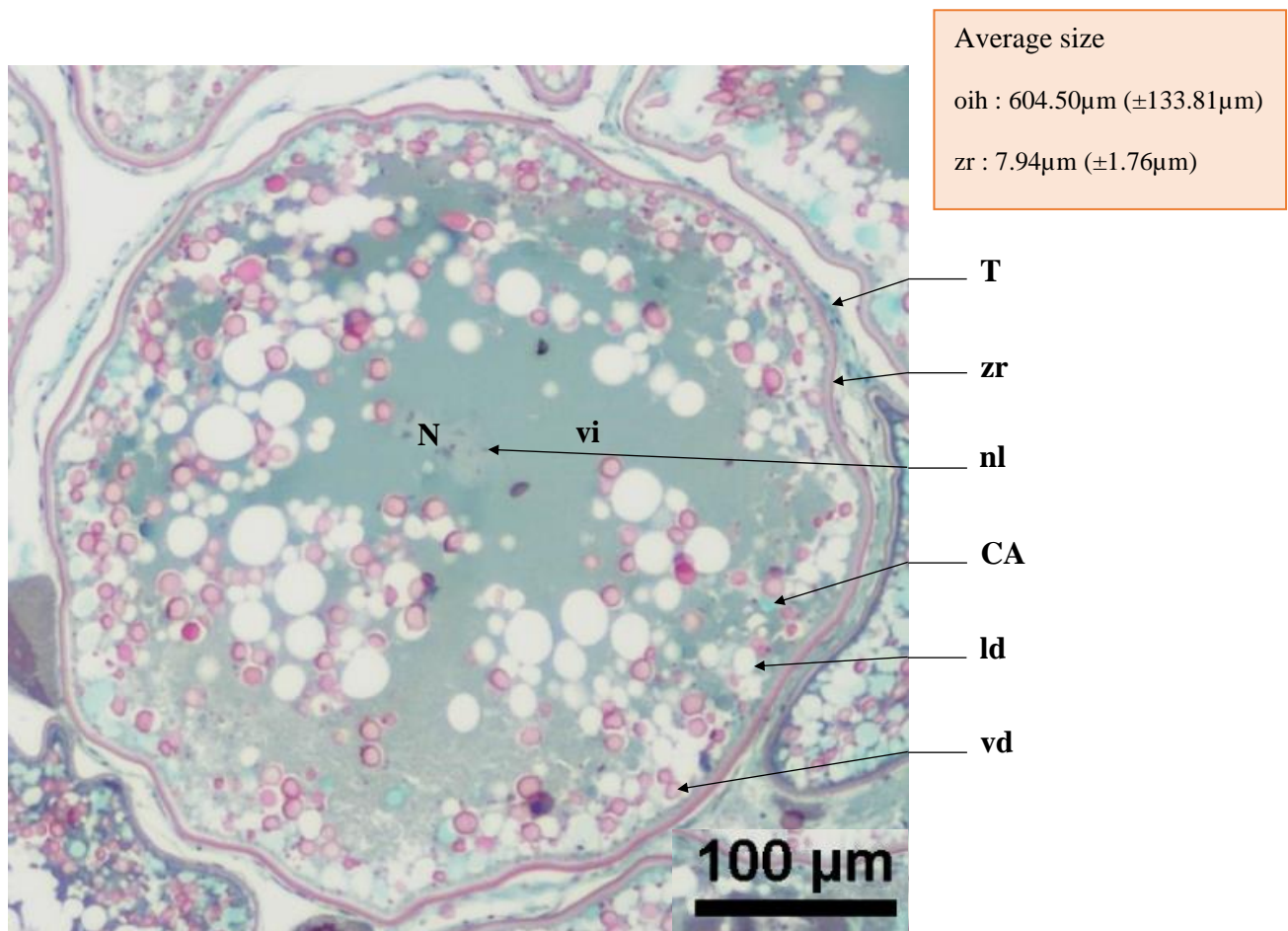
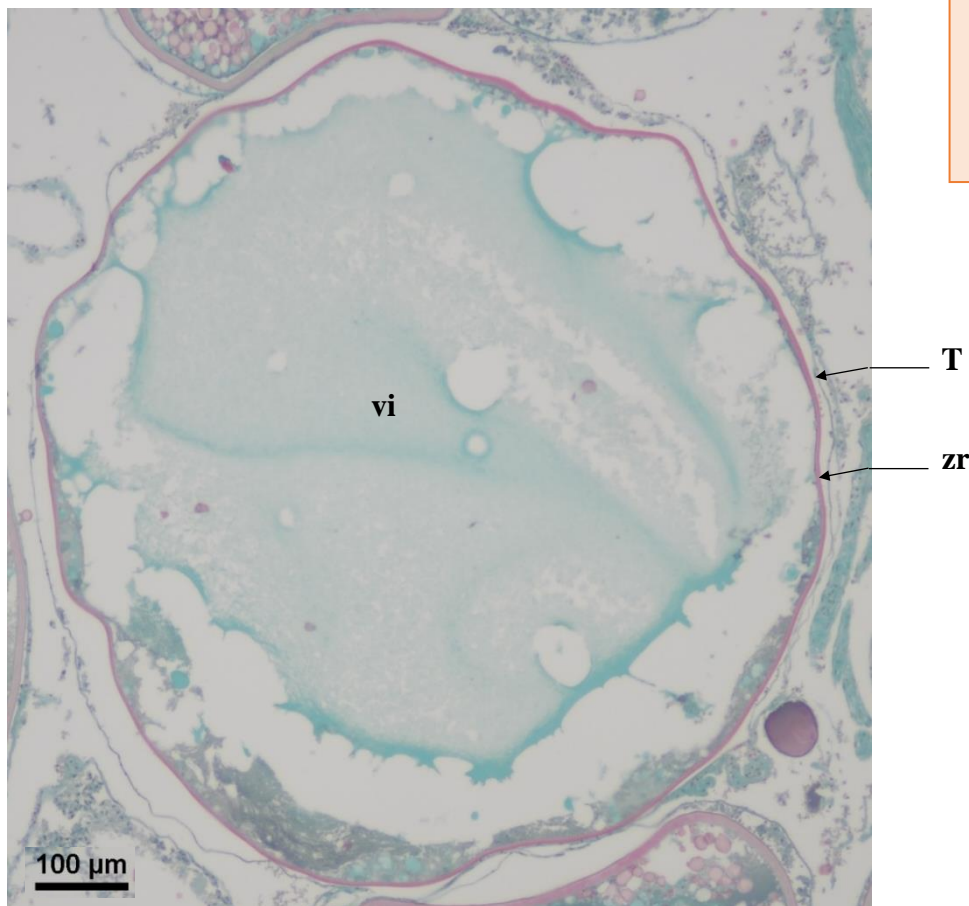


Figure 21 : Oocyte in hydration (**oih**). Cortical alveoli (**CA**) can be seen under the *zona radiata* (**zr**) that is at its thickest, pink and striated under the theca (**T**). Vitellus droplets (**vd**) fuse into a homogeneous vitellus (**vi**). Lipid droplets (**ld**) are present and the nucleus (**N**) contains multiple nucleoli (**nl**)

Hydrated oocyte (ho)

A hydrated oocyte (**ho**) is defined by a blue homogenous vitellus (**vi**) and a pink and striated *zona radiata* (**zr**).

Identification : Biggest germ cell type found in the ovary. The dehydration process during the slide mounting can lead to deformed oocytes, with a theca (**T**) that may be detached from the *zona radiata* (**zr**). Whether this oocyte has been discharged from its follicle in the lamella or not, this cell type will be categorized as **oh**. The **zr** is **pink, thick and striated**, and the oocyte is filled entirely with **homogeneous vitellus (turquoise blue color)**.



Average size

ho : 822.38μm (±62.92μm)

zr : 5.00μm (±0.82μm)

Figure 22 : Hydrated oocyte (**oh**) that has not been discharged, still encased within its theca (**T**), with a homogeneous vitellus (**vi**) and a pink and striated *zona radiata* (**zr**)

Post-Ovulatory Follicle (POF)

A Post-Ovulatory Follicle (**POF**) may show signs of lysis, with the presence of macrophage cells (**mc**) inside their cavity. A **POF** indicates that a hydrated oocyte (**oh**) has been discharged into the lumen. A **POF** is composed of all the somatic tissues of the follicle (theca (**T**) and follicular cells (**fc**) left behind after the mature oocyte (**oh**) has been discharged into the lumen. Their green dye is identical to that of connective tissue (**ct**). **POF** vary in size and shape and are essentially empty sockets that have receded onto themselves.

Identification : A **POF** is a sack of somatic tissue that may be identified by the presence of macrophage cells (**mc**) inside its cavity. Macrophage cells are very small, gray tinged, and are often found clustered together. A **POF** will vary greatly in size and shape and can easily be mistaken with connective tissue (**ct**).

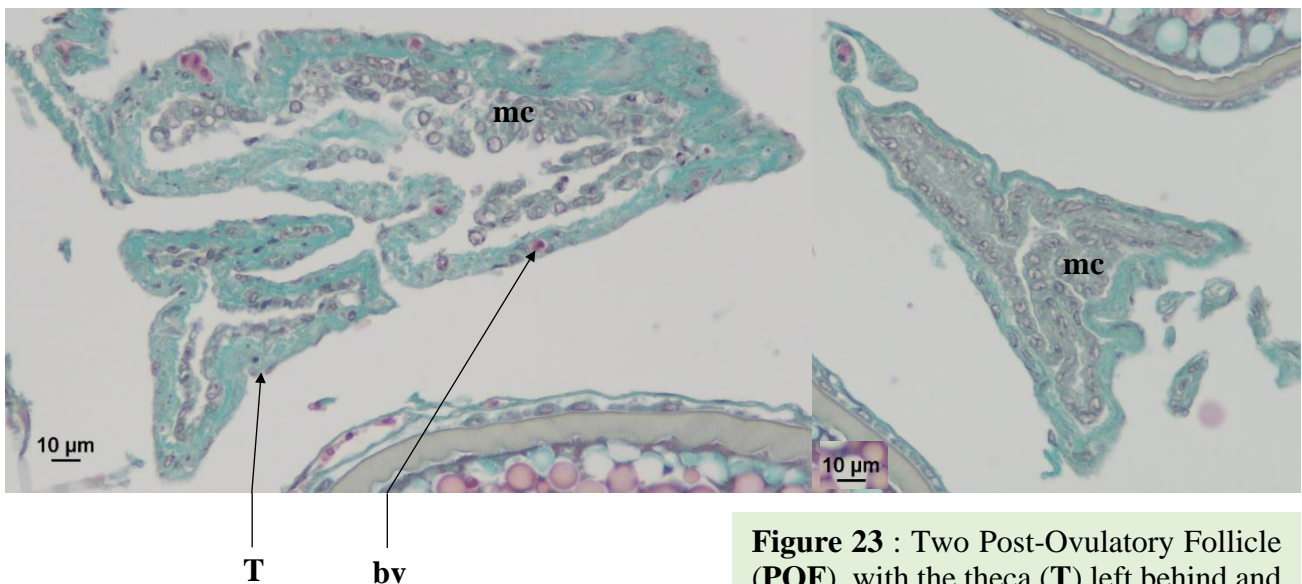


Figure 23 : Two Post-Ovulatory Follicle (**POF**), with the theca (**T**) left behind and blood vessels (**bv**). Macrophage cells (**mc**) are present in the **POF**'s cavity

Atresia (aoA & aoB) and Lysis (L)

Torres-Martínez *et al.* (2017) define atresia as the degeneration, reabsorption, or even ablation, of ovarian follicles. In general, the first sign of atresia is the degeneration of the germinal vesicle of the oocyte, followed by the fragmentation of the *zona radiata* (**zr**) that will take an irregular appearance. This will lead to an hypertrophy of the follicular cells. There can be cell differentiations of the follicular cells (**fc**) into phagocytes and/or macrophages.

In this study, we will define two types of atresia. Oocytes in early atresia (**aoA**) and oocytes in late atresia (**aoB**). **aoA** are all germinal cells in lysis, from the oogonium (**og**) stage until the **undischarged** hydrated oocyte (**oh**) stage. They will always be encased in somatic cells (follicular cells (**fc**) and/or theca (**T**)). **aoB** are all hydrated oocytes in lysis that have been **discharged** and are thus not encased in somatic cells anymore. Since an **aoB** is a cellular structure in lysis in the middle of the **lumen**, their shapes will often be warped, scattered and surrounded by lysis (**L**).

Identification : An **aoA** is a **follicle in lysis**. This means that the **oocyte is still encased inside a theca, within the ovarian lamella**.

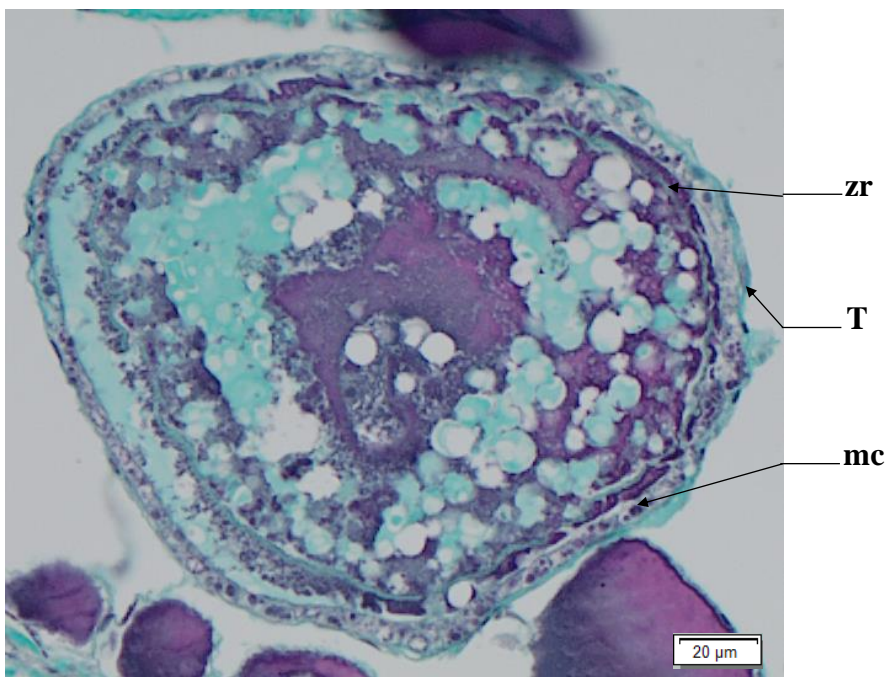


Figure 24 : Oocyte in early atresia (**aoA**). The oocyte has not been discharged into the **lumen**, and the follicle is still encased by its theca (**T**). the *zona radiata* (**zr**) is distorted and macrophage cells (**mc**) can be seen between the **zr** and **T**

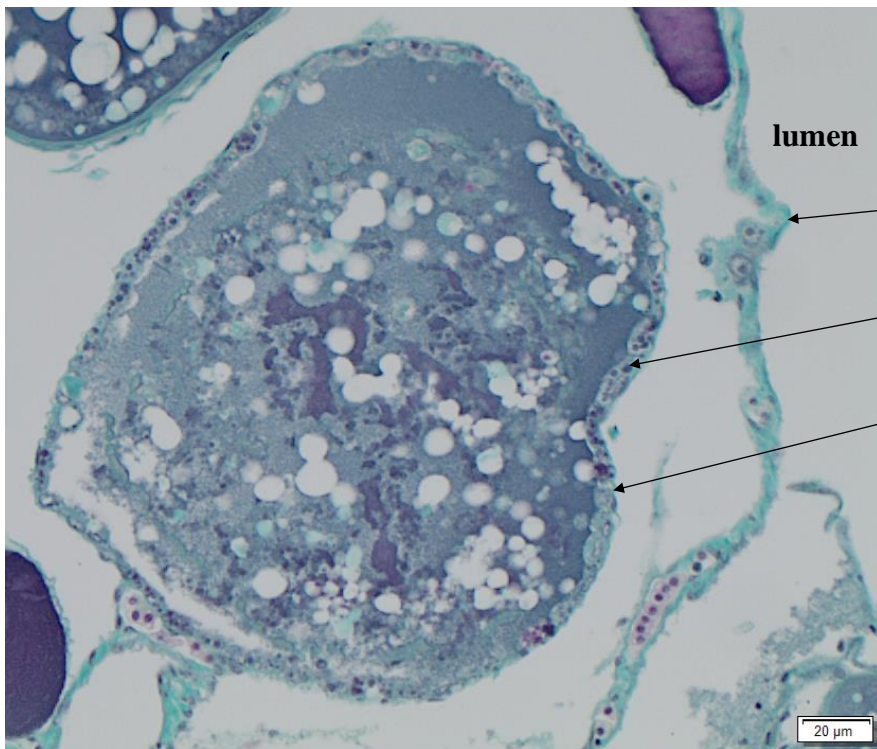


Figure 25 : Presence of macrophages (mc) under the theca (T) of an oaA still inside the connective tissue (ct) of the ovarian lamella

Identification : An oaB is a **discharged follicle in lysis**. This means that the **oocyte is in the lumen without a theca** and is undergoing lysis. The mature follicle may show fragmentation of its *zona radiata* (zr) that will take an irregular appearance. Possible presence of macrophage cells lysis.

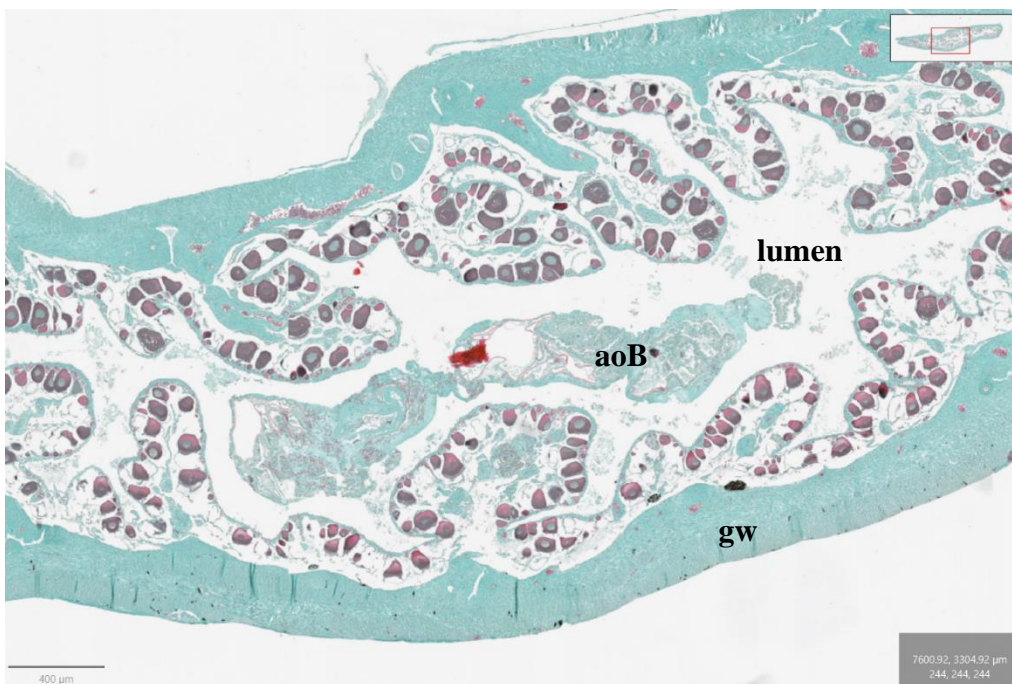


Figure 26 : aoB is a hydrated oocyte in lysis, no longer encased in a theca and is in the **lumen** of the ovary

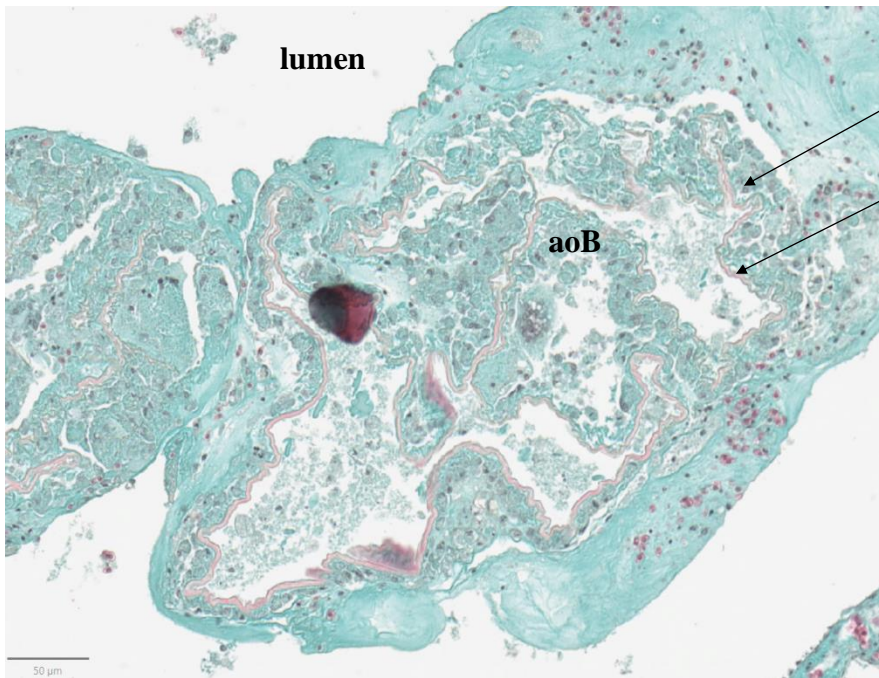


Figure 26 : aoB is a hydrated oocyte in lysis surrounded by macrophage cells (**mc**) and is in the **lumen** of the ovary. No longer encased in a theca, the **zr** is still present

Identification : Lysis can be difficult to identify, especially with the presence of atresia. They can be found **anywhere inside the gonad, at any maturity phase**. This **cluster of cells in lysis** can contain macrophages, are of **different shapes and sizes**, and do **not possess a theca and/or zona radiata**

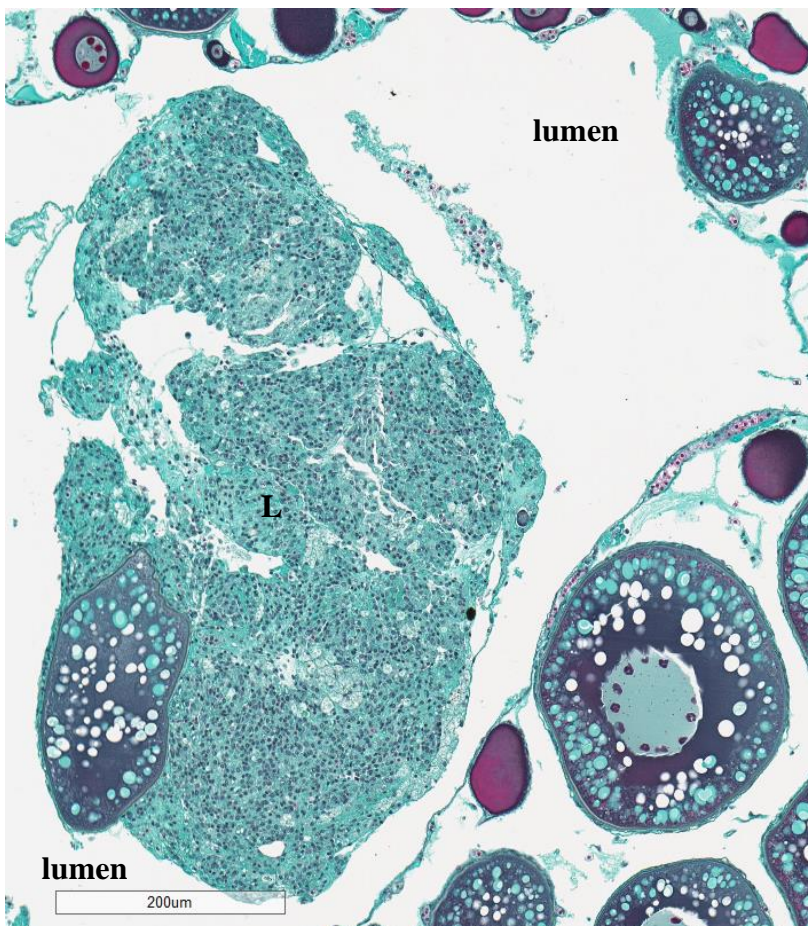


Figure 27 : Lysis (L) in the **lumen**

Connective tissue (ct) & Gonadal wall (gw)

The connective tissue (**ct**) links all of the ovarian structures together to form the ovarian lamellas. Follicles can be found inside the ovarian lamellas, encased in **ct**.

Connective tissue (**ct**) is made of green-colored cells, just like the cells that make up the gonad wall (**gw**). Gonad wall cells are muscular tissue while **ct** is not. Be wary not to mix the both up! Even if a sampling point falls on a very small piece of **ct** in the middle of a wide expanse of intercellular space (**Is**), this sampling point will be classified under **ct**.

The gonad wall (**gw**) will have the same green tint as the **ct**. Muscle bundles and blood vessels (**bv**) can be found in the **gw**. If a sampling point falls on muscular tissue within the **gw**, then the sampling point will be put into the **gw** category. On the other hand, if a sampling point within the **gw** falls on a blood vessel (**bv**), then this structure will be classified under **bv**.

The boundary of the **gw** starts from the outer most cell layer of the gonad and ends at the inner most cell layer of the gonad wall (**gw**), just before entering into the ovarian lamellas. If the **gw** has been stretched, ripped or spread, but the sampling point lands between the inner and outer most cell layers before the ovarian lamellas, then the sampling point will be classified under the **gw** category. Do not hesitate to unzoom in order to obtain a more general view of where the sampling point is in the gonad. This will allow the reader a better view of where the **gw** ends and the **ct** starts.

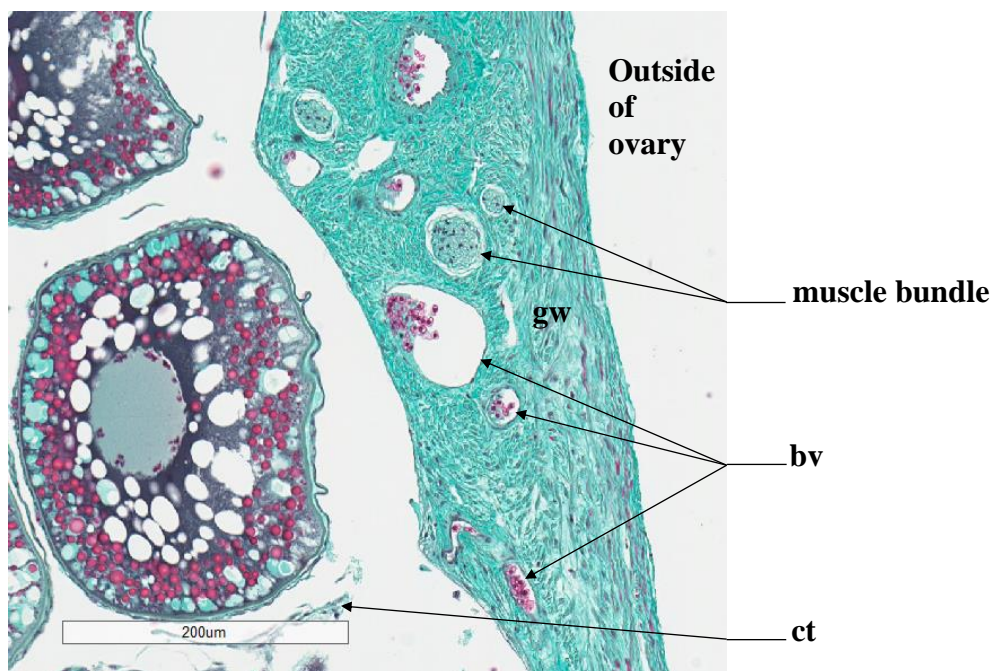


Figure 28 : Cross section of a megrim ovary with its gonad wall (**gw**). The ovarian lamellas are held together by connective tissue (**ct**), delimiting the **lumen** and the outside of the ovary. Blood vessels (**bv**) and **muscle bundles** can be seen

Blood vessel (bv)

Blood vessels (**bv**) are numerous and of variable diameter, with a size that can vary from that of a single cell to over 100µm.

Found within the theca (**T**), inside germinal epithelium or the gonad wall (**gw**), blood vessels (**bv**) are identifiable by the presence of blood cells (small red cells with a darker nucleus). If a sampling point falls in the « white zone » inside a cavity containing blood cells, this sampling point will be classified under the **bv** category.

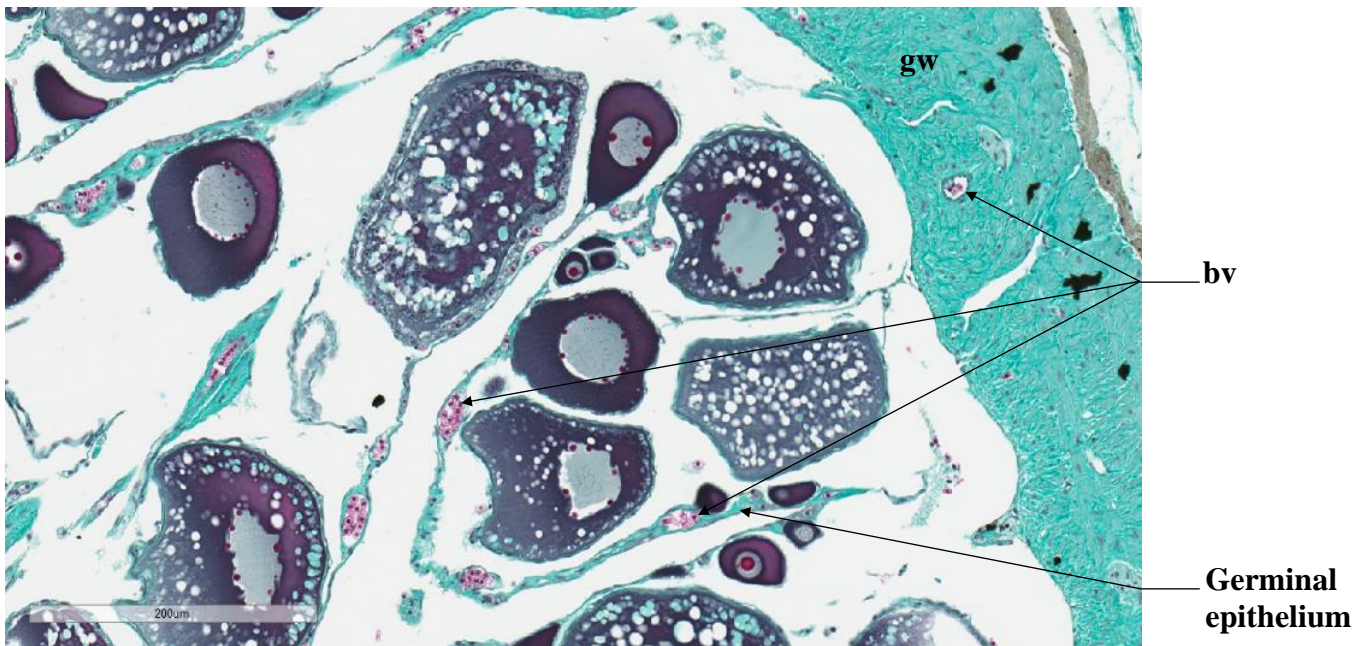


Figure 29 : Presence of blood vessels (**bv**) in the **germinal epithelium**, as well as in the gonadal wall (**gw**).

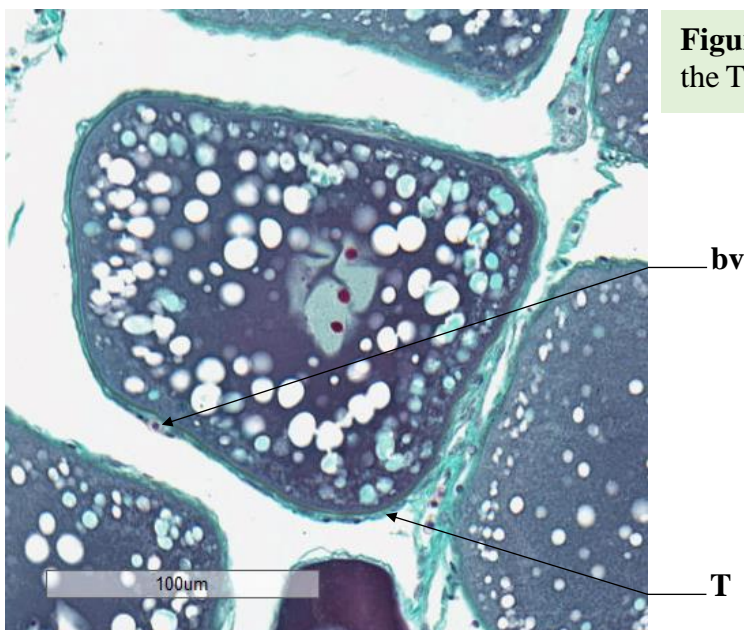


Figure 30 : Presence of a blood vessel (**bv**) in the Theca (**T**) of an cortical alveoli oocyte (**cao**)

Bibliography

Anderson, E., 1969. Oocyte-follicle Cell Differentiation in Two Species of Amphineurans (Mollusca), *Mopalia mucosa* and *Chaetopleura apiculata*. J. Morphol. 129, 89-126.

Anderson, E., 1968. Cortical alveoli formation and vitellogenesis during oocyte differentiation in the Pipefish, *Syngnathus fuscus*, and the Killifish, *Fundulus heteroclitus*. J. Morphol. 125, 23-60.

Aragón, L., Aranda, G., Santos, A., Medina, A., 2010. Quantification of ovarian follicles in bluefin tuna *Thunnus thynnus* by two stereological methods. J. Fish Biol. 77, 719-730.

Brown-Peterson, N.J., Wyanski, D.M., Saborido-Rey, F., Macewicz, B.J., Lowerre-Barbieri, S.K., 2011. A Standardized Terminology for Describing Reproductive Development in Fishes. Mar. Coast. Fish. 3, 52-70.

Domínguez-Castanedo, O., Uribe, M.C., Rosales-Torres, A.M., 2016. Morphological development of the structures related to annualism in the ovarian follicle of the killifish *Millerichthys robustus* (Costa,1995) (Teleostei: Cyprinodontiformes). J. Morphol. 277, 1219-1230.

Gabe, M., 1968. Techniques Histologiques, 2ème ed. Masson et C., Paris.

ICES, 2008. Report of the Workshop on Maturity Ogive Estimation for Stock Assessment (WKMOG), 3-6 June 2008, Lisbon, Portugal. ICES CM2008/ACOM:33. 72 pp.

ICES, 2010. Report of the ICES/HELCOM Workshop on Flatfish in the Baltic Sea (WKFLABA), 8-11 November 2010, Öregrund, Sweden. ICES CM 2010/ACOM:68. 85pp.

ICES, 2014. Report of the Workshop for maturity staging chairs (WKMATCH), 11-15 June 2012, Split, Croatia. ICES CM 2012/ACOM:58. 57 pp.

ICES, 2018. Report of the Workshop for Advancing Sexual Maturity Staging in Fish (WKASMSF), 30 April - 4 May 2018, ICES Headquarters, Copenhagen, Denmark. ICES CM/EOSG: 38. 75 pp.

ICES, 2019. Working Group on Biological Parameters (WGBIOP), 7-10 October 2019, Lisbon, Portugal. ICES Scientific Reports. 1:85. 93 pp.

Lowerre-Barbieri, S.K., Brown-Peterson, N.J., Murua, H., Tomkiewicz, J., Wyanski, D.M., Saborido-Rey, F., 2011. Emerging Issues and Methodological Advances in Fisheries Reproductive Biology. Mar. Coast. Fish. 3, 32-51

Robson, S.M., 2004. Age, growth, reproductive biology and population dynamics of the common megrim *Lepidorhombus whiffiagonis* (Walbaum, 1792) from off the west coast of Ireland. Unpublished thesis (Doctor of Philosophy in Fisheries Biology), Galway-Mayo Institute of Technology.

Sauger, C., Quinquis, J., Dubroca, L., Parrad, S., Kellner, K., Heude-Berthelin, C., 2019. Sample collection protocol for the extraction of female gonads in the megrim (*Lepidorhombus spp.*) for maturity staging through histology. IFREMER, <https://doi.org/10.13155/70724>

Sauger, C., Dubroca, L., Villain-Naud, N., Kellner, K., Heude-Berthelin, C., Elie, N., 2020. Protocol for the determination of histological structures found in the ovaries and during the oogenesis of the megrim, *Lepidorhombus whiffiagonis* (Walbaum, 1792). IFREMER

Torres-Martínez, A., Hernández-Franyutti, A., Uribe, M.C., Contreras-Sánchez, W.M., 2017. Ovarian structure and oogenesis of the extremophile viviparous teleost *Poecilia mexicana* (Poeciliidae) from an active sulfur spring cave in Southern Mexico. *J. Morphol.*, Wiley Periodicals 278, 1667-1681.

Tyler, C.R., Sumpter, J.P., 1996. Oocyte growth and development in teleosts. *Rev. Fish Biol. Fish.*, Chapman & Hall 6, 287-318.

