



HAL
open science

Toxicities associated with sequential or combined use of immune checkpoint inhibitors and small targeted therapies in non-small cell lung cancer: A critical review of the literature

Anne-Laure Désage, Michaël Duruisseaux, Claire Lafitte, Sophie Bayle-Bleuez, Christos Chouaid, Pierre Fournel, Thomas Pierret

► To cite this version:

Anne-Laure Désage, Michaël Duruisseaux, Claire Lafitte, Sophie Bayle-Bleuez, Christos Chouaid, et al.. Toxicities associated with sequential or combined use of immune checkpoint inhibitors and small targeted therapies in non-small cell lung cancer: A critical review of the literature. *Cancer Treatment Reviews*, 2024, 129, 10.1016/j.ctrv.2024.102805 . hal-04728403

HAL Id: hal-04728403

<https://hal.science/hal-04728403v1>

Submitted on 9 Oct 2024

HAL is a multi-disciplinary open access archive for the deposit and dissemination of scientific research documents, whether they are published or not. The documents may come from teaching and research institutions in France or abroad, or from public or private research centers.

L'archive ouverte pluridisciplinaire **HAL**, est destinée au dépôt et à la diffusion de documents scientifiques de niveau recherche, publiés ou non, émanant des établissements d'enseignement et de recherche français ou étrangers, des laboratoires publics ou privés.



Distributed under a Creative Commons Attribution - NonCommercial - NoDerivatives 4.0 International License



Complications of Treatment

Toxicities associated with sequential or combined use of immune checkpoint inhibitors and small targeted therapies in non-small cell lung cancer: A critical review of the literature

Anne-Laure Désage^{a,*}, Michael Duruisseaux^{b,c,d}, Claire Lafitte^b, Sophie Bayle-Bleuez^a, Christos Chouaid^e, Pierre Fournel^a, Thomas Pierret^b

^a Department of Pulmonology and Thoracic Oncology, North Hospital, University Hospital of Saint-Etienne, Saint-Etienne, France

^b Respiratory Department, Louis Pradel Hospital, Hospices Civils de Lyon Cancer Institute, Lyon, France

^c Oncopharmacology Laboratory, Cancer Research Center of Lyon, UMR INSERM 1052 CNRS 5286, Lyon, France

^d Université Claude Bernard, Université de Lyon, Lyon, France

^e Pneumology Department, Centre Hospitalier Intercommunal de Crêteil, Crêteil, France



ARTICLE INFO

Keywords:

Immune checkpoint inhibitors
Small targeted therapies
Concomitant or sequential administration
Toxicities
Non-small cell lung cancer

ABSTRACT

Background: Immune checkpoint inhibitors (ICIs) have become standard-of-care at different stage disease in non-small cell lung cancer (NSCLC). Based on the increasing characterization of molecular aberrations and oncogenic drivers in NSCLC, it is expected that more and more patients will benefit from orally small targeted therapies in NSCLC. However, their concomitant or sequential use is associated with an increased risk of a various toxicity pattern.

Methods: Relevant publications were included if they reported data on the question of toxicities associated with sequential or combined use of ICIs and small targeted therapies used in NSCLC treatment. MEDLINE, Google Scholar, and the Cochrane Library were searched for the following request, from database inception until June 2023.

Results: This review highlighted a various pattern of toxicities (*i.e.*, interstitial lung disease, hepatitis, dermatoses) in the context of both sequential and concomitant administration of ICIs and small targeted therapies. Such toxicities seem rather a “drug-effect” than a “class-effect” and some of these toxicities are more specific of a small targeted therapy. This review highlights on the impact of treatment sequence administration and emphasis for physicians to be particularly careful whether small targeted therapy is administered within one to three months after last ICIs injection.

Conclusion: Physicians have to be aware of severe toxicities in case of both concomitant or sequential ICIs/small targeted therapies administration in NSCLC. Further studies are needed to better understand the mechanisms underlying these toxicities in order to prevent them and to refine ICIs and small targeted therapy sequencing strategy.

Introduction

Immune checkpoint inhibitors (ICIs), mainly represented by anti-programmed cell death receptor-1/programmed death ligand 1 [PD-(L)1], significantly improve survival outcomes in advanced non-small cell lung cancer (NSCLC) and represent a standard of care [1–7]. ICIs also confer significant benefit as a treatment consolidation after radio-chemotherapy for locally advanced NSCLC [8,9]. They are also being tested in both neoadjuvant and adjuvant settings for localized NSCLC

and are close to be considered as standard of care worldwide in peri-operative setting [10–12]. ICI-related specific toxicities have emerged and are named immune-related adverse events (irAEs) [13,14]. The biological mechanisms of irAEs are largely unknown but may rely on cross reactivity with self-peptides results in breakout of host immune tolerance [13]. The most frequently reported irAEs with anti-PD-1 include thyroiditis, pneumonitis, hepatitis, diarrhea, and colitis [14,15]. It is estimated that approximately 10 % of patients treating with anti-PD-1 will experience grade ≥ 3 irAEs [14].

* Corresponding author.

E-mail address: anne-laure.desage@chu-st-etienne.fr (A.-L. Désage).

<https://doi.org/10.1016/j.ctrv.2024.102805>

Received 2 April 2024; Received in revised form 29 June 2024; Accepted 22 July 2024

Available online 23 July 2024

0305-7372/© 2024 The Author(s). Published by Elsevier Ltd. This is an open access article under the CC BY-NC-ND license (<http://creativecommons.org/licenses/by-nc-nd/4.0/>).

Based on the increasing characterization of molecular aberrations and oncogenic drivers in NSCLC, it is expected that up to half of advanced NSCLC patients will receive orally available small targeted therapies during their treatment history. Small targeted therapies are mainly represented by tyrosine kinase inhibitors (TKIs) that inhibit the tyrosine kinase activity of tyrosine kinase-dependent oncogenic proteins leading to cell death and clinical activity. Based on biopharmaceutical optimization, TKIs are increasingly specific of tyrosine kinase dependent oncogenic proteins leading to better tolerance by reducing off-target side effects. KRAS inhibitors are small targeted therapies that trap KRAS in its inactive GDP-bound state through covalent binding [16,17].

Sequential anti-PD-(L)1 and TKI is associated with an increased prevalence of a diverse range of toxicities in NSCLC [18–20]. Severe hepatitis was reported in a *KRASG12C*-mutant NSCLC patient who received sequential anti-PD-(L)1 and sotorasib therapy [21]. This raises the hypothesis that small targeted therapies may trigger severe anti-PD-(L)1-mediated toxicities, questioning the optimal sequencing of targeted therapies and anti-PD-(L)1. Herein, we aim to address specific toxicities with either sequential or concomitant ICI and small targeted therapy administration in NSCLC.

Methods

Relevant publications (case reports, original reports, and reviews) were included if they reported data on the question of toxicities associated with sequential or combined use of ICIs and small targeted therapies used in NSCLC treatment. MEDLINE, Google Scholar, and the Cochrane Library were searched for the following request, from database inception until June 2023.

For sequential toxicities, the query in MEDLINE was: (“toxicity” OR “adverse event” AND “immune checkpoint inhibitors” AND “XX” [MESH Terms]); for toxicities resulting from combined treatment, it was (“toxicity” OR “adverse event” AND “concomitant” AND “immune checkpoint inhibitors” AND “XX” [MESH Terms]). To increase accuracy, the same query was made using the [ALL FIELDS] filter. No restriction filters were applied regarding the type of study articles. The same query for either sequential or combined treatment toxicities was used in Google Scholar and the Cochrane Library. In Google Scholar, an additional restriction filter was applied to select only articles that contain the request formulation in their title. In the Cochrane Library, the request formulation was only made with MESH Terms.

In the queries, “XX” was replaced by small targeted therapies currently available in NSCLC according to the 2023 ESMO Clinical Practice Guideline [22]: erlotinib, gefitinib, afatinib, osimertinib, mobocertinib, dacomitinib, alectinib, brigatinib, lorlatinib, crizotinib, ceritinib, trametinib, dabrafenib, sotorasib, adagrasib, capmatinib, tepotinib, larotrectinib, entrectinib, reprotrectinib, pralsetinib, and selipratinib.

Results

No publications were found in Google Scholar and the Cochrane Library databases.

Relevant articles were selected from the MEDLINE database [18–21,23–44]. None of them reported data for the following small targeted therapies in NSCLC: dacomitinib, mobocertinib, brigatinib, lorlatinib, entrectinib, reprotrectinib, dabrafenib, trametinib, praseltinib, capmatinib, adagrasib, larotrectinib.

Type of toxicities associated with sequential or combined use of ICIs and small targeted therapies in NSCLC

Lung toxicities

Preliminary reports of toxicities associated with sequential osimertinib following ICIs emerged in 2017 [23,24]. A single-center retrospective study including 19 patients treated with osimertinib

reported four cases of interstitial lung disease (ILD), leading to osimertinib discontinuation [23]. Three of them were previously treated with nivolumab (*i.e.*, anti-PD-1). Systemic steroids were begun for two patients [23]. Osimertinib administration eight days after the last nivolumab infusion conducted to mild infiltration of lungs, fever and shortness of breath within one month after the beginning of osimertinib [24]. Respiratory symptoms were gradually resolved after osimertinib discontinuation. However, same symptoms appeared a week following osimertinib re-introduction. Hypersensitivity pneumonitis was confirmed through bronchoalveolar lavage and transbronchial biopsy. Definitive discontinuation of osimertinib resulted in clinical improvement without administration of steroids [24]. In a post-marketing evaluation of osimertinib conducted in Japan, ILD was more frequent among patients previously treated with nivolumab (15 %) than among those who did not receive an ICI (5.7 %) [25]. Previous nivolumab treatment was an independent risk factor of ILD onset during osimertinib treatment (adjusted odds ratio [OR] 2.84; 95 % CI [1.98;4.07]) [25]. Among 41 patients treated with ICIs followed by osimertinib, 15 % experienced a severe irAE [18]. Grade 3 pneumonitis was the most frequent irAE; patients with pneumonitis responded to high-dose steroids with resolution of symptoms over weeks to months [18] (Table 1).

ILD is also reported in case of concomitant EGFR TKIs and ICIs administration (Table 2). The TATTON phase Ib trial evaluating concomitant treatment with osimertinib and durvalumab was stopped early due to safety concerns regarding ILD [26,27]; 11/23 patients (48 %) receiving durvalumab and osimertinib after prior EGFR TKIs experienced grade 3 or higher AEs and 5/23 (22 %) patients experienced ILD [26]. The increased risk of ILD with concomitant administration of ICIs and EGFR TKIs was also highlighted in the analysis of FDA Adverse Events Reporting System (FAERS) database. Among 70 patients treated with nivolumab and EGFR TKIs, ILD was reported in 25.7 % of them, and the adjusted OR for ILD with EGFR TKIs was 5.09 (95 % CI [2.87;9.03]) with nivolumab and 1.22 (95 % CI [1.00;1.47]) without [28].

Hepatic toxicities

Severe hepatic toxicities are described with EGFR TKIs, crizotinib, ceritinib, alectinib and sotorasib in case of sequential or concomitant administration with ICIs (Table 1 and 2).

Hepatitis onset during osimertinib treatment following nivolumab was described in a single-center retrospective study [29]. In this study, 7/47 patients included received osimertinib immediately (*i.e.*, within 180 days) after the last nivolumab infusion and grade 3 or 4 hepatitis was reported for 4/7 patients. One patient required high-dose steroids, and, in addition to osimertinib discontinuation, another patient required 2 mg/kg/day prednisolone followed by oral mycophenolate mofetil 2 g/day [29]. Grade 4 hepatitis requiring high-dose steroids and mycophenolate mofetil was reported for a patient treated with sequential ICIs followed by osimertinib. For this patient, osimertinib was discontinued [18]. Erlotinib associated with nivolumab led to grade 3 TRAEs in 24 % of the 21 chemotherapy-naïve *EGFR*-mutated advanced NSCLC patients [30]. Treatment was discontinued in two patients for, respectively, grade 3 diarrhea and concomitant grade 3 elevated aspartate aminotransferase (AST)/grade 2 elevated alanine aminotransferase (ALT) [30]. Among 28 patients who received erlotinib associated with atezolizumab, 46 % experienced a grade 3 TRAE, including 14 % grade 3 hepatitis [31]. None of these grade 3 TRAEs led to treatment discontinuation [31]. Among 7 patients who received concomitant gefitinib and pembrolizumab, 3/7 (42.9 %) experienced grade 3 and 2/7 (28.6 %) grade 4 TRAEs [32]. Liver-related toxicity resulted in permanent treatment discontinuation for four patients. Recruitment to the later trial was stopped after seven patients enrolled, due to liver-related toxicity [32].

Lin *et al.* assessed whether sequential ICI followed by crizotinib increases hepatotoxicity [20]. Eleven patients received sequential ICI followed by crizotinib; 5/11 (45.5 %) experienced grade 3 or 4 elevated ALT (27.3 % grade 4) and 4/11 (36.4 %) a grade 3 or 4 elevated AST, compared to, respectively, 34/442 (8.1 %) and 14/442 (3.4 %) of ICI-

Table 1
Toxicities of sequential immune checkpoint inhibitors and small targeted therapies in non-small cell lung cancer.

Study	Study design	number of patients treated with sequential ICI and small targeted therapy*	ICI regimen	small targeted therapy	Time interval between ICI and small targeted therapy	Time to onset of first toxicity after small targeted therapy introduction	Toxicity	Toxicity grade [†]	Steroids	Other treatment
Mamesaya <i>et al.</i> [24]	case report	1	nivolumab	osimertinib	8 days	31 days	hypersensitivity pneumonitis	not reported	no	no
Kotake <i>et al.</i> [23]	monocentric retrospective	5	nivolumab	osimertinib	2 weeks	6 weeks	ILD (n = 3)	not reported	yes (n = 2)	no
Gemma <i>et al.</i> [25]	multicentric real-world post-marketing data	202	nivolumab	osimertinib	not reported	not reported	ILD (n = 43/287 patients previously treated with nivolumab). The exact number in case of direct sequence is not reported.	not reported	not reported	not reported
Uchida <i>et al.</i> [42]	monocentric retrospective	12	nivolumab (n = 11) pembrolizumab (n = 1)	osimertinib (n = 7) erlotinib + BVZ (n = 2) gefitinib (n = 1) afatinib (n = 2)	15 days, 20 days and 5 months	1 month (n = 2) and 4 months (n = 1)	ILD (n = 3), all patients were treated with osimertinib.	grade 2 (n = 2) grade 3 (n = 1)	yes (n = 3)	no
Schoenfeld <i>et al.</i> [18]	monocentric retrospective	41	PD-(L)1 monotherapy (<i>i.e.</i> , nivolumab, pembrolizumab or atezolizumab) or as combination with ipilimumab or platinum-based chemotherapy	osimertinib	≤29 days (n = 3 pneumonitis and n = 1 colitis) 39 days (n = 1 hepatitis) 39 days (n = 1 hepatitis)	14 days (n = 1 colitis) 15 days (n = 1 pneumonitis) 24 days (n = 1 pneumonitis) 39 days (n = 1 hepatitis) 167 days (n = 1 pneumonitis)	pneumonitis (n = 3) colitis (n = 1) hepatitis (n = 1)	grade 3 grade 3 grade 4	yes (n = 5)	infliximab for colitis (n = 1) mycophenolate mofetil for hepatitis (n = 1)
Jung <i>et al.</i> [43]	monocentric retrospective	16	nivolumab or pembrolizumab	gefitinib (n = 6) osimertinib (n = 6)	20 and 28 days respectively 40 days	7 and 12 days respectively 54 days	pneumonitis (n = 2) pneumonitis (n = 1)	grade 3 grade 3	yes yes	no
Yamaguchi <i>et al.</i> [29]	monocentric retrospective	7	nivolumab	osimertinib	range 24 to 180 days	range 29 to 526 days	hepatitis (n = 4)	grade 3–4	yes (n = 2)	mycophenolate mofetil (n = 1)
Cui <i>et al.</i> [39]	case report	1	pembrolizumab with platinum-based chemotherapy	osimertinib	3 weeks	3 weeks	toxic epidermal necrosis	grade 2–3 rash grade 3–4 stomatitis	yes	intravenous immunoglobulin
Gianni <i>et al.</i> [40]	case report	1	pembrolizumab with platinum-based chemotherapy	osimertinib	10 days	23 days	hepatitis mucositis	grade 3 grade 2	yes	no
Mc coach <i>et al.</i> [19]	data of phase 1/2 LIBRETTO-001	152**	anti PD-(L)1 (<i>i.e.</i> , atezolizumab, avelumab, cemiplimab, durvalumab, nivolumab, pembrolizumab and spartalizumab)	selpercatinib	not reported	1.7 (1.0–3.3) week	hypersensitivity reaction (n = 17)	grade 1 (n = 1) grade 2 (n = 11) grade 3 (n = 5)	yes (n = 19/22 patients among the whole cohort)	no

(continued on next page)

Table 1 (continued)

Study	Study design	number of patients treated with sequential ICI and small targeted therapy*	ICI regimen	small targeted therapy	Time interval between ICI and small targeted therapy	Time to onset of first toxicity after small targeted therapy introduction	Toxicity	Toxicity grade [†]	Steroids	Other treatment
Lin <i>et al.</i> [20]	monocentric retrospective	11	PD-(L)1 monotherapy (<i>i. e.</i> , nivolumab, pembrolizumab or atezolizumab) or as combination with ipilimumab or platinum-based chemotherapy	crizotinib	30 (21–135) days	38 (13–49) days	ALT elevation AST elevation	grade 3–4 (n = 5) grade 3–4 (n = 4)	no	no
Begum <i>et al.</i> [21]	case report	1	pembrolizumab-pemetrexed combination	sotorasib	14 weeks	12 days	ALP elevation bilirubin elevation ALT elevation	grade 2 grade 1 grade 3	yes	no
Thummalapalli <i>et al.</i> [36]	multicentric retrospective	86**	PD-(L)1 monotherapy (<i>i. e.</i> , pembrolizumab, atezolizumab, durvalumab) or as combination with pemetrexed-platinum chemotherapy	sotorasib	4.6 (3.0 to 11.6) weeks 7.9 weeks 4.6 weeks 3.1 weeks	6.4 (2.0 to 14.1) weeks 3.4 weeks 77.7 weeks 11.6 weeks	hepatotoxicity (n = 12) pancreatitis + hepatotoxicity (n = 1) pneumonitis (n = 1) pneumonitis + anemia (n = 1)	grade 3 (n = 11) grade 4 (n = 1) grade 3 grade 3	5/13 patients with grade 3 or higher hepatic toxicity	no
Chour <i>et al.</i> [37]	multicentric retrospective	48	PD(L)1 monotherapy (<i>i. e.</i> , pembrolizumab, atezolizumab, nivolumab) or as combination with platinum-based chemotherapy, ipilimumab or investigational agent	sotorasib	32 (22.5–131) days	31 (2–113) days	GGT elevation (n = 13) ALT elevation (n = 12) AST elevation (n = 8)	grade ≥ 3 grade ≥ 3 grade ≥ 3	yes (n = 7)	no

BVZ: Bevacizumab.ILD: Interstitial Lung Disease. ALT: Alanine Aminotransferase.

AST: Aspartate Aminotransferase. ALP: Alkaline Phosphatase. GGT: Gamma-Glutamyltransferase.

*Defined the number of patients in the study who were treated with sequential immune checkpoint inhibitors followed by small targeted therapies.

**Not precised if all patients received ICI as last line before small targeted therapy initiation.

[†]According to CTCAE (Common Terminology Criteria for Adverse Events) classification.

Table 2
Toxicities of concomitant administration of immune checkpoint inhibitors and EGFR or ALK tyrosine kinase inhibitors in non-small cell lung cancer.

Study	Treatment	% Grade III/IV [¶]	Grade III/IV adverse events [¶]
Rudin et al. [31]	erlotinib-atezolizumab	46 % grade III	hepatitis (14 %)
Gettinger et al. [30]	erlotinib-nivolumab	24 % grade III	increased in AST (5 %) and AST/ALT levels (5 %), diarrhea (10 %) and weight loss (1.5 %)
Yang et al. [32]	gefitinib-pembrolizumab	42.9 % grade III 28.6 % grade IV	increased in AST (57.1 %) and ALT (71.4 %) levels
	erlotinib-pembrolizumab	33.3 % grade III	skin toxicity (2 patients), neuralgic amyotrophy + liver function test elevation (1 patient)
Oxnard et al. [26]	osimertinib-durvalumab	48 %	one grade 3 ILD (i.e., at 3 mg/kg durvalumab) and one grade 4 ILD (i.e., at 10 mg/kg durvalumab)
Ahn et al. [27]			
Felip et al. [38]	ceritinib-nivolumab	86 %	increased ALT (32 %), GGT (27 %) and amylase (14 %), rash (14 %)
Spigel et al. [34]	crizotinib-nivolumab	38 % (Hepatitis)	–
Kim et al. [41]	alectinib-atezolizumab	57 %	rash (19 %), bilirubin elevation (10 %), increased ALT (10 %) and dyspnea (10 %)

[¶]According to CTCAE (Common Terminology Criteria for Adverse Events) classification.

naïve patients treated with crizotinib ($p < 0.0001$) [20]. Four patients required permanent crizotinib discontinuation, and for one patient crizotinib was resumed with dose reduction; no steroids were administered and all cases were reversible [20]. Contrary to crizotinib, the safety analysis of VISION phase 1/2 open-label multi-cohort trial evaluating tepotinib for *MET* exon 14 skipping NSCLC did not find any significant difference according to prior systemic therapies received; 62/255 (24.3 %) of patients treated with tepotinib experienced grade 3 or 4 TRAEs [33]. Among patients who received prior ICIs the incidence of liver enzyme elevation was consistent with that in the overall population, and no pneumonitis was reported among these [33]. In the case of concomitant administration, phase 1/2 Checkmate 370 trial evaluating crizotinib and nivolumab as first-line treatment for *ALK*-rearranged NSCLC was interrupted due to severe hepatotoxicity [34]. Among the first 13 enrolled patients, 5/13 (38 %) experienced grade 3 or higher hepatic toxicity. Of these, two patients died subsequently to grade 3 ALT/AST elevation and grade 3 acute liver failure [34]. Treatment association was discontinued and steroids were administered for two patients. Three of the five patients who presented grade 3 or higher hepatic TRAEs fully recovered [34]. The phase 1b study evaluating crizotinib and pembrolizumab for previously untreated *ALK*-rearranged NSCLC patients was also interrupted earlier due to an excess of hepatitis dose-limiting toxicities [35].

A preliminary case report published in 2021 emphasis on hepatotoxicity risk with sequential ICI and sotorasib [21]. Sotorasib was initiated 14 weeks after the last pembrolizumab-pemetrexed infusion and on day 12 after sotorasib initiation, grade 2 alkaline phosphatase (ALP), grade 1 bilirubin and grade 3 ALT elevation were observed. Steroids were started on day 15 after sotorasib initiation and were markedly increased to 2 mg/kg intravenous methylprednisolone in addition to N-acetyl cysteine since the patient presented grade 4 ALT/GGT elevation and grade 3 ALP/bilirubin elevation [21]. Among patients who experienced grade ≥ 3 sotorasib TRAEs, 15/16 received previously anti-PD(L)1 [36]. These grade ≥ 3 sotorasib TRAEs consisted mainly of hepatotoxicity and resulted in treatment discontinuation for

10 patients [36]. Steroids were administered to 5/13 patients with grade ≥ 3 hepatotoxicity. Clinical improvement defined as grade 1 hepatotoxicity or better was observed for four patients within 12 weeks of steroid initiation [36]. In a multicenter retrospective cohort study conducted in France, grade ≥ 3 sotorasib-related AEs were significantly more frequent for ICI exposed patients compared to their counterparts (i.e., non-sequential ICI exposed patients or ICIs-naïve patients; 50 % vs. 13 %; $p < 0.001$) [37]. Grade ≥ 3 sotorasib-related hepatotoxicity was reported for 16/48 (33 %) of patients who were previously treated with ICIs [37]. Sotorasib was discontinued for 17/22 of them; steroids were administered for 7 patients [37].

Gastrointestinal toxicities

Grade 3 colitis was reported among a patient treated with sequential ICIs followed by osimertinib [18]. This patient required high-dose steroids and infliximab [18] (Table 1).

In phase Ib escalation and expansion cohort of ceritinib associated with nivolumab among 36 treatment-naïve or prior-treated patients with either *ALK* inhibitor or chemotherapy, grade 3 or 4 AEs led to treatment discontinuation in 8 patients [38]. The most frequent AE was diarrhea, occurring in 69 % patients; one patient had grade 3 or 4 diarrhea [38] (Table 2).

Cutaneous toxicities

Severe cutaneous toxicities are also described for EGFR TKIs, ceritinib, alectinib and sotorasib in case of sequential or concomitant administration with ICIs (Table 1 and 2).

Osimertinib administration three weeks after last chemo-immunotherapy infusion conducted to a toxic epidermal necrosis within three weeks after osimertinib beginning, requiring osimertinib discontinuation [39]. Despite high-dose steroids and intravenous immunoglobulin, extended dermatoses conducted to death 19 days later [39]. In another case, osimertinib was introduced 10 days after the last chemo-immunotherapy infusion [40]. A grade 3 hepatitis and concomitant grade 2 mucositis was reported 23 days after osimertinib administration, requiring high-dose steroids [40]. After eight days of osimertinib wash-out and steroids, osimertinib re-introduction conducted to onset of grade 3 hepatotoxicity and grade 3 cutaneous erythema (i.e., clinical diagnosis of Stevens-Johnson syndrome) 14 days later [40]. Grade 3 TRAEs – mainly skin reactions – were reported for 4/12 patients (33.3 %) who received concomitant administration of erlotinib and pembrolizumab; treatment was discontinued for three of them [32].

Among 21 patients included in phase Ib evaluating alectinib associated with atezolizumab, 57 % of them experienced grade 3 TRAEs [41]. Of these, 33.3 % of patients required steroids. Rash was the most frequently reported grade 3 TRAE (19 %), followed by blood bilirubin, ALT elevation and dyspnea (10 % each) [41].

Rash-related AE was reported for 23/36 (64 %) of patients treated with ceritinib and nivolumab; this AE was more severe whether ceritinib was administered at 450 mg (i.e., 29 % grade 3) than 300 mg (i.e., 14 % grade 3) [38].

One grade 5 toxic epidermal necrosis related to sotorasib was reported for a patient who received last pembrolizumab infusion 4 days before sotorasib initiation [37].

Hypersensitivity reaction

Mc Coach et al. analyzed the risk for hypersensitivity reaction with selpercatinib in prior ICI-treated patients and their ICI-naïve counterparts [19]. Hypersensitivity reaction was defined by maculopapular rash often preceded by fever with arthralgias/myalgias and followed by one or greater symptoms including thrombocytopenia, increased AST/ALT, hypotension, tachycardia, or increased creatinine [19]. Among the 329 patients with *RET*-fusion positive NSCLC included in the safety analysis set, 152 had previously received ICIs [19]. 17/22 (77 %) patients who experienced hypersensitivity reaction with selpercatinib had been

previously treated with ICIs (*i.e.*, anti PD-(L)1) (Table 1); 19/22 required high-dose steroids and treatment was permanently discontinued for three patients. Hypersensitivity reaction was more frequent among patients who had been previously treated with ICIs (11.2 %) than those who had not (2.8 %). Grade 3 hypersensitivity reaction was reported for 3.3 % of patients previously treated with ICIs. Other grade 3 or more AEs were more frequent in ICI treated patients (63.2 %) than in ICI-naïve patients (56.5 %) [19].

Sequence of treatment administration: A major determinant of toxicities

The sequence of treatment administration appears to be a major determinant of increased toxicities. In an analysis of 26 patients receiving EGFR TKIs before and/or after anti PD-1, no ILD was reported among patients treated with EGFR TKIs before receiving ICIs [42]. No irAEs were observed among 29 patients treated with osimertinib followed by ICIs [18]. Small targeted therapies within eight weeks before ICIs administration did not result in increased risk of pneumonitis [43]. Conversely, 15 % of patients treated with sequential PD-(L)1 blockade followed by osimertinib experienced severe irAEs [18].

Another major determinant of increased toxicity is the timing of therapy administration (Table 1; Figs. 1 and 2). The risk of toxicities seems particularly increased whether small targeted therapy is administered within one month after the last immunotherapy infusion [18,20,23,24,37,39,40]. The onset of ILD was more frequent (27.8 %) whether osimertinib was introduced within one month following the last nivolumab infusion [25] and there was a trend towards a shorter median interval between nivolumab last infusion and osimertinib initiation among patients who experienced ILD (2 weeks [1–4]) than those who did not (7 weeks [4–17] respectively; $p = 0.08$) [23]. The median interval between the last ICI infusion and crizotinib administration was shorter (30 days [21–135]) in case of grade 3–4 AST/ALT elevation as compared with patients who did not experience transaminase elevation (50 days [10–12]) [20]. Grade ≥ 3 sotorasib-related AEs were more frequent (*i.e.*, 28 % of patients) whether patients received last anti-PD-(L)1 infusion within 12 weeks before sotorasib initiation [36]. 58 % of patients who received a last infusion of anti-PD-(L)1 within 30 days before sotorasib initiation experienced a severe sotorasib-related hepatotoxicity [37]. Severe toxicities are also described within two to three months after the last ICI infusion [19,21,29,42]. The risk of ILD onset

remains particularly high (14.2 %) whether patients received osimertinib between two and three months after the last nivolumab infusion [25]. In case of seliprecatinib, the majority of hypersensitivity reaction onset (14/17) occur within three months after the last ICI infusion [19].

A longer interval between nivolumab and osimertinib seems to prevent from this side-effect as only one case of ILD was reported among a patient who received osimertinib six months after the last nivolumab infusion [25]. No cases of grade ≥ 3 sotorasib-related AEs were reported whether patients received last anti-PD(L)1 infusion more than 12 weeks before sotorasib initiation [36].

Increased risk of toxicities: A drug effect or a class effect?

Another main question arises through these overlapping toxicities is whether increased toxicities is a drug or class-effect interaction with ICIs.

Increased AEs following ICIs are reported for both tyrosine kinase inhibitors (*i.e.*, osimertinib, seliprecatinib and crizotinib) and KRAS G12C inhibitor (*i.e.*, sotorasib) [18–20,23,24,29,39,40,42]. In case of sequential administration, several evidence outlined the individual risk of osimertinib as compared with first (*i.e.*, erlotinib or gefitinib) or second generation (*i.e.*, afatinib) EGFR TKIs [18,42]. Among 12 patients who received EGFR TKIs after nivolumab infusion, 3/7 treated with osimertinib experienced ILD whereas none of those treated with first or second-generation EGFR TKIs did so [42] (Table 1). No patient developed severe irAE while exposed to erlotinib or gefitinib following ICI administration [18]. Conflicting results on first-generation EGFR TKIs are reported as two cases of grade 3 pneumonitis were observed among patients who received gefitinib following nivolumab [43] (Table 1). As another assessment of drug-specific interaction, tepotinib did not result in significant increased toxicities in the context of sequential treatment [33].

Mechanisms of interactions between ICIs and small targeted therapies

The exact mechanism of interaction between ICIs and small targeted therapies that results in increased toxicities is unknown. However, several hypothesis discuss to explain these toxicities, especially in the context of sequential treatment (Fig. 3).

First, an increased risk of AE seems to occur independently of either

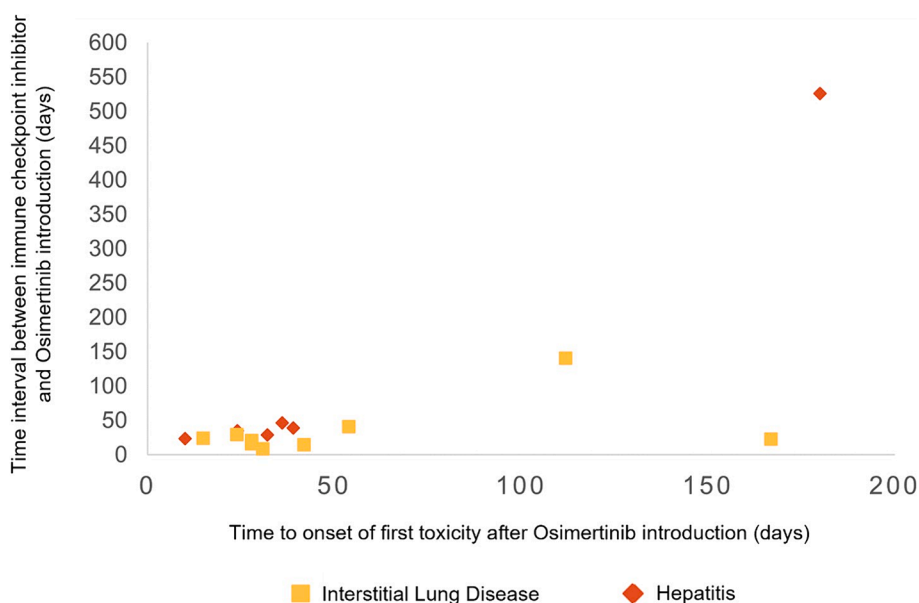


Fig. 1. Immune related adverse events onset on osimertinib after immune checkpoint inhibitors. Each point matches with the data of one patient according to Mameyasa et al. [24], Kotake et al. [23], Uchida et al. [42], Schoenfeld et al. [18], Jung et al. [43], Gianni et al. [40] and Yamaguchi et al. [29].

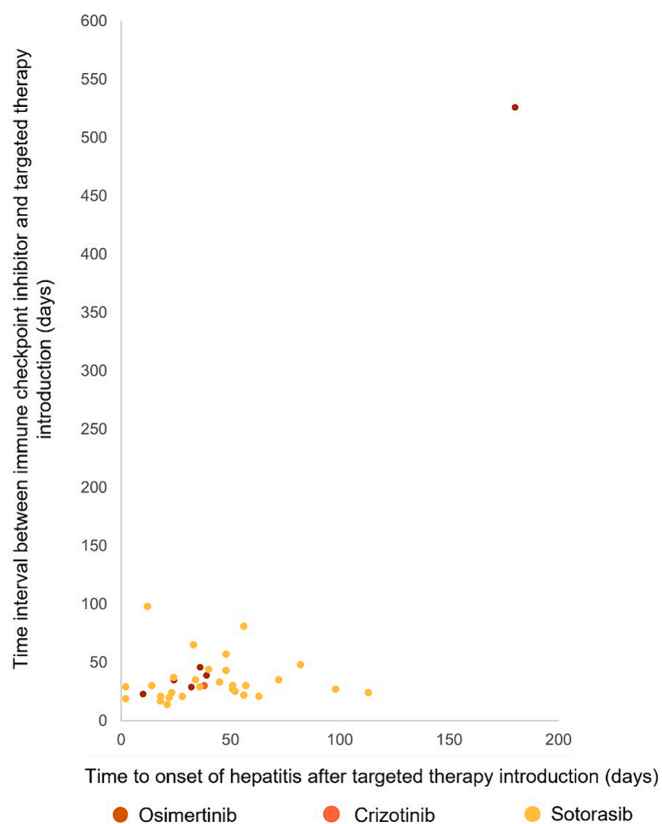


Fig. 2. Hepatitis onset according to different small targeted therapies following immune checkpoint inhibitors. Each point matches with the data of one patient according to Schoenfeld et al. [18], Yamaguchi et al. [29], Gianni et al. [40], Begum et al. [21], Thummalapalli et al. [36], Chour et al. [37] and Lin et al. [20].

the duration of PD-(L)1 blockade and previous history of irAEs while exposed to ICIs [18,20,36,37]. Previous history of irAEs was not associated with an increased risk of grade ≥ 3 sotorasib-related AEs (*i.e.*, no previous irAEs 16 % vs. previous irAEs 20 %, $p = 0.757$) [36]. No patient who developed severe sotorasib-related hepatotoxicity had a previous history or either ICI-related hepatitis or ICI-related immune-mediated disorder [37]. Among patients who received sequential ICI followed by crizotinib and developed grade ≥ 3 hepatitis, none has preexisting autoimmune disorder [20].

Liver and bronchial biopsies have been performed for respectively grade 3 hepatitis and pneumonitis [21,24,29]. Portal and lobular inflammatory changes in a pattern typical of checkpoint inhibitor hepatitis was reported by an expert review in sotorasib-induced hepatitis [21]. Lobular inflammation and bile duct injury typical of ICI-induced hepatitis was reported among a grade 4 sotorasib-related hepatitis [37]. A strong CD3 + CD8 + cytotoxic T-cell infiltration was observed in both liver and bronchial biopsies performed consequently to osimertinib irAEs [24,29]. CD20 + or CD4 + lymphocytes were less expressed [24,29]. The increased risk of hypersensitivity reaction secondary to sequential ICIs and seliprecatinib was compared as a type 4 hypersensitivity reaction [19,45].

The slow elimination and prolonged receptor occupancy of the anti-PD-(L)1 antibody associated with immunomodulator effect of small targeted therapies might explain the risk of long-term irAEs occurrence. A phase 1 study investigating anti-PD-1 found a sustained occupancy of 70 % or more of PD-1 on circulating T-cells for a time period equal to two months or more following anti-PD-1 administration [46]. These *in vitro* observations are in line with liquid chromatography-mass spectrometry analysis reported in clinical setting [44]. Nivolumab blood concentration was analyzed among three patients previously treated by

nivolumab and who experienced ILD (grade 1 and grade 3 respectively) and hepatitis (grade 3 ALT elevation) while exposed to osimertinib. Nivolumab was still detected in a patient serum sample (*i.e.*, 2.1 $\mu\text{g/ml}$) treated with osimertinib who developed grade 3 ILD more than one hundred days after nivolumab discontinuation [44]. Some reports highlighted the immunomodulator effects of small targeted therapies. *In vitro* experiments with erlotinib and additional EGFR inhibitors were found to increase both basal and IFN γ -induced MHC class I presentation [47]. Pre-clinical studies of sotorasib found a significant increase of CD4 $^{+}$ /CD8 $^{+}$ T-cells, macrophages and CD103 $^{+}$ dendritic cells [48]. Transcriptional analysis also found a significant increase of interferon signaling, MHC and TLR score following sotorasib administration [48].

In line with a “drug-effect” rather than a “class-effect”, small targeted therapy metabolite accumulation may trigger ICIs-related toxicities. In a treatment sequencing of pembrolizumab followed by erlotinib and osimertinib; osimertinib administration resulted in grade 3 pneumonitis 15 days after beginning [18].

Impact on survival

The objective response rate with durvalumab and osimertinib was estimated to be 43 % whereas pembrolizumab associated with either gefitinib or erlotinib achieved a response rate of 41.7 % [26,32]; this is lower than response rate with osimertinib (80 %) and first-generation EGFR TKIs (76 %) [49]. Several studies have been interrupted, in particular in the context of concomitant ICI and small targeted therapies association, which might have an impact on survival [26,27,34,35]. Although comparable median progression-free survival, a significantly shorter duration of treatment was observed in case of severe sotorasib-related AEs (2.8 vs. 4.7 months, $p = 0.018$) [37].

Hypotheses for management of toxicities associated with sequential use of ICIs and small targeted therapies

These observations raise the question of a wash-out period for sequential ICIs and small targeted therapies administration. Most patients who experienced severe irAEs had a short interval between ICIs and osimertinib (*i.e.*, ≤ 29 days) [18]. 3/6 patients presented severe irAEs within 15 days after osimertinib administration [18]. Osimertinib re-introduction 18 days later after grade IV toxicity resulted in a recurrent grade III hepatitis whereas osimertinib re-introduction more than 70 days after the initial toxicity did not result in a recurrent irAEs [18]. Chour *et al.* recently suggest to avoid starting sotorasib within 30 days after last anti-PD-(L)1 infusion [37].

In case of sequential treatment administration, concomitant administration of steroids with small targeted therapies might be proposed. In the case reported by Gianni *et al.*, after a period of treatment wash-out and steroid administration for grade III hepatitis and grade III cutaneous erythema, osimertinib was resumed at 80 mg daily with prednisone 25 mg/day [40]. In this report, the patient successfully continued osimertinib with good tolerance and slowly decreased steroid therapy [40].

Discussion

To our knowledge, this is one of the first literature review that emphasis on increased toxicities for both sequential and concomitant administration of ICIs and small targeted therapies in NSCLC [50,51].

This review highlighted a various pattern of AEs (*i.e.*, ILD, hepatitis, colitis, cutaneous and hypersensitivity reaction) in the context of both sequential and concomitant administration of ICIs and small targeted therapies. Otherwise, toxicities are presented heterogeneously (*i.e.*, AEs, TRAEs, irAEs) regarding drug imputability. The risk of ILD seems increased with osimertinib whereas high-grade hepatitis is particularly reported with sotorasib and ALK inhibitors [18,21,23,25,37,42]. Risk of hypersensitivity reaction are reported with seliprecatinib while skin

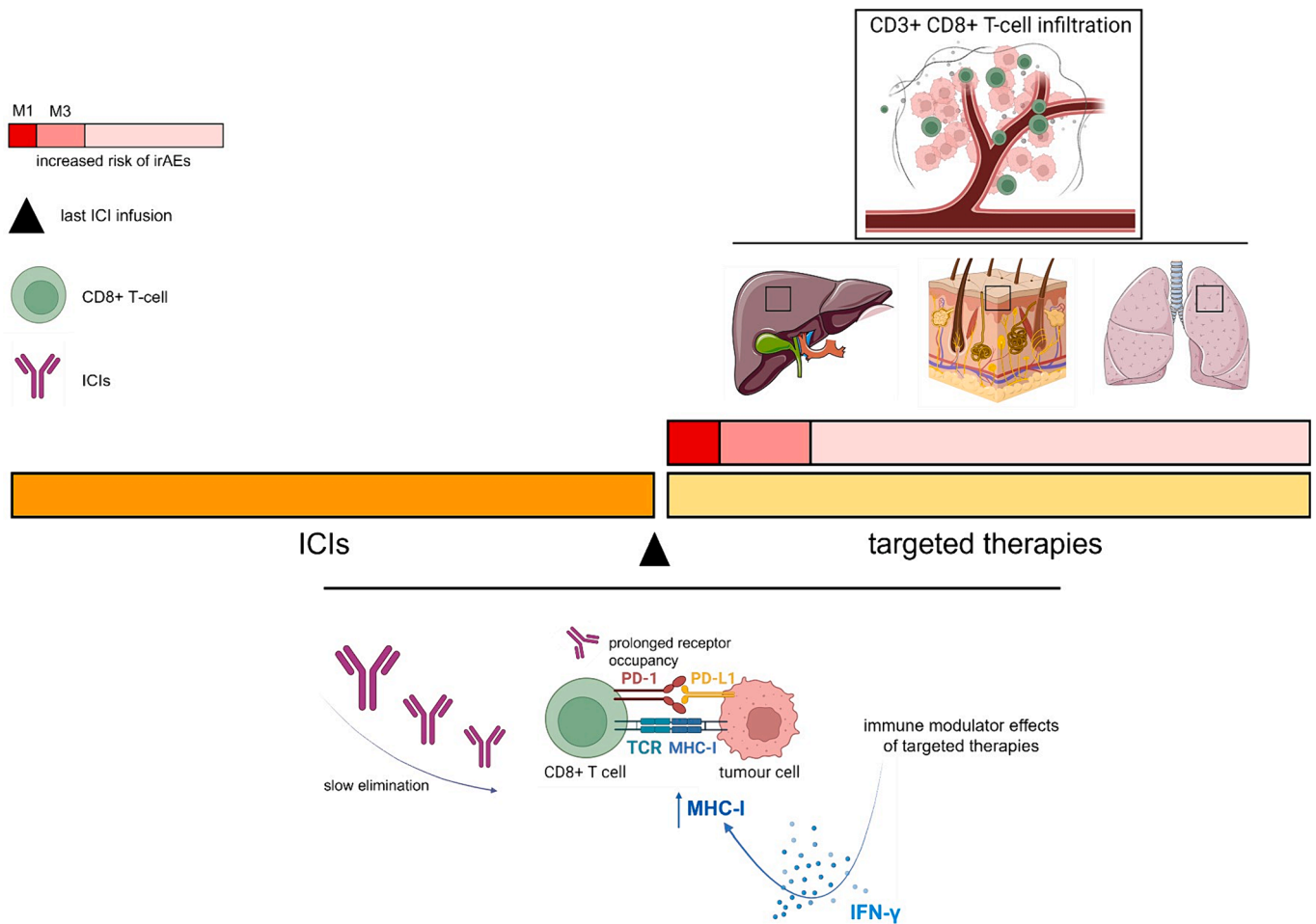


Fig. 3. Hypotheses of mechanisms of toxicities in case of sequential ICIs and small targeted therapies administration in NSCLC. This figure was created with Biorender.com.

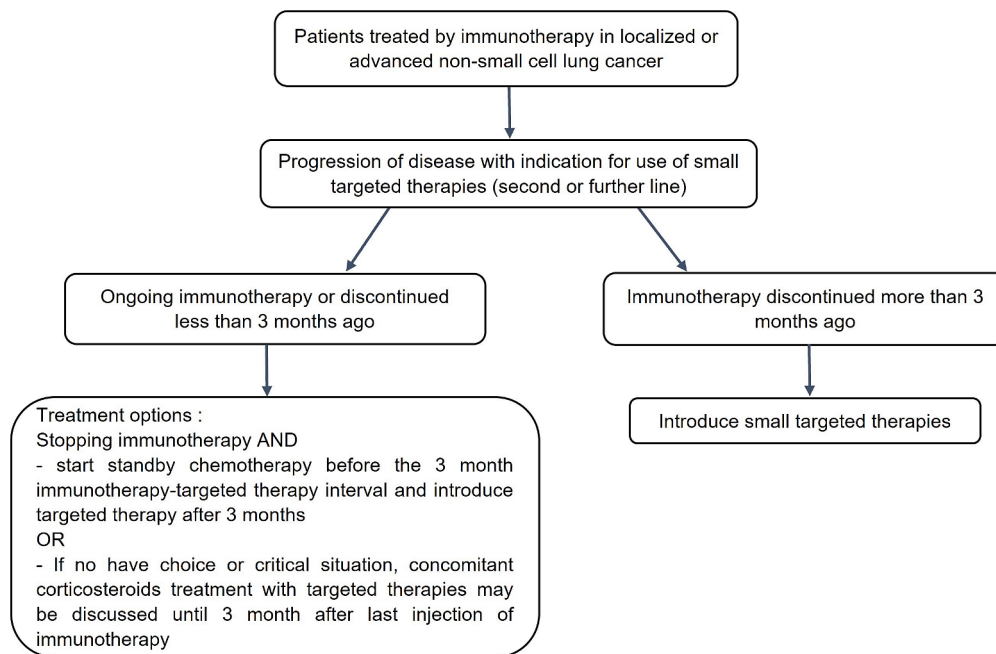


Fig. 4. A proposed algorithm of possible clinical situations after immunotherapy for immunotherapy-small targeted therapy sequences. This proposed algorithm has not to be considered as general recommendations as it is not supported by a high degree of evidence in literature.

irAEs are also described with osimertinib [19,39,40]. Contrary to melanoma [52,53], no description of toxicity of BRAF plus MEK inhibition following ICIs is reported in case of NSCLC. These observations also support that these overlapping toxicities might result from a “drug-effect” rather than a “class-effect”. Interestingly, in a recent case series, most patients who discontinued sotorasib (after ICIs) because of hepatotoxicity did not have hepatotoxicity with adagrasib [54]. Thus, further studies are needed to evaluate the tolerability of different ICIs/small targeted therapies sequences or association.

This review also raises the question as to how to prevent these toxicities in a clinical setting. This is of particular concern in case of sequential treatment administration. A proactive molecular screening for patients at the metastatic stage as well as for early-stage disease is determinant to carefully select patients who could receive immunotherapy [8,10–12]. Physicians have to be aware of these overlapping toxicities when initiating small targeted therapy within one to three months after the last ICI infusion. A longer wash-out between ICIs and small targeted therapies administration could limit these toxicities but such treatment strategy seems difficult to apply in case of cancer progression. Based on preliminary observations with BRAF-MEK inhibitor for melanoma, another way to limit these toxicities might be the concomitant use of steroids during small targeted therapies [52]. Further studies are needed in the next future to better understand the mechanism of increased toxicities on sequential treatment and thus better prevent these severe AEs. An algorithm for management of immunotherapy and small targeted therapy sequences is proposed in Fig. 4.

Conclusion

Although there is little published data, specific concerns about an increased risk of AEs is currently emerging for both concomitant and sequential ICI administration with small targeted therapies in NSCLC. Nowadays, this question is of particular relevance in case of sequential treatment administration. Molecular biology result is important prior to the introduction of immunotherapy. If a targetable molecular alteration has been identified and immunotherapy is underway or has recently been administered, it will be necessary to consider the benefit-risk balance with regard to the introduction of the targeted therapy. It is necessary to take into account the type of small targeted therapies, the time since the last immunotherapy injection, the irAEs and their severity depending on the type of treatment and therapeutic alternatives.

Declaration of competing interest

The authors declare that they have no known competing financial interests or personal relationships that could have appeared to influence the work reported in this paper.

References

- Reck M, Rodríguez-Abreu D, Robinson AG, Hui R, Csósz T, et al. Pembrolizumab versus chemotherapy for PD-L1-positive non-small-cell lung cancer. *N Engl J Med* 2016;375(19):1823–33.
- Mok TSK, Wu YL, Kudaba I, Kowalski DM, Cho BC, et al. Pembrolizumab versus chemotherapy for previously untreated, PD-L1-expressing, locally advanced or metastatic non-small-cell lung cancer (KEYNOTE-042): a randomised, open-label, controlled, phase 3 trial. *Lancet* 2019;393(10183):1819–30.
- Gandhi L, Rodríguez-Abreu D, Gadgeel S, Esteban E, Felip E, et al. Pembrolizumab plus chemotherapy in metastatic non-small-cell lung cancer. *N Engl J Med* 2018;378(22):2078–92.
- Paz-Ares L, Luft A, Vicente D, Tafreshi A, Güümüş M, et al. Pembrolizumab plus chemotherapy for squamous non-small-cell lung cancer. *N Engl J Med* 2018;379(21):2040–51.
- Herbst RS, Baas P, Kim DW, Felip E, Pérez-Gracia JL, et al. Pembrolizumab versus docetaxel for previously treated, PD-L1-positive, advanced non-small-cell lung cancer (KEYNOTE-010): a randomised controlled trial. *Lancet* 2016;387(10027):1540–50.
- Brahmer J, Reckamp KL, Baas P, Crinò L, Eberhardt WEE, et al. Nivolumab versus docetaxel in advanced squamous-cell non-small-cell lung cancer. *N Engl J Med* 2015;373(2):123–35.
- Rittmeyer A, Barlesi F, Waterkamp D, Park K, Ciardiello F, et al. Atezolizumab versus docetaxel in patients with previously treated non-small-cell lung cancer (OAK): a phase 3, open-label, multicentre randomised controlled trial. *Lancet* 2017;389(10066):255–65.
- Antonia SJ, Villegas A, Daniel D, Vicente D, Murakami S, et al. Durvalumab after chemoradiotherapy in stage III non-small-cell lung cancer. *N Engl J Med* 2017;377(20):1919–29.
- Antonia SJ, Villegas A, Daniel D, Vicente D, Murakami S, et al. Overall survival with durvalumab after chemoradiotherapy in stage III NSCLC. *N Engl J Med* 2018;379(24):2342–50.
- Forde PM, Spicer J, Lu S, Provencio M, Mitsudomi T, et al. Neoadjuvant Nivolumab plus chemotherapy in resectable lung cancer. *N Engl J Med* 2022;386(21):1973–85.
- Wakelee HA, Altorki NK, Zhou C, Csósz T, Vynnychenko IO, et al. IMPower010: Primary results of a phase III global study of atezolizumab versus best supportive care after adjuvant chemotherapy in resected stage IB-IIIa non-small cell lung cancer (NSCLC). *J Clin Oncol* 2021;39(15_suppl). 8500–8500.
- Paz-Ares L, O’Brien MER, Mauer M, Dafni U, Oselin K, et al. VP3-2022: Pembrolizumab (pembro) versus placebo for early-stage non-small cell lung cancer (NSCLC) following complete resection and adjuvant chemotherapy (chemo) when indicated: Randomized, triple-blind, phase III EORTC-1416-LCG/ETOP 8–15 – PEARLS/KEYNOTE-091 study. *Ann Oncol* 2022;33(4):451–3.
- Postow MA, Sidlow R, Hellmann MD. Immune-Related Adverse Events Associated with Immune Checkpoint Blockade. *N Engl J Med* 2018;378(2):158–68.
- Martins F, Sofiya L, Sykiotis GP, Lamine F, Maillard M, et al. Adverse effects of immune-checkpoint inhibitors: epidemiology, management and surveillance. *Nat Rev Clin Oncol* 2019;16(9):563–80.
- Khoja J, Day D, Chen TW, Siu LL, Hansen AR. Tumour- and class-specific patterns of immune-related adverse events of immune checkpoint inhibitors: a systematic review. *Ann Oncol* 2017;28(10):2377–85.
- Ostrem JM, Peters U, Sos ML, Wells JA, Shokat KM. K-Ras(G12C) inhibitors allosterically control GTP affinity and effector interactions. *Nature* 2013;503(7477):548–51.
- Patricelli MP, Janes MR, Li LS, Hansen R, Peters U, et al. Selective inhibition of oncogenic KRAS output with small molecules targeting the inactive state. *Cancer Discov* 2016;6(3):316–29.
- Schoenfeld AJ, Arbour KC, Rizvi H, Iqbal AN, Gadgeel SM, et al. Severe immune-related adverse events are common with sequential PD-(L)1 blockade and osimertinib. *Ann Oncol* 2019;30(5):839–44.
- McCoach CE, Rolfo C, Drilon A, Lacouture M, Besse B, et al. Hypersensitivity reactions to Selpercatinib treatment with or without prior immune checkpoint inhibitor therapy in patients with NSCLC in LIBRETTO-001. *J Thorac Oncol* 2022;17(6):768–78.
- Lin JJ, Chin E, Yeap BY, Ferris LA, Kamesan V, et al. Increased hepatotoxicity associated with sequential immune checkpoint inhibitor and Crizotinib therapy in patients with non-small cell lung cancer. *J Thorac Oncol* 2019;14(1):135–40.
- Begum P, Goldin RD, Possamai LA, Popat S. Severe immune checkpoint inhibitor hepatitis in KRAS G12C-Mutant NSCLC potentially triggered by sotorasib: case report. *JTO Clin Res Rep* 2021;2(9):100213.
- Hendricks LE, Kerr KM, Menis J, Mok TS, Nestle U, et al. Oncogene-addicted metastatic non-small-cell lung cancer: ESMO Clinical Practice Guideline for diagnosis, treatment and follow-up. *Ann Oncol* 2023;34(4):339–57.
- Kotake M, Murakami H, Kenmotsu H, Naito T, Takahashi T. High incidence of interstitial lung disease following practical use of osimertinib in patients who had undergone immediate prior nivolumab therapy. *Ann Oncol* 2017;28(3):669–70.
- Mamesaya N, Kenmotsu H, Katsumata M, Nakajima T, Endo M, et al. Osimertinib-induced interstitial lung disease after treatment with anti-PD1 antibody. *Invest New Drugs* 2017;35(1):105–7.
- Gemma A, Kusumoto M, Sakai F, Endo M, Kato T, et al. Real-world evaluation of factors for interstitial lung disease incidence and radiologic characteristics in patients with EGFR T790M-positive NSCLC treated with Osimertinib in Japan. *J Thorac Oncol* 2020;15(12):1893–906.
- Oxnard GR, Yang JCH, Yu H, Kim SW, Saka H, et al. TATTON: a multi-arm, phase Ib trial of osimertinib combined with selumetinib, savolitinib, or durvalumab in EGFR-mutant lung cancer. *Ann Oncol* 2020;31(4):507–16.
- Ahn MJ, Cho BC, Ou X, Walding A, Dymond AW, et al. Osimertinib Plus Durvalumab in Patients With EGFR-Mutated, Advanced NSCLC: A Phase 1b, Open-Label, Multicenter Trial. *J Thorac Oncol* 2022;17(5):718–23.
- Oshima Y, Tanimoto T, Yuji K, Tojo A. EGFR-TKI-associated interstitial pneumonitis in Nivolumab-treated patients with non-small cell lung cancer. *JAMA Oncol* 2018;4(8):1112–5.
- Yamaguchi O, Kaira K, Kawasaki T, Mouri A, Hashimoto K, et al. Severe hepatotoxicity due to osimertinib after nivolumab therapy in patients with non-small cell lung cancer harboring EGFR mutation. *Thorac Cancer* 2020;11(4):1045–51.
- Gettinger S, Hellmann MD, Chow LQM, Borghaei H, Antonia S, et al. Nivolumab Plus Erlotinib in Patients With EGFR-Mutant Advanced NSCLC. *J Thorac Oncol* 2018;13(9):1363–72.
- Rudin CM, Cervantes A, Dowlati A, Besse B, Ma B, et al. Safety and clinical activity of atezolizumab plus erlotinib in patients with non-small-cell lung cancer. *ESMO Open* 2023;8(2):101160.
- Yang JCH, Gadgeel SM, Sequist LV, Wu CL, Papadimitrakopoulou VA, et al. Pembrolizumab in combination with Erlotinib or Gefitinib as first-line therapy for

- advanced NSCLC with sensitizing EGFR mutation. *J Thorac Oncol* 2019;14(3): 553–9.
- [33] Le X, Sakai H, Felip E, Veillon R, Garassino MC, et al. Tepotinib Efficacy and safety in patients with MET Exon 14 skipping NSCLC: outcomes in patient subgroups from the VISION Study with relevance for clinical practice. *Clin Cancer Res* 2022;28(6): 1117–26.
- [34] Spigel DR, Reynolds C, Waterhouse D, Garon EB, Chandler J, et al. Phase 1/2 study of the safety and tolerability of Nivolumab Plus Crizotinib for the first-line treatment of anaplastic lymphoma kinase translocation — positive advanced non-small cell lung cancer (CheckMate 370). *J Thorac Oncol* 2018;13(5):682–8.
- [35] Patel SP, Pakkala S, Pennell NA, Reckamp KL, Lanzalone S, et al. Phase Ib Study of crizotinib plus pembrolizumab in patients with previously untreated advanced non-small cell lung cancer with ALK translocation. *Oncologist* 2020;25(7): 562–e1012.
- [36] Thummalpalali R, Bernstein E, Herzberg B, et al. Clinical and genomic features of response and toxicity to Sotorasib in a real-world cohort of patients with advanced KRAS G12C-mutant non-small cell lung cancer. *JCO Precis Oncol* 2023;7: e2300030.
- [37] Chour A, Denis J, Mascaux C, Zysman M, Bigay-Game L, et al. Brief report: severe Sotorasib-related hepatotoxicity and non-liver adverse events associated with sequential anti-programmed cell death (Ligand)1 and Sotorasib therapy in KRASG12C-mutant lung cancer. *J Thorac Oncol* 2023;S1556–0864(23):00572–5.
- [38] Felip E, de Braud FG, Maur M, Loong HH, Shaw AT, et al. Ceritinib plus Nivolumab in patients with advanced ALK-rearranged non-small cell lung cancer: results of an open-label, multicenter, phase 1B study. *J Thorac Oncol* 2020;15(3):392–403.
- [39] Cui W, Cotter C, Sreter KB, Heelan K, Creamer D, et al. Case of fatal immune-related skin toxicity from sequential use of Osimertinib after pembrolizumab: lessons for drug sequencing in never-smoking non-small-cell lung cancer. *JCO Oncol Pract* 2020;16(12):842–4.
- [40] Gianni C, Bronte G, Delmonte A, Burgio MA, Andrikou K, et al. Case report: stevens-johnson syndrome and hepatotoxicity induced by Osimertinib Sequential to Pembrolizumab in a PATIENT With EGFR-mutated lung adenocarcinoma. *Front Pharmacol* 2021;12:672233.
- [41] Kim DW, Gadgeel S, Gettinger SN, Riely GJ, Oxnard GR, et al. Brief report: safety and antitumor activity of Alectinib Plus Atezolizumab from a phase 1b study in advanced ALK-positive NSCLC. *JTO Clin Res Rep* 2022;3(8):100367.
- [42] Uchida T, Kaira K, Yamaguchi O, Moura A, Shiono A, et al. Different incidence of interstitial lung disease according to different kinds of EGFR-tyrosine kinase inhibitors administered immediately before and/or after anti-PD-1 antibodies in lung cancer. *Thorac Cancer* 2019;10(4):975–9.
- [43] Jung J, Kim HY, Kim DG, Park SY, Ko AR, et al. Sequential Treatment with an Immune Checkpoint Inhibitor Followed by a Small-Molecule Targeted Agent Increases Drug-Induced Pneumonitis. *Cancer Res Treat* 2021;53(1):77–86.
- [44] Shinno Y, Goto Y, Ohuchi M, Hamada A, Nokihara H, et al. The long half-life of programmed cell death protein 1 inhibitors may increase the frequency of immune-related adverse events after subsequent EGFR tyrosine kinase inhibitor therapy. *JTO Clin Res Rep* 2020;1(1):100008.
- [45] Rittberg R, Abraham N, Laskin J, Ho C. Hyper-sensitive? targeted therapy with a primed immune system. *J Thorac Oncol* 2022;17(6):734–6.
- [46] Brahmer JR, Drake CG, Wollner I, Powderly JD, Picus J, et al. Phase I study of single-agent anti-programmed death-1 (MDX-1106) in refractory solid tumors: safety, clinical activity, pharmacodynamics, and immunologic correlates. *J Clin Oncol* 2010;28(19):3167–75.
- [47] Lizotte PH, Hong RL, Luster TA, Cavanaugh ME, Taus LJ, et al. A high-throughput immune-oncology screen identifies EGFR inhibitors as potent enhancers of antigen-specific cytotoxic T-lymphocyte tumor cell killing. *Cancer Immunol Res* 2018;6(12):1511–23.
- [48] Canon J, Rex K, Saiki AY, Mohr C, Cooke K, et al. The clinical KRAS(G12C) inhibitor AMG 510 drives anti-tumour immunity. *Nature* 2019;575(7781):217–23.
- [49] Soria JC, Ohe Y, Vansteenkiste J, Reungwetwattana T, Chewaskulyong B, et al. Osimertinib in untreated EGFR-mutated advanced non-small-cell lung Cancer. *N Engl J Med* 2018;11;378(2):113–25.
- [50] Adderley H, Blackhall FH, Lindsay CR. Toxicity with small molecule and immunotherapy combinations in non-small cell lung cancer. *Cancer Immunol Immunother* 2021;70(3):589–95.
- [51] Kalra A, Rashdan S. The toxicity associated with combining immune check point inhibitors with tyrosine kinase inhibitors in patients with non-small cell lung cancer. *Front Oncol* 2023;13:1158417.
- [52] Saab KR, Mooradian MJ, Wang DY, Chon J, Xia CY, et al. Tolerance and efficacy of BRAF plus MEK inhibition in patients with melanoma who previously have received programmed cell death protein 1-based therapy. *Cancer* 2019;125(6): 884–91.
- [53] Dummer R, Long GV, Robert C, Tawbi HA, Flaherty KT, et al. Randomized phase III trial evaluating Spartalizumab Plus Dabrafenib and Trametinib for BRAF V600-mutant unresectable or metastatic melanoma. *J Clin Oncol* 2022;1;40(13): 1428–38.
- [54] Luo J, Florez N, Donnelly A, Lou Y, Lu K, et al. Adagrasib treatment after sotorasib-related hepatotoxicity in patients with KRASG12C-mutated non-small cell lung cancer: a case series and literature review. *JCO Precis Oncol* 2024. <https://ascopubs.org/doi/10.1200/PO.23.00644>.