



**HAL**  
open science

## The use of PEEK as an occlusal splint in a patient with histaminosis: A case report

Julien Delrieu, Sabine Joniot, Thierry Vergé, Florent Destruhaut, Karim Nasr, Thibault Canceill

### ► To cite this version:

Julien Delrieu, Sabine Joniot, Thierry Vergé, Florent Destruhaut, Karim Nasr, et al.. The use of PEEK as an occlusal splint in a patient with histaminosis: A case report. *Special Care in Dentistry*, 2022, 42 (6), pp.646-650. 10.1111/scd.12725 . hal-04709081

**HAL Id: hal-04709081**

<https://hal.science/hal-04709081v1>

Submitted on 25 Sep 2024

**HAL** is a multi-disciplinary open access archive for the deposit and dissemination of scientific research documents, whether they are published or not. The documents may come from teaching and research institutions in France or abroad, or from public or private research centers.

L'archive ouverte pluridisciplinaire **HAL**, est destinée au dépôt et à la diffusion de documents scientifiques de niveau recherche, publiés ou non, émanant des établissements d'enseignement et de recherche français ou étrangers, des laboratoires publics ou privés.



Distributed under a Creative Commons Attribution - NonCommercial - NoDerivatives 4.0 International License

## CASE REPORT

# The use of PEEK as an occlusal splint in a patient with histaminosis: A case report

Julien Delrieu<sup>1,2</sup> | Sabine Joniot<sup>1</sup> | Thierry Vergé<sup>1</sup> | Florent Destruhaut<sup>1,3</sup> | Karim Nasr<sup>1</sup> | Thibault Canceill<sup>1,4</sup> 

<sup>1</sup>Université Paul Sabatier, Faculté de Chirurgie Dentaire, Hôpitaux de Toulouse, Toulouse, France

<sup>2</sup>Université Toulouse 2 Jean-Jaurès, UMR Education, Formation, Travail, Savoirs, Toulouse, France

<sup>3</sup>URU EvolSan, Université Toulouse III Paul Sabatier, Toulouse, France

<sup>4</sup>CIRIMAT, Université Toulouse III Paul Sabatier, CNRS, INPT, Faculté de Pharmacie, Toulouse, France

## Correspondence

Thibault Canceill, UFR Odontologie, 3 chemin des Maraîchers 31400 Toulouse, France.

Email: [thibault.canceill@univ-tlse3.fr](mailto:thibault.canceill@univ-tlse3.fr)

## Abstract

Poly-(etheretherketone) (PEEK) began to be used in the field of odontology more than 10 years ago, especially in relation to the creation of removable partial dentures. Here we report the case of a 62 years old woman diagnosed with histamine intolerance (or histaminosis), who presented a very particular set of oral symptoms. She described a certain tingling, burning, and swelling of the mucous membranes. These symptoms seem to be linked with the wearing of a resin occlusal splint which was initially prescribed to compensate for the absence of a meniscus in the left temporomandibular joint of the patient. After a multidisciplinary concertation, it was decided to create a new splint with a resin-free material. For this reason, the production of a PEEK prosthesis was considered. Following the installation of the occlusal splint in the patient, and after clinical adjustments, she described the occlusion positioning as correct and a disappearance of the symptomatology. Mechanically, PEEK seems to have higher mechanical resistance than PMMA. Despite these characteristics, the use of PEEK still presents some limitations, especially concerning the overall aesthetic. Additionally, the prescription of the occlusal splint seems to be limited to patients who need special care. The case presented here thus confirms a new perspective concerning the use of PEEK as an occlusal splint.

## KEYWORDS

case report, dental materials, histaminosis, occlusal splint, PEEK, poly-(etheretherketone)

## 1 | INTRODUCTION

Histamine intolerance (or histaminosis) is characterized by the impossibility for patients to break down their intake of histamine, a molecule found in many foods,

including fruits, vegetables, several fish or even certain meat.<sup>1</sup> The main cause mentioned in the literature to explain histamine intolerance is a deficiency in Diamine Oxidase (DAO),<sup>2</sup> one of the enzymes responsible for the metabolism of histamine,<sup>3,4</sup> which leads to an

This is an open access article under the terms of the [Creative Commons Attribution-NonCommercial-NoDerivs](https://creativecommons.org/licenses/by-nc-nd/4.0/) License, which permits use and distribution in any medium, provided the original work is properly cited, the use is non-commercial and no modifications or adaptations are made.

© 2022 The Authors. *Special Care in Dentistry* published by Special Care Dentistry Association and Wiley Periodicals LLC.

accumulation of histamine in the blood.<sup>1</sup> The symptoms of this pathology are very similar to those of an allergic reaction. They affect the respiratory, circulatory and nervous systems, the skin barrier and also the digestive system with major gastrointestinal symptoms.<sup>5,6</sup>

The management of these patients with special needs is necessarily multidisciplinary in order to limit the occurrence of symptoms and to manage them when they develop. The purpose of this case report is to present the design of a specific occlusal splint in a patient with histaminosis.

## 2 | CASE DESCRIPTION

Here we report the case of a 62-year-old woman who had been directed to our specialized consultation in order to investigate the potential allergies she may have developed to various dental materials.

This patient followed a complex 15 years medical course to try to explain her atypical symptomatology. From a general point of view, she has food intolerances to many fruits and vegetables. Without any apparent relation to these intolerances, she also suffers from chronic anal pruritus—according to the doctors already consulted. The itching and irritation may be temporary or more persistent depending on the day. The patient did not report alcohol or tobacco consumption; she regularly drank tea during the day. After multiple medical consultations, internal medicine specialists diagnosed the patient with histamine intolerance (or histaminosis). This disease links all the various symptoms together she had presented for many years. In the mouth, the patient describes symptoms of tingling, burning and swelling of the mucous membranes that were initially localized on the tongue and now also extend to the lingual floor. This symptomatology has been evolving since 2005, when a resin occlusal splint was made that the patient still wears, continuously during the day and discontinuously at night. The wearing of this stabilization splint is accompanied by the appearance of the symptoms, whereas its removal makes them disappear. Clinically, no oral mucosa showed any apparent symptom of erythema nor swelling.

The splint was initially prescribed to compensate for the absence of a meniscus in the left temporomandibular joint, which, together with the patient's recurrent cervical hernias, caused significant chronic pain. The absence of the meniscus was detected by magnetic resonance imaging in 2005 and has obviously not changed since. Regardless of the mucosal signs triggered by wearing the splint, its adjustment in a myo-centric position with an average thickness of 2 mm has always helped the woman to relieve her joint pain.

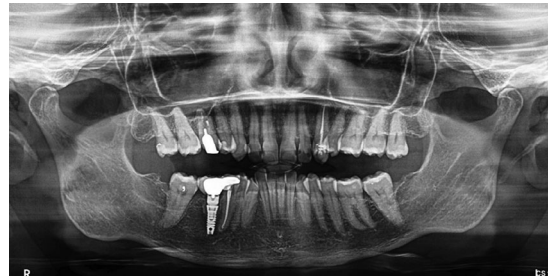
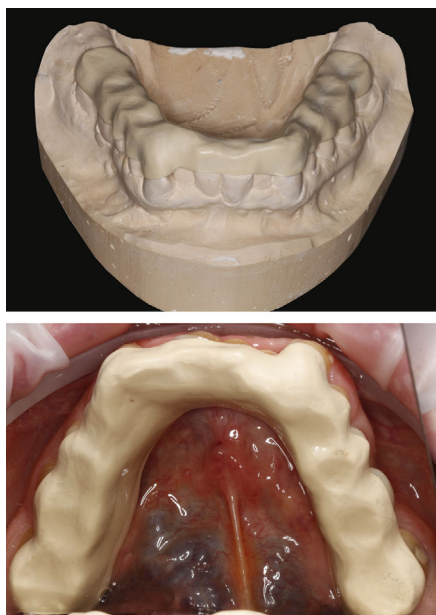


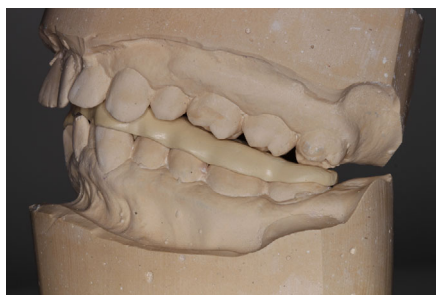
FIGURE 1 Panoramic X-ray of the patient performed during her first consultation in our dental unit

The patient's dental history included caries treatments in adolescence on teeth #16 and #46 which were treated endodontically, as were #24 and #35 later (Figure 1). The #16 has since undergone apical resection due to the presence of a periapical granuloma. The tooth #46 was extracted in the 2000's and replaced with an implant. Composite resins, of different ages due to their different radiolucency, are present on the maxillary incisors.

The oral manifestations presented by the patient during the wearing of her mouthpiece being evocative of a possible hypersensitivity reaction, complete skin prick-tests (SPT) were carried out in the allergology department of the hospital. These SPT, based on the injection of allergens extracts into the skin, constitute the most common and safe tests to determine a possible allergy<sup>7</sup> but they did not reveal here any allergic-type reaction in the patient. As a result and after a multidisciplinary concertation with the internist, the allergologist and several odontologists, it was decided to make a new splint with a resin-free material. We wanted to use a biomaterial that would release as few monomers as possible and that would be totally different in nature from the resin used in the previous tray. Benli et al. showed that PEEK presented the best surface behavior in terms of wear and roughness, compared to materials considered hypoallergenic such as polyethyleneterephthalate or ethylene vinyl acetate.<sup>8</sup> For this reason, and according to their recommendation in the conclusion, the production of a poly-(etheretherketone) (PEEK) prosthesis was considered. An impression of each arch and a recording of the patient's myocentric relationship were sufficient to prepare the design of the splint with the dental technician (Figure 2). We carried out registrations using irreversible hydrocolloids, but current CAD/CAM techniques would also have allowed for the recording of dental and mucosal surfaces for this type of treatment. The most common and easiest way for the prosthodontic lab to work with the material is to use digitized models and define the limits and shape of the future mouthpiece. This is then manufactured in a PEEK disc either in the laboratory or externally. Here, the settings chosen for the thickness of the splint



**FIGURE 2** Photographs of the PEEK occlusal splint on the plaster cast (upper) and when placed in mouth (lower). It clearly appears that the PEEK splint is much more visible than one in transparent resin



**FIGURE 3** The high mechanical resistance of PEEK material enables to adapt its thickness in a patient with difficult occlusal context

(2 mm) were based on the one in resin that the patient was already wearing because it helped relieve her joint problems.

Following the installation of the occlusal splint in the patient, and after clinical adjustments, she described a good occlusion positioning (Figure 3) and a disappearance of the oral symptomatology that occurred when wearing the resin splint. We did not face any particular difficulties during the installation and modifications of the occlusal splint, the procedure being very similar to the installation of a resin one. The patient was seen again several times to modify the areas of contact between the splint and the mucosa. These were the only points that bothered her. During an exchange of medical documents with the patient by e-mail, she confirmed to us that she was able to wear her

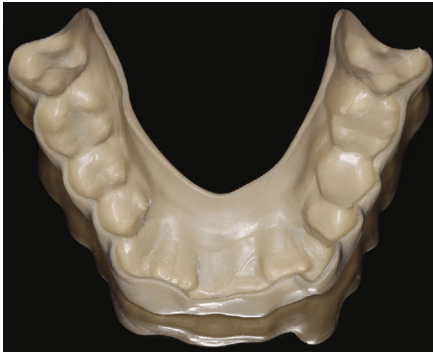mouthpiece every night and that she no longer had any oral symptoms, except for dietary reasons. To this day, the patient has been wearing the mouthpiece for more than a year and a half and her follow-up shows that her body has accepted it well. Further investigations on the treatment of her histaminosis are still underway.

### 3 | DISCUSSION

The case presented here confirms the perspective of using PEEK as an occlusal splint. This material is a semi-crystalline polyaromatic thermoplastic polymer which has been marketed in the industry since the early 1980's.<sup>9</sup> Its first biomedical application was developed in the late 1990's<sup>10</sup> as an alternative to metallic or ceramic medical devices in orthopedics or craniofacial reconstructive surgery. It has begun to be used in the field of odontology more than 10 years ago to create removable partial denture's basis, or several elements in implantology (fixtures abutments, healing screws).<sup>11</sup> This material is free of corrosion and radiolucent<sup>12,13</sup> which offers an interesting perspective in comparison with metals.

Its biocompatibility brings PEEK closer to the other materials that can be implanted for an extended period of time in a patient. Bacterial adhesion to PEEK is considered as low and appears to be comparable to that of Titanium, Zirconia or PMMA.<sup>9,11</sup> It is hypo-allergenic in the absence of monomers in its structure,<sup>14,15</sup> so it may trigger far fewer hypersensitivity reactions than other polymers. Only two cases have already been reported concerning allergic reactions to this material since it is used in medicine.<sup>16,17</sup> However, even if the biocompatibility of PEEK may seem attractive, its use in oral implantology may be limited by its bioinertia and its osseointegration capacity.<sup>18</sup> There are two mainstream techniques to improve the bioactivity of PEEK: by incorporation of bioactive materials in the matrix or by surface chemical modification.<sup>18,19</sup> Production and characterization processes are developing quickly and thus promise a profitable future for the material.

Its mechanical properties are even more interesting because in its natural state, that is, when it is not modified, PEEK shows a behavior close to natural hard tissue such as cortical bone and dentin.<sup>20</sup> With an elastic modulus close to 3.5-4GPa according to the majority of the studies,<sup>9</sup> strength transmission to natural tissues can be envisaged without harmful effects. Indeed, the use of materials (either metallic or ceramic) with mechanical properties far removed from living tissue can lead to pathogenic effects, such as stress shielding.<sup>21</sup> The reinforced versions of PEEK increase the elasticity modulus to a level close to that of cortical bone. This is especially true when the



**FIGURE 4** The lingual side of the splint is particularly deep in order to stabilize the structure

material is modified by carbon or hydroxyapatite adjunction for example.<sup>19</sup>

The conception of a PEEK occlusal splint has only been described once in the literature by Wang et al. who have performed occlusal splints to treat sleep bruxism in patients.<sup>22</sup> They chose to position the prosthesis on the upper jaw with an anterior fenestration to limit the esthetic disturbance.<sup>22</sup> Mechanically, PEEK seems to have higher mechanical resistance than PMMA, particularly in traction, flexion and resilience.<sup>23</sup> Its surface hardness is close to that of PMMA,<sup>24</sup> which is interesting for a use in contact with the occlusal surfaces of teeth. Inflexion, PEEK is more rigid and less flexible than PMMA resins,<sup>23</sup> a property which will greatly limit the deformations that the material may undergo during insertion and removal of the prosthesis (here the splint). This is the reason why it is necessary to take great care not to place the material below the retentive lines of the teeth (buccal and lingual) with the material, which could hinder the removal of the splint by the patient. To compensate for the lack of stability that may result, our dental technician has created a deeper lingual margin (Figure 4). Because the patient was uncomfortable with the contact of this flange on the tongue-floor, we had to carefully reduce this part of the splint in order to avoid compromising its stability.

Despite these characteristics, the use of PEEK still presents some limitations and its indication for occlusal splint seems to be limited for instance to patients who need special care due to a particular health status.

First of all, it is not possible to repair it and thus to modify it by any adjunction process. That means that the slightest fracture will compel the dentist and its technician to make a new splint entirely. This limitation is however relative, insofar as the precision of PMMA splints does not allow for reparation in case of fractures. Moreover, the use of CAD/CAM could make it possible to manufacture a second splint. Depending on this property, the practitioner has to limit to a minimum the oral modi-

fications he may perform on the splint because it may weaken it and an adjunction of material will not be possible thereafter.

Then, as the material is not widely used—mainly as a substitute to metallic armatures on removable partial dentures—only a few dental technicians are equipped to work on the PEEK in their own lab. When a special request is made for a patient, unequipped technicians will delocalize their production to specific laboratories through a digital process and the delivery time of the device is extended.

Finally, PEEK material presents really poor aesthetic properties. Even if different shades exist, they remain opaque and unnatural. In the case we have presented above, the splint has a milky shade that contrasts a lot with natural and ceramic teeth. It was however not a problem for the patient as the splint relieved its symptomatology, but the matter may be of concern to other patients more discerning of the appearance of their prosthesis despite the fact that most splints are worn during sleep.

This very white color makes it a material that stains very easily with food pigments, especially in patients who drink tea or coffee without removing their mouthpiece. Once ingrained, these stains are complex to remove. Thus, the hygiene maintenance of PEEK prostheses should be very clearly specified to patients at all appointments.

## 4 | CONCLUSION

This case report confirms the interesting new indication for PEEK as an occlusal splint beyond the best-known uses for framework for removable partial dentures and abutments on implants. Even though all dental technicians are not yet equipped to work on this material, it will still be possible to subcontract the process. The possibility of using PEEK as splints will allow the dentists to treat all their patients, whatever their allergies or other health issues. Many people turning to highly specialized occlusion specialists are effectively in a therapeutic limbo unable to treat their oro-cranial pain. Ruling out allergies by using a hypoallergenic material can often be perceived as a welcome option by the patient.

## ACKNOWLEDGMENTS

None to declare. Funding: None to declare.

## CONFLICT OF INTEREST

The authors declare no conflict of interest.

## ETHICS STATEMENT

The present article does not present any research performed on humans nor on animals. The patient consent

has been obtained for publication of information and photos.

## ORCID

Thibault Canceill  [https://orcid.org/0000-0002-0049-](https://orcid.org/0000-0002-0049-7622)

7622

## REFERENCES

- Comas-Basté O, Sánchez-Pérez S, Veciana-Nogués MT, Latorre-Moratalla M, Vidal-Carou MDC. Histamine intolerance: the current state of the Art. *Biomolecules*. 2020;10(8):ePub1181.
- Izquierdo-Casas J, Comas-Basté O, Latorre-Moratalla ML, et al. Low serum diamine oxidase (DAO) activity levels in patients with migraine. *J Physiol Biochem*. 2018;74(1):93–99.
- Kovacova-Hanusikova E, Buday T, Gavliakova S, Plevkova J. Histamine, histamine intoxication and intolerance. *Allergol Immunopathol (Madr)*. 2015;43(5):498–506.
- Aschenbach JR, Honscha KU, von Vietinghoff V, Gäbel G. Bioelimination of histamine in epithelia of the porcine proximal colon of pigs. *Inflamm Res Off J Eur Histamine Res Soc Al*. 2009;58(5):269–276.
- Maintz L, Novak N. Histamine and histamine intolerance. *Am J Clin Nutr*. 2007;85(5):1185–1196.
- Schnedl WJ, Lackner S, Enko D, Schenk M, Mangge H, Holasek SJ. Non-celiac gluten sensitivity: people without celiac disease avoiding gluten-is it due to histamine intolerance? *Inflamm Res Off J Eur Histamine Res Soc Al*. 2018;67(4):279–284.
- Frati F, Incorvaia C, Cavaliere C, et al. The skin prick test. *J Biol Regul Homeost Agents*. 2018;32(1):19–24.
- Benli M, Eker Gümüş B, Kahraman Y, et al. Surface roughness and wear behavior of occlusal splint materials made of contemporary and high-performance polymers. *Odontology*. 2020;108(2):240–250.
- Skirbutis G, Dzingutė A, Masiliūnaitė V, Šulcaitė G, Žilinskas J. PEEK polymer's properties and its use in prosthodontics. A review. *Stomatologija*. 2018;20(2):54–58.
- Papathanasiou I, Kamposiora P, Papavasiliou G, Ferrari M. The use of PEEK in digital prosthodontics: a narrative review. *BMC Oral Health*. 2020;20(1):217.
- Najeeb S, Zafar MS, Khurshid Z, Siddiqui F. Applications of polyetheretherketone (PEEK) in oral implantology and prosthodontics. *J Prosthodont Res*. 2016;60(1):12–19.
- Hahnel S, Wieser A, Lang R, Rosentritt M. Biofilm formation on the surface of modern implant abutment materials. *Clin Oral Implants Res*. 2015;26(11):1297–1301.
- Sobieraj MC, Kurtz SM, Rimnac CM. Notch sensitivity of PEEK in monotonic tension. *Biomaterials*. 2009;30(33):6485–6494.
- Zoidis P, Papathanasiou I, Polyzois G. The use of a modified poly-ether-ether-ketone (PEEK) as an alternative framework material for removable dental prostheses. A clinical report. *J Prosthodont Off J Am Coll Prosthodont*. 2016;25(7):580–584.
- Vaezi M, Yang S. A novel bioactive PEEK/HA composite with controlled 3D interconnected HA network. *Int J Bioprinting* 2015; ePublication
- Maldonado-Naranjo AL, Healy AT, Kalfas IH. Polyetheretherketone (PEEK) intervertebral cage as a cause of chronic systemic allergy: a case report. *Spine J Off J North Am Spine Soc*. 2015;15(7):ePub1-3.
- Kofler L, Wambacher M, Schweinzer K, Scherl M, Kofler H. Allergic reaction to polyether ether ketone following cross-reactivity to epoxy resin. *J Cutan Med Surg*. 2017;21(1):78–79.
- Zheng Y, Xiong C, Zhang S, Li X, Zhang L. Bone-like apatite coating on functionalized poly(etheretherketone) surface via tailored silanization layers technique. *Mater Sci Eng C Mater Biol Appl*. 2015;55:512–523.
- Uddin MN, Dhanasekaran PS, Asmatulu R. Mechanical properties of highly porous PEEK bionanocomposites incorporated with carbon and hydroxyapatite nanoparticles for scaffold applications. *Prog Biomater*. 2019;8(3):211–221.
- Garcia-Gonzalez D, Rusinek A, Jankowiak T, Arias A. Mechanical impact behavior of polyether-ether-ketone (PEEK). *Compos Struct*. 2015;124:88–99.
- Lee W-T, Koak J-Y, Lim Y-J, Kim S-K, Kwon H-B, Kim M-J. Stress shielding and fatigue limits of poly-ether-ether-ketone dental implants. *J Biomed Mater Res B Appl Biomater*. 2012;100(4):1044–1052.
- Wang S, Li Z, Ye H, Zhao W, Liu Y, Zhou Y. Preliminary clinical evaluation of traditional and a new digital PEEK occlusal splints for the management of sleep bruxism. *J Oral Rehabil*. 2020;47(12):1530–1537.
- Muhsin SA, Hatton PV, Johnson A, Sereno N, Wood DJ. Determination of Polyetheretherketone (PEEK) mechanical properties as a denture material. *Saudi Dent J*. 2019;31(3):382–391.
- Shrivastava SP, Dable R, Raj APN, Mutneja P, Srivastava SB, Haque M. Comparison of mechanical properties of PEEK and PMMA: an in vitro study. *J Contemp Dent Pract*. 2021;22(2):179–183.

**How to cite this article:** Delrieu J, Joniot S, Vergé T, Destruhaut F, Nasr K, Canceill T. The use of PEEK as an occlusal splint in a patient with histaminosis: A case report. *Spec Care Dentist*. 2022;42:646–650. <https://doi.org/10.1111/scd.12725>