



HAL
open science

Stress shielding in stemmed reverse shoulder arthroplasty: an updated review

Angelo V. Vasiliadis, Vasileios Giovanoulis, Nikolaos Lepidas, Ioannis Bampis, Elvire Servien, Sebastien Lustig, Stanislas Gunst

► **To cite this version:**

Angelo V. Vasiliadis, Vasileios Giovanoulis, Nikolaos Lepidas, Ioannis Bampis, Elvire Servien, et al.. Stress shielding in stemmed reverse shoulder arthroplasty: an updated review. SICOT-J, 2024, 10, pp.37. 10.1051/sicotj/2024029 . hal-04704650

HAL Id: hal-04704650





<https://hal.science/hal-04704650v1>

Submitted on 21 Sep 2024

HAL is a multi-disciplinary open access archive for the deposit and dissemination of scientific research documents, whether they are published or not. The documents may come from teaching and research institutions in France or abroad, or from public or private research centers.

L'archive ouverte pluridisciplinaire **HAL**, est destinée au dépôt et à la diffusion de documents scientifiques de niveau recherche, publiés ou non, émanant des établissements d'enseignement et de recherche français ou étrangers, des laboratoires publics ou privés.

Stress shielding in stemmed reverse shoulder arthroplasty: an updated review

Angelo V. Vasiliadis^{1,2,*} , Vasileios Giovanoulis² , Nikolaos Lepidas³, Ioannis Bampis^{2,4}, Elvire Servien^{2,5}, Sebastien Lustig^{2,6} , and Stanislas Gunst³ 

¹ Department of Orthopaedic Surgery, St. Luke's Hospital, Panorama-Thessaloniki, 55236, Greece

² Orthopaedics Surgery and Sports Medicine Department, FIFA Medical Center of Excellence, Croix-Rousse Hospital, Lyon University Hospital, Lyon, 69004, France

³ Ramsay Santé, Hôpital Privé Jean Mermoz, Centre Orthopédique Santy, 24 avenue Paul Santy, Lyon 69008, France

⁴ Orthopaedics Department, Bioclinic, 11524 Athens, Greece

⁵ Interuniversity Laboratory of Biology of Mobility, LIBM, EA 7424, Claude Bernard Lyon 1 University, Lyon, 69008, France

⁶ Univ Lyon, Claude Bernard Lyon 1 University, IFSTTAR, LBMC UMR_T9406, Lyon, 69622, France

Received 8 July 2024, Accepted 26 July 2024, Published online 20 September 2024

Abstract – *Background:* Reverse shoulder arthroplasty (RSA) is popular for the treatment of degenerative glenohumeral joint disease. Bone remodeling around the humeral stem related to stress shielding (SS) has been described. This review focuses on the specific radiological characteristics, risk factors, and clinical consequences of SS in RSA. *Methods:* A meticulous review was conducted of articles published between 2013 and 2023. Data on the definition, risk factors, and clinical impact of stress shielding were recorded. *Results:* Twenty-eight studies describing 2691 patients who had undergone RSA were included. The mean age of patients ranged from 63 to 80 years with mean follow-up periods of 12 months to 9.6 years. The prevalence of SS reached up to 39% at a 2-year follow-up. Females and elderly are typically at higher risk due to osteopenia. SS was more frequent with the use of long stems (>100 mm) compared to short stems (<100 mm). Stem design, onlay or inlay, and neck-shaft-angle did not influence SS. Frontal misalignment and a high filling ratio are risk factors for SS. Biological factors also contribute to SS, associated with scapular notching. No correlation was found between SS and clinical outcomes. *Conclusions:* SS is common in patients with cementless implants after RSA, especially in female and elderly patients. It can be limited by implanting stems with a low diaphyseal filling-ratio, in correct coronal alignment. Risk factors for polyethylene debris, primarily scapular notching, should be avoided. The authors found no clinical consequences of stress shielding, but longer-term follow-up studies are required to confirm these findings.

Key words: Reverse shoulder arthroplasty, Stress shielding, Risk factors, Clinical outcomes, Radiographic outcomes.

Introduction

Reverse shoulder arthroplasty (RSA) represents a successful treatment option for degenerative disease of the glenohumeral joint [1, 2]. It was initially proposed by Grammont for a rotator cuff disease and good clinical results have been achieved in mid- and long-term follow-up [3]. Many factors may contribute to alterations around the humeral stem, which is responsible for the load transfer to the bone, and therefore humeral stem design could lead to different biological reactions of the components [4]. Nagels et al. [5] defined SS as a reduction in bone density in the humerus, following Wolff's law, due to a decrease in mechanical stress caused using humeral stem [6]. Additionally,

Melis et al. [6] defined SS as one or more signs of bone narrowing or formation of osteolysis by measuring changes in the proximal humerus's bone mineral density (BMD) and cortical thickness.

Preservation of bone has therefore become a major goal. Through the last decades, an important evolution regarding the humeral stem has been achieved. A progressive shift from long cemented stems to the adoption of long uncemented and more recently short cementless stems provides orthopedics surgeons with a variety of options [7]. However, there are several risk factors that we must consider, which may lead to bone resorption and implant loosening [8]. The degree of SS observed may vary depending on the type of implant used, the location of the implant, and the type of fixation [6, 8]. Therefore, careful monitoring of patients who have undergone

*Corresponding author: vasigiova@gmail.com

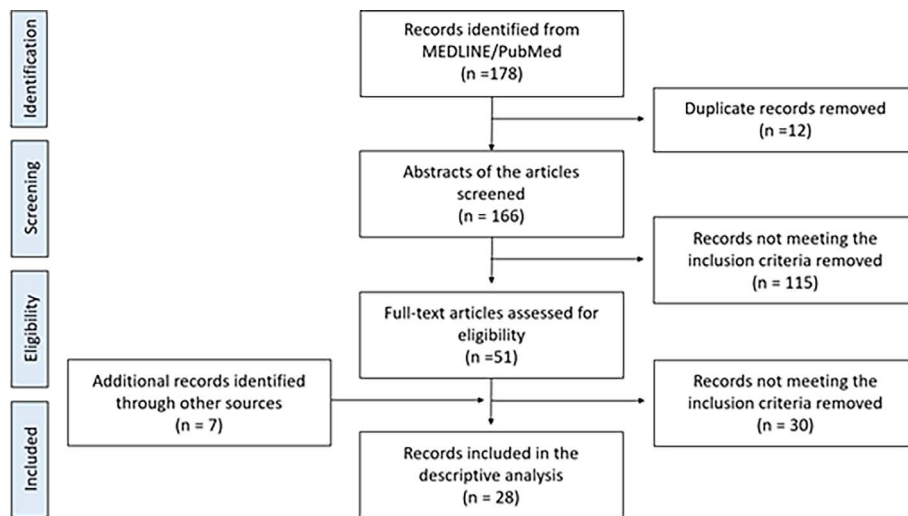


Figure 1. Flowchart of studies included.

RSA is important to detect any signs of SS and to address them early to avoid potential complications that may require revision surgery.

The present study is a review of all published articles describing SS in RSA to gather as much data as possible for the analysis of the risk factors and radiological and functional outcomes of SS, to best inform patient management.

Methods

Study design

A literature review was conducted across MEDLINE/PubMed from conception up to March 2023. Alone or in combination the terms “reverse shoulder arthroplasty”, “stress shielding”, “risk factors”, “clinical outcomes”, “functional outcomes” and “radiological outcomes” were used for data extraction. References listed in included articles were also analyzed to identify additional cases.

Study selection

Articles were screened by title, abstract, and full text by two researchers (VG and AVV) working independently. Disagreements about inclusion were settled by a third investigator (SG) if no consensus could be reached. Excluded studies were listed.

The same authors (VG, AVV.) reviewed the papers separately and extracted the data for each included study. They used a predefined Microsoft Excel spreadsheet for data extraction. The following data were extracted: (1) study type details: authors, publication year, country, study design, level of evidence; (2) study population: sample size, age, level of evidence, gender, indications, follow-up; (3) range of motion; (4) functional/clinical outcomes; (5) radiographic outcomes (6) post-operative complications, revisions for any reason; (7) potential risk factors for SS.

Selection criteria

The abstracts of these papers were reviewed to determine if eligibility criteria were met, which were: (i) patients undergoing RSA for any reason; (ii) full-text articles in indexed journals; (iii) articles published in English; (iv) human studies; (v) mean follow-up of at least 12 months. Exclusion criteria were: (i) treatment using total shoulder arthroplasty (TSA) and hemiarthroplasty, (ii) studies included only stemless prosthesis, (iii) availability of only an abstract, (iv) review article and meta-analysis, (v) case reports and (vi) engineering and mathematical modeling studies. The risk of bias was assessed using the Cochrane Risk of Bias Tool for randomized studies and the Newcastle-Ottawa Scale for observational studies. This assessment was conducted by two independent reviewers (VG and AVV), with disagreements resolved by a third reviewer (SG).

Results

Of the 161 articles initially identified, 28 articles were found eligible after the screening process for this review. A summary of the flowchart of the literature search can be illustrated in [Figure 1](#). Two out of the 28 studies (7.1%) were prospective [9, 10] 25 (89.3%) were retrospective [4, 6, 11–33], and one case series [34]. Eight studies (28.6%) had a level of evidence IV [9, 15, 17, 20, 23–25, 31], whereas 20 studies (71.4%) had a level of evidence III ([Table 1](#)) [4, 6, 10–14, 16, 18, 19, 21, 22, 26–30, 36, 37]. All cohort studies were graded as good/high quality based on the Newcastle scale.

In total, 2691 patients (1029 males and 1657 females from the available data) were included. The mean age ranged from 63 years [10] to 80 years [14]. Their mean follow-up period ranged from 1 year [29] to 9.6 years [6] ([Table 1](#)). One article (4%) only included cases of revision RSA [22], two papers (7.1%) considered cases of both primary and revision RSA, and the remaining 25 papers (89%) considered primary RSA patients only ([Table 1](#)). The most common aetiologies among

Table 1. The basic characteristics of the included studies and participants.

Study	Design/Level	Gender (M/F)	Age (years)	FU (months)	Indications
Yokoya et al. [35]	Retrospective/III	42/93	M:78.2/F:77.6	M:36.5/F:30.6	Primary RCA: 55.6% MRC tear: 31.9% Fractures: 6.7% OA/RA: 5.9
Nourissat et al. [36]	Retrospective/III	4/14	74.6	72	Primary MRC tear OA
Erickson et al. [37]	Retrospective/III	295/282	68.5 to 69.4	24	Primary
Giordano et al. [11]	Retrospective/III	10/66	76 to 76.2	36 to 46.8	Primary RCA OA
Kim et al. [12]	Retrospective/III	25/79	72.1 to 73.5	13.2 to 13.5	Primary
Kramer et al. [13]	Retrospective/III	8/43	74	27	Primary PHF
Lopez et al. [14]	Retrospective/III	29/39	78 to 80	26.5 to 37.8	Primary PHF
Valenti et al. [15]	Retrospective/IV	9/15	68.7	44.7	Primary MRC tear
Mazaleyrat et al. [4]	Retrospective/III	29/103	74.5 to 75.3	9 years (108 m)	Primary RCA: 56.8% MRC tear: 36.3% OA: 12.8%
Nagase et al. [31]	Case series/IV	1/12	74	57.9	Primary RA: 100%
Polisetty et al. [16]	Retrospective/III	40/52	73.2 to 74.8	29 to 31	Primary MRC tear OA
Abdic et al. [17]	Retrospective/IV	42/80	74	–	Primary RCA: 63 to 78% OA: 33 to 41% RA: 4 to 5%
Brolin et al. [18]	Retrospective/III	31/89	70.6	35.2	Primary
Denard et al. [19]	Retrospective/III	49/70	69.3 to 71.1	36.1 to 36.8	Primary RCA FRC repair OA
Inoue et al. [20]	Retrospective/IV	23/58	76.5	18.5	Mixed RCA: 81.3% FRC repair: 8.3% Malunion PHF: 4.2% OA: 4.2% Revision: 2%
Aibinder et al. [21]	Retrospective/III	65 both	68	3.8 years	Primary RCA: 50.8% OA: 38.5% AVN: 3.1% Post-traumatic: 1.5% RA: 6.1%
Merolla et al. [22]	Retrospective/III	23/51	74.7 to 75.8	24	Primary RCA
Raiss et al. [23]	Retrospective/IV	77 both	72	28	Primary OA
Harmsen and Norris [24]	Retrospective/IV	82/82	68.2	36.6	Primary RCA: 42.1% MRC tear: 29.9% OA: 17.7% RA: 4.9% Infection: 1.8% PHF: 1.2%

(Continued on next page)

Table 1. (Continued)

Study	Design/Level	Gender (M/F)	Age (years)	FU (months)	Indications
Weber-Spickschen et al. [25]	Retrospective/IV	6/8	70	43	Revision Haematoma Infection
Al-Hadithy et al. [9]	Prospective/IV	8/29	79	5 years	Primary RCA
Wiater et al. [26]	Retrospective/III	35/66	71.95 to 72.47	32.4 to 37	Primary RCA MRC tear
Holschen et al. [27]	Retrospective/III	16/26	72 to 76	34 to 42	Primary RCA: 100%
Melis et al. [6]	Retrospective/III	20/45	69.4	9.6 years	Mixed RCA: 73.8% MRC tear: 13.8% Revisions: 12.4%
Mazaleyrat et al. [28]	Retrospective/III	24/80	74.6 to 75.1	9.5 years	Primary RCA: 53–54% MRC tear: 33–36% OA: 11–13%
Erickson et al. [29]	Retrospective/III	145/131	67.8 to 69.4	12 minimum	Primary
Giuseffi et al. [30]	Retrospective/III	15/29	76	27	Primary RCA: 75% AVN: 13.6% OA: 4.5% RA: 6.8%
Schnetzke et al. [10]	Prospective/III	4/20	63	25	Primary OA: 62.1% Post-traumatic: 27.6% AVN: 6.9% RA: 3.4%

Abbreviations: M, male; F, female; FU, follow-up; RCA, rotator cuff arthropathy; MRC tear, massive rotator cuff tear; OA, osteoarthritis; RA, rheumatoid arthritis; PHF, proximal humeral fracture; FRC repair, failed rotator cuff repair; AVN, avascular necrosis.

patients who had undergone primary RSA with a known etiology were rotator cuff arthropathy (proportions ranging from 50.8 to 81.3%) [20, 21], glenohumeral osteoarthritis (4.2 to 41%) [17–20], massive rotator cuff tear (14 to 36.3%) [4, 6] and inflammatory arthropathy (3.4% to 6.8%) [10, 30]. In mixed studies of primary and revision RSA [6, 20], the main indications for revision RSA were glenoid loosening of an anatomic prosthesis, conversion for humeral head replacement; and failed hemiarthroplasty or TSA. The study of exclusively revision RSAs involved 15 patients who had undergone conversions from TSA to RSA because of hematoma or infection (Table 1) [25].

Overall, 22 studies examined the clinical/functional outcomes and these studies used 12 clinical/functional subjective scores (Table 2). The most commonly used score was the Constant score in 13 studies (59.1%) [6, 9–15, 22, 26, 27, 31, 37]. The visual analog scale (VAS) pain score [11, 12, 15, 16, 19, 22, 24–26, 29, 30, 35] and the American Shoulder and Elbow Surgeons (ASES) score [11, 12, 14, 16, 19, 21, 24–26, 29, 35, 37] were each used in 12/22 studies (55%). The subjective shoulder value (SSV) score was used in five studies (23%) [10, 15, 25–27] and the simple assessment numeric evaluation (SANE) score [19, 24, 29], the Western Ontario osteoarthritis of the shoulder (WOOS) score [25, 29, 35] and the Neer score [21, 29, 30] were mentioned in three studies (14%). The Simple

Shoulder Test score [19, 22] and the Oxford [9, 25] shoulder score were used in two studies (9.1%), and the Japanese Orthopaedic Association (JOA) score [36], Shoulder36 (version 1.3) score [31] and the disability of arm, shoulder and hand (DASH) score [10] were used in one study each (Table 2).

Postoperative range of motion (ROM) was evaluated in 19/28 studies (68%) (Table 2) [6, 9–12, 14–16, 19, 21, 22, 24, 26, 27, 29–31, 36, 37]. Mean ROM was measured with a goniometer in terms of forward flexion, abduction, external rotation, and internal rotation. Studies that compared preoperative and postoperative ROM found significant improvements at final follow-up [9–11, 15, 19, 21, 22, 24, 26, 27, 30]. Two studies found that patients with a short humeral stem had significantly higher ROM in active forward flexion and internal rotation compared with those with standard humeral stems [29, 35]. Two studies found that patients with cemented prostheses had greater ROM in forward flexion and abduction but lower ROM in external and internal rotation than those with uncemented implants [6, 14]. One study found that patients with an onlay humeral prosthesis had significantly greater ROM in active external rotation and forward flexion [16]. Finally, one study comparing outcomes in patients with different implant neck-shaft angles (155° vs. 135°) found no differences between the groups in any of the considered movements (forward flexion, abduction, and external rotation) [27].

Table 2. Detailed data on ROM, strength, functional/clinical outcomes, radiographic outcomes, and complications in RSA.

Study	ROM	Strength	Functional/Clinical outcomes	Radiographic outcomes	Complications
Yokoya et al. [35]	FF, IR, ER Not improve	–	JOA Not improve	AP, axillary, scapular Y Cortical thinning and osteopenia: 50.3% Calcar osteolysis: 34.8% Great tuberosity: 29.6%	–
Nourissat et al. [36]	–	–	Constant ↓ in patients with resorption ASES	AP, lateral Cortical contact: 79% Humeral resorption: 21%	Dislocation (5.5%)
Erickson et al. [37]	FF, IR, ER Short stem: ↑FF, IR	–	ASES, WOOS, VAS Short stem had better scores	Grashey, axillary Short stem: ↑FR _{met} , FR _{dia}	Short-stem: Periprosthetic fracture (0.4%) Revision (0.3%) Standard-stem: Infection (0.8%) Revision (0.4%)
Erickson et al. [29]	FF, IR, ER More IR in short-stem	–	ASES, WOOS, SANE, Neer, VAS Less VAS, better ASES and WOOS in short-stem vs. standard- stem	Grashey, axillary Higher FR in standard-stem Valgus alignment: 8.6% (standard-stem) vs. 2.2% (short-stem) Calcar osteolysis: 12.9% (standard-stem)	–
Giordano et al. [11]	FF, IR, ER, Abd Improve	Handheld dynamometer ↑post-op.	Constant, ASES, VAS Improve	AP, IR, ER Scapular notching: 35.2% (short stem) and 23.8 (long stem)	Short-onlay-stem: Loosening, glenoid (2.9%) Dislocation (2.9%) Long-inlay-stem: Infection (2.4%) Dislocation (2.4%) Low FR (19.6%): Acromial fracture (3.9%) Persistent pain (3.9%) ROM difficulty (11.8%) High FR (20.8%): Acromial fracture (3.8%) Persistent pain (%) ROM difficulty (9.8%)
Kim et al. [12]	FF, IR, ER High FR: ↑FF, IR	–	Constant, ASES, VAS Improve High FR: ↑ASES	AP, axillary, lateral Low FR: ↓ stress shielding	Non-cemented: Revision (5.9%) Cemented: Revision (5.9%)
Kramer et al. [13]	–	–	Constant Improve	AP, axillary, Neer Great tuberosity healing: 71% (non- cemented), 79% (cemented) Lesser tuberosity healing: 82% (non- cemented), 94% (cemented) Scapular notching: 6% (non-cemented), 18% (cemented)	Non-cemented: Revision (5.9%) Cemented: Revision (5.9%)
Lopez et al. [14]	FF, IR, ER, Abd Cemented: ↑ FF (127° vs 108° in non-cemented)	–	Constant, ASES Not differences cemented vs. non- cemented	AP, axillary Radiolucent lines: 17.8% (cemented), 8.3% (non-cemented)	Non-cemented (8.6%) Cemented (17.7%)

(Continued on next page)

Table 2. (Continued)

Study	ROM	Strength	Functional/Clinical outcomes	Radiographic outcomes	Complications
Valenti et al. [15]	FF, IR, ER, Abd Improve	–	Constant, VAS, SSV Improve	Tuberosity healing: 64% (cemented), 91% (non-cemented) AP, axillary, IR, ER Radiolucent lines: only cemented Tuberosity resorption: non-cemented Stress shielding: non-cemented	–
Mazaleyrat et al. [4]	–	–	–	AP, axillary Tuberosity resorption: cemented > non-cemented	Non-cemented (8.5%) Cemented (4.2%)
Mazaleyrat et al. [28]	–	–	–	AP, axillary Tuberosity resorption: 59% (non-cemented), 30% (cemented) Stress shielding: 39% (non-cemented) Scapular notching: 41% (both non-cemented and cemented) Scapular Y	Non-cemented (5.4%): Periprosthetic fracture (3.6%) Humeral loosening (1.8%) Cemented (1.8%): Humeral loosening (1.8%) 0%
Nagase et al. [31]	FF, IR, ER, Abd ↑ FF, Abd ↓ ER	–	Constant, Shoulder36 Improve	Stress shielding: 21.4% No loosening No heterotopic ossification AP, scapular Y	
Polisetty et al. [16]	FF, IR, ER Onlay: greater FF and ER	–	ASES, VAS, SST No differences between inlay and onlay humeral design	Tuberosity and calcar resorption: 73.9% (onlay design)	Inlay design: Scapular notching (8.7%) Acromial fracture (8.7%) Onlay design: Scapular notching (8.7%) Acromial fracture (13.6%)
Abdic et al. [17]	–	–	–	AP Malaligned: larger stem and ↑ FR	–
Brolin et al. [18]	–	–	–	AP Osteolysis: higher in cemented Stress shielding: higher in non-cemented Grashey	Cemented: Humeral loosening (1.7%)
Denard et al. [19]	FF, ER Improve	–	ASES, VAS, SST, SANE Improve	High adaptive changes: 3.2% (non-cemented) Calcar osteolysis: 43% (non-cemented), 58% (cemented)	Total (8.4%): Infection (10%) Stiffness (10%) Instability (10%) Scapular fracture (50%) Persistent pain (10%) Popping (10%) Revision (2.5%)
Inoue et al. [20]	–	–	–	AP ↑ bone resorption in greater tuberosity, lateral diaphysis, calcar	–
Aibinder et al. [21]	FF, IR, ER Improve	–	ASES, Neer ↑ ASES Excellent Neer (41%)	AP Stress shielding: 14% Calcar resorption: 23% Scapular notching: 5%	Total (9%) both TSA and RSA: Infection (33.3%) Fracture of humeral tray (22.3%) Glenoid loosening (11.1%) Instability (33.3%)

(Continued on next page)

Table 2. (Continued)

Study	ROM	Strength	Functional/Clinical outcomes	Radiographic outcomes	Complications
Merolla et al. [22]	FF, IR, Abd Improve	–	Constant, VAS ↑ Constant ↓ VAS	Grashey, axillary, scapular Y Glenoid radiolucency: inlay > onlay Scapular notching: 39% (inlay), 5% (onlay) Humeral radiolucency: 25% (inlay), 10% (onlay) Cortical thinning, spot weld and tuberosity resorption: inlay > onlay	Inlay design: Dislocation (5.6%) Instability (2.8%) Onlay design: Scapular fracture (5.3%) Acromial fracture (2.6%) Infection (7.9%) Revision (2.6%) Total (7.8%): Infections (2.6%) Dislocation (1.3%) Acromial fracture (2.6%) Total (15.1%): Acromial/scapular fracture (19.4%) Deep infection (19.4%) Dislocation (13.9%) Transient neuropathy (11.1%) Superficial infection (8.3%) Periprosthetic fracture (2.8%) Humeral shaft fracture (2.8%) Malposition (2.8%) Retained drill fragment (2.8%) Dislocation (7.1%)
Raiss et al. [38]	–	–	–	AP, 3 different rotation views FR influenced the radiographic changes Cortical contact led to high bone adaptations Bone adaptations: female > male AP, axillary, scapular Y Radiolucent lines (met): 97.4% Cortical resorption: no Osteolysis: no	
Harmsen and Norris [24]	FF, ER, Abd Improve	Abd. strength in scapular plane improve (dynamometer)	ASES, VAS, SANE ↑ ASES, SANE ↓ VAS	AP, axillary, scapular Y Radiolucent lines: 0% (glenoid), 7.1% (humeral stem) Stress shielding: 14.3% Resorption: no Loosening: no	
Weber-Spickschen et al. [25]	–	–	ASES, Oxford, WOOS, SSV, VAS ↑ ASES, Oxford, WOOS, SSV ↓ VAS	AP, axillary, lateral Scapular notching: 68% Stress shielding: 10.8% Heterotrophic ossification: 42%	Total (10.8%): Glenoid implant failure (5.4%) Acromial fracture (2.7%) Broken glenoid screw (2.7%) Revision (2.7%)
Al-Hadithy et al. [9]	FF, IR, ER, Abd Improve	–	Constant, Oxford ↑ Constant, Oxford	AP, laterals Loosening: no Stress shielding: 7.8% (non-cemented)	Non-cemented (7.8%): Systemic (3.1%) Dislocation (4.7%) Cemented (16.2%): Systemic (8.1%) Dislocation (2.7%) Infection (2.7%) Acromial fracture (2.7%)
Wiater et al. [26]	FF, IR, ER Improve	–	Constant, ASES, SSV, VAS ↑ Constant, ASES, SSV ↓ VAS		

(Continued on next page)

Table 2. (Continued)

Study	ROM	Strength	Functional/Clinical outcomes	Radiographic outcomes	Complications
Holschen et al. [27]	FF, ER, Abd Not differences between operated and non-operated side	–	Constant, SSV No differences between 155° and 135° neck shaft angle	AP, axillary Scapular notching: 66% (155°) and 33% (135°) Calcification: 48% (155°) and 38% (135°) Stress shielding: 29% (155°) and 10% (135°)	135° neck-shaft angle: Infection (4.8%)
Melis et al. [6]	FF, ER, ER (90°), Abd No differences between cemented and non-cemented	–	Constant No differences between cemented and non-cemented Very satisfied and satisfied: 84.5%	AP, axillary Scapular notching: 88% GT resorption: 69% (cemented) and 100% (non-cemented) LT resorption: 45% (cemented) and 76% (non-cemented)	Total (10.3%): Instability (5.9%) Humeral fracture (2.9%) Acromial fracture (1.5%) Cemented: Humeral loosening (11.8%) Non-cemented: Humeral loosening (5.9%) Total (6.9%): Brachial plexus abnormality (2.3%) Dislocation (2.3%) Infection (2.3%) Total (8.3%): Acromial fracture (8.3%)
Giuseffi et al. [30]	FF, ER Improve	–	Neer, VAS Neer: Excellent (61.4%) ↓ VAS	AP, scapular Y Malaligned: 4.6% Heterotopic ossification: 41%	Total (6.9%): Brachial plexus abnormality (2.3%) Dislocation (2.3%) Infection (2.3%) Total (8.3%): Acromial fracture (8.3%)
Schnetzke et al. [10]	FF, ER, Abd Improve	Arm strength (ISOBEX dynamometer)	Constant, SSV, DASH, Pain ↑ Constant, SSV ??? DASH ↓ Pain	AP, axillary, scapular Y Cortical thinning/osteopenia: 42.1% High adaptations: 10.5%	Total (8.3%): Acromial fracture (8.3%)

Abbreviations: ROM, range of motion; FF, forward flexion; IR, internal rotation; ER, external rotation; Abd, abduction; JOA, Japanese Orthopaedic Association; AP, anteroposterior; ASES, American Shoulder and Elbow Surgeons; WOOS, Western Ontario Osteoarthritis of the Shoulder; VAS, visual analogue score; FR_{met}, filling ratio metaphyseal; FR_{dia}, filling ratio diaphyseal; SSV, subjective shoulder value; SST, Simple Shoulder Test; SANE, Simple Assessment Numeric Evaluation; ADLEIR, Activities of daily living with requirement for external and internal rotation score; DASH, Disability of Arm, Shoulder and Hand; TSA, total shoulder arthroplasty; RSA, reverse shoulder arthroplasty; CVS, cerebrovascular stroke.

Arm strength was only evaluated in three studies (11%), two of which investigated abduction strength in the scapular plane using a dynamometer [10, 24] while in the third study [11] strength measurements were performed with a handheld dynamometer in forward elevation, abduction, external rotation with the arm at the side, and external rotation with the arm at 90° abduction. All three studies found significant improvements in mean arm strength postoperatively (Table 2).

All 28 studies mentioned radiographic outcomes, based on true anteroposterior, internal/external rotation, axillary, and scapular Y views. Scapular notching was evaluated in 15/28 studies (54%) [4, 6, 9–11, 13, 14, 16, 19, 26–28, 31, 36, 37] in each case using the Sirveaux classification [32]. Six studies [4, 13, 14, 18, 26, 28] compared complications between patients with cemented and uncemented prostheses (Table 2). Three studies [14, 18, 26] found more complications in the cemented group, two studies [4, 28] reported more complications in the non-cemented group, while one study found a similar rate of complications between cemented and non-cemented group [13]. Three studies [11, 16, 22] compared complication rates among patients with onlay and inlay implants, with the only design associated with more complications in each case. Two studies [11, 35] compared complication rates associated with short and long humeral stems, and both found no difference (Table 2). The most commonly reported risk factors for SS in RSA were the type of fixation (identified in 17/28 studies, 61%) [4, 11–15, 17–19, 23–26, 31, 35–37], the type and design of the humeral stem (in 14 studies, 50%) [4, 9, 11, 16, 17, 19–24, 35–37], the filling ratio (in eight studies, 29%) [12–14, 17, 23, 35–37], female sex (in three studies, 11%) [18, 20, 36] and stem alignment (in one study, 4%) [17] (Table 3).

Discussion

The present review found that the prevalence of stress shielding at a minimum of 3 years [26, 31] in RSA with uncemented humeral stems was reported at between 7.8% and 39% [10, 18, 21, 26, 30, 31]. Numerous factors affect SS after RSA, while clinical outcomes were comparable between different fixation methods and implant designs [6, 24, 27]. Radiologic outcomes after RTSA usually assess the following signs: radiolucency, condensation lines, cortical thinning, spot weld, loosening, bone resorption (near calcar or tuberosities area), and subsidence for the humeral implant and scapular notching, bone spurs, heterotopic ossifications, radiolucency and loosening for the glenoid implant [11, 26, 37]. These features are evaluated on standardized radiographs and located in seven zones based on the Gruen classification [40] and adapted to the shoulder by Melis [6] or in five zones for short humeral stems (Fig. 2). An example of several X-rays based on the author's clinical experience is illustrated in Figure 3. This review suggests that limiting the SS for bone preservation and potential revisions is desired which agrees with the current tendency in the recent literature [39]. This work also supports the use of implants with short stems and a low filling ratio (FR) have a protective role against stem subsidence.

Inoue et al. identified female sex as a risk factor for bone resorption induced by SS because of micro-architectural bone

deterioration related to osteoporosis [20]. The high prevalence of osteoporosis in elderly female patients was also identified as a risk factor for SS by Morita et al. [33] and Yokoya et al. found that female sex was significantly associated with cortical thinning and osteopenia [36]. In contrast, Brolin et al. found no correlation between sex and SS (cortical thickness) [18] possibly because their patients were relatively young.

Several studies [4, 9, 13–15, 18, 19, 21, 23, 25, 26, 36] have reported high rates of SS in patients after uncemented RSA, while stress shielding in patients with cemented stems has only been evaluated in one study [31]. Mazaleyrat et al. [4] observed signs of SS, such as osteopenia, in up to 89% of cementless stems at a mean follow-up of 9 years. Kramer et al. [13] in a comparative retrospective study of cemented vs. uncemented RSA for proximal humerus fracture, found SS in all uncemented group patients (100%), compared to other studies with press-fit fixation of a primary RSA performed with standard-length stems [19] or uncemented RSA (18.5%) for degenerative cases [21]. Thus, this review claims that stress shielding may be a phenomenon specifically associated with cementless stems.

This study seems to prove that long stems with >100 mm in length can lead to SS in terms of cortical thinning and osteolysis. Three studies also identified diaphyseal fixation with long stems (>100 mm) as a risk factor for stress shielding in RSA [11, 22, 36]. Similarly, Harmsen and Norris [24] have observed a high rate of SS of 97.4% with the use of a diaphyseal press-fit humeral stem in RSA [11, 19, 22, 24]. Also, it has been shown that shorter stems (<94 mm) may reduce the risk of SS [17]. On the contrary, one recent work compared the use of short stems (60–65 mm) and long stems (111–147 mm) provides comparable findings in terms of SS [35]. The authors reported a possible explanation for the higher metaphyseal and diaphyseal filling ratio in the short stem group.

The relationship between stress shielding and the design of the humeral component (inlay vs onlay) has only been investigated in four studies. Inlay stems seem to be protective against humeral SS compared with onlay stems, which seem to be a risk factor for bone resorption in the greater tuberosity, lateral diaphysis, and calcar region [11, 16, 20]. However, Merolla et al. [22] found that inlay stems were associated with higher rates of cortical thinning and spot welds.

Stress shielding may also vary with the neck-shaft angle (NSA) of the prosthesis, with various studies [11, 18, 36, 37] reporting SS rates ranging from 7.1% for a long straight 155° NSA inlay stem [11] to 93.5% for a humeral component with a 135° NSA [36]. However, the rates of SS associated with different NSAs have only been compared in three studies [17, 20, 27]. Yokoya et al. [36] found that the prevalence of SS was significantly higher in patients with a 135° NSA prosthesis (59.6% to 93.5%) than in those with a 155° NSA stem (26.9%). Meanwhile, Giordano et al. [11], found a SS rate of just 7.1% in patients treated with a long straight inlay implant with a 155° NSA. On the contrary though, Merolla et al. [22] found that the use of a larger NSA (155° vs 145°) was associated with higher rates of SS in terms of cortical thinning (58%) and spot welds (11%). It is well known that correct coronal alignment of the humeral stem is crucial to avoid discrepancies with the true NSA of the humerus. These offsets, particularly with short

Table 3. Detailed data on potential risk factors for stress shielding in RSA.

Study	Sample	Age (years)	Risk factor	Outcomes	FU (months)
Yokoya et al. [35]	135 shoulders	77.8	– Type of stem (length) – Type of stem (thickness) – Type of fixation – Filling ratio – Gender	– Predictors of stress shielding: long stems, cementless stems, larger proximal FR and larger metaphysis diameters – $FR_{prox} > 0.7$ is an independent predictors of stress shielding – Stress shielding: NSA 155° (26.9%), NSA 135° (59.6–93.5%) – Stress shielding was seen in 50.4% of the shoulders	34.6
Nourissat et al. [36]	19 shoulders	74.6	– Filling ratio – Type of fixation – Type of stem (length) – Type of fixation	– Low rate of stress shielding: press-fit ovoid stem of 100 mm length – No correlation between the filling ratio and resorption of the bone – Lower rate of stress shielding: humeral neck-shaft angle of 145° – No differences on stress shielding between short inlay press-fit stem and standard press-fit stem	72
Erickson et al. [37]	577 shoulders Short-stem: 220 Standard-stem: 357	Short-stem: 68.5 Standard-stem: 69.4	– Filling ratio – Type of stem (length) – Type of stem (design)	– There is an ideal FR_{met} around 60–70% to minimize stress shielding – Short (60–65 mm) stems lead to comparable rate of stress shielding compared with standard-length (111–147 mm) stems	Minimum 2 y
Giordano et al. [11]	76 shoulders Onlay: 34 Inlay: 42	Onlay: 76.2 Inlay: 76	– Type of fixation – Type of stem (length) – Type of stem (design)	– Higher rate stress shielding: onlay with 145° neck-shaft angle cohort – Lower rate of stress shielding: long-inlay straight stems – Lower rate of stress shielding: humeral neck-shaft angle of 155° (7.1%) versus 145° (17.6%)	Onlay: 46.8 Inlay: 36
Kim et al. [12]	104 shoulders HFR: 53 LFR: 51	HFR: 72.1 LFR: 73.5	– Filling ratio – Type of fixation	– Patients with low FR stems with autogenous bone grafting had significantly less humeral stress shielding than patients with high FR and press-fit stem	HFR: 13.5 LFR: 13.2
Kramer et al. [13]	51 shoulders Cemented: 34 Cementless: 17	All: 74 Cemented: 74.4 Uncemented: 74.1	– Type of fixation – Filling ratio	– Not correlation of higher FR_{dist} with severe stress shielding	27
Lopez et al. [14]	68 shoulders Cemented: 45 Cementless: 23	Cemented: 78 Uncemented: 80	– Type of fixation – Filling ratio	– Stress shielding: 30.4% of uncemented group – Not correlation of FR_{diaph} with stress shielding	Cemented: 37.8 Uncemented: 26.5
Valenti et al. [15]	24 shoulders Cemented: 5 Cementless: 19	68.7	– Type of fixation	– Signs of stress shielding appeared exclusively in non-cemented stems	44.7
Mazaleyrat et al. [4]	140 shoulders Cemented: 70 Cementless: 70	Cemented: 74.5 Cementless: 75.3	– Type of fixation – Type of stem (design)	– Proximal humeral osteolysis: inlay-type RSA with cementless stems – Proximal humeral osteolysis can in part be attributed to stress shielding – Signs of stress shielding, such as osteopenia, was only in cementless (89%)	Cemented: 9.6 y Uncemented: 8.9 y
Nagase et al. [31]	14 shoulders with rheumatoid arthritis	74	– Type of fixation	– Stress shielding: 21.4% of humeral cemented stems	57.9
Polisetty et al. [16]	92 shoulders Onlay: 46	Onlay: 74.8 Inlay: 73.2	– Type of stem (design)	– Stress shielding, onlay-style had more instances of GT (73.9%) and calcar (39.1%) resorption – Inlay-style prosthesis: better prevention of	Onlay: 29 Inlay: 31

(Continued on next page)

Table 3. (Continued)

Study	Sample	Age (years)	Risk factor	Outcomes	FU (months)
Abdic et al. [17]	Inlay: 46 124 shoulders	74	– Type of fixation – Filling ratio	humeral stress shielding – Small stems (≤ 90 mm) are implicated in a higher incidence of malpositioning with high endocortical contact – Smaller malaligned stem (≤ 90 mm): higher rate of endocortical contact distally, which associated with stress shielding – Short stems (< 94 mm) may decrease stress shielding	n/a
Brolin et al. [18]	120 shoulders	70.6	– Type of stem (length) – Alignment of stem – Type of fixation	– Uncemented stems had significantly more internal stress shielding – Neither age nor gender had a correlation with stress shielding	35.2
Denard et al. [39]	Cemented: 49 Cementless: 71 119 shoulders	Cemented: 71.1	– Gender – Type of fixation	– Proximal stress shielding was more common with press-fit fixation	Press-fit: 36.1
	Cemented: 26 Cementless: 93	Cementless: 69.3	– Type of stem (length)	– Proximal lateral stress shielding: 25% in cemented and 68% press-fit group – Standard length stems (111–147 mm) can lead to stress shielding	Cemented: 36.8
Inoue et al. [20]	48 shoulders	76.5	– Gender – Type of stem (design)	– Female gender and onlay-type stem were significant independent risk factors for grade 4 bone resorption (GT, lateral diaphysis and calcar), due to stress shielding – The mechanism of bone resorption after RSA may be related to stress shielding and polyethylene wear	18.5
Aibinder et al. [21]	100 shoulders TSA: 35 RSA: 65	68.2	– Type of stem	– GT stress shielding: 18.5% in cementless short humeral component	3.8 y
Merolla et al. [22]	74 shoulders	Inlay: 75.8	– Type of stem (length)	– The standard stem (inlay-design) showed higher stress shielding and higher rate of GT resorption	Inlay: 35.1
	Aequalis II: 36 Ascend flex: 38	Onlay: 74.7	– Type of stem (design)	– Stress shielding: NSA 155° (cortical thinning, 26.9%; spot welds, 11%), NSA 145° (cortical thinning, 26%)	Onlay: 29.1
Raiss et al. [38]	GI: 150 TSA GII: 77 RSA	GI: 68 GII: 72	– Filling ratio – Type of fixation – Type of stem (length)	– Stress shielding: higher in the uncemented group – Stress shielding: 35% of stems, with high bone adaptations in 17% – FR ≥ 0.8 increases the rate of stress shielding – Stress shielding in 97% in RSA in stems with 66–94 mm of length	GI: 32 GII: 28

(Continued on next page)

Table 3. (Continued)

Study	Sample	Age (years)	Risk factor	Outcomes	FU (months)
Harmsen and Norris [24]	232 shoulders	68.2	– Type of fixation – Type of stem (length)	– Internal stress shielding is observed to the coated diaphyseal press-fit humeral stem – Internal stress shielding of 97.4% in the early post-operative period	26.4
Weber-Spickschen et al. [25]	15 shoulders Cemented: 1 Cementless: 14	70	– Type of fixation	– Stress shielding: 13.3% in cementless humeral stem	43
Al-Hadithy et al. [9]	41 shoulders	79	– Type of stem	– Proximal humeral bone resorption: 10% in uncemented and hydroxyapatite coated humeral stem, due to stress shielding	5 y
Wiater et al. [26]	101 shoulders Cemented: 37 Cementless: 64	Cemented: 71.95 Cementless: 72.47	– Type of fixation	– Stress shielding: 7.8% in uncemented stems – Stress shielding and bone resorption: laterally at the metadiaphyseal junction	Cemented: 37 Cementless: 32.4

Abbreviations: n/a, not applicable; FU, follow-up; y, years.

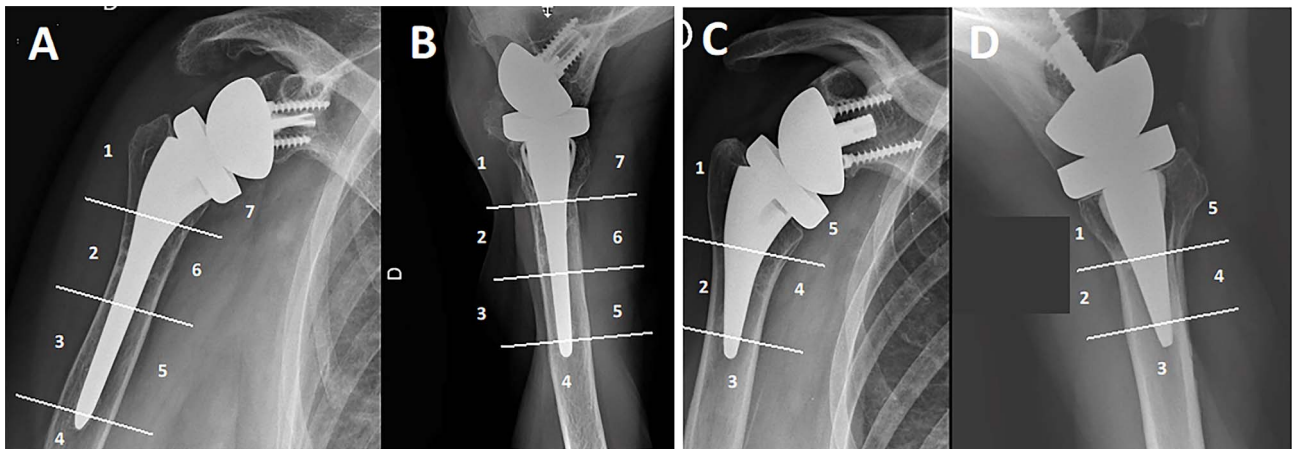


Figure 2. Humeral zones for standard-length and short humeral stems according to the Gruen classification [40] adapted to the shoulder are used to locate sites of osteolysis, radiolucent lines, and stress shielding. (A) Anteroposterior view and (B) Axillary view of standard-length stem (>100 mm). (C) Anteroposterior view and (D) Axillary view of short stem (<100 mm).

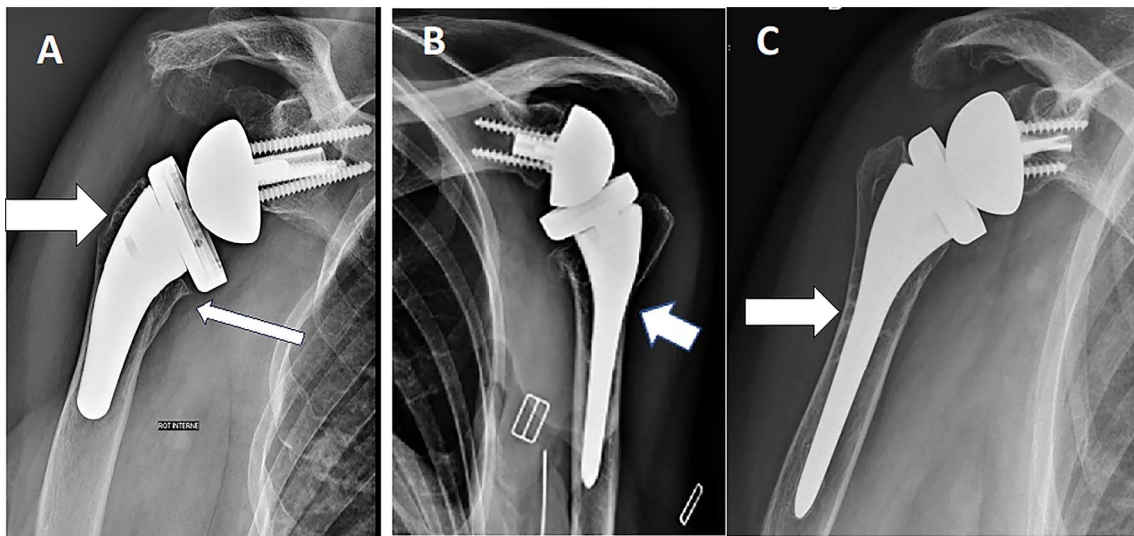


Figure 3. (A) Anteroposterior (AP) radiograph of a Right shoulder with evidence of under the baseplate osteolysis (thin arrow) and greater tuberosity osteolysis (thick arrow). (B) AP radiograph of a Left shoulder with evidence of lateral cortical thinning (arrow). (C) AP radiograph of a Left shoulder with evidence of spot welds (arrow).

stems, can lead to diaphyseal endocortical contact, a finding that is also related to SS [17]. At present, it is not clear what the ideal NSA is and surgeons must be weary of the use of curved cementless short stems because stem misalignment is associated with NSA alteration, endocortical contact, and increased SS [33].

Despite the high rates of SS associated with cementless humeral stems [4, 19], recent studies have found that this may be reduced thanks to specifically designed prostheses [17, 20, 37]. The influence of stem geometry on SS is difficult to assess because many factors may be involved, such as the NSA, inlay or onlay design, and humeral lateralization and distalization, and these characteristics are not compared directly in existing studies

In five studies, a high filling ratio was proposed as a possible risk factor for the development of stress shielding [12, 17, 23, 35, 36], while three studies did not observe a relation

between FR and SS [13, 14, 37]. Based on this literature review, there may be an ideal metaphyseal and diaphyseal FR of <math><0.7</math>, to minimize SS [23, 36, 37]. This correlates with the work by Kim et al. [12] who found that SS rates one year after RSA were much lower in patients with low filling ratios (≤ 0.64) and impaction grafting, than in those with high filling ratios (≥ 0.75). Similarly, Abdic et al. [17] found that smaller stem sizes (≤ 82 mm) were protective against SS because they ensured lower filling ratios. More recently, Yokoya et al. reported that a proximal filling ratio above 0.7 was an independent predictor of SS and proximal humeral osteolysis at a mean follow-up of 34 months [36]. However, the fact that three studies found no correlation between filling ratios and SS suggests that other factors may be implicated, although the small size of these studies may also have contributed to their negative findings [13, 14, 37].

Varus or valgus misalignment of the stem in the proximal humerus is another recognized risk factor for SS [17]. The risk of misalignment with shorter humeral prostheses has been explained by the inability to rely on diaphyseal alignment and misaligned short stems are most often implanted in valgus [17, 21]. The use of an uncemented curved short humeral implant may also increase the risk of SS because of the higher risk of distal endocortical contact [17]. Despite several studies showing favorable outcomes with short humeral stems compared with conventional long humeral stems, misalignment is more common with short stems [41]. Poor alignment may lead to excessively horizontal or vertical stems, with an increased risk of scapular notching and dislocation [34]. Some short stems have been designed with different lengths to avoid poor alignment, but further long-term comparative studies are required to determine the most suitable stem length in terms of alignment, endocortical contact, and SS [41]. Overall, however, existing results indicate that stress shielding can be limited by ensuring good frontal alignment and a low filling ratio. In a cadaveric study, Gunst et al. [42] showed that these objectives could be achieved with short stems by inserting them with standard-length compactors.

As previously documented in anatomic TSA, inflammation caused by polyethylene debris or metal degradation is also a risk factor for radiological changes around the implants in RSA. Peduzzi et al. [43] found that under-the-baseplate osteolysis could be related to the presence of polyethylene implants and polyethylene wear, as suggested previously by others [38, 44–46]. These debris have been identified as the cause of high-grade tuberosity resorption in patients with cementless stems [4]. Other works [9, 32] have found a significant association between scapular notching and tuberosity resorption. Stress shielding may therefore result from a combination of mechanical and biological factors.

Regarding clinical outcome, Mazaleyrat et al. [4] found no correlation between SS and clinical outcomes at the last follow-up. They did find although that patients with cemented stems had significantly better active ROM than those with press-fit stems. Melis et al. [6], comparing outcomes in patients with cemented versus uncemented stems, found that SS was more common in patients with uncemented stems but that clinical outcomes did not differ significantly between the two groups at up to 8 years, except internal rotation ROM, which was significantly higher in the uncemented group. Similarly, Denard et al. [19], reviewing 93 press-fit and 26 cemented stems with the same design at a minimum follow-up of 2 years, found no difference in clinical outcomes or ROM between the two groups despite SS being more common in the press-fit group. Finally, two studies investigating the utility of adjustable systems [24] or with different inclination angles of the humeral component [27] found no association between the presence of SS and clinical results. To date therefore, there are no data in the literature indicating any association between SS and clinical outcomes in RSA; however, further studies with longer follow-up are required to confirm this.

This review has several limitations. It includes RSA for all indications, including both primary and revision RSAs, which introduces additional variables that could complicate the analysis of the confounding effect of diagnosis on stress shielding.

For instance, RSA performed for revision procedures or proximal humerus fractures cannot be directly compared to primary RSAs. Additionally, we could not perform subgroup analyses and the authors could only describe the risk factors. Due to the high heterogeneity of the study parameters, a meta-analysis was not feasible. Nevertheless, this is the first study to comprehensively summarize the risk factors for the development of stress shielding after RSA.

Conclusions

Stress shielding is a common phenomenon after cementless RSA, particularly in female and elderly patients, due to osteoporosis. The risk of SS can be reduced by implanting stems in correct coronal alignment with a low diaphyseal filling ratio. Factors known to promote the release of polyethylene debris, notably scapular notching, should be avoided. While no clinical consequences of SS have yet been reported, this finding needs to be confirmed at longer follow-up.

Funding

This research did not receive any specific funding.

Conflicts of interest

Authors AVV, VG, NL, and IM declare they have no conflicts of interest. Author ES has received institutional research support from Corin. Author SL has received consultant honoraria from Stryker, Smith, and from Nephew, Heraeus, Depuy Synthes, and has received institutional research support from Lépine and Amplitude. Author SG has received consultant honoraria from Lépine and Dedienné Santé. Non-financial interests: Author SL is a member of the editorial board of the Journal of Bone and Joint Surgery (Am).

Data availability statement

Data are available on request.

Author contribution statement

AVV: Conceptualization, Methodology, Data collection, writing an original draft.

VG: Conceptualization, Methodology, Data collection, editing the manuscript.

NL: Study design, Data curation, Writing, and Reviewing.

IM: Study design, Data curation, Writing, and Reviewing.

ES: Writing, Reviewing, and Editing.

SL: Supervision, Writing, Reviewing, and Editing.

SG: Conceptualization, Study design, Supervision, Writing, Reviewing, and Editing.

Ethics approval

Ethical approval was not required.

References

1. Boileau P, Sinnerton RJ, Chuinard C, Walch G (2006) Arthroplasty of the shoulder. *J Bone Joint Surg Br* 88, 562–575.
2. Baulot E, Chabernaud D, Grammont PM (1995) Results of Grammont's inverted prosthesis in omarthritis associated with major cuff destruction. Apropos of 16 cases. *Acta Orthop Belg* 61 Suppl 1, 112–119.

3. Favard L, Levigne C, Nerot C, et al. (2011) Reverse prostheses in arthropathies with cuff tear: are survivorship and function maintained over time? *Clin Orthop* 469, 2469–2475.
4. Mazaleyrat M, Favard L, Boileau P, Berhouet J (2021) Humeral osteolysis after reverse shoulder arthroplasty using cemented or cementless stems comparative retrospective study with a mean follow-up of 9 years. *Orthop Traumatol Surg Res OTSR* 107, 102916.
5. Nagels J, Stokdijk M, Rozing PM (2003) Stress shielding and bone resorption in shoulder arthroplasty. *J Shoulder Elbow Surg* 12, 35–39.
6. Melis B, DeFranco M, Lädermann A, et al. (2011) An evaluation of the radiological changes around the Grammont reverse geometry shoulder arthroplasty after eight to 12 years. *J Bone Joint Surg Br* 93, 1240–1246.
7. Casagrande DJ, Parks DL, Torngren T, et al. (2016) Radiographic evaluation of short-stem press-fit total shoulder arthroplasty: short-term follow-up. *J Shoulder Elbow Surg* 25, 1163–1169.
8. Schmidutz F, Agarwal Y, Müller PE, et al. (2014) Stress-shielding induced bone remodeling in cementless shoulder resurfacing arthroplasty: a finite element analysis and in vivo results. *J Biomech* 47, 3509–3516.
9. Al-Hadithy N, Doms P, Sewell MD, Pandit R (2014) Reverse shoulder arthroplasty in 41 patients with cuff tear arthropathy with a mean follow-up period of 5 years. *J Shoulder Elbow Surg* 23, 1662–1668.
10. Schnetzke M, Preis A, Coda S, et al. (2017) Anatomical and reverse shoulder replacement with a convertible, uncemented short-stem shoulder prosthesis: first clinical and radiological results. *Arch Orthop Trauma Surg* 137, 679–684.
11. Giordano MC, Corona K, Morris BJ, et al. (2022) Comparative study of 145° onlay curved stem versus 155° inlay straight stem reverse shoulder arthroplasty: clinical and radiographic results with a minimum 2-year follow-up. *J Shoulder Elbow Surg* 31, 2089–2095.
12. Kim SC, Park JH, Bukhary H, Yoo JC (2022) Humeral stem with low filling ratio reduces stress shielding in primary reverse shoulder arthroplasty. *Int Orthop* 46, 1341–1349.
13. Kramer M, Olach M, Zdravkovic V, et al. (2022) Cemented vs. uncemented reverse total shoulder arthroplasty for the primary treatment of proximal humerus fractures in the elderly—a retrospective case-control study. *BMC Musculoskelet Disord* 23, 1043.
14. Lopiz Y, García-Fernandez C, Vallejo-Carrasco M, et al. (2022) Reverse shoulder arthroplasty for proximal humeral fracture in the elderly. Cemented or uncemented stem? *Int Orthop* 46, 635–644.
15. Valenti P, Zampeli F, Caruso G, et al. (2022) Proximal humeral bone defect in reverse shoulder arthroplasty combined with latissimus-dorsi transfer is not related with a poor outcome. *Orthop Traumatol Surg Res OTSR* 108, 103263.
16. Polisetty TS, Baessler AM, Levy JC, Badman BL (2021) Onlay versus inlay reverse total shoulder arthroplasty: a retrospective comparison of radiographic and clinical outcomes. *Semin Arthroplasty JSES* 31, 202–208.
17. Abdic S, Athwal GS, Wittmann T, et al. (2021) Short stem humeral components in reverse shoulder arthroplasty: stem alignment influences the neck-shaft angle. *Arch Orthop Trauma Surg* 141, 183–188.
18. Broolin TJ, Cox RM, Horneff Iii JG, et al. (2020) Humeral-sided radiographic changes following reverse total shoulder arthroplasty. *Arch Bone Jt Surg* 8, 50–57.
19. Denard PJ, Haidamous G, Gobezie R, et al. (2020) Short-term evaluation of humeral stress shielding following reverse shoulder arthroplasty using press-fit fixation compared with cemented fixation. *J Shoulder Elbow Surg* 29, 906–912.
20. Inoue K, Suenaga N, Oizumi N, et al. (2020) Humeral bone resorption after reverse shoulder arthroplasty using uncemented stem. *JSES Int* 4, 138–143.
21. Aibinder WR, Bartels DW, Sperling JW, Sanchez-Sotelo J (2019) Mid-term radiological results of a cementless short humeral component in anatomical and reverse shoulder arthroplasty. *Bone Jt J* 101-B, 610–614.
22. Merolla G, Walch G, Ascione F, et al. (2018) Grammont humeral design versus onlay curved-stem reverse shoulder arthroplasty: comparison of clinical and radiographic outcomes with minimum 2-year follow-up. *J Shoulder Elbow Surg* 27, 701–710.
23. Raiss P, Schnetzke M, Wittmann T, et al. (2019) Postoperative radiographic findings of an uncemented convertible short stem for anatomic and reverse shoulder arthroplasty. *J Shoulder Elbow Surg* 28, 715–723.
24. Harmsen SM, Norris TR (2017) Radiographic changes and clinical outcomes associated with an adjustable diaphyseal press-fit humeral stem in primary reverse shoulder arthroplasty. *J Shoulder Elbow Surg* 26, 1589–1597.
25. Weber-Spickschen TS, Alfke D, Agneskirchner JD (2015) The use of a modular system to convert an anatomical total shoulder arthroplasty to a reverse shoulder arthroplasty: clinical and radiological results. *Bone Jt J* 97-B, 1662–1667.
26. Wiater JM, Moravek JE, Budge MD, et al. (2014) Clinical and radiographic results of cementless reverse total shoulder arthroplasty: a comparative study with 2 to 5 years of follow-up. *J Shoulder Elbow Surg* 23, 1208–1214.
27. Holschen M, Kiriazis A, Bockmann B, et al. (2022) Treating cuff tear arthropathy by reverse total shoulder arthroplasty: do the inclination of the humeral component and the lateral offset of the glenosphere influence the clinical and the radiological outcome? *Eur J Orthop Surg Traumatol Orthop Traumatol* 32, 307–315.
28. Mazaleyrat M, Favard L, Garaud P, et al. (2021) Press-fit vs. cemented humeral stem fixation for reverse shoulder arthroplasty: functional outcomes at a mean follow-up of 9.5 years. *J Shoulder Elbow Surg* 30, 72–79.
29. Erickson BJ, Denard PJ, Griffin JW, et al. (2022) Initial and 1-year radiographic comparison of reverse total shoulder arthroplasty with a short versus standard length stem. *J Am Acad Orthop Surg* 30, e968–e978.
30. Giuseffi SA, Streubel P, Sperling J, Sanchez-Sotelo J (2014) Short-stem uncemented primary reverse shoulder arthroplasty: clinical and radiological outcomes. *Bone Jt J* 96-B, 526–529.
31. Nagase Y, Naito M, Momoyama G, et al. (2021) Midterm clinical outcomes of reverse shoulder arthroplasty in Japanese patients with rheumatoid arthritis using patient-reported outcome measures (Shoulder36). *JSES Int* 5, 114–120.
32. Sirveaux F, Favard L, Oudet D, et al. (2004) Grammont inverted total shoulder arthroplasty in the treatment of glenohumeral osteoarthritis with massive rupture of the cuff. Results of a multicentre study of 80 shoulders. *J Bone Joint Surg Br* 86, 388–395.
33. Morita A, Kobayashi N, Choe H, et al. (2021) Preoperative factors predicting the severity of BMD loss around the implant after total hip arthroplasty. *BMC Musculoskelet Disord* 22, 290.
34. Sanchez-Sotelo J (2021) Current concepts in humeral component design for anatomic and reverse shoulder arthroplasty. *J Clin Med* 10, 5151.

35. Yokoya S, Harada Y, Sumimoto Y, et al. (2023) Factors affecting stress shielding and osteolysis after reverse shoulder arthroplasty: a multicenter study in a Japanese population. *J Orthop Sci Off J Jpn Orthop Assoc* 29(2), 521–528. S0949–2658(23)00009-X.
36. Nourissat G, Corsia S, Harris HW, Bouché P-A (2022) Specific design of a press fit humeral stem provides low stress shielding in reverse shoulder arthroplasty at minimum 5 years FU. *J Shoulder Elb Arthroplasty* 6, 24715492221112543.
37. Erickson BJ, Denard PJ, Griffin JW, et al. (2022) A 135° short inlay humeral stem leads to comparable radiographic and clinical outcomes compared with a standard-length stem for reverse shoulder arthroplasty. *JSES Int* 6, 802–808.
38. Raiss P, Edwards TB, Deutsch A, et al. (2014) Radiographic changes around humeral components in shoulder arthroplasty. *J Bone Joint Surg Am* 96, e54.
39. Denard PJ, Raiss P, Gobezie R, et al. (2018) Stress shielding of the humerus in press-fit anatomic shoulder arthroplasty: review and recommendations for evaluation. *J Shoulder Elbow Surg* 27, 1139–1147.
40. Gruen TA, McNeice GM, Amstutz HC (1979) “Modes of failure” of cemented stem-type femoral components: a radiographic analysis of loosening. *Clin Orthop* 141, 17–27.
41. Oh JH, Jeong HJ, Won Y-S (2023) Implant selection for successful reverse total shoulder arthroplasty. *Clin Shoulder Elb* 26, 93–106.
42. Gunst S, Nigues A, Vogels J, et al. (2022) Using standard-length compactors to implant short humeral stems in total shoulder arthroplasty: a cadaver study of humeral stem alignment. *PLoS One* 17, e0268075.
43. Peduzzi L, Goetzmann T, Wein F, et al. (2019) Proximal humeral bony adaptations with a short uncemented stem for shoulder arthroplasty: a quantitative analysis. *JSES Open Access* 3, 278–286.
44. Jullion S, Jacquot A, Mole D (2016) Long-term results of reverse shoulder arthroplasty. Problems and complications related to the glenoid. In: *Shoulder concepts. Reverse shoulder arthroplasty*. Sauramps Medical, Montpellier.
45. Rachuene PA, Dey R, Kauta NJ, Sivarasu S, du Plessis J-P, Roche S, Vrettos B (2024) Pre-operative planning for reverse shoulder arthroplasty in low-resource centres: a modified Delphi study in South Africa. *SICOT-J* 10, 23.
46. Carli AV, Patel AR, Cross MB, Mayman DJ, Carroll KM, Pellicci PM, Jerabek SA (2020) Long-term performance of oxidized zirconium on conventional and highly cross-linked polyethylene in total hip arthroplasty. *SICOT-J* 6, 10.

Cite this article as: Vasiliadis AV, Giovanoulis V, Lepidas N, Bampis I, Servien E, Lustig S & Gunst S (2024) Stress shielding in stemmed reverse shoulder arthroplasty: an updated review. *SICOT-J* 10, 37