



**HAL**  
open science

# Extrusion and meniscal mobility evaluation in case of ramp lesion injury: a biomechanical feasibility study by 7T magnetic resonance imaging and digital volume correlation

Mathieu Severyns, François Zot, Ghina Harika-Germaneau, Arnaud Germaneau, Guillaume Herpe, M. Naudin, Valery Valle, J. Danion, T. Vendevre

## ► To cite this version:

Mathieu Severyns, François Zot, Ghina Harika-Germaneau, Arnaud Germaneau, Guillaume Herpe, et al.. Extrusion and meniscal mobility evaluation in case of ramp lesion injury: a biomechanical feasibility study by 7T magnetic resonance imaging and digital volume correlation. *Frontiers in Bio-engineering and Biotechnology*, 2024, 11, pp.1289290. 10.3389/fbioe.2023.1289290 . hal-04699157

**HAL Id: hal-04699157**

**<https://hal.science/hal-04699157v1>**

Submitted on 16 Sep 2024

**HAL** is a multi-disciplinary open access archive for the deposit and dissemination of scientific research documents, whether they are published or not. The documents may come from teaching and research institutions in France or abroad, or from public or private research centers.

L'archive ouverte pluridisciplinaire **HAL**, est destinée au dépôt et à la diffusion de documents scientifiques de niveau recherche, publiés ou non, émanant des établissements d'enseignement et de recherche français ou étrangers, des laboratoires publics ou privés.



Distributed under a Creative Commons Attribution 4.0 International License



## OPEN ACCESS

## EDITED BY

Petri Tanska,  
University of Eastern Finland, Finland

## REVIEWED BY

Ville-Pauli Karjalainen,  
University of Oulu, Finland  
Lasse Räsänen,  
Suomen Terveystalo, Finland

## \*CORRESPONDENCE

A. Germaneau,  
✉ arnaud.germaneau@univ-poitiers.fr

RECEIVED 05 September 2023

ACCEPTED 11 December 2023

PUBLISHED 05 January 2024

## CITATION

Severyns M, Zot F, Harika-Germaneau G, Germaneau A, Herpe G, Naudin M, Valle V, Danion J and Vendevre T (2024), Extrusion and meniscal mobility evaluation in case of ramp lesion injury: a biomechanical feasibility study by 7T magnetic resonance imaging and digital volume correlation. *Front. Bioeng. Biotechnol.* 11:1289290. doi: 10.3389/fbioe.2023.1289290

## COPYRIGHT

© 2024 Severyns, Zot, Harika-Germaneau, Germaneau, Herpe, Naudin, Valle, Danion and Vendevre. This is an open-access article distributed under the terms of the [Creative Commons Attribution License \(CC BY\)](https://creativecommons.org/licenses/by/4.0/). The use, distribution or reproduction in other forums is permitted, provided the original author(s) and the copyright owner(s) are credited and that the original publication in this journal is cited, in accordance with accepted academic practice. No use, distribution or reproduction is permitted which does not comply with these terms.

# Extrusion and meniscal mobility evaluation in case of ramp lesion injury: a biomechanical feasibility study by 7T magnetic resonance imaging and digital volume correlation

M. Severyns<sup>1,2</sup>, F. Zot<sup>1</sup>, G. Harika-Germaneau<sup>3</sup>, A. Germaneau<sup>1\*</sup>, G. Herpe<sup>4</sup>, M. Naudin<sup>4</sup>, V. Valle<sup>1</sup>, J. Danion<sup>5</sup> and T. Vendevre<sup>1,6</sup>

<sup>1</sup>Institut Pprime UPR 3346, Centre National de Recherche Scientifique–Université de Poitiers–ISAE-ENSMA, Poitiers, France, <sup>2</sup>Department of Orthopaedic Surgery and Traumatology, Clinique Porte Océane, Les Sables d'Olonne, France, <sup>3</sup>Unité de Recherche Clinique Pierre Deniker, CH Henri Laborit, Centre de Recherches sur la Cognition et l'Apprentissage UMR 7295, Centre National de Recherche Scientifique–Université de Poitiers, Poitiers, France, <sup>4</sup>CHU de Poitiers, Department of Radiology, LabCom I3M Centre National de Recherche Scientifique–Siemens Healthineers, LMA, UMRCNRS 7348, Université de Poitiers, Poitiers, France, <sup>5</sup>CHU de Poitiers, ABS Lab, Poitiers, France, <sup>6</sup>CHU de Poitiers, Department of Orthopaedic Surgery and Traumatology, Poitiers, France

**Introduction:** The existing body of literature on the biomechanical implications of ramp lesions is limited, leaving a significant gap in our understanding of how these lesions impact joint kinematics and loading in the medial compartment. This cadaveric biomechanical study aims to address this gap by employing an innovative Digital Volume Correlation (DVC) method, utilizing 7 Tesla Magnetic Resonance Imaging (MRI) images under various loading conditions. The primary objective is to conduct a comprehensive comparison of medial meniscal mobility between native knees and knees affected by grade 4 ramp lesions. By focusing on the intricate dynamics of meniscal mobility and extrusion, this work seeks to contribute valuable insights into the biomechanical consequences of medial meniscus ramp lesions.

**Materials and methods:** An initial set of 7T MRI imaging sessions was conducted on two intact native knees, applying load values up to 1500N. Subsequently, a second series of images was captured on these identical knees, with the same loads applied, following the creation through arthroscopy of medial meniscus ramp lesions. The application of DVC enabled the precise determination of the three components of displacement and spatial variations in the medial menisci, both with and without ramp lesions.

**Results:** The measured directional displacements between native knees and injured knees indicate that, following the application of axial compression load, menisci exhibit increased extrusion and posterior mobility as observed through DVC.

**Discussion:** Injuries associated with Subtype 4 medial meniscus ramp lesions appear to elevate meniscal extrusion and posterior mobility during axial compression in the anterior cruciate ligament of intact knees. Following these preliminary results, we plan to expand our experimental approach to encompass

individuals undergoing weight-bearing MRI. This expansion aims to identify meniscocapsular and/or meniscotibial insufficiency or rupture in patients, enabling us to proactively reduce the risk of osteoarthritic progression.

#### KEYWORDS

medial meniscus, ramp lesion, digital volume correlation (DVC), magnetic resonance imaging (MRI), displacement fields

## 1 Introduction

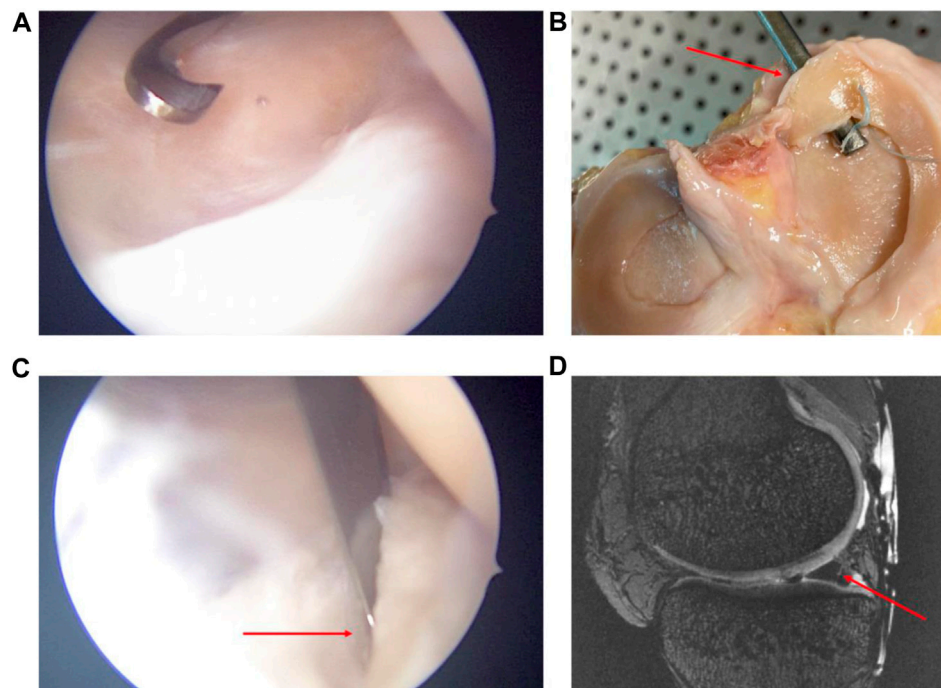
In the context of anterior cruciate ligament (ACL) reconstruction, medial meniscus ramp lesions (RL) and lateral meniscus posterior ramp lesions are prevalent, accounting for over one-third of cases in both primary and revision surgeries (Magosch et al., 2021). Specifically, medial meniscus RLs (Figure 1) are frequently observed traumatic injuries, with a prevalence rate of 21.9% (ranging from 9.0% to 41.7%) at the time of ACL reconstruction (Kunze et al., 2021a; Brophy et al., 2022). They are defined as a distinct category of injuries occurring within the posterior horn of the medial meniscus and its meniscocapsular attachments (Thaunat et al., 2021).

Among the various types of RL, meniscocapsular junction tears, classified as type 1, are the most common, followed by type 4 lesions, which involve a complete tear in the red zone of the meniscus (Thaunat et al., 2021). This underscores the need to understand and address these specific types of meniscal injuries in the context of ACL reconstruction, as they play a crucial role in the overall stability and functionality of the knee joint. Addressing these lesions effectively is essential for optimizing patient outcomes and

preventing the long-term complications associated with ACL reconstruction.

At present, understanding of the biomechanical behavior of meniscus is at the forefront of orthopedic discussions (Kunze et al., 2021b; Ollivier et al., 2022). Meniscocapsular and meniscotibial lesions of the posterior horn of the medial meniscus increase anterior tibial translation, internal and external rotation, and pivot shift in ACL-deficient knees (Ahn et al., 2011; Engebretsen et al., 2012; Peltier et al., 2015; Stephen et al., 2016; DePhillipo et al., 2018; Mouton et al., 2020). However, the available literature discussing the biomechanical consequences of RL remains limited. It is not clear whether these lesions affect joint kinematics and loading in the medial compartment (Chahla et al., 2016; Seil, 2018). Recently, Krych et al. (2017) and Mariani et al. (2022) showed that meniscal extrusion was due not only to root lesions but also to meniscotibial ligament (MTL) injuries. Although meniscal extrusion is often the consequence of hyper-pressure in the medial femerotibial compartment, it could also be the cause in different cases, one of them being RL.

Magnetic Resonance Imaging (MRI) plays a pivotal role in investigating meniscal injuries, particularly RL. Its ability to



**FIGURE 1**

Arthroscopic views (A,B) of subtype 4 medial meniscus RL creation by a posteromedial approach. Open view of the knee and its meniscal RL injury after experimentation (C). MRI sagittal view in sequence T2 DESS of the subtype 4 RL injury (D). Red arrows show the subtype 4 RL.

provide detailed, non-invasive, and precise imaging significantly contributes to early detection, appropriate treatment planning, and successful outcomes for patients dealing with this specific meniscal injury. From a biomechanical point of view, Digital Volume Correlation (DVC) is currently used to determine the three components of displacement and spatial variations of a material or structure from volume images (Bay et al., 1999; Buljac et al., 2018; Disney et al., 2018).

The combination of MRI and DVC ensures powerful synergy in medical imaging and biomechanical analysis. While MRI provides detailed and high-resolution images of internal structures, capturing intricate anatomical information, DVC is a sophisticated image analysis technique used to quantify deformation and strain in complex structures. The integration of MRI with DVC enhances biomechanical studies by correlating structural information with mechanical behavior. This correlation is invaluable in fields such as orthopedics, where understanding the mechanical properties of tissues is crucial for the development of effective treatment strategies and injury prevention programs.

This biomechanical work concerned a case study, of which the objective was to compare medial meniscal mobility between native knees and knees with grade 4 RL by a DVC method using 7 Tesla MRI at different loadings. The hypothesis of this study is that medial meniscus RL increases meniscal mobility and extrusion.

## 2 Materials and methods

### 2.1 Specimen preparation and loading device

This experimental study was conducted on two cadaveric knees that had a Normo-axial morphotype with a meniscal (and cartilaginous state deemed intact during the 7 Tesla MRI (7T MRI) examination. Specimen preparations were carried out at the Anatomy Laboratory of the University of Poitiers (DC-2019-3704 Université de Poitiers). The epidemiological data showed a 63-year-old man (73 kg, named Knee 1) and an 81-year-old woman (79 kg, named Knee 2) with no osteoarticular history and whose CT scan measurements of HKA angle were 178.9° (leg length: 123.4 cm) and 177.8° (leg length: 127.7 cm) respectively. The knees were then disarticulated below the hip and above the ankle and dissected, preserving the entire capsule and peripheral ligaments without opening the knee joint. Proximal and distal fixations of rigid polyurethane resin were made in order to facilitate fixation of the anatomical parts on an MRI-compatible loading bench without ferromagnetic components and designed specifically for this series of experiments (Figure 2). The knee was positioned in the loading device in the sagittal direction, aligning the loading axis with the orientation of the MRI tube. The loading bench could impose compression loading up to 1500N. Imposed load ability was preliminarily calibrated and controlled during experiments by a specific homemade hydraulic sensor. Biomechanical experiments were conducted in accordance with established guidelines for *in vitro* studies (Wilke et al., 1998). Cadaveric knees from fresh and non-formalin-fixed specimens were cryopreserved after the primary dissection phase. Before each experiment, the thawing protocol consisted of placing the cadaveric segments at room

temperature for 48 h in order to optimize the elasticity/stiffness relationship and to get closer to the physiological conditions found in living patients.

### 2.2 Experimental protocol


Images were acquired using a 7-Tesla scanner (Magnetom Terra, Siemens Healthineers, Erlangen, Germany) with a dedicated Transmit/Receive 28-channel knee coil (QED, Mayfield Village, OH, United States). Anatomical images were acquired using 3D T2 DESS 0.35 mm isotropic (TR 8ms, TE 2.48 ms, slice 0.35 mm, 464 × 464 matrix size, FA 24°, FOVr 164mm, FOVp 72.4%, 1 Nex, PAT 2). An initial series of 7T MRI imaging sessions were conducted on native knees under axial loads of 750N and 1500N, equivalent to one to two times the body weight load. Subsequently, a second set of images was captured on the same knees, employing the same loads, following the creation of grade 4 medial meniscus RL (Thaunat et al., 2021) using a posteromedial instrumental approach under arthroscopy (Figure 1).

### 2.3 Digital volume correlation and assessment criteria

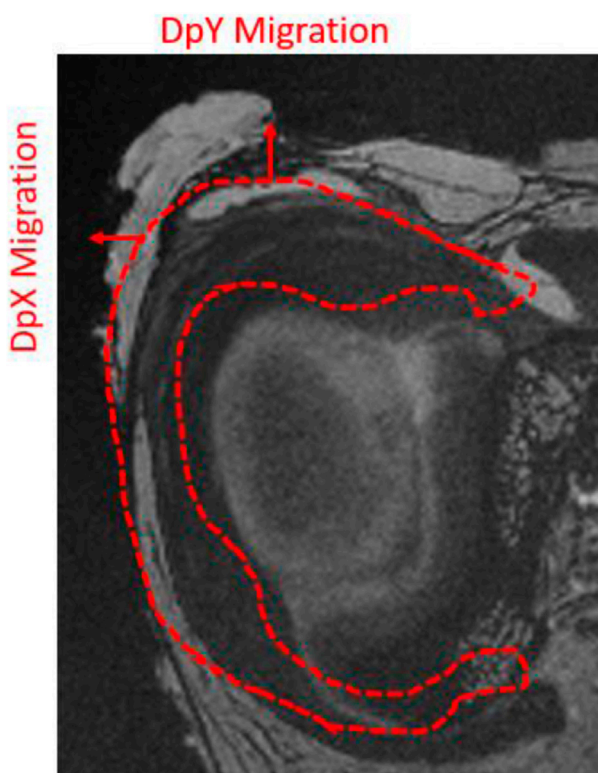
To measure displacement fields through DVC, a sub-volume of voxels ( $D$ ) is defined at each voxel in the initial image. The position of each sub-volume is subsequently determined by assessing the degree of similarity within the initial image. To achieve this objective, a correlation sub-volume is characterized by the voxel values denoted as  $f(\vec{X})$  at the reference state, with  $\vec{X}$  representing the initial position vector. The position of the desired sub-volume in the deformed state is designated as  $\vec{x}$ , and the corresponding grey levels are denoted as  $g(\vec{x})$ . The degree of similarity between a sub-volume in the initial and deformed states is assessed through a correlation coefficient (Germaine et al., 2007) established by optimizing a functional  $f(\vec{X}) - g(\vec{\phi}(\vec{X}))$ , where  $\vec{\phi}$  signifies the material transformation between the deformation states. Tricubic interpolation of grey levels was employed to attain displacement field measurements with subvoxel resolution. This non-contact method facilitates the measurement of volume displacements within the structure, ranging from 1  $\mu\text{m}$  to several tens of millimeters (Germaine et al., 2008; Valle et al., 2019).

The overlay of constrained and unconstrained MRI images was carried out through semi-automated tibial registration of the image sequences using 3DSlicer software (Version 4.11, Kitware, France). Manual segmentation of the medial meniscus was performed by an experienced surgeon with expertise in medical image analysis, utilizing the first MRI scan to extract the relevant meniscal area. This singular segmentation aimed to delineate the specific region of interest to be analyzed through the DVC process. Given the stationary nature of the knee bones, meticulous image registrations were conducted between steps, referencing the bone structures. This approach ensured precise alignment, facilitating accurate measurements in the DVC computation area associated with the meniscus.

The displacement fields were analyzed in three dimensions. Observation of displacements along the  $X$  and  $Y$  directions



**FIGURE 2**  
Anatomical view of a knee segment with its proximal and distal fixations of rigid polyurethane resin (A). MRI-compatible loading bench, (B) pressure sensor, (C) *in situ* loading setup in the 7T MRI device (D).



**FIGURE 3**  
Illustration of the orientation of the displacement fields analyzed in DVC on a coronal MRI slice of a right cadaveric knee.

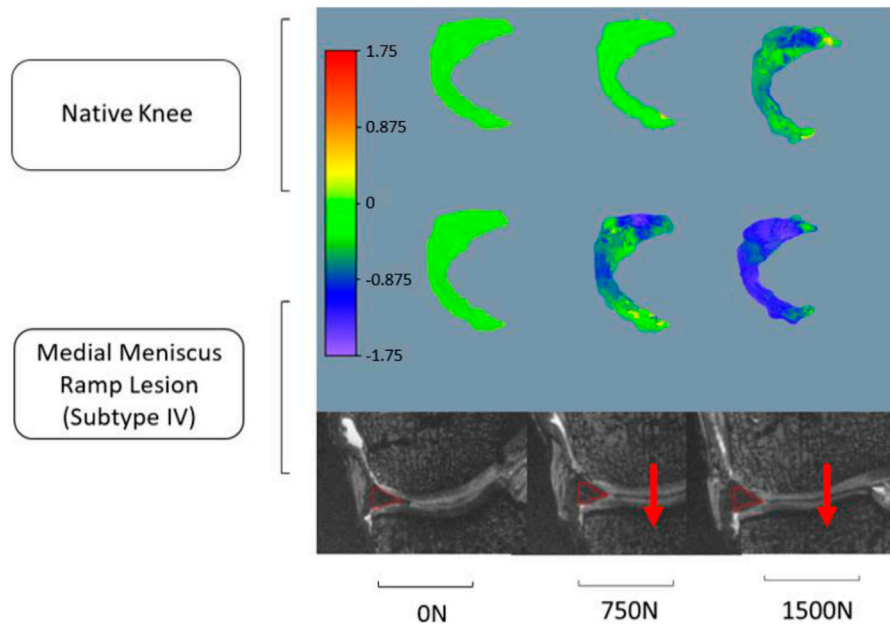
facilitated analysis of anteroposterior and lateromedial migration of the meniscus after axial compression, with the knee positioned in full extension (Figure 3). The measurement uncertainty provided by the DVC process for these MRI data was assessed at 0.05 voxel.

### 3 Results

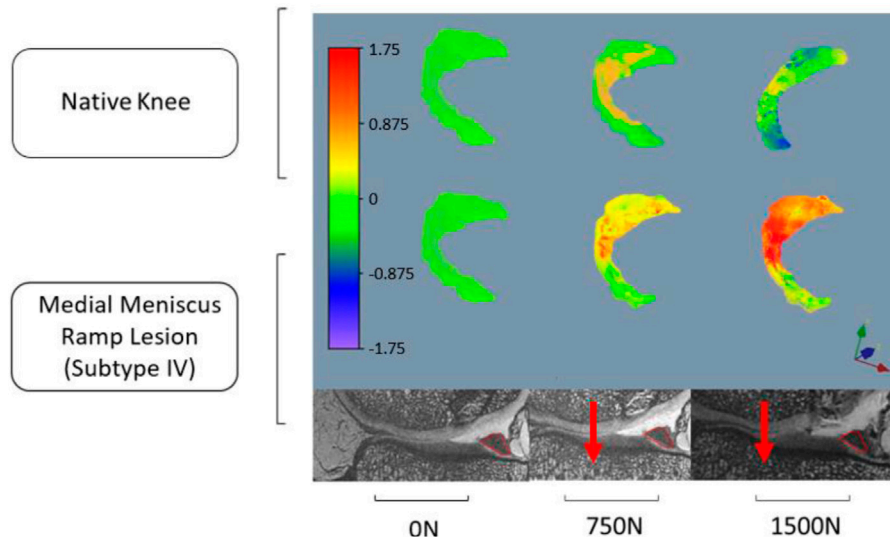
The red contour in Figure 3 illustrates meniscus migration during loading. The directional displacements of the medial meniscus were measured by DVC. Figures 4–7 show the directional displacement fields obtained by DVC after the application of 0N, 750N, and 1500N of axial load.

Mean displacements were measured on the posterior segment of the medial meniscus, anteriorly to the RL. In the lateromedial direction (X), the mean displacements measured at 1500N load were  $-0.983 \text{ mm} (\pm 0.027 \text{ mm})$  on the knee 1 *versus*  $-1.568 \text{ mm} (\pm 1.097 \text{ mm})$  on the same knee with RL injury. For knee 2, the mean displacements measured according to X with the same load were  $0.738 \text{ mm} (\pm 0.133 \text{ mm})$  before and  $1.647 \text{ mm} (\pm 0.031 \text{ mm})$  after RL injury. Positive or negative values are associated with the knee's laterality. With a grade 4 medial meniscal RL, the meniscus increases its extrusion in the frontal plane (Figures 4, 6).

In the anteroposterior direction (Y), the mean displacements measured at 1500N load were  $0.167 \text{ mm} (\pm 0.183 \text{ mm})$  on knee 1 *versus*  $1.150 \text{ mm} (\pm 0.287 \text{ mm})$  on the same knee with RL injury. For knee 2, the mean displacements measured in Y with the same load were  $0.739 \text{ mm} (\pm 0.132 \text{ mm})$  before and  $2.559 \text{ mm} (\pm 0.459 \text{ mm})$  after RL injury. With grade 4 RL, the posterior segment of the medial meniscus increases its posterior extrusion in the sagittal plane (Figures 5, 7).



**FIGURE 4**  
Observation of the displacement fields (in mm) after DVC assessment for knee 1 according to the lateromedial direction (X).



**FIGURE 5**  
Observation of the displacement fields (in mm) after DVC assessment for knee 1 according to the anteroposterior direction (Y).

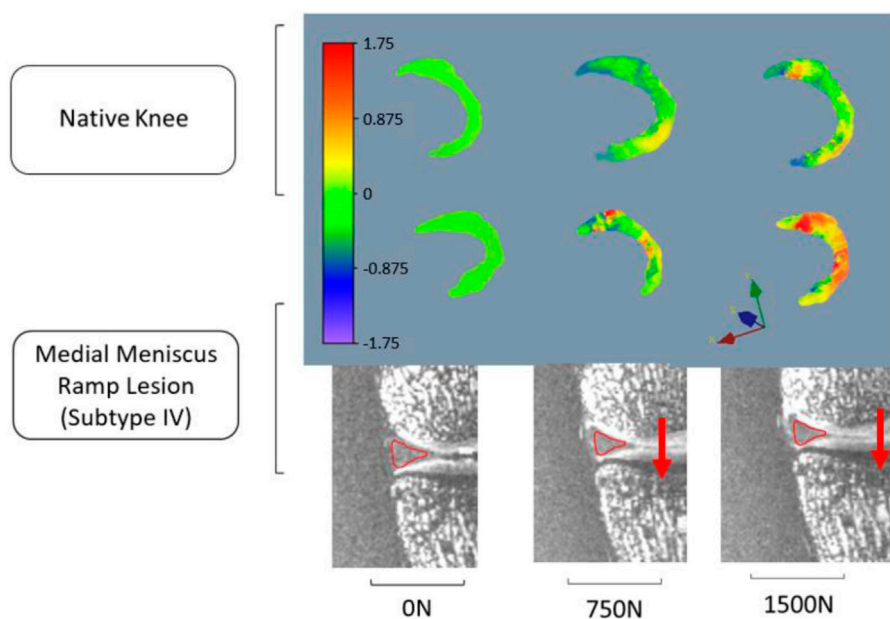
All data on the anteroposterior and/or lateromedial migration of the meniscus after axial compression between native knees and injured knees are summarized in [Table 1](#).

## 4 Discussion

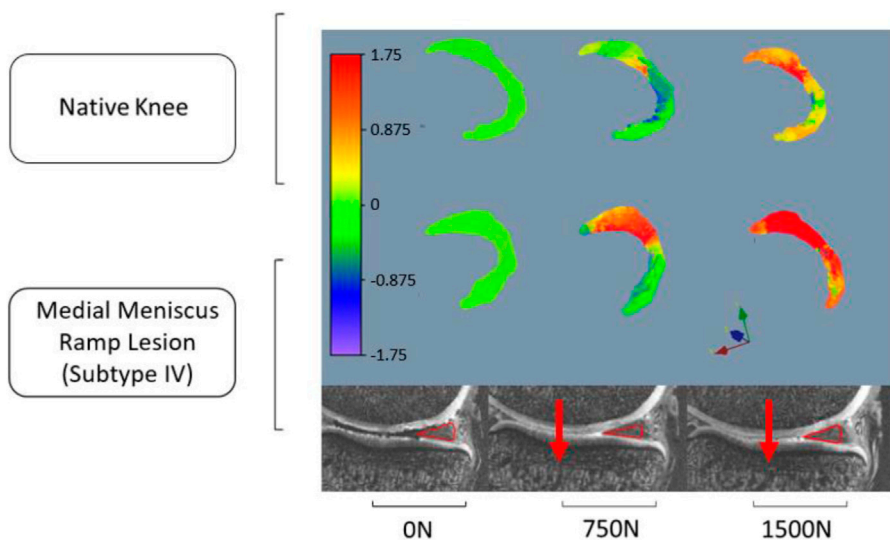
The main finding of this study is that medial meniscus RL injury increases meniscal extrusion, which is defined as the internal

displacement of the medial meniscus with regard to the medial margin of the tibial plateau, and meniscal posterior mobility during axial compression. This biomechanical study confirms the hypothesis that RL could be responsible for meniscal extrusion usually considered as the result of meniscal root lesion or disruption of the coronary ligaments or isolated MTL injury (Chahla et al., 2016; Krych et al., 2017; Naendrup et al., 2019; Thaunat et al., 2021; Mariani et al., 2022).

Meniscal extrusion is recognized as a significant predictor of accelerated joint degeneration (Hein et al., 2011; Krych et al., 2017).



**FIGURE 6**  
Observation of the displacement fields (in mm) after DVC assessment for knee 2 according to the lateromedial direction (X).



**FIGURE 7**  
Observation of the displacement fields (in mm) after DVC assessment for knee 2 according to the anteroposterior direction (Y).

Diagnosing meniscal extrusion is crucial, due not only to the acute functional limitations it imposes on patients but also because of its direct association with osteoarthritis (OA), a condition often observed in the elderly (Sugita et al., 2001; Guermazi et al., 2015). Meniscal extrusion has been shown to diminish the hoop function of the meniscus, increasing the risk of knee OA (Ozeki et al., 2022). In our case, RLs are prevalent meniscal injuries, typically occurring in cases of ACL rupture or knee laxity associated with anterior cruciate ligament insufficiency. These injuries are particularly common in patients under 30 years of

age and male patients (Liu et al., 2011). Current literature consensus indicates that meniscal extrusion, whether with or without ACL deficiency, amplifies mechanical loading. Consequently, abnormal mechanical stress can trigger a pathological response in joint tissues, leading to cartilage degradation characteristic of knee OA, particularly in the medial compartment (Daszkiewicz and Łuczkiwicz, 2021). Similarly, a significant correlation has been established between the degree of medial meniscus extrusion and the onset of post-arthroscopic osteonecrosis of the knee (Yamaguchi et al., 2021).

TABLE 1 Displacement measurement obtained by DVC after application of 0N, 750N, and 1500N axial loads between native knees and injured knees (in mm).

Displacement measurement (mm)	KNEE 1					
	Native Knee			Medial Meniscus RL		
	0N	750N	1500N	0N	750N	1500N
Lateromedial direction (DpX)						
Mean	-0.046	-0.281	-0.983	0.016	-0.683	-1.568
Min-Max	-0.077–0.006	-0.407–0.121	-1.599–0.008	-0.031–0.045	-2.041–0.301	-3.154–0.412
SD	0.015	0.100	0.272	0.019	0.346	1.097
Anteroposterior direction (DpY)						
Mean	-0.075	0.141	0.167	-0.029	0.318	1.150
Min-Max	-0.094–0.005	0.047–0.221	-1.014–0.691	-0.056–0.018	0.104–0.735	1.091–1.732
SD	0.007	0.041	0.183	-0.029	0.105	0.287
	KNEE 2					
	Native Knee			Medial Meniscus RL		
	0N	750N	1500N	0N	750N	1500N
Lateromedial direction (DpX)						
Mean	0.018	0.604	0.738	0.014	0.978	1.647
Min-Max	-0.026–0.041	0.365–0.967	0.487–0.774	-0.032–0.045	0.13615–2.406	1.101–2.627
SD	0.014	0.137	0.133	0.020	0.505	0.309
Anteroposterior direction (DpY)						
Mean	-0.029	0.010	0.739	-0.028	1.746	2.559
Min-Max	-0.054–0.013	-0.483–0.249	0.480–0.981	-0.052–0.012	0.821–2.582	1.472–3.166
SD	0.010	0.073	0.132	0.013	0.364	0.459

Naendrup et al. (2019) found non-significant results on knee medial stress due to RL injuries. No differences were found with respect to kinematics, *in situ* forces in the ACL, or bony contact forces between intact knees and knees with a ramp lesion. However, this study was performed on ACL-intact knees with a maximum axial compression load of 200N on a freedom robotic testing system. While the same authors think that the indications for RL repair may be limited, there are a number of reasons that seem to justify meniscal repair in addition to the risk of OA degeneration due to RL. Medial menisci with RL are less stable and could progress toward a bucket-handle tear, especially in subtype 4 or 5 lesions (Thaunat et al., 2021). In addition, DePhilippo et al. (2018) have observed that meniscotibial and meniscocapsular lesions of the posterior segment of the medial meniscus increase knee anterior tibial translation, internal and external rotation, and pivot shift in ACL-deficient knees. Optimal treatment has been debated in the literature, especially for stable RL, although good outcomes have been shown both with and without repair (Brophy et al., 2022). Healing rates of RL were significantly better when lesions were repaired and surgical procedures appeared reliable (Hatayama et al., 2020). Recently, Park et al. (2022) analyzed the joint capsule adjacent to the medial meniscus and found that the perimeniscal joint capsule

had collagen fiber orientation similar to that of circumferential meniscal fibers, potentially playing a role in preventing extrusion. They also found that the circumferential rim augmentation suture reduced the degree of meniscal extrusion while restoring meniscal function, potentially preventing the progression of arthritis in a rabbit root tear model and by means of porcine knee biomechanical analysis (Park et al., 2022).

The typical method for quantifying extrusion involves measuring the distance between the medial edge of the tibial plateau and the most prominent medial point of the medial meniscus (Choi et al., 2010). Existing literature suggests that meniscal extrusion exceeding 3–4 mm can have biomechanical implications on the tibiofemoral compartment contact area and pressures (Debieux et al., 2021). It is important to note that our findings, although lower than these thresholds, pertain to knees without osteoarthritis (OA) and ACL insufficiency.

Furthermore, even in healthy knees, some studies have demonstrated meniscal mobility. In an ultrasound-based study, Kawaguchi et al. (2012) showed that physiologic loading causes mild meniscal extrusion. Another ultrasound study demonstrated that the posterior portion experiences greater extrusion than the anterior portion, particularly as regards the medial meniscus



(Sharafat Vaziri et al., 2022). Additionally, research has explored meniscal displacements and 3D morphological changes under knee weight-bearing and early flexion conditions in healthy adults, utilizing MRI (Liu et al., 2021). Of note, data through MRI regarding injured knees with volume quantification are lacking. Our study stands out as the first to evaluate meniscal displacement using DVC under various axial compression loads. The direct correlation DVC technique is reliable and reproducible, provided that study sub-volumes are optimized (Palanca et al., 2015; Marter et al., 2020).

The study has some limitations. First, it was a cadaver study. Although we tried to optimize the elasticity/stiffness ratio with respect to ethical use and institutional thawing procedure, the performance of this study on fresh cadaver knees would have allowed us to come even closer to reproducing the physiological conditions of meniscal displacement in living patients.

Secondly, the study was conducted using only two anatomical specimens. The results underscored the specific observations associated with each specimen. Mediolateral extrusion was comparable between the two knees, while variability was noted in the anteroposterior direction. In the instance of one knee (knee 2), native anteroposterior mobility surpassed that of the other. The results indicated that mobility after RL could be proportionate to mobility in the intact condition. This work served as a case study and proof of concept, demonstrating the integration of 7T MRI and DVC to characterize the mechanical behavior of the meniscus in knee articulation under loading. While intriguing initial conclusions were drawn, it is essential to validate these results through additional experiments involving a larger number of specimens.

This study was conducted with the knee in extension because of the 7T MRI device. However, extrusion of the meniscus's medial body seemed to be greater in full extension compared to any other flexing angles. Mechanical loading can significantly deform the menisci in knee extension; however, this effect is limited during knee flexion (Liu et al., 2021). In contrast, anteroposterior mobility commonly increases with the rise of knee flexion motion (Sharafat Vaziri et al., 2022). For this reason, the data concerning lateromedial displacement (X) appear to be more informative.

It is possible that variability between our results and the findings of future studies could be due to the characteristics of the created lesions. The definition of RL is constantly debated, especially in terms of length. RL has been commonly defined as a 25 mm tear (Chahla et al., 2016; Balazs et al., 2019). However, during our experimentation, the RL length we were able to achieve was 20 and 21 mm in accordance with DePhillipo et al. (2018), who clearly established that the length of the posteromedial meniscocapsular junction may not exceed 20 mm because otherwise it would be extended to the midportion of the meniscus.

Utilization of a 7T MRI device brought forth numerous advantages and advancements. 7T MRI offers spatial resolution superior to 3T MRI, enabling the capture of highly detailed images of the knee joint and meniscus. This heightened clarity proves invaluable when evaluating intricate structures such as meniscal root attachments and subtle pathological changes within the meniscus. It bears mentioning that the biomechanical research presented in this study could be designed for routine use on the 1.5T or 3T scanners commonly employed in clinical practice. Subsequent studies need to be conducted to assess the capacity of

1.5T or 3T scanners to perform DVC measurements of mechanical fields within the meniscus with adequate resolution.

## 5 Conclusion

In this work, original experiments were developed to perform *in situ* mechanical loadings of anatomical knee specimens in a 7T MRI device and to measure volume displacements in intact meniscus or after lesion. Subtype 4 medial meniscus RL injury increases meniscal extrusion and meniscal posterior mobility during axial compression in ACL-intact knees. Indeed, the meniscotibial ligament and meniscocapsular junction seem to behave like the belt and suspenders of the medial meniscus. Although these data improve biomechanical knowledge of RL, their clinical impact in ACL-intact knees must be evaluated in the long term before proposing systematic arthroscopic repair. Following the proof of concept developed in this work, the plan is to extend the experimental approach to encompass individuals undergoing weight-bearing MRI. This expansion aims to measure *in vivo* deformation in soft structures, identifying meniscocapsular and/or meniscotibial insufficiency or rupture in patients.

## Data availability statement

The raw data supporting the conclusions of this article will be made available by the authors, without undue reservation.

## Ethics statement

The studies involving humans were approved by Ethics committee of the French Ministry of Health under the number: DC-2019-3704 UNIVERSITE DE POITIERS, ABSLab F-86000 Poitiers, France. The studies were conducted in accordance with the local legislation and institutional requirements. The human samples used in this study were acquired as a gift from another research group. Written informed consent for participation was not required from the participants or the participants' legal guardians/next of kin in accordance with the national legislation and institutional requirements.

## Author contributions

MS: Conceptualization, Data curation, Formal Analysis, Investigation, Methodology, Visualization, Writing—original draft. FZ: Methodology, Software, Visualization, Writing—review and editing. GH-G: Formal Analysis, Methodology, Visualization, Writing—review and editing. AG: Conceptualization, Formal Analysis, Investigation, Methodology, Project administration, Supervision, Visualization, Writing—original draft, Writing—review and editing. GH: Investigation, Project administration, Resources, Software, Writing—review and editing. MN: Investigation, Software, Writing—review and editing. VV: Formal Analysis, Software, Supervision, Writing—review and editing. JD: Investigation, Methodology, Resources, Writing—review and editing. TV: Conceptualization, Data curation, Formal Analysis, Investigation, Methodology, Resources, Supervision, Validation, Writing—review and editing.

## Funding

The author(s) declare that no financial support was received for the research, authorship, and/or publication of this article.

## Acknowledgments

We would like to thank ABS Lab of the University of Poitiers; Mr. Christian Normand, design engineer of the Pprime Institute, for the realization of the MRI-compatible load bench and Mr. Jeffrey Arsham, an American translator, for rereading and correcting the original English-language manuscript.

## References

- Ahn, J. H., Bae, T. S., Kang, K.-S., Kang, S. Y., and Lee, S. H. (2011). Longitudinal tear of the medial meniscus posterior horn in the anterior cruciate ligament-deficient knee significantly influences anterior stability. *Am. J. Sports Med.* 39, 2187–2193. doi:10.1177/0363546511416597
- Balazs, G. C., Greditzer, H. G., Wang, D., Marom, N., Potter, H. G., Marx, R. G., et al. (2019). Ramp lesions of the medial meniscus in patients undergoing primary and revision ACL reconstruction: prevalence and risk factors. *Orthop. J. Sports Med.* 7, 232596711984350. doi:10.1177/2325967119843509
- Bay, B. K., Smith, T. S., Fyhrle, D. P., and Saad, M. (1999). Digital volume correlation: three-dimensional strain mapping using X-ray tomography. *Exp. Mech.* 39, 217–226. doi:10.1007/BF02323555
- Brophy, R. H., Steinmetz, R. G., Smith, M. V., and Matava, M. J. (2022). Meniscal ramp lesions: anatomy, epidemiology, diagnosis, and treatment. *J. Am. Acad. Orthop. Surg.* 30, 255–262. doi:10.5435/JAAOS-D-21-00091
- Buljac, A., Jäilin, C., Mendoza, A., Neggens, J., Taillandier-Thomas, T., Bouterf, A., et al. (2018). Digital volume correlation: review of progress and challenges. *Exp. Mech.* 58, 661–708. doi:10.1007/s11340-018-0390-7
- Chahla, J., Dean, C. S., Moatshe, G., Mitchell, J. J., Cram, T. R., Yacuzzi, C., et al. (2016). Meniscal ramp lesions: anatomy, incidence, diagnosis, and treatment. *Orthop. J. Sports Med.* 4, 232596711665781. doi:10.1177/2325967116657815
- Choi, C.-J., Choi, Y.-J., Lee, J.-J., and Choi, C.-H. (2010). Magnetic resonance imaging evidence of meniscal extrusion in medial meniscus posterior root tear. *Arthroscopy* 26, 1602–1606. doi:10.1016/j.arthro.2010.05.004
- Daszkiewicz, K., and Luczkiewicz, P. (2021). Biomechanics of the medial meniscus in the osteoarthritic knee joint. *PeerJ* 9, e12509. doi:10.7717/peerj.12509
- Debieux, P., Jimenez, A. E., Novaretti, J. V., Kaleka, C. C., Kriscenski, D. E., Astur, D. C., et al. (2021). Medial meniscal extrusion greater than 4 mm reduces medial tibiofemoral compartment contact area: a biomechanical analysis of tibiofemoral contact area and pressures with varying amounts of meniscal extrusion. *Knee Surg. Sports Traumatol. Arthrosc.* 29, 3124–3132. doi:10.1007/s00167-020-06363-0
- DePhillipo, N. N., Moatshe, G., Brady, A., Chahla, J., Aman, Z. S., Dornan, G. J., et al. (2018). Effect of meniscocapsular and meniscotibial lesions in ACL-deficient and ACL-reconstructed knees: a biomechanical study. *Am. J. Sports Med.* 46, 2422–2431. doi:10.1177/0363546518774315
- Disney, C. M., Lee, P. D., Hoyland, J. A., Sherratt, M. J., and Bay, B. K. (2018). A review of techniques for visualising soft tissue microstructure deformation and quantifying strain *ex vivo*: soft tissue microstructure deformation and quantifying strain. *J. Microsc.* 272, 165–179. doi:10.1111/jmi.12701
- Engebretsen, L., Wijdicks, C. A., Anderson, C. J., Westerhaus, B., and LaPrade, R. F. (2012). Evaluation of a simulated pivot shift test: a biomechanical study. *Knee Surg. Sports Traumatol. Arthrosc.* 20, 698–702. doi:10.1007/s00167-011-1744-1
- Germaneau, A., Doumalin, P., and Dupré, J. C. (2007). Full 3D measurement of strain field by scattered light for analysis of structures. *Exp. Mech.* 47, 523–532. doi:10.1007/s11340-006-9029-1
- Germaneau, A., Doumalin, P., and Dupré, J.-C. (2008). Comparison between X-ray micro-computed tomography and optical scanning tomography for full 3D strain measurement by digital volume correlation. *NDT E Int.* 41, 407–415. doi:10.1016/j.ndteint.2008.04.001
- Guermazi, A., Eckstein, F., Hayashi, D., Roemer, F. W., Wirth, W., Yang, T., et al. (2015). Baseline radiographic osteoarthritis and semi-quantitatively assessed meniscal damage and extrusion and cartilage damage on MRI is related to quantitatively defined cartilage thickness loss in knee osteoarthritis: the Multicenter Osteoarthritis Study. *Osteoarthr. Cartil.* 23, 2191–2198. doi:10.1016/j.joca.2015.06.017

## Conflict of interest

The authors declare that the research was conducted in the absence of any commercial or financial relationships that could be construed as a potential conflict of interest.

## Publisher's note

All claims expressed in this article are solely those of the authors and do not necessarily represent those of their affiliated organizations, or those of the publisher, the editors and the reviewers. Any product that may be evaluated in this article, or claim that may be made by its manufacturer, is not guaranteed or endorsed by the publisher.

- Hatayama, K., Terauchi, M., Saito, K., Takase, R., and Higuchi, H. (2020). Healing status of meniscal ramp lesion affects anterior knee stability after ACL reconstruction. *Orthop. J. Sports Med.* 8, 232596712091767. doi:10.1177/2325967120917674
- Hein, C. N., Deperio, J. G., Ehrensberger, M. T., and Marzo, J. M. (2011). Effects of medial meniscal posterior horn avulsion and repair on meniscal displacement. *Knee* 18, 189–192. doi:10.1016/j.knee.2010.04.006
- Kawaguchi, K., Enokida, M., Otsuki, R., and Teshima, R. (2012). Ultrasonographic evaluation of medial radial displacement of the medial meniscus in knee osteoarthritis. *Arthritis Rheum.* 64, 173–180. doi:10.1002/art.33319
- Krych, A. J., Reardon, P. J., Johnson, N. R., Mohan, R., Peter, L., Levy, B. A., et al. (2017). Non-operative management of medial meniscus posterior horn root tears is associated with worsening arthritis and poor clinical outcome at 5-year follow-up. *Knee Surg. Sports Traumatol. Arthrosc.* 25, 383–389. doi:10.1007/s00167-016-4359-8
- Kunze, K. N., Haddad, A., White, A. E., Cohn, M. R., LaPrade, R. F., and Chahla, J. (2021b). The top 50 most cited publications in meniscus research. *J. Knee Surg.* 36, 329–334. doi:10.1055/s-0041-1733881
- Kunze, K. N., Wright-Chisem, J., Polce, E. M., DePhillipo, N. N., LaPrade, R. F., and Chahla, J. (2021a). Risk factors for ramp lesions of the medial meniscus: a systematic review and meta-analysis. *Am. J. Sports Med.* 49, 3749–3757. doi:10.1177/0363546520986817
- Liu, T., Shen, X., Ji, Q., Xiao, J., Zuo, J., and Gao, Z. (2021). The MRI-based 3D morphologic changes of knee meniscus under knee weight-bearing and early flexion conditions. *Sci. Rep.* 11, 22122. doi:10.1038/s41598-021-01531-9
- Liu, X., Feng, H., Zhang, H., Hong, L., Wang, X. S., and Zhang, J. (2011). Arthroscopic prevalence of ramp lesion in 868 patients with anterior cruciate ligament injury. *Am. J. Sports Med.* 39, 832–837. doi:10.1177/0363546510388933
- Magosch, A., Mouton, C., Nührenböcker, C., and Seil, R. (2021). Medial meniscus ramp and lateral meniscus posterior root lesions are present in more than a third of primary and revision ACL reconstructions. *Knee Surg. Sports Traumatol. Arthrosc.* 29, 3059–3067. doi:10.1007/s00167-020-06352-3
- Mariani, P. P., Torre, G., and Battaglia, M. J. (2022). The post-traumatic meniscal extrusion, sign of meniscotibial ligament injury. A case series. *Orthop. Traumatol. Surg. Res.* 108, 103226. doi:10.1016/j.otsr.2022.103226
- Marter, A., Burson-Thomas, C., Dickinson, A., Rankin, K., Mavrogordato, M., Pierron, F., et al. (2020). Measurement of internal implantation strains in analogue bone using DVC. *Mater. (Basel)* 13, E4050. doi:10.3390/ma13184050
- Mouton, C., Magosch, A., Pape, D., Hoffmann, A., Nührenböcker, C., and Seil, R. (2020). Ramp lesions of the medial meniscus are associated with a higher grade of dynamic rotatory laxity in ACL-injured patients in comparison to patients with an isolated injury. *Knee Surg. Sports Traumatol. Arthrosc.* 28, 1023–1028. doi:10.1007/s00167-019-05579-z
- Naendrup, J.-H., Pfeiffer, T. R., Chan, C., Nagai, K., Novaretti, J. V., Sheehan, A. J., et al. (2019). Effect of meniscal ramp lesion repair on knee kinematics, bony contact forces, and *in situ* forces in the anterior cruciate ligament. *Am. J. Sports Med.* 47, 3195–3202. doi:10.1177/0363546519872964
- Ollivier, M., Batty, L., Murgier, J., and Pujol, N. (2022). Recent advances in ligamentous, meniscal and joint-preserving knee surgery: pushing the limits. *Orthop. Traumatol. Surg. Res.* 108, 103282. doi:10.1016/j.otsr.2022.103282
- Ozeki, N., Koga, H., and Sekiya, I. (2022). Degenerative meniscus in knee osteoarthritis: from pathology to treatment. *Life (Basel)* 12, 603. doi:10.3390/life12040603
- Palanca, M., Tozzi, G., Cristofolini, L., Viceconti, M., and Dall'Ara, E. (2015). Three-dimensional local measurements of bone strain and displacement: comparison of three digital volume correlation approaches. *J. Biomech. Eng.* 137. doi:10.1115/1.4030174

- Park, D. Y., Yin, X. Y., Chung, J. Y., Jin, Y. J., Kwon, H. J., Lee, G. B., et al. (2022). Circumferential rim augmentation suture around the perimeniscal capsule decreases meniscal extrusion and progression of osteoarthritis in rabbit meniscus root tear model. *Am. J. Sports Med.* 50, 689–698. doi:10.1177/03635465211064297
- Peltier, A., Lording, T., Maubisson, L., Ballis, R., Neyret, P., and Lustig, S. (2015). The role of the meniscotibial ligament in posteromedial rotational knee stability. *Knee Surg. Sports Traumatol. Arthrosc.* 23, 2967–2973. doi:10.1007/s00167-015-3751-0
- Seil, R. (2018). Editorial commentary: medial meniscal ramp lesions: lessons learned from the past in the pursuit of evidence. *Arthroscopy* 34, 1638–1640. doi:10.1016/j.arthro.2018.02.032
- Sharafat Vaziri, A., Aghaghazvini, L., Jahangiri, S., Tahami, M., Borazjani, R., Tahmasebi, M. N., et al. (2022). Determination of normal reference values for meniscal extrusion using ultrasonography during the different range of motion: a pilot, feasibility study. *J. Ultrasound Med.* 41, 2715–2723. doi:10.1002/jum.15955
- Stephen, J. M., Halewood, C., Kittl, C., Bollen, S. R., Williams, A., and Amis, A. A. (2016). Posteromedial meniscocapsular lesions increase tibiofemoral joint laxity with anterior cruciate ligament deficiency, and their repair reduces laxity. *Am. J. Sports Med.* 44, 400–408. doi:10.1177/0363546515617454
- Sugita, T., Kawamata, T., Ohnuma, M., Yoshizumi, Y., and Sato, K. (2001). Radial displacement of the medial meniscus in varus osteoarthritis of the knee. *Clin. Orthop. Relat. Res.* 387, 171–177. doi:10.1097/00003086-200106000-00023
- Thaunat, M., Ingale, P., Penet, A., Kacem, S., Haidar, I., Bauwens, P.-H., et al. (2021). Ramp lesion subtypes: prevalence, imaging, and arthroscopic findings in 2156 anterior cruciate ligament reconstructions. *Am. J. Sports Med.* 49, 1813–1821. doi:10.1177/03635465211006103
- Valle, V., Bokam, P., Germaneau, A., and Hedan, S. (2019). New development of Digital Volume Correlation for the study of fractured materials. *Exp. Mech.* 59, 1–15. doi:10.1007/s11340-018-0415-2
- Wilke, H.-J., Wenger, K., and Claes, L. (1998). Testing criteria for spinal implants: recommendations for the standardization of *in vitro* stability testing of spinal implants. *Eur. Spine J.* 7, 148–154. doi:10.1007/s005860050045
- Yamaguchi, J., Yasuda, K., Kondo, E., Kaibara, T., Ueda, D., Yabuuchi, K., et al. (2021). Extrusion of the medial meniscus is a potential predisposing factor for post-arthroscopy osteonecrosis of the knee. *BMC Musculoskelet. Disord.* 22, 852. doi:10.1186/s12891-021-04730-7