



HAL
open science

Impact of Day 1 carotid patency on outcome in dissection-related tandem occlusions treated with mechanical thrombectomy

Guillaume Perrin, Elisabeth Molinier, Benjamin Gory, Maeva Kyheng, Julien Labreuche, Marco Pasi, Kevin Janot, Romain Bourcier, Igor Sibon, Arturo Consoli, et al.

► To cite this version:

Guillaume Perrin, Elisabeth Molinier, Benjamin Gory, Maeva Kyheng, Julien Labreuche, et al.. Impact of Day 1 carotid patency on outcome in dissection-related tandem occlusions treated with mechanical thrombectomy. *Journal de Neuroradiologie / Journal of Neuroradiology*, 2024, 51 (2), pp.196-203. 10.1016/j.neurad.2024.01.076 . hal-04697120

HAL Id: hal-04697120

<https://hal.science/hal-04697120>

Submitted on 13 Sep 2024

HAL is a multi-disciplinary open access archive for the deposit and dissemination of scientific research documents, whether they are published or not. The documents may come from teaching and research institutions in France or abroad, or from public or private research centers.

L'archive ouverte pluridisciplinaire **HAL**, est destinée au dépôt et à la diffusion de documents scientifiques de niveau recherche, publiés ou non, émanant des établissements d'enseignement et de recherche français ou étrangers, des laboratoires publics ou privés.



Distributed under a Creative Commons Attribution 4.0 International License



Available online at
ScienceDirect
 www.sciencedirect.com

Elsevier Masson France
EM|consulte
 www.em-consulte.com



Original Article

Impact of Day 1 carotid patency on outcome in dissection-related tandem occlusions treated with mechanical thrombectomy

Guillaume Perrin^{a,†}, Elisabeth Molinier^{a,†}, Benjamin Gory^b, Maeva Kyheng^c, Julien Labreuche^c, Marco Pasi^a, Kevin Janot^d, Romain Bourcier^e, Igor Sibon^f, Arturo Consoli^g, Jean-Philippe Desilles^h, Jean-Marc Olivotⁱ, Chrysanthi Papagiannaki^j, Sebastien Soize^k, Jean-Christophe Gentric^l, Cyril Dargazanli^m, Jildaz Caroffⁿ, Raoul Pop^o, Olivier Naggara^p, Solene Moulin^q, Omer Eker^r, Quentin Alias^s, Frederic Clarençon^t, Bertrand Lapergue^u, Gaultier Marnat^{v,*}, on behalf of the ETIS Registry Investigators (see appendix)

^a Neurology department, Tours University Hospital, Tours, France

^b Neuroradiology Department, Nancy University Hospital, INSERM 1254, IADI, Université de Lorraine, Nancy, France

^c Biostatistic Department – Lille University Hospital, Lille, France

^d Neuroradiology department, Tours University Hospital, Tours, France

^e Neuroradiology Department, Nantes University Hospital, Nantes, France

^f Neurology Department, Bordeaux University Hospital, Bordeaux, France

^g Neuroradiology Department, Foch Hospital, Suresnes, France

^h Neuroradiology Department, Fondation Ophtalmologique A. De Rothschild, Paris, France

ⁱ Neurology Department, Toulouse University Hospital, Toulouse, France

^j Neuroradiology Department, Rouen University Hospital, Rouen, France

^k Neuroradiology Department, Reims University Hospital, Reims, France

^l Neuroradiology Department, Brest University Hospital, Brest, France

^m Neuroradiology Department, Montpellier University Hospital, Montpellier, France

ⁿ Neuroradiology Department, Kremlin-Bicêtre University Hospital, Kremlin-Bicêtre, France

^o Neuroradiology Department, Strasbourg University Hospital, Strasbourg, France

^p Neuroradiology Department, Sainte-Anne University Hospital, Paris, France

^q Neurology Department, Reims University Hospital, Reims, France

^r Neuroradiology Department, Lyon University Hospital, Lyon, France

^s Neuroradiology Department, Rennes University Hospital, Rennes, France

^t Neuroradiology Department, Pitié-Salpêtrière University Hospital, Paris, France

^u Neurology Department, Foch Hospital, Suresnes, France

^v Neuroradiology Department, Bordeaux University Hospital, Bordeaux, France

ARTICLE INFO

Article History:

Available online 1 February 2024

Key words:

mechanical thrombectomy
 dissection
 carotid
 stenting

ABSTRACT

Background: The clinical benefit of mechanical thrombectomy (MT) for stroke patients with tandem occlusion is similar to that of isolated intracranial occlusions. However, the management of cervical internal carotid artery (ICA) occlusion during the MT, particularly in the setting of carotid dissection, remains controversial. We aimed to investigate the clinical impact of cervical ICA patency at day 1 on 3-month functional outcome. **Methods:** We collected data from the Endovascular Treatment in Ischemic Stroke, a prospective national registry in 30 French centers performing MT between January 2015 and January 2022. Inclusion criteria were consecutive tandem occlusions related to cervical ICA dissection treated with MT. Tandem occlusions of other etiology, isolated cervical ICA occlusions without intracranial thrombus and patients without day-1 ICA imaging were excluded. Primary endpoint was the 3-month functional outcome. Secondary endpoints included intracranial hemorrhage (ICH), excellent outcome, mortality and early neurological improvement. A sensitivity analysis was performed in patients with intracranial favorable recanalization after MT.

NON-STANDARD ABBREVIATIONS: ASD, Absolute Standard Deviation; ASPECTS, Alberta Stroke Program Early CT Score; CI, Confidence Interval; ETIS, Endovascular Treatment in Ischemic Stroke; ICA, internal carotid artery; ICH, intracerebral hemorrhage; IQR, Interquartile Range; IVT, Intravenous Thrombolysis; mRS, modified Rankin Score; MT, mechanical thrombectomy; mTICI, modified Thrombolysis in Cerebral Infarction; NIHSS, National Institute of Health Stroke Scale; OR, Odds Ratio; PH, Parenchymal Hemorrhage; SD, Standard deviation; sICH, symptomatic intracranial hemorrhage

* Corresponding author: Gaultier Marnat; Neuroradiology Department, Bordeaux University Hospital, Bordeaux, France.

E-mail address: Gaultier.marnat@chu-bordeaux.fr (G. Marnat).

† Contributed equally

<https://doi.org/10.1016/j.neurad.2024.01.076>

0150-9861/© 2024 The Author(s). Published by Elsevier Masson SAS. This is an open access article under the CC BY license (<http://creativecommons.org/licenses/by/4.0/>)

Results: During the study period, 137 patients were included of which 89(65%) presented ICA patency at day 1. The odds of favorable outcome did not significantly differ between patients with patent and occluded ICA at day 1 (68.7 vs 59.1%; aOR=1.30; 95%CI 0.56-3.00, $p=0.54$). Excellent outcome, early neurological improvement, mortality and ICH were also comparable between groups. Sensitivity analysis showed similar results.

Conclusion: ICA patency at day 1 in patients with tandem occlusions related to dissection did not seem to influence functional outcome. Endovascular recanalization of the cervical ICA including stenting might not be systematically required in this setting.

© 2024 The Author(s). Published by Elsevier Masson SAS. This is an open access article under the CC BY license (<http://creativecommons.org/licenses/by/4.0/>)

INTRODUCTION

The benefit of mechanical thrombectomy (MT) in patients presenting with tandem occlusions has already been established.¹ However, pending the results of ongoing trials, the endovascular strategy remains poorly codified.^{2,3} Several publications reported the positive role of the recanalization of the extracranial internal carotid artery (ICA).^{4,5} Yet, in these studies, no distinction was made between tandem occlusion etiologies including atherosclerosis and dissection. Cervical ICA dissection usually accounts for around 20% of tandem occlusions.⁶ If literature brings important evidence supporting the positive role of ICA stenting and durable cervical arterial patency in atherosclerotic tandem occlusions, there is no such tendency regarding dissection related tandem occlusions.^{7,8} Indeed, recent studies demonstrated no clear benefit from cervical ICA stenting in this specific tandem occlusions etiology.^{8,9} These findings are very likely explained by important differences in physiopathology, patient and cardiovascular profile, natural history including the risk of recurrent stroke and endovascular technical approach for ICA recanalization among atherosclerosis and dissection related tandem occlusions. Still, evidences are missing to elucidate the importance of reaching durable cervical ICA patency. In this study, we aimed to assess the impact of Day-1 extracranial ICA patency in dissection related tandem occlusions on 3-months functional outcome.

METHODS

The data used in this study are available from the corresponding author upon reasonable request.

Study population

We conducted a retrospective study reviewing data from the Endovascular Treatment in Ischemic Stroke (ETIS; clinical trial identifier NCT03776877) national registry between January 2015 and January 2022. ETIS is a French nationwide prospective observational registry collecting data of consecutive patients treated with MT^{10,11}. Local ethical committees approved the study. Oral consent was obtained from patients or their relatives. Our study included all consecutive patients with tandem occlusion related to ICA dissection treated with MT and included in the ETIS registry in the participating centers. ICA dissection diagnosis was locally assessed by a trained neuroradiologist. All included patients were reviewed to confirm the ICA dissection. ICA dissection diagnosis was based on angiographic features (per-thrombectomy angiographic aspect), noninvasive imaging explorations demonstrating cervical ICA arterial wall hematoma, epidemiological data and exclusion of differential stroke etiologies. Exclusion criteria were: tandem occlusion of other cause than dissection including atherosclerosis, isolated cervical ICA occlusion without intracranial occlusion, posterior circulation occlusions and missing day-1 arterial imaging.

Treatment protocol

MT indications were decided on a case-by-case basis according to standard guidelines, patient condition and local multidisciplinary discussion. The endovascular strategy was left to the discretion of the

interventionist. In particular, carotid stenting was performed according to several criteria including intracranial recanalization status after MT, prior intra-venous thrombolysis (IVT), cervical ICA dissection angiographic aspect, Willis circle functionality and local habits. Intra-operative antithrombotic therapy may also be used including intravenous aspirin, GpIIb/IIIa inhibitor, cangrelor or heparin according to local habits and per operative angiographic features. Prior IVT was administered according to usual guidelines, in the absence of contraindications.¹² Illustrative cases are provided in [Figures 1 and 2](#).

Collected data and outcomes

Clinical, imaging, timeline, and angiographic data were prospectively recorded. 90-day modified Rankin Scale (mRS) scores were collected by certified investigators during routinely scheduled visits or by trained research nurses during a standardized telephone interview. Angiographic and imaging data were locally assessed by senior neuroradiologists. Procedural complications (embolism in a new territory and intracranial arterial perforation) were recorded. Cervical ICA patency status was assessed on day-1 imaging (MRI or angio-CT). The primary outcome was favorable outcomes defined as a 3-month mRS score of 0-2 or equal to pre-stroke mRS. Secondary outcomes included excellent outcome (3-month mRS 0-1), mortality, early neurological improvement, any intracranial hemorrhage (ICH), symptomatic ICH (sICH), parenchymal hematoma (PH), decompressive craniectomy and day-1 ASPECTS shift. Early neurological improvement was defined by the variation in NIHSS (delta NIHSS) between admission and day-1. ICH was assessed according to the ECASS II classification. Symptomatic intracranial hemorrhage (sICH) was defined as a neurological deterioration (NIHSS worsening ≥ 4 points or death) along with ICH. Infarct extension was assessed with delta ASPECTS between initial and day-1 imaging.

Statistical analysis

Quantitative variables are expressed as means \pm standard deviation or medians (interquartile range, IQR) and categorical variables are expressed as numbers (percentage). Normality of distributions was assessed using histograms and Shapiro-Wilk test. To assess the selection bias due to missing information on carotid recanalization, patient's characteristics were described according to the patients with and without available information on carotid recanalization and the magnitude of the between-group differences were assessed by calculating the absolute standardized differences; an absolute standardized difference <0.2 was interpreted as small difference. Further analyses were conducted among the 137 patients with carotid recanalization information. The rate of carotid recanalization was calculated with its 95% exact confidence interval (CI) calculated using the Clopper-Pearson method. We studied the association of carotid recanalization with binary outcomes (favorable and excellent outcomes, 90-day mortality, decompressive craniectomy, any ICH, sICH and PH) by using logistic regression model with Firth's penalized likelihood approach in cases of small number of outcome events. We derived from logistic regression models odds ratios (ORs) for recanalized versus non-recanalized carotid artery as effect sizes. NIHSS and

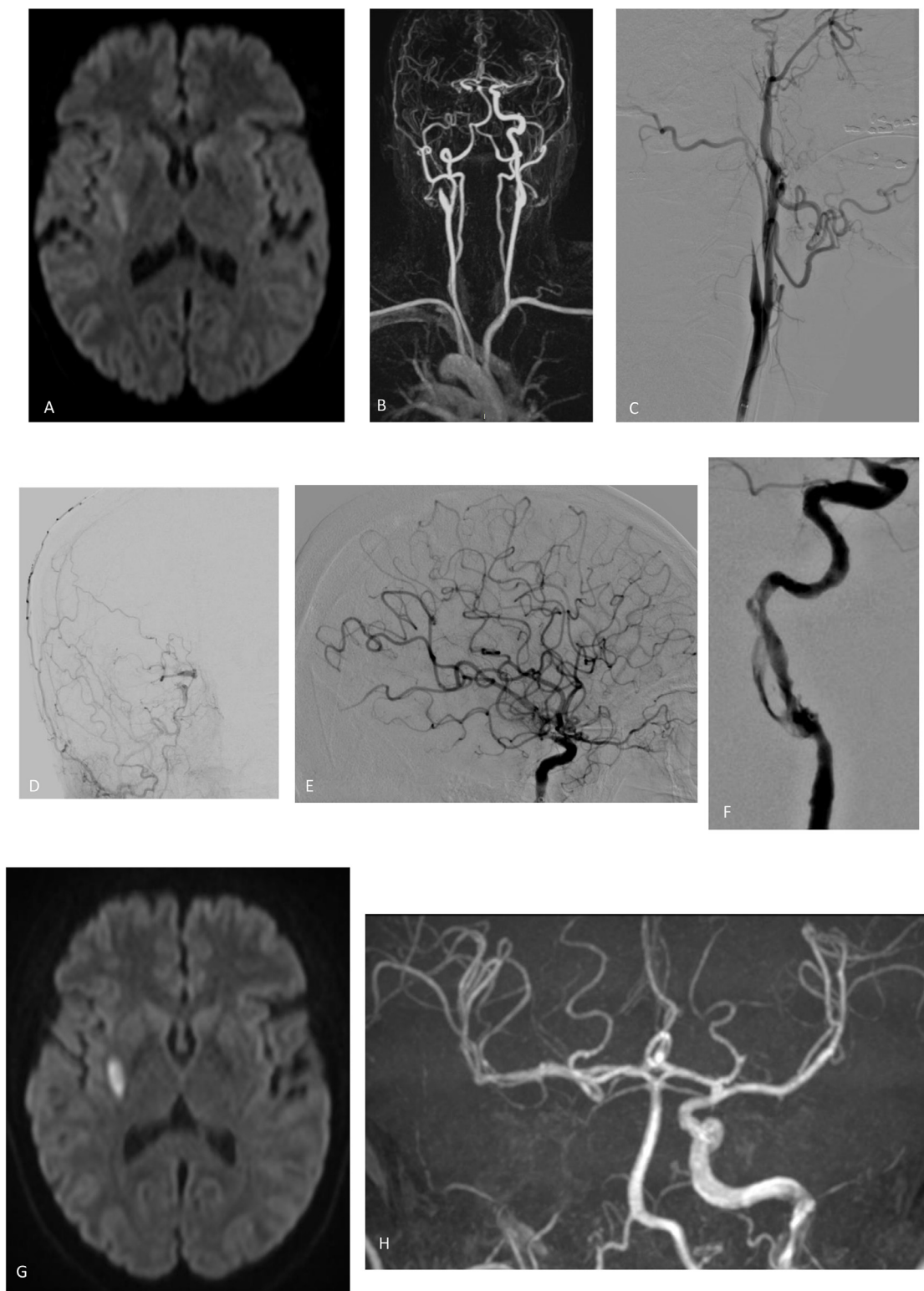


Figure 1. A 62 years-old patient suffering from a sudden left hemiplegia underwent this initial MRI showing a limited lenticular infarction (A) and a tandem occlusion of the right cervical ICA plus the M1 segment of the right middle cerebral artery (B). Endovascular treatment was initiating confirming the tandem occlusion (C, D) and allowing a complete intracranial recanalization (E). No further endovascular treatment of the cervical ICA was performed because the ICA catheterism was associated with a partial reopening of the ICA dissection (F) and the circle of Willis was found functional. The neurological deficit recovered rapidly after the endovascular procedure. Day-1 imaging demonstrated a limited final infarct volume (G) but also a reocclusion of the cervical ICA (H) without neurological worsening.

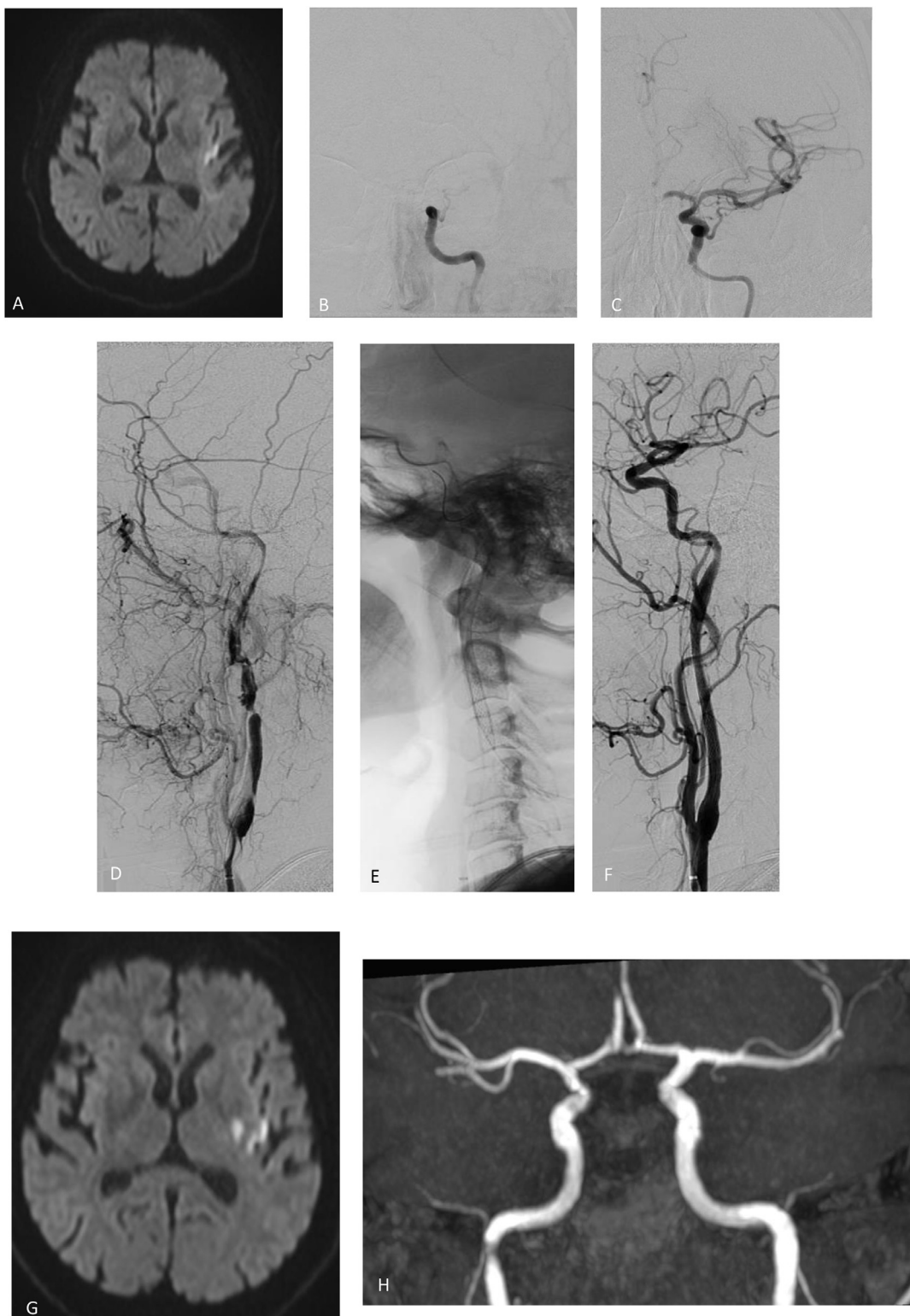


Figure 2. This 52 years-old patient presented with right hemiplegia and aphasia due to a tandem occlusion. MRI performed 4 hours after onset demonstrated slight infarction of the insula (A) along with a left tandem occlusion likely related to an ICA dissection. Complete intracranial reperfusion (B, C) was achieved first. Angiographic findings confirmed the dissection of the subpetrosal cervical ICA (D). Considering the persistent high-grade stenosis and the very irregular shape of the residual arterial lumen, emergent carotid stenting was performed association with an intravenous 250mg Aspirin bolus (E, F). Day-1 imaging revealed a very limited extension of infarction (G) without ICH and a patency of the left cervical ICA (H). A dual antiplatelet therapy was initiated.

ASPECTS changes at 24 hours were compared using an analysis of covariance adjusted for baseline values. Using patients without carotid recanalization as reference, we derived from these regression models, mean differences as effect sizes. All analyses of association of carotid recanalization outcomes were further adjusted on pre-specified factors (pre-treatment NIHSS score, pre-treatment ASPECTS, and time from onsets to groin puncture). All analyses were repeated in patients with mTICI $\geq 2b$ at the end of endovascular procedure regarding the strong differences in mTICI $\geq 2b$ according to carotid recanalization status. Statistical testing was done at the two-tailed α level of 0.05. Data were analyzed using the SAS software package, release 9.4 (SAS Institute, Cary, NC).

RESULTS

From January 2015 to January 2022, among 1206 patients with tandem occlusions included in the ETIS registry, 195 patients with dissection tandem occlusions were finally enrolled in 30 participating centers. Among these, 137 had data available for day-1 carotid patency (study population) and 58 had a missing value (excluded patients) (see study flowchart, Fig. 3). Baseline characteristics according to included and excluded patients are reported in **Supplemental Table 1**. Several differences were found between included and excluded patients. In particular, differences in the site of intracranial occlusion (ASD=53.6%) with a lower rate of intracranial ICA occlusions (46.6% vs 22.6%) and a higher admission ASPECTS [7(6-8) vs 6 (5-7); ASD=31.0%] in the included study population.

Among the 137 patients included, 89 (65.0%, 95%CI 56.3 to 72.9%) presented a patent ICA at Day 1. Baseline characteristics according to carotid patency status are reported in **Table 1** for overall study population and in **Supplemental table 2** among patients with successful intracranial recanalization, since a higher rate of intracranial

recanalization was found in patients with carotid recanalization (82.0% vs 66.0%, ASD=37.3).

As shown in **Table 2**, the rate of favorable and excellent outcomes was higher in patients with carotid recanalization than in patients without recanalization (68.7% vs 59.1% and 41.0% vs 31.8% respectively) but the differences did not reach the significance levels with an adjusted OR of 1.30 (95%CI 0.56 to 3.00) for favorable outcome and 1.43 (95%CI 0.64 to 3.20) for excellent outcome. The rate of 90-day mortality did not differ between the two study groups with an adjusted OR of 1.40 (95%CI 0.32 to 8.29). No significant association was observed between day 1 ICA patency and the rates of any ICH, PH and sICH (aOR for any ICH= 1.91, 95%CI 0.87 to 4.20, aOR for PH= 1.72, 95%CI 0.44 to 9.53 and aOR for sICH=2.27, 95%CI 0.45 to 22.43, respectively), decompressive craniectomy (4.4 vs 1.3%), delta NIHSS between admission and day-1 (aOR=0.99; 95%CI -1.63 to 3.62, $p=0.45$) and delta ASPECTS between admission imaging and day-1 (aOR=-0.06; 95%CI -0.75-0.63, $p=0.35$). Results are also summarized in **supplemental figure 1**.

Sensitivity analysis performed in patients with successful intracranial recanalization (mTICI $\geq 2b$ at the end of endovascular procedure) showed similar results (**Supplemental Table 3**). We also investigated the variable associated with functional outcomes in the subgroup of patients with ICA occlusion on day 1 imaging (supplemental table 4).

DISCUSSION

This study revealed that ICA patency at Day 1 in patients with dissection tandem occlusions treated with MT was not significantly associated with an improved functional outcome at 3 months, despite a trend toward more favorable outcomes in the patent ICA subgroup. This result was also observed among patients with successful

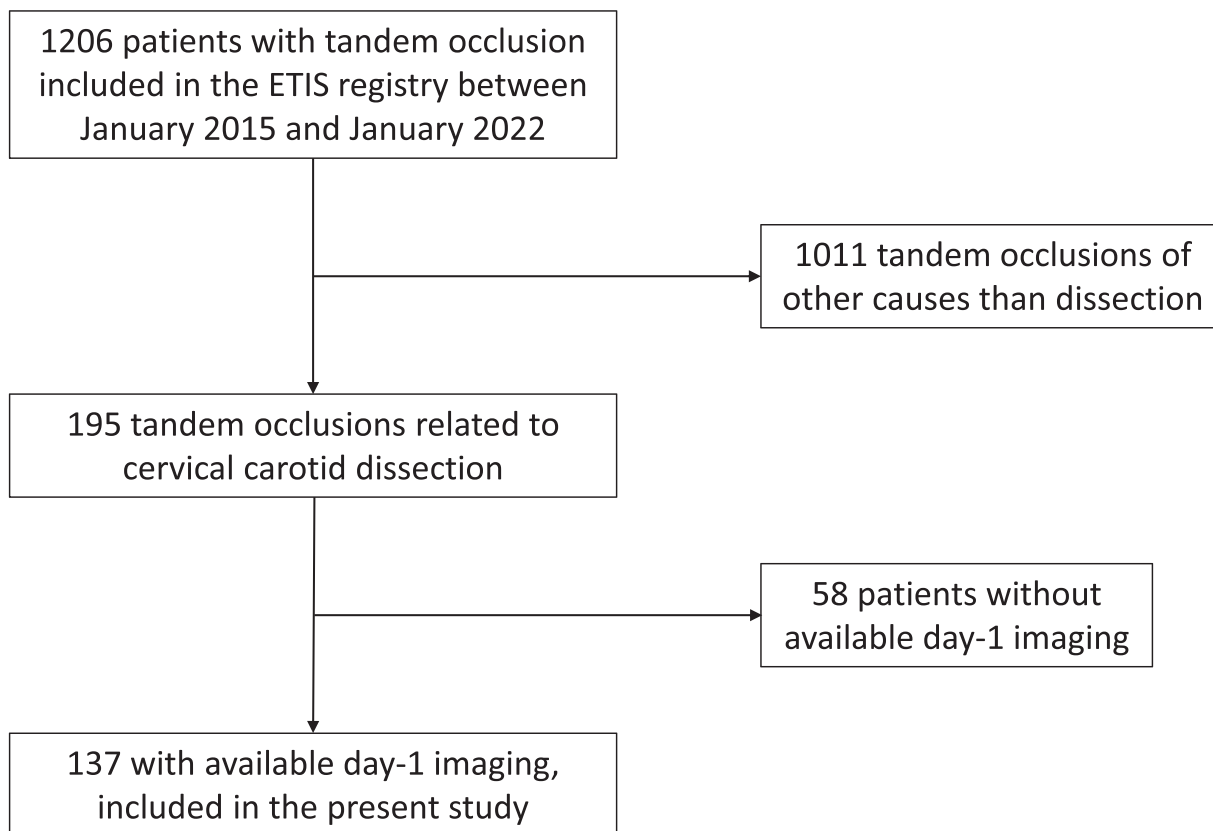


Figure 3. Study flowchart

Table 1
Baseline characteristics according to carotid patency at day-1 in included population (n=137)

Parameters	Day-1 ICA patency		ASD (%)
	No (n=48)	Yes (n=89)	
Age, y mean \pm SD	50.6 \pm 13.2	51.6 \pm 11.3	8.4
Men	34/48 (70.8)	72/89 (80.9)	23.7
Medical history			
Hypertension	9/48 (18.8)	23/88 (26.1)	17.8
Diabetes mellitus	3/48 (6.3)	2/88 (2.3)	19.8
Hypercholesterolemia	3/48 (6.3)	9/88 (10.2)	14.5
Current smoking	13/47 (27.7)	23/88 (26.1)	3.4
History of previous stroke	3/48 (6.3)	7/83 (8.4)	8.4
Pre-stroke mRS			
0	46/48 (95.8)	85/87 (97.7)	10.6
\geq 1	2/48 (4.2)	2/87 (2.3)	
Pre stroke Antithrombotic treatment	4/48 (8.3)	10/87 (11.5)	10.6
Admission mode			
Drip and ship	27/46 (58.7)	46/89 (51.7)	19.0
Mothership	19/46 (41.3)	43/89 (48.3)	
Stroke event			
Wake-up stroke or unknown symptom onset	17/47 (36.2)	28/89 (31.5)	10.0
Systolic BP, mmHg, mean \pm SD ¹	140.8 \pm 21.4	137.8 \pm 19.6	14.9
Distolic BP, mmHg, mean \pm SD ¹	85.3 \pm 16.7	84.2 \pm 14.2	7.6
NIHSS score, median (IQR) ²	16 (13 to 19)	15 (10 to 19)	18.9
ASPECTS score, median (IQR) ³	7 (6 to 8)	7 (5 to 8)	19.4
EVT characteristics			
Intravenous thrombolysis	29/48 (60.4)	50/89 (56.2)	8.6
Number of pass ⁴	2 (1 to 3)	2 (1 to 3)	10.9
General anesthesia	11/48 (22.9)	36/89 (40.4)	38.4
Cervical stenting	9/48 (18.7)	32/89 (36.0)	40.0
Intracranial occlusion site			
M1	26/48 (54.2)	46/89 (51.7)	51.7
M2	6/48 (12.5)	28/89 (31.5)	
Intracranial ICA	16/48 (33.3)	15/89 (16.9)	
Procedural complication	4/47 (8.5)	8/78 (10.3)	6.0
Intraoperative Aspirin administration	6/35 (17.1)	26/58 (44.8)	62.7
Intraoperative GP2b3a or cangrelor administration	1/32 (3.1)	10/52 (19.2)	52.9
Intraoperative Heparin administration	2/30 (6.7)	11/47 (23.4)	48.2
Cervical ICA patency at the end of EVT	24/46 (52.2)	74/79 (93.7)	106
Final mTICI \geq 2B	31/47 (66.0)	73/89 (82.0)	37.3
Workflow			
Onset to puncture time, min, median (IQR) ⁵	262.5 (178 to 315)	246.5 (189 to 309)	2.0
Onset to imaging time, min, median (IQR) ⁶	110.5 (85 to 167)	115 (85 to 174)	3.9
Imaging to puncture time, min, median (IQR) ⁷	97 (67 to 156)	105 (69 to 180)	9.3

Values expressed as number (percentage) unless otherwise indicated.

¹ 13 missing data (11 in group with 24 hours carotid recanalization)

² 1 missing data in group with 24 hours carotid recanalization

³ 8 missing (3 in group with 24 hours carotid recanalization)

⁴ 8 missing data (2 in group with 24 hours carotid recanalization)

⁵ 5 missing data (3 in group with 24 hours carotid recanalization)

⁶ 10 missing data (4 in group with 24 hours carotid recanalization)

⁷ 7 missing data (2 in group with 24 hours carotid recanalization). Abbreviations:

ASPECTS= Alberta stroke program early computed tomography score; BP=blood pressure; ICA=internal carotid artery; IQR=interquartile range; NIHSS=National Institutes of Health Stroke Scale;; SD=standard deviation;

intracranial recanalization at the end of the MT procedure. Also, no significant influence of day 1 ICA patency was detected on secondary endpoints (ICH, early neurological status, mortality, infarct extension, decompressive craniectomy).

While the benefits of endovascular intracranial recanalization appear well-established in dissection tandem occlusions, the

management of the cervical ICA occlusion is more controversial.^{8,13,14} This therapeutic uncertainty is mainly related to a) the influence of the patency of the cervical ICA on the risk of recurrent stroke, b) specific technical issues related to endovascular treatment of dissection related tandem occlusions, c) complications and difficulties potentially associated with ICA stenting in this singular indication. Recurrence rate after the initial ischemic event related to ICA dissection is debated but seems actually much lower than recurrence rate in cervical ICA atherosclerosis, which has been previously reported around 15.9 to 26%¹⁵. Data provided by the CADISS trial cohort revealed low risk of a new ischemic stroke whatever the introduced anti-thrombotic medication as secondary prevention.¹⁶ On the other hand, recent publications reported that a persistent cervical ICA occlusion was associated with an increased risk of stroke during follow-up.^{17–19} Reaching a durable ICA patency implies a targeted endovascular approach including emergent cervical ICA stenting during the MT procedure along with antiplatelet therapy. Despite being reasonably feasible in number of cases, such stenting can be complex: cervical ICA loops are frequent in this population, catheterization the true arterial lumen without extending the dissection can be tricky, the choice of the stent type and the optimal associated antiplatelet therapy remain unelucidated to date. As a result of these complex discussions, previous publications regarding endovascular management of dissection related tandem occlusions revealed that the benefit of cervical ICA stenting might be marginal.^{8,13,14,20,9} In this perspective, studies evaluating ICA patency at day-1 and stenting in tandem dissection occlusions found conflicting results. Previous studies showed a marked benefit in functional outcome of ICA patency at Day 1.^{5,7} However, the underlying etiologies – dissection or atherosclerosis – were not analyzed separately. Differently, several authors reported that the interest of emergent ICA stenting and maintaining durable ICA patency might be minor among dissection related tandem occlusions.^{8,13,14} Again, it seems that, probably mostly due its lower recurrent stroke risk, emergent stenting of ICA dissection and durable ICA patency does not represent the same critical issue as encountered in the treatment of atherosclerosis related tandem occlusions. Indeed, for atherosclerotic tandem occlusions, emergent carotid stenting and day-1 carotid patency might be more crucial, subject to the results of ongoing trial².

An important issue with emergent ICA stenting is stent thrombosis, which occurs mostly within the first 24 hours. Its occurrence is not rare, estimated at about 14.5%²¹ but up to 45% in some studies.²² This stent thrombosis has been reported to be associated with a worse functional prognosis.^{7,6} To limit this phenomenon, the use of antiplatelet agents may be necessary, but the risk of an increased hemorrhagic transformation rate may be considered.^{23,24} As expected, in our study, cervical ICA stenting and intraoperative use of antithrombotic therapy were more frequent in the patent carotid group at day-1. This should very likely explain the trend toward higher odds of ICH at day-1 (any ICH, PH and sICH) even if the difference did not reach significance. However, this might be taken into consideration. Given the limited impact of day-1 patency of the cervical ICA on the clinical outcome, maintaining such patency might not be targeted at all cost.

The decision on whether to deploy an ICA stent to preserve arterial patency is strongly related to intracranial recanalization in our experience but also among literature. Attempted extracranial recanalization is predominantly undertaken in cases of successful intracranial recanalization.¹³ In this sense, we carried out an analysis on the sub-group of patients with favorable intracranial recanalization (final mTICI score 2b-2c-3). In this sensitivity analysis, extracranial ICA patency was again not associated with improved outcome. Some authors suggest a more conservative approach in managing dissection tandem occlusions, without necessarily performing systematic ICA stenting.^{13,14,20,9,25} The treatment of extracranial occlusion may best be reserved to specific cases such as insufficiently functional

Table 2
Comparisons in clinical outcomes according to day-1 ICA patency status in overall study sample.

	Day-1 ICA patency		Unadjusted		Adjusted	
	No (n=48)	Yes (n=89)	Effect size (95%CI)	p-values	Effect size (95%CI)	p-values
Clinical outcomes						
Favorable outcome ¹	26/44 (59.1)	57/83 (68.7)	1.52 (0.71 to 3.24)	0.28	1.30 (0.56 to 3.00)	0.54
Excellent outcome ²	14/44 (31.8)	34/83 (41)	1.49 (0.69 to 3.21)	0.31	1.43 (0.64 to 3.20)	0.39
90-day mortality	2/44 (4.5)	6/83 (7.2)	1.43 (0.35 to 8.03) ³	0.65 ³	1.40 (0.32 to 8.29) ³	0.67 ³
Decompressive craniectomy	2/45 (4.4)	1/80 (1.3)	NA	NA	NA	NA
Hemorrhagic complications						
Any ICH	15/45 (33.3)	44/87 (50.6)	2.05 (0.97 to 4.33)	0.061	1.91 (0.87 to 4.20)	0.11
PH	2/47 (4.3)	8/87 (9.2)	1.95 (0.51 to 10.62) ³	0.37 ³	1.72 (0.44 to 9.53) ³	0.46 ³
slCH	1/45 (2.2)	6/87 (6.9)	2.37 (0.48 to 23.22) ³	0.36 ³	2.27 (0.45 to 22.43) ³	0.36 ³
24h NIHSS shift ⁵	-3.17 (-5.35 to -0.99)	-3.84 (-5.44 to -2.23)	-0.67 (-3.37 to 2.04)	0.63	0.99 (-1.63 to 3.62)	0.45
24h ASPECTS shift ⁵	-0.69 (-1.27 to -0.11)	-0.84 (-1.26 to -0.41)	-0.15 (-0.87 to 0.57)	0.68	-0.06 (-0.75 to 0.63)	0.35

Values are expressed in n (%) unless otherwise indicated. OR indicates odd ratio for carotid recanalization to be associated with each outcome obtained using logistic regression model. Adjusted model on nihss, aspect score at baseline and time between onset to puncture.

¹ Pre-specified primary outcome defined as a 90-day mRS score of 0 to 2, or equal to pre-stroke mRS score.

² Defined as a 90-day mRS score of 0 to 1, or equal to pre-stroke mRS score

³ p-values and OR (95%CI) calculated using penalized logistic regression model

⁵ Mean (95%CI) and differences (95%CI) were calculated using linear regression model. Abbreviations: ASPECTS=Alberta Stroke Program Early CT Score, CI=confidence intervals, ICH=intracerebral hemorrhage, IQR=interquartile range, NIHSS=National Institutes of Health Stroke Scale, PH=parenchymal hemorrhage, slCH=symptomatic intracerebral hemorrhage.

circle of Willis or particularly threatening intraluminal thrombus. Still, our study was based on a real-life observational registry. Consequently, the decision of ICA stenting was not standardized but based on individual case-by-case decision. It usually relied on multiple factors including circle of Willis patency, intracranial recanalization of the intracranial occlusion after mechanical thrombectomy, the degree of cervical ICA patency after ICA catheterization to perform intracranial thrombectomy, a threatening aspect of the cervical ICA during endovascular treatment (for example, detection of an intraluminal thrombus), infarct volume on baseline imaging and potential intracranial ICH on baseline imaging. Of course, we strongly believe that the specific subgroup of patients with non-functional circle of Willis should benefit from an “aggressive” treatment of cervical ICA to maintain a durable patency. Efforts must be made toward this important objective. However, our aim was here to investigate the influence of ICA patency in a global population of ICA dissection presenting with tandem occlusion. Among them, our results revealed that ICA patency might not have a significant influence on outcome and might not be systematically targeted.

Of course, the patency and efficacy of the circle of Willis undoubtedly plays an important role in patients with persisting occlusion or re-occlusion of the cervical ICA. Assessment of its functionality on baseline imaging and/or during the endovascular treatment is highly recommended at the time of treatment of a dissection related tandem occlusion. However, in our study, precise data on circle of Willis collaterals were not collected. This was a limitation of this work. However, this variable would have been a matter of debate given the absence of standardized definition of complete and sufficient circle of Willis, especially in the context of acute ischemic stroke (angiographic complete assessment through contralateral carotid and vertebral basilar runs? Assessment of noninvasive imaging? Mixed definitions?). Again, we strongly believe that efforts are needed to obtain cervical ICA recanalization in patients without efficient circle of Willis. However, the purpose of our study was to raise additional clinical data to question the importance of cervical ICA patency in this singular stroke presentation. In these patients, our results revealed that ICA patency might not have a significant influence on outcome and might not be systematically targeted.

Several limitations should be acknowledged. Given the infrequent nature of this pathology, our study sample was restricted limiting the statistical power of the analysis (we calculated that 860 patients would have been necessary to detect a difference in favorable outcome rate with a power of 80 and a two-sided type I-error of 0.05). Still, collecting large population of such specific occlusion topography

is challenging. We managed here to constitute a relatively large and unique multicenter cohort given the rarity of the disease. There are very few available studies investigating the impact of carotid patency at Day 1 on the functional outcome of dissection related tandem occlusions with even more limited study population²⁶. Still, despite non-significant, we cannot exclude that the trend toward an improved prognosis in the patent ICA group might be the reflect of a real benefit and a lack of statistical power of our study. Another limitation was the retrospective nature of the study introducing inherent bias and missing data, especially regarding missing Day-1 imaging. In addition, potential differences due the absence of formal standardization and guidelines in the endovascular approach of such tandem occlusions and in early antithrombotic management might have influenced the patency status of the cervical ICA. In particular, given the real-life retrospective nature of the registry, decision for emergent ICA stenting was at operator discretion, on a case-by-case basis. The absence of centralized imaging and angiographic analysis may also constitute a limitation. Finally, as discussed above, information regarding the functionality of the circle of Willis were not available.

CONCLUSION

Our results suggest that short-term carotid patency in tandem occlusion related to carotid dissection does not influence early neurological improvement or functional outcome at 3 months. These findings reinforce the hypothesis that emergent carotid stenting might not be systematic in dissection related tandem occlusions but reserved for selected cases. Still, the benefit of a durable ICA patency in this population might be marginal and we cannot exclude that the treatment of cervical occlusion might be beneficial for a subgroup of patients. Future dedicated studies and clinical trials are needed to identify the optimal therapeutic management of patients with tandem occlusions due to ICA dissection.

Ethics approval

This study involves human participants and was approved by Comité Consultatif sur le Traitement de l'Information en Matière de Recherche dans le Domaine de Santé 03776877. IDRCB: 2017-A03457-46. Participants gave informed consent to participate in the study before taking part.

Declaration of competing interest

The authors have no disclosure related to the present publication.

Supplementary materials

Supplementary material associated with this article can be found, in the online version, at doi:10.1016/j.neurad.2024.01.076.

REFERENCES

- Goyal M, Menon BK, van Zwam WH, Dippel DWJ, Mitchell PJ, Demchuk AM, Dávalos A, Majoie CBLM, van der Lugt A, de Miquel MA, et al. Endovascular thrombectomy after large-vessel ischaemic stroke: a meta-analysis of individual patient data from five randomised trials. *Lancet*. 2016;387:1723–1731.
- Zhu F, Hossu G, Soudant M, Richard S, Achit H, Beguinat M, Costalat V, Arquizan C, Consoli A, Lapergue B, et al. Effect of emergent carotid stenting during endovascular therapy for acute anterior circulation stroke patients with tandem occlusion: A multicenter, randomized, clinical trial (TITAN) protocol. *International Journal of Stroke*. 2021;16:342–348.
- Jacquin G, Poppe AY, Labrie M, Daneault N, Deschaintre Y, Gioia LC, Odier C, Raymond J, Roy D, Weill A, et al. Lack of Consensus Among Stroke Experts on the Optimal Management of Patients With Acute Tandem Occlusion. *Stroke*. 2019;50:1254–1256.
- Zhu F, Bracard S, Anxionnat R, Derelle A-L, Tonnelet R, Liao L, Mione G, Humbertjean L, Lacour J-C, Hossu G, et al. Impact of Emergent Cervical Carotid Stenting in Tandem Occlusion Strokes Treated by Thrombectomy: A Review of the TITAN Collaboration. *Front. Neurol.* 2019;10:206.
- Bricout N, Personnic T, Ferrigno M, Labreuche J, Estrade L, Bretzner M, Leclerc X, Cordonnier C, Boulouis G, Henon H. Day 1 Extracranial Internal Carotid Artery Patency Is Associated With Good Outcome After Mechanical Thrombectomy for Tandem Occlusion. *Stroke*. 2018;49:2520–2522.
- Pop R, Zinchenko I, Quenardelle V, Mihoc D, Manisor M, Richter JS, Severac F, Simu M, Chibbaro S, Rouyer O, et al. Predictors and Clinical Impact of Delayed Stent Thrombosis after Thrombectomy for Acute Stroke with Tandem Lesions. *AJNR Am J Neuroradiol*. 2019. ajnr;ajnr.A5976v1.
- Julien Allard, François Delvoe, Raoul Pop, Julien Labreuche, Benjamin Maier, Gaultier Marnat, Igor Sibon, François Zhu, Bertrand Lapergue, Arturo Consoli, et al. 24-Hour Carotid Stent Patency and Outcomes after Endovascular Therapy: A Multi-center Study. *Stroke*. Accepted.
- Anadani M, Marnat G, Consoli A, Papanagiotou P, Nogueira RG, Siddiqui A, Ribo M, Spiotta AM, Bourcier R, Kyheng M, et al. Endovascular Therapy of Anterior Circulation Tandem Occlusions: Pooled Analysis From the TITAN and ETIS Registries. *Stroke*. 2021;52:3097–3105.
- Marnat G, Bühlmann M, Eker OF, Gralla J, Machi P, Fischer U, Riquelme C, Arnold M, Bonafé A, Jung S, et al. Multicentric Experience in Distal-to-Proximal Revascularization of Tandem Occlusion Stroke Related to Internal Carotid Artery Dissection. *AJNR Am J Neuroradiol*. 2018;39:1093–1099.
- Ducroux C, Derex L, Nourredine M, Haesebaert J, Buisson M, Alesefir W, Boisseau W, Daneault N, Deschaintre Y, Diestro JDB, et al. Successful thrombectomy is beneficial in patients with pre-stroke disability: Results from an international multicenter cohort study. *J Neuroradiol*. 2023;50:59–64.
- Malka D, Janot K, Pasi M, Desilles J-P, Marnat G, Sibon I, Consoli A, Dargazanli C, Arquizan C, Gory B, et al. Effects of weather conditions on endovascular treatment case volume for patients with ischemic stroke. *J Neuroradiol*. 2023;50:593–599.
- Berge E, Whiteley W, Audebert H, De Marchis G, Fonseca AC, Padiglioni C, Pérez de la Ossa N, Strbian D, Tsvigoulis G, Turc G. European Stroke Organisation (ESO) guidelines on intravenous thrombolysis for acute ischaemic stroke. *European Stroke Journal*. 2021;6:1–LXII.
- Marnat G, Lapergue B, Sibon I, Gariel F, Bourcier R, Kyheng M, Labreuche J, Dargazanli C, Consoli A, Blanc R, et al. Safety and Outcome of Carotid Dissection Stenting During the Treatment of Tandem Occlusions: A Pooled Analysis of TITAN and ETIS. *Stroke*. 2020;51:3713–3718.
- Da Ros V, Pusceddu F, Lattanzi S, Scaggiante J, Sallustio F, Marrama F, Bandettini di Poggio M, Toscano G, Di Giuliano F, Rolla-Bigliani C, et al. Endovascular treatment of patients with acute ischemic stroke and tandem occlusion due to internal carotid artery dissection: A multicenter experience. *Neuroradiol J*. 2022. 197140092211086.
- Bonati LH, Jansen O, de Borst GJ, Brown MM. Management of atherosclerotic extracranial carotid artery stenosis. *The Lancet Neurology*. 2022;21:273–283.
- Antiplatelet treatment compared with anticoagulation treatment for cervical artery dissection (CADISS): a randomised trial. *The Lancet Neurology*. 2015;14:361–367.
- Lichy C, Metso A, Pezzini A, Leys D, Metso T, Lyrer P, Debette S, Thijs V, Abboud S, Kloss M, et al. Predictors of delayed stroke in patients with cervical artery dissection. *Int J Stroke*. 2015;10:360–363.
- Traenka C, Grond-Ginsbach C, Goeggel Simonetti B, Metso TM, Debette S, Pezzini A, Kloss M, Majersik JJ, Southerland AM, Leys D, et al. Artery occlusion independently predicts unfavorable outcome in cervical artery dissection. *Neurology*. 2020;94:e170–e180.
- Ifergan H, Reiner P, Simonato D, Polara GF, Mazighi M, Houdart E, Jouvent E, Labeyrie M-A. Early ischemic recurrence in acute spontaneous cervical artery dissection. *J Neuroradiol*. 2023;50:523–529.
- Karam A, Bricout N, Khyeng M, Cordonnier C, Leclerc X, Henon H, Casolla B. Safety and outcome of mechanical thrombectomy in ischaemic stroke related to carotid artery dissection. *J Neurol*. 2022;269:772–779.
- Pop R, Hasiu A, Mangin PH, Severac F, Mihoc D, Nistoran D, Manisor M, Simu M, Chibbaro S, Gheoca R, et al. Postprocedural Antiplatelet Treatment after Emergent Carotid Stenting in Tandem Lesions Stroke: Impact on Stent Patency beyond Day 1. *AJNR Am J Neuroradiol*. 2021;42:921–925.
- Yilmaz U, Körner H, Mühl-Benninghaus R, Simgen A, Kraus C, Walter S, Behnke S, Faßbender K, Reith W, Unger MM. Acute Occlusions of Dual-Layer Carotid Stents After Endovascular Emergency Treatment of Tandem Lesions. *Stroke*. 2017;48:2171–2175.
- Heck DV, Brown MD. Carotid stenting and intracranial thrombectomy for treatment of acute stroke due to tandem occlusions with aggressive antiplatelet therapy may be associated with a high incidence of intracranial hemorrhage. *J NeuroIntervent Surg*. 2015;7:170–175.
- Zhu F, Labreuche J, Haussen DC, Piotin M, Steglich-Arnholm H, Taschner C, Papanagiotou P, Lapergue B, Dorn F, Cognard C, et al. Hemorrhagic Transformation After Thrombectomy for Tandem Occlusions. *Stroke*. 2019;50:516–519.
- Marnat G, Mourand I, Eker O, Machi P, Arquizan C, Riquelme C, Aygnac X, Bonafé A, Costalat V. Endovascular Management of Tandem Occlusion Stroke Related to Internal Carotid Artery Dissection Using a Distal to Proximal Approach: Insight from the RECOSt Study. *AJNR Am J Neuroradiol*. 2016;37:1281–1288.
- Scopelliti G, Karam A, Labreuche J, Bricout N, Marrama F, Diomedes M, Ben Hassen W, Leclerc X, Cordonnier C, Henon H, et al. Internal carotid artery patency after mechanical thrombectomy for stroke due to occlusive dissection: Impact on outcome. *Eur Stroke J*. 2023;8:199–207.