



HAL
open science

Clinical and histopathological features of a chronic radiation-induced dermatitis in a dog and management with an ultra-hydrolysed collagen cream

Noëlle Cochet Faivre, Hélène Dropsy, Degorce Rubiales, Emanuele Monderna

► To cite this version:

Noëlle Cochet Faivre, Hélène Dropsy, Degorce Rubiales, Emanuele Monderna. Clinical and histopathological features of a chronic radiation-induced dermatitis in a dog and management with an ultra-hydrolysed collagen cream. *Veterinary Record Case Reports*, 2024, 10.1002/vrc2.989 . hal-04695205

HAL Id: hal-04695205

<https://hal.science/hal-04695205v1>

Submitted on 12 Sep 2024

HAL is a multi-disciplinary open access archive for the deposit and dissemination of scientific research documents, whether they are published or not. The documents may come from teaching and research institutions in France or abroad, or from public or private research centers.

L'archive ouverte pluridisciplinaire **HAL**, est destinée au dépôt et à la diffusion de documents scientifiques de niveau recherche, publiés ou non, émanant des établissements d'enseignement et de recherche français ou étrangers, des laboratoires publics ou privés.

CASE REPORT

Companion or pet animals

Clinical and histopathological features of a chronic radiation-induced dermatitis in a dog and management with an ultra-hydrolysed collagen cream

Noëlle Cochet Faivre^{1,2}  | H el ene Dropsy¹ | Fr ed erique Degorce Rubiales³ | Emanuele Monderna⁴¹Dermatology, Ecole Nationale V et erinaire d'Alfort, Maisons-Alfort, France²Laboratoire de Sant e Animale, Anses, INRAE, Ecole Nationale V et erinaire d'Alfort, BIPAR, Maisons-Alfort, France³Laboratoire d'Anatomie Pathologique V et erinaire, Toulouse, France⁴Monderna Health & Wellness Care, Bordeaux, France**Correspondence**No elle Cochet Faivre, Dermatology, Ecole Nationale V et erinaire d'Alfort, Maisons-Alfort, F-94700, France.
Email: noelle.cochet-faivre@vet-alfort.fr**Abstract**

In this report, we present a case of chronic radiation-induced dermatitis, controlled with an ultra-hydrolysed marine collagen cream. We also describe the clinical and histopathological features of chronic radiation dermatitis in a dog.

BACKGROUND

This article is of twofold interest. It describes for the first time, the clinical and histological aspects of chronic radiodermatitis (RD) in a dog and compares it with that described in humans. It also offers a treatment that has been shown to be effective, based on ultra-hydrolysed collagen, in a condition for which no treatment has been shown to be effective.

CASE PRESENTATION

Radiotherapy (RT) has become an indispensable part of oncologic treatment protocol for a range of malignancies. Skin reactions are one of the most common side effects of RT. In humans, it is estimated that over 85%–95% of patients develop moderate to severe skin reactions following RT.^{1,2} There are no data from large-scale veterinary studies, but a recent study shows 100% transient acute RD following post-operative definitive intent conformal radiation therapy for canine apocrine gland anal sac adenocarcinoma in 12 dogs.³ In this same study, nine dogs (75%) had grade 1 late skin toxicity consisting of hyperpigmentation/hypopigmentation of the skin, alopecia and leukotrichia according to the Veterinary Radiation Therapy Oncology Group grading scheme.⁴

The high-energy x-rays used in RT produce both direct and indirect ionisation events that not only damage cancer cells, but also pose a risk of injury to normal tissues in the path

of the treatment beams, such as the skin, particularly at the beam entrance. Radiation exerts its greatest impact on small fraction of rapidly proliferating cells as found in the basal layer, hair follicles and sebaceous glands, which are injured or destroyed.⁵ The radiation induces also vascular endothelium damage.⁶ The pathogenesis of chronic radiation dermatitis is thought to be caused by imbalance of proinflammatory cytokines (TNF- α , IL-6 and IL-1) leading to leukocyte infiltration and profibrotic cytokines like TGF- β and PDGF, which promote fibrosis by activating fibroblasts.⁶ The concomitant endothelium damage exacerbates the fibrosis and deteriorates healing process.

Radiation skin injury can be categorised as acute or late (i.e., chronic) injuries. Acute injury occurs within hours to weeks after radiation exposure, whereas late injury develops more than 90 days after the completion of radiation treatment.⁷ While the acute side effects of irradiation typically resolve within 2–4 weeks of RT completion, chronic RD is usually an irreversible and progressive condition in humans.^{2,8}

Herein, we describe epidermal and dermal repair after application of an amino acid-enriched cream in a chronic RD in a dog. In addition, we describe clinical and histopathological features in the lesional skin of canine chronic RD.

A 5-year-old, entire, male, atopic, water rescue golden retriever was referred for a focal inflammatory dermatitis that started 3 months after its last RT session and did not respond to twice-daily application of glycerin, niacinamide and shea butter-based cream (Lipikar La Roche-Posay France). RT was

This is an open access article under the terms of the [Creative Commons Attribution-NonCommercial-NoDerivs](https://creativecommons.org/licenses/by-nc-nd/4.0/) License, which permits use and distribution in any medium, provided the original work is properly cited, the use is non-commercial and no modifications or adaptations are made.

  2024 The Author(s). *Veterinary Record Case Reports* published by John Wiley & Sons Ltd on behalf of British Veterinary Association.

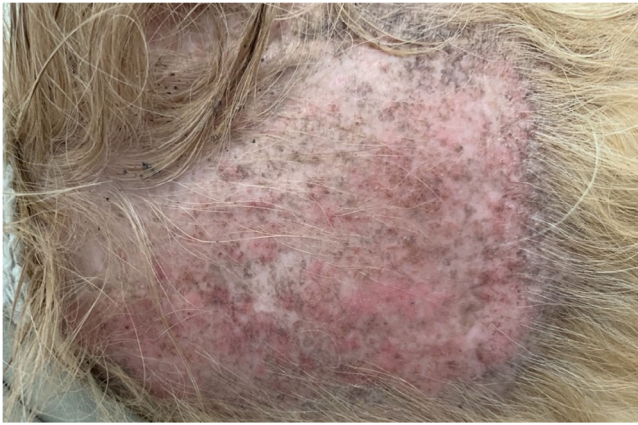

FIGURE 1 Painful flare-up of radiodermatitis: marked erythema and thickness of the skin.

initiated on the site of a surgical skin flap in the dorsal region following removal of a liposarcoma. The protocol used was 12 sessions, three per week at a dose of 3 Gy each for a total of 36 Gy, using 9 MeV electrons with a 0.7 cm bolus on a 15 × 15 cm field. In the medical history, the onset of an acute radiation dermatitis with oedema, ulceration estimated at grade 3 (according to the VRTOG acute radiation morbidity scoring scheme) was reported 1 day after the last RT session.⁴ Complete healing of the acute RD was observed 3 weeks after treatment with colloid dressings and systemic antibiotherapy.

On physical examination upon referral, the dog had no abnormalities other than dermatological. In the dorsolumbar region, the skin is thickened, warm, erythematous and hyperpigmented over an area of 15 × 15 cm. Comedones and furunculosis were observed.

Cytological examination of furuncles showed the presence of inflammatory cells without evidence of bacteria.

The history and clinical signs led to the diagnosis of chronic RD. A twice-daily ointment composed of paraffinum liquidum, cera microcristallina, ceresin, lanolin alcohol, panthenol, glycerine and bisabolol (Aquaphor, Eucerin) was prescribed, as well as sun protection with a ultraviolet protective suit. A few weeks after this prescription, a marked improvement in the animal's comfort and skin appearance was reported, with partial hair regrowth in the periphery. However, the dog was seen again a year later as the owner reported painful inflammatory flare-ups occurring every 8–12 weeks. (Figure 1). Marked erythema, persistent alopecia, focal hyperpigmentation and skin thickness were observed.

INVESTIGATIONS

Skin biopsy, performed 14 months after the last RT session, featured a chronic progressive superficial fibrosing paucicellular interface dermatitis. The epidermis was the site of irregular acanthosis of moderate intensity. The follicular infundibulum was also involved. The very superficial dermis up to the epidermis was oedematous and showed ectasia of the capillary blood vessels, some lesions of erythrocyte extravasation, a polymorphic lymphoplasmacytic and mastocytic perivascular inflammatory infiltrate and the presence of myofibroblasts with nuclei, sometimes enlarged, but without clear cytonuclear atypia (Figure 2a–c).

LEARNING POINTS/TAKE-HOME MESSAGES

- The chronic radiodermatitis described in this dog has similar epidemiological, clinical and histopathological features to those described in humans.
- Histopathological examination reveals epidermal acanthosis, dermal fibrosis, superficial oedema, mixed perivascular inflammation, myofibroblasts and vascular ectasia.
- Ultra-hydrolysed collagen is well tolerated, and may help in the management of chronic radiodermatitis.

Histological appearance was consistent with radiation-induced skin lesions.

TREATMENT

A twice-daily application of collagen, cardiospermum halicabum flower/leaf/vine extract, and punica granatum seed oil-based cream (Dermoioniq Crème Brevet, Monderna Health and Wellness) was prescribed.

OUTCOME AND FOLLOW-UP

One month later, while the cream was still applied twice a day, a dramatic improvement was reported by the owner (Figure 3), which was confirmed by a skin biopsy. The epidermis was hyperplastic, but the irregular acanthosis was more discrete than before. There was still discrete lymphocytic exocytosis without atypia. There was no spongiosis in the epidermis nor oedema in the dermis. There was still a perivascular inflammatory infiltrate of discrete to moderate intensity, but much reduced, consisting of a few mast cells, plasma cells and lymphocytes. Myofibroblast hyperplasia was discrete. The collagen fibres of the very superficial dermis appeared to be horizontal rather than vertical or separated by oedema. Anagen hair bulbs were still absent (Figure 4a–c).

Sixteen months after the first application of Dermoioniq cream, no new inflammatory and painful flare-ups have been reported. Sun protection and once-daily Dermoioniq cream application is continued.

DISCUSSION

The occurrence of chronic post-irradiation reaction may develop suddenly and with various severities. In humans, there is no association between having had acute RD and the risk of later developing chronic RD.² In this case, therefore, it cannot be concluded that grade 3 RD was a triggering factor for the subsequent lesions. Skin changes result from a combination of RT features (total irradiated volume, total dose, altered fractionation, RT technique, postoperative RT, use of bolus) and intrinsic patient risk factors (concurrent treatment), connective tissue disorders (such as lupus

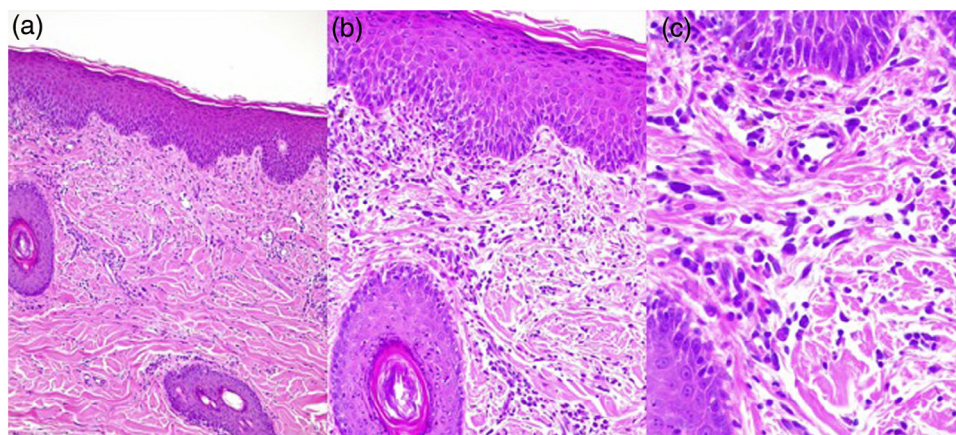


FIGURE 2 Histopathology (before treatment with Dermoioniq cream during a flare-up of radiodermatitis) showing irregular acanthosis, interfacial dermatitis with lymphocytic exocytosis, spongiosis and discrete hydropic vesicular lesions, oedematous superficial dermis, polymorphic perivascular infiltrate, fibrosis. (a) $\times 10$, (b) $\times 20$, (c) $\times 40$. All haematoxylin and eosin.

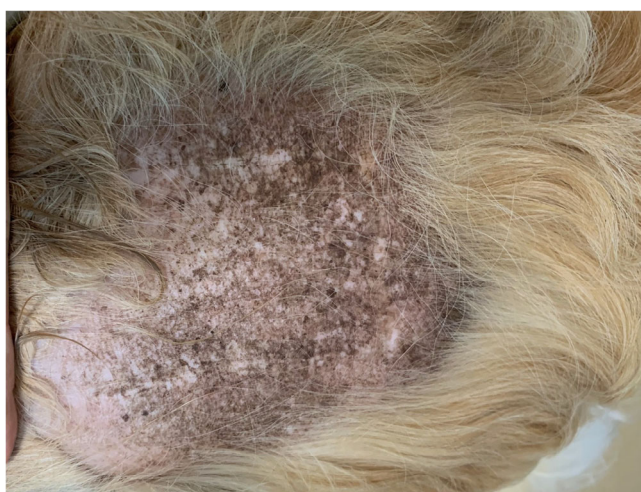

FIGURE 3 Reduced erythema and skin thickness.

erythematosus), skin disorders (such as atopic dermatitis), genetic factors like DNA repair deficiency and personal factors like age, chronic sun exposure, and so forth.^{6,8,9} This dog had several intrinsic risk factors, including the target of the RT just below the skin graft and being an atopic dog. The influence of previous sun exposure of the graft cannot be excluded as it was a water rescue dog.

In humans, the most complicating factor of radiation burns is the unpredictable successive inflammatory waves occurring weeks to years after radiation exposure.⁹ In this dog, painful, inflammatory waves are described every 8–12 weeks by the owner.

Clinical manifestations of chronic RD in human include dyspigmentation, epidermal thinning, dermal atrophy or epidermal and dermal thickening, alopecia, telangiectasia, skin infection, ulceration and chronic wounds. Radiotherapy-induced fibrosis (RIF) is the 'hallmark' of chronic RT damage. RIF may lead to cosmetic and functional defects, which can deteriorate patients' quality of life.

Histological features in humans include an epidermal hyperkeratosis, focal parakeratosis and hyperplasia. There may be spongiosis or basal liquefactive degeneration. Cytological atypia and dyskeratosis may be present. In the dermis, myofibroblasts and perivascular inflammatory infiltrates

around ectatic blood vessels with oedematous endothelial cells are visible. Dense fibrosis and elastosis in dermis and loss of appendages, particularly hair follicles, are observed.¹⁰

Clinically, dyspigmentation, epidermal and dermal thickening and alopecia are seen in this dog. Histologically there is irregular acanthosis, interface dermatitis with spongiosis, fibrosis, myofibroblasts, vascular ectasia and perivascular inflammatory infiltrate, and loss of hair follicles. Human and canine chronic RD appear to share clinical and histopathological features.

Diagnosis of chronic radiation dermatitis is usually based on anamnesis, time of onset of lesions, and clinical examination. In cases of unclear clinical manifestations, a biopsy and histopathological examination are recommended in humans. In this case, the presumptive diagnosis was chronic RD because of anamnesis, time of onset and clinical features, but the recurrent inflammatory pain flares not described in the veterinary literature, led to histopathological examination that confirmed the diagnosis.

In human medicine, there are no established therapies for the treatment of RD. In the Delphi survey for consensus on the clinical management of chronic RD and radiation fibrosis (CRDF), strong consensus was achieved on the recommendation of sunscreen to protect the skin from ultraviolet-induced radiation changes, vascular laser as first-line treatment for vascular changes, and the use of fractional ablative laser therapy for skin contractures and fibrosis or induration. Moderate consensus was achieved concerning the use of topical and/or intralesional corticosteroids and oral pentoxifylline in the management of chronic CRDF.¹¹

In veterinary medicine, the bibliography describes current management practices for acute RD, but not for chronic RD.^{3,5} In this case, sunscreen, Aquaphor and massage were not sufficient.

Collagen is a molecule that is well tolerated by the skin in biomedical and cosmetic applications. The native protein is approximately 300 kDa and has moisturising properties; hydrolysed collagen (HC) has antioxidant properties by scavenging free radicals and also promotes cell proliferation and collagen secretion in fibroblast cells.^{12,13} The prescribed Dermoioniq cream is produced from marine collagen. This product is characterised by the presence of a high

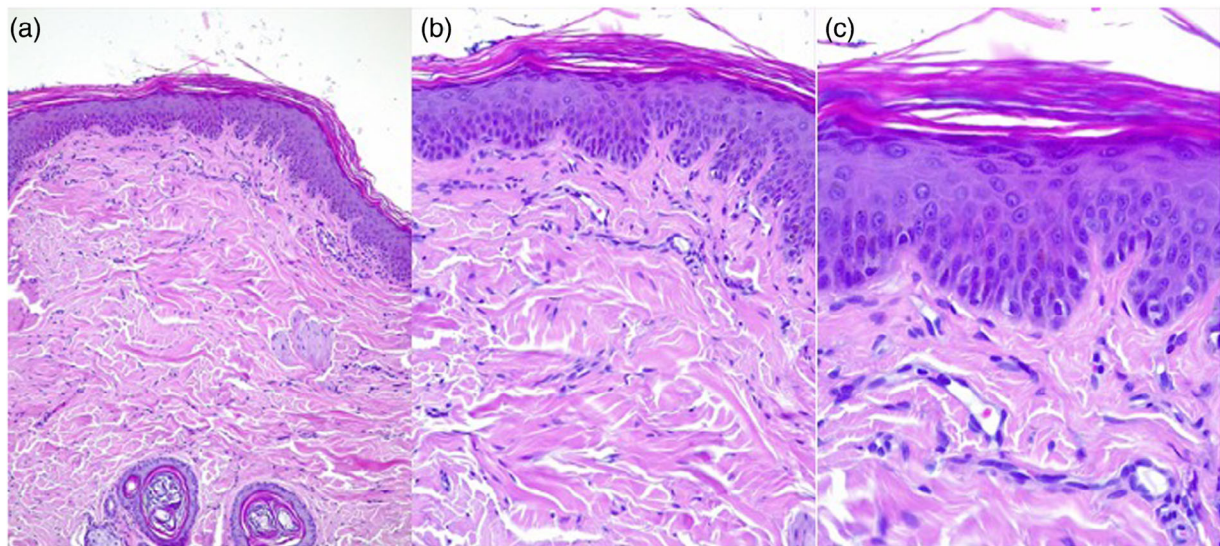


FIGURE 4 Histopathology (after 1 month of treatment with Dermoioniq cream) showing more discrete and regular acanthosis, dermis without oedema, and superficial collagen fibres appear to be horizontal again.

proportion of low molecular weight HC (<0.5 kDa), which allows good transepidermal penetration (laboratory data). This product has demonstrated on human explant healing properties, mainly by favouring both the proliferation and migration of basal cell buds and neocollagenogenesis (laboratory data).

Within 1 month, the owner noticed a marked improvement in skin texture and a reduction in erythema. Histopathological examination confirmed this impression with a reduction in inflammatory infiltration, myofibroblasts, oedema, epidermal acanthosis and a harmonious reorganisation of collagen fibres. This effect was maintained with no relapses reported 16 months after the start of the treatment. The apparent efficacy of Dermoioniq cream, in this case of RD, could be linked to its high content of hydrolysed collagen, which has antioxidant properties and the ability to increase the synthesis of collagen fibres, elastin and hyaluronic acid by fibroblasts.^{12,13} This may help to reduce the presence of inflammatory cells and myofibroblasts responsible for RIF lesions, as observed in control histopathological examination.

To the best of the authors' knowledge, this is the first description of an effective treatment for chronic RD in dogs. Dermoioniq cream seems to be an interesting option that needs to be confirmed with more cases. This case also highlights that human and canine chronic RD appear to share clinical and histopathological features.

AUTHOR CONTRIBUTIONS

Noëlle Cochet Faivre: supervision; project administration; writing—review and editing; visualisation; methodology; validation; writing—original draft; investigation; conceptualisation. **Hélène Dropsy:** investigation; writing—review and editing; methodology; validation; visualisation. **Frédérique Degorce Rubiales:** investigation; writing—review and editing; validation; visualisation. **Emanuele Monderna:** conceptualisation; writing—review and editing; validation; visualisation.

ACKNOWLEDGEMENTS

We thank the owner for his confidence.

CONFLICT OF INTEREST STATEMENT

Noëlle Cochet Faivre, Hélène Dropsy, Frédérique Degorce Rubiales: none declared. Emanuele Monderna: head of MHW Care.


FUNDING INFORMATION

This study was self-funded.

ETHICS STATEMENT

The authors confirm that the ethical policies of the journal, as noted on the journal's author guidelines page, have been adhered to.

ORCID

Noëlle Cochet Faivre  <https://orcid.org/0000-0002-1820-0006>

REFERENCES

1. Yang X, Ren H, Guo X, Hu C, Fu J. Radiation-induced skin injury: pathogenesis, treatment, and management. *Aging*. 2020;12(22):23379.
2. Borrelli MR, Shen AH, Lee GK, Momeni A, Longaker MT, Wan DC. Radiation-induced skin fibrosis: pathogenesis, current treatment options, and emerging therapeutics. *Ann Plast Surg*. 2019;83(4S):S59–S64.
3. Williams C, Parys M, Handel I, Serra JC, Lawrence J. Minimal late radiation toxicity and transient early toxicity following postoperative definitive intent conformal radiation therapy (20 × 2.5 Gy) for canine apocrine gland anal sac adenocarcinoma. *Vet Radiol Ultrasound*. 2022;63(2):224–33.
4. Ladue T, Klein MK. Toxicity criteria of the veterinary radiation therapy oncology group. *Vet Radiol Ultrasound*. 2001;42(5):475–76.
5. Collen EB, Mayer MN. Acute effects of radiation treatment: Skin reactions. *Can Vet J*. 2006;47(9):931–35.
6. Spalek M. Chronic radiation-induced dermatitis: challenges and solutions. *Clin Cosmet Investig Dermatol*. 2016;9:473–82.
7. Hegedus F, Mathew LM, Schwartz RA. Radiation dermatitis: an overview. *Int J Dermatol*. 2017;56:909–17.
8. Leventhal J, Young MR. Radiation dermatitis: recognition, prevention, and management. *Oncology*. 2017;31(12):885–87, 894–899.
9. Ryan JL. Ionizing radiation: the good, the bad, and the ugly. *J Invest Dermatol*. 2012;132(3):985–93.
10. Calonje E, Brenn T, Lazar AJ, MacKee PH, Billings SD, editors. *McKee's pathology of the skin: with clinical correlations*. 5th ed. Philadelphia, PA: Elsevier; 2020.

11. Wilson BN, Shah R, Menzer C, Aleisa A, Sun MD, Kwong BY, et al. Consensus on the clinical management of chronic radiation dermatitis and radiation fibrosis: a Delphi survey. *Br J Dermatol.* 2022;187(6):1054–56.
12. Aguirre-Cruz G, León-López A, Cruz-Gómez V, Jiménez-Alvarado R, Aguirre-Álvarez G. Collagen hydrolysates for skin protection: oral administration and topical formulation. *Antioxidants.* 2020;9(2):181.
13. León-López A, Morales-Peñaloza A, Martínez-Juárez VM, Vargas-Torres A, Zeugolis DI, Aguirre-Álvarez G. Hydrolyzed collagen—sources and applications. *Molecules.* 2019;24(22):4031.

How to cite this article: Cochet Faivre N, Dropsy H, Degorce Rubiales F, Monderna E. Clinical and histopathological features of a chronic radiation-induced dermatitis in a dog and management with an ultra-hydrolysed collagen cream. *Vet Rec Case Rep.* 2024;e989. <https://doi.org/10.1002/vrc2.989>

MULTIPLE-CHOICE QUESTION

What is the clinical or histopathological manifestation that is considered to be the hallmark of chronic radiation dermatitis?

POSSIBLE ANSWERS TO MULTIPLE-CHOICE QUESTION

1. Erythema occurring a few days or weeks after RT
2. Recurrent painful flare-ups after RT
3. Fibrosis
4. Alopecia, hyperpigmentation

CORRECT ANSWER

3. Fibrosis.

Radiotherapy induced fibrosis is the 'hallmark' of chronic RT damage by activation of the fibroblasts