



**HAL**  
open science

# Heterotopic ovarian transplantation instead hormonal replacement therapy after radical hysterectomy for cervical cancer: case report and review of literature

Blandine Courbiere, Laura Miquel, Pauline Bottin, Magali Provansal,  
Jacqueline Saias-Magnan, Catherine Metzler-Guillemain

## ► To cite this version:

Blandine Courbiere, Laura Miquel, Pauline Bottin, Magali Provansal, Jacqueline Saias-Magnan, et al.. Heterotopic ovarian transplantation instead hormonal replacement therapy after radical hysterectomy for cervical cancer: case report and review of literature. *Journal of Assisted Reproduction and Genetics*, 2024, 41 (9), pp.2515-2520. 10.1007/s10815-024-03196-5 . hal-04690503

**HAL Id: hal-04690503**

**<https://hal.science/hal-04690503v1>**

Submitted on 21 Jan 2025

**HAL** is a multi-disciplinary open access archive for the deposit and dissemination of scientific research documents, whether they are published or not. The documents may come from teaching and research institutions in France or abroad, or from public or private research centers.

L'archive ouverte pluridisciplinaire **HAL**, est destinée au dépôt et à la diffusion de documents scientifiques de niveau recherche, publiés ou non, émanant des établissements d'enseignement et de recherche français ou étrangers, des laboratoires publics ou privés.

# Heterotopic ovarian transplantation instead hormonal replacement therapy after radical hysterectomy for cervical cancer: case report and review of literature

Blandine Courbiere<sup>1,2,5</sup>  · Laura Miquel<sup>1</sup> · Pauline Bottin<sup>1</sup> · Magali Provansal<sup>3</sup> · Jacqueline Saias-Magnan<sup>1</sup> · Catherine Metzler-Guillemain<sup>1,4</sup>

## Abstract

**Purpose** Only a few case reports have described heterotopic ovarian tissue transplantation (OTT) with the only objective of restoring ovarian function.

**Methods** Case report and review of the literature for reporting cases of heterotopic OTT with the only aim of restoring ovarian endocrine function. In a cancer survivor woman with a history of hysterectomy and bilateral oophorectomy for cervical cancer and because she poorly tolerated hormone replacement therapy (HRT), we performed a heterotopic OTT in a pelvic subcutaneous “pocket” after an OT cryostorage of 17 years.

**Results** A cyclic ovarian endocrine function started 3 months after OTT with an immediate patient self-described improvement of her quality of life. A second OTT was performed 19 months after, due to hot flushes recurrence and FSH increase. Despite a cyclic endocrine function, progesterone levels have always been low, resulting in a relative hyperoestrogenism state.

**Conclusion** In the future, the indications of heterotopic OTT could be spread in alternative to HRT. However, our data suggest that the heterotopic graft environment is less favorable to corpus luteum development, and further studies are needed to assay the best site of heterotopic graft, the optimal number of ovarian cortex fragments to graft, and the potential risk of relapse in case of malignant residual disease.

**Keywords** Cancer · Ovarian cryopreservation · Heterotopic transplantation · Endocrine function

## Introduction

Ovarian tissue cryopreservation belongs to the recommended strategy for preserving fertility before any treatment that could significantly impair fertility in age reproductive women [1]. Orthotopic transplantation of cryopreserved-thawed ovarian tissue is a promising technique for restoring both fertility and ovarian endocrine function in women who experienced premature ovarian insufficiency after undergoing gonadotoxic treatment. The first live birth after ovarian tissue transplantation (OTT) was reported in 2004 [2], and since then, following the births of several hundred children, OTT can be considered as a therapeutic technique for fertility restoration [3]. However, to date, only few case reports have described heterotopic OTT in the only objective to restore ovarian function [4–7]. We report an informative case of restoration of ovarian endocrine function after heterotopic OTT in a woman treated with radical hysterectomy and bilateral oophorectomy for a cervical cancer.

<sup>1</sup> Department of Gynecology-Obstetric and Reproductive Medicine - CECOS, AP-HM, Hôpital La Conception, Marseille, France

<sup>2</sup> IMBE, Aix-Marseille Univ, CNRS, IRD, Avignon Univ, Marseille, France

<sup>3</sup> Department of Medical Oncology, Institut Paoli Calmettes, Marseille, France

<sup>4</sup> INSERM, MMG, Aix Marseille Univ, Marseille, France

<sup>5</sup> Department of Gynecology - Obstetric and Reproductive Medicine, 147 bd Baille, Marseille 13005, France

## Case report

In 2003, a 24-year-old woman was diagnosed a cervical adenocarcinoma T1B1 with N+. Despite a medical indication of radical hysterectomy with bilateral oophorectomy followed by a pelvic (40 Gy) and lombo-aortic irradiation (50 Gy), she asked for ovarian tissue cryopreservation with the argument hoping research advances in reproductive medicine in the future. A total of 36 ovarian fragments were cryopreserved with a slow freezing protocol. The PET scan at the time of ovarian tissue freezing showed no ovarian metastatic diseases. Anatomopathological assay of the entire ovarian medulla and of a fragment of ovarian cortex per ovary did not observe malignant residual disease (MRD) nor vascular embol. The primordial follicle density was 65 per 10 champs (X 400).

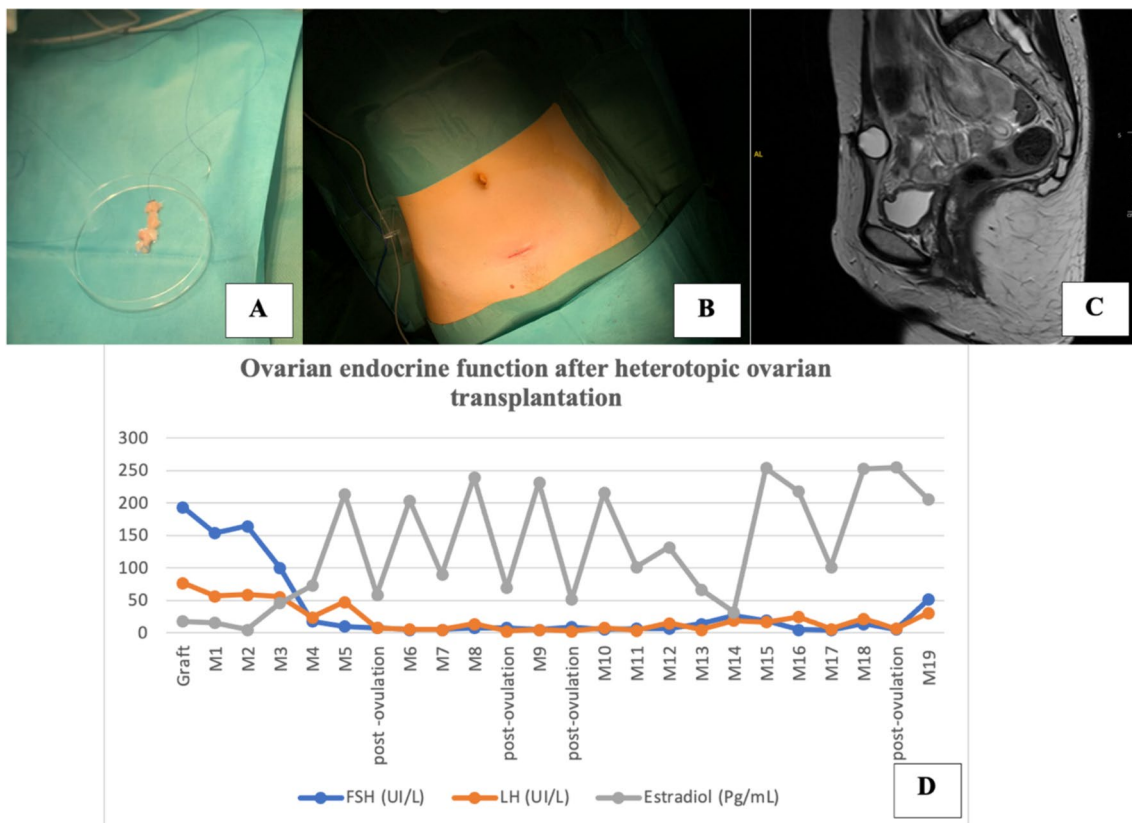
In 2021, at 41 years, her quality of life was deeply impaired because no one hormone replacement therapy (HRT) was tolerated. All formulations and dosages of 17-B-estradiol were attempted, and each time, she developed melasma. Because the patient stopped HRT, she presented permanent asthenia, disabling hot flushes

and osteopenia. After a storage of 17 years, the patient asked for returning the cryopreserved ovarian tissue. The intervention indication was discussed and approved by an oncologist board. The patient has been informed that we could not exclude totally the possibility of MRD with risk of local relapse. Pre-autograft hormonal blood test showed the following: FSH = 194 UI/L, LH = 77 UI/L, estradiol = 18 pg/mL, AMH = 0.03 µg/mL.

Heterotopic ovarian autograft was performed in June 2021: 10 ovarian tissue fragments about 0.5 cm<sup>2</sup> were thawed and ovarian tissue fragments were threaded onto a 3/0 PDS and were fixed through a small incision above pubis in a pocket between rectus sheath and the rectus muscle (Fig. 1a, b). Patient underwent blood sampling for serum FSH, LH, estradiol, and progesterone assays every month until restoration ovarian function.

FSH level decreased below 25 UI/L 3 months after the graft and in December 2021 (i.e., 6 months after OTT), FSH was 5 UI/L, LH = 5.8 UI/L, E2 = 204 pg/mL, and AMH = 0.43 µg/mL.

Patient was followed weekly by hormonal tests and monthly by abdominal sonography. During an ovulation



**Fig. 1** Heterotopic transplantation of pieces of ovarian cortex (A) through a small incision above pubis in a pocket between rectus sheath and the rectus muscle (B). MRI showing a pre-ovulatory fol-

licle (C) and blood tests showing restoration of a cyclic ovarian endocrine function three months after graft (D)

period, MRI scan was performed to control the localization of graft and showed a dominant follicle (Fig. 1c). The patient was able to recognize ovulation by a subcutaneous “arch”. Figure 1 shows her hormonal profile with a cyclic FSH and LH surge about every 30 days with a mean estrogen level of  $131.5 \pm 89.6$  pg/mL. Despite an apparent preserved follicular phase with recruitment of a dominant follicle, luteal phase was impaired with a Pg level always  $< 0.5$  ng/mL and a maximum post-ovulatory Pg level at 1.98 ng/mL. This patient felt that her quality of life significantly improved with disappearance of hot flushes and a better physical and emotional well-being. She also noticed an increase of her breast volume with a cyclical breast tension. Two bone density scans were conducted at the same department in July 2020 and in October 2022, which were performed respectively 15 months before and 12 months after the restoration of endocrine function. The *T*-scores were respectively  $-1.5$  SD for lumbar spine and  $-1.8$  SD for the femoral neck before the graft, and they respectively changed to  $-1.1$  SD and  $-1.5$  SD post-graft.

In 2023 May, at 19 months after OTT, due to recurrence of hot flushes and an impairment of ovarian endocrine function with a FSH increase, we decided to perform a second heterotopic graft of eight pieces near the first site. FSH returned at 8.3 UI/L UI/L after 3 months with two mature follicles of 19 mm and 15 mm.

The patient gave a written consent to publication and for the retrospective analysis of their medical data. In France, the law authorizes ovarian autograft to restore endocrine function up to the age of 50.

## Discussion

We report an interesting case of a physiologic endocrine ovarian function returning with restoration of quality of life thanks to a heterotopic OTT performed only in this objective. Table 1 resumes the only four reported heterotopic transplantation case reports of frozen-thawed ovarian tissue performed with the only aim to restore endocrine ovarian function. In 2001, Callejo et al. described a case of heterotopic OTT of cryopreserved OT in a woman volunteer for research [4]. Her ovarian tissue was cryopreserved at 47 that does not provide the best model to assay restoration of an ovarian endocrine function. In 2004, Kim et al. was the first to report in woman treated by hysterectomy for cervical cancer the restoration of ovarian function after heterotopic OTT in two sites: between the rectus sheath and the rectus muscle, and between breast tissue and the superficial fascia of the pectoralis muscle [5]. Ovarian function was restored only at the abdominal site, as evidenced by the visualization of a growing follicle. However, the ovarian tissue had been frozen at 37 years, and the return of ovarian function was defined by a decrease in FSH and disappearance of hot

flushes. The lowest FSH was 39 IU/L, which cannot be considered as a “normal” ovarian function.

Twenty years later after Kim et al., at our knowledge, we describe only the second case of heterotopic OTT after cancer as an alternative to hormone replacement therapy. In our case, FSH returned to a low and “normal” level (5 IU/L) with a cyclic ovarian function. In 2012, Poirot et al. reported a puberty induction in a 13 year-old girl who presented a premature ovarian insufficiency (POI) after hematopoietic stem cell transplantation for sickle cell disease PMID [6]. After ovarian heterotopic OTT, she presented a “normal” pubertal development with regular menstruations for 2 years.

The indications for heterotopic OTT could be extended in the future to avoid the need for HRT. Recently, Oktay and Marin performed an emergency fresh heterotopic OTT to the forearm solely for endocrine function restoration immediately after an incidental oophorectomy of an single ovary [7]. In our experience, a single heterotopic OTT could restore a physiological ovarian hormonal function for 19 months. In the meta-analysis of Khattak et al., the median duration of the graft function after orthotopic transplantation of frozen-thawed ovarian tissue was 2.5 years with a range of 0.7–5 years [8]. In the experience of Oktay et al., ovarian function after heterotopic OTC was restored more than 40 months [9].

Kim et al. reported also a patient with a long-term endocrine function during 7 years after two consecutive heterotopic OTT performed at 1-year intervals [10].

Our present case provides several lessons about heterotopic OTT. First, ovarian tissue remained perfectly functional after 17 years of cryostorage. In 2002, when the ovarian tissue was frozen for this woman, the outcome after thawing was completely unknown; live-birth after autograft was described only in animals [11]. Freezing ovarian tissue was a kind of gamble on the future. The first lesson is that even in case of a medical indication of hysterectomy, even in case for whom fertility outcome is uncertain, oncologist should refer women for OTC. Indications for bilateral oophorectomy are rare, but we believe that indications for heterotopic OTT for restoring endocrine function are susceptible to grow in the future. So, in 2003, when we froze this woman’s ovarian tissue, we were convinced it was only for psychological purposes for her and that we would never be able to reuse it. The subsequent events, nearly 20 years later, showed us we were wrong. On the other hand, if women who have undergone OTC no longer have any plans for parenthood, grafting can be discussed as an alternative to HRT. In our department, requests for grafting for this indication are starting to increase among women who want “natural” hormones, and the surgical heterotopic graft is much simpler than a laparoscopy. Female fertility preservation is a recent discipline, and the possibility of restoring endocrine function through heterotopic OTT could lead to new demands.

**Table 1** Review of heterotopic transplantation case reports of frozen-thawed ovarian tissue performed in the only aim to restore endocrine ovarian function

	Pathology	Age at cryostorage (years)	Age at OTT	Site of graft	FSH pre-OTT	Return ovarian function	Lowest FSH post-OTT	Highest Progesterone after ovulation (ng/mL)	Duration of endocrine function
Callejo et al. (2001)	Hysterectomy for uterine leiomyomas with bilateral salpingo-oophorectomy Patient volunteer for research	47	47	Muscle pocket in abdominal wall	80	120 days = 4 months	Between 20 and 30 UI/L	2.2	270 days = 9 months
Kim et al. (2004)	Cervical cancer Ib	37	After the completion of treatment (> 37 ans)	Two sites: -Between rectus sheath and rectus muscle -Between breast tissue and superficial fascia of the pectoralis muscle	87–100 UI/L	14 weeks = 3.5 months	39 IU/l	9.6	28 weeks = 7 months
Poirot et al., 2012	Hematopoietic stem cell transplantation for sickle cell disease	10	13	Subcutaneous tissue of the abdominal wall	89 U	2 months	< 10 UI/L	No data	2 years = 24 months
Case	Cervical adenocarcinoma T1B1	24	41	Pocket between rectus sheath and the rectus muscle	194 IU/L	3 months	5 UI/L	1.98	19 months

We have no data on the ideal number of fragments to graft in the heterotopic site to optimize their usage relative to graft longevity. With 10 fragments, the graft lasted 19 months, but only one mature follicle was recruited per month. Thus, we hypothesize a paracrine regulation between the ovarian fragments, which could explain why there were no multiple recruited follicles. Therefore, for the second graft in May 2023, we only grafted eight fragments (with endocrine function still active in May 2024), but perhaps grafting even fewer could be sufficient for a 2-year endocrine function. In Poirot et al.'s experience, grafting three fragments also allowed for a 2-year endocrine function.

Then, we hypothesize that HRT does not provide the same hormonal impregnation nor the same biological effect than endogenous ovarian estrogens. Indeed, the study of Ablove et al. conducted on sheep observed different effects of endogenous ovarian estrogen Vs exogenous estrogen replacement on the  $\beta$  estrogen receptors [12]. Despite that the improvement of quality of life described by our patient was subjective, we noticed an improvement of her well-being without side-effects after a lack of tolerance and observance of numerous HRT tried for 15 years. There is likely a psychological effect of well-being induced by this graft compared to the poor tolerance of the different HRT she tried. It may also be worth considering that women prefer being grafted with "their own ovarian tissue" rather than administering HRT daily. However, the disappearance of climacteric syndrome 3 months after OTT was in accordance with the increase of estradiol levels. Moreover, and surprisingly, she did not develop melasma in post-graft. Despite she still presents with osteopenia, and even a slight improvement in *T*-score, heterotopic grafting performs as well, if not better, for bone mass compared to HRT.

There are no data on the quality of the luteal phase after heterotopic OTT. Our data suggest that the heterotopic graft environment is less favorable to corpus luteum development. Progesterone levels remained always low, resulting in a relative hyperoestrogenism state. As this patient had no uterus, low progesterone levels, probably due to poor corpus luteum quality in the heterotopic position, had no clinical translation. In the case of heterotopic OTC for endocrine replacement purposes, adding progesterone would be probably necessary if the patient still has a uterus.

The risk of relapse after the transplantation of ovarian tissue potentially contaminated with microscopic undiagnosed malignant residual disease (MRD) must always be discussed. This risk must be seriously considered in certain pathologies such as acute leukemia [13]. In our case of cervical cancer, the oncologists considered the risk of MRD to be low [14], and even more so as the heterotopic site circumscribed the ovarian tissue in an easily accessible and surgically resectable area. However, the number of heterotopic OTT cases after cancer and the follow-up period

are too short to be able to guarantee the absence of risk of relapse after heterotopic OTT.

## Conclusions

In case of medical indication of radical hysterectomy with bilateral oophorectomy, gynecological surgeons should be aware about the possibility of cryopreserving OT, because heterotopic OTT can be performed for only restoring ovarian endocrine function. However, further studies are needed to assay the best site of heterotopic graft (forearm, subcutaneous abdominal localization, other site?), the optimal number of ovarian cortex fragments to graft, and the potential risk of MRD. In the future, the indications of heterotopic OTT could be widespread as an alternative to HRT.

**Author contribution** BC and CMG accompanied the patient throughout her entire medical journey, coordinating with heterotopic OTT. MP played a pivotal role as the oncology reference. BC, PB, and LM conducted experiments, and BC authored the manuscript. All authors reviewed and approved the final manuscript.

**Data availability** Data will be made available to the editors of the journal for review or query upon request.

## Declarations

**Ethical approval** No ethical approval needed, because in our country, the law authorizes ovarian autograft to restore endocrine function up to the age of 50.

**Consent for publication** The patient gave a written consent for publication and for the retrospective analyses of their medical data.

**Competing interests** The authors declare no competing interests.

## References

1. ESHRE Guideline Group on Female Fertility Preservation, Anderson RA, Amant F, Braat D, D'Angelo A, Chuva de Sousa Lopes SM, et al. ESHRE guideline: female fertility preservation. *Hum Reprod Open*. 2020;2020:hoaa052. <https://doi.org/10.1093/hropen/hoaa052>.
2. Donnez J, Dolmans MM, Demylle D, Jadoul P, Pirard C, Squifflet J, et al. Livebirth after orthotopic transplantation of cryopreserved ovarian tissue. *Lancet*. 2004;364:1405–10. [https://doi.org/10.1016/S0140-6736\(04\)17222-X](https://doi.org/10.1016/S0140-6736(04)17222-X).
3. Dolmans M-M, von Wolff M, Poirot C, Diaz-Garcia C, Cacciottola L, Boissel N, et al. Transplantation of cryopreserved ovarian tissue in a series of 285 women: a review of five leading European centers. *Fertil Steril*. 2021;115:1102–15. <https://doi.org/10.1016/j.fertnstert.2021.03.008>.
4. Callejo J, Salvador C, Miralles A, Vilaseca S, Lailla JM, Balasch J. Long-term ovarian function evaluation after autografting by implantation with fresh and frozen-thawed human ovarian tissue. *J Clin Endocrinol Metab*. 2001;86:4489–94. <https://doi.org/10.1210/jcem.86.9.7871>.

5. Kim SS, Hwang I-T, Lee H-C. Heterotopic autotransplantation of cryobanked human ovarian tissue as a strategy to restore ovarian function. *Fertil Steril*. 2004;82:930–2. <https://doi.org/10.1016/j.fertnstert.2004.02.137>.
6. Poirot C, Abirached F, Prades M, Coussieu C, Bernaudin F, Piver P. Induction of puberty by autograft of cryopreserved ovarian tissue. *Lancet*. 2012;379:588. [https://doi.org/10.1016/S0140-6736\(11\)61781-9](https://doi.org/10.1016/S0140-6736(11)61781-9).
7. Oktay KH, Marin L. Comparison of orthotopic and heterotopic autologous ovarian tissue transplantation outcomes. *Fertil Steril* 2023;S0015-0282(23)01933-7. <https://doi.org/10.1016/j.fertnstert.2023.10.015>.
8. Khattak H, Malhas R, Craciunas L, Afifi Y, Amorim CA, Fishel S, et al. Fresh and cryopreserved ovarian tissue transplantation for preserving reproductive and endocrine function: a systematic review and individual patient data meta-analysis. *Hum Reprod Update*. 2022;28:400–16. <https://doi.org/10.1093/humupd/dmac003>.
9. Kim SS, Lee WS, Chung MK, Lee HC, Lee HH, Hill D. Long-term ovarian function and fertility after heterotopic autotransplantation of cryobanked human ovarian tissue: 8-year experience in cancer patients. *Fertil Steril*. 2009;91:2349–54. <https://doi.org/10.1016/j.fertnstert.2008.04.019>.
10. Kim SS. Assessment of long term endocrine function after transplantation of frozen-thawed human ovarian tissue to the heterotopic site: 10 year longitudinal follow-up study. *J Assist Reprod Genet*. 2012;29:489–93. <https://doi.org/10.1007/s10815-012-9757-3>.
11. Baird DT, Campbell B, de Souza C, Telfer E. Long-term ovarian function in sheep after ovariectomy and autotransplantation of cryopreserved cortical strips. *Eur J Obstet Gynecol Reprod Biol*. 2004;113(Suppl 1):S55-59. <https://doi.org/10.1016/j.ejogrb.2003.11.023>.
12. Ablove TS, Austin JL, Phernetton TM, Magness RR. Effects of endogenous ovarian estrogen versus exogenous estrogen replacement on blood flow and ER $\beta$  $\alpha$  and ER $\beta$  levels in the bladder. *Reprod Sci*. 2009;16:657–64. <https://doi.org/10.1177/1933719109334255>.
13. Grubliauskaite M, van der Perk MEM, Bos AME, Meijer AJM, Gudleviciene Z, van den Heuvel-Eibrink MM, et al. Minimal infiltrative disease identification in cryopreserved ovarian tissue of girls with cancer for future use: a systematic review. *Cancers (Basel)*. 2023;15: 4199. <https://doi.org/10.3390/cancers15174199>.
14. Chen J, Wang R, Zhang B, Lin X, Wei J, Jia Y, et al. Safety of ovarian preservation in women with stage I and II cervical adenocarcinoma: a retrospective study and meta-analysis. *Am J Obstet Gynecol*. 2016;215:460.e1-460.e13. <https://doi.org/10.1016/j.ajog.2016.04.023>.