



HAL
open science

Vena cava leiomyosarcoma surgery results in a retrospective cohort of 41 patients from two centers

Thibaud Bertrand, Matthieu Faron, Olaf Mercier, Carine Ngo, Cécile Le Pechoux, Antonin Levy, Justin Issard, Clémence Henon, Charles Honoré, Elie Fadel, et al.

► To cite this version:

Thibaud Bertrand, Matthieu Faron, Olaf Mercier, Carine Ngo, Cécile Le Pechoux, et al.. Vena cava leiomyosarcoma surgery results in a retrospective cohort of 41 patients from two centers. *Journal of Surgical Oncology*, 2024, Online ahead of print. 10.1002/jso.27765 . hal-04683795

HAL Id: hal-04683795

<https://hal.science/hal-04683795v1>

Submitted on 24 Sep 2024



HAL is a multi-disciplinary open access archive for the deposit and dissemination of scientific research documents, whether they are published or not. The documents may come from teaching and research institutions in France or abroad, or from public or private research centers.

L'archive ouverte pluridisciplinaire **HAL**, est destinée au dépôt et à la diffusion de documents scientifiques de niveau recherche, publiés ou non, émanant des établissements d'enseignement et de recherche français ou étrangers, des laboratoires publics ou privés.



Distributed under a Creative Commons Attribution - NonCommercial - NoDerivatives 4.0 International License

Vena cava leiomyosarcoma surgery results in a retrospective cohort of 41 patients from two centers

Thibaud Bertrand¹  | Matthieu Faron MD, PhD^{1,2} | Olaf Mercier MD, PhD³ |
Carine Ngo MD⁴ | Cécile Le Pechoux MD⁵ | Antonin Levy MD, PhD^{5,6} |
Justin Issard MD³ | Clémence Henon MD, PhD^{6,7} | Charles Honoré MD, PhD¹  |
Elie Fadel MD, PhD³ | Axel Le Cesne MD, PhD^{6,7}

¹Department of Surgical Oncology, Gustave Roussy Cancer Campus, Villejuif, France

²INSERM 1018, CESP, Equipe ONCOSTAT, Université Paris Saclay, Villejuif, France

³Department of Thoracic Surgery and Heart-Lung Transplantation Marie-Lannelongue Hospital, GHPSJ, Le Plessis Robinson, France

⁴Biology and Pathology, Gustave Roussy Cancer Campus, Villejuif, France

⁵Radiation Oncology Department, Gustave Roussy Cancer Campus, Villejuif, France

⁶INSERM 1030, Molecular Radiotherapy and Therapeutic innovations, Université Paris Saclay, Villejuif, France

⁷Medical Oncology Department, Gustave Roussy Cancer Campus, Villejuif, France

Correspondence

Matthieu Faron, MD, PhD, Department of Surgical Oncology, Gustave Roussy Cancer Campus, 114, Rue Edouard Vaillant, 94805 Villejuif, France.

Email: matthieu.faron@gustaveroussy.fr

Abstract

Background: Leiomyosarcoma of the vena cava (LMS-VC) is a rare entity with poor oncological outcomes and a lack of histological staging prognostic factors.

Methods: Outcomes of consecutive patients operated on LMS-VC between March 2003 and May 2022, in two specialized sarcoma centers were reported.

Result: Forty-one patients were identified. Median size of LMS-VC was 9 cm with 68% of complete obstruction. After surgery, severe complication rate was 30%. No postoperative mortality was reported. Microscopic complete excision was obtained for 71% of patients, R1 for 27% and one patient presented an R2 resection. Grade 3 was found in 24%. After a median follow-up of 70 months, 3 years disease-free survival (DFS) and 5 years DFS were 34% and 17%, and 3 years overall survival (OS) and 5 years OS were 74% and 50%. Distant metastasis concerned 54% of recurrences, local 7% and local and distant 5%. Multivariate analysis showed that FNCLCC grade ($p < 0.001$) and perioperative chemotherapy ($p = 0.026$) were significant factors for DFS. In multivariate analysis, FNCLCC grade was a significant factor for OS ($p = 0.004$).

Discussion: Perioperative chemotherapy may have a role to play in lowering the risk of recurrence for LMS-VC, particularly in high-grade tumor.

KEYWORDS

inferior vena cava, leiomyosarcoma, LMS, outcomes, primary, prognostic, superior vena cava

1 | INTRODUCTION

Leiomyosarcomas (LMS) are rare malignancy of mesenchymal origin that can arise anywhere on the body, including within the endothelial smooth muscle of the intima of great vessels.^{1,2} To date,

approximately 450 cases of vascular LMS have been reported worldwide.³ Primary tumor site within the vascular system most frequently observed is the inferior vena cava (IVC), followed by renal vein, great saphenous vein, pulmonary vein, and femoral vein.⁴ This condition predominantly affects women, with a sex ratio favoring

This study was presented as a poster at the annual meeting of the European Society of Medical Oncology (ESMO) 2023.

This is an open access article under the terms of the [Creative Commons Attribution-NonCommercial-NoDerivs](https://creativecommons.org/licenses/by-nc-nd/4.0/) License, which permits use and distribution in any medium, provided the original work is properly cited, the use is non-commercial and no modifications or adaptations are made.

© 2024 The Author(s). *Journal of Surgical Oncology* published by Wiley Periodicals LLC.

females at 3.5:1, and is typically diagnosed during the sixth decade of life.⁵⁻⁷ Traditionally, three tumor growth patterns have been described: extraluminal (62%), intraluminal (5%), and a combination of extraluminal and intraluminal (33%).⁷ According to the Kieffer classification, based on the morphology, Leiomyosarcoma of the vena cava (LMS-VC) can be classified into Type I (K1), located below the renal veins, Type II (K2), situated below the hepatic veins up to the renal veins, and Type III (K3), located above the hepatic veins.⁸ The role of perioperative chemotherapy and/or radiotherapy in the management of this condition remains unclear^{3,9} and is not formally recommended by current guidelines.¹⁰ Factors such as tumor size, absence of metastatic disease at the time of surgery, K3 tumor classification, intraluminal growth pattern, extensive IVC involvement, IVC occlusion and its associated clinical consequences (lower limb edema, Budd-Chiari syndrome), completeness of resection, margin status, and the necessity for adjuvant therapy are all intuitive factors influencing survival and are supported by extensive data sets.¹¹⁻¹⁴ Nevertheless, there is a lack of conclusive evidence regarding histological staging and its significant prognostic implications.^{11,13}

This retrospective study aims to report our experience with LMS-VC surgery and its associated perioperative chemotherapy.

2 | PATIENTS AND METHODS

2.1 | Patients

All consecutive patients treated at Gustave Roussy and Marie-Lannelongue Hospital between 2000 and 2022 with a pathologically confirmed LMS-IVC were retrospectively identified from our prospectively maintained histological database of patients treated for soft tissue sarcoma (STS). Cases of LMS not originating from the IVC (or renal vein) were excluded. All cases underwent review at our multidisciplinary tumor boards specialized in sarcoma and member of the NetSarc+ network.¹⁵ An extensive chart review was performed from June to September 2022, based on the Saikia et al. reporting checklist.¹² French law does not warrant informed consent for retrospective study and all data were treated anonymously. This study adheres to the Strengthening the Reporting of Cohort, cross-sectional and case-control studies in Surgery (STROCSS 2021) guidelines.¹⁶

2.2 | Perioperative management

All patients underwent a contrast-enhanced CT scan to assess LMS-VC extension¹⁷ and the presence of pulmonary metastases. In cases where a locally advanced tumor was suspected, an MRI was performed to evaluate adjacent invasion and tumor thrombosis.¹⁸

Definitive diagnosis through biopsies was ideally made before initiating treatment.¹⁵ They were ideally performed via a retroperitoneal way with a co-axial system. Some patients referred to our

centers after diagnosis may have had other modalities (e.g., echocopy, surgical biopsy...).

Preoperative chemotherapy (CT) and radiotherapy (RT) were discussed in multidisciplinary tumor boards for borderline resectable tumors (tumors abutting 180° circumferentially around the abdominal aorta and superior mesenteric artery, with significant contact with the duodenum, pancreas, or liver) and high grade to enhance resectability rates. Adjuvant CT or RT was proposed to patient with incomplete microscopic resection margins or higher grade tumors.

2.3 | Intervention

The primary goal was to achieve a complete en-bloc excision of the mass.¹² The surgical strategy was determined based on the Kieffer level and the presence of intraluminal extent or free-floating thrombus. Cardiopulmonary bypass was typically required for K3 patients, with a sterno-laparotomy approach being preferred. For K2 and K1 patients, a median laparotomy approach with or without a transverse splint was favored. Regarding the IVC, exposure was achieved via Kocher, Cattell-Braasch, or even right liver mobilization to obtain proximal and distal control of the IVC and sufficient margins.¹⁹ Systemic heparin was delivered before the proximal IVC was clamped while monitoring blood pressure. The distal IVC was secured. Thrombectomy was carried out if needed. Four options were then considered: ligation (if cardiac input monitoring remained stable and venous collaterals were identified on preoperative CT scans); primary suture (if more than 75% of vena cava circumference remained after tumor excision); autologous or biologic patch (if more than 25% of vena cava circumference remained after tumor excision); and ringed Gortex graft in other cases (Figure 1).²⁰ Large arteries were resected if any tumoral rupture risk was suspected and reconstruction performed by dacron graft, venous bypass, or primary suture. In terms of major organ resection: the duodenum-pancreas

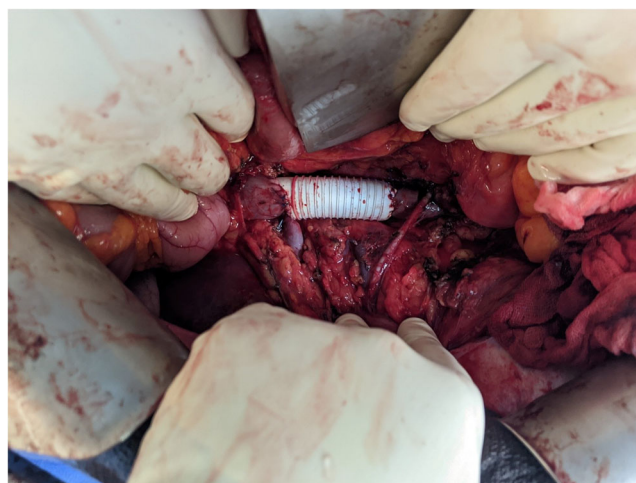


FIGURE 1 Ringed Gortex graft to restore infra-renal vena-cava continuity given hemodynamic intolerance of caval clamping.

was preserved when not directly invaded; minor liver resections were performed for minimal tumoral contact; and major liver resection (usually right hepatectomy) was carried out only for involvement of the hepatic veins, with reimplantation of the middle and left hepatic vein into the right atrium. Partial right atrium resection was accepted. The operative site was then covered with an epiplooplasty, and a drain was left in place. All procedures were conducted by thoracic-vascular and surgical oncologist with expertise in locally advanced tumors and sarcomas.

2.4 | Outcomes

Mortality was defined as death occurring in the hospital or within 90 days of the surgery. Postoperative morbidity was classified according to the Clavien-Dindo (CD) Classification.²¹ Tumors were graded according to the Federation Nationale des Centres de Lutte Contre le Cancer (FNCLCC) grade.²² A positive margin was defined as the presence of tumor cells less than 1 mm from the resection margin. Overall survival (OS) was calculated from the date of diagnosis to the date of death and censored at the date of the last follow-up for patients alive at that time. Disease-free survival (DFS) was calculated from the date of diagnosis to the date of first radiographic evidence of recurrence, metastatic disease, or death, or censored at the date of the last follow-up.

2.5 | Statistics

Quantitative variables were presented as median, IQR. Qualitative data were presented as count (percentage). Survival curves were calculated according to Kaplan–Meier. Median follow-up was estimated by reversed Kaplan–Meier. Univariate and multivariable Cox model was used to identify variables associated with OS and DFS. Given the number of patients, no method of variable selection was used for the multivariable analysis. Tumor size and grade, margin, and Kieffer level which were previously identified in the literature were used to control for confounding on the chemotherapy effect.²³

All tests were bilateral and a p value of less than 0.05 was considered significant. Statistical analysis was performed using SPSS 26.0 for Windows software (SPSS Inc.).

3 | RESULTS

3.1 | Patients' selection

Ninety-seven patients were identified from the histological database. Among them, 41 were included in the cohort (Figure 2). The median age was 58 years (Table 1). Males were accounting for 37% of the cohort. Abdominal pain was the most common symptom in 44% of the patients followed by palpable mass (10%). Only one patient presented an omentum metastasis at presentation.

The radiologic evaluation found IVC as the most common primary site, with a K2 presentation and complete obstruction in 68% of cases. The main organ involved was the right kidney (44%).

3.2 | Perioperative chemotherapy

A total of 12 patients received perioperative chemotherapy. Ten patients were given as neoadjuvant and two as adjuvant treatment. They tended to have larger tumors with a median size of 12 cm, more K3 presentation (30%), and heavier organ involvement: duodenum and pancreas each at 40% and liver at 30%. Neoadjuvant CT regimens were Doxorubicin plus Dacarbazine for 50% of patients, Doxorubicin plus Ifosfamid for 30% and Gemcitabin for 20%. The median number of cycles was 5. Neoadjuvant RT was delivered to one patient (50.4 Gy). Stable disease was seen in five patients and partial response in the five others. The median time between neoadjuvant treatment initiation and surgery was 146 days. Two patients needed adjuvant CT with Doxorubicin plus Dacarbazine for six cycles: one R0 with grade 3 tumor and one R1 with grade 2 tumor. Four patients needed adjuvant RT with 50.4 Gy: three R1 with two grade 2, one grade 3 and one R0 with grade 1 but aortic and iliac vessels contact. The median time between surgery and adjuvant treatment onset was 71 days.

3.3 | Surgical management, early and late postoperative complications

All but one patient had complete excision of the tumor (Table 2). Median laparotomy was the most frequent approach (54%). The two main options for VC management were ringed Gortex graft (42%) and ligation (no reconstruction) (32%). Five patients needed associated aortic (1 dacron graft, one suture) or iliac vessels (2 ligations, 1 bypass) resections. The right kidney was the most frequently resected organ (54%) followed by minor liver resection (20%). Median preoperative bleeding was 600 mL, and median operative time was 270 min. Cardiopulmonary bypass was required for 12% of patients.

Sixty-three percent of patients presented a complication. CD ≥ 3 complications concerned 30% of patients and 15% needed reinterventions. The most frequent complications were acute kidney injury (AKI) with 30% of patients, thrombotic events (13%), pleural effusion (10%), and hemorrhage (8%). Reconstructed IVC thrombosis accounted for two of the thrombotic events. No postoperative death was reported. Late reintervention was needed for 5% of patients.

After POD90, 15% of patients presented a complication (5% of CD ≥ 3). Two patients needed a reintervention and two others needed a new hospitalization. Thrombo-embolic events occurred in 7.5% of patients and two others presented chronic kidney disease (CKD).

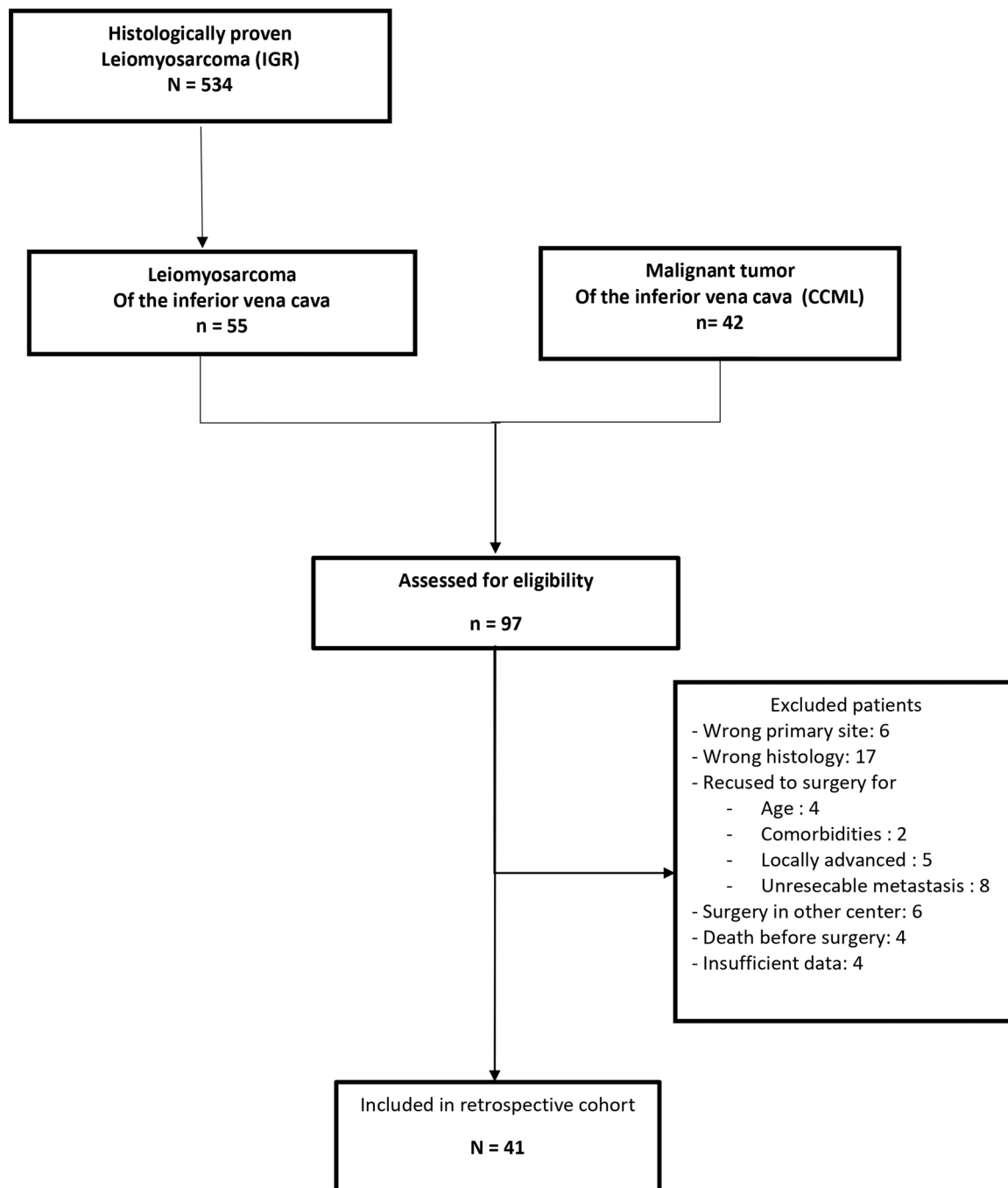


FIGURE 2 Study flowchart. CCML, Marie-Lannelongue Hospital; IGR, Institut Gustave Roussy.

3.4 | Pathology

Surgical specimens showed complete tumoral excision (R0) in 71% of patients (Table 3). Concerning no CT patients, R0 accounted for 83% of the surgical specimen, R1 14%, and R2 3%. Concerning CT patients, R0 accounted for 42% of surgical specimens, R1 58%, and no incomplete macroscopic margin was observed. The median residual cell rate after NACT or NACT-NART was 70%. A majority of patients presented FNCLCC Grade 2 LMS-VC.

3.5 | Oncological outcome

After a median follow-up of 70 months, there were 27 recurrences and 22 deaths. The median DFS was 22 months and OS was 55 months. Respectively, the 3 and 5-year DFS rates were 34% and 17%. OS, at the same time points were 74% and 50% (Figure 3). Seven patients were lost to follow-up. The median follow-up time was 70 months (95% CI 66 - Not Reached).

Distant metastasis was the main site of recurrence and occurred in 54% of the patients. On the contrary, local recurrence only

TABLE 1 Baseline characteristics of patients with and without perioperative chemotherapy.

	No CT N = 29	CT N = 12	All N = 41
<i>Patients' characteristics</i>			
Age at diagnosis (years, median, IQR)	60 (54–67)	52 (42–58)	58 (52–67)
Male (n, %)	11 (38)	4 (33)	15 (37)
BMI (kg/m ² , median, IQR)	25 (23–28)	25 (21–26)	25 (23–28)
Symptomatic lesion (n, %)	19 (66)	11 (91.7)	30 (73)
Palpable mass	2 (7)	2 (17)	4 (10)
Abdominal pain	15 (41)	6 (50)	18 (44)
Morphine use	2 (7)	4 (33)	6 (15)
ASA score (n, %)			
ASA I	1 (3)	4 (33)	5 (12)
ASA II	19 (66)	7 (58)	26 (63)
ASA III	9 (31)	1 (8)	10 (24)
<i>Disease's characteristics</i>			
Tumor size (cm, median, IQR)	8 (6–10)	10 (8–15)	9 (6–11)
Kieffer levels (n, %)			
K1	6 (21)	3 (25)	9 (22)
K2	17 (59)	6 (50)	23 (56)
K3	6 (20)	3 (25)	9 (22)
Primary tumor site (n, %)			
Right renal vein	3 (10)	1 (8)	4 (10)
IVC	24 (83)	11 (92)	35 (85)
SVC	2 (7)	0	2 (5)
Tumor pattern (n, %)			
Vena cava complete obstruction	20 (69)	8 (67)	28 (68)
Intraluminal extent	6 (21)	2 (17)	8 (20)
Free-floating thrombus	3 (10)	2 (17)	5 (12)
Preoperative organ involvement (n, %)			
Adrenal extension	5 (17)	1 (8)	6 (15)
Kidney extension	14 (48)	4 (33)	18 (44)
Duodenum extension	1 (3)	5 (42)	6 (15)
Pancreas extension	1 (3)	4 (33)	5 (12)
Liver extension	2 (7)	3 (25)	5 (12)
Atrial extension	3 (10)	0	3 (7)
Aortic extension	2 (7)	2 (17)	4 (10)
Iliac vessels extension	4 (14)	2 (17)	6 (15)
Metastasis at diagnosis (omentum)	0	1 (8)	1 (2)

Abbreviations: ASA, American Society of Anesthesia; BMI, body mass index; CT, perioperative chemotherapy; IVC, inferior vena cava; SVC, superior vena cava.

TABLE 2 Surgical treatment characteristics, early and late postoperative course.

	All N = 41
<i>Surgical approaches (n, %)</i>	
- Median laparotomy	22 (54)
- Median laparotomy plus right splint	8 (20)
- Subcostal laparotomy	2 (5)
- Lumbotomy	1 (2)
- Sterno-laparotomy	6 (15)
- Sternotomy	2 (5)
<i>Excision strategy (n, %)</i>	
- En-bloc	3 (7)
- Complete	37 (93)
Thrombectomy (n, %)	8 (20)
<i>Vena cava management (n, %)</i>	
- Ligation	13 (32)
- Patch	5 (12)
- Primary suture	6 (15)
- Gortex graft	17 (42)
<i>Associated organ resections (n, %)</i>	
- Right nephrectomy	22 (54)
- Minor hepatectomy	8 (20)
- Major hepatectomy	2 (5)
- Duodenum	3 (7)
- Spleen	1 (2)
- Bladder	2 (5)
- Right atrium	2 (5)
Perioperative bleeding (mL, median, IQR)	600 (200–2000)
Perioperative transfusion (units, median, IQR)	0 (0–4)
Cardiopulmonary bypass (n, %)	5 (12)
Operative time (min, median, IQR)	270 (180–360)
<i>Early postoperative course (<90 POD) (n, %)</i>	
- Overall complication rate	26 (63)
- Clavien-Dindo ≥3a	12 (30)
- Reintervention	6 (15)
- Length of stay (days, median, IQR)	17 (10–25)
<i>Late postoperative course (>90 POD)</i>	
- Overall complication rate (n, %)	6 (15)
- Clavien-Dindo ≥3a	2 (5)
- Reintervention	2 (5)
- Readmission	2 (5)

Abbreviations: CT, perioperative chemotherapy; POD, postoperative days.

TABLE 3 Surgical specimens' characteristics, adjuvant treatment, oncological outcomes.

	No CT N = 29	CT N = 12	All N = 41
Surgical specimens (n, %)			
- Complete excision (R0)	24 (83)	5 (42)	29 (71)
- Microscopic margin invaded (R1)	4 (14)	7 (58)	11 (27%)
- Incomplete excision (R2)	1 (3)	0	1 (2%)
- Tumor size (cm, median, IQR)	9 (6–12)	12 (9–13)	10 (7–13)
- Residual cells (% median, IQR)		70 (61–80)	
FNCLCC grade			
- Grade 1	5 (17)	0	5 (12)
- Grade 2	18 (62)	8 (67)	26 (63)
- Grade 3	6 (21)	4 (33)	10 (24)
Recurrence (n, %)			
- Local recurrence	2 (7)	1 (8)	3 (7)
- Distant recurrence	14 (48)	8 (67)	22 (54)
- Local and distant recurrence	0	2 (17)	2 (5)
Cause of death (n, %)			
- Sarcomatosis	3 (10)	3 (25)	6 (15)
- Distant progression	1 (3)	1 (8)	2 (5)
- Local progression	0	1 (8)	1 (2)
- Sepsis	3 (10)	0	3 (7)
- Acute hepatic failure	2 (7)	1 (8)	3 (7)
- Unknown	5 (17)	2 (17)	7 (17)

Abbreviation: CT, perioperative chemotherapy.

occurred in 7% of patients, and local and distant recurrence was scarce (5%). First distant metastasis was found in the lung (25%), liver 15%, bone (15%), peritoneum (2.5%), and mammary tissue (2.5%).

Recurrence treatment was generally multimodal but CT was the first-line therapy (27.5%).

3.6 | Prognostic analysis

Univariate analysis showed that microscopic margins, tumor size on surgical specimens, and FNCLCC grade were associated with DFS (Table 4). Multivariable analysis showed that FNCLCC grade ($p < 0.001$), and perioperative chemotherapy ($p = 0.026$) were independently associated with DFS.

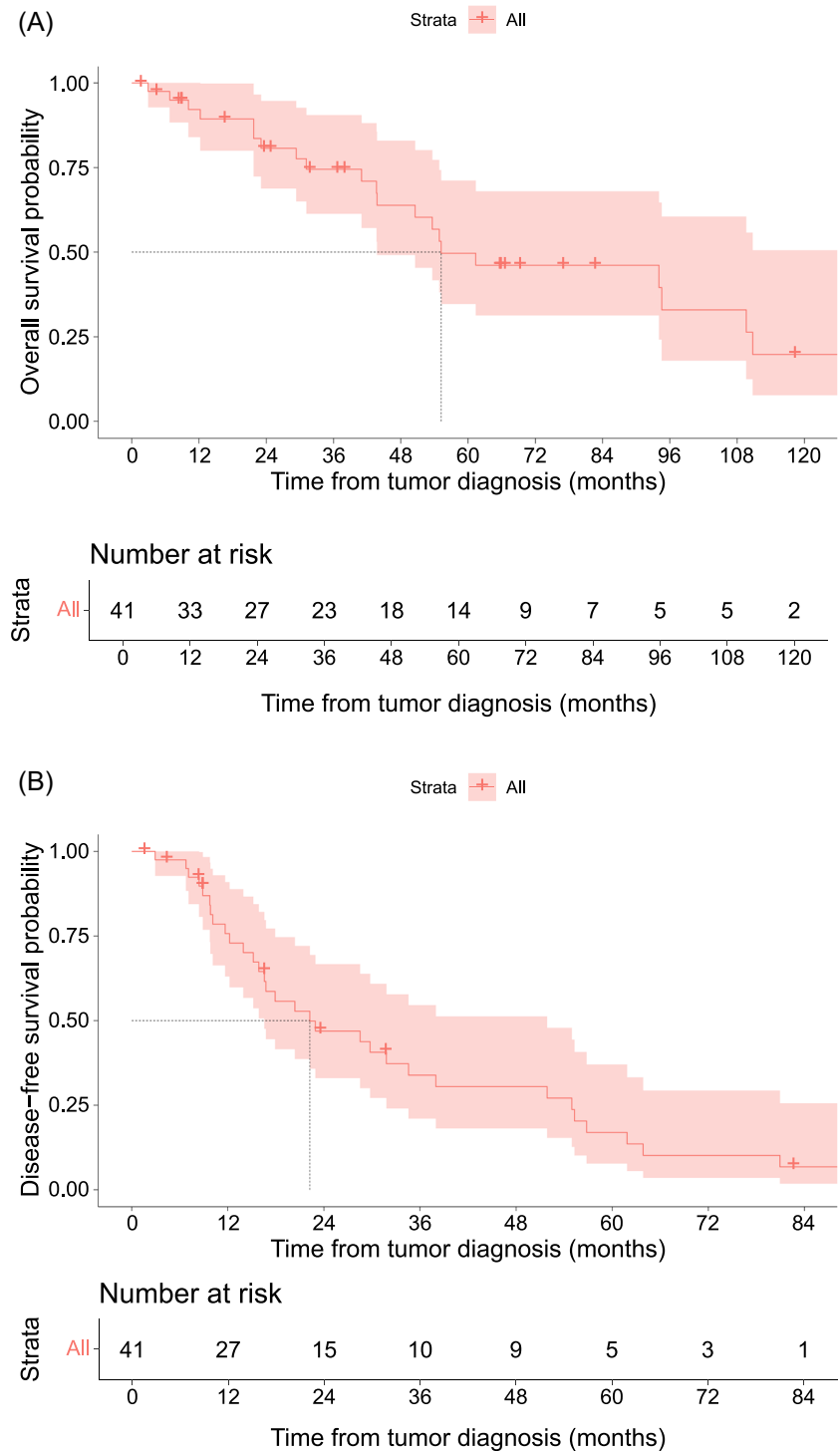
Considering OS, univariate analysis showed microscopic margins and FNCLCC grade were prognostic factors. Multivariable analysis showed that FNCLCC grade was the only independent predictor of OS ($p = 0.004$).

4 | DISCUSSION

In this 20-year experience from two specialized centers, we analyzed 41 patients who underwent surgical treatment for LMS-VC. This series stands as one of the largest available, and it yields noteworthy findings from both surgical and oncological perspectives.

From a surgical standpoint, three major aspects warrant discussion: the extent of resection, the IVC reconstruction, and surgical complications. In the last decade, compartmental resection has become the standard of care for retroperitoneal sarcomas. However, existing evidence primarily focuses on well-differentiated or de-differentiated liposarcomas rather than leiomyosarcomas. It's important to note that while liposarcomas can have tumor boundaries that are challenging to discern intraoperatively, leiomyosarcomas typically have more easily identifiable boundaries. Moreover, liposarcomas tend to recur locally, whereas leiomyosarcomas tend to recur at distant sites. Considering these distinctions, we advocate for tailoring surgical resection plans to the specific characteristics of leiomyosarcomas, without necessarily extending resections to uninvolved organs, such as the colon. Fairweather et al. have reported that while 26% and 33% of resected adjacent kidneys and colons showed histopathological organ involvement in dedifferentiated liposarcoma and well-differentiated liposarcoma, respectively, the figure for LMS was only 9%.^{24,25} Nonetheless, over 55% of our patients required organ resection, with the kidney and liver being the most commonly affected. For liver involvement, most resections were minor hepatectomies, with major hepatectomies (required when the hepatic vein was involved) being relatively infrequent. Similarly, duodenal or pancreatic head resection was infrequent, which is advantageous given the poor outcomes associated with these procedures.^{26,27} In our series, we achieved a complete R0 resection in 71% of patients, a rate higher than that reported by Jeong et al. and Blair et al.^{14,28} The second important surgical aspect is the necessity of IVC reconstruction. While it is often assumed that the IVC should always be reconstructed, it's worth noting that since LMS is a slow-growing tumor, many patients have the time to develop collateral vessels before surgery. Consequently, 32% of our patients did not require IVC reconstruction. Clinical examination and CT scan analysis can provide valuable evidence for the presence of collaterals. In cases of good tolerance, we routinely opted for no reconstruction. When reconstruction was necessary, the most commonly used technique was a Ringed Goretex graft, allowing for the reconstruction of even extensive IVC defects. However, this approach has two drawbacks: an increased risk of infection, particularly when combined with digestive resection, and the need for lifelong anticoagulation. In our sample, tumor size tended to be larger with a median of 9 cm and a range from 2.4 to 23 cm. Sulpice et al. and Teixeira et al. did not observe such size.^{29,30} Notably, our sample had a larger proportion of K3 LMS-VC cases, explaining our higher rate of cardiopulmonary bypass utilization^{14,28–31} and simpler resections (patch or direct suture) were less frequent. In general, it's essential to strike a balance between systematic reconstruction and the associated need for anticoagulation and ligation, considering

FIGURE 3 (A) Overall survival. (B) Disease-free survival.



potential complications such as lower limb edema. Currently, no preoperative interventional procedures have been described to promote collateral venous pathway development before excision surgery for K1 and K2 LMS-VC. One potential option could be adapted from coil and cover techniques developed for venous hemorrhage or endovascular embolization.^{32,33} The rate of CD ≥ 3 complications was 30%, with no postoperative deaths observed. While these figures are within the range typically observed for major procedures, it underscores the importance of careful

patient selection and the use of prehabilitation techniques to reduce risks. Nevertheless, we did observe a high rate of postoperative AKI, affecting 30% of patients, with two patients developing CKD after surgery. This can impact access to certain adjuvant treatment modalities. In particular, radical nephrectomy with vena cava thrombectomy, high BMI, prolonged perioperative hypotension, and postoperative anemia are known risk factors for postoperative AKI, while selective renal artery embolization offers protection.^{34,35} Prehabilitation and liberal postoperative transfusion could potentially

TABLE 4 Univariate and multivariate analysis with Cox model of prognostic factors for disease-free and overall survival of all patients.

	Categories	Univariate HR	95% CI	p	Multivariate HR	95% CI	p
<i>Disease-free survival</i>							
Microscopic Margin	R0	1		0.025			
	R1	1.95	0.9–4.1				
	R2	47.9	2.9–780				
Kieffer levels	K1	1		0.5			
	K2	1.1	0.5–2.7				
	K3	1.75	0.6–5.				
CT	No CT	1		>0.9	1		0.026
	CT	1.04	0.5–2.2	0.30	0.38	0.2–0.92	
FNCLCC grade	Grade 1			<0.001	1		<0.001
	Grade 2	10.4	1.3–81.2		20	2.3–175	
	Grade 3	26.	3.1–227		65.6	6.3–683	
Tumor size on the surgical specimen (cm)		1.12	1–1.2	0.006			
<i>Overall survival</i>							
Microscopic margin	R0	1		0.055			
	R1	1.65	0.7–4				
	R2	44.8	2.7–731				
Tumor size on the surgical specimen (cm)		1.07	1–1.2	0.2			
FNCLCC grade	Grade 1	1		0.004	1		0.004
	Grade 2	4.50	0.6–35		4.12	0.43–39.2	
	Grade 3	16.8	2–149		19.7	1.7–222	
Kieffer levels	K1	1		0.054	1		0.1
	K2	1.58	0.4–5.7		1.21	0.3–5	
	K3	4.41	1.1–18		3.48	0.8–15	
CT	No CT	1		>0.9	1		0.3
	CT	0.96	0.4–2.31		0.63	0.2–1.7	

Abbreviations: CI, confidence interval; CT, perioperative chemotherapy; DFS, disease-free survival; OS, overall survival.

mitigate the most common surgical morbidities after LMS-VC excision.

From an oncological perspective, three key points merit discussion: the aggressiveness of the disease, patterns of recurrence, and the use of neo/adjuvant therapies. In our series, LMS-VC exhibited marked aggressiveness, with a median DFS of less than 2 years and a 5-year OS of 50%. However, these outcomes compare favorably to other studies; for instance, Wachtel et al. reported a median DFS of 12 months and an OS of 23 months, while Saikia et al. found 28 and 60 months, respectively.^{11,12} Among the 27 patients experiencing recurrence, 24 (89%) had distant or combined distant and local recurrences, with local-only recurrence observed in only 3 (11%) patients. This pattern underscores that LMS-VC is a systemic disease, and despite tumor size and limited surgery extent, local recurrence is

rarely a primary concern. Given this high risk of early recurrence, it is imperative to establish rigorous follow-up protocols and consider neo/adjuvant therapies. Recent ESMO guidelines recognize the scarcity of available studies guiding optimal surveillance for these patients but suggest differential follow-up approaches for high and low-risk patients. In our view, LMS-VC should be classified as a high-risk sarcoma, warranting shorter intervals for follow-up, adhering to guidelines such as every 3–4 months in the initial 2–3 years, followed by semiannual check-ups for up to 5 years, and then annual assessments for up to 10 years. The question of whether neo/adjuvant treatments can reduce recurrence risk is also essential. Our data supports the use of neo/adjuvant therapies, particularly for FNCLCC grade 2 and 3 lesions. Unfortunately, we had insufficient data on grade 1 sarcoma patients to evaluate the potential benefits for this subgroup. However, after

adjusting for grade, we observed that patients who received neo/ adjuvant chemotherapy had a lower hazard for DFS (HR = 0.38 [95% CI 0.2–0.92], $p = 0.026$). Due to our limited sample size, we could not compare the timing of chemotherapy administration (neo vs. adjuvant). Neo-adjuvant treatment offers potential advantages, including the possibility of achieving an objective response that allows for organ-sparing surgeries, especially when dealing with tumors in contact with the liver or pancreatic head. Additionally, it ensures that treatment is administered without delays due to postoperative complications, which can be common after high-risk procedures, potentially impeding timely treatment. Although only a few patients underwent radiotherapy, considering the recurrence pattern, its substantial impact on risk reduction is unlikely. The two main CT modalities have been described by the EORTC and Gronchi et al.^{36,37} Our results are not in line with SMAC analysis, EORTC 62931 trial, and Saikia and all that have not found a link between adjuvant treatment (mainly adjuvant CT) and DFS for LMS,^{12,38,39} but the particular location to the IVC may be different than other LMS. Concerning adjuvant RT, the Scandinavian Group has found a lesser risk of local and distant recurrence respectively.⁴⁰ Their results are not supported by an in vitro study which found a large heterogeneity of radiation response between different LMS types.⁴¹ As well in the STRASS trial, subgroup analyses of abdominal recurrence-free survival based on sarcoma subtype and grade indicate that preoperative radiotherapy does not benefit for leiomyosarcoma and high-grade retroperitoneal sarcoma (but the individual sizes of all subgroups were relatively small). It goes against SMAC analysis, EORTC 62931 trial, and Saikia that all have not found an association between adjuvant treatment (mainly adjuvant CT) and DFS for LMS.^{12,38,39} One of the key elements of the decision could be the FNCLCC grade which was found significant for DFS and OS in our series whereas Laskin et al. concluded its absence of effect on prognosis.¹³

Our study has several strengths. First, it is one of the largest studies in the current literature. Second, all cases were confirmed by a specialized pathologist and patients were managed by teams trained in sarcomas. Finally, a multivariable model was used to control confounding bias. Yet, this work has several limitations which should be kept in mind. First, given the rarity of the disease, we present highly annotated data from a relatively limited number of selected patients. Second, the retrospective nature of this study does not allow us to make strong conclusions because of the risk of residual bias. Our results must be confirmed by subsequent studies.

The vena cava is a rare location for LMS that should be considered at high risk of distant recurrences. Neo/adjuvant chemotherapy may be able to lower that risk. In experienced teams, surgery can be performed with good short and long terms outcomes.

AUTHOR CONTRIBUTIONS

Thibaud Bertrand participated in the patients' screening and inclusion, data collection, and results analysis and writing of the article. Matthieu Faron participated in the study design, manuscript supervision, and corrections. Olaf Mercier, Carine Ngo, Cécile Le Pechoux, Antonin Levy, Justin Issard, Clémence Henon, and Charles Honore contributed to data collection and manuscript revision for

important intellectual content. Elie Fadel and Axel Le Cesne contributed to study conception and design, project administration, manuscript drafting, and manuscript revision for important intellectual content. All authors approved the final version of the manuscript.

CONFLICT OF INTEREST STATEMENT

The authors declare no conflict of interest.

DATA AVAILABILITY STATEMENT

The data on which this study is based can be accessed on request from the corresponding author (Matthieu Faron). The data are not publicly available because they contain information that could potentially compromise the privacy of the patients.

ETHICS STATEMENT

The study was approved by the Ethics Committee of "Gustave Roussy Cancer Campus."

ORCID

Thibaud Bertrand  <http://orcid.org/0009-0008-6126-2246>

Charles Honoré  <http://orcid.org/0000-0003-1184-6143>

REFERENCES

1. WHO Classification of Tumours Editorial Board. *Soft Tissue and Bone Tumours*. Vol 3, 5th ed. WHO Classification of Tumours; 2020.
2. Dzsiniich C, Gloviczki P, van Heerden JA, et al. Primary venous leiomyosarcoma: a rare but lethal disease. *J Vasc Surg*. 1992;15:595-603.
3. Joung HS, Nooromid MJ, Eskandari MK, Wayne JD. Surgical approach, management, and oncologic outcomes of primary leiomyosarcoma of the inferior vena cava: an institutional case series. *J Surg Oncol*. 2020;122:1348-1355. doi:10.1002/jso.26163
4. Gage MJ, Patel AV, Koenig KL, Newman E. Non-vena cava venous leiomyosarcomas: a review of the literature. *Ann Surg Oncol*. 2012;19:3368-3374. doi:10.1245/s10434-012-2379-2
5. Fujita S, Takahashi H, Kanzaki Y, et al. Primary leiomyosarcoma in the inferior vena cava extended to the right atrium: a case report and review of the literature. *Case Rep Oncol*. 2016;9:599-609. doi:10.1159/000450598
6. Mastoraki A, Leotsakos G, Mastoraki S, et al. Challenging diagnostic and therapeutic modalities for leiomyosarcoma of inferior vena cava. *Int J Surg*. 2015;13:92-95. doi:10.1016/j.ijsu.2014.11.051
7. Hartman DS, Hayes WS, Choyke PL, Tibbetts GP. From the archives of the AFIP. Leiomyosarcoma of the retroperitoneum and inferior vena cava: radiologic-pathologic correlation. *Radiographics*. 1992;12:1203-1220. doi:10.1148/radiographics.12.6.1439022
8. Kieffer E, Alaoui M, Piette J-C, Cacoub P, Chiche L. Leiomyosarcoma of the inferior vena cava. *Ann Surg*. 2006;244:289-295. doi:10.1097/01.sla.0000229964.71743.db
9. Alkhalili E, Greenbaum A, Langsfeld M, et al. Leiomyosarcoma of the inferior vena cava: a case series and review of the literature. *Ann Vasc Surg*. 2016;33:245-251. doi:10.1016/j.avsg.2015.10.016
10. Swallow CJ, Strauss DC, Bonvalot S, et al. Management of primary retroperitoneal sarcoma (RPS) in the adult: an updated consensus approach from the Transatlantic Australasian RPS Working Group. *Ann Surg Oncol*. 2021;28:7873-7888. doi:10.1245/s10434-021-09654-z
11. Wachtel H, Gupta M, Bartlett EK, et al. Outcomes after resection of leiomyosarcomas of the inferior vena cava: a pooled data analysis of 377 cases. *Surg Oncol*. 2015;24:21-27. doi:10.1016/j.suronc.2014.10.007

12. Saikia J, Rastogi S, Barwad A, et al. A systematic review of the current management approaches in leiomyosarcoma of inferior vena cava—results from analysis of 118 cases. *Asian Cardiovasc Thorac Ann.* 2022;30:349-363. doi:10.1177/02184923211049911
13. Laskin WB, Fanburg-Smith JC, Burke AP, Kraszewska E, Fetsch JF, Miettinen M. Leiomyosarcoma of the inferior vena cava: clinico-pathologic study of 40 cases. *Am J Surg Pathol.* 2010;34:873-881.
14. Jeong S, Han Y, Cho Y-P, Kwon T-W. Clinical outcomes of surgical resection for leiomyosarcoma of the inferior vena cava. *Ann Vasc Surg.* 2019;61:377-383. doi:10.1016/j.avsg.2019.05.053
15. Bonvalot S, Gagnard E, Stoeckle E, et al. Survival benefit of the surgical management of retroperitoneal sarcoma in a reference center: a nationwide study of the French Sarcoma Group from the NetSarc database. *Ann Surg Oncol.* 2019;26:2286-2293. doi:10.1245/s10434-019-07421-9
16. Mathew G, Agha R, Albrecht J, et al. STROCSS 2021: strengthening the reporting of cohort, cross-sectional, and case-control studies in surgery. *Int J Surg.* 2021;96:106165. doi:10.1016/j.jisu.2021.106165
17. Webb EM, Wang ZJ, Westphalen AC, Nakakura EK, Coakley FV, Yeh BM. Can CT features differentiate between inferior vena cava leiomyosarcomas and primary retroperitoneal masses. *Am J Roentgenol.* 2013;200:205-209. doi:10.2214/AJR.11.7476
18. Monteagudo Cortecero J, Guirau Rubio MD, Payá Romá A. Leiomyosarcoma of the inferior vena cava: AIRP best cases in radiologic-pathologic correlation. *Radiographics.* 2015;35:616-620. doi:10.1148/rg.352130105
19. Fletcher-Sanfelio D, García-Granero Á, Doménech Dolz A, et al. Anatomía quirúrgica aplicada a abordajes transperitoneales de la aorta abdominal y los troncos viscerales. Artículo dinámico. *Cir Esp.* 2021;99:562-571. doi:10.1016/j.cireng.2021.08.002
20. Azoulay D, Lim C, Salloum C (Eds.). *Surgery of the Inferior Vena Cava.* Springer International Publishing; 2017. doi:10.1007/978-3-319-25565-1
21. Dindo D, Demartines N, Clavien P-A. Classification of surgical complications: a new proposal with evaluation in a cohort of 6336 patients and results of a survey. *Ann Surg.* 2004;240:205-213. doi:10.1097/01.sla.0000133083.54934.ae
22. Guillou L, Coindre JM, Bonichon F, et al. Comparative study of the National Cancer Institute and French Federation of Cancer Centers Sarcoma Group grading systems in a population of 410 adult patients with soft tissue sarcoma. *J Clin Oncol.* 1997;15:350-362. doi:10.1200/JCO.1997.15.1.350
23. Heinze G, Wallisch C, Dunkler D. Variable selection – a review and recommendations for the practicing statistician. *Biometrical J.* 2018;60:431-449. doi:10.1002/bimj.201700067
24. Fairweather M, Gonzalez RJ, Strauss D, Raut CP. Current principles of surgery for retroperitoneal sarcomas. *J Surg Oncol.* 2018;117:33-41. doi:10.1002/jso.24919
25. Fairweather M, Wang J, Jo VY, Baldini EH, Bertagnolli MM, Raut CP. Incidence and adverse prognostic implications of histopathologic organ invasion in primary retroperitoneal sarcoma. *J Am Coll Surg.* 2017;224:876-883. doi:10.1016/j.jamcollsurg.2017.01.044
26. Flacc M, Faron M, Mir O, et al. Postoperative outcome of surgery with pancreatic resection for retroperitoneal soft tissue sarcoma: results of a retrospective bicentric analysis on 50 consecutive patients. *J Gastrointest Surg.* 2021;25:2299-2306. doi:10.1007/s11605-020-04882-2
27. MacNeill AJ, Gronchi A, Miceli R, et al. Postoperative morbidity after radical resection of primary retroperitoneal sarcoma: a report from the transatlantic RPS working group. *Ann Surg.* 2018;267:959-964. doi:10.1097/SLA.0000000000002250
28. Blair AB, Reames BN, Singh J, et al. Resection of retroperitoneal sarcoma en-bloc with inferior vena cava: 20-year outcomes of a single institution. *J Surg Oncol.* 2018;118:127-137. doi:10.1002/jso.25096
29. Sulpice L, Rayar M, Levi Sandri G-B, et al. Leiomyosarcoma of the inferior vena cava. *J Visc Surg.* 2016;153:161-165. doi:10.1016/j.jviscsurg.2015.11.002
30. Teixeira FJR, do Couto Netto SD, Perina ALF, et al. Leiomyosarcoma of the inferior vena cava: survival rate following radical resection. *Oncol Lett.* 2017;14:3909-3916. doi:10.3892/ol.2017.6706
31. Illuminati G, Pizzardi G, Calio' F, Pacilè MA, Masci F, Vietri F. Outcome of inferior vena cava and noncaval venous leiomyosarcomas. *Surgery.* 2016;159:613-620. doi:10.1016/j.surg.2015.08.026
32. Van Sickler AP, Smith AH, Ellis RC, et al. A novel technique and outcomes for transcaval endoleak embolization. *Ann Vasc Surg.* 2023;93(23):300-307. doi:10.1016/j.avsg.2023.01.013
33. Ono S, Yamazoe S, Takigawa Y, Hasegawa H. Percutaneous transhepatic coil and cover technique with small system for the extrahepatic portal vein hemorrhage after pancreaticoduodenectomy. *Radiol Case Rep.* 2022;17:1246-1250. doi:10.1016/j.radcr.2022.01.036
34. Cui R, Li F, Shao J, et al. Postoperative anemia is a risk factor for acute kidney injury after open aorta and vena cava surgeries. *PLoS One.* 2020;15:e0240243. doi:10.1371/journal.pone.0240243
35. Hua Y-B, Li X, Wang D-X. Prevalence and risk factors of myocardial and acute kidney injury following radical nephrectomy with vena cava thrombectomy: a retrospective cohort study. *BMC Anesthesiol.* 2021;21:243. doi:10.1186/s12871-021-01462-y
36. Gronchi A, Palmerini E, Quagliuolo V, et al. Neoadjuvant chemotherapy in high-risk soft tissue sarcomas: final results of a randomized trial from Italian (ISG), Spanish (GEIS), French (FSG), and Polish (PSG) Sarcoma Groups. *J Clin Oncol.* 2020;38:2178-2186. doi:10.1200/JCO.19.03289
37. D'Ambrosio L, Touati N, Blay J-Y, et al. Doxorubicin plus dacarbazine, doxorubicin plus ifosfamide, or doxorubicin alone as a first-line treatment for advanced leiomyosarcoma: a propensity score matching analysis from the European Organization for Research and Treatment of Cancer Soft Tissue and Bone Sarcoma Group. *Cancer.* 2020;126:2637-2647. doi:10.1002/cncr.32795
38. Sarcoma Meta-analysis Collaboration (SMAC). Adjuvant chemotherapy for localized resectable soft tissue sarcoma in adults. *Cochrane Database Syst Rev.* 2000;2000(4):CD001419. doi:10.1002/14651858.CD001419
39. European Organisation for Research and Treatment of Cancer - EORTC. A randomized phase III study of neoadjuvant chemotherapy followed by surgery versus surgery alone for patients with high-risk retroperitoneal sarcoma (RPS). clinicaltrials.gov; 2021.
40. Trovik LH, Ovrebø K, Almqvist M, et al. Adjuvant radiotherapy in retroperitoneal sarcomas. A Scandinavian Sarcoma Group study of 97 patients. *Acta Oncol.* 2014;53:1165-1172. doi:10.3109/0284186X.2014.921723
41. Haas RL, Froot BGJ, Scholten AN, et al. Cellular radiosensitivity of soft tissue sarcoma. *Radiat Res.* 2021;196:23-30. doi:10.1667/RADE-20-00226.1

SUPPORTING INFORMATION

Additional supporting information can be found online in the Supporting Information section at the end of this article.

How to cite this article: Bertrand T, Faron M, Mercier O, et al. Vena cava leiomyosarcoma surgery results in a retrospective cohort of 41 patients from two centers. *J Surg Oncol.* 2024; 1-10. doi:10.1002/jso.27765