



**HAL**  
open science

## **FGFR1 wild-type rosette-forming glioneuronal tumours**

Mégane Le Quang, Aude Trinquet, Aurore Siegfried, Amaury de Barros, Luc Bauchet, Sam Ng, Vincent Jecko, Guillaume Chotard, Morgan Ollivier, Gilles Adam, et al.

► **To cite this version:**

Mégane Le Quang, Aude Trinquet, Aurore Siegfried, Amaury de Barros, Luc Bauchet, et al..  
FGFR1 wild-type rosette-forming glioneuronal tumours. *Acta Neuropathologica*, 2024, 148 (1), pp.26.  
10.1007/s00401-024-02779-x . hal-04680760

**HAL Id: hal-04680760**

**<https://hal.science/hal-04680760v1>**

Submitted on 29 Aug 2024

**HAL** is a multi-disciplinary open access archive for the deposit and dissemination of scientific research documents, whether they are published or not. The documents may come from teaching and research institutions in France or abroad, or from public or private research centers.


L'archive ouverte pluridisciplinaire **HAL**, est destinée au dépôt et à la diffusion de documents scientifiques de niveau recherche, publiés ou non, émanant des établissements d'enseignement et de recherche français ou étrangers, des laboratoires publics ou privés.



Distributed under a Creative Commons Attribution - NonCommercial - NoDerivatives 4.0 International License



## FGFR1 wild-type rosette-forming glioneuronal tumours

Mégane Le Quang<sup>1</sup> · Aude Trinquet<sup>2,3</sup> · Aurore Siegfried<sup>4,5</sup> · Amaury de Barros<sup>6</sup> · Luc Bauchet<sup>3,7</sup> · Sam Ng<sup>3,7</sup> · Vincent Jecko<sup>8</sup> · Guillaume Chotard<sup>1</sup> · Morgan Ollivier<sup>9</sup> · Gilles Adam<sup>10</sup> · Fabrice Bonneville<sup>10</sup> · Julien Masliah-Planchon<sup>11,12</sup> · Yvan Nicaise<sup>5</sup> · Clémentine Decamps<sup>5</sup> · Valérie Rigau<sup>2,3</sup> · Emmanuelle Uro-Coste<sup>4,5,13</sup> 

Received: 3 July 2024 / Revised: 28 July 2024 / Accepted: 30 July 2024  
© The Author(s) 2024

We present three cases of rosette-forming glioneuronal tumours (RGNT), diagnosed through DNA-methylation profiling, without the classical *FGFR1* alteration commonly reported in this entity.

Case 1 involves a 29-year-old man with no significant medical history, presenting with two episodes of severe headaches, occurring 1 year apart, which resolved spontaneously. Ophthalmological examination revealed metamorphopsia in the bitemporal hemifields, also resolving spontaneously. MRI revealed a lesion in the third ventricle with central enhancement, obstructing the interventricular foramina, invading the basal cisterns and making contact with the pituitary stalk and optic chiasm (Fig. 1a). Biopsy during ventriculocysternostomy (VCS) revealed a proliferation forming numerous neurocytic rosettes, occasionally longitudinally sectioned and resembling columns, accompanied by a myxoid background (Fig. 1b). There were no histological signs of aggressiveness. The cells strongly expressed glial markers and synaptophysin (Fig. 1c). Monitoring was

decided upon and the patient has been asymptomatic for 6 months.

Case 2 concerns a 27-year-old woman who had been suffering from subacute headaches of increasing intensity for 2 years. Ophthalmological examination showed bilateral early papilledema. MRI revealed a lesion centred on the fourth ventricle with FLAIR hyperintensity and spontaneous T1 peripheral hyperintensity, without significant gadolinium enhancement. The lesion had infiltrated the cerebellar vermis and extended into the beginning of the foramina of Luschka (Fig. 1d). Histological analysis of surgical resection revealed a biphasic proliferation alternating oligo-like or piloid areas with areas containing neurocytic and perivascular rosettes (Fig. 1e). There were no histological signs of aggressiveness. The cells exhibited strong expression of glial markers and heterogeneous synaptophysin expression (Fig. 1f). The patient remained clinically and radiologically free of relapse at the last follow-up which took place 14 months post-surgery.

✉ Emmanuelle Uro-Coste  
uro-coste.e@chu-toulouse.fr

<sup>1</sup> Pathology Department, Bordeaux University Hospital, Bordeaux, France

<sup>2</sup> Pathology Department, Montpellier University Hospital, Montpellier, France

<sup>3</sup> Montpellier Institute for Neuroscience (IGF), INSERM U1191, Montpellier University Hospital, Montpellier, France

<sup>4</sup> Pathology Department, Toulouse University Hospital, Toulouse, France

<sup>5</sup> INSERM U1037, Toulouse Cancer Research Centre (CRCT), Toulouse, France

<sup>6</sup> Neurosurgery Department, Toulouse University Hospital, Toulouse, France

<sup>7</sup> Neurosurgery Department, Montpellier University Hospital, Montpellier, France

<sup>8</sup> Neurosurgery Department, Bordeaux University Hospital, Bordeaux, France

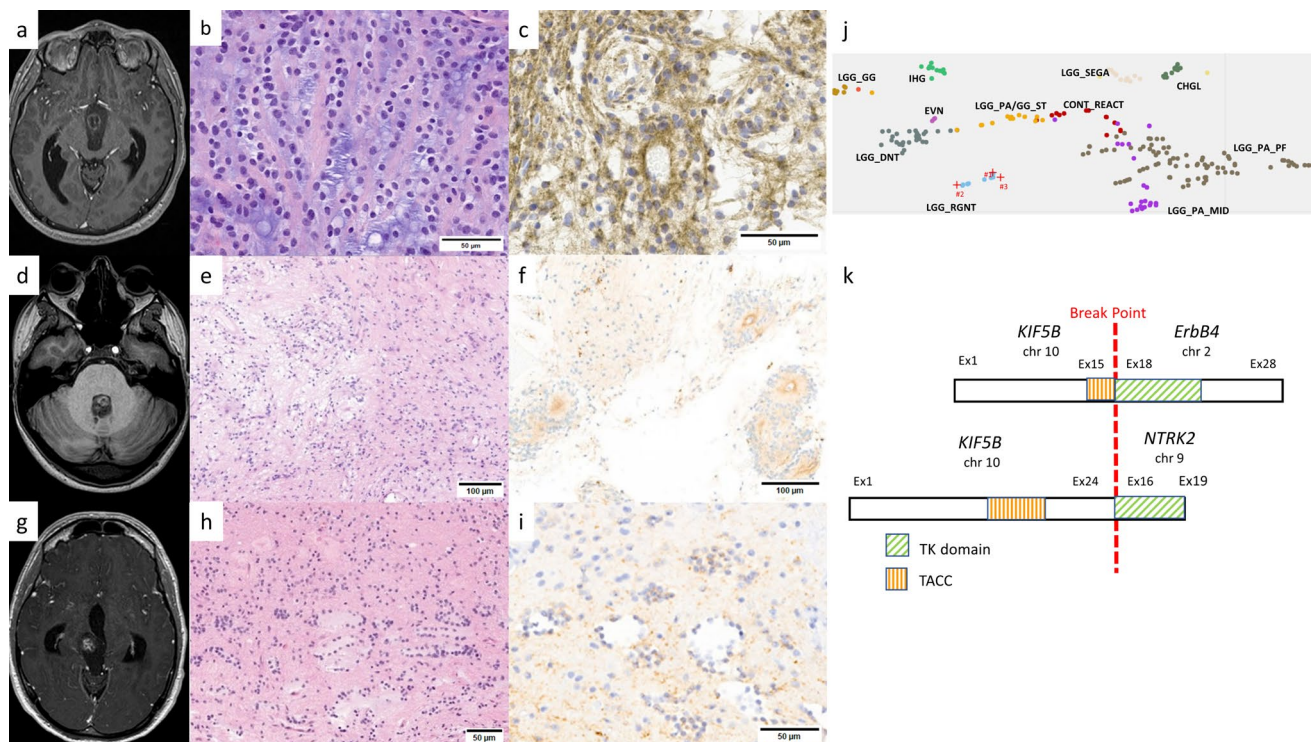
<sup>9</sup> Neuroimaging Department, Bordeaux University Hospital, Bordeaux, France

<sup>10</sup> Neuroimaging Department, Toulouse University Hospital, Toulouse, France

<sup>11</sup> Genetics Department & Oncopaediatrics and Young Adults Department, Curie Institute, Paris, France

<sup>12</sup> INSERM U830, Laboratory of Translational Research in Paediatric Oncology, SIREDO Paediatric Oncology Centre, Curie Institute, Paris, France

<sup>13</sup> Service d'Anatomie et Cytologie Pathologiques, Institut Universitaire du Cancer-Oncopole, 1, avenue Irène Joliot-Curie, 31059 Toulouse Cedex 9, France



**Fig. 1** MRI on the T1 sequence revealed well-circumscribed lesions with heterogeneous gadolinium enhancement located in the third ventricle obstructing the two interventricular foramina and invading the basal cisterns in case 1 (a), in the fourth ventricle in case 2 (d) and in the right mesencephalon in case 3 (g). Haematoxylin and eosin (HE) staining showed characteristic neurocytic rosettes viewed longitudinally, with a columnar arrangement in this small biopsy in case 1 (b), a biphasic proliferation with neurocytic rosettes (left) and piloid features (right) in case 2 (e) and rosettes with various size and shapes

in case 3 (h). Cell staining for synaptophysin was diffuse and strong in case 1 (c), more heterogeneous in cases 2 (f) and 3 (i). Zoom on t-SNE using idat files freely available on GEO (publication PMID: 29539639) enhanced with personal data on extraventricular neurocytomas (EVN) (j). Schematic representation of *KIF5B-ERBB4* fusions in case 1 and in the lung adenocarcinoma described by Guenzi et al. [6] (top) compared to the *KIF5B-NTRK2* fusion reported in extraventricular neurocytoma by Gubbiotti et al. [5] (bottom) (k)

Case 3 concerns a 33-year-old man with migraines since childhood, with recent onset of photophobia and binocular diplopia accompanying the headaches as well as Parinaud's syndrome. MRI revealed a lesion in the right mesencephalon with heterogeneous enhancement after gadolinium injection, extending into the quadrigeminal cistern, pineal region and thalamus (Fig. 1g). Surgical resection showed a biphasic proliferation alternating oligo-like or piloid areas with Rosenthal fibres and areas containing rosette formations centred on amorphous, hyaline material (Fig. 1h). There were no histological signs of aggressiveness. Immunohistochemistry revealed strong Olig2 expression and weaker, focal expression of GFAP and synaptophysin (Fig. 1i). Last follow-up MRI, which took place six years post-surgery, showed no tumour recurrence.

For case 1, DNA-methylation profiling using v2 chip revealed diagnostic scores of 0.98693 for MC RGNT in v12.8 and 0.71257 in v12.5. Cases 2 and 3, analysed using v1 chips, showed diagnostic scores of 0.99851 and 0.78276 in v12.5 and 0.99951 and 0.49826 in v12.8, respectively. t-SNE analysis localised the cases within the MC RGNT

cluster (Fig. 1j). Copy number variation (CNV) analysis showed a flat profile for all three cases.

All three cases underwent next-generation sequencing (NGS) molecular analysis with large panel targeting the *FGFR1* gene, with no alterations of this latter found: DRAGON (SureSelect CD Curie CGP) panel was used for cases 1 and 2 and DNA panel from Toulouse University Hospital for case 3 (Supplementary Tables 1 and 2, online resource). For case 1, no molecular alteration was identified. It is noteworthy that this case could not undergo RNA sequencing due to the limited amount of biopsy material available. Case 2 underwent RNA sequencing using the RNA Illumina TSO500 panel and panel from Toulouse University Hospital while case 3 utilised the Illumina TruSight RNA Fusion panel (Supplementary Tables 3, 4 and 5, online resource).

Case 2 exhibited an *AKT2* E17K mutation, previously reported in thyroid and breast cancers [7, 9]. *AKT2* is a serine/threonine kinase playing a role in the PTEN/PI3K/AKT pathway, including numerous oncogenes, in particular *PIK3CA*, which is frequently mutated in RGNT [1, 8]. The

E17K hotspot mutation occurs at the beginning of exon 3 within the protein's functional domain. A similar mutation has been described in breast, colorectal and ovarian carcinomas in the *AKT1* gene, with experimental studies demonstrating the oncogenic nature of this mutation through overactivation of the protein's kinase activity, thereby setting in motion the cell survival pathway [2]. The significant similarity between the *AKT1* and *AKT2* genes suggests the oncogenic potential of the E17K mutation can be extended to *AKT2*.

Case 3 showed a *KIF5::ERBB4* fusion which was structurally identical to that recently reported in lung adenocarcinoma (Fig. 1k) [6]. The KIF5B protein has already been observed in several oncogenic fusions with other tyrosine kinases [4]. The coiled-coil portion of KIF5B leads to dimerisation, followed by transphosphorylation and activation of its partner's tyrosine kinase domain. The ERBB4 protein belongs to the MAPK signalling pathway. In the brain, no *ERBB4* fusion has yet been reported. However, a fusion between the *KIF5B* gene and *NTRK2*, coding another protein with tyrosine kinase activity, has been described in an extraventricular neurocytoma (Fig. 1k) [5].

RGNT are defined in the 5th edition of the World Health Organization (WHO) classification of central nervous system tumours as biphasic tumours comprising both glial and neurocytic components, with neurocytic rosette or perivascular pseudorosette formations associated with synaptophysin expression. Desirable criteria include the presence of a *FGFR1* mutation with coexisting *PIK3CA* and/or *NF1* mutation. Several teams have reported the constant presence of *FGFR1* mutation in their RGNT series, suggesting that this criterion should appear as essential in the next classification [1, 8]. Nevertheless, our three cases of RGNT proven by DNA-methylation profiling show that the absence of *FGFR1* alteration does not eliminate this diagnosis. Furthermore, two of our cases which underwent exhaustive molecular investigations (NGS and RNA sequencing with a large panel) presented only a single oncogenic event. On the other hand, our observations concur with previous studies on the exclusive localisation of these tumours in the midline which could be a significant diagnostic aid given the lack of specificity of current WHO diagnostic criteria [1].

This study extends the spectrum of RGNT by including tumours with genetic abnormalities other than *FGFR1* mutation. Our finding is important from a therapeutic point of view since there are AKT inhibitors involved in clinical trials as well as second-generation pan-ErbB tyrosine kinase inhibitors [3, 10].

**Supplementary Information** The online version contains supplementary material available at <https://doi.org/10.1007/s00401-024-02779-x>.

**Acknowledgements** We would like to thank the “111 des Arts” Association for their support. Samples were retrieved from Toulouse University Hospital Centre Tumour Bank BB-0033-00014, Montpellier University Hospital Centre Tumour Bank BB-0033-00031 and Bordeaux University Hospital Centre Tumour Bank BB-0033-00036.

**Funding** This article is funded by the association “111 des Arts”.

**Open Access** This article is licensed under a Creative Commons Attribution-NonCommercial-NoDerivatives 4.0 International License, which permits any non-commercial use, sharing, distribution and reproduction in any medium or format, as long as you give appropriate credit to the original author(s) and the source, provide a link to the Creative Commons licence, and indicate if you modified the licensed material. You do not have permission under this licence to share adapted material derived from this article or parts of it. The images or other third party material in this article are included in the article's Creative Commons licence, unless indicated otherwise in a credit line to the material. If material is not included in the article's Creative Commons licence and your intended use is not permitted by statutory regulation or exceeds the permitted use, you will need to obtain permission directly from the copyright holder. To view a copy of this licence, visit <http://creativecommons.org/licenses/by-nc-nd/4.0/>.

## References

- Appay R, Bielle F, Sievers P, Baretts D, Fina F, Boutonnat J et al (2022) Rosette-forming glioneuronal tumours are midline, FGFR1-mutated tumours. *Neuropathol Appl Neurobiol* 48(5):e12813. <https://doi.org/10.1111/nan.12813>
- Carpten JD, Faber AL, Horn C, Donoho GP, Briggs SL, Robbins CM et al (2007) A transforming mutation in the pleckstrin homology domain of AKT1 in cancer. *Nature* 448(7152):439–444. <https://doi.org/10.1038/nature05933>
- Davies BR, Guan N, Logie A, Crafter C, Hanson L, Jacobs V et al (2015) Tumors with AKT1E17K mutations are rational targets for single agent or combination therapy with AKT inhibitors. *Mol Cancer Ther* 14(11):2441–2451. <https://doi.org/10.1158/1535-7163.MCT-15-0230>
- Gow CH, Liu YN, Li HY, Hsieh MS, Chang SH, Luo SC et al (2018) Oncogenic function of a KIF5B-MET fusion variant in non-small cell lung cancer. *Neoplasia* 20(8):838–847. <https://doi.org/10.1016/j.neo.2018.06.007>
- Gubbiotti MA, Santi M, Storm PB, Li M, Xu F, Abdullaev Z et al (2023) First-time identification of a KIF5B-NTRK2 fusion in extraventricular neurocytoma. *J Neuropathol Exp Neurol* 82(3):272–275. <https://doi.org/10.1093/jnen/nlad002>
- Guenzi E, Pluvy J, Guyard A, Nguenang M, Rebah K, Benrahmoune Z et al (2021) A new KIF5B-ERBB4 gene fusion in a lung adenocarcinoma patient. *ERJ Open Res* 7(1):00582–02020. <https://doi.org/10.1183/23120541.00582-2020>
- Pozdeyev N, Gay LM, Sokol ES, Hartmaier R, Deaver KE, Davis S et al (2018) Genetic analysis of 779 advanced differentiated and anaplastic thyroid cancers. *Clin Cancer Res* 24(13):3059–3668. <https://doi.org/10.1158/1078-0432.CCR-18-0373>
- Sievers P, Appay R, Schrimpf D, Stichel D, Reuss DE, Wefers AK et al (2019) Rosette-forming glioneuronal tumors share a distinct DNA methylation profile and mutations in FGFR1, with recurrent co-mutation of PIK3CA and NF1. *Acta Neuropathol* 138(3):497–504. <https://doi.org/10.1007/s00401-019-02038-4>
- Stephens PJ, Tarpey PS, Davies H, Van Loo P, Greenman C, Wedge DC et al (2012) The landscape of cancer genes and mutational processes in breast cancer. *Nature* 486(7403):400–404. <https://doi.org/10.1038/nature11017>

10. Wang S, Li J (2019) Second-generation EGFR and ErbB tyrosine kinase inhibitors as first-line treatments for non-small cell lung cancer. *Onco Targets Ther* 12:6535–6548. <https://doi.org/10.2147/OTT.S198945>

**Publisher's Note** Springer Nature remains neutral with regard to jurisdictional claims in published maps and institutional affiliations.