



HAL
open science

Clinical Evaluation of Use Decellularized Cartilage as a Bio Scaffold for the Repair of Articular Cartilage in Dogs with Osteoarthritis

Ali Wasfi Sadeq, Bassim K Khashjoori

► **To cite this version:**

Ali Wasfi Sadeq, Bassim K Khashjoori. Clinical Evaluation of Use Decellularized Cartilage as a Bio Scaffold for the Repair of Articular Cartilage in Dogs with Osteoarthritis. UTTAR PRADESH JOURNAL OF ZOOLOGY, 2024, 45, pp.9 - 17. 10.56557/upjoz/2024/v45i154216 . hal-04677271

HAL Id: hal-04677271

<https://hal.science/hal-04677271v1>

Submitted on 26 Aug 2024

HAL is a multi-disciplinary open access archive for the deposit and dissemination of scientific research documents, whether they are published or not. The documents may come from teaching and research institutions in France or abroad, or from public or private research centers.

L'archive ouverte pluridisciplinaire **HAL**, est destinée au dépôt et à la diffusion de documents scientifiques de niveau recherche, publiés ou non, émanant des établissements d'enseignement et de recherche français ou étrangers, des laboratoires publics ou privés.



Clinical Evaluation of Use Decellularized Cartilage as a Bio Scaffold for the Repair of Articular Cartilage in Dogs with Osteoarthritis

Ali Wasfi Sadeq ^{a++*} and Bassim K. Khashjoori ^{b#}

^a College of Veterinary Medicine, Basrah University, Iraq.

^b Department of Surgery and Obstetric, College of Veterinary Medicine, Basrah University, Iraq.

Authors' contributions

This work was carried out in collaboration between both authors. Both authors read and approved the final manuscript.

Article Information

DOI: <https://doi.org/10.56557/upjoz/2024/v45i154216>

Open Peer Review History:

This journal follows the Advanced Open Peer Review policy. Identity of the Reviewers, Editor(s) and additional Reviewers, peer review comments, different versions of the manuscript, comments of the editors, etc are available here: <https://prh.mbimph.com/review-history/3749>

Original Research Article

Received: 01/05/2024

Accepted: 03/07/2024

Published: 04/07/2024

ABSTRACT

Articular cartilage lacks the ability to repair itself because it is devoid of blood vessels, nerves, and lymph, and there is no effective treatment that contributes to the cartilage repair process. Osteoarthritis (OA) represents a difficult challenge and an increasing health care burden worldwide. Nowadays, the generation of scaffolds has received great and increasing attention in order to preserve the biophysical environment and bioactive factors. In addition, improved decellularization technology has contributed to providing new promising solutions in the treatment of OA.

⁺⁺ Post Graduate Student;

[#] Assistant Professor;

^{*}Corresponding author: Email: ali.w@uokerbala.edu.iq;

Cite as: Sadeq, Ali Wasfi, and Bassim K. Khashjoori. 2024. "Clinical Evaluation of Use Decellularized Cartilage As a Bio Scaffold for the Repair of Articular Cartilage in Dogs With Osteoarthritis". *UTTAR PRADESH JOURNAL OF ZOOLOGY* 45 (15):9-17. <https://doi.org/10.56557/upjoz/2024/v45i154216>.

Osteoarthritis (OA): Osteoarthritis (OA) is a common and debilitating joint disease that affects dogs worldwide. Treating cartilage abnormalities is challenging due to the restricted regenerative capacity of cartilage and the constraints of existing therapies. Therefore, there is a need for novel and innovative therapies that can target the underlying causes of osteoarthritis and promote cartilage regeneration. This study was conducted to evaluate the efficacy of decellularized cartilage for treating full-thickness defects of articular cartilage in dogs.

Methodology: Methodology ten dogs, healthy adult cross-breed, they were divided into two equal groups, Group I (the control group) was left without treatment. While group II (the DC group) was treated by the application of decellularized cartilage, in this research, we investigated the utilization of decellularized xenograft articular cartilage as treatment can, the dogs were euthanized on day 56 after surgery. Clinical, macroscopic evaluations were performed.

Results: Results statically analysis of pain, lameness at walking and trot showed effectively reduce pain and improve functionality in severe stifle osteoarthritis. Macroscopically, the fibrous tissue appeared to fill the gap with the complete absence of the bone marrow of the decellularized cartilage group compare with control group.

Conclusion: Conclusion decellularized cartilage used as a treatment can effectively reduce pain, enhance movement and accelerate cartilage regeneration.

Keywords: Articular cartilage; osteoarthritis; decellularized cartilage; bio-scaffold dogs.

1. INTRODUCTION

The articular cartilage is connective tissue that loses blood arteries, veins, and lymphatic tissue. It is very specialised to adapt to harsh biomechanical environments [1]. The hyaline articular cartilage tissues are extensively hydrated and cover the contact surfaces of joint, which form parts of synovial articulation. It functions to carry and absorb the load, so as to facilitate efficient frictionless operation of other elements in the skeleton. The limited natural healing ability of cartilage leading to osteoarthritis [2]. Osteoarthritis is a common disease that damages all joint structures and frequently affects the stifle joint. Cartilage has reduced healing capabilities due to its intrinsic low vascularity, which leads to a diminished replicative capability of chondrocytes. Dogs will often have problems with their complex synovial stifle joint. When the cruciate ligament ruptures and the patella dislocates, osteoarthritis of the stifle joint principally results. Osteoarthritis is progressive, causing severe pain and significantly reducing your dog's quality of life [3]. Cartilage tissue regeneration is becoming a hopeful approach for repairing damaged cartilage. Scaffolds for repairing cartilage have been extensively studied for a long time as an essential part of tissue engineering [4]. The scaffolds consist of many components such as collagen, gelatin, chitosan, fibrin, hyaluronan, chondroitin sulphate, porous ceramic, bio glass, and others [5]. There is still debate on which scaffold is the most effective one when it comes

to cartilage repair. Despite having potential off-target effects from cell-based therapies, decellularization technology offers a method to eliminate specific cells from tissues while maintaining ECM. This process gives rise to scaffolds with low immunogenicity and highly desirable biological and biomechanical properties [6]. Generally, cartilage tissue is first treated mechanically, which involves tissue smashing and submitting the tissue to freezing and thawing procedures more than once. This is then followed by additional processing through other means like chemically that actually helps to get rid of cellular tissues. Decellularized scaffolds are implanted to knee joint cartilage injuries to support for the repair of the cartilage and enhance integration of the surrounding tissues through the infiltration of cells and deposition of ECM [7-9]. During the procedure of cartilage regeneration with decellularized cartilage scaffolds, three key steps are included: growing new cells and implanting them in the tissue; replacement of the damaged cartilage; and filling the hole left by the tissue [10]. For instance, articular cartilage has comparatively poor intrinsic healing capabilities and as such, minor damages and abrasions to the chondral or osteochondral tissues may result to severe degenerative (OA) depending on the kind and magnitude of the injury caused to the cartilage. In the course of time, such techniques as autologous chondrocyte transplantation, arthroplasty, subchondral drilling, and microfractures and total knee arthroplasty become the main of surgical intervention, though possessing

a number of drawbacks [11]. Advancements in current treatments, this is still prove to be a real challenging activity in fix of articular cartilage deficits. Therefore, there is a need for novel and innovative therapies that can target the underlying causes of osteoarthritis and promote cartilage regeneration, decellularized cartilage from animal donors with different species have several advantages: A xeno-grafts do not regress and they maintain their volume as a result of non-resorbable behaviour. Thus, many of the orthopaedic surgeries from today using these materials with low rates of replacement [12]. B. Related donor tissue is easily accessible and we have more tissue availability and are less costly as compared to allogeneic transplants. The price of commercially available xenografts is approximately one-tenth that of allografts. In addition, complex sterilisation processes generally result in longer shelf lives [13]. A major advantage is that the expanded cartilage can be retained for several years after surgical implantation. Unlike allografts, which tend to resorb over time. Many studies have shown that natural antibodies that react with α -1,3-Gal epitopes are involved in the induction of hyperacute rejection. The primary cause of this rejection is the activation of the classical complement pathway within the host, Inactivating the GGTA1 gene can greatly reduce this initial rejection step that shown in xenograft by decellularize process [14]. Aime of study, based on this knowledge, we examined the effectiveness of decellularized cartilage in the repair of articular cartilage defects of dog's stifle joint. The success of this study may have significant clinical implication for patients in future.

2. METHODOLOGY

2.1 Experimental Animals Design

ten healthy cross-breed dogs aged 1-2 years and weighing average 20 kg were used. The animals were housed in individual enclosures and administered with 0.2 mg/kg of Ivermectin [15]. The animals were divided into two equal group. Both groups making full thickness articular cartilage defect, diameter was 8 mm and depth of 4 mm in medial femoral condyle. Group I (control group) was left without treatment. In group II (DC group) was treated by filled the defect site by decellularization cartilage.

2.2 Chondral Tissue Harvest

Fresh whole femoral condyles of calves were collected from a slaughterhouse immediately after slaughter and then transported on ice to laboratory facilities. Tissues and muscles on the harvested joint were stripped. Condyles were lavage with sterile 0.9% normal saline to remove debris and blood and then placed in 250 mL biopsy cup. Then cutting medial and lateral femoral condyle and condyle fossa using surgical blade into flakes by a surgical blade [16].

2.3 Decellularization Cartilage

The modified procedures were used to decellularize the bovine chondral graft flakes. In summary, the samples were washed three times in a PBS solution with 200 U/mL penicillin. After that, the samples were placed in PBS and frozen in liquid nitrogen at -196°C . In the end, the samples were quickly thawed at 37°C . The freezing and thawing process was repeated three times. The frozen-thawed graft pieces were soaked in a solution that included 0.02% Tris/EDTA and a protease inhibitor. then, the sample incubated at 4°C for 48 hrs. Subsequently, the tissues were transferred to a mixture of distilled water with 0.1% Triton X-100 or 2% SDS and stirred for 1 hrs in ice. After PBS wash, the tissues rinsing a DNase/RNase PBS solution for 24hrs. Subsequently, the tissue samples were treated with a 0°C . Samples were washed for thirty minutes in distilled water, followed by a staining with 02% Tris/EDTA solution for the next forty-eight hours. Then the tissues were washed in PBS and the second PBS washing was followed by its incubation in physiological saline at 4 Celsius till used. The cartilage flakes were then debrided by using sterile scissors in such a manner that all the specimens were chipped into small particles measuring $1\text{-}2\text{ mm}^3$ in size. Subsequently, the collected samples were rinsed with physiological saline solution and assessed for gross morphologic features under haematoxylin and eosin staining protocol [H & E] and surface electrical microscopy [17].

2.4 Surgical Procedure

The surgical procedure was conducted in a completely sterile environment. Prior to the

Table 1. The criteria for evaluating clinical signs and activity in osteoarthritis dog [18]

Lameness at walk	
1	No lameness; regular weight-bearing on all strides observed
2	Mild lameness with partial weight-bearing
3	Obvious lameness with partial weight-bearing
4	Marked lameness with no weight-bearing
Lameness at trot	
1	No lameness
2	Mild lameness
3	lameness with partial weight-bearing
4	Marked lameness with no weight-bearing
Pain at palpation/mobilisation	
1	No pain was elicited on palpation/mobilisation of the affected joint.
2	Mild pain elicited, e.g., turns the head in recognition.
3	Moderate pain elicited, e.g., pulling the limb away.
4	Severe pain elicited, e.g., vocalises or becomes aggressive
5	Severe pain elicited, e.g., not allowing the examiner to palpate/mobilise the joint.

procedure, all animals underwent a 12-hour period of food deprivation and were allowed unrestricted access to water for a maximum of 5 hours. Prior to the surgical treatment, all dogs received a prophylactic antibiotic (penicillin-streptomycin) at a dosage of 8 mg/kg intramuscularly. then, the dogs were administered a sedative consisting of a mixture of xylazine-hydrochloride 2% at a dose of 5 mg/kg body weight intramuscularly (I/M) and ketamine-hydrochloride 10% at a dosage of 10 mg/kg body weight I/M. The dogs were placed in a sideways lying posture on the surgical table, and the hair on the left hind leg was removed and cleansed to prepare for a sterile procedure. Subsequently, a traditional lateral approach was executed by creating an incision through the skin, subcutaneous tissue, lateral fascia, and joint capsule using a #11 scalpel blade, Metzenbaum scissors, and a combination of careful and accurate cutting. The trochlear groove was uncovered, and the location of the defect was chosen at the midpoint of the trochlear groove. A full-thickness chondral defect (cylindrical defect) (8mm diameter by ~ 4mm deep) was induced by using a manual drill. The surgical site was then flushed with standard saline solution (0.9% NaCl) to remove debris. Dogs were randomly divided into two equal groups, The first group left without treatment, The second group was treated with DC only. [18]. After 56 days had passed from the initial surgery, dogs were euthanised, and joints were harvested for clinical and macroscopic evaluation.

2.5 Clinical Evaluation

All surgeries were completed, and no intraoperative and postoperative complications

were experienced. After surgery, dogs were observed and monitored for lameness and pain assessment. Their movements were observed and documented in the open field, as they moved and ran freely, in order to evaluate their gait. Simultaneously, the dogs' discomfort was assessed using palpation, which included observing the following behaviours: fast and shallow breathing, frequent changes between standing and laying down, quick movements of the affected limb, and attempts to bark and attack. The grades used to assess both evaluations were developed by Catarino et al.[19]. In this scenario, clinical parameters were evaluated: the grade of lameness at walking, lameness at trot, pain on days 14, 28, 42, and 56. Table 1 [20].

2.6 Macroscopic Evaluation

After euthanasia on day 56, high-resolution digital photographs of the articular surface of the femoral condyle were taken. Macroscopic examination of cartilage repair has been depicted Methodically

3. RESULTS AND DISCUSSION

3.1 Clinical Evaluation: Lameness Analysis Results

3.1.1 Pain analysis results

Pain analysis results showed effectively reduced pain and improve functionality in severe stifle osteoarthritis of the decellularized cartilage group compare with control group.

3.2 Macroscopic Evaluation

After euthanasia on day 56, Digital high-resolution photographs of the femoral condyle articular surface were taken. Macroscopic examination of the repair of the cartilage has been carried out based on gross morphology, which showed a variation in the depth of the hole at the graft site; this was treatment-

dependent, and accordingly, the control group shows the minimum healing process where the defect cavity still apparent in the site of operation indicating no or minimum healing (Fig. 1, A). The DC group showed more advanced healing in which the fibrous tissue appeared to fill the gap with the complete absence of the bone marrow (Fig. 1, B).

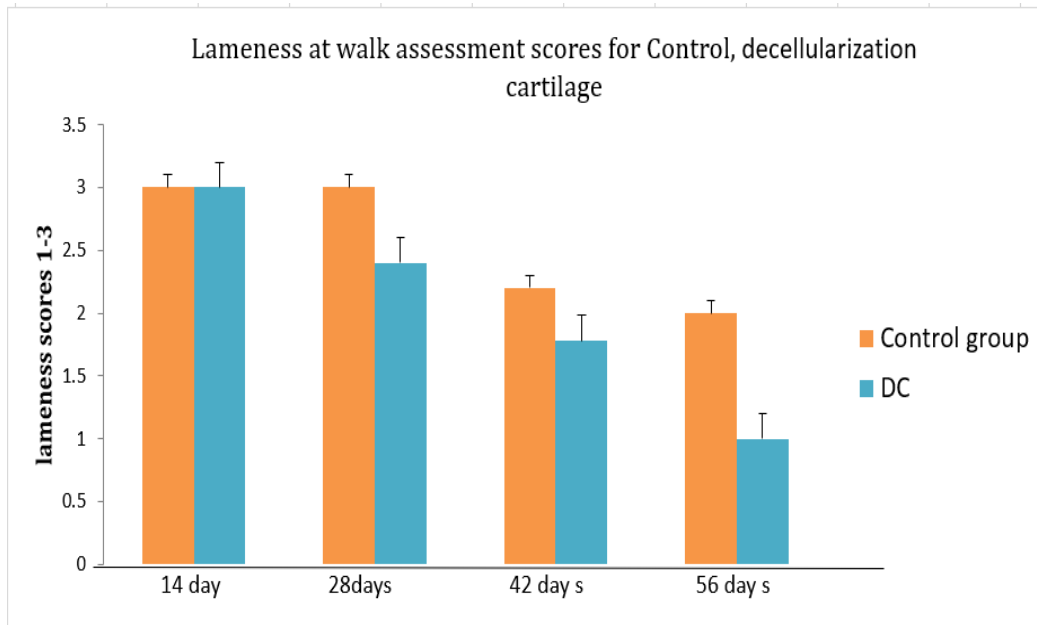


Chart 1. lameness at walk

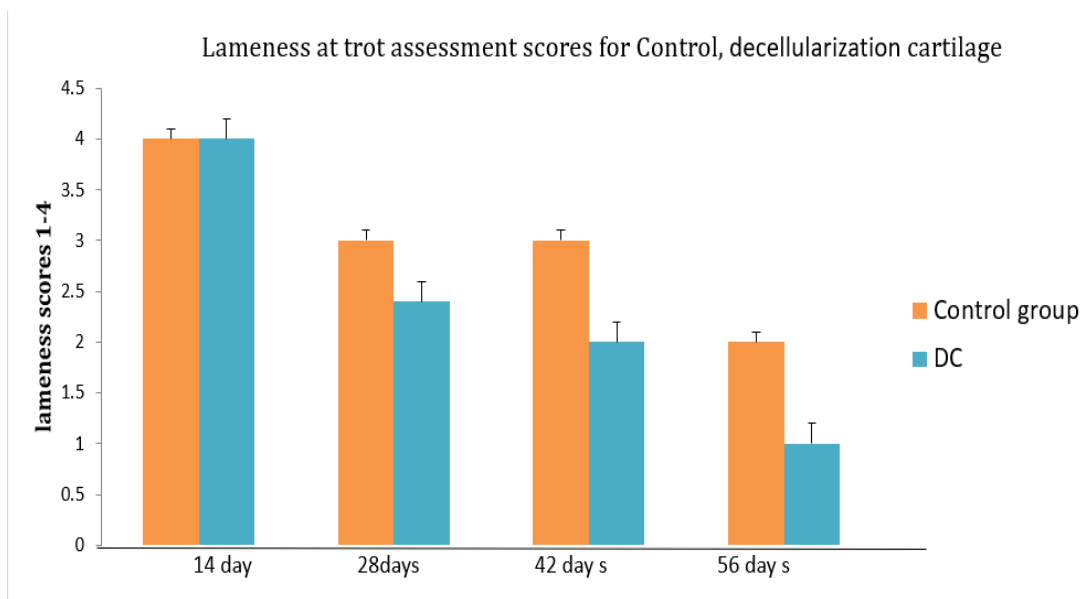


Chart 2. lameness at trot

In this direction, this study was undertaken to investigate firstly the novel treatment of osteoarthritis which experimentally induced in dogs. The development of osteoarthritis was apparent in terms of the highest significant [$p < 0.05$] lameness score in untreated dogs during the whole experimental duration. The lameness scores were demonstrated in control group; hence, the animals could not raise their legs and move a few steps. The treated group that received decellularized cartilage had significantly the lowest lameness and pain scores during the

experimental duration. Another significant clinical sign of osteoarthritis was pain during palpation. Similarly, the recorded results revealed that the positive control group with no treatment had significantly [$p < 0.05$] the highest score for pain on palpation during the whole experimental duration. However, groups that received treatment decellularization cartilage had lower scores. Reducing pain and improving limb function at days 28, 42, and 56 in dogs of the group treated with decellularized cartilage, The aforesaid changes were overwhelmed in group

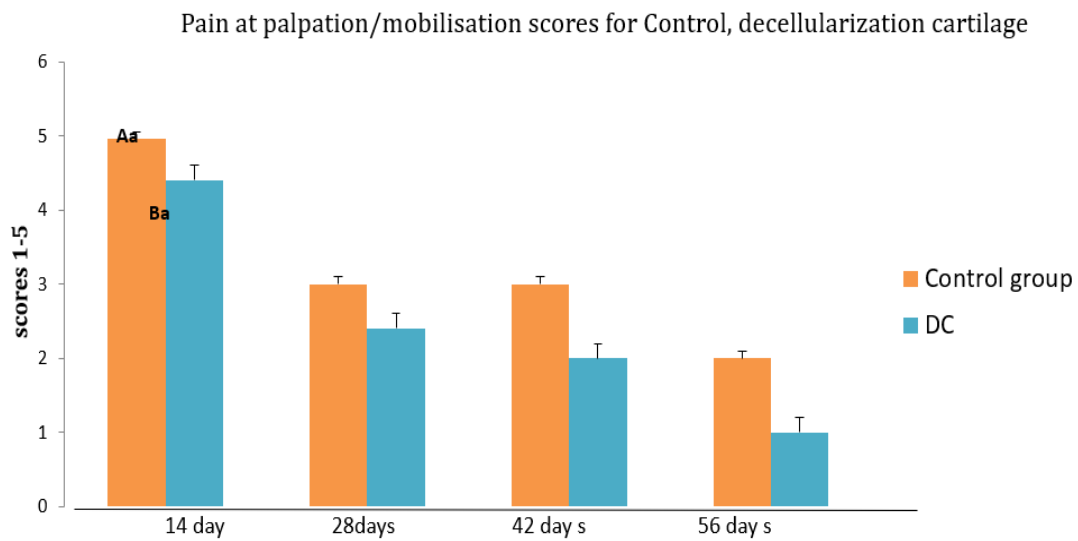


Chart 3. Pain scor

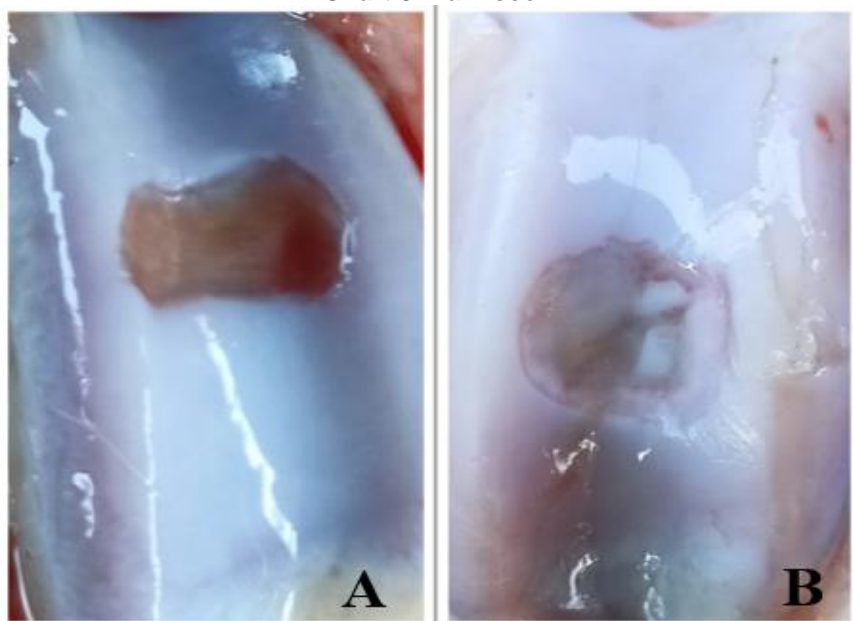


Fig. 1. Shown [A] control group, [B] Decellularize cartilage group

treated by acellular cartilage, respectively, these two groups showed marked cartilage development which appear to be more fixed in the grafting site, surrounded by area of intensive collage deposition, the amount of the newly generated cartilage was more in the second group than in the first one. In this study, cellular residues were removed through an optimized decellularization step, thus eliminating the possibility of immune rejection. The morphology and structure of the tissue were preserved and the structure of the osteochondral unit was maintained. These results are identical to what mentioned by Cheng et al., [21].

Macroscopic, The control group was showed the minimum healing process where the defect cavity still apparent in the site of operation indicating no or minimum healing due to cartilage has reduced healing capabilities, its intrinsic low vascularity, which leads to a diminished replicative capability of chondrocytes, compare with other group that observed by Bunzendahl et al. [3]. The Decellularization cartilage group showed more advanced healing in which the fibrous tissue appeared to fill the gap with the complete absence of the bone marrow, The [DC] are an excellent choice for creating a tissue-engineered cartilage scaffold for cartilage regeneration because they maintain the original structure and ECM components of cartilage tissue. This finding is consistent with Liu et al. [22].

4. CONCLUSION

The current study revealed that decellularized cartilage exerted anti-osteoarthritis effectiveness by preventing the articular cartilage degradation in dogs with osteoarthritis. because decellularized cartilage has less ethical and safety constraints, it may be rapidly implemented in clinics as an effective and practical treatment for osteoarthritis. All things considered, this work offers new insight into the anti-articular cartilage degrading effectiveness of decellularized cartilage and points to it being a viable and effective scaffolded therapy option for the treatment of osteoarthritis.

DISCLAIMER (ARTIFICIAL INTELLIGENCE)

Authors hereby declare that NO generative AI technologies such as Large Language Models (ChatGPT, COPILOT, etc) and text-to-image generators have been used during writing or editing of manuscripts.

ACKNOWLEDGEMENTS

The authors acknowledge the Deanship, Veterinary medicine college of Basrah, All surgery department faculty staff who helped to complete this research.

ETHICAL APPROVAL

All procedures used in this study were approved by the Ethics Committee (42/2023), at the College of Veterinary Medicine, University of Basrah.

COMPETING INTERESTS

Authors have declared that no competing interests exist.

REFERENCES

1. Nie X, Chuah YJ, Zhu W, He P, Peck Y, Wang DA. Decellularized tissue engineered hyaline cartilage graft for articular cartilage repair. *Biomaterials*. 2020;235:119821. Available:<https://doi.org/10.1016/j.biomaterials.2020.119821>
2. Yang X, Li S, Ren Y, Qiang L, Liu Y, Wang J. 3D printed hydrogel for articular cartilage regeneration. *Composites Part B: Engineering*. 2022;237(15).
3. Bunzendahl L, Moussavi A, Bleyer M, Dehnert J, Boretius S. Histological findings and T2 Relaxation time in canine menisci of elderly dogs—An Ex Vivo Study in Stifle Joints. *Vet. Sci. J.* 2023 ;10.
4. Chen Xia, Sheng Mei, Chenhui Gu, Lin Zheng, Chen Fang, Yiling Shi, Kaiwei Wu, Tongtong Lu, Yongming Jin, Xianfeng Lin, Pengfei Chen, Decellularized cartilage as a prospective scaffold for cartilage repair, *Materials Science and Engineering: C*. 2019;101:588-595. Available:<https://doi.org/10.1016/j.msec.2019.04.002> ISSN:0928-4931.
5. Lin X, Chen J, Qiu P, Zhang Q, Wang S, Su M, Chen Y, Jin K, Qin A, Fan S, Chen P, Zhao X. Biphasic hierarchical extracellular matrix scaffold for osteochondral defect regeneration, *Osteoarthritis and Cartilage*. 2018;26(3): 433-444,

- Available:<https://doi.org/10.1016/j.joca.2017.12.001>.
ISSN 1063-4584.
Available:<https://www.sciencedirect.com/science/article/pii/S1063458417313523>)
6. Gundry M, Hopkins S, Knapp K. A review on bone mineral density loss in total knee replacements leading to increased fracture risk. *Clinic Rev Bone Miner Metab.* 2017;15:162–174.
Available:<https://doi.org/10.1007/s12018-017-9238-4>
 7. Heyong Yin, Yu Wang, Xun Sun, Ganghua Cui, Zhen Sun, Peng Chen, Yichi Xu, Xueling Yuan, Haoye Meng, Wenjing Xu, Aiyuan Wang, Quanyi Guo, Shibi Lu, Jiang Peng, Functional tissue-engineered microtissue derived from cartilage extracellular matrix for articular cartilage regeneration, *Acta Biomaterialia.* 2018;77:127-141.
ISSN:1742-7061.
Available:<https://doi.org/10.1016/j.actbio.2018.07.031>.
 8. Bolaños RV, Cokelaere SM, McDermott JE, Benders KE, Gbureck U, Plomp SG, Weinans H, Groll J, Van Weeren PR, Malda J. The use of a cartilage decellularized matrix scaffold for the repair of osteochondral defects: the importance of long-term studies in a large animal model. *Osteoarthritis and cartilage.* 2017;25(3):413-20.
 9. Chu W, Hu G, Peng L, Zhang W, Ma Z. The use of a novel deer antler decellularized cartilage-derived matrix scaffold for repair of osteochondral defects. *Journal of Biological Engineering.* 2021;15:1-2.
 10. Li Z, Zhu T, Fan W. Osteochondral autograft transplantation or autologous chondrocyte implantation for large cartilage defects of the knee: a meta-analysis. *Cell Tissue Bank.* 2016;17:59–67.
Available:<https://doi.org/10.1007/s10561-015-9515-8>
 11. Nishitani K, Nakagawa Y, Nakamura S, Mukai S, Kuriyama S, Matsuda S. Resection-induced leveling of elevated plug cartilage in osteochondral autologous transplantation of the knee achieves acceptable clinical results. *The American Journal of Sports Medicine.* 2018;46(3):617-622.
DOI: 10.1177/0363546517739614
 12. Moriarty S U.S. reaches historic milestone of 1 million transplants; 2022.
Available:<https://unos.org/news/u-s-reaches-1-million-transplants/> UNOS. Accessed On:23 November 2022
 13. Koons GL, Diba M, Mikos AG Materials design for bone-tissue engineering. *Nat Rev Mater.* 2020;5:584–603.
Available:<https://doi.org/10.1038/s41578-020-0204-2>.
 14. Tritschler H, Fischer K, Seissler J, Fiedler J, Halbgebauer R, Huber-Lang M, Schnieke A, Brenner RE. New Insights into Xenotransplantation for Cartilage Repair: Porcine Multi-Genetically Modified Chondrocytes as a Promising Cell Source. *Cells.* 2021;10(8):2152.
Available:<https://doi.org/10.3390/cells10082152>.
 15. Hamza, Abdulsatar. Histopathological observations of efficacy of a cellular cartilage matrix powder on repair cartilage defects in dog models. 2020;20:1031-1037.
DOI:10.35124/bca.2020.20.1.1031
 16. Kang D, Shin S, Jang J, Park H, Lee J, Wang S. Decellularization of Human Nasal Septal Cartilage for the Novel Filler Material of Vocal Fold Augmentation. *Journal of Voice.* 2017; 31(1):127-127.
 17. Landry J, Maza P. Effectiveness of the anaesthetic combination of tiletamine, zolazepam, ketamine and xylazine for the sterilisation of street dogs in field clinics, *Vet Rec Case Rep;* 2020.
DOI: 10.1136/vetreccr-2019-000953.
 18. Alcaide-Ruggiero L, Molina-Hernandez V, Morgaz J, Fernandez-Sarmiento J, Granados M, Navarrete-Calvo R. Particulate cartilage and platelet-rich plasma treatment for stifle chondral defects in sheep. *Stifle Surgery, Sports Traumatology, Arthroscopy J;* 2023.
 19. Catarino J, Carvalho P, Santos S, Angela Martins A, Requicha J. Treatment of canine osteoarthritis with allogeneic platelet-rich plasma: review of five cases. *Open Veterinary Journal.* 2020;10(2):226-231.
 20. Lee E, Lee MI, Kim S, Kang BJ. 2023. Spontaneous osteoarthritis in dogs - clinical effects of single and multiple intra-articular injections of hyaluronic acid. *Acta Scientiae Veterinarian.* 2023;51:1901.
 21. Cheng J, Shen K, Zuo Q, Yan K, Zhang X, Liang W, Fan WA. xenogeneic

- decellularized multiphasic scaffold for the repair of osteochondral defects in a rabbit model. *Materials & Design J.* 2023;225.
22. Liu Y, Shah KM, Luo J. Strategies for articular cartilage repair and regeneration. *Frontiers in Bioengineering and Biotechnology.* 2023;9:770655. Available:<https://doi.org/10.3389/fbioe.2021.770655>

Disclaimer/Publisher's Note: The statements, opinions and data contained in all publications are solely those of the individual author(s) and contributor(s) and not of the publisher and/or the editor(s). This publisher and/or the editor(s) disclaim responsibility for any injury to people or property resulting from any ideas, methods, instructions or products referred to in the content.

© Copyright (2024): Author(s). The licensee is the journal publisher. This is an Open Access article distributed under the terms of the Creative Commons Attribution License (<http://creativecommons.org/licenses/by/4.0>), which permits unrestricted use, distribution, and reproduction in any medium, provided the original work is properly cited.

Peer-review history:
The peer review history for this paper can be accessed here:
<https://prh.mbimph.com/review-history/3749>