



**HAL**  
open science

# Full Digital Workflow for Aesthetic Rehabilitation of the Upper Teeth: A Case Report

Gilbert Jorquera, Louis Hardan, Rim Bourgi, David Arias, Carlos Enrique Cuevas-Suárez, Krystyna Pietrzycka, Monika Lukomska-Szymanska

## ► To cite this version:

Gilbert Jorquera, Louis Hardan, Rim Bourgi, David Arias, Carlos Enrique Cuevas-Suárez, et al.. Full Digital Workflow for Aesthetic Rehabilitation of the Upper Teeth: A Case Report. Applied Sciences, 2024, 14 (13), pp.5957. 10.3390/app14135957 . hal-04672966

**HAL Id: hal-04672966**

**<https://hal.science/hal-04672966v1>**

Submitted on 19 Aug 2024

**HAL** is a multi-disciplinary open access archive for the deposit and dissemination of scientific research documents, whether they are published or not. The documents may come from teaching and research institutions in France or abroad, or from public or private research centers.







L'archive ouverte pluridisciplinaire **HAL**, est destinée au dépôt et à la diffusion de documents scientifiques de niveau recherche, publiés ou non, émanant des établissements d'enseignement et de recherche français ou étrangers, des laboratoires publics ou privés.



Distributed under a Creative Commons Attribution 4.0 International License

Case Report

# Full Digital Workflow for Aesthetic Rehabilitation of the Upper Teeth: A Case Report

Gilbert Jorquera <sup>1</sup>, Louis Hardan <sup>2</sup>, Rim Bourgi <sup>2,3</sup>, David Arias <sup>4</sup>, Carlos Enrique Cuevas-Suárez <sup>5</sup>,  
Krystyna Pietrzycka <sup>6</sup> and Monika Lukomska-Szymanska <sup>7,\*</sup>

<sup>1</sup> Department of Oral Rehabilitation, Facultad de Odontología, Universidad de Los Andes, Santiago 7620001, Chile; giorquera@uandes.cl

<sup>2</sup> Department of Restorative Dentistry, School of Dentistry, Saint-Joseph University, Beirut 1107 2180, Lebanon; louis.hardan@usj.edu.lb (L.H.); rim.bourgi@net.usj.edu.lb (R.B.)

<sup>3</sup> Department of Biomaterials and Bioengineering, INSERM UMR\_S 1121, University of Strasbourg, 67000 Strasbourg, France

<sup>4</sup> Independent Researcher, Santiago 7620001, Chile; od.davidarias@gmail.com

<sup>5</sup> Dental Materials Laboratory, Academic Area of Dentistry, Autonomous University of Hidalgo State, San Agustín Tlaxiaca 42160, Mexico; cecuevas@uaeh.edu.mx

<sup>6</sup> Department of Endodontics, Medical University of Lodz, 92-213 Lodz, Poland; krystyna.pietrzycka@umed.lodz.pl

<sup>7</sup> Department of General Dentistry, Medical University of Lodz, 92-213 Lodz, Poland

\* Correspondence: monika.lukomska-szymanska@umed.lodz.pl

**Abstract:** The present case report presents a digital workflow for designing an aesthetic rehabilitation of the upper anterior teeth in an adult male. The patient suffered from a gummy smile resulting from an unfavorable ratio between upper lip length and gingiva/tooth display. In addition, the tooth shapes, color, and position were not accepted by the patient. The treatment planning included gingivectomy based on a digitally designed PMMA guide performed using a soft tissue SOGA laser (Shenzhen Soga Technology Co., Ltd., Shenzhen, China). The preparation was guided by the plastic guides for preparation control created digitally in Exocad software (Rijeka 3.1. Darmstadt, Germany) and printed in three-dimensional plastic. Next, both arches and maximum intercuspation were scanned. The milled lithium disilicate veneers were manufactured using CAD-computer-aided manufacturing (CAM) equipment. The restorations were cemented using a translucent light-cure resin cement (RelyX Universal, 3M ESPE, St. Paul, MN, USA). Next, occlusion adjustment and polishing were executed. Based on the present case report, it can be assumed that the application of digital techniques allows us to achieve an aesthetic and functional result with reduced work time and errors. Emphasizing the clinical impact, these methods enhance patient satisfaction and treatment accuracy in intricate aesthetic rehabilitations.

**Keywords:** case reports; digital smile design; digital workflow; gingival display; gummy smile; veneers



**Citation:** Jorquera, G.; Hardan, L.; Bourgi, R.; Arias, D.; Cuevas-Suárez, C.E.; Pietrzycka, K.; Lukomska-Szymanska, M. Full Digital Workflow for Aesthetic Rehabilitation of the Upper Teeth: A Case Report. *Appl. Sci.* **2024**, *14*, 5957. <https://doi.org/10.3390/app14135957>

Academic Editor: Arthur R. G. Cortes

Received: 10 June 2024

Revised: 2 July 2024

Accepted: 5 July 2024

Published: 8 July 2024



**Copyright:** © 2024 by the authors. Licensee MDPI, Basel, Switzerland. This article is an open access article distributed under the terms and conditions of the Creative Commons Attribution (CC BY) license (<https://creativecommons.org/licenses/by/4.0/>).

## 1. Introduction

Recently, modern technologies have been introduced into dentistry. Computer design software has progressed into an effective means of treatment planning and communication between clinicians, patients, and dental technicians. Smile design can nowadays be performed with the use of digital technology, namely computer software such as PowerPoint (Microsoft Corp., Redmond, WA, USA), Keynote (Apple Inc., Cupertino, CA, USA), Photoshop software from Adobe Systems (San Jose, CA, USA), or digital smile design (DSD), combining digital photography and imaging software [1].

Regardless of the system employed, the design should be based on macro- and microesthetics concepts [2–4]. Macroesthetics refers to the interrelationships between the face, lips, gingiva, and teeth, while microesthetics refers to the individual tooth. Both elements should be carefully considered and evaluated in order to create a harmonious and esthetic

smile. The gummy smile and improper teeth shape are major patient concerns. The former is an undesirable relation between the length of the upper lip and the display of the gingiva and teeth. It can result from short teeth, passive eruption, gingival overgrowth [5], insufficient length of the upper lip, as well as hyper-elevation of the muscles of the upper lip [6,7]. Crown lengthening can be utilized as a standalone aesthetic surgery to extend the clinical crown when the incisal edge location is ideal. Hence, crown lengthening along with restorative therapy is indicated when also the position of the incisal edges should be improved.

Improvements in ceramics' physical and optical characteristics, as well as adhesive cementation techniques, have unquestionably made it possible to adhere to three crucial criteria: aesthetic, function, and bioeconomic principles. Ceramics have been employed because of their biocompatibility, biomimicry, lifespan, and excellent resistance, especially when reinforced with lithium disilicate [8,9].

It has turned out that the results are more predictable. According to Pneumas et al. [10], the survival rate of porcelain veneers varied from 92% after five years to 64% at ten years. Through their 20-year retrospective analysis, Beier et al. [11] calculated the 90% survival rate of porcelain veneers at 12 to 13 years.

As long as the procedure is carried out in accordance with a precise treatment plan and a properly adhered-to protocol during the clinical and laboratory stages, lithium disilicate veneers provide good aesthetics with predictable and long-lasting outcomes [12,13].

Overall, tooth wear was considered as a non-carious loss of tooth structure. This irreversible phenomenon is the result of varied mechanisms like the dissolution of hard tissues with acidic constituents (known as dental erosion), contact with exogenous materials (known as dental abrasion), or tooth-to-tooth contact (known as dental attrition) [14]. These mechanisms often act in synergy or chronologically, which might increase tooth wear at a slightly young age [15]. This condition causes copious problems like increased tooth hypersensitivity, variations in the vertical dimension of occlusion with probable functional defect, pulp involvement, and possibly reduced aesthetic look [16]. To rehabilitate a worn dentition, ceramics can be used [17].

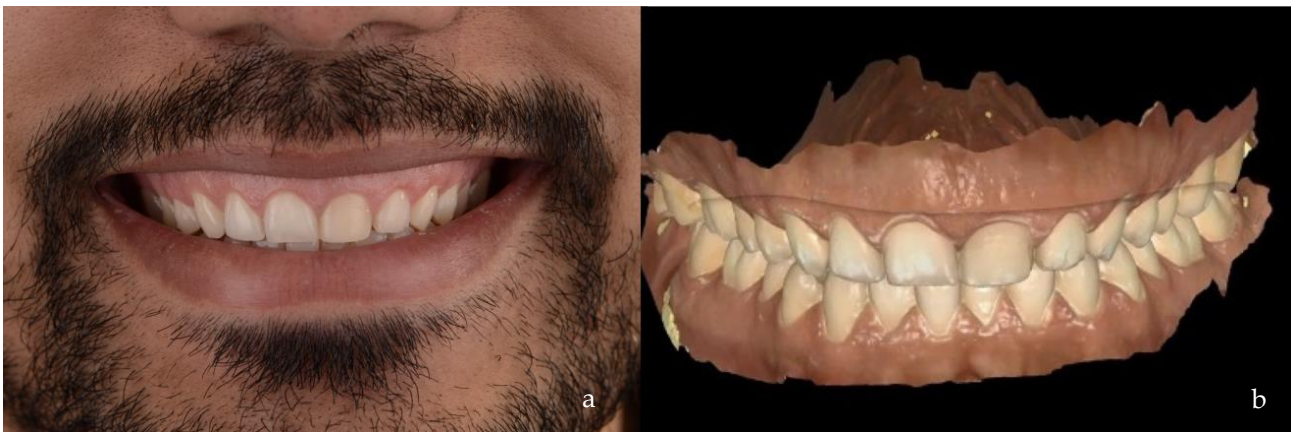The implementation of computer-aided design and computer-aided manufacturing (CAD/CAM) technologies can be utilized at the step of planning and treatment to provide predictable prosthodontic rehabilitation [18]. This article outlines a step-by-step process for diagnosing a patient with a gummy smile, treatment planning, and optimizing the final aesthetic result with the use of digital technology.

## 2. Materials and Methods

### 2.1. Visit I Diagnosis and Treatment Planning

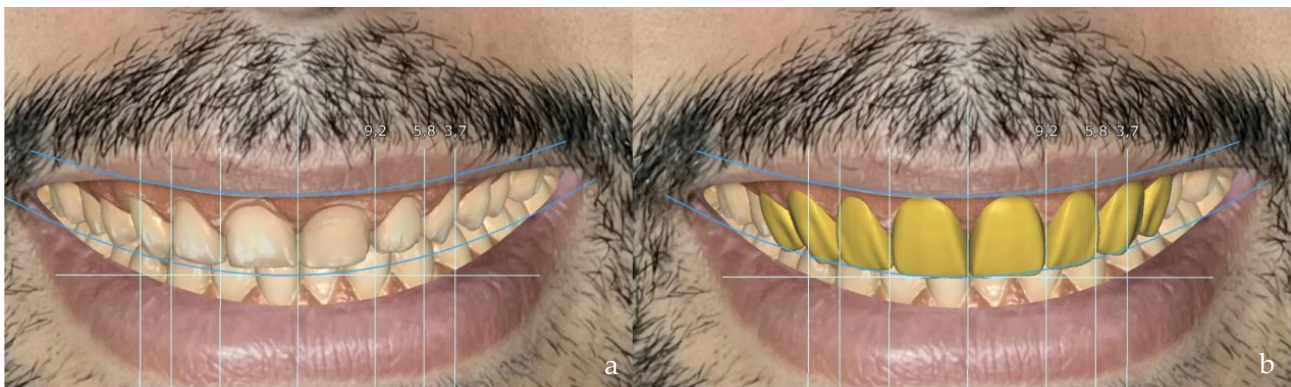
A 39-year-old male patient in good health, without medical conditions affecting treatment, presented with an unaesthetic smile characterized by excessive gingival display and reduced tooth length due to abrasion (medical history was insignificant). After intraoral examination, the patient was diagnosed with a gummy smile, decreased teeth length and negative smile line, and teeth inclined in the occlusal plane. Additionally, tooth 21 had a discolored resin restoration. Extra- and intra-oral photographs and intra-oral scans (IOS) with CEREC PrimeScan (software 5.2, Dentsply Sirona, Bensheim, Germany) were performed (Figure 1). Both arches and the patient's occlusal relationship were scanned. Intraoral scans and photos enable not only accurate analysis of the smile but also the discussion of the treatment plan with the patient. Additionally, cone-beam computed tomography (CBCT) scans (Axeos; Dentsply Sirona, Fleury-sur-Orne, France) were performed to provide adequate information before gingivectomy.

The treatment plan included an aesthetic gingivectomy procedure to restore the ideal length of the anterior teeth and final restoration with CAD-CAM veneers to improve the shape and color of anterior teeth and premolars.



**Figure 1.** Intraoral photo. (a) Frontal view; (b) frontal view of the scanned teeth.

The DSD was performed in the Exocad software (Rijeka 3.1. Darmstadt, Germany). It consisted of the virtual correction of the gingival smile, alignment of the upper occlusal plane, and modifying the size of the upper teeth (first premolars, canines, lateral, and central incisors) with thin ceramic veneers. Next, a digital mock-up was presented to the patient (Figure 2).



**Figure 2.** Intraoral scan superimposed on the intraoral photo. (a) Before treatment; (b) digital mock-up.

## 2.2. Visit II (After 7 Days)

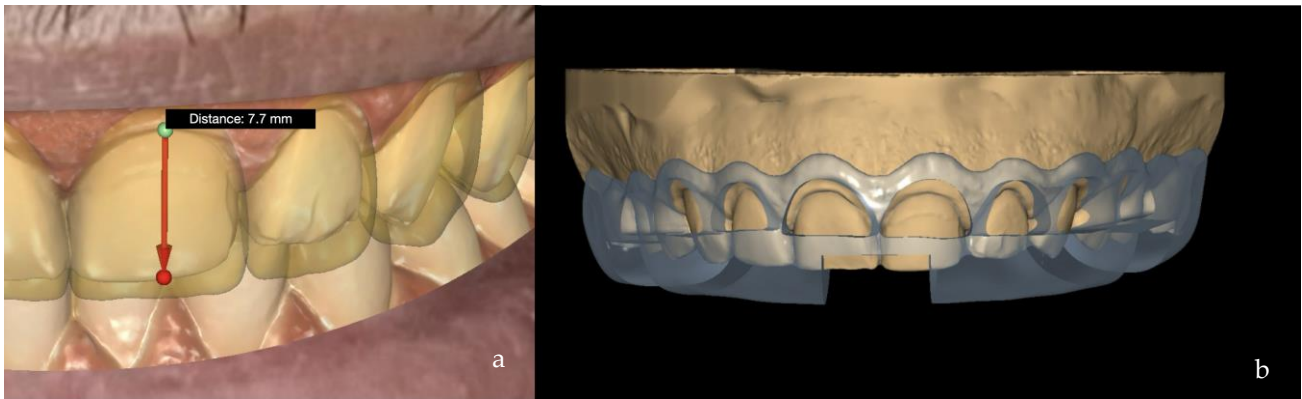
### 2.2.1. Gingivectomy Procedure

A virtual planning of the gingivectomy procedure was performed based on periodontal examination and CBCT. The amount of soft tissue to be removed was determined with respect to the shape and size of the designed veneers and the biological width.

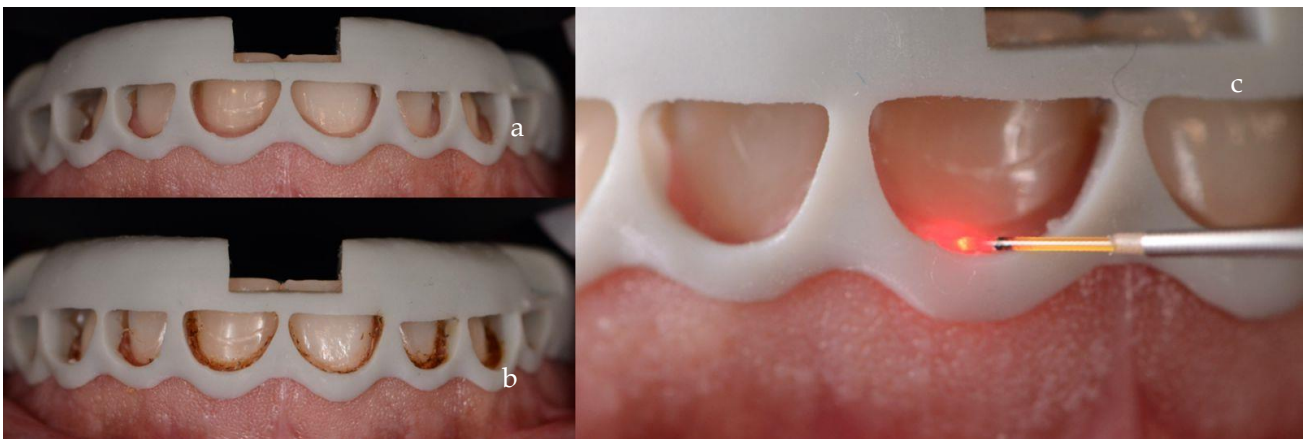
### 2.2.2. Surgical Guide

The guide was designed in Exocad (Rijeka 3.1. Darmstadt, Germany), considering its upper cutting limit according to the shape and size of the designed restorations (Figure 3). A three-dimensional (3D) printer (ProJet MJP 3600 Dental 3D systems) was used to print the guide.

Next, the guide was transferred to the patient's mouth to marginal gingival tissue to be removed (Figure 4). Check windows were incorporated into the design to ensure their correct seating to the teeth. There was an additional window revealing the incisal edges of central incisors to verify their position.



**Figure 3.** (a) Teeth simulation in Exocad. The red dot indicates the original tooth level, the green dot indicates the gingival margin, while the transparency represents planned teeth shape; (b) the virtual design of the guide placed on the upper arch.

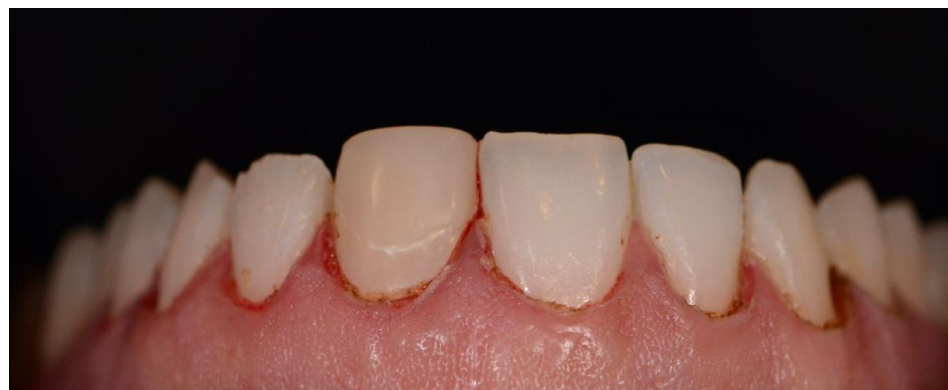

**Figure 4.** A surgical guide placed on teeth. (a) Before gingivectomy; (b) during gingivectomy; (c) after gingivectomy.

### 2.2.3. Gingivectomy with Soft Tissue Laser

Once the correct seating of the guide has been verified, the SOGA soft tissue laser (Shenzhen Soga Technology Co., Ltd., Shenzhen, China) was used to cut and coagulate the gingiva.

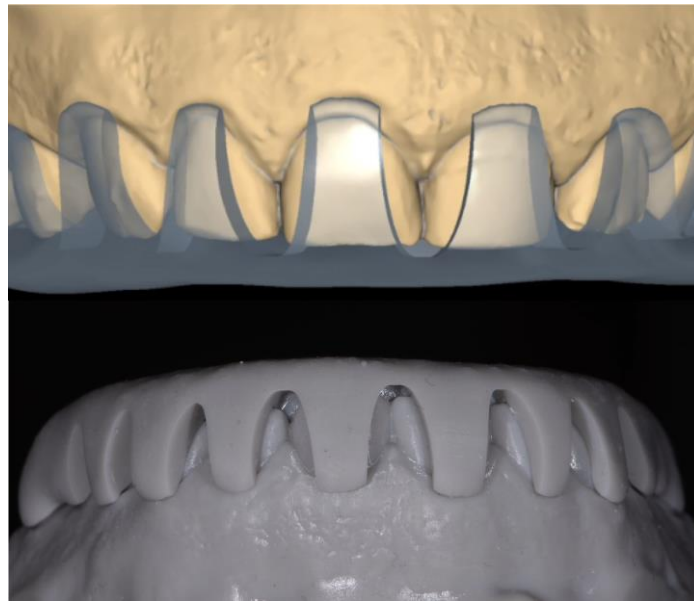
The benefits of this technique are precision in gingival tissue removal, low invasiveness rates, shorter healing duration, increased aesthetic outcome, and reduced complication probability (Figure 5).



**Figure 5.** Teeth after gingivectomy.

#### 2.2.4. Preliminary Procedures

Firstly, a control guide corresponding to the shape of the designed veneers was printed by means of a Phrozen Aqua Gray 4K resin (PHROZEN TECH Co., Ltd., Taiwan, China) in Phrozen Sonic Mighty 4K Resin 3D Printer (PHROZEN TECH Co., Ltd., Taiwan, China) (Figure 6). Special windows were designed to facilitate access to the prepared tooth surface and verification of preparation depth. Next, the composite restoration in tooth 21 was removed, and a minimal veneer preparation was performed on the first premolars, canines, and central and lateral incisors.

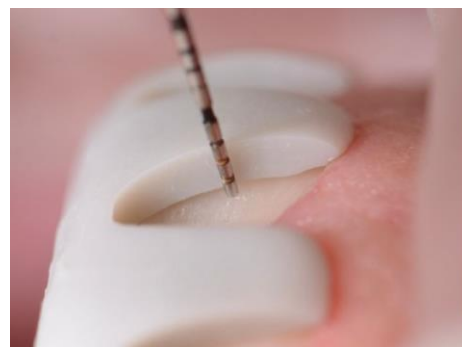

**Figure 6.** Control guide designed in Exocad.

#### 2.2.5. Teeth Preparation

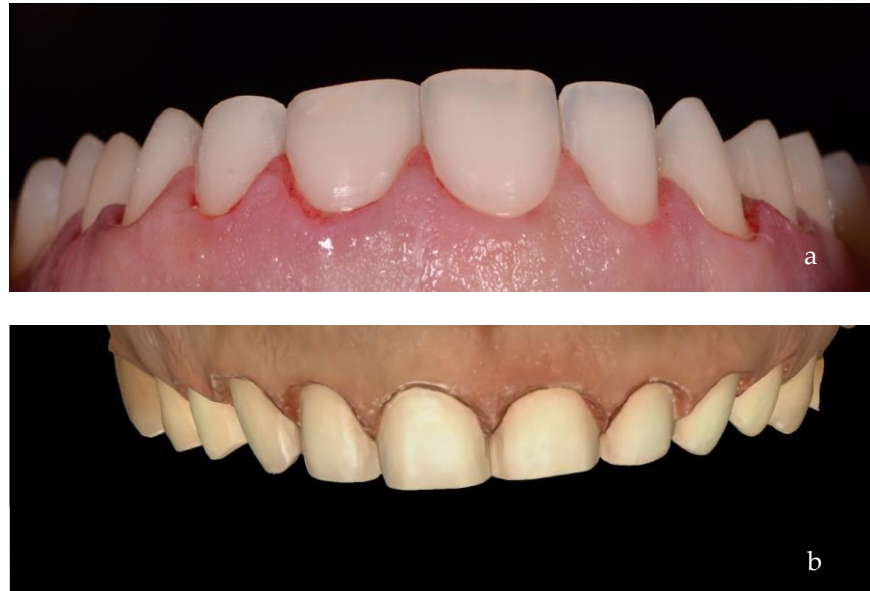The teeth were prepared with a butt-joint margin, with a 1.5 mm reduction of the incisal edges in relation to the final planned length of the porcelain veneer. The leveling of the labial surface was performed in three different planes: the cervical, the middle, and the incisal, by means of a Style Indiretto Intensiv bur kit (Swiss Dental Products powered by Styleitaliano) and a reduction guide. The following sequence of an Indiretto Intensiv kit (Swiss Dental Products powered by Styleitaliano) was used: V2, then V3 and V4 bur. The burs were mounted in a T3 racer Dentsply Sirona handpiece using abundant water cooling.

A North Carolina periodontal probe (Gainesville, FL, USA) and control guide were used to verify the reduction depth (Figure 7). The preparation was limited to enamel with an average thickness between 0.4 mm and 0.5 mm. Only 0.9 mm preparation was performed in tooth 21, which was in the retruded position.



**Figure 7.** A periodontal probe and a control guide were used to verify the preparation depth.

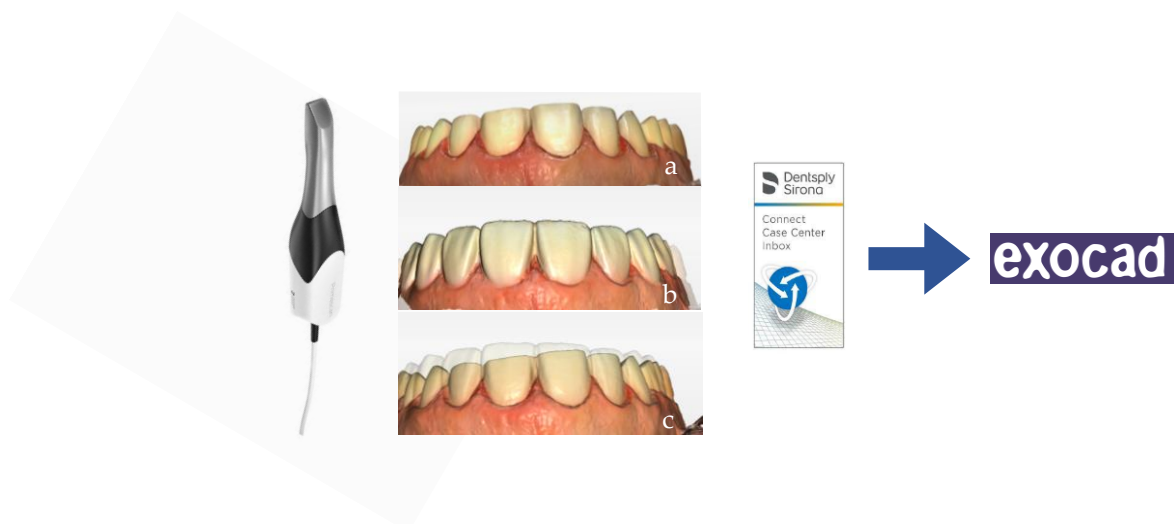Next, the prepared surfaces were smoothed using a silicon polisher No. 9608 (Brownie Point, Komet Dental, Lemgo, Germany) mounted on a contra-angle handpiece with abundant water cooling and a speed of 5000 rpm. Visual control and initial scanning of the preparations were performed to ensure that there were no irregularities, i.e., sharp edges or unrounded angles (Figure 8).



**Figure 8.** Teeth prepared for veneers. (a) Visual control; (b) initial scan.

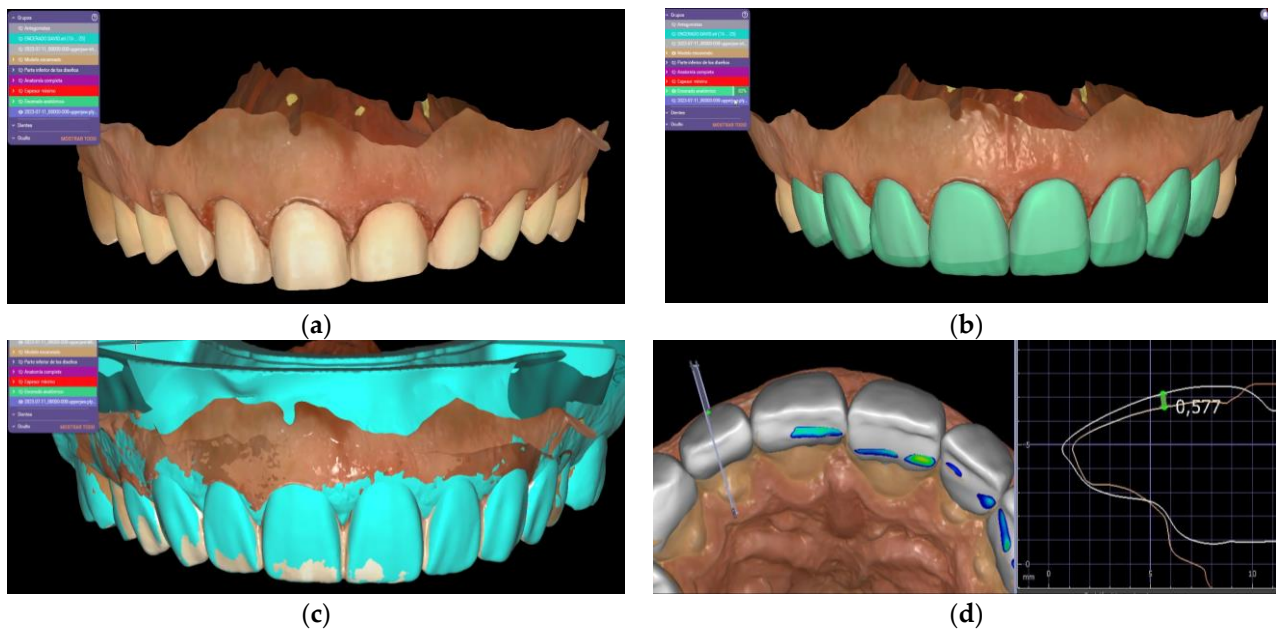
#### 2.2.6. Scanning

Next, intraoral scanning was performed with CEREC PrimeScan software 5.2 (Dentsply Sirona, Bensheim, Germany) in biocopy mode in order to replicate the size and shape of the final restorations. The scan of dental preparations and the design of the initial DSD were juxtaposed in Exocad. The difference in volume corresponded to veneers (Figure 9).



**Figure 9.** (a) Scanner; (b) scanned teeth with preparation, veneers' design, veneers juxtaposed on prepared teeth; (c) data export to Exocad.

Additionally, a thickness check of restorations was performed in the dental laboratory before veneer fabrications (Figure 10).



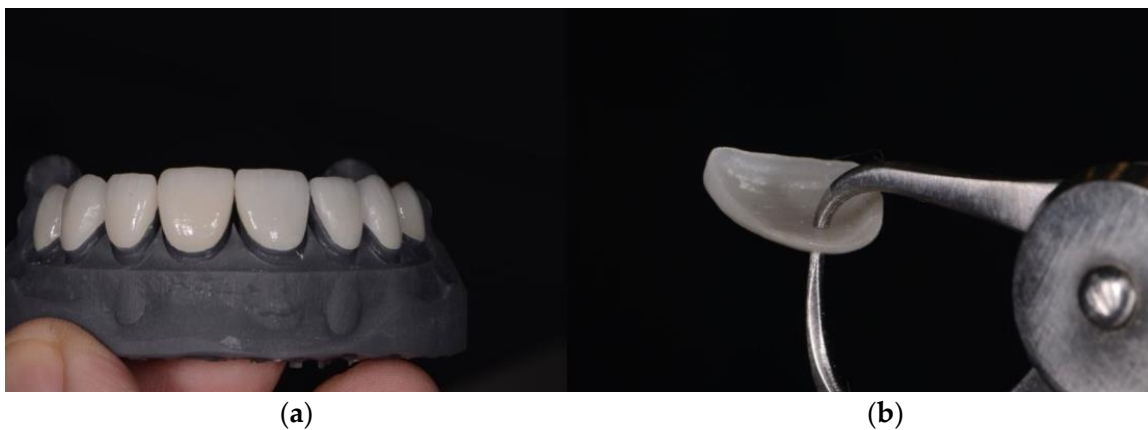**Figure 10.** (a) Scanned teeth, (b) veneers juxtaposed on prepared teeth, (c) thickness check of restorations, and (d) control of occlusion.

#### 2.2.7. Temporalization

The temporary restorations were performed using Protemp 4 (3M, St. Paul, MN, USA) in the 2nd appointment based on a digital index silicone impression. The silicone used was Express Putty Soft (3M, St. Paul, MN, USA). Next, excess material was carefully removed with surgical blade number 12 (Morton, England) and Komet bur (850314012, Komet, Germany).

#### 2.2.8. Laboratory Procedures

Eight lithium disilicate veneers (medium translucency (MT) A1 blocks; eMAX CAD, Ivoclar Vivadent, Schaan, Liechtenstein) were milled using an MCX5 machine (Dentsply Sirona, Bensheim, Germany) (Figure 11). After crystallization in a Programat P300 (Ivoclar Vivadent, Schaan, Liechtenstein) ceramic oven (p81 program), veneers were characterized with an IPS Ivocolor stain kit and crystallized (Programat P300, Ivoclar Vivadent, Schaan, Liechtenstein ceramic oven, p6 program). Next, a printed model was used to adjust contact points. Additionally, the thickness of veneers was checked and recorded (0.4 mm and 0.5 mm, except for tooth 21).



**Figure 11.** (a) Veneers placed on printed model; (b) thickness check of veneer.



### 2.3. Visit III (After 7 Days)

Temporary restorations were removed with a scaler (Sirosonic, Dentsply Sirona, Bensheim, Germany), and teeth were cleaned with brush and paste (Premier Dental, Exton, PA, USA).

### 2.4. Clinical Check-Up

The fit and interproximal contacts of the veneers were assessed using a check model. Subsequently, the veneers were positioned on the teeth, and their fit and color were carefully evaluated intraorally. Additionally, a translucent try in RelyX veneer (3M ESPE, St. Paul, MN, USA) was applied. The patient and dentist accepted the appearance of veneers at this stage.

### 2.5. Cementation of Veneers

Isolation was achieved by means of a rubber dam (Nic Tone Dental Dam, thick, mint, MDC dental, Zapopan, Mexico). Next, teeth were air-abraded using 20 µm aluminum oxide particles with AquaCare Aluminium Oxide Air Abrasion Powder (Velopex, London, UK). Air-abrading the prepared teeth before cementation ensures thorough cleaning of debris and contaminants while creating a micro-retentive surface for improved bond strength between the tooth and the restorative materials. This process optimizes the longevity and effectiveness of dental restorations by minimizing microleakage and promoting durable adhesion. After meticulous cleaning and drying, interproximal surfaces were secured using Teflon tape (PTFE Iso Tape 5 mm Santa Catarina, Brasil).

Next, teeth were etched using 35% phosphoric acid (Scotchbond Universal Etchant, 3M ESPE, St. Paul, MN, USA) for 20 s and abundantly washed with distilled water and dried. Afterward, Scotchbond Universal Plus adhesive (3M ESPE, St. Paul, MN, USA) was applied according to the manufacturer's instructions: dried with air directly to eliminate the solvents from the adhesive and left unpolymerized until the veneers were placed (following recommendations in the RelyX Universal instructions).

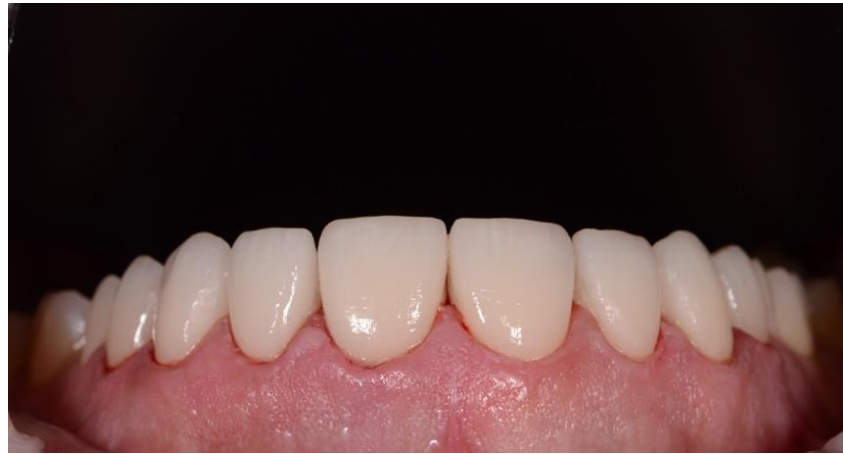The intaglio surfaces of ceramic restorations were etched with 10% hydrofluoric acid (porcelain etch, Ultradent Product Inc., South Jordan, UT, USA) for 20 s and cleaned in an ultrasonic tube. Next, intaglio surfaces were uniformly covered with Ceramic Silane (3M ESPE, St. Paul, MN, USA). After drying the silane, cement was applied after 10 s.

Translucent light-cure resin cement (RelyX Universal, 3M ESPE, St. Paul, MN, USA) was introduced on the inner part of the veneers following the manufacturer's instructions. Next, veneers, one by one, were positioned on the prepared teeth. Firstly, central incisors were cemented simultaneously. Next, other veneers were introduced and polymerized separately. The excess cement near the margins was eliminated using an Eccesso LM Arte instrument (LM-Dental, Parainen, Finland). Polymerization was performed for 20 s/surface with a light-emitting diode (LED) light-curing unit curing pen (Eightteeth, Changzhou, China) at 1000 mW/cm<sup>2</sup>. Each surface, including the facial, palatal, mesial, and distal, was polymerized.

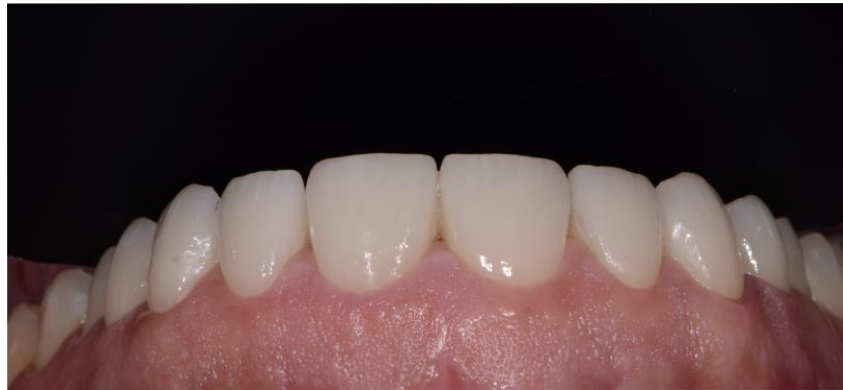### 2.6. Occlusal Adjustment and Polishing

Following minimal occlusion adjustment with C1 and C3 burs (Indiretto Style Italiano kit, Intensiv, Swiss Dental Products powered by Styleitaliano), finally, the restorations were polished by polishing points (Dialite Feather Lite, Brasseler USA Dental, Savannah, GA, USA) and polishing paste (Dialite Intra-Oral Polishing Paste, Brasseler USA Dental, Savannah, GA, USA).

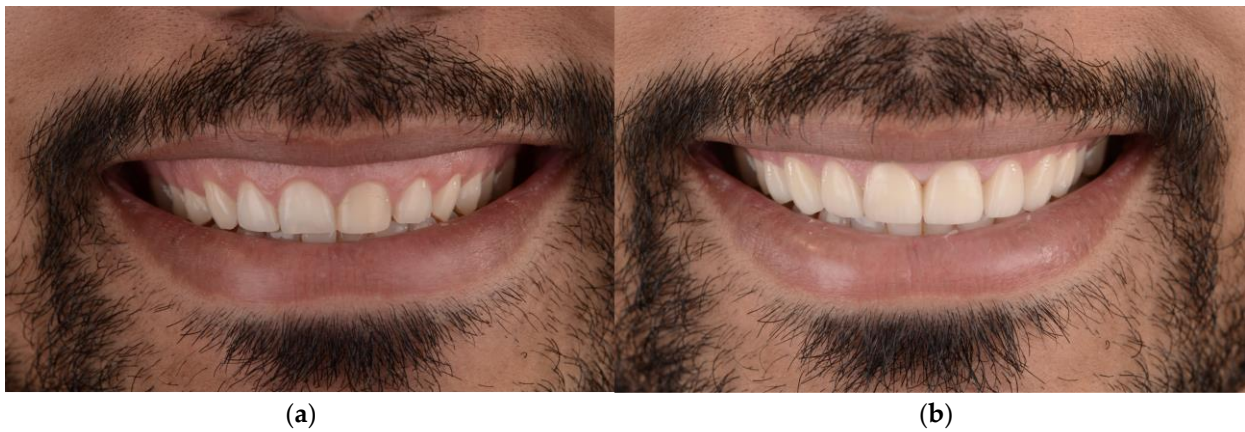The patient approved both the shape and size of the final restorations, and the treatment met his aesthetic expectations satisfactorily (Figures 12–14).



**Figure 12.** Immediate situation post-cementation with RelyX Universal resin cement.



**Figure 13.** Clinical situation 7 days after cementation.



**Figure 14.** Frontal view. (a) The initial situation; (b) the final situation.

Before treatment, the patient exhibited a gummy smile with a zenith of 3 mm on the teeth. Following treatment, the zenith was reduced to 1 mm, resulting in a significantly improved aesthetic outcome (Figure 15).

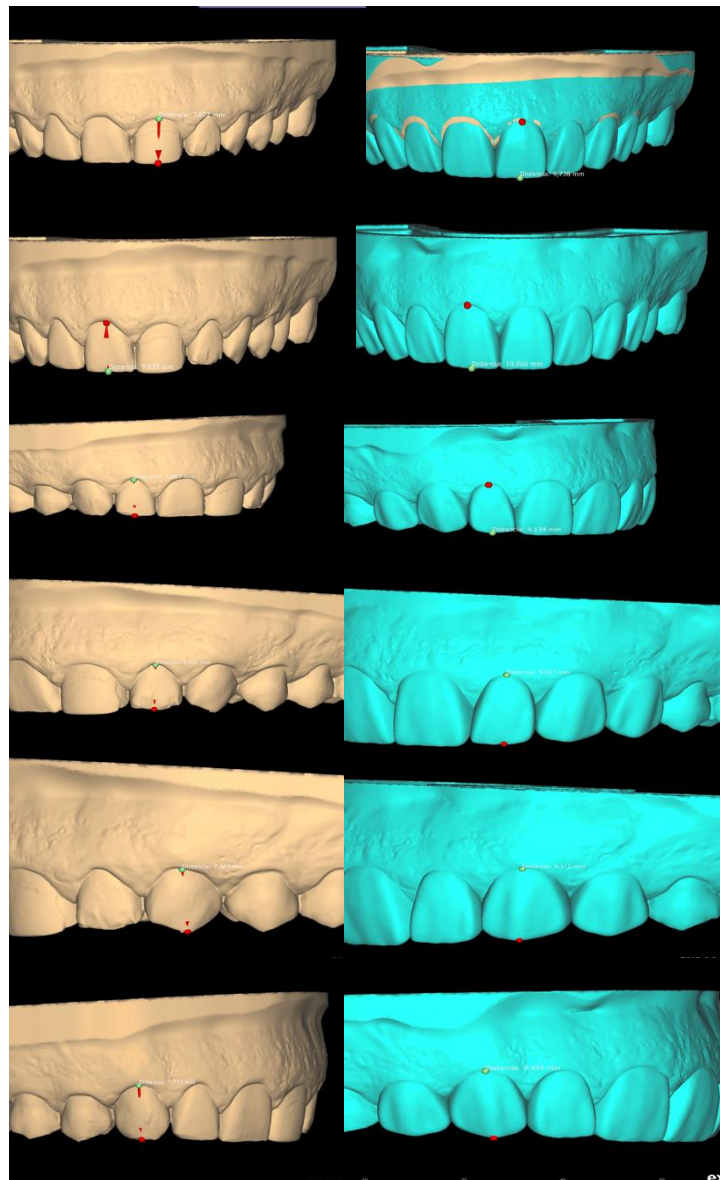


Figure 15. Measurements before and after treatment.

### 3. Summary

Treatment of excessive gingival display and improper teeth shape was performed with a multidisciplinary digital approach. Yet, clinicians considered advanced tools for succeeding in this smile in a simple and fast way. One should state that excessive gingival display is a sensitive technique for clinicians and an emotionally charged aesthetic concern for many patients. The numerous contributing factors must be comprehended by the dentist in an attempt to make the proper diagnosis and to create an aesthetic treatment strategy that is clinically predictable. The diagnosis of a gummy smile is relatively uncommon; excessive gingival tissue affects 10% of people between the ages of 20 and 30 and is more frequently found in women [19,20]. A previous study revealed a substantial gender difference in the vertical lip–tooth–jaw relationship; on average, the upper lip of the women was 1.5 mm superior to those of the male participants at maximum smile. The gingival smile line is the smile at its fullest and exposes the gingiva superior to the maxillary anterior teeth [21].

Orthodontists, general dentists, and non-specialists agree that a typical feminine smile is one in which the entire incisor crown is visible and the upper lip rests on the gingival margin of the maxillary incisor. People generally find it the most appealing when a man's upper lip stands on the gingival margin of the clinical crown of the maxillary incisor. The

upper lip should be on the gingival margin of the maxillary incisor crown, and there should be 2 mm of upper lip incisor coverage, as stated by orthodontists and clinicians [22]. An appropriate examination can provide a precise diagnosis based on factors like facial symmetry and proportions in both frontal and lateral views, the length of the upper lip at rest, the display of the maxillary teeth, the amount of gingival exposure during speaking, smiling, and laughing, the smile line, and the gingival margin line [23]. Normally, the literature discussed performing a gingivectomy with or without bone recontouring, and before any preparation of the substrate. Then, the placement of the provisional directly after surgery or after 2 weeks in order to make the final preparations, simply following the complete maturation of the soft tissues that could last from 3 to 6 months after the surgical phase [24,25]. Having said that, the stability of soft tissues can be warranted before the prosthetic procedure. Such methods, though, might not be appropriate for patients who have very high expectations for aesthetic needs because they either include a transitional phase with unsightly gingival recession or long-term provisional that are prone to leakage, staining, and discoloration. The case presented in this study suggests a substitute procedure, the drive of which is to deliver the patient with aesthetically pleasing restorations from the first appointment. Dental provisionals were delivered directly to the patient after the gingivectomy and replaced one day after with the final CAD-CAM veneer. In this condition, a correction was made to the patient's aesthetic complaint in only two days.

It is crucial to achieve appropriate hemostasis before taking final impressions, delivering the temporaries, and finally placing the final restorations. The stability of the soft tissues during impression and the delivery of the final prosthetic veneers was guaranteed by using the diode laser to perform the gingivectomy in conjunction with the use of hemostatic agents. Particular focus was placed on the provisional restorations' marginal adaption and emergence profiles during the first day; appropriately shaped temporaries were determined to be essential for soft tissue healing and stability [26].

By achieving a simulation and previsualization of the final outcome of the suggested therapy, DSD is a digital mode that aids in the creation of the new smile design [27]. A digitally created design includes patient involvement in the designing process of their own smile, allowing for customization of the smile design in accordance with individual needs and preferences that complement the patient's morpho-psychological features, connecting with the patient on an emotional level and improving their acceptance of the expected treatment [28,29]. Digital dentistry is a concept that can help in a diagnostic vision by improving communication between patient and clinician. Thus, the treatment predictability will be enhanced by means of a meticulous examination of the patient's dental and facial appearances that might have gone ignored by photographic, clinical, and diagnostic models based on an evaluation process [30,31].

The limitations of the technique used in this study could be noticed by the high cost when compared with the conventional methods using alginate impression instead of digital scanning. Research is advocated to address the effect of factors like a possible error or misfit of the guide used for gingivectomy, as well as the influence of 3D printers and software systems, on the accuracy of the guides for gingivectomy techniques.

#### 4. Future Perspectives

Looking ahead, the integration of digital dentistry into routine practice holds promising future perspectives. Continued advancements are expected to streamline planning and therapeutic procedures, leading to faster and more accurate dental treatments. This evolution will likely expand capabilities in DSD, enhancing customization to align with individual patient preferences and anatomical nuances. Furthermore, the ongoing development of digital technologies is anticipated to improve interdisciplinary collaboration and communication, optimizing treatment outcomes across various dental specialties. As digital tools become more accessible and sophisticated, they are poised to revolutionize

dental care, offering clinicians enhanced diagnostic capabilities, treatment predictability, and overall patient satisfaction.

**Author Contributions:** Conceptualization, G.J. and L.H.; methodology, R.B. and L.H.; software, R.B.; validation, L.H., D.A. and M.L.-S.; formal analysis, L.H.; investigation, L.H. and R.B.; resources, G.J., C.E.C.-S. and D.A.; data curation, R.B. and K.P.; writing—original draft preparation, G.J., M.L.-S. and R.B.; writing—review and editing, C.E.C.-S., M.L.-S. and L.H.; visualization, L.H. and K.P.; supervision, L.H.; project administration, G.J.; funding acquisition, M.L.-S. All authors have read and agreed to the published version of the manuscript.

**Funding:** This research received no external funding.

**Institutional Review Board Statement:** The article is a case report (one patient) of regular treatment, therefore, it does not require approval of the committee.

**Informed Consent Statement:** Informed consent was obtained from all subjects involved in the study.

**Data Availability Statement:** The data presented in this study are available upon reasonable request from the first author.

**Conflicts of Interest:** The authors declare no conflicts of interest.

## References

1. Thomas, P.A.; Krishnamoorthi, D.; Mohan, J.; Raju, R.; Rajajayam, S.; Venkatesan, S. Digital Smile Design. *J. Pharm. Bioallied Sci.* **2022**, *14* (Suppl. S1), S43–S49. [[CrossRef](#)] [[PubMed](#)]
2. McLaren, E.A.; Culp, L. Smile Analysis—The Photoshop Smile Design Technique: Part 1. *J. Cosmet. Dent.* **2013**, *29*, 94–108.
3. McLaren, E.A.; Garber, D.A.; Figueira, J. The Photoshop Smile Design Technique (Part 1): Digital Dental Photography. *Compend. Contin. Educ. Dent.* **2013**, *34*, 772–779.
4. Dym, H.; Pierre, R. Diagnosis and Treatment Approaches to a “Gummy Smile”. *Dent. Clin.* **2020**, *64*, 341–349. [[CrossRef](#)] [[PubMed](#)]
5. Ong, M.; Tseng, S.C.; Wang, H.L. Surgical Crown Lengthening. *Clin. Adv. Periodontics* **2011**, *1*, 233–239. [[CrossRef](#)]
6. Monaco, A.; Streni, O.; Marci, M.C.; Marzo, G.; Gatto, R.; Giannoni, M. Gummy Smile: Clinical Parameters Useful for Diagnosis and Therapeutical Approach. *J. Clin. Pediatr. Dent.* **2004**, *29*, 19–25. [[CrossRef](#)] [[PubMed](#)]
7. Hwang, W.S.; Hur, M.S.; Hu, K.S.; Song, W.-C.; Koh, K.-S.; Baik, H.-S.; Kim, S.-T.; Kim, H.-J.; Lee, K.-J.; Hwanga, M.-S.H.W.-S. Surface Anatomy of the Lip Elevator Muscles for the Treatment of Gummy Smile Using Botulinum Toxin. *Angle Orthod.* **2009**, *79*, 70–77. [[CrossRef](#)] [[PubMed](#)]
8. De Almeida Decurcio, R.; de Carvalho Cardoso, P. Porcelain laminate veneers: A minimally invasive esthetic procedure. *Stomatol* **2011**, *17*.
9. Azouzi, I.; Kalgoum, I.; Hadyaoui, D.; Harzallah, B.; Cherif, M. Ceramic veneers for smile optimization: A multidisciplinary approach. *MOJ Clin. Med. Case Rep.* **2018**, *8*, 00227. [[CrossRef](#)]
10. Peumans, M.; De Munck, J.; Fieuws, S.; Lambrechts, P.; Vanherle, G.; Van Meerbeek, B. A prospective ten-year clinical trial of porcelain veneers. *J. Adhes. Dent.* **2004**, *6*, 65–76. [[PubMed](#)]
11. Beier, U.S.; Kapferer, I.; Burtscher, D.; Dumfahrt, H. Clinical performance of porcelain laminate veneers for up to 20 years. *Int. J. Prosthodont.* **2012**, *25*, 79–85. [[PubMed](#)]
12. Tajammul, A. Porcelain laminate veneers: A minimally invasive esthetic procedure. *J. Evol. Med. Dent. Sci.* **2013**, *2*, 8856–8860.
13. Calamia, J.R.; Calamia, C.S. Porcelain laminate veneers: Reasons for 25 years of success. *Dent. Clin. N. Am.* **2007**, *51*, 399–417. [[CrossRef](#)] [[PubMed](#)]
14. Shellis, R.P.; Addy, M. The interactions between attrition, abrasion and erosion in tooth wear. *Erosive Tooth Wear* **2014**, *25*, 32–45.
15. Addy, M.; Shellis, R. Interaction between attrition, abrasion and erosion in tooth wear. *Dent. Eros.* **2006**, *20*, 17–31.
16. Wetselaar, P.; Wetselaar-Glas, M.J.; Katzer, L.D.; Ahlers, M.O. Diagnosing tooth wear, a new taxonomy based on the revised version of the Tooth Wear Evaluation System (TWES 2.0). *J. Oral Rehabil.* **2020**, *47*, 703–712. [[CrossRef](#)] [[PubMed](#)]
17. Hardan, L.; Mancino, D.; Bourgi, R.; Cuevas-Suarez, C.E.; Lukomska-Szymanska, M.; Zarow, M.; Jakubowicz, N.; Zamarripa-Calderón, J.E.; Kafa, L.; Etienne, O. Treatment of tooth wear using direct or indirect restorations: A systematic review of clinical studies. *Bioengineering* **2022**, *9*, 346. [[CrossRef](#)] [[PubMed](#)]
18. Imburgia, M.; Canale, A.; Cortellini, D.; Maneschi, M.; Martucci, C.; Valenti, M. Minimally invasive vertical preparation design for ceramic veneers. *Int. J. Esthet. Dent.* **2016**, *11*, 460–471.
19. Tjan, A.H.; Miller, G.D.; The, J.G. Some esthetic factors in a smile. *J. Prosthet. Dent.* **1984**, *51*, 24–28. [[CrossRef](#)] [[PubMed](#)]
20. Peck, S.; Peck, L.; Kataja, M. The gingival smile line. *Angle Orthod.* **1992**, *62*, 91–100. [[PubMed](#)]
21. Peck, S.; Peck, L.; Kataja, M. Some vertical lineaments of lip position. *Am. J. Orthod. Dentofacial Orthop.* **1992**, *101*, 519–524. [[CrossRef](#)] [[PubMed](#)]

22. Dutra, M.B.; Ritter, D.E.; Borgatto, A.; Derech, C.D.A.; Rocha, R. Influence of gingival exposure on the smile esthetics. *Dent. Press J. Orthod.* **2011**, *16*, 111–118. [[CrossRef](#)]
23. Trushkowsky, R.; Arias, D.M.; David, S. Digital Smile Design concept delineates the final potential result of crown lengthening and porcelain veneers to correct a gummy smile. *Int. J. Esthet. Dent.* **2016**, *11*, 338–354. [[PubMed](#)]
24. Zucchelli, G.; Mazzotti, C.; Monaco, C. A standardized approach for the early restorative phase after esthetic crown-lengthening surgery. *Int. J. Periodontics Restor. Dent.* **2015**, *35*, 601–611. [[CrossRef](#)] [[PubMed](#)]
25. Lee, E.A. Aesthetic crown lengthening: Classification, biologic rationale, and treatment planning considerations. *Pract. Proced. Aesthet. Dent.* **2004**, *16*, 769–778. [[PubMed](#)]
26. Montalvo-Arias, D.; Rojas, G.M.; Apa, M.A. The “Gummy Smile” challenge: A novel multidisciplinary approach. *J. Cosmet. Dent.* **2017**, *33*, 50.
27. Alharkan, H.M. Integrating digital smile design into restorative dentistry: A narrative review of the applications and benefits. *Saudi Dent. J.* **2023**, *36*, 561–567. [[CrossRef](#)]
28. Dag, O.D.; Dagli, I.; Kurt, A. The influence of different tooth proportions obtained using digital smile design on the perception of smile esthetics. *J. Esthet. Restor. Dent.* **2024**, *36*, 494–502. [[CrossRef](#)] [[PubMed](#)]
29. Chitlange, P.M.; Madhu, P.P.; Reche, A. Digital smile design—An overview of 3D digital workflow. *J. Clin. Diagn. Res.* **2023**, *17*, ZE01–ZE05. [[CrossRef](#)]
30. Sv, A. The digital protocol development and effectiveness evaluation for complex dental treatment. *New Arm. Med. J.* **2021**, *15*, 34.
31. Joda, T.; Balmer, M.; Jung, R.E.; Ioannidis, A. Clinical use of digital applications for diagnostic and treatment planning in prosthodontics: A scoping review. *Clin. Oral Implants Res.* **2023**. [[CrossRef](#)]

**Disclaimer/Publisher’s Note:** The statements, opinions and data contained in all publications are solely those of the individual author(s) and contributor(s) and not of MDPI and/or the editor(s). MDPI and/or the editor(s) disclaim responsibility for any injury to people or property resulting from any ideas, methods, instructions or products referred to in the content.