



**HAL**  
open science

## Recurrent cervical swelling syndrome as a rare cause of left supraclavicular edema: Case series and literature review

E. Charvet, T. Mahévas, S. Rivière, D. Gobert, V. Jachiet, V. Panayotopoulos, N. Abisror, E. Ghrenassia, L. Arrive, S. Vignes, et al.

### ► To cite this version:

E. Charvet, T. Mahévas, S. Rivière, D. Gobert, V. Jachiet, et al.. Recurrent cervical swelling syndrome as a rare cause of left supraclavicular edema: Case series and literature review. *Annales de Dermatologie et de Vénérologie*, 2024, 151 (3), pp.103286. 10.1016/j.annder.2024.103286 . hal-04652488

**HAL Id: hal-04652488**

**<https://hal.science/hal-04652488>**

Submitted on 18 Jul 2024

**HAL** is a multi-disciplinary open access archive for the deposit and dissemination of scientific research documents, whether they are published or not. The documents may come from teaching and research institutions in France or abroad, or from public or private research centers.

L'archive ouverte pluridisciplinaire **HAL**, est destinée au dépôt et à la diffusion de documents scientifiques de niveau recherche, publiés ou non, émanant des établissements d'enseignement et de recherche français ou étrangers, des laboratoires publics ou privés.

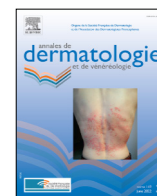


Distributed under a Creative Commons Attribution 4.0 International License



Available online at  
**ScienceDirect**  
[www.sciencedirect.com](http://www.sciencedirect.com)

Elsevier Masson France  
**EM|consulte**  
[www.em-consulte.com/en](http://www.em-consulte.com/en)



## Research letter

# Recurrent cervical swelling syndrome as a rare cause of left supraclavicular edema: Case series and literature review



E. Charvet<sup>a,\*</sup>, T. Mahévas<sup>a</sup>, S. Rivière<sup>a</sup>, D. Gobert<sup>a</sup>, V. Jachiet<sup>a</sup>, V. Panayotopoulos<sup>a</sup>, N. Abisror<sup>a</sup>,  
 E. Ghrenassia<sup>a</sup>, L. Arrive<sup>b</sup>, S. Vignes<sup>c</sup>, A. Mekinian<sup>a</sup>, O. Fain<sup>a</sup>

<sup>a</sup> Sorbonne University, Department of Internal Medicine, AP-HP, Saint Antoine Hospital, 75012 Paris, France

<sup>b</sup> Assistance Publique-Hôpitaux de Paris, Radiology Department, Saint Antoine Hospital, AP-HP, 184 rue du Faubourg Saint Antoine, 75012 Paris, France

<sup>c</sup> Lymphology Department, Primary Lymphedema Reference Center, Cognacq Jay Hospital, Paris, France

## ARTICLE INFO

### Article history:

Received 9 December 2021

Accepted 22 May 2024

© 2024 The Authors. Published by Elsevier Masson SAS. This is an open access article under the CC BY license (<http://creativecommons.org/licenses/by/4.0/>).

### Keywords:

Angioedema

Lymphology

Oedema

## 1. Introduction

Supraclavicular edema is a relatively common condition in medical practice. Superior vena cava syndrome, left supraclavicular lymph node, hypothyroidism, and angioedema are common causes. In some rare cases, lymphatic disorders such as cervical thoracic duct anomalies are involved. The two main causes of cervical chylous effusion are thoracic duct occlusion and post-traumatic (postoperative or not) leakage [1]. Once these diagnoses have been ruled out, the occurrence of recurrent, fluctuating, asymmetric, left-sided supraclavicular edema suggests paroxysmal thoracic duct occlusion syndrome, primarily described by Preyer and named recurrent cervical swelling syndrome (RCSS) by Franceschi or spontaneous cervical swelling syndrome by Betraints [2–4].

The purpose of this paper is to review the characteristics of RCSS and analyze the presenting signs and symptoms, therapeutic options, and outcome. Herein, we report seven new cases of RCSS and then present a literature review.

## 2. Case series and literature review

Seven adult patients with recurrent left cervical edema and diagnosis of RCSS, admitted to the Internal Medicine Unit of Saint Antoine Hospital (the French reference center for angioedema)

between January 1, 2015 and August 1, 2021 were included (Table 1). Differential diagnoses were excluded. Two investigators (EC, TM) then searched MEDLINE, PubMed Central, and Google Scholar for articles in English or French published until December 2021 and containing the keywords “recurrent cervical swelling syndrome, recurrent lymphangiectasia of the left supraclavicular fossa, benign supraclavicular tumor, paroxysmal cervical swelling, spontaneous cervical swelling syndrome”. All articles with sufficient data were included in the literature review. Among 676 references screened, we found eight articles describing 19 cases of recurrent, transient, and non-inflammatory left supraclavicular edema with exclusion of differential diagnosis (malignant tumors, cysts) (Tables 2 and 3) [4–8]. Data from seven patients followed at our center (Table 1) were pooled with six well-documented cases from the literature review (Table 3).

We identified 26 cases of RCSS. All patients were women with left cervical edema lasting between 1 and 7 days (Fig. 1). The median age was 55.5 years old [interquartile range (IQR) 30–82]. The median number of episodes before diagnosis was 3 [IQR 1–24]. The median time from first symptoms to diagnosis was 12 months [range: 1–120]. Clinical and therapeutic characteristics are summarized in Table 3. Fourteen patients had pleural effusion and one patient had pericardial effusion without cardiac dysfunction. Eleven patients had gastrointestinal symptoms, including: abdominal pain (10/11), ascites (5/11), diarrhea and/or vomiting (3/11). None of the patients had a history of chest wall trauma or thoracic surgery. Four of the patients had eaten a high-fat meal in the previous days.

\* Corresponding author at: Sorbonne University, Service de Médecine Interne, AP-HP, Hôpital Saint Antoine, 75012 Paris, France.

E-mail address: [estelle.charvet@aphp.fr](mailto:estelle.charvet@aphp.fr) (E. Charvet).

**Table 1**  
Clinical and therapeutic characteristics of our seven patients presenting with recurrent cervical swelling syndrome.

Case No./sex/age BMI (kg/m <sup>2</sup> )	Trigger	Duration Frequency of crises	Evolution (months) Median number of crises before diagnosis	Left cervical swelling associated symptoms	Imagery	Treatment	Efficacy
1/F/55 BMI: 26	NS	3–5 days 1/month	18 24	Pleural effusion Ascites Abdominal pain Vomiting	– CT scan: pleural effusion and ascites – MRI: focal dilatation supra clavicular lymphatic duct – lymphoscintigraphy: left side asymmetry during the dynamic phase	Low-fat diet and Lanreotide (30 mg SR)	PR (decreased frequency) After 39 months of follow up
2/F/35 sickle cell disease BMI: 27	Fast food	3–4 days 1/year	12 3	Abdominal pain Diarrhea Ascites Pleural effusion	– MRI: left clavicular edema ectasia of the butt of the thoracic duct without visible obstacle	Low fat diet and Lanreotide (30 mg SR)	CR no recurrence after 3 months of follow-up
3/F/28 BMI: NS	NS	3–5 days 1/6 months	6 3	Abdominal pain Diarrhea Ascites	– MRI: left clavicular edema – US doppler: normal	Low fat diet	CR no recurrence after 14 months of follow-up
4/F/34 BMI: 21	Alcohol	3–4 days 1/3 months	48 15	Lumbar pain Abdominal pain	– MRI: left clavicular edema	0	NS
5/F/63 BMI: 19	Meal containing wild boar	2–3 days First event	1 1	Pleural effusion Ascites Pericardial effusion Abdominal pain Thoracic pain	– MRI: left clavicular edema, thoracic duct dilatation without obstruction	Low fat diet preventive enoxaparin	CR no recurrence after 15 months of follow-up
6/F/41 BMI: NS	NS	2–3 days 1/3 years	120 7	Pleural effusion Ascites Abdominal pain	– CT scan: left clavicular edema, pleural effusion, ascites – MRI after crises: no compression	Low fat diet	NS
7/F/45 BMI: 18	NS	4 1/2 months	11 5	Abdominal pain	– MRI: left clavicular edema	Low-fat diet and Lanreotide (30 mg SR)	PR 5 months of follow up

NS: not specified; Hb: hemoglobin; Ht: hematocrit; CT scan: computerized tomography scanner; MRI: magnetic resonance imaging; SR sustained release; CR complete remission; PR partial remission

**Table 2**  
Summary of case reports from the literature review.

Case No./sex/age	Trigger	Duration and frequency	Symptoms associated with left cervical swelling	Imaging	Treatment	Efficacy
F/56 [5]	Hypertension of the spine	NS	Recurrent pleural effusion	– Chest X-ray: pleural effusion	NS	NS
F/67 [6]	NS	2 days	Dyspnea	– Chest CT scan: normal	NS	NS
F/33 [7]	NS	5 days 4 events/3 years	Pleural effusion Abdominal pain Weight gain of 1–2 kg	– Chest X-ray: bilateral pleural effusion – CT scan: normal – Duplex US: cystic tubular lesion of 30 × 14 × 17 mm in the subcutaneous tissue of the left supraclavicular groove – MRI: cervical soft tissue surrounding the cyst appeared to be infiltrated with edematous fluid	Puncture of cyst	No recurrence
F/64 [9]	Large fat-rich meal	3 days 3 events / 25 years	Abdominal pain	– TDM: diffuse infiltration of the subcutaneous tissue of the left supraclavicular fossa and diffuse edema in the retroperitoneal area – Lymphoscintigraphy: abnormal lymphatic drainage with trace extravasation into the left infraclavicular fossa	Low-fat diet supplemented with medium-chain triglycerides	No recurrence at one year of follow up
F/55 [3]	NS	NS	NS	– ECD: microcystic supraclavicular dilation – ECD demonstrated a dilated non-compressible cervical TD (7 mm diameter)	No treatment	NS
F/44 [3]	NS	NS	NS	– ECD: dilated and obstructed thoracic duct (8 mm) – CT scan: retroperitoneal effusion.	Low-fat diet	NS
F/58 [4]	NS	2 days 2 attacks prior to diagnosis	Dyspnea Pleural effusion	– ECD: edema of the supraclavicular fossa and left cervical region extending toward the paratracheal region – no distension of the thoracic duct – Chest CT: pleural fluid	NS	
F/46 [4]	Physical exercise	4 days 1 attack prior to diagnosis		– ECD: edema of the supraclavicular fossa – thoracic duct distension present	NS	
F/65 [4]	Physical labor	3 days 3 attacks before diagnosis	Dyspnea Pleural effusion	– ECD: edema of the supraclavicular fossa and left cervical region extending to the paratracheal region – no distension thoracic duct – Chest CT: bilateral pleural fluid – Lymphoscintigraphy: extravasation left cervical region	NS	
F/58 [4]	Physical exercise	3.5 days Recurrent attacks	Dyspnea Pleural effusion	– ECD: edema of the supraclavicular fossa and left cervical region—thoracic duct distension absent – Chest CT: bilateral pleural fluid	NS	
F/53 [4]	Warm weather	3.5 days	Pleural effusion	– ECD: edema of the supraclavicular fossa and left cervical region extending toward the paratracheal region—thoracic duct distension present – Chest CT: bilateral pleural fluid	NS	
F/38 [4]	NS	NS	Pleural effusion	– ECD: edema of the supraclavicular fossa and left cervical region—thoracic duct distension absent – Chest CT: bilateral pleural fluid	NS	
F/47 [4]	NS	7 days 2 attacks before diagnosis	Pleural effusion	– ECD: edema of the supraclavicular fossa and left cervical region—thoracic duct distension absent – Chest CT: bilateral pleural fluid – Lymphoscintigraphy: Extravasation left cervical region	NS	
F/82 [4]		2 days	Dyspnea Pleural effusion	– ECD: edema of the supraclavicular fossa and left cervical region—thoracic duct distension present	NS	
F/74 [8]	high-fat meal and alcohol	Few days	Pleural effusion	– CT scan: minor bilateral pleural effusion (predominantly on the left side), infiltration of the left side of the neck extending to the left axilla and the mediastinum	anticoagulant therapy	
F/45 [8]	NS	2 days	Abdominal pain	– CT scan: infiltration of subcutaneous tissue in the supraclavicular fossa and in the omohyoid muscle, and extensive inflammatory infiltrate in the retroperitoneum. – MRI: small cyst in the cervical area.		
F/65 [8]	NS	NS	Dyspnea	– Lymphoscintigraphy: impregnation time of 2 h and 45 min on the axillary lymphatic vessel (normal values within 10–30 min)		
F/64 [8]				– CT scan: liquid infiltration in the left supraclavicular hollow in the retroperitoneum and in the mediastinum. – Lymphoscintigraphy: significant delay of the lymphatic flow in the thoracic duct		
F/62 [8]				– CT scan: left supraclavicular mass associated with abdominal infiltration distributed around the colon and minor bilateral pleural effusions. – Pleural puncture: chylous effusion	low-fat diet	No recurrence at 3 months of follow up

CT scan: Computed Tomography scan, ECD: Echo Color Doppler; NS: not specified.

**Table 3**  
Characteristics of all patients with recurrent swelling syndrome.

Characteristics	N = 26
Age (years; median [IQR]), female (n,%)	55.5 [30–82], 26 (100%)
Duration in days (n, median [IQR])	4 [1–7]
Pleural effusion (n)	14
Abdominal pain / Ascites (n)	10/5
Trigger fat-rich meal / physical exercise (n)	4/3
Thoracic duct dilatation (MRI)	7
Treatment	11
Low fat diet	6 (4 CR, 2 NS)
Low fat diet + lanreotide	4 (2CR, 2 PR)

IQR: interquartile range, CR: complete response, PR: partial response, NS: not specified; MRI magnetic resonance imaging.

Standard laboratory tests, including blood cell count, liver and kidney function, thyroid stimulating hormone, lipids, and C-reactive protein were normal in all our patients. One patient had sickle cell disease with a history of hemodilution. Protein electrophoresis showed no monoclonal peak, and plasma C1 inhibitor protein activity was normal in 7/7 patients. Chest computed tomography (CT) showed no deep lymphadenopathy and no superior vena cava in all cases. Thoracic magnetic resonance imaging (MRI) of lymph nodes was performed during attacks in 7 patients and showed left supraclavicular edema in all cases and a dilated aspect of the thoracic duct terminal without occlusion or cervical thoracic duct cyst in 5 cases. Two of our patients received icatibant, antihistamines and intravenous corticoids for suspected bradykinin or histamine angioedema, and one patient received intravenous immunoglobulins for suspected Clarkson's disease without benefit. Finally, 10 patients were treated with a low-fat diet, and four patients were also treated with lanreotide (30 mg extended-release intramuscular injection once a month), which resulted in partial remission in two patients (reduced frequency or duration of attacks) and complete remission in the other two patients.

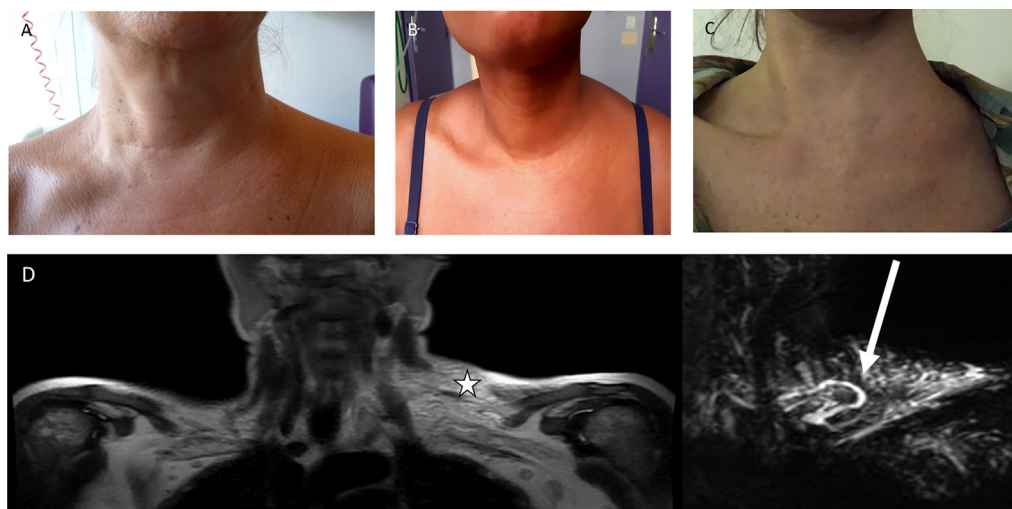### 3. Discussion

Recurrent cervical swelling syndrome (RCSS), also known as paroxysmal thoracic duct occlusion syndrome or recurrent left supraclavicular lymphangiectasia, is poorly described in the literature [9]. As indicated above, other causes of supraclavicular edema must be excluded before RCSS can be diagnosed. Preyer et al. were

the first to report this rare entity [2]. Franceschi proposed the term of recurrent cervical swelling syndrome [3]. Since then, very few cases have been reported. To date, there is no consensus on diagnostic criteria. The diagnosis of RCSS is based on clinical and radiographic signs. Clinically, RCSS is a recurrent left supraclavicular noninflammatory edema, sometimes associated with other signs such as pleural effusion, pericardial effusion and ascites. Thoracic imaging such as CT scan is important to rule out superior vena cava syndrome and left supraclavicular lymph node. Thoracic duct imaging is necessary to rule out endo- or extra-luminal occlusion of the thoracic duct and lymph-node MRI seems to be the best option for this [10].

In our series of 7 personal cases and 19 cases from the literature, the duration of left cervical swelling was 1–7 days, with associated signs in all cases. Pleural effusion and dyspnea were more common than abdominal pain and ascites. The pathophysiology of this syndrome is poorly understood. Many variants of terminal thoracic duct (TD) exist but the main termination seems to be on the left side, either in the internal jugular vein or in its confluence with the subclavian vein [11]. This preferential localization is the cause of this left supraclavicular edema. With regard to our cases, in which we indicate that a high-fat diet was consumed a few days before the edema, and with regard to the literature review, a possible hypothesis for this rare phenomenon could be that a high-fat diet may cause an influx of chylomicrons into the thoracic duct that exceeds the transport capacities, thus causing a temporary and paroxysmal lymphatic stasis in the thoracic duct [9]. However, diet was not always mentioned in the patients' medical history and no rechallenge with a high-fat diet was suggested in our patients. Lipid levels were normal throughout. The other hypothesis could be that of a constitutional abnormality of the thoracic duct such as ectasia, which may favor the extravasation of lymphatic fluid into the subcutaneous tissue [12]. No anatomical abnormalities were described in our series. Finally, in our experience and in the literature, all cases were described in women. No correlation with menstruation was observed; however, estrogenic influence could be implicated in the mechanism of edema. In their series, Betraíns et al. suggest a possible role of physical activity and outdoor temperature, which we did not find either in our series or in the other reported cases [4]. Taken together, a high-fat diet, the influence of female hormones, and thoracic duct ectasia could lead to edema.

In conclusion, we propose three diagnostic criteria for the diagnosis of RCSS:



**Fig. 1.** (a–c) Patients with recurrent swelling syndrome during an attack. (d) Thoracic lymph-node magnetic resonance imaging (T2): left supraclavicular edema (star) and dilated aspect of the thoracic duct endings (arrow).

- (1) Clinical: Recurrent non-inflammatory left supraclavicular edema,
- (2) Radiological: CT or lymph node MRI of the neck with evidence of left supraclavicular edema at the end of the thoracic duct, which is normal or dilated,
- (3) Exclusion of the following diseases: vena cava syndrome, bradykinin angioedema, tumor or lymph node, lymphatic malformation, and hypothyroidism.

In the absence of large series, the therapeutic options in RCSS are limited. In some cases, a low-fat diet seems to be effective [9]. Second, lanreotide, a somatostatin analog also used in Waldmann's disease, could decrease the chyle flow in the thoracic duct [13]. With this treatment, two of our patients experienced a reduction in the number and duration of attacks [14].

### Conflicts of interest

The authors declare that they have no conflicts of interest.

### References

- [1] Chen E, Itkin M. Thoracic duct embolization for chylous leaks. *Semin Intervent Radiol* 2011;28:63–74.
- [2] Preyer S, Kaiserling E, Heinle H, et al. Benign supraclavicular tumorous lymphangiectasia—a new disease? *Lymphology* 1995;28:118–25.
- [3] Franceschi C, Gianesini S, Bahnini A, et al. The recurrent cervical swelling syndrome. *Phlebology* 2012;27:90–2.
- [4] Betraíns A, Hermans R, Gheysens O, et al. Spontaneous cervical swelling syndrome as a rare cause of neck edema: case series and literature review. *Oxf Med Case Rep* 2021;2021:omab029.
- [5] Reilly KM, Tsou E. Bilateral chylothorax. A case report following episodes of stretching. *JAMA* 1975;233:536–7.
- [6] Garcia Restoy E, Bella Cueto F, Espejo Arenas E, et al. Spontaneous bilateral chylothorax: uniform features of a rare condition. *Eur Respir J* 1988;1:872–3.
- [7] Dendorfer U, Rademacher A, Rieger J, et al. Recurrent swelling of the left supraclavicular fossa. *Vasc Med* 2004;9:141–3.
- [8] Planchette J, Jaccard C, Nigron A, et al. Recurrent thoracic duct cyst of the left supraclavicular fossa: A retrospective study of 6 observational case series and literature review. *Medicine (Baltimore)* 2021;100:e28213.
- [9] Varron L, Vignes S, Green L, et al. Recurrent lymphangiectasia of the left supraclavicular fossa: an unusual cause of paroxysmic swelling. *Arch Dermatol* 2011;147(11):1337–8.
- [10] Okuda I, Udagawa H, Hirata K, et al. Depiction of the thoracic duct by magnetic resonance imaging: comparison between magnetic resonance imaging and the anatomical literature. *Jpn J Radiol* 2011;29:39–45.
- [11] Kinnaert P. Anatomical variations of the cervical portion of the thoracic duct in man. *J Anat* 1973;115:45–52.
- [12] Kolbenstvedt A, Aanesen J. Cystic dilatation of the thoracic duct presenting as a supraclavicular mass. *Br J Radiol* 1986;59:1228–9.
- [13] Prasad D, Srivastava A, Tambe A, Yachha SK, Sarma MS, Poddar U. Clinical profile, response to therapy, and outcome of children with primary intestinal lymphangiectasia. *Dig Dis* 2019;37:458–66.
- [14] Kalomenidis I. Octreotide and chylothorax. *Curr Opin Pulm Med* 2006;12:264–7.