



HAL
open science

Duodenal neuroendocrine tumor successfully removed by endoscopic submucosal dissection with adaptative traction device

Elena de Cristofaro, Jérôme Rivory, Thomas Walter, Jérémie Jacques, Timothée Wallenhorst, Pierre Lafeuille, Mathieu Pioche

► To cite this version:

Elena de Cristofaro, Jérôme Rivory, Thomas Walter, Jérémie Jacques, Timothée Wallenhorst, et al.. Duodenal neuroendocrine tumor successfully removed by endoscopic submucosal dissection with adaptative traction device. *Endoscopy*, 2024, 56 (S 01), pp.E317-E318. 10.1055/a-2291-9448 . hal-04647923

HAL Id: hal-04647923

<https://hal.science/hal-04647923v1>

Submitted on 6 Jan 2025

HAL is a multi-disciplinary open access archive for the deposit and dissemination of scientific research documents, whether they are published or not. The documents may come from teaching and research institutions in France or abroad, or from public or private research centers.

L'archive ouverte pluridisciplinaire **HAL**, est destinée au dépôt et à la diffusion de documents scientifiques de niveau recherche, publiés ou non, émanant des établissements d'enseignement et de recherche français ou étrangers, des laboratoires publics ou privés.



Distributed under a Creative Commons Attribution 4.0 International License

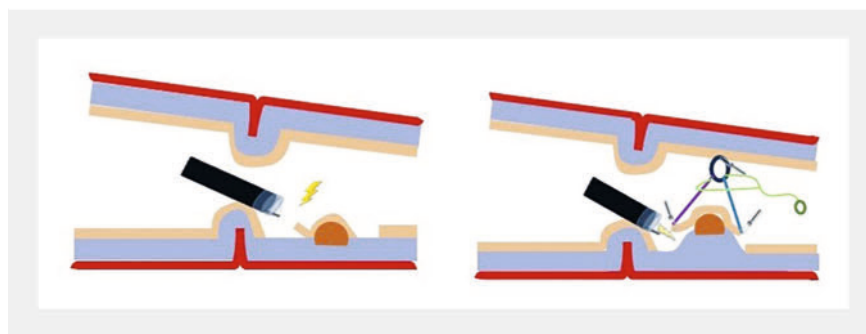
Duodenal neuroendocrine tumor successfully removed by endoscopic submucosal dissection with adaptative traction device

OPEN
ACCESS

Duodenal neuroendocrine tumors (D-NETs) are uncommon neoplastic entities [1]. The current guidelines advocate for resection when the lesion is ≤ 20 mm in size, in the absence of lymph node involvement [2]. However, the utility of endoscopic resection remains unclear, especially due to the risk of incomplete resection [3]. Endoscopic submucosal dissection (ESD) is an attractive technique because it offers the potential to achieve en bloc resection with clear margins. In a previous retrospective study, ESD for D-NETs achieved a 100% en bloc resection rate; however, the R0 resection rate is far from perfect and the perforation rate is not null [4]. The use of a traction device, with double clips and rubber band traction, has been described previously to improve the exposure of the tiny submucosal space [5].

In this case, we describe the benefits of using an adaptative traction device (A-TRACT; Hospices Civils de Lyon, Lyon, France) during duodenal ESD (► **Video 1**). A 76-year-old patient was referred for removal of a D-NET of 8 mm in size, located in the upper part of the duodenal bulb, just behind the pylorus. An ESD was indicated to ensure R0 resection. After circumferential incision and trimming, the two loops of A-TRACT 2 were fixed by two clips to the lesion edges and another clip was used to affix the rubber band to the opposite mucosal wall, allowing exposure of the lesion previously hidden by the pylorus (► **Fig. 1**). The dissection was started with good traction, allowing the cut line to be clearly identified. After half of the lesion had been cut, traction was tightened to optimize visualization, and the dissection was safely completed in 40 minutes without adverse events. The histopathology revealed a G1 NET with lateral free margins but without deep free margins.

We hypothesize that this traction device could facilitate duodenal ESD, which is



► **Fig. 1** Schematic representation of the adaptive traction device (A-TRACT 2; Hospices Civils de Lyon, Lyon, France), allowing visualization of the lesion, which was previously hidden by the pylorus, and optimal exposure of the submucosa.

known to be technically challenging and with high risk of adverse events.

Endoscopy_UCTN_Code_TTT_1AO_2AG_3AD

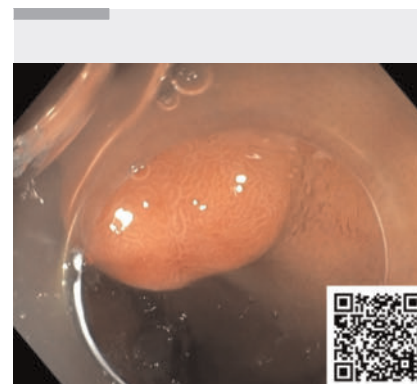
Conflict of Interest

J. Jacques, M. Pioche, and J. Rivory are co-founders of the ATRACT devices and co. E. De Cristofaro, T. Walter, T. Wallenhorst, and P. Lafeuille declare that they have no conflict of interest.

The authors

Elena De Cristofaro¹, **Jérôme Rivory**², **Thomas Walter**³, **Jérémy Jacques**⁴, **Timothée Wallenhorst**⁵, **Pierre Lafeuille**², **Mathieu Pioche**²

- 1 Gastroenterology Unit, Department of Systems Medicine, University of Rome Tor Vergata, Rome, Italy
- 2 Gastroenterology and Endoscopy Unit, Edouard Herriot Hospital, Hospices Civils de Lyon, Lyon, France
- 3 Department of Medical Oncology, Edouard Herriot Hospital, Hospices Civils de Lyon, Lyon, France
- 4 Gastroenterology and Endoscopy Unit, Dupuytren University Hospital, Limoges, France



► **Video 1** Use of an adaptative traction device with endoscopic submucosal dissection for successful removal of a duodenal neuroendocrine tumor.

- 5 Gastroenterology and Endoscopy Unit, Pontchaillou University Hospital, Rennes, France

Corresponding author

Mathieu Pioche, MD, PhD
Endoscopy Unit, Department of Digestive Diseases, Pavillon L – Edouard Herriot Hospital, Place d'Arsonval 5, 69437 Lyon Cedex, France
Mathieu.pioche@chu-lyon.fr

References

- [1] Hoffmann KM, Furukawa M, Jensen RT et al. Duodenal neuroendocrine tumors: classification, functional syndromes, diagnosis and medical treatment. *Best Pract Res Clin Gastroenterol* 2005; 19: 675–697. doi:10.1016/j.bpg.2005.05.009
- [2] Panzuto F, Ramage J, Pritchard DM et al. European Neuroendocrine Tumor Society (ENETS) 2023 guidance paper for gastroduodenal NET G1–G3. *J Neuroendocrinol* 2023; 35: e13306. doi:10.1111/jne.13306
- [3] Gincul R, Ponchon T, Napoleon B et al. Endoscopic treatment of sporadic small duodenal and ampullary neuroendocrine tumors. *Endoscopy* 2016; 48: 979–986. doi:10.1055/s-0042-112570
- [4] Gupta S, Kumar P, Chacchi R et al. Duodenal neuroendocrine tumors: short-term outcomes of endoscopic submucosal dissection performed in the Western setting. *Endosc Int Open* 2023; 11: E1099–E1107. doi:10.1055/a-2181-0320
- [5] Oung B, Walter T, Hervieu V et al. Nonampullary duodenal subepithelial neuroendocrine tumor removed R0 by endoscopic submucosal dissection with double clips and rubber band traction. *Gastrointest Endosc* 2019; 4: 570–573

Bibliography

Endoscopy 2024; 56: E317–E318
 DOI 10.1055/a-2291-9448
 ISSN 0013-726X
 © 2024. The Author(s).

This is an open access article published by Thieme under the terms of the Creative Commons Attribution License, permitting unrestricted use, distribution, and reproduction so long as the original work is properly cited.

(<https://creativecommons.org/licenses/by/4.0/>)

Georg Thieme Verlag KG, Rüdigerstraße 14,
 70469 Stuttgart, Germany



ENDOSCOPY E-VIDEOS

<https://eref.thieme.de/e-videos>



E-Videos is an open access online section of the journal *Endoscopy*, reporting on interesting cases

and new techniques in gastroenterological endoscopy. All papers include a high-quality video and are published with a Creative Commons CC-BY license. *Endoscopy E-Videos* qualify for HINARI discounts and waivers and eligibility is automatically checked during the submission process. We grant 100% waivers to articles whose corresponding authors are based in Group A countries and 50% waivers to those who are based in Group B countries as classified by Research4Life (see: <https://www.research4life.org/access/eligibility/>).

This section has its own submission website at <https://mc.manuscriptcentral.com/e-videos>