



HAL
open science

Innovations for colonic endoscopic submucosal dissection: combination of the latest game changers

Mathieu Pioche, Louis Jean Masgnaux, Romain Legros, Timothée Wallenhorst, Jérémie Albuys, Jérôme Rivory, Jeremie Jacques

► To cite this version:

Mathieu Pioche, Louis Jean Masgnaux, Romain Legros, Timothée Wallenhorst, Jérémie Albuys, et al.. Innovations for colonic endoscopic submucosal dissection: combination of the latest game changers. *Endoscopy*, 2024, 56 (03), pp.242-243. 10.1055/a-2224-8465 . hal-04647921

HAL Id: hal-04647921

<https://hal.science/hal-04647921v1>

Submitted on 8 Nov 2024

HAL is a multi-disciplinary open access archive for the deposit and dissemination of scientific research documents, whether they are published or not. The documents may come from teaching and research institutions in France or abroad, or from public or private research centers.

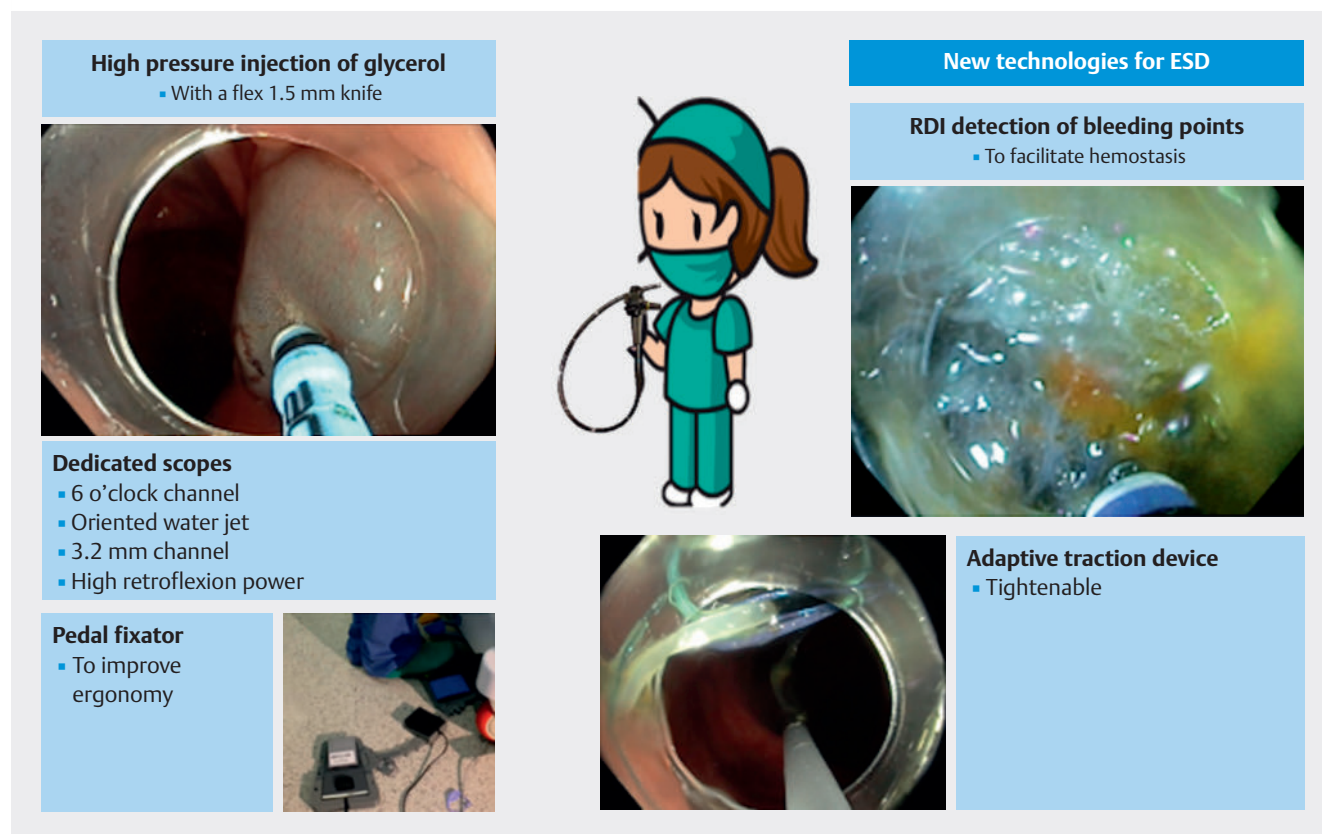
L'archive ouverte pluridisciplinaire **HAL**, est destinée au dépôt et à la diffusion de documents scientifiques de niveau recherche, publiés ou non, émanant des établissements d'enseignement et de recherche français ou étrangers, des laboratoires publics ou privés.



Distributed under a Creative Commons Attribution 4.0 International License

Innovations for colonic endoscopic submucosal dissection: combination of the latest game changers


OPEN
ACCESS



► **Fig. 1** New game changers for endoscopic submucosal dissection. Flex knife for high pressure jet injection of macromolecules. Adaptive multipolar traction. Improved ergonomomy with a pedal fixator. Red dichromic imaging (RDI) for the detection of bleeding points.

Endoscopic submucosal dissection (ESD) in 2023 is nothing like it was originally in 2001, with major changes in equipment and strategies. However, the spread of ESD has been slow because it is a challenging procedure, and major new developments are expected to simplify it further. We present a case of ESD of a nongranular laterally spreading tumor in the right colon angle, using a combination of the latest technological developments (► **Fig. 1**, ► **Video 1**) to simplify the main difficulties of the procedure. We used a pediatric therapeutic colonoscope (PCF 190L; Olympus, Tokyo Japan) with a 3.2-mm operating channel located in the 6 o'clock position with waterjet function. While high-pressure injection

of macromolecules was possible with some devices [1] such as the Erbe jet (Erbe, Tübingen, Germany) [2], the rigidity and size of the knife made dissection of the very thin colonic (rectal) submucosa difficult. With the arrival of the new Hybrid flex knife (Erbe), the flexibility and finesse of the electrode are now close to those of the most commonly used colonic knives (e.g. DualKnife; Olympus), and allow application of high pressure to the colon. However, exposure remains a key factor, and the use of a multipolar adaptive traction device (ATRACT; Hospices civils de Lyon, Lyon, France) remains essential for creation of triangulation and adjustment of traction during the procedure [3]. Ergonomics is surely also



► **Video 1** New game changers for endoscopic submucosal dissection.

one of the keys to this procedure, and pedal management needs to be improved to avoid pedal errors and to make it easier to locate the correct pedal without the need to look down at the feet. To this end, the IPEFIX pedal fixator has already demonstrated its effectiveness in reducing the number of pedal errors, and the need to look at the feet, in a prospective randomized study [4].

Finally, managing bleeding through early detection is a key factor in reducing operating time and operator fatigue, and in this respect, red dichromic imaging (RDI; Olympus) is a valuable aid in achieving hemostasis quickly and reducing endoscopist stress [5].

New game-changing innovations for ESD and their combined use could improve the accessibility and dissemination of the technique, without skipping organized and effective training.

Endoscopy_UCTN_Code_TTT_1AQ_2AD

Conflict of Interest

J. Rivory, J. Jacques, R. Legros, T. Wallenhorst, and M. Pioche are co-founders of the ATRACT device, and also consultants for Olympus, Pentax, Erbe, and Boston for training in ESD. L.-J. Masgnaux is the inventor of the ATRACT device. The Ipefix patent is the property of the institution Hospices civils de Lyon. J. Albouys declares that he has no conflict of interest.

The authors

Mathieu Pioche¹, Louis Jean Masgnaux¹, Romain Legros², Timothée Wallenhorst³, Jérémie Albouys², Jérôme Rivory¹, Jeremie Jacques²

1 Gastroenterology and Endoscopy Unit, Edouard Herriot Hospital, Hospices Civils de Lyon, Lyon, France

- 2 Gastroenterology and Endoscopy Unit, Dupuytren University Hospital, Limoges, France
- 3 Gastroenterology and Endoscopy Unit, Pontchaillou Hospital, Rennes, France

Corresponding author

Mathieu Pioche, MD, PhD

Endoscopy Unit, Department of Digestive Diseases, Pavillon L – Edouard Herriot Hospital, Place d'Arsonval 5, 69437 Lyon Cedex, France
Mathieupioche15@gmail.com

Citation Format

Endoscopy 2023; 55: E1172–E1173,
DOI 10.1055/a-2191-5546

References

- [1] Pioche M, Lépilliez V, Déprez P et al. High pressure jet injection of viscous solutions for endoscopic submucosal dissection (ESD): first clinical experience. *Endosc Int Open* 2015; 3: E368–E372. doi:10.1055/s-0034-1391902
- [2] Jacques J, Sautereau D, Carrier P et al. High-pressure injection of glycerol with Hybrid-Knife for ESD is feasible and increases the ease and speed of the procedure: an in vivo study in pigs and first use in human. *Surg Endosc* 2015; 29: 3382–3385
- [3] Masgnaux L-J, Grimaldi J, Rivory J et al. Endoscopic submucosal dissection assisted by adaptive traction: results of the first 54 procedures. *Endoscopy* 2023; doi:10.1055/a-2109-4350
- [4] Yzet C, Rivory J, Wallenhorst T et al. A 3D-printed pedal fixator for connecting different pedal-operated tools reduces the number of mistakes during endoscopic submucosal dissection. *Endosc Int Open* 2023; 11: E635–E640
- [5] Fujimoto A, Saito Y, Abe S et al. Clinical usefulness of red dichromatic imaging in hemostatic treatment during endoscopic submucosal dissection: first report from a multicenter, open-label, randomized controlled trial. *Dig Endosc* 2022; 34: 379–390

Bibliography

Endoscopy 2024; 56: 242–243

DOI 10.1055/a-2224-8465

ISSN 0013-726X

© 2023. The Author(s).

This is an open access article published by Thieme under the terms of the Creative Commons Attribution License, permitting unrestricted use, distribution, and reproduction so long as the original work is properly cited.

(<https://creativecommons.org/licenses/by/4.0/>)

Georg Thieme Verlag KG, Rüdigerstraße 14, 70469 Stuttgart, Germany



ENDOSCOPY E-VIDEOS

<https://eref.thieme.de/e-videos>



E-Videos is an open access online section of the journal *Endoscopy*, reporting on interesting cases and new techniques in gastroenterological endoscopy. All papers include a high-quality video and are published with a Creative Commons CC-BY license. *Endoscopy E-Videos* qualify for HINARI discounts and waivers and eligibility is automatically checked during the submission process. We grant 100% waivers to articles whose corresponding authors are based in Group A countries and 50% waivers to those who are based in Group B countries as classified by Research4Life (see: <https://www.research4life.org/access/eligibility/>).

This section has its own submission website at <https://mc.manuscriptcentral.com/e-videos>