



**HAL**  
open science

## Management of intrahepatic and perihilar cholangiocarcinomas: Guidelines of the French Association for the Study of the Liver ( AFEF )

Cindy Neuzillet, Marie Decraecker, H el ene Larrue, Line Ntanda-Nwandji,  
Louise Barbier, Sandrine Barge, Arthur Belle, Carine Chagneau, Julien  
Edeline, Catherine Guettier, et al.

### ► To cite this version:

Cindy Neuzillet, Marie Decraecker, H el ene Larrue, Line Ntanda-Nwandji, Louise Barbier, et al.. Management of intrahepatic and perihilar cholangiocarcinomas: Guidelines of the French Association for the Study of the Liver ( AFEF ). Liver International, 2024, 10.1111/liv.15948 . hal-04647913

**HAL Id: hal-04647913**

**<https://hal.science/hal-04647913>**

Submitted on 16 Jul 2024

**HAL** is a multi-disciplinary open access archive for the deposit and dissemination of scientific research documents, whether they are published or not. The documents may come from teaching and research institutions in France or abroad, or from public or private research centers.

L'archive ouverte pluridisciplinaire **HAL**, est destin ee au d ep ot et  a la diffusion de documents scientifiques de niveau recherche, publi es ou non,  emanant des  tablissements d'enseignement et de recherche fran ais ou  trangers, des laboratoires publics ou priv es.



Distributed under a Creative Commons Attribution - NonCommercial - NoDerivatives 4.0  
International License

**REVIEW**

# Management of intrahepatic and perihilar cholangiocarcinomas: Guidelines of the French Association for the Study of the Liver (AFEF)

Cindy Neuzillet<sup>1</sup> | Marie Decraecker<sup>2</sup> | H el ene Larrue<sup>3</sup> | Line C. Ntanda-Nwandji<sup>4</sup> | Louise Barbier<sup>5</sup> | Sandrine Barge<sup>6</sup> | Arthur Belle<sup>7</sup> | Carine Chagneau<sup>8</sup> | Julien Edeline<sup>9</sup> | Catherine Guettier<sup>10</sup> | Florence Huguet<sup>11</sup> | J er mie Jacques<sup>12</sup> | Brigitte Le Bail<sup>13</sup> | Sarah Leblanc<sup>14</sup> | Ma it e Lewin<sup>15</sup> | David Malka<sup>16</sup> | Maxime Ronot<sup>17</sup> | V eronique Vendrely<sup>18</sup> |  Eric Vibert<sup>19</sup> | Christophe Bureau<sup>3</sup>  | Marc Bourliere<sup>20</sup> | Nathalie Ganne-Carrie<sup>21</sup> | Jean-Fr ed eric Blanc<sup>2</sup>

**Correspondence**

Jean-Fr ed eric Blanc, Oncology Digestive Unit, INSERM U1312, University Hospital of Bordeaux, Bordeaux, France.  
Email: [jean-fr ed eric.blanc@chu-bordeaux.fr](mailto:jean-fr ed eric.blanc@chu-bordeaux.fr)

**Handling Editor:** Alejandro Forner

**Abstract**

Intrahepatic cholangiocarcinoma (iCCA) is the second most common malignant primary liver cancer. iCCA may develop on an underlying chronic liver disease and its incidence is growing in relation with the epidemics of obesity and metabolic diseases. In contrast, perihilar cholangiocarcinoma (pCCA) may follow a history of chronic inflammatory diseases of the biliary tract. The initial management of CCAs is often complex and requires multidisciplinary expertise. The French Association for the Study of the Liver wished to organize guidelines in order to summarize the best evidence available about several key points in iCCA and pCCA. These guidelines have been elaborated based on the level of evidence available in the literature and each recommendation has been analysed, discussed and voted by the panel of experts. They describe the epidemiology of CCA as well as how patients with iCCA or pCCA should be managed from diagnosis to treatment. The most recent developments of personalized medicine and use of targeted therapies are also highlighted.

**KEYWORDS**

cytology, guidelines, interventional radiology, intrahepatic cholangiocarcinoma, pathology, perihilar cholangiocarcinoma, risk factor, screening, stenting, surgery, targeted therapies

**Abbreviations:** 5FU, 5-fluorouracil; ACE, carcinoembryonic antigen; AFP, alpha-fetoprotein; CCA, cholangiocarcinoma; C1gG4, (Immunoglobulin G4) cholangiopathy; CISGEM, Cisplatin - Gemcitabine; eCCA, extrahepatic cholangiocarcinoma; ERCP, endoscopic retrograde cholangiopancreatography; EUS, endoscopic ultrasound; FDG, fluorodeoxyglucose; FISH, fluorescence in situ hybridization; FNA, fine-needle aspiration; HCC, hepatocellular carcinoma; HPF, high power field; HR, hazard ratio; iCCA, intrahepatic cholangiocarcinoma; IHC, immunohistochemistry; LT, liver transplantation; MDT, multidisciplinary team meeting; MIP, maximum intensity projection; MPR, multiple plan reconstruction; MRI, magnetic resonance imaging; MSI, microsatellite instability; NGS, next-generation sequencing; ODD, odds ratio; OS, overall survival; pCCA, perihilar cholangiocarcinoma; PET, positron emission tomography; PSC, primary sclerosing cholangitis; RFS, recurrence-free survival; TLR, locoregional treatments.

For affiliations refer to page 14.

This is an open access article under the terms of the [Creative Commons Attribution-NonCommercial-NoDerivs](https://creativecommons.org/licenses/by-nc-nd/4.0/) License, which permits use and distribution in any medium, provided the original work is properly cited, the use is non-commercial and no modifications or adaptations are made.

  2024 The Authors. *Liver International* published by John Wiley & Sons Ltd.

## 1 | INTRODUCTION

Intrahepatic cholangiocarcinoma (iCCA) is the second most common malignant primary liver cancer just after hepatocellular carcinoma (HCC). Even though most cholangiocarcinomas (CCAs) in France are sporadic (i.e. without clearly identified risk factors), iCCA may develop on an underlying chronic liver disease and its incidence is growing in relation with the epidemics of obesity and metabolic diseases. In contrast, perihilar cholangiocarcinoma (pCCA) may follow a history of chronic inflammatory diseases of the biliary tract. The initial management of CCAs is often complex in patients presenting biliary obstruction, malnutrition and sepsis risk. Moreover, it is essential to ensure patient access to ever-improving medical, surgical and radiological therapies in the era of personalized medicine. Management requires multidisciplinary expertise in hepatogastroenterology (hospital and community practice), endoscopy, hepatobiliary surgery, oncology, radiology, anatomic pathology and supportive care.

The guidelines from the French Association for the Study of the Liver (AFEF; Association Française pour l'Étude du Foie) aim to cover the totality of iCCA and pCCA management, propose optimal care protocols for all disease stages and identify key elements of the care pathway to improve patient outcomes.

## 2 | GENERAL ORGANIZATION AND METHODS FOR THE GUIDELINES

These guidelines were developed by a group of experts brought together by AFEF with a methodology described in the appendix. Arguments are provided for each recommendation in the main text, and an extended version is presented in Appendix S2.

## 3 | CHAPTER 1: RISK FACTORS AND SCREENING

Intrahepatic cholangiocarcinomas (iCCAs) are the second most common primary liver cancer, sharing risk factors with hepatocellular carcinoma (HCC) such as cirrhosis, metabolic steatopathy, excessive alcohol use and hepatitis B and C viruses.<sup>1-16</sup>

Chronic biliary inflammation including chronic cholangitis, cystic diseases and biliary lithiasis<sup>17-24</sup> is the main risk factors of perihilar cholangiocarcinomas (pCCAs) in Europe.

Environmental factors, particularly liver fluke infections, contribute to high pCCA prevalence in Asia<sup>25,26</sup> while primary sclerosing cholangitis (PSC) is a significant risk factor in Europe and North America. French recommendations for the screening of cholangiocarcinoma in PSC were previously published.<sup>27</sup> Fibrocystic diseases, including Caroli's syndrome, increase the risk of iCCA,<sup>17</sup> while choledochal cysts, especially types I and IV, expose to a risk for bile duct and gallbladder cancers, with an incidence increasing with age.<sup>18</sup> Intrahepatic lithiasis and choledocholithiasis<sup>3</sup> are

### Key points

Cholangiocarcinomas are rare, heterogeneous cancers arising from the biliary tree. Their management is multidisciplinary, requiring a combination of radiological, anatomopathological, endoscopic, surgical, oncological, molecular and supportive care expertise. This review presents French recommendations for the diagnosis and treatment of these cancers.

strongly associated with CCA. Congenital fibrosis,<sup>4</sup> Von Meyenburg complexes,<sup>20</sup> ABCB4 mutations and LPAC syndrome<sup>28</sup> have controversial links to CCA, with a risk of malignancy too low to support a systematic screening.

General risk factors like type 2 diabetes, alcohol and tobacco use, chronic viral hepatitis and underlying liver diseases contribute to the increasing incidence of CCA, particularly iCCA.<sup>3</sup>

Lynch syndrome and BRCA1/2 mutations may also be associated with risk of CCA development in some families.<sup>29-33</sup> Mismatch repair deficiency is present in less than 1.5% of iCCAs,<sup>34</sup> and the relative risk for CCA development in patients with germline BRCA2 mutation is estimated at 5%.<sup>35</sup>

Others potential risk factors and the rationale for screening are detailed in Appendix S1.

### Guidelines

#### (1) What risk factors merit systematic investigation when cholangiocarcinoma is suspected?

It is recommended to search for the following risk factors: biliary cystic and lithiasic pathologies, PSC, cirrhosis, HBV/HCV infection, alcohol use, diabetes, smoking. Expert opinion: Strong agreement.

#### (2) Is there a place for targeted screening, and if so, in what situations and with what protocols (type and frequency)?

##### (2.1) Should patients with low phospholipid-associated cholelithiasis (LPAC) syndrome be screened for cholangiocarcinoma?

It is probably not recommended to propose cholangiocarcinoma screening to patients with LPAC syndrome in the absence of macrolithiasis. Expert opinion: Strong agreement.

##### (2.2) Should patients with Caroli disease be screened for cholangiocarcinoma?

It is probably recommended to propose cholangiocarcinoma screening to patients with Caroli disease. GRADE 2+; Strong agreement.

A yearly MRI may be proposed as a screening protocol. Expert opinion: Strong agreement.

(2.3) *Should patients with biliary hamartomas be screened for cholangiocarcinoma?*

The association between cholangiocarcinoma and biliary hamartoma is controversial and rare. It is probably not recommended to propose cholangiocarcinoma screening to patients with biliary hamartomas. GRADE 2-; Strong agreement.

**(3) What examinations should be done in the setting of cholangiocarcinoma screening for patients with PSC?**

It is recommended to propose cholangiocarcinoma screening to patients with primary sclerosing cholangitis (PSC). GRADE 1+; Strong agreement.

If the initial MRI was performed without contrast enhancement, it is recommended to perform an MRI with contrast enhancement in the 6 months following the diagnosis of PSC. GRADE 1+; Strong agreement.

When cholangiocarcinoma is suspected and after discussion in a multidisciplinary team meeting (MDT), it is recommended to perform biliary tract endoscopy for endobiliary tissue sampling. GRADE 1+; Strong agreement.

It is not recommended to assay CA19-9 for cholangiocarcinoma screening in patients with primary sclerosing cholangitis. GRADE 1+; Strong agreement.

It is recommended to perform yearly contrast-enhanced MRI for screening in this setting.

**(4) Is there a place for preventive interventions? Should patients with choledochal cysts undergo surgery?**

In the presence of a choledochal cyst associated with an anomalous pancreaticobiliary junction in an adult patient, it is probably recommended to propose cyst excision by a team with hepatobiliary surgery expertise. GRADE 2+; Strong agreement.

## 4 | CHAPTER 2: DIAGNOSIS AND PRETHERAPEUTIC WORKUP

### 4.1 | Intrahepatic cholangiocarcinoma

#### 4.1.1 | Imaging

Imaging for iCCA relies on a multimodal approach including multiphase CT scan, MRI/MR cholangiopancreatography (MRCP) and [<sup>18</sup>F]-fluorodeoxyglucose (FDG) PET scans.<sup>36</sup>

Multiphase liver CT is the standard imaging protocol for formal diagnosis, with a diagnostic performance of 70%, sensitivity of 78% and specificity of 80% in iCCA.<sup>37</sup> Its diagnostic performance for lymph node (LN) metastases is estimated at 77%.<sup>38</sup> Dynamic gadolinium-enhanced liver MRI increases specificity and is particularly useful in atypical forms of iCCA. The utility of FDG-PET scans

for assessing LN involvement and distant metastases remains to be evaluated. Meta-analyses showed that this technique offers only limited sensitivity of 52% and specificity of 91% for the detection of LN.<sup>39</sup> However, FDG-PET outperforms CT scan for the detection of distant metastases (88% vs. 79%, respectively).<sup>40,41</sup>

Contrast-enhanced ultrasound may improve the detection of nodules in cirrhosis but that its utility in characterizing cholangiocarcinoma lesions and in pretherapeutic assessment is not demonstrated.<sup>42,43</sup>

#### 4.1.2 | Endoscopy

Indications for upper gastrointestinal endoscopy to eliminate a primary gastric cancer or endoscopic ultrasound to eliminate pancreatic lesions as differential diagnoses of CCA should be discussed on a case-by-case basis in a multidisciplinary tumour board (MDT).

#### 4.1.3 | Histology

iCCAs are divided into several histological subtypes (small-duct or large-duct CCA) according to the mechanisms of carcinogenesis and their histological and immunohistochemical characteristics.

In the absence of chronic liver disease, the main differential diagnosis of iCCA is a liver metastasis of an adenocarcinoma from unknown primary origin. The 'basic' but not specific phenotype for iCCA is cytokeratin (CK)7+ CK20-. C-reactive protein (CRP) has proven useful for differentiating iCCA from liver metastases (sensitivity: 76%–93%; specificity: 88%–91%),<sup>44</sup> and particularly sensitive (97%) for small-duct subtype of iCCAs.<sup>45</sup>

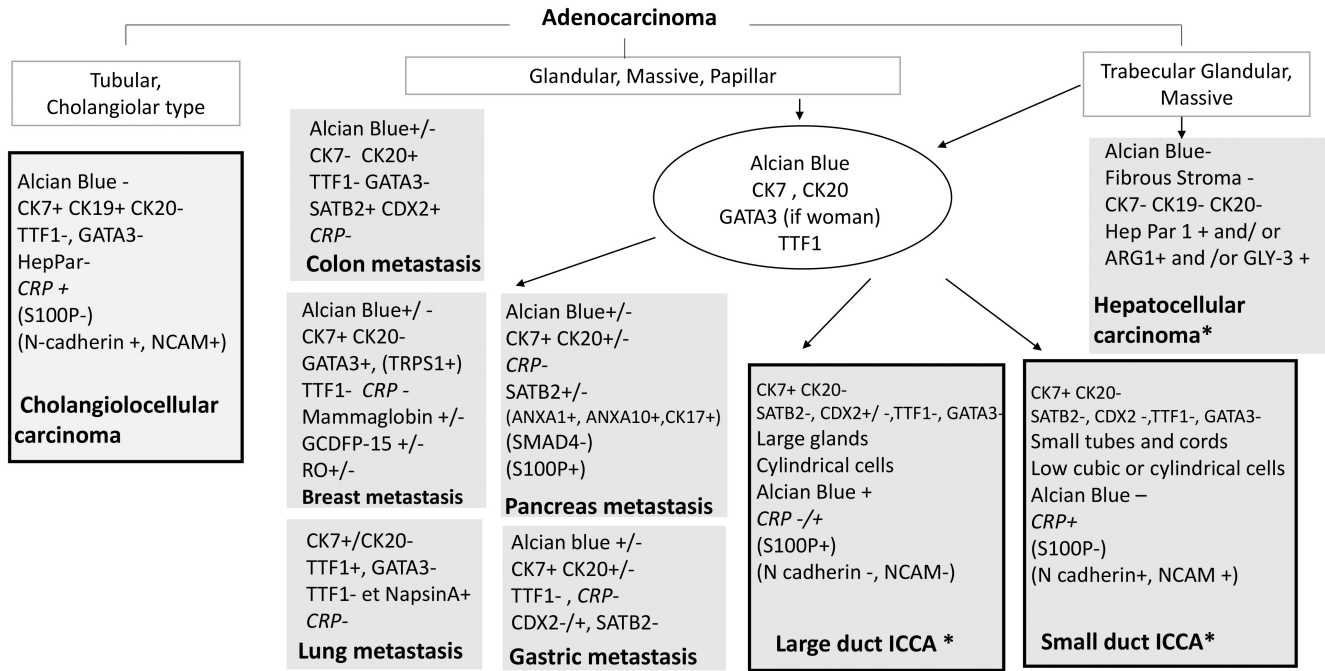
In daily practice, the CK7+ CK20- CRP+ phenotype associated with negative CDX2 or SATB2 (intestinal or gastric origin), TTF1 (pulmonary origin) and GATA3 (breast origin) transcription factors argues in favour of CCA.<sup>46-50</sup> The strategy for perform differential diagnostic between iCCA and liver metastatic adenocarcinoma from other origin is described in Figure 1.

A biopsy of non-tumoral liver tissue is essential as the presence of advanced fibrosis or cirrhosis will orient diagnostic hypotheses in different directions. In the setting of chronic liver disease, distinguishing iCCAs from HCCs when both are poorly differentiated, or iCCAs from scirrhous HCCs (often CK7 and/or CK19 positive) may prove difficult via morphology on a biopsy. Resultantly, hepatocellular (e.g. HepPar-1, glypican-3, Arginase-1, alpha-fetoprotein) and/or canalicular (e.g. CEA, CD10, BSEP) markers may be needed.

### 4.2 | Perihilar cholangiocarcinoma

#### 4.2.1 | Imaging

Multiphase liver CT with multiplanar reconstruction (MPR) and maximum intensity projection (MIP) performed upstream of any biliary stenting is the standard imaging method for local staging. This allows



**FIGURE 1** Main differential diagnosis of adenocarcinoma on liver biopsy, with classical profiles. A simple technical panel is proposed in the circle, including immunostaining and alcian blue staining for mucosecretion. If necessary, other markers may be useful and chosen on the basis of results from the initial panel and the clinical situation, taking care not to exhaust the sample, as molecular analysis must remain possible. New markers of interest are indicated (in italics and brackets). \*Unusual profiles are possible, particularly on biopsy, such as: CK7- (<5%) or CK19- (<10%), GATA3+ (5%–10%), Hepar +/GLY-3+ (<10%) or even AFP+ for CCI and CK7+, CK19+ (5%–20%), CK20 (<5%), HepPar1- or GLY-3 for HCC, depending on differentiation and HCC subtype. ARG-1, arginase 1; CRP, C-reactive protein; GCDPF-15, gross cystic disease fluid protein 15; GLY-3, glypican 3; RO, oestrogen receptor; TRPS1, trichorhinophalangeal syndrome type 1.

**Guidelines: diagnosis and pretherapeutic workup for iCCA**

**(1) What should the diagnostic and pretherapeutic workup include for iCCA?**

It is recommended to prioritize multiphase CT of chest, abdomen and pelvis GRADE 1+; Strong agreement.

In the absence of extrahepatic metastases, it is recommended to perform liver MRI (with MRCP in biliary diseases) GRADE 1+; Strong agreement.

It is recommended to perform a needle biopsy of liver tumour to confirm the diagnosis and eliminate differential diagnoses. GRADE 1+; Strong agreement.

It is not recommended to perform FDG-PET systematically for staging. Expert opinion: Strong agreement.

After biopsy, should doubt persist concerning liver metastases, it is recommended to pursue immunohistochemically guided evaluations with the goal of identifying an extrahepatic primary tumour (digestive endoscopy, FDG-PET). Expert opinion: Strong agreement.

**(2) What should the differential diagnosis procedure comprise for iCCA**

When a malignant lesion is suspected in a non-cirrhotic liver, it is recommended to prioritize biopsy as a means to guide complementary investigations. GRADE 1+; Strong agreement.

It is recommended to prioritize the following immunohistochemical panel to differentiate iCCA from liver metastases: CK7, CK20, CDX2/SATB2, TTF1 and GATA3 in women. GRADE 1+; Strong agreement.

It is probably recommended to use anti-CRP antibodies secondarily to differentiate CCA from liver metastases. GRADE 2+; Strong agreement.

It is probably recommended to systematically perform a concomitant biopsy of non-tumour liver tissue, away from the lesion, particularly when surgical intervention is under consideration. GRADE 2+; Strong agreement.

for the detection of the lesion and the evaluation of vascular involvement with 89% sensitivity and 93% specificity, and ductal extension with 86% sensitivity.<sup>51</sup> CT is also the gold standard for LN and metastatic staging and it furthermore enables volumetry when major liver resection is planned.<sup>52</sup>

MRI must associate MRCP and liver MRI with gadolinium injection. MRCP before biliary stent placement will provide precise information on ductal extent and facilitate the identification of liver metastases.

The utility of FDG-PET remains to be defined.

#### 4.2.2 | Endoscopy

Endoscopic ultrasound (EUS) is a minimally invasive technology for identifying pathological LNs and guiding fine-needle aspiration (FNA) biopsies.<sup>53-60</sup>

Because of its invasive nature, endoscopic retrograde cholangiopancreatography (ERCP) should be limited to cases for which cytology/histology samples or preoperative drainage is needed. Transpapillary brush cytology or forceps biopsy is recommended during ERCP, particularly if there is an indication for biliary drainage, as it confers specificity close to 100%.<sup>61-63</sup> The combination of the two sampling techniques during retrograde catheterization is valuable as it brings sensitivity up to 60%<sup>64</sup> with a minimum of five passes for brush cytology and three samples for forceps biopsy.<sup>65</sup>

Cholangioscopy enables the direct visualization of bile duct walls and several studies have confirmed its potential usefulness for pre-operative evaluation of the longitudinal extension of distal and hilar CCAs.<sup>66-68</sup>

The strategy for diagnostic and pretherapeutic workup for pCCA is described in Figure 2.

#### 4.2.3 | Histology

Cytology of bile aspirate is valuable only if the sample is taken at the stenosis. The examination of cytological or histological samples obtained by ERCP brush cytology or forceps biopsy, cholangioscopy biopsy or EUS-FNA requires specific expertise in anatomical pathology-cytopathology. Biliary brush cytology samples are best analysed via liquid-based cytology methods such as ThinPrep (Hologic) or PrepStain (BD SurePath), which provide an increase in diagnostic sensitivity and a reduction in inadequate samples. Endobiliary forceps biopsies obtained during ERCP (three ideally) or cholangioscopy (six ideally) can be analysed via standard buffered formalin fixation and paraffin embedding. At least three HES-stained sections are needed. Cyto block preparations are pertinent for such millimetric and fragmented samples.

Cyto block preparation is likely useful systematically for endobiliary biopsy samples to avoid any loss of material. In 2014, the

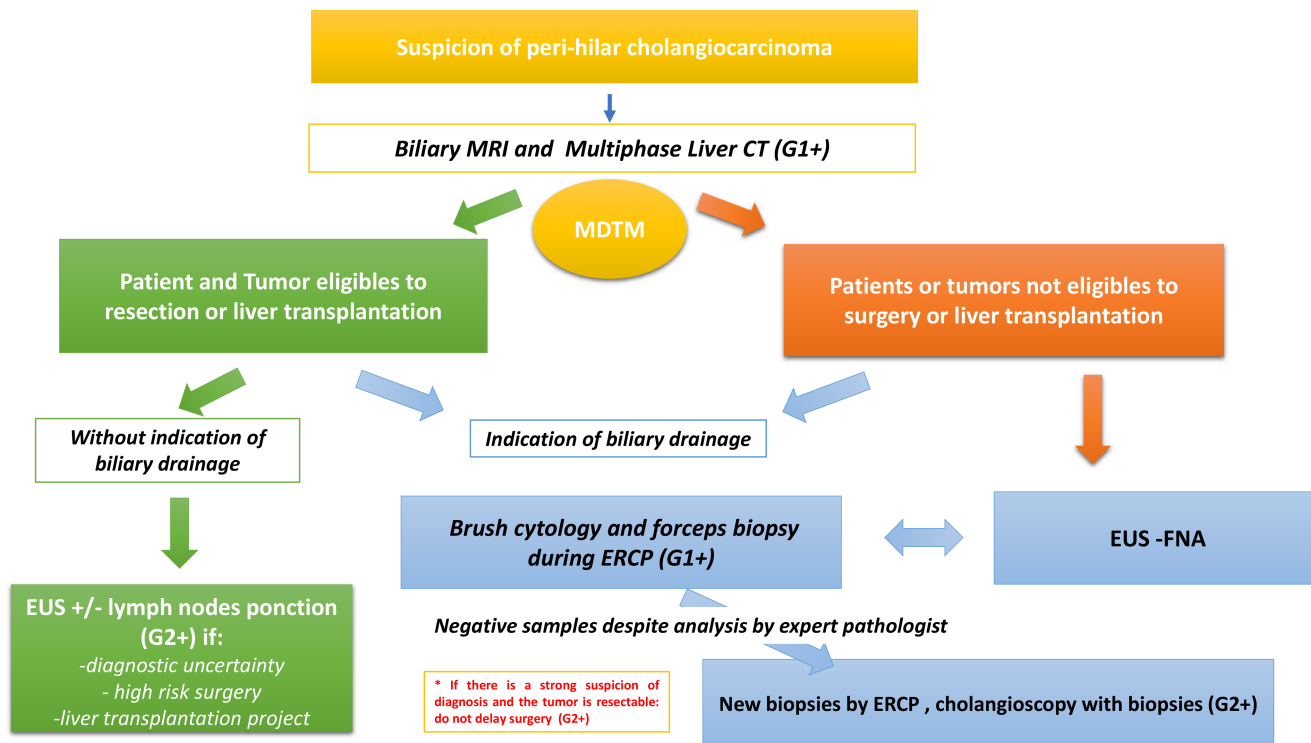


FIGURE 2 Strategy for diagnostic and pretherapeutic workup for pCCA. EUS, endoscopic ultrasonography; ERCP, endoscopic retrograde cholangiopancreatography; FNA, fine-needle aspiration, MDTM, multidisciplinary team meeting; pCCA, perihilar cholangiocarcinoma.

TABLE 1 Other causes of perihilar biliary strictures.

**1/ Benign, non-neoplastic peri hilar biliary strictures**

- Post-operative/traumatic: cholecystectomy, liver transplantation
- Inflammatory cholangitis: **PSC**, **IgG4 cholangitis**, eosinophilic cholangitis, follicular cholangitis, xanthogranulomatous cholangitis, mast cell cholangitis, sarcoidosis
- Lithiasic cholangitis: pyogenic recurrent cholangitis, Mirizzi syndrome
- Infectious cholangitis: HIV (cryptosporidiosis, others), tuberculosis, mycosis, parasitosis
- Vascular cholangitis: ischemia, portal biliopathy
- Toxic cholangitis: post-CEL, **immunotherapy**, radiotherapy

**2/ Peri hilar biliary strictures related to benign neoplasia**

- IPNB (intra canal papillary tumor), without invasive contingent
- Biliary adenoma, mucinous tumor of the bile ducts
- Granular cell tumors
- Benign peripheral nerve tumors

**3/ Peri hilar biliary strictures due to other cancers**

- Hepatocellular carcinoma (endobiliary growth)
- Metastases: colon, breast, other (endobiliary growth)
- Biliary NETs
- Lymphomas/leukemias/myelomas
- Sarcomas
- Melanoma
- Langerhans cell Histiocytosis X and Erdheim Cheister disease

Papanicolaou Society of Cytopathology proposed describing brush cytology and EUS-FNA samples via six categories: I–non-diagnostic; II–negative (for malignancy); III–atypical; IV–neoplastic: benign or other; V–suspicious (for malignancy); VI–positive/malignant (Papanicolaou guidelines hereafter).<sup>69</sup>

pCCA is the leading cause of perihilar biliary strictures that result in cholestatic jaundice. Other causes are most commonly benign inflammatory disorders. They are described in Table 1 and a special focus on PSC and IgG4-related sclerosing cholangitis is provided in Appendix S2.

**Guidelines: diagnosis and pretherapeutic workup for pCCA****(1) What should the diagnostic and pretherapeutic workup include for pCCA?**

It is recommended to perform multiphase CT and liver MRI with MRCP for the diagnosis and pretherapeutic workup of pCCA before any endoscopic interventions. GRADE 1+; Strong agreement.

It is not recommended to perform percutaneous biopsy of the primary tumour. GRADE 1–; Strong agreement.

It is not recommended to perform systematically FDG-PET for staging. Expert opinion: Strong agreement.

It is probably recommended to assay IgG4 in blood when the diagnosis remains uncertain or histological evidence of CCA is absent. GRADE 2+; Strong agreement.

**(2) In what way can endoscopic ultrasound contribute to pCCA staging?**

It is probably recommended to perform endoscopic ultrasound and LN FNA for non-metastatic pCCA staging, as it performs better than CT or MRI imaging for the identification of metastatic lymphadenopathies. GRADE 2+; Strong agreement.

**(3) Should ERCP be done for pCCA staging?**

It is probably not recommended to perform ERCP for pCCA staging. GRADE 2–; Strong agreement.

**(4) In what way can cholangioscopy contribute to pCCA staging?**

It is probably not recommended to perform cholangioscopy in first intent for tissue sampling. GRADE 2–; Strong agreement.

**(5) When and how should histology samples be obtained for pCCA?**

It is probably recommended to obtain histological evidence as per the proposed algorithm. Endoscopic techniques (transpapillary brush cytology, forceps biopsy and EUS-FNA) are complementary. They may furthermore be combined (if indication to a biliary drainage) to improve their poor individual diagnostic performance GRADE 2+; Strong agreement.

For metastatic disease, it is recommended to biopsy the most easily accessed site. GRADE 1+; Strong agreement.

It is probably recommended to not delay surgical management when cancer is strongly suspected even if biopsies are negative. GRADE 2+; Strong agreement.

It is probably not recommended to perform ERCP sampling if there is no associated indication for biliary drainage. Expert opinion: Strong agreement.

It is recommended to discuss the utility of EUS-FNA of the primary tumour with a hepatobiliary surgeon in case of resectable/transplantable tumour, due to the hypothetical risk of needle tract seeding. Expert opinion: Strong agreement.

When LN is visualized during EUS, it is probably recommended to biopsy them systematically because of their prognostic impact able to modify the therapeutic approach. GRADE 2+; Strong agreement.

It is recommended to perform both brush cytology and forceps biopsy during the initial ERCP. GRADE 1+; Strong agreement.

**(5) What are the recommendations for pathologists concerning the technical aspects of biliary cytology and the writing of reports?**

It is recommended to employ thin-layer cytology techniques for biliary brush cytology. GRADE 1+; Strong agreement.

It is recommended to employ cytoblock techniques for EUS-FNA samples of perihilar biliary lesions. GRADE 1+; Strong agreement.

It is probably recommended to employ cytoblock techniques for endobiliary forceps biopsy samples. GRADE 2+; Strong agreement.

It is recommended to report perihilar biliary lesion brush cytology and EUS-FNA cytopathology results using Papanicolaou guidelines. Expert opinion: Strong agreement.

When an initial biliary brush cytology is negative, it is probably recommended to repeat ERCP in a specialized centre and to combine endobiliary brush cytology and forceps biopsy. GRADE 2+; Strong agreement.

In the presence of an initial atypical biliary sample from a hilar stenosis, it is probably recommended to propose cytological examination within a delay of 14 days, and, should the diagnosis remain uncertain thereafter, repeat ERCP in a specialized centre, combine endobiliary brush cytology and forceps biopsy and discuss cholangioscopy. GRADE 2+; Strong agreement.

A suspicious cytology result as defined in the Papanicolaou guidelines is sufficient for initiating chemotherapy or planning surgery once validated in a specialized MDT. Expert opinion: Strong agreement.

In the presence of two consecutive negative cytology/histology results but a clinical and radiological presentation indicative of CCA, and after cholangioscopy and IgG4 assay, the possibility of initiating chemotherapy in patients with unresectable tumours must be validated in an MDT. Expert opinion: Strong agreement.

It is probably recommended to perform diagnostically aimed molecular analyses such as NGS on negative, atypical or suspicious perihilar biliary stricture samples from patients with PSC. GRADE 2+; Strong agreement.

It is probably not recommended to perform systematically fluorescence in situ hybridization (FISH) in endobiliary samples to detect genetic abnormalities. GRADE 2-; Strong agreement.

It is recommended to perform IgG4 and IgG immunostaining on endobiliary biopsies with lymphoplasmacytic infiltration, quantify IgG4-positive plasma cells and evaluate the IgG4/IgG ratio (threshold >40%). GRADE 1+; Strong agreement.

It is recommended to not establish a histological diagnosis of ClgG4 based on the sole number of intratissular IgG4-positive plasma cells, but rather incorporate in that diagnosis at least two of the three cardinal signs: storiform fibrosis, phlebitis, lymphoplasmacytic infiltration. Expert Opinion, Strong agreement.

## 5 | CHAPTER 3: BILIARY DRAINAGE

### 5.1 | Biliary drainage in curative or potentially curative situations

As suboptimal drainage or complications (infection particularly) may complicate possible curative surgery, complete staging and assessment of operability should be done before deciding on drainage, after patient case discussion in an MDT. In emergency situation (sepsis) wherein pre-intervention complete staging and discussion with surgical team are not possible, drainage should be deployed via removable devices (plastic stents or external drainage). Preoperative biliary drainage is considered in cases of cholangitis, hepatobiliary sepsis, comorbidities, jaundice (bilirubin >50 μmol/L), indication of neoadjuvant therapy or extensive surgery (>50% of liver parenchyma). Left lobectomy cases do not require preoperative drainage, as it may increase infection-related morbidity. Biliary drainage, performed by an experienced operator, does not increase morbidity in hepatobiliary surgery and should include drainage of all opacified segments, avoiding atrophic segments and draining at least 50% of functional hepatic parenchyma.<sup>70-75</sup>

### 5.2 | Biliary drainage in palliative situation

In palliative care, the goal is to drain an adequate hepatic volume (≥50%) unilaterally or bilaterally, clarified by MRCP. Indications for



biliary drainage should be discussed in an MDT. Uncovered metal stents are preferred over plastic stents in unresectable pCCA,<sup>76-78</sup> with permanent metal stents reserved for cases with histological confirmation and contraindications for surgery. If ERCP-guided drainage is insufficient, supplementary EUS-guided hepaticogastrostomy left-side drainage or CT-guided percutaneous drainage can be considered, with priority given to EUS-guided drainage whenever possible.<sup>79</sup>

### Guidelines

#### (1) What are the indications for biliary drainage in (potentially) resectable pCCA?

For patients with (potentially) curable disease, it is recommended to discuss biliary drainage collegially in the presence of a hepatobiliary surgeon, an endoscopist and a radiologist. GRADE 1+; Strong agreement.

It is recommended to stage the disease (CT, MRI) before any biliary drainage to avoid compromising lesion resectability assessments. GRADE 1+; Strong agreement.

It is probably recommended to privilege endoscopic techniques for preoperative drainage when it is indicated. GRADE 2+; Strong agreement.

It is recommended to use removable plastic stents for preoperative drainage when it is indicated. GRADE 1+; Strong agreement.

If the diagnosis is uncertain or a therapeutic strategy has not been established (emergency), removable plastic stents must be used. Expert opinion: Strong agreement.

It is not recommended to deploy biliary drainage for cholestasis without jaundice. GRADE 1-; Strong agreement.

#### (2) What are the protocols for biliary drainage in palliative care?

In the palliative setting, it is recommended to perform biliary drainage in a centre specialized in biliopancreatic disease with pertinent radiological and endoscopic competencies. GRADE 1+; Strong agreement.

It is recommended to use uncovered metal stents, which offer longer patency. GRADE 1+; Strong agreement.

When ERCP-guided biliary drainage is impossible or insufficient, the case should be discussed among radiologists and endoscopists to determine the complementary drainage best suited to the patient's needs (CT-guided percutaneous or EUS-guided hepaticogastrostomy). Expert opinion: Strong agreement.

If percutaneous drainage is deployed, it is recommended to avoid the use of a permanent external drain. Expert opinion: Strong agreement.

## 6 | CHAPTER 4: SURGERY: RESECTION AND TRANSPLANTATION

### 6.1 | Intrahepatic cholangiocarcinoma

A resectable iCCA is defined as complete resection of all disease while leaving a functional liver remnant<sup>80</sup> in terms of volume, the Glissonian pedicles and venous drainage. Less than 15% of patients with iCCA are candidates for surgery, which is nonetheless the treatment offering the best survival for localized lesions.<sup>81</sup>

Exploratory laparoscopy to assess tumour resectability may be proposed,<sup>82,83</sup> especially for patients with high CA 19-9 serum levels, these latter suggesting carcinosis or major vascular invasion.<sup>84</sup>

#### 6.1.1 | Prognostic factors

Poor prognostic factors<sup>85-96</sup> are (1) biology: high CA 19-9, high CEA, hypoalbuminemia, the ALBI score, the prognostic nutritional index, albumin/gamma-glutamyltransferase ratio and neutrophil/lymphocyte ratio; (2) morphology: presence of multiple nodules (>3) or satellite nodules (intrahepatic metastases <2cm at <2cm from the primary nodule) and large size (non-consensually >50-75 mm), (3) histology: LN involvement, R1 resection (margin <1 mm), vascular invasion, poor differentiation and perineural invasion. LN involvement and resection margin status are the two elements most highly associated with poor prognosis.<sup>97</sup>

#### 6.1.2 | Recurrence

Early recurrence usually occurs intra- (24% around the resection margins, 29% distantly) and/or extrahepatically (15% uniquely extrahepatic, 32% intra- and extrahepatic). The risk of early recurrence is largely dependent on tumoral characteristics (R1, N+)<sup>98</sup> and the risk of late recurrence (>2 years) on the presence of underlying liver disease, justifying prolonged surveillance.

#### 6.1.3 | Resectability

Because R1 margin classification is a poor prognosis factor affecting both overall survival (OS) and recurrence-free survival (RFS), R0 classification, with a 5-year survival rate of 40%, must be the aim of surgery. The desired clean margin size varies across studies from 9 to 10 mm.<sup>99</sup>

LN involvement beyond the Glissonian pedicle carries the same prognostic weight as visceral metastases and is thus a contraindication for resection. Lymphadenectomy contributes to survival even when there is no preoperative suspicion of involvement.<sup>100-102</sup> Removal of  $\geq 6$  LNs is recommended.

## 6.1.4 | Liver transplantation

Recurrence is particularly low when liver transplantation (LT) is done for 'very early' iCCA (single tumours  $\leq 2$  cm).<sup>103,104</sup>

LT for locally advanced unresectable iCCA has been studied in patients who showed  $\geq 6$  months of tumour stability after neoadjuvant therapy associating gemcitabine with cisplatin or capecitabine. A 5-year survival rate of 83% was reported, but with recurrence in half of the patients.<sup>105</sup>

## 6.2 | Perihilar cholangiocarcinoma

A resectable pCCA is defined as complete resection of all disease while leaving a functional liver remnant in terms of volume, the Glissonian pedicles and venous drainage. In this setting, most hepatectomies are extensive and include resection of the biliary confluence, sometimes the portal vein bifurcation and rarely the hepatic artery.<sup>106,107</sup>

### 6.2.1 | Prognostic factors

The prognostic factors affecting OS<sup>108,109</sup> are: (1) as concerns biology, preoperative bilirubin  $>50 \mu\text{mol/L}$ ; (2) as concerns surgery, use of intraoperative transfusions and combined vascular resection; (3) as concerns histology, lymph node involvement, R1 classification, perineural invasion, pTNM stage  $>T3$  and poor differentiation.

Factors affecting both morbidity and mortality are preoperative cholangitis, low indocyanine green clearance, future liver remnant (FLR) volume  $<30\%$ , blood loss, age, vascular reconstruction, incomplete biliary drainage associated with an FLR  $<50\%$ , right (extended) lobectomy and undrained preoperative jaundice (total bilirubin  $>50 \mu\text{mol/L}$ ).<sup>110</sup>

### 6.2.2 | Resectability

Because R1 classification is also a poor prognosis factor affecting both OS and RFS, R0 classification must be the aim of surgery.

Numerous studies have shown the benefits of resecting the associated liver segment, for both survival and the obtainment of R0 margins. This holds true in Bismuth–Corlette type I and II cancers. Because they drain bile close to the hilum confluence, liver segments I and IVb must be systematically resected. Because of the surgical morbidity and mortality associated with it, Whipple procedures are rarely done in association with extended liver resections for pCCA.

LN involvement is also a leading poor prognostic factor. Factors associated with LN involvement are age, serum CA 19–9  $>200 \text{IU/L}$ , tumour size and Bismuth–Corlette classification.<sup>111</sup> The removal of  $\geq 5$  LNs is recommended.

## 6.2.3 | Liver transplantation

LT has pertinence for some pCCAs. Particularly, the protocol developed by the Mayo Clinic enables LT after neoadjuvant therapy in young, selected patients with localized but not locally resectable tumours (extension to secondary ducts or underlying hepatopathy (e.g. PSC) contraindicating extensive hepatectomy).<sup>112–114</sup> The criteria of the United Network for Organ Sharing (UNOS) require no lymph node involvement, no transperitoneal biopsy and a transversal tumour diameter  $<3$  cm. The Mayo protocol comprises 5-flouracil chemosensitization, external beam radiotherapy with a boost and finally the LT. Just before inscription on the transplant waiting list, an exploratory laparoscopy is performed, during which a lymphadenectomy is done for histological examinations to definitively rule out any LN involvement. Of the patients for whom LT is indicated, 25%–30% will ultimately not undergo the surgery, notably because of tumoral progression.

### Guidelines

#### *Intrahepatic cholangiocarcinoma*

##### **(1) In what situations should surgery be proposed for iCCAs?**

Following an evaluation of the non-tumoral liver and a systematic search for any underlying chronic liver disease, it is recommended to propose resection surgery and lymphadenectomy for non-metastatic (excluding satellite nodules and locoregional lymph nodes) iCCAs. GRADE 1+; Strong agreement.

The presence of any one poor prognostic factor (regional LN involvement, size  $>75$  mm, elevated CA 19–9 and/or CEA, multiple nodules, likely R1 status) is not a contraindication for surgery. Expert opinion: Strong agreement.

It is probably not recommended to perform surgery when  $\geq 2$  poor prognostic factors are present. GRADE 2–; Strong agreement.

If doubt persists on the resectability of an iCCA (complex case, suspicion of peritoneal carcinosis), exploratory laparoscopy may be proposed. Expert opinion: Strong agreement.

##### **(2) What should the goal be for the resection margin?**

It is probably recommended to aim for a resection margin of 10 mm when possible, in iCCA. GRADE 2+; Strong agreement.

##### **(3) What should lymphadenectomy comprise in iCCA resection?**

It is recommended to perform regional lymphadenectomy with  $\geq 6$  LNs removed, regardless of preoperative invasion assessments, as these latter are poorly sensitive. GRADE 1+; Strong agreement.

**(4) What is the place of LT in iCCA?**

It is probably not recommended to propose liver transplantation in iCCA outside of clinical studies. GRADE 2-; Strong agreement.

**Perihilar cholangiocarcinoma****(1) In what situations should surgery be proposed for pCCAs?**

Following an evaluation of the future liver remnant (volume, cholestasis) and systematic search for any underlying hepatopathy or cholangiopathy, it is recommended to propose resection and lymphadenectomy for non-metastatic pCCAs. GRADE 1+; Strong agreement.

It is probably not recommended to propose resection in the presence of locoregional LN involvement or likely R1 status. GRADE 2-; Strong agreement.

If there is doubt on the resectability of a pCCA, exploratory laparoscopy may be proposed. Expert opinion: Strong agreement.

**(2) What should the goal be for the resection margin?**

It is not recommended to propose resection in pCCA if R2 margins are likely. GRADE 1-; Strong agreement.

It is recommended to aim for healthy R0 margins in pCCA resection. GRADE 1+; Strong agreement. It is recommended to resect associated segments, at least segments I and IVb, to increase the rate of clean margins in pCCA. GRADE 1+; Strong agreement.

It is recommended to perform en bloc resection of the portal vein bifurcation when invasion is suspected to enlarge the circumferential margin for pCCAs. GRADE 1+; Strong agreement.

It is probably not recommended to perform arterial resections systematically or associate Whipple procedures for pCCAs. GRADE 2-; Strong agreement.

**(3) What should lymphadenectomy comprise in pCCA resection?**

It is probably recommended to perform regional lymphadenectomy with  $\geq 5$  LNs removed GRADE 2+; Strong agreement.

**(4) What is the place of LT in pCCA?**

It is probably recommended to propose liver transplantation to selected patients with localized unresectable pCCA tumours not exceeding 30mm and absence of lymph node involvement after a course of neoadjuvant therapy as defined in a liver transplant centre. GRADE 2+; Strong agreement.

**7 | CHAPTER 5: LOCOREGIONAL TREATMENT****7.1 | Rationale**

Locoregional treatments (LRTs) comprise a range of ablative (radiofrequency, microwave, irreversible electroporation, cryoablation and by extension stereotactic radiation therapy) and intra-arterial (embolization, chemoembolization, radioembolization, intra-arterial chemotherapy) therapies. In the setting of unresectable iCCA, these LRTs may be deployed first line or second line when systemic chemotherapy fails to halt tumour progression. The levels of evidence concerning the efficacy and oncological benefits of LRTs are low, with most of the available data acquired from heterogenous studies (in patient selection, place of LRTs in the therapeutic strategy, employed techniques, judgement criteria) usually retrospective in nature.<sup>115-121</sup>

**7.2 | Radiation therapy****7.2.1 | Unresectable or inoperable CCA**

Most data for inoperable CCA come from non-comparative retrospective studies including both iCCAs and eCCAs. 45-Gray (Gy) to 54-Gy radiation therapies were delivered with conventional fractionation, often in association with 5-FU/platinum chemotherapies with acceptable toxicities. Median OSs varied from 11 months to 15 months.<sup>122-125</sup>

- Complementary biliary brachytherapy after chemoradiotherapy (CRT): Several retrospective studies have reported improved local control when complementary brachytherapy is administered, but the largest comparative retrospective study did not find any significant differences as concerns OS.<sup>126</sup>
- Stereotactic radiation therapy: Several trials and meta-analyses have suggested that stereotactic radiation therapy may provide benefits, including improved local control and OS and acceptable toxicity in iCCA.<sup>127</sup>

**7.2.2 | Perioperative treatments**

Preoperative CRT tends to increase R0 resection rates and OS.<sup>128</sup> Neoadjuvant radiation therapy in the setting of LT for pCCA has been studied in small, single-centre studies with differing administration protocols.<sup>112</sup>

The studies on adjuvant radiation therapy in pCCA are largely retrospective, with low levels of evidence and contradictory

results.<sup>129-132</sup> Chemotherapy and CRT have never been compared in prospective trials.

### Guidelines

#### (1) What is the place of interventional radiologic locoregional treatments in CCA?

It is not recommended to perform intra-arterial treatments alone if standard treatments are possible. GRADE 1-; Strong agreement.

Percutaneous ablation may be considered for unique iCCA <3cm if surgical resection is not possible. Expert opinion: Strong agreement.

Intra-arterial treatments may be prioritized in association with first-line systemic chemotherapy in patients with unresectable iCCA and no extrahepatic disease. Expert opinion: Strong agreement.

Isolated intra-arterial treatment may be discussed as an alternative after failure of standard systemic treatments for iCCA without extrahepatic progression. Expert opinion: Strong agreement.

It is not recommended to propose interventional radiology for pCCA. GRADE 1-; Strong agreement.

#### (2) What is the place of endoscopic ablation techniques?

It is not recommended to perform endoscopic ablation techniques (photodynamic therapy, endobiliary radiofrequency) outside of the clinical trial setting. GRADE 1-; Strong agreement.

#### (3) What is the place of radiation therapy in inoperable CCA?

It is probably not recommended to propose conventional CRT for patients with unresectable iCCA or pCCA outside of the therapeutic trial setting. GRADE 2-; Strong agreement.

Stereotactic body radiation therapy may be considered for unique iCCA lesions <5 cm if surgical resection is not possible. Expert opinion: Strong agreement.

#### (4) What is the place of radiation therapy in the perioperative treatment of pCCA?

It is probably not recommended to propose neoadjuvant radiation therapy for patients with pCCA if transplantation is not being planned. GRADE 2-; Strong agreement.

Adjuvant CRT can be discussed in a specialized MDT for patients with pCCA and R1 resection results after a chemotherapy course. Expert opinion: Strong agreement.

## 8 | CHAPTER 6: SYSTEMIC TREATMENTS

### 8.1 | Adjuvant therapies

Several randomized phase 3 trials that compared adjuvant gemcitabine-based protocols (gemcitabine, gemcitabine-oxaliplatin (GemOx)) to surveillance failed to provide any clear benefit for median survival.<sup>131,133-135</sup> In the British BILCAP study, 447 patients were randomized into observation or treatment with adjuvant oral capecitabine (1250 mg/m<sup>2</sup> twice daily, 2 weeks out of three, for eight cycles/6 months)<sup>130</sup> with a reported good tolerability. Improvement in OS (primary objective) did not reach statistical significance in the intention-to-treat analysis but it did once adjust on gender, node status and histological grade (HR: .71,  $p = .01$ ). Improvement in RFS (secondary objective) was also significant, but only during the first 24 months following surgery. Based on these results, adjuvant capecitabine for 6 months is considered as a standard in patients with resected iCCA and pCCA.

### 8.2 | Advanced disease: First-line treatments

Chemotherapy regimens combining platinum with another agent (mainly gemcitabine) appear to outperform best supportive care (BSC) and fluoropyrimidine or gemcitabine monotherapy.<sup>124,136-159</sup> The ABC-02 trial established the combination of cisplatin and gemcitabine (CisGem) as the backbone standard chemotherapy in CCA.<sup>141</sup> There is no additional benefit to combine three cytotoxic drugs (as FOLFIRINOX or cisplatin-gemcitabine-nab-paclitaxel regimens) or to add VEGF<sup>160</sup> or EGFR<sup>145</sup> inhibitors to platinum-gemcitabine regimen. Two international, phase-3 randomized controlled trial showed a benefit of immunotherapy addition to CisGem: TOPAZ-1 with durvalumab<sup>161</sup> and Keynote 966 with pembrolizumab.<sup>162</sup> The TOPAZ-1 trial showed that first-line CisGem plus durvalumab provided better OS (primary objective), response rates and progression-free survival (PFS) than CisGem plus placebo. Similarly, addition of pembrolizumab to CisGem regimen improved the OS compared to CisGem plus placebo.

### 8.3 | Advanced disease: Second-line treatments

The available studies, the large majority of which were non-randomized and the majority retrospective, report low response rates (3%-12%) and modest PFS (1.9-4 months) and OS (6.2-11 months) medians.<sup>163-173</sup> More recently, the ABC-06 trial, a randomized phase III trial showed an increased OS in patients treated by FOLFOX compared to those receiving best supportive care and established FOLFOX regimen as the standard of care chemotherapy in second line. However, the benefit is weak (less than 1 month in median OS, 5% response rate) and we do not have strong evidence

TABLE 2 Clinical trials in second line with targeted therapies.

Drug	Target	Ref	Phase	N	OS (months)	PFS (months)	ORR
Ivosidenib	IDH1	Abou-Alfa <sup>180</sup>	III	124	10.3	2.7	25%
Pemigatinib	FGFR2 fusion	Abou-Alfa <sup>181</sup>	II	100	17.5	7	38.5%
Futibatinib	FGFR2 fusion	Goyal <sup>182</sup>	II	103	21.7	8.9	41.7%
Derazantinib	FGFR2 fusion	Mazzafero <sup>183</sup>	II	29	17.2	7.8	22%
Infigratinib	FGFR2 fusion	Javle <sup>184</sup>	II	122	12.2	7.3	23.1%
RLY-4008	FGFR2 fusion	Borad <sup>185</sup>	I	38			63%–88%
Pertuzumab + Trastuzumab	HER2 (IHC 3+) or amplification (FISH/NGS)	Javle <sup>186</sup>	II	39	10.9	4	23%
Neratinib	HER2 mutation	Harding <sup>187</sup>	II	25	5.4	2.8	16%
Trastuzumab Deruxtecan	HER2 (IHC 3+) or IHC 2+ and FISH +	Obha <sup>188</sup>	II	22	5.1	7.1	36.4%
Tucitanib + trastuzumab	HER2 3+ or amplification (FISH/NGS)	Nakamura <sup>189</sup>	II	29	15.5	5.5	46.7%
Zanidatamab	HER (IHC 2–3+) and amplification (FISH)	Harding <sup>190</sup>	IIb	80	Not reach	5.5	41.3%
Dabrafenib + Trametinib	b-raf V600E	Subbiah <sup>191</sup>	II	43	14	9	20%

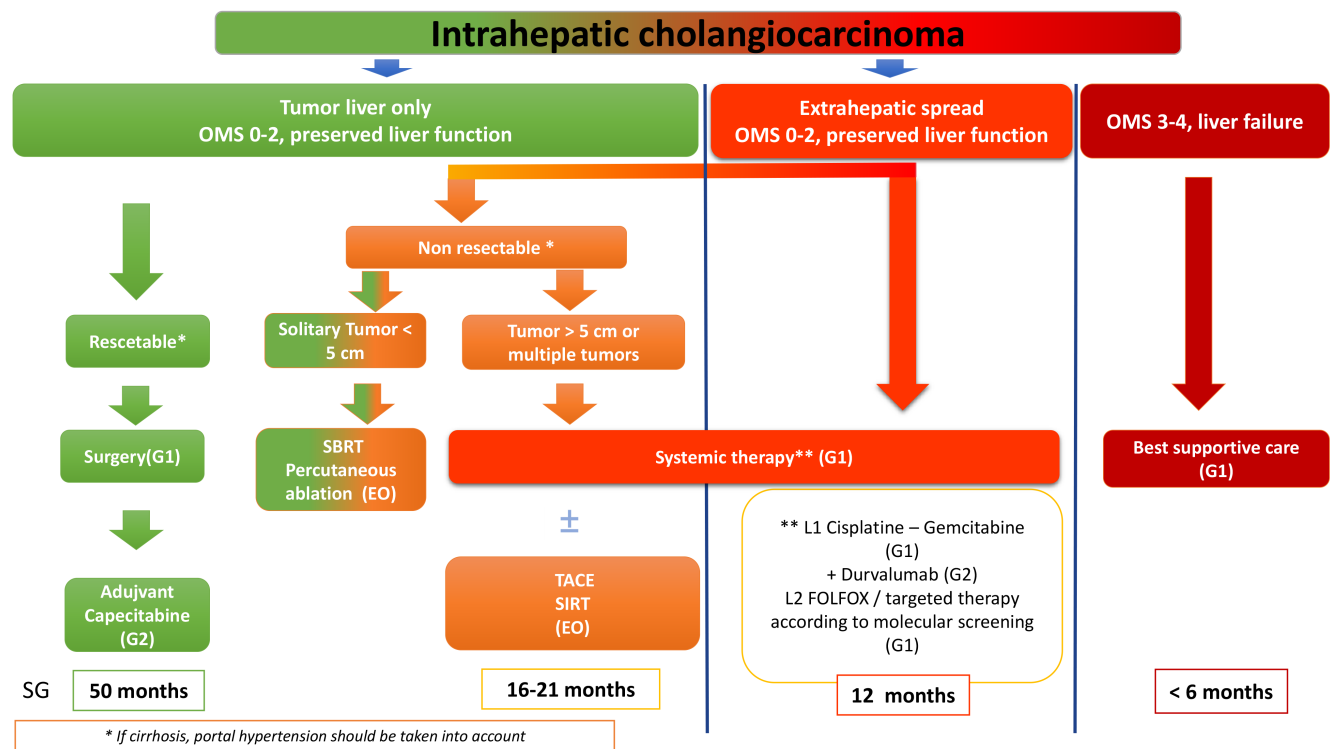


FIGURE 3 Therapeutic algorithm for intrahepatic cholangiocarcinoma. EO, expert opinion; SBRT, stereotactic body radiation therapy; SIRT, selective internal radiation therapy; TACE, trans-arterial chemoembolization.

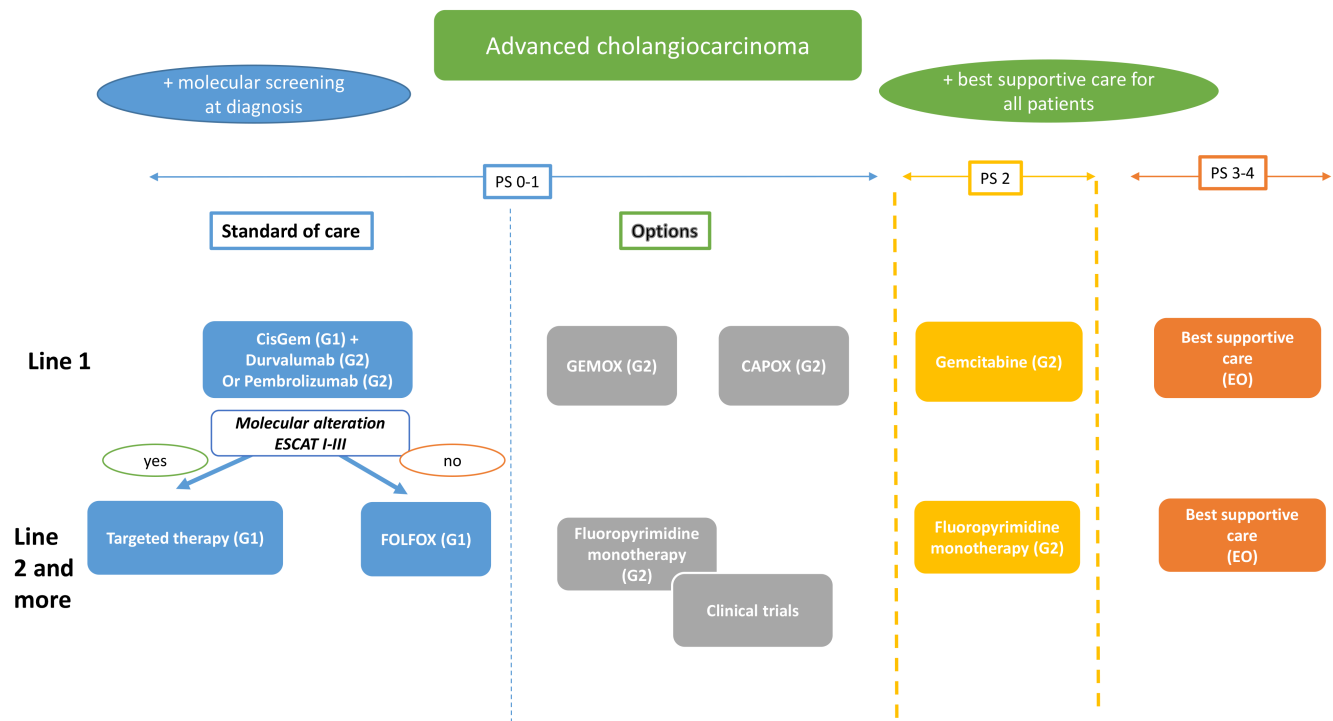


FIGURE 4 Systemic therapy for advanced cholangiocarcinoma: therapeutic algorithm. EO, expert opinion.

supporting a clear advantage for combined chemotherapies over monotherapies (notably fluoropyrimidine). There is not enough data to support the place of irinotecan (or nanoliposomal irinotecan) alone or in combination with fluoropyrimidines as a standard of care in second line in European patients.

## 8.4 | Genetic alterations in CCA and targeted therapies

High-throughput sequencing studies have revealed high molecular heterogeneity in CCA and numerous potential therapeutic targets (IDH1/2, FGFR2, BRAF, HER2, MSI, NTRK, etc.).<sup>174-179</sup>

The main results of trials evaluating targeted therapies in second or third line are summarized in Table 2. Among them, ivosidenib, an orally administered therapeutic that targets mutated isocitrate dehydrogenase 1 (IDH1), was the only drug evaluated in phase III trial after CisGem failure and significantly improved PFS and offered good tolerability when compared to placebo.<sup>180</sup> Several phase 2 trials suggest an interest for treatments targeting FGFR2, BRAF, KRAS G12C, HER2, NTRK in advanced CCA.<sup>181-205</sup> CCAs with microsatellite instability (MSI) have been shown to respond to anti-programmed death-1 (PD-1) antibodies.<sup>206,207</sup>

Main results of clinical trials with targeted therapies are presented in Table 2.

Therapeutic algorithms are presented in Figure 3 (global strategy for iCCA) and Figure 4 (systemic treatment of advanced CCA).

### Guidelines

#### (1) What adjuvant therapies are recommended?

It is probably recommended to propose a 6-month regimen of adjuvant capecitabine after surgical resection of iCCAs or pCCAs showing R0 or R1 margins only in patients with otherwise good PS (ECOG score 0–1) and in a postoperative delay of no more than 16 weeks. GRADE 2+; Strong agreement.

It is not recommended to use gemcitabine chemotherapy, alone or in association, in adjuvant setting. GRADE 1–; Strong agreement.

In pCCA with R1 margins, a 4- to 6-month regimen of adjuvant capecitabine followed by CRT with capecitabine can be discussed in a specialized MDT. Expert opinion: Strong agreement.

#### (2) What chemotherapies are recommended as first- and second-line treatments?

##### First line

- It is recommended to propose cisplatin–gemcitabine as chemotherapy backbone for patients with good PS (e.g. ECOG 0–1). GRADE 1+; Strong agreement.

- It is probably recommended to add durvalumab or pembrolizumab to a 6-month cisplatin–gemcitabine regimen in patients with good PS (ECOG 0–1). GRADE 2+; Strong agreement.
- When cisplatin–gemcitabine is contraindicated, it is probably recommended to propose capecitabine and oxaliplatin (CAPOX) (GRADE 2+; strong agreement) or gemcitabine–oxaliplatin (GEMOX) regimens (expert opinion; strong agreement).
- It is probably recommended to propose gemcitabine alone for patients with impaired PS (e.g. ECOG 2) GRADE 2+; Strong agreement.

#### Second line

- It is recommended to prioritize the pertinent targeted treatment for 'actionable' molecular alterations (ESMO Scale for clinical actionability of molecular targets (ESCAT) I–II). GRADE 1+; Strong agreement.
- In patients with good PS (e.g. ECOG 0–1) who show progression after first-line gemcitabine or cisplatin–gemcitabine but lack actionable molecular alterations, it is recommended to propose FOLFOX (5FU-folinic acid-oxaliplatin). GRADE 1+; strong agreement.
- Fluoropyrimidine alone can be proposed to patients with impaired PS (e.g. ECOG 2). Expert opinion: strong agreement.

#### Any line

- Supportive care should be implemented, whether associated or not with specific therapies. Expert opinion: strong agreement.
- The management of patients with highly impaired PS (e.g. ECOG 3–4) should comprise supportive care only. Expert opinion: strong agreement.

### (3) What is the place of gene mutation analysis for guiding patient care?

In patients with advanced iCCA or pCCA, it is recommended to systematically establish a molecular portrait of the tumour comprising (GRADE 1+; strong agreement):

- MLH1, MSH2, MSH6 and PMS2 immunohistochemistry (IHC) for mismatch repair (MMR) phenotyping and, if positive for DNA mismatch repair system deficiency (dMMR), MSI confirmation by molecular biology (Pentaplex PCR) (for prescription of immunotherapy).
- IHC for HER2 overexpression and, if positive (2+ or 3+), confirmation of ERBB2 amplification by FISH.
- NGS-based DNA (or RNA) panel including search for IDH1, KRAS and BRAF mutations.
- NGS-based RNA panel to search for fusion transcripts, including FGFR2 and NTRK genes.

- It is recommended to perform this screening at first-line treatment initiation. GRADE 1+; Strong agreement.

#### If a targetable mutation is identified

- In first line: inclusion in clinical trials.
- In previously treated patients:

IDH1 mutation: ivosidenib, GRADE 1+; Strong agreement.

FGFR2 fusion/rearrangement: pemigatinib, GRADE 2+; Strong agreement, futibatinib, GRADE 2+; Strong agreement, infigratinib, GRADE 2+; Strong agreement.

NTRK fusion/rearrangement: larotrectinib, GRADE 2+; Strong agreement.

MSI: pembrolizumab, GRADE 2+; Strong agreement.

BRAF V600E mutation: dabrafenib+trametinib, GRADE 2+; Strong agreement.

HER2 amplification: trastuzumab+pertuzumab, Expert opinion: Strong agreement, zanidatamab, GRADE 2+; Strong agreement.

### AFFILIATIONS

<sup>1</sup>GI Oncology, Medical Oncology Department, Institut Curie, Versailles Saint-Quentin University, Paris Saclay University, Saint-Cloud, France

<sup>2</sup>Oncology Digestive Unit, INSERM U1312, University Hospital of Bordeaux, Bordeaux, France

<sup>3</sup>Department of Hepatology, University Hospital, Toulouse III-Paul Sabatier University, Toulouse, France

<sup>4</sup>INSERM U1286 INFINITE, University Hospital of Lille France, Lille, France

<sup>5</sup>New Zealand Liver Transplant Unit and HPB Surgery, Te Toka Tumai, University of Auckland, Auckland, New Zealand

<sup>6</sup>Centre Hospitalier Intercommunal Créteil–CHI Créteil, Créteil, France

<sup>7</sup>Department of Gastroenterology and Digestive Oncology, Cochin Hospital, Assistance Publique–Hôpitaux de Paris, Paris, France

<sup>8</sup>Polyclinique Bordeaux Rive Droite, Lormont, France

<sup>9</sup>Department of Medical Oncology, CLCC Eugène Marquis, COSS-UMR S1242, INSERM, Univ Rennes, Rennes, France

<sup>10</sup>Department of Pathology, APHP University Paris Saclay, Hôpital Bicetre, Paris, France

<sup>11</sup>Radiation Oncology Department, Tenon Hospital, APHP-Sorbonne University, Paris, France

<sup>12</sup>Hépatogastro-Entérologie, CHU de Limoges, Limoges, France

<sup>13</sup>Pathology Department, University Hospital of Bordeaux, Bordeaux, France

<sup>14</sup>Gastroenterology Department, Private Hospital Jean Mermoz, Ramsay Santé, Lyon, France

<sup>15</sup>Service de Radiologie, AP-HP-Université Paris Saclay Hôpital Paul Brousse, Villejuif, France

<sup>16</sup>Medical Oncology Department, Institut Mutualiste Monsouris, Paris, France

<sup>17</sup>Department of Radiology, Beaujon Hospital, APHP Nord Clichy, University Paris Cité, CRI UMR, Paris, France

<sup>18</sup>Radiotherapy Department, Bordeaux University Hospital, Bordeaux, France

<sup>19</sup>Centre Hepato-Biliaire, AP-HP-Université Paris Saclay Hôpital Paul Brousse, Villejuif, France

<sup>20</sup>Liver Unit, Saint Joseph Hospital, Marseille, France

<sup>21</sup>Hepatology Department, AP-HP, Avicenne Hospital, Bobigny, France

## FUNDING INFORMATION

None.

## CONFLICT OF INTEREST STATEMENT

Louise Barbierm Christophe Bureau, Catherine Guettier, Maïté Lewin, Hélène Larrue, Line C. Ntanda-Wandji: None. Sandrine Barge: Gilead. Arthur Belle: Boston Scientific, Cousin, Ipsen. Jean-Frédéric Blanc: AstraZeneca, Bayer, BMS, Eisai, Incyte, Ipsen, MSD, Servier, Roche, Taiho, MSD. Marc Bourliere: Abbott, BMS, Boehringer Ingelheim, Gilead, GSK, Idenix, Intercept, Janssen, Merck, Novartis, Roche, Vertex. Carine Chagneau: Gilead, Abbvie. Marie Decraecker: Ipsen. Julien Edeline: AstraZeneca, Bayer, Basilea, Beigene, BMS, Eisai, Incyte, Ipsen, Merck Serono, MSD, Roche, Servier, Beigene, BMS, Tahio. Nathalie Ganne-Carrie: Bayer, Gilead, Ipsen, Roche, Shionogi. Florence Huguet: Amgen, BMS, Merck, MSD. Jérémie Jacques: Abbvie, Boston Scientific, Erbe Medical, Fujifilm, Lumendi, Mayoli, Norgine, Olympus, Pentax. Brigitte Le Bail: AstraZeneca. Sarah Leblanc: Alfasigma, AstraZeneca, Boston Scientific, Norgine, Olympus, Ovesco. David Malka: Abbvie, Agios, Amgen, Astrazeneca, Bayer, BMS, Foundation Medicine, HalioDx, Incyte, Leo Pharma, Merck Serono, MSD, Pierre Fabre Oncologie, Roche, Sanofi, Servier, Taiho, Veracyte, Viatrix. Cindy Neuzillet: Amgen, Astrazeneca, Baxter, BMS, Fresenius Kabi, Incyte Biosciences, Merck, MSD, Mundipharma, Nestlé Health Science, Novartis, Nutricia, OSE Immunotherapeutics, Pierre Fabre, Roche, Sanofi, Servier, Viatrix. Maxime Ronot: Guerbet, General electrics, Terumo, Servier, Angiodynamics, Astra-Zeneca. Véronique Vendrely: BMS, Servier, Amgen. Eric Vibert: Boston Scientific, Roche, Caresyntax, Twinical.

## DATA AVAILABILITY STATEMENT

N/A.

## ETHICS APPROVAL STATEMENT

N/A.

## PATIENT CONSENT STATEMENT

N/A.

## PERMISSION TO REPRODUCE MATERIAL FROM OTHER SOURCES

N/A.

## CLINICAL TRIAL REGISTRATION

N/A.

## ORCID

Christophe Bureau  <https://orcid.org/0000-0002-7669-7698>

## REFERENCES

- Mosconi S, Beretta GD, Labianca R, Zampino MG, Gatta G, Heinemann V. Cholangiocarcinoma. *Crit Rev Oncol Hematol*. 2009;69(3):259-270.
- Nakeeb A, Pitt HA, Sohn TA, et al. Cholangiocarcinoma. A spectrum of intrahepatic, perihilar, and distal tumors. *Ann Surg*. 1996;224(4):463-473; discussion 473-5.
- Clements O, Eliahoo J, Kim JU, Taylor-Robinson SD, Khan SA. Risk factors for intrahepatic and extrahepatic cholangiocarcinoma: a systematic review and meta-analysis. *J Hepatol*. 2020;72(1):95-103.
- Petrick JL, Yang B, Altekruse SF, et al. Risk factors for intrahepatic and extrahepatic cholangiocarcinoma in the United States: a population-based study in SEER-Medicare. *PLoS One*. 2017;12(10):e0186643.
- Shaib YH, El-Serag HB, Davila JA, Morgan R, McGlynn KA. Risk factors of intrahepatic cholangiocarcinoma in the United States: a case-control study. *Gastroenterology*. 2005;128(3):620-626.
- Lee TY, Lee SS, Jung SW, et al. Hepatitis B virus infection and intrahepatic cholangiocarcinoma in Korea: a case-control study. *Am J Gastroenterol*. 2008;103(7):1716-1720.
- Welzel TM, Graubard BI, El-Serag HB, et al. Risk factors for intrahepatic and extrahepatic cholangiocarcinoma in the United States: a population-based case-control study. *Clin Gastroenterol Hepatol*. 2007;5(10):1221-1228.
- Palmer WC, Patel T. Are common factors involved in the pathogenesis of primary liver cancers? A meta-analysis of risk factors for intrahepatic cholangiocarcinoma. *J Hepatol*. 2012;57(1):69-76.
- Chang JS, Tsai CR, Chen LT. Medical risk factors associated with cholangiocarcinoma in Taiwan: a population-based case-control study. *PLoS One*. 2013;8(7):e69981.
- Cougot D, Neuveut C, Buendia MA. HBV induced carcinogenesis. *J Clin Virol*. 2005;34 Suppl 1:S75-S78.
- Zhang X, Zhang H, Ye L. Effects of hepatitis B virus X protein on the development of liver cancer. *J Lab Clin Med*. 2006;147(2):58-66.
- Battaglia S, Benzoubir N, Nobilet S, et al. Liver cancer-derived hepatitis C virus Core proteins shift TGF-Beta responses from tumor suppression to epithelial-mesenchymal transition. *PLoS One*. 2009;4(2):e4355.
- Hirohashi K, Uenishi T, Kubo S, et al. Macroscopic types of intrahepatic cholangiocarcinoma: clinicopathologic features and surgical outcomes. *Hepato-Gastroenterology*. 2002;49(44):326-329.
- Perumal V, Wang J, Thuluvath P, Choti M, Torbenson M. Hepatitis C and hepatitis B nucleic acids are present in intrahepatic cholangiocarcinomas from the United States. *Hum Pathol*. 2006;37(9):1211-1216.
- Matsumoto K, Onoyama T, Kawata S, et al. Hepatitis B and C virus infection is a risk factor for the development of cholangiocarcinoma. *Intern Med*. 2014;53(7):651-654.
- Izquierdo-Sanchez L, Lamarca A, La Casta A, et al. Cholangiocarcinoma landscape in Europe: diagnostic, prognostic and therapeutic insights from the ENSCCA Registry. *J Hepatol*. 2022;76(5):1109-1121.
- Dayton MT, Longmire WP, Tompkins RK. Caroli's disease: a premalignant condition? *Am J Surg*. 1983;145(1):41-48.
- Sastry AV, Abbadessa B, Wayne MG, Steele JG, Cooperman AM. What is the incidence of biliary carcinoma in choledochal cysts, when do they develop, and how should it affect management? *World J Surg*. 2015;39(2):487-492.
- Cai WK, Sima H, Chen BD, Yang GS. Risk factors for hilar cholangiocarcinoma: a case-control study in China. *World J Gastroenterol*. 2011;17(2):249-253.
- Jain D, Sarode VR, Abdul-Karim FW, Homer R, Robert ME. Evidence for the neoplastic transformation of Von-Meyenburg complexes. *Am J Surg Pathol*. 2000;24(8):1131-1139.
- Song JS, Lee YJ, Kim KW, Huh J, Jang SJ, Yu E. Cholangiocarcinoma arising in von Meyenburg complexes: report of four cases. *Pathol Int*. 2008;58(8):503-512.
- Kim HK, Jin SY. Cholangiocarcinoma arising in von Meyenburg complexes. *Korean J Hepatol*. 2011;17(2):161-164.



23. Nakanuma Y, Sato Y, Ojima H, et al. Clinicopathological characterization of so-called "cholangiocarcinoma with intraductal papillary growth" with respect to "intraductal papillary neoplasm of bile duct (IPNB)". *Int J Clin Exp Pathol*. 2014;7(6):3112-3122.
24. Ariake K, Unno M, Yoshida H, et al. Risk factors and characteristics of young patients with the biliary tract carcinoma: results of a project study for biliary surgery by the Japanese Society of Hepato-Biliary-Pancreatic Surgery. *J Hepatobiliary Pancreat Sci*. 2020;27(9):571-580.
25. Sithithaworn P, Haswell-Elkins MR, Mairiang P, et al. Parasite-associated morbidity: liver fluke infection and bile duct cancer in northeast Thailand. *Int J Parasitol*. 1994;24(6):833-843.
26. Honjo S, Srivatanakul P, Sriplung H, et al. Genetic and environmental determinants of risk for cholangiocarcinoma via *Opisthorchis viverrini* in a densely infested area in Nakhon Phanom, northeast Thailand. *Int J Cancer*. 2005;117(5):854-860.
27. Chazouillères O, Potier P, Bouzbib C, et al. Non-invasive diagnosis and follow-up of primary sclerosing cholangitis. *Clin Res Hepatol Gastroenterol*. 2022;46(1):101775.
28. de Vries E, Mazzetti M, Takkenberg B, et al. Carriers of ABCB4 gene variants show a mild clinical course, but impaired quality of life and limited risk for cholangiocarcinoma. *Liver Int*. 2020;40(12):3042-3050.
29. Win AK, Lindor NM, Young JP, et al. Risks of primary Extracolonic cancers following colorectal cancer in Lynch syndrome. *J Natl Cancer Inst*. 2012;104(18):1363-1372.
30. Bonadona V, Bonaïti B, Olschwang S, et al. Cancer risks associated with germline mutations in MLH1, MSH2, and MSH6 genes in Lynch syndrome. *JAMA*. 2011;305(22):2304-2310.
31. Watson P, Vasen HFA, Mecklin JP, et al. The risk of extra-colonic, extra-endometrial cancer in the Lynch syndrome. *Int J Cancer*. 2008;123(2):444-449.
32. Aarnio M, Sankila R, Pukkala E, et al. Cancer risk in mutation carriers of DNA-mismatch-repair genes. *Int J Cancer*. 1999;81(2):214-218.
33. Barrow E, Robinson L, Alduaij W, et al. Cumulative lifetime incidence of extracolonic cancers in Lynch syndrome: a report of 121 families with proven mutations. *Clin Genet*. 2009;75(2):141-149.
34. Kendre G, Murugesan K, Brummer T, Segatto O, Saborowski A, Vogel A. Charting co-mutation patterns associated with actionable drivers in intrahepatic cholangiocarcinoma. *J Hepatol*. 2023;78(3):614-626.
35. Lin J, Shi J, Guo H, et al. Alterations in DNA damage repair genes in primary liver cancer. *Clin Cancer Res*. 2019;25(15):4701-4711.
36. Joo I, Lee JM, Yoon JH. Imaging diagnosis of intrahepatic and perihilar cholangiocarcinoma: recent advances and challenges. *Radiology*. 2018;288(1):7-13.
37. Vilgrain V. Staging cholangiocarcinoma by imaging studies. *HPB*. 2008;10(2):106-109.
38. Saleh M, Virarkar M, Bura V, et al. Intrahepatic cholangiocarcinoma: pathogenesis, current staging, and radiological findings. *Abdom Radiol (NY)*. 2020;45(11):3662-3680.
39. Hu JH, Tang JH, Lin CH, Chu YY, Liu NJ. Preoperative staging of cholangiocarcinoma and biliary carcinoma using 18F-fluorodeoxyglucose positron emission tomography: a meta-analysis. *J Investig Med*. 2018;66(1):52-61.
40. Moon CM, Bang S, Chung JB, et al. Usefulness of 18F-fluorodeoxyglucose positron emission tomography in differential diagnosis and staging of cholangiocarcinomas. *J Gastroenterol Hepatol*. 2008;23(5):759-765.
41. Lee Y, Yoo IR, Boo SH, Kim H, Park HL, Hyun OJ. The role of F-18 FDG PET/CT in intrahepatic cholangiocarcinoma. *Nucl Med Mol Imaging*. 2017;51(1):69-78.
42. Forner A, Vidili G, Rengo M, Bujanda L, Ponz-Sarvisé M, Lamarca A. Clinical presentation, diagnosis and staging of cholangiocarcinoma. *Liver Int*. 2019;39 Suppl 1:98-107.
43. Vidili G, Arru M, Solinas G, et al. Contrast-enhanced ultrasound liver imaging reporting and data system: lights and shadows in hepatocellular carcinoma and cholangiocellular carcinoma diagnosis. *World J Gastroenterol*. 2022;28(27):3488-3502.
44. Yeh YC, Lei HJ, Chen MH, et al. C-reactive protein (CRP) is a promising diagnostic Immunohistochemical marker for intrahepatic cholangiocarcinoma and is associated with better prognosis. *Am J Surg Pathol*. 2017;41(12):1630-1641.
45. Akita M, Sawada R, Komatsu M, et al. An immunohistochemical panel of C-reactive protein, N-cadherin, and S100 calcium binding protein P is useful for intrahepatic cholangiocarcinoma subtyping. *Hum Pathol*. 2021;109:45-52.
46. Kälsh J, Padden J, B rtram S, et al. Annexin A10 optimally differentiates between intrahepatic cholangiocarcinoma and hepatic metastases of pancreatic ductal adenocarcinoma: a comparative study of immunohistochemical markers and panels. *Virchows Arch*. 2017;470(5):537-543.
47. Laurent E, Begueret H, Bonhomme B, et al. SOX10, GATA3, GCDFP15, androgen receptor, and mammaglobin for the differential diagnosis between triple-negative breast cancer and TTF1-negative lung adenocarcinoma. *Am J Surg Pathol*. 2019;43(3):293-302.
48. Clark BZ, Beriwai S, Dabbs DJ, Bhargava R. Semiquantitative GATA-3 immunoreactivity in breast, bladder, gynecologic tract, and other cytokeratin 7-positive carcinomas. *Am J Clin Pathol*. 2014;142(1):64-71.
49. Miettinen M, McCue PA, Sarlomo-Rikala M, et al. GATA3: a multi-specific but potentially useful marker in surgical pathology: a systematic analysis of 2500 epithelial and nonepithelial tumors. *Am J Surg Pathol*. 2014;38(1):13-22.
50. Yatabe Y, Mitsudomi T, Takahashi T. TTF-1 expression in pulmonary adenocarcinomas. *Am J Surg Pathol*. 2002;26(6):767-773.
51. Ruys AT, van Beem BE, Engelbrecht MRW, Bipat S, Stoker J, Van Gulik TM. Radiological staging in patients with hilar cholangiocarcinoma: a systematic review and meta-analysis. *Br J Radiol*. 2012;85(1017):1255-1262.
52. Blechacz B, Komuta M, Roskams T, Gores GJ. Clinical diagnosis and staging of cholangiocarcinoma. *Nat Rev Gastroenterol Hepatol*. 2011;8(9):512-522.
53. Fritscher-Ravens A, Broering DC, Knoefel WT, et al. EUS-guided fine-needle aspiration of suspected hilar cholangiocarcinoma in potentially operable patients with negative brush cytology. *Am J Gastroenterol*. 2004;99(1):45-51.
54. Gleeson FC, Rajan E, Levy MJ, et al. EUS-guided FNA of regional lymph nodes in patients with unresectable hilar cholangiocarcinoma. *Gastrointest Endosc*. 2008;67(3):438-443.
55. El Chafic AH, Dewitt J, Leblanc JK, et al. Impact of preoperative endoscopic ultrasound-guided fine needle aspiration on postoperative recurrence and survival in cholangiocarcinoma patients. *Endoscopy*. 2013;45(11):883-889.
56. Téllez-Ávila FI, Bernal-Méndez AR, Guerrero-Vázquez CG, Martínez-Lozano JA, Ramírez-Luna MÁ. Diagnostic yield of EUS-guided tissue acquisition as a first-line approach in patients with suspected hilar cholangiocarcinoma. *Am J Gastroenterol*. 2014;109(8):1294-1296.
57. Lee JH, Salem R, Aslanian H, Chacho M, Topazian M. Endoscopic ultrasound and fine-needle aspiration of unexplained bile duct strictures. *Am J Gastroenterol*. 2004;99(6):1069-1073.
58. Wu LM, Jiang XX, Gu HY, et al. Endoscopic ultrasound-guided fine-needle aspiration biopsy in the evaluation of bile duct strictures and gallbladder masses: a systematic review and meta-analysis. *Eur J Gastroenterol Hepatol*. 2011;23(2):113-120.
59. Weilert F, Bhat YM, Binmoeller KF, et al. EUS-FNA is superior to ERCP-based tissue sampling in suspected malignant biliary obstruction: results of a prospective, single-blind, comparative study. *Gastrointest Endosc*. 2014;80(1):97-104.
60. Moura DTH, de Moura EGH, Matuguma SE, et al. EUS-FNA versus ERCP for tissue diagnosis of suspect malignant biliary strictures: a

- prospective comparative study. *Endosc Int Open*. 2018;6(6):E769-E777.
61. Mehmood S, Loya A, Yusuf MA. Biliary brush cytology revisited. *Acta Cytol*. 2016;60(2):167-172.
  62. Kobayashi M, Ryozaawa S, Araki R, et al. Investigation of factors affecting the sensitivity of bile duct brush cytology. *Intern Med*. 2019;58(3):329-335.
  63. Weber A, von Weyhern C, Fend F, et al. Endoscopic transpapillary brush cytology and forceps biopsy in patients with hilar cholangiocarcinoma. *World J Gastroenterol*. 2008;14(7):1097-1101.
  64. Navaneethan U, Njei B, Lourdasamy V, Konjeti R, Vargo JJ, Parsi MA. Comparative effectiveness of biliary brush cytology and intrahepatic biopsy for detection of malignant biliary strictures: a systematic review and meta-analysis. *Gastrointest Endosc*. 2015;81(1):168-176.
  65. Kawashima H, Itoh A, Ohno E, Goto H, Hirooka Y. Transpapillary biliary forceps biopsy to distinguish benign biliary stricture from malignancy: how many tissue samples should be obtained? *Dig Endosc*. 2012;24 Suppl 1:22-27.
  66. Tyberg A, Raijman I, Siddiqui A, et al. Digital pancreaticocholangioscopy for mapping of pancreaticobiliary neoplasia: can we alter the surgical resection margin? *J Clin Gastroenterol*. 2019;53(1):71-75.
  67. Pereira P, Santos S, Morais R, et al. Role of peroral cholangioscopy for diagnosis and staging of biliary tumors. *Dig Dis*. 2020;38(5):431-440.
  68. Nishikawa T, Tsuyuguchi T, Sakai Y, et al. Preoperative assessment of longitudinal extension of cholangiocarcinoma with peroral video-cholangioscopy: a prospective study. *Dig Endosc*. 2014;26(3):450-457.
  69. Pitman MB, Centeno BA, Ali SZ, et al. Standardized terminology and nomenclature for pancreatobiliary cytology: the papanicolaou society of cytopathology guidelines. *Diagn Cytopathol*. 2014;42(4):338-350.
  70. Farges O, Regimbeau JM, Fuks D, et al. Multicentre European study of preoperative biliary drainage for hilar cholangiocarcinoma. *Br J Surg*. 2013;100(2):274-283.
  71. Hameed A, Pang T, Chiou J, et al. Percutaneous vs. endoscopic preoperative biliary drainage in hilar cholangiocarcinoma—a systematic review and meta-analysis. *HPB (Oxford)*. 2016;18(5):400-410.
  72. Al Mahjoub A, Menahem B, Fohlen A, et al. Preoperative biliary drainage in patients with resectable perihilar cholangiocarcinoma: is percutaneous transhepatic biliary drainage safer and more effective than endoscopic biliary drainage? A meta-analysis. *J Vasc Interv Radiol*. 2017;28(4):576-582.
  73. Zhao XQ, Dong JH, Jiang K, Huang XQ, Zhang WZ. Comparison of percutaneous transhepatic biliary drainage and endoscopic biliary drainage in the management of malignant biliary tract obstruction: a meta-analysis. *Dig Endosc*. 2015;27(1):137-145.
  74. Coelen RJS, Roos E, Wiggers JK, et al. Endoscopic versus percutaneous biliary drainage in patients with resectable perihilar cholangiocarcinoma: a multicentre, randomised controlled trial. *Lancet Gastroenterol Hepatol*. 2018;3(10):681-690.
  75. O'Brien S, Bhutiani N, Egger ME, et al. Comparing the efficacy of initial percutaneous transhepatic biliary drainage and endoscopic retrograde cholangiopancreatography with stenting for relief of biliary obstruction in unresectable cholangiocarcinoma. *Surg Endosc*. 2020;34(3):1186-1190.
  76. Sangchan A, Kongkasame W, Pugkhem A, Jenwitheesuk K, Mairiang P. Efficacy of metal and plastic stents in unresectable complex hilar cholangiocarcinoma: a randomized controlled trial. *Gastrointest Endosc*. 2012;76(1):93-99.
  77. Almadi MA, Barkun A, Martel M. Plastic vs. self-expandable metal stents for palliation in malignant biliary obstruction: a series of meta-analyses. *Am J Gastroenterol*. 2017;112(2):260-273.
  78. Hong W, Sun X, Zhu Q. Endoscopic stenting for malignant hilar biliary obstruction: should it be metal or plastic and unilateral or bilateral? *Eur J Gastroenterol Hepatol*. 2013;25(9):1105-1112.
  79. Moole H, Bechtold ML, Forcione D, Puli SR. A meta-analysis and systematic review: success of endoscopic ultrasound guided biliary stenting in patients with inoperable malignant biliary strictures and a failed ERCP. *Medicine (Baltimore)*. 2017;96(3):e5154.
  80. Weber SM, Ribero D, O'Reilly EM, Kokudo N, Miyazaki M, Pawlik TM. Intrahepatic cholangiocarcinoma: expert consensus statement. *HPB (Oxford)*. 2015;17(8):669-680.
  81. Amini N, Ejaz A, Spolverato G, Kim Y, Herman JM, Pawlik TM. Temporal trends in liver-directed therapy of patients with intrahepatic cholangiocarcinoma in the United States: a population-based analysis. *J Surg Oncol*. 2014;110(2):163-170.
  82. Goere D, Wagholikar GD, Pessaux P, et al. Utility of staging laparoscopy in subsets of biliary cancers: laparoscopy is a powerful diagnostic tool in patients with intrahepatic and gallbladder carcinoma. *Surg Endosc*. 2006;20(5):721-725.
  83. D'Angelica M, Fong Y, Weber S, et al. The role of staging laparoscopy in hepatobiliary malignancy: prospective analysis of 401 cases. *Ann Surg Oncol*. 2003;10(2):183-189.
  84. Mavros MN, Economopoulos KP, Alexiou VG, Pawlik TM. Treatment and prognosis for patients with intrahepatic cholangiocarcinoma: systematic review and meta-analysis. *JAMA Surg*. 2014;149(6):565-574.
  85. Conci S, Ruzzenente A, Vignani L, et al. Patterns of distribution of hepatic nodules (single, satellites or multifocal) in intrahepatic cholangiocarcinoma: prognostic impact after surgery. *Ann Surg Oncol*. 2018;25(12):3719-3727.
  86. Addeo P, Jedidi I, Locicero A, et al. Prognostic impact of tumor multinodularity in intrahepatic cholangiocarcinoma. *J Gastrointest Surg*. 2019;23(9):1801-1809.
  87. Doussot A, Gonen M, Wiggers JK, et al. Recurrence patterns and disease-free survival after resection of intrahepatic cholangiocarcinoma: preoperative and postoperative prognostic models. *J Am Coll Surg*. 2016;223(3):493-505 e2.
  88. Groot Koerkamp B, Fong Y. Outcomes in biliary malignancy. *J Surg Oncol*. 2014;110(5):585-591.
  89. de Jong MC, Nathan H, Sotiropoulos GC, et al. Intrahepatic cholangiocarcinoma: an international multiinstitutional analysis of prognostic factors and lymph node assessment. *J Clin Oncol*. 2011;29(23):3140-3145.
  90. Spolverato G, Kim Y, Ejaz A, Frank SM, Pawlik TM. Effect of relative decrease in blood hemoglobin concentrations on postoperative morbidity in patients who undergo major gastrointestinal surgery. *JAMA Surg*. 2015;150(10):949-956.
  91. Spolverato G, Vitale A, Cucchetti A, et al. Can hepatic resection provide a long-term cure for patients with intrahepatic cholangiocarcinoma? *Cancer*. 2015;121(22):3998-4006.
  92. Tsilimigras DI, Hyer JM, Moris D, et al. Prognostic utility of albumin-bilirubin grade for short- and long-term outcomes following hepatic resection for intrahepatic cholangiocarcinoma: a multi-institutional analysis of 706 patients. *J Surg Oncol*. 2019;120(2):206-213.
  93. Wang C, Pang S, Si-Ma H, et al. Specific risk factors contributing to early and late recurrences of intrahepatic cholangiocarcinoma after curative resection. *World J Surg Oncol*. 2019;17(1):2.
  94. Sasaki K, Margonis GA, Andreatos N, et al. Preoperative risk score and prediction of long-term outcomes after hepatectomy for intrahepatic cholangiocarcinoma. *J Am Coll Surg*. 2018;226(4):393-403.
  95. Akgul O, Bagante F, Olsen G, et al. Preoperative prognostic nutritional index predicts survival of patients with intrahepatic cholangiocarcinoma after curative resection. *J Surg Oncol*. 2018;118(3):422-430.

96. Jing CY, Fu YP, Shen HJ, et al. Albumin to gamma-glutamyltransferase ratio as a prognostic indicator in intrahepatic cholangiocarcinoma after curative resection. *Oncotarget*. 2017;8(8):13293-13303.
97. Ribero D, Pinna AD, Guglielmi A, et al. Surgical approach for long-term survival of patients with intrahepatic cholangiocarcinoma: a multi-institutional analysis of 434 patients. *Arch Surg*. 2012;147(12):1107-1113.
98. Tsilimigras DJ, Mehta R, Aldrighetti L, et al. Development and validation of a laboratory risk score (LabScore) to predict outcomes after resection for intrahepatic cholangiocarcinoma. *J Am Coll Surg*. 2020;230(4):381-391 e2.
99. Hu LS, Zhang XF, Weiss M, et al. Recurrence patterns and timing courses following curative-intent resection for intrahepatic cholangiocarcinoma. *Ann Surg Oncol*. 2019;26(8):2549-2557.
100. Yoh T, Cauchy F, Le Roy B, et al. Prognostic value of lymphadenectomy for long-term outcomes in node-negative intrahepatic cholangiocarcinoma: a multicenter study. *Surgery*. 2019;166(6):975-982.
101. Adachi T, Eguchi S, Beppu T, et al. Prognostic impact of preoperative lymph node enlargement in intrahepatic cholangiocarcinoma: a multi-institutional study by the Kyushu Study Group of Liver Surgery. *Ann Surg Oncol*. 2015;22(7):2269-2278.
102. Zhang XF, Xue F, Dong DH, et al. Number and station of lymph node metastasis after curative-intent resection of intrahepatic cholangiocarcinoma impact prognosis. *Ann Surg*. 2021;274(6):e1187-e1195.
103. Sapisochin G, Facciuto M, Rubbia-Brandt L, et al. Liver transplantation for "very early" intrahepatic cholangiocarcinoma: international retrospective study supporting a prospective assessment. *Hepatology*. 2016;64(4):1178-1188.
104. De Martin E, Rayar M, Golse N, et al. Analysis of liver resection versus liver transplantation on outcome of small intrahepatic cholangiocarcinoma and combined hepatocellular-Cholangiocarcinoma in the setting of cirrhosis. *Liver Transpl*. 2020;26(6):785-798.
105. Lunsford KE, Javle M, Heyne K, et al. Liver transplantation for locally advanced intrahepatic cholangiocarcinoma treated with neoadjuvant therapy: a prospective case-series. *Lancet Gastroenterol Hepatol*. 2018;3(5):337-348.
106. Nagino M, Ebata T, Yokoyama Y, et al. Evolution of surgical treatment for perihilar cholangiocarcinoma: a single-center 34-year review of 574 consecutive resections. *Ann Surg*. 2013;258(1):129-140.
107. Ruzzenente A, Bagante F, Olthof PB, et al. Surgery for Bismuth-Corlette type 4 perihilar cholangiocarcinoma: results from a Western Multicenter Collaborative Group. *Ann Surg Oncol*. 2021;28(12):7719-7729.
108. Song SC, Choi DW, Kow AW, et al. Surgical outcomes of 230 resected hilar cholangiocarcinoma in a single centre. *ANZ J Surg*. 2013;83(4):268-274.
109. Nuzzo G, Giuliante F, Ardito F, et al. Improvement in perioperative and long-term outcome after surgical treatment of hilar cholangiocarcinoma: results of an Italian multicenter analysis of 440 patients. *Arch Surg*. 2012;147(1):26-34.
110. Wiggers JK, Groot Koerkamp B, Cieslak KP, et al. Postoperative mortality after liver resection for perihilar cholangiocarcinoma: development of a risk score and importance of biliary drainage of the future liver remnant. *J Am Coll Surg*. 2016;223(2):321-331 e1.
111. Aoba T, Ebata T, Yokoyama Y, et al. Assessment of nodal status for perihilar cholangiocarcinoma: location, number, or ratio of involved nodes. *Ann Surg*. 2013;257(4):718-725.
112. Darwish Murad S, Kim WR, Harnois DM, et al. Efficacy of neoadjuvant chemoradiation, followed by liver transplantation, for perihilar cholangiocarcinoma at 12 US centers. *Gastroenterology*. 2012;143(1):88-98 e3; quiz e14.
113. Ethun CG, Lopez-Aguilar AG, Anderson DJ, et al. Transplantation versus resection for hilar cholangiocarcinoma: an argument for shifting treatment paradigms for resectable disease. *Ann Surg*. 2018;267(5):797-805.
114. Moris D, Kostakis ID, Machairas N, et al. Comparison between liver transplantation and resection for hilar cholangiocarcinoma: a systematic review and meta-analysis. *PLoS One*. 2019;14(7):e0220527.
115. Edeline J, Lamarca A, McNamara MG, et al. Locoregional therapies in patients with intrahepatic cholangiocarcinoma: a systematic review and pooled analysis. *Cancer Treat Rev*. 2021;99:102258.
116. Ortner MEJ, Caca K, Berr F, et al. Successful photodynamic therapy for nonresectable cholangiocarcinoma: a randomized prospective study. *Gastroenterology*. 2003;125(5):1355-1363.
117. Zoepf T, Jakobs R, Arnold JC, Apel D, Riemann JF. Palliation of nonresectable bile duct cancer: improved survival after photodynamic therapy. *Am J Gastroenterol*. 2005;100(11):2426-2430.
118. Pereira SP, Jitlal M, Duggan M, et al. PHOTOSTENT-02: porfimer sodium photodynamic therapy plus stenting versus stenting alone in patients with locally advanced or metastatic biliary tract cancer. *ESMO Open*. 2018;3(5):e000379.
119. Sofi AA, Khan MA, Das A, et al. Radiofrequency ablation combined with biliary stent placement versus stent placement alone for malignant biliary strictures: a systematic review and meta-analysis. *Gastrointest Endosc*. 2018;87(4):944-951.e1.
120. Yang J, Wang J, Zhou H, et al. Efficacy and safety of endoscopic radiofrequency ablation for unresectable extrahepatic cholangiocarcinoma: a randomized trial. *Endoscopy*. 2018;50(8):751-760.
121. Kang H, Chung MJ, Cho IR, et al. Efficacy and safety of palliative endobiliary radiofrequency ablation using a novel temperature-controlled catheter for malignant biliary stricture: a single-center prospective randomized phase II TRIAL. *Surg Endosc*. 2021;35(1):63-73.
122. Torgeson A, Lloyd S, Boothe D, et al. Chemoradiation therapy for Unresected extrahepatic Cholangiocarcinoma: a propensity score-matched analysis. *Ann Surg Oncol*. 2017;24(13):4001-4008.
123. Liu J, Zhong M, Feng Y, et al. Prognostic factors and treatment strategies for intrahepatic Cholangiocarcinoma from 2004 to 2013: population-based SEER analysis. *Transl Oncol*. 2019;12(11):1496-1503.
124. Phelip JM, Vendrely V, Rostain F, et al. Gemcitabine plus cisplatin versus chemoradiotherapy in locally advanced biliary tract cancer: Fédération francophone de Cancérologie digestive 9902 phase II randomised study. *Eur J Cancer*. 2014;50(17):2975-2982.
125. Tao R, Krishnan S, Bhosale PR, et al. Ablative radiotherapy doses lead to a substantial prolongation of survival in patients with inoperable intrahepatic cholangiocarcinoma: a retrospective dose response analysis. *J Clin Oncol*. 2016;34(3):219-226.
126. Yoshioka Y, Ogawa K, Oikawa H, et al. Impact of intraluminal brachytherapy on survival outcome for radiation therapy for unresectable biliary tract cancer: a propensity-score matched-pair analysis. *Int J Radiat Oncol Biol Phys*. 2014;89(4):822-829.
127. Frakulli R, Buwenge M, Macchia G, et al. Stereotactic body radiation therapy in cholangiocarcinoma: a systematic review. *Br J Radiol*. 2019;92(1097):20180688.
128. Nelson JW, Ghafoori AP, Willett CG, et al. Concurrent chemoradiotherapy in resected extrahepatic cholangiocarcinoma. *Int J Radiat Oncol Biol Phys*. 2009;73(1):148-153.
129. Ben-Josef E, Guthrie KA, El-Khoueiry AB, et al. SWOG S0809: a phase II intergroup trial of adjuvant Capecitabine and gemcitabine followed by radiotherapy and concurrent Capecitabine in extrahepatic cholangiocarcinoma and gallbladder carcinoma. *J Clin Oncol*. 2015;33(24):2617-2622.
130. Primrose JN, Fox RP, Palmer DH, et al. Capecitabine compared with observation in resected biliary tract cancer (BILCAP): a randomised, controlled, multicentre, phase 3 study. *Lancet Oncol*. 2019;20(5):663-673.
131. Horgan AM, Amir E, Walter T, Knox JJ. Adjuvant therapy in the treatment of biliary tract cancer: a systematic review and meta-analysis. *J Clin Oncol*. 2012;30(16):1934-1940.

132. Ren B, Guo Q, Yang Y, et al. A meta-analysis of the efficacy of post-operative adjuvant radiotherapy versus no radiotherapy for extrahepatic cholangiocarcinoma and gallbladder carcinoma. *Radiat Oncol.* 2020;15(1):15.
133. Takada T, Amano H, Yasuda H, et al. Is postoperative adjuvant chemotherapy useful for gallbladder carcinoma? A phase III multicenter prospective randomized controlled trial in patients with resected pancreaticobiliary carcinoma. *Cancer.* 2002;95(8):1685-1695.
134. Ebata T, Hirano S, Konishi M, et al. Randomized clinical trial of adjuvant gemcitabine chemotherapy versus observation in resected bile duct cancer. *Br J Surg.* 2018;105(3):192-202.
135. Edeline J, Benabdelghani M, Bertaut A, et al. Gemcitabine and oxaliplatin chemotherapy or surveillance in resected biliary tract cancer (PRODIGE 12-ACCORD 18-UNICANCER GI): a randomized phase III study. *J Clin Oncol.* 2019;37(8):658-667.
136. Glimelius B, Hoffman K, Sjöden PO, et al. Chemotherapy improves survival and quality of life in advanced pancreatic and biliary cancer. *Ann Oncol.* 1996;7(6):593-600.
137. Sharma A, Mohanti B, Raina V, et al. A phase II study of gemcitabine and oxaliplatin (Oxigem) in unresectable gall bladder cancer. *Cancer Chemother Pharmacol.* 2010;65(3):497-502.
138. Schinzari G, Rossi E, Mambella G, et al. First-line treatment of advanced biliary ducts carcinoma: a randomized phase II study evaluating 5-FU/LV plus oxaliplatin (Folfox 4) versus 5-FU/LV (de Gramont regimen). *Anticancer Res.* 2017;37(9):5193-5197.
139. Eckel F, Schmid RM. Chemotherapy in advanced biliary tract carcinoma: a pooled analysis of clinical trials. *Br J Cancer.* 2007;96(6):896-902.
140. Eckel F, Schmid RM. Chemotherapy and targeted therapy in advanced biliary tract carcinoma: a pooled analysis of clinical trials. *Chemotherapy.* 2014;60(1):13-23.
141. Valle J, Wasan H, Palmer DH, et al. Cisplatin plus gemcitabine versus gemcitabine for biliary tract cancer. *N Engl J Med.* 2010;362(14):1273-1281.
142. Okusaka T, Nakachi K, Fukutomi A, et al. Gemcitabine alone or in combination with cisplatin in patients with biliary tract cancer: a comparative multicentre study in Japan. *Br J Cancer.* 2010;103(4):469-474.
143. Valle JW, Furuse J, Jitlal M, et al. Cisplatin and gemcitabine for advanced biliary tract cancer: a meta-analysis of two randomised trials. *Ann Oncol.* 2014;25(2):391-398.
144. André T, Tournigand C, Rosmorduc O, et al. Gemcitabine combined with oxaliplatin (GEMOX) in advanced biliary tract adenocarcinoma: a GERCOR study. *Ann Oncol.* 2004;15(9):1339-1343.
145. Malka D, Cervera P, Foulon S, et al. Gemcitabine and oxaliplatin with or without cetuximab in advanced biliary-tract cancer (BINGO): a randomised, open-label, non-comparative phase 2 trial. *Lancet Oncol.* 2014;15(8):819-828.
146. Fiteni F, Nguyen T, Verney D, et al. Cisplatin/gemcitabine or oxaliplatin/gemcitabine in the treatment of advanced biliary tract cancer: a systematic review. *Cancer Med.* 2014;3(6):1502-1511.
147. Sharma A, Kalyan Mohanti B, Pal Chaudhary S, et al. Modified gemcitabine and oxaliplatin or gemcitabine + cisplatin in unresectable gallbladder cancer: results of a phase III randomised controlled trial. *Eur J Cancer.* 2019;123:162-170.
148. Kim ST, Kang JH, Lee J, et al. Capecitabine plus oxaliplatin versus gemcitabine plus oxaliplatin as first-line therapy for advanced biliary tract cancers: a multicenter, open-label, randomized, phase III, noninferiority trial. *Ann Oncol.* 2019;30(5):788-795.
149. Phelip JM, Edeline J, Blanc JF, et al. Modified FOLFIRINOX versus CisGem first-line chemotherapy for locally advanced non resectable or metastatic biliary tract cancer (AMEBICA)-PRODIGE 38: study protocol for a randomized controlled multicenter phase II/III study. *Dig Liver Dis.* 2019;51(2):318-320.
150. Sahai V, Catalano PJ, Zalupski MM, et al. Nab-paclitaxel and gemcitabine as first-line treatment of advanced or metastatic cholangiocarcinoma. *JAMA Oncol.* 2018;4(12):1707-1712.
151. Shroff RT, Borad MJ, Xiao L, et al. A phase II trial of gemcitabine (G), cisplatin (C), and nab-paclitaxel (N) in advanced biliary tract cancers (aBTCs). *J Clin Oncol.* 2017;35(15\_suppl):4018.
152. McNamara MG, Goyal L, Doherty M, et al. NUC-1031/cisplatin versus gemcitabine/cisplatin in untreated locally advanced/metastatic biliary tract cancer (NuTide:121). *Future Oncol Lond Engl.* 2020;16(16):1069-1081.
153. Perkhofe L, Striefler JK, Sinn M, et al. LBA10 Nal-IRI with 5-fluorouracil (5-FU) and leucovorin or gemcitabine plus cisplatin in advanced biliary tract cancer: final results of the NIFE-trial (AIO-YMO HEP-0315), a randomized phase II study of the AIO biliary tract cancer group. *Ann Oncol.* 2021;32:51282.
154. Kang MJ, Lee JL, Kim TW, et al. Randomized phase II trial of S-1 and cisplatin versus gemcitabine and cisplatin in patients with advanced biliary tract adenocarcinoma. *Acta Oncol Stockh Swed.* 2012;51(7):860-866.
155. Sasaki T, Isayama H, Nakai Y, et al. A randomized phase II study of gemcitabine and S-1 combination therapy versus gemcitabine monotherapy for advanced biliary tract cancer. *Cancer Chemother Pharmacol.* 2013;71(4):973-979.
156. Morizane C, Okusaka T, Mizusawa J, et al. Randomized phase II study of gemcitabine plus S-1 versus S-1 in advanced biliary tract cancer: a Japan Clinical Oncology Group Trial (JCOG 0805). *Cancer Sci.* 2013;104(9):1211-1216.
157. Li H, Zhang ZY, Zhou ZQ, Guan J, Tong DN, Zhou GW. Combined gemcitabine and S-1 chemotherapy for treating unresectable hilar cholangiocarcinoma: a randomized open-label clinical trial. *Oncotarget.* 2016;7(18):26888-26897.
158. Morizane C, Okusaka T, Mizusawa J, et al. Randomized phase III study of gemcitabine plus S-1 combination therapy versus gemcitabine plus cisplatin combination therapy in advanced biliary tract cancer: a Japan Clinical Oncology Group Study (JCOG1113, FUGA-BT). *J Clin Oncol.* 2018;36(4\_suppl):205.
159. Sakai D, Kanai M, Kobayashi S, et al. Randomized phase III study of gemcitabine, cisplatin plus S-1 (GCS) versus gemcitabine, cisplatin (GC) for advanced biliary tract cancer (KHBO1401-MITSUBA). *Ann Oncol.* 2018;29:viii205.
160. Valle JW, Wasan H, Lopes A, et al. Cediranib or placebo in combination with cisplatin and gemcitabine chemotherapy for patients with advanced biliary tract cancer (ABC-03): a randomised phase 2 trial. *Lancet Oncol.* 2015;16(8):967-978.
161. Oh DY, Lee KH, Lee DW, et al. Gemcitabine and cisplatin plus durvalumab with or without tremelimumab in chemotherapy-naïve patients with advanced biliary tract cancer: an open-label, single-centre, phase 2 study. *Lancet Gastroenterol Hepatol.* 2022;7(6):522-532.
162. Kelley RK, Ueno M, Yoo C, et al. Pembrolizumab in combination with gemcitabine and cisplatin compared with gemcitabine and cisplatin alone for patients with advanced biliary tract cancer (KEYNOTE-966): a randomised, double-blind, placebo-controlled, phase 3 trial. *Lancet.* 2023;401(10391):1853-1865.
163. Walter T, Horgan AM, McNamara M, et al. Feasibility and benefits of second-line chemotherapy in advanced biliary tract cancer: a large retrospective study. *Eur J Cancer.* 2013;49(2):329-335.
164. Lamarca A, Hubner RA, David Ryder W, Valle JW. Second-line chemotherapy in advanced biliary cancer: a systematic review. *Ann Oncol.* 2014;25(12):2328-2338.
165. Brireau B, Dahan L, De Rycke Y, et al. Second-line chemotherapy for advanced biliary tract cancer after failure of the gemcitabine-platinum combination: a large multicenter study by the association des gastro-Entérologues Oncologues. *Cancer.* 2015;121(18):3290-3297.
166. Fornaro L, Vivaldi C, Cereda S, et al. Second-line chemotherapy in advanced biliary cancer progressed to first-line platinum-gemcitabine combination: a multicenter survey and pooled analysis with published data. *J Exp Clin Cancer Res.* 2015;34:156.

167. Kim BJ, Hyung J, Yoo C, et al. Prognostic factors in patients with advanced biliary tract cancer treated with first-line gemcitabine plus cisplatin: retrospective analysis of 740 patients. *Chemother Pharmacol*. 2017;80(1):209-215.
168. Neuzillet C, Casadei Gardini A, Brieau B, et al. Prediction of survival with second-line therapy in biliary tract cancer: actualisation of the AGEO CT2BIL cohort and European multicentre validations. *Eur J Cancer Oxf Engl*. 1990;111:94-106.
169. Neuzillet C, Casadei-Gardini A, Brieau B, et al. Flupyrimidine single agent or doublet chemotherapy as second line treatment in advanced biliary tract cancer. *Int J Cancer*. 2020;147(11):3177-3188.
170. Cereda S, Milella M, Cordio S, et al. Capecitabine with/without mitomycin C: results of a randomized phase II trial of second-line therapy in advanced biliary tract adenocarcinoma. *Cancer Chemother Pharmacol*. 2016;77(1):109-114.
171. Zheng Y, Tu X, Zhao P, et al. A randomised phase II study of second-line XELIRI regimen versus irinotecan monotherapy in advanced biliary tract cancer patients progressed on gemcitabine and cisplatin. *Br J Cancer*. 2018;119(3):291-295.
172. Ramaswamy A, Ostwal V, Sharma A, et al. Efficacy of capecitabine plus irinotecan vs irinotecan monotherapy as second-line treatment in patients with advanced gallbladder cancer: a multicenter phase 2 randomized clinical trial (GB-SELECT). *JAMA Oncol*. 2021;7(3):436-439.
173. Lamarca A, Palmer DH, Wasan HS, et al. Second-line FOLFOX chemotherapy versus active symptom control for advanced biliary tract cancer (ABC-06): a phase 3, open-label, randomised, controlled trial. *Lancet Oncol*. 2021;22(5):690-701.
174. Nakamura H, Arai Y, Totoki Y, et al. Genomic spectra of biliary tract cancer. *Nat Genet*. 2015;47(9):1003-1010.
175. Jain A, Javle M. Molecular profiling of biliary tract cancer: a target rich disease. *J Gastrointest Oncol*. 2016;7(5):797-803.
176. Farshidfar F, Zheng S, Gingras MC, et al. Integrative genomic analysis of cholangiocarcinoma identifies distinct IDH-mutant molecular profiles. *Cell Rep*. 2017;18(11):2780-2794.
177. Jusakul A, Cutcutache I, Yong CH, et al. Whole-genome and epigenomic landscapes of etiologically distinct subtypes of cholangiocarcinoma. *Cancer Discov*. 2017;7(10):1116-1135.
178. Nepal C, O'Rourke CJ, Oliveira DVNP, et al. Genomic perturbations reveal distinct regulatory networks in intrahepatic cholangiocarcinoma. *Hepatology*. 2018;68(3):949-963.
179. Verlingue L, Malka D, Allorant A, et al. Precision medicine for patients with advanced biliary tract cancers: an effective strategy within the prospective MOSCATO-01 trial. *Eur J Cancer*. 2017;87:122-130.
180. Abou-Alfa GK, Macarulla T, Javle MM, et al. Ivosidenib in IDH1-mutant, chemotherapy-refractory cholangiocarcinoma (ClarIDHy): a multicentre, randomised, double-blind, placebo-controlled, phase 3 study. *Lancet Oncol*. 2020;21(6):796-807.
181. Abou-Alfa GK, Sahai V, Hollebecque A, et al. Pemigatinib for previously treated, locally advanced or metastatic cholangiocarcinoma: a multicentre, open-label, phase 2 study. *Lancet Oncol*. 2020;21(5):671-684.
182. Goyal L, Meric-Bernstam F, Hollebecque A, et al. Futibatinib for FGFR2-rearranged intrahepatic cholangiocarcinoma. *N Engl J Med*. 2023;388(3):228-239.
183. Mazzaferro V, El-Rayes BF, Droz Dit Busset M, et al. Derazantinib (ARQ 087) in advanced or inoperable FGFR2 gene fusion-positive intrahepatic cholangiocarcinoma. *Br J Cancer*. 2019;120(2):165-171.
184. Javle M, Roychowdhury S, Kelley RK, et al. Infigratinib (BGJ398) in previously treated patients with advanced or metastatic cholangiocarcinoma with FGFR2 fusions or rearrangements: mature results from a multicentre, open-label, single-arm, phase 2 study. *Lancet Gastroenterol Hepatol*. 2021;6(10):803-815.
185. Borad MJ, Schram AM, Kim RD, et al. Updated dose escalation results for ReFocus, a first-in-human study of highly selective FGFR2 inhibitor RLY-4008 in cholangiocarcinoma and other solid tumors. *J Clin Oncol*. 2023;41(16\_suppl):4009.
186. Javle M, Borad MJ, Azad NS, et al. Pertuzumab and trastuzumab for HER2-positive, metastatic biliary tract cancer (MyPathway): a multicentre, open-label, phase 2a, multiple basket study. *Lancet Oncol*. 2021;22(9):1290-1300.
187. Harding JJ, Piha-Paul SA, Shah RH, et al. Antitumour activity of neratinib in patients with HER2-mutant advanced biliary tract cancers. *Nat Commun*. 2023;14(1):630.
188. Ohba A, Morizane C, Ueno M, et al. Multicenter phase II trial of trastuzumab deruxtecan for HER2-positive unresectable or recurrent biliary tract cancer: HERB trial. *Future Oncol*. 2022;18(19):2351-2360.
189. Nakamura Y, Mizuno N, Sunakawa Y, et al. Tucatinib and trastuzumab for previously treated human epidermal growth factor receptor 2-positive metastatic biliary tract cancer (SGNTUC-019): a phase II basket study. *J Clin Oncol*. 2023;41:5569-5578.
190. Harding JJ, Fan J, Oh DY, et al. Zanidatamab for HER2-amplified, unresectable, locally advanced or metastatic biliary tract cancer (HERIZON-BTC-01): a multicentre, single-arm, phase 2b study. *Lancet Oncol*. 2023;24(7):772-782.
191. Subbiah V, Kreitman RJ, Wainberg ZA, et al. Dabrafenib plus trametinib in BRAFV600E-mutated rare cancers: the phase 2 ROAR trial. *Nat Med*. 2023;29(5):1103-1112.
192. Tran B, Meric-Bernstam F, Arkenau HT, et al. Efficacy of TAS-120, an irreversible fibroblast growth factor receptor inhibitor (FGFRi), in patients with cholangiocarcinoma and FGFR pathway alterations previously treated with chemotherapy and other FGFRi's. *Ann Oncol*. 2018;29:ix49-ix50.
193. Javle M, Lowery M, Shroff RT, et al. Phase II study of BGJ398 in patients with FGFR-altered advanced Cholangiocarcinoma. *J Clin Oncol*. 2018;36(3):276-282.
194. Javle MM, Shroff RT, Zhu A, et al. A phase 2 study of BGJ398 in patients (pts) with advanced or metastatic FGFRaltered cholangiocarcinoma (CCA) who failed or are intolerant to platinum-based chemotherapy. *J Clin Oncol*. 2016;34(4\_suppl):335.
195. Papadopoulos KP, El-Rayes BF, Tolcher AW, et al. A phase 1 study of ARQ 087, an oral pan-FGFR inhibitor in patients with advanced solid tumours. *Br J Cancer*. 2017;117(11):1592-1599.
196. Meric-Bernstam F, Beeram M, Mayordomo JI, et al. Single agent activity of ZW25, a HER2-targeted bispecific antibody, in heavily pretreated HER2-expressing cancers. *J Clin Oncol*. 2018;36(15\_suppl):2500.
197. Bekaii-Saab T, Phelps MA, Li X, et al. Multi-institutional phase II study of selumetinib in patients with metastatic biliary cancers. *J Clin Oncol*. 2011;29(17):2357-2363.
198. El-Khoueiry AB, Rankin CJ, Ben-Josef E, et al. SWOG 0514: a phase II study of sorafenib in patients with unresectable or metastatic gallbladder carcinoma and cholangiocarcinoma. *Investig New Drugs*. 2012;30(4):1646-1651.
199. Wainberg ZA, Lassen UN, Elez E, et al. Efficacy and safety of dabrafenib (D) and trametinib (T) in patients (pts) with BRAF V600E-mutated biliary tract cancer (BTC): a cohort of the ROAR basket trial. *J Clin Oncol*. 2019;37(4\_suppl):187.
200. Meric-Bernstam F, Bahleda R, Hierro C, et al. Futibatinib, an irreversible FGFR1-4 inhibitor, in patients with advanced solid tumors harboring GGF/FGFR aberrations: a phase I dose-expansion study. *Cancer Discov*. 2022;12(2):402-415.
201. Meric-Bernstam F, Hanna DL, El-Khoueiry AB, et al. Zanidatamab (ZW25) in HER2-positive biliary tract cancers (BTCs): results from a phase I study. *J Clin Oncol*. 2021;39(3\_suppl):299.
202. Nogova L, Sequist LV, Perez Garcia JM, et al. Evaluation of BGJ398, a fibroblast growth factor receptor 1-3 kinase inhibitor, in patients with advanced solid tumors harboring genetic alterations in fibroblast growth factor receptors: results of a global phase I, dose-escalation and dose-expansion study. *J Clin Oncol*. 2017;35(2):157-165.

203. Subbiah V, Kreitman RJ, Wainberg ZA, et al. Dabrafenib and trametinib treatment in patients with locally advanced or metastatic BRAF V600-mutant anaplastic thyroid cancer. *J Clin Oncol*. 2018;36(1):7-13.
204. Ross JS, Wang K, Gay L, et al. New routes to targeted therapy of intrahepatic cholangiocarcinomas revealed by next-generation sequencing. *Oncologist*. 2014;19(3):235-242.
205. Drilon A, Laetsch TW, Kummar S, et al. Efficacy of larotrectinib in TRK fusion-positive cancers in adults and children. *N Engl J Med*. 2018;378(8):731-739.
206. Marabelle A, Le DT, Ascierto PA, et al. Efficacy of pembrolizumab in patients with noncolorectal high microsatellite instability/mismatch repair-deficient cancer: results from the phase II KEYNOTE-158 study. *J Clin Oncol*. 2020;38(1):1-10.
207. Le DT, Durham JN, Smith KN, et al. Mismatch repair deficiency predicts response of solid tumors to PD-1 blockade. *Science*. 2017;357(6349):409-413.

## SUPPORTING INFORMATION

Additional supporting information can be found online in the Supporting Information section at the end of this article.

**How to cite this article:** Neuzillet C, Decraecker M, Larrue H, et al. Management of intrahepatic and perihilar cholangiocarcinomas: Guidelines of the French Association for the Study of the Liver (AFL). *Liver Int*. 2024;00:1-21. doi:[10.1111/liv.15948](https://doi.org/10.1111/liv.15948)