



HAL
open science

Acute Thoracic Endograft Stenosis after Blunt Thoracic Aortic Injury: Use of a Large Self Expanding Stent Graft as a Low Risk Effective and Potentially Durable Treatment

Aurelien Hostalrich, Thibaut Boisroux, Benoit Lebas, Jean Segal,
Jean-Baptiste Ricco, Xavier Chaufour

► To cite this version:

Aurelien Hostalrich, Thibaut Boisroux, Benoit Lebas, Jean Segal, Jean-Baptiste Ricco, et al.. Acute Thoracic Endograft Stenosis after Blunt Thoracic Aortic Injury: Use of a Large Self Expanding Stent Graft as a Low Risk Effective and Potentially Durable Treatment. *European Journal of Vascular and Endovascular Surgery*, 2024, 68 (1), pp.135-136. 10.1016/j.ejvs.2024.03.001 . hal-04642365

HAL Id: hal-04642365

<https://hal.science/hal-04642365>

Submitted on 9 Jul 2024

HAL is a multi-disciplinary open access archive for the deposit and dissemination of scientific research documents, whether they are published or not. The documents may come from teaching and research institutions in France or abroad, or from public or private research centers.

L'archive ouverte pluridisciplinaire **HAL**, est destinée au dépôt et à la diffusion de documents scientifiques de niveau recherche, publiés ou non, émanant des établissements d'enseignement et de recherche français ou étrangers, des laboratoires publics ou privés.



Distributed under a Creative Commons Attribution 4.0 International License

RESEARCH LETTER

Acute Thoracic Endograft Stenosis after Blunt Thoracic Aortic Injury: Use of a Large Self Expanding Stent Graft as a Low Risk Effective and Potentially Durable Treatment

Aurelien Hostalrich ^a, Thibaut Boisroux ^a, Benoit Lebas ^a, Jean Segal ^a, Jean-Baptiste Ricco ^{a,b,*}, Xavier Chaufour ^a

^a Department of Vascular Surgery, University Hospital Rangueil, Toulouse, France

^b University of Poitiers, School of Medicine, Poitiers, France

The revolution in thoracic endovascular aortic repair (TEVAR) for patients with blunt thoracic aortic injury (BTAI) has led to spectacular improvement in the prognosis of this major aortic trauma.¹

Even if the literature on the immediate outcome of TEVAR for BTAI in young patients is reassuring, hyperplastic stenosis at the boundary between the distal end of the thoracic aortic endograft and the descending thoracic aorta is a delayed complication with dramatic consequences that may be attributed to excessive oversizing in patients with a small aorta (Fig. 1A).²

Treatment of this lesion is not yet the subject of guideline recommendations. Only a few clinical cases have suggested varied solutions: (1) open conversion with implantation of an aortic prosthesis under extracorporeal circulation and removal of the stent graft, leading to a significant risk of paraplegia;³ (2) insertion of another thoracic aortic endograft, entailing considerable risk of recurrence; and (3) an axillofemoral bypass, a low risk procedure that improves vascularisation of the lower limbs but has poor midterm patency, rendering it inappropriate for young patients. Nieuwstraten *et al.* recently reported the case of a patient treated with a Palmaz stent leading to positive post-operative evolution.⁴

In this clinical situation, use of a Sinus-XL self expanding nitinol stent (OptiMed, Ettlingen, Germany) was reported for the first time in 2019.⁵ Here the results of application of this technique in five consecutive patients operated on between January 2019 and December 2023 at a mean \pm standard deviation age of 18 ± 4 years is described. At the time of re-operation, all five patients had severe arterial hypertension with pulmonary oedema (three patients), weakness of the lower extremities (three patients), or renal ischaemia (two patients). In this cohort, monitoring following re-intervention consisted of computed tomography angiography (CTA) at 1, 3, 6 months and 1 year, followed by

annual duplex ultrasonography. Two patients presented with moderate and asymptomatic hyperplasia on CTA, 6 months following TEVAR. As the evolution of mild aortic hyperplasia is unknown, and since CTA is an effective means of surveillance, the decision was taken not to intervene earlier in these asymptomatic patients.

The five patients initially had a grade II or III BTAI and received the smallest thoracic endovascular graft available (Zenith Alpha thoracic endovascular graft ZTA-P-24-100; Cook Medical, Bloomington, IN, USA) with median oversizing of 18% (interquartile range [IQR] 15, 21). Despite only moderate oversizing of the endograft, they presented with post-TEVAR hyperplastic stenosis and were re-operated on a mean of 13.6 ± 5.1 months after TEVAR (median 12 months, IQR 9, 18 months) with insertion of an OptiMed Sinus-XL self expanding nitinol stent.

The mean follow up after re-intervention was 18.6 ± 5.7 months. No patient was lost to follow up. Immediate disappearance of ischaemic symptoms was observed, and there was no clinical recurrence or abnormality on imaging.

The diameter of the self expanding nitinol stent was empirically chosen as the average between the diameter of the aortic endograft and that of the underlying aorta. Typically, a bare stent of 20 mm diameter was used (Fig. 1B). Pre-dilatation was required in one patient. No distal emboli were observed either during or after stent insertion. During the first post-operative month, direct oral anticoagulants were combined with long term treatment with aspirin or clopidogrel.

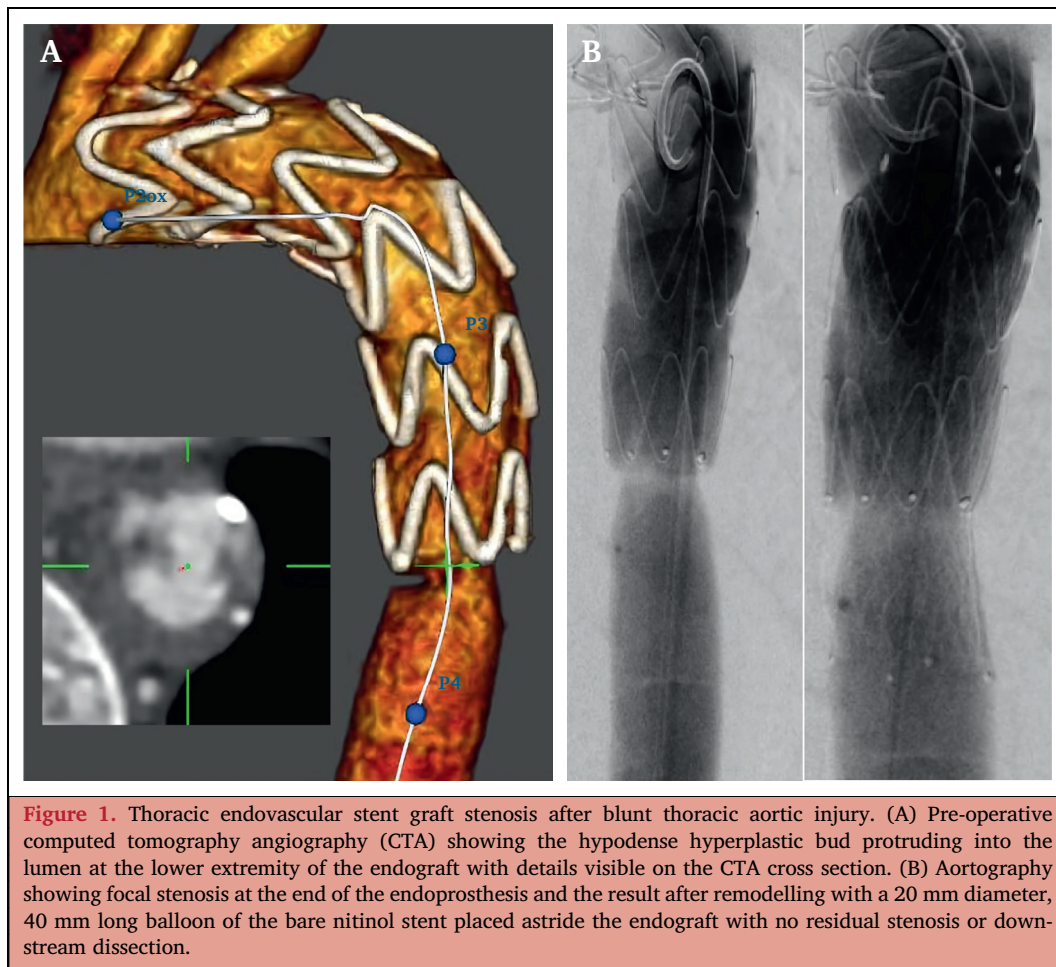
The results of this retrospective cohort suggest that use of a large, self expanding stent for thoracic endograft stenosis after BTAI provides medium term stable aortic revascularisation at 2 years, without resorting to major open conversion surgery that entails significant risks.

* Corresponding author. Department of Vascular Surgery, University Hospital Rangueil, 1 avenue Jean Poulhes, 31059 Toulouse, Cedex 09, France. Tel.: +33 5 61 32 26 20.

E-mail address: jean.baptiste.ricco@univ-poitiers.fr (Jean-Baptiste Ricco).

CONFLICTS OF INTEREST STATEMENT AND FUNDING

None declared.



REFERENCES

- 1 Boutin L, Caballero MJ, Guarrigue D, Hammad E, Rennuit I, Delhaye N, et al.; TraumaBase Group. Blunt traumatic aortic injury management, a French TraumaBase analytic cohort. *Eur J Vasc Endovasc Surg* 2022;**63**:401–9.
- 2 García Reyes ME, Gonçalves Martins G, Fernández Valenzuela V, Domínguez González JM, Maeso Lebrun J, Bellmunt Montoya S. Long-term outcomes of thoracic endovascular aortic repair focused on bird beak and oversizing in blunt traumatic thoracic aortic injury. *Ann Vasc Surg* 2018;**50**:140–7.
- 3 Martinelli O, Malaj A, Faccenna F, Ruberto F, Alunno A, Totaro M, et al. Open conversion for recurrent endograft occlusion after endovascular treatment of blunt traumatic aortic injury: a peculiar case report. *Ann Vasc Surg* 2020;**67**:568.
- 4 Nieuwstraten JA, Stadius van Eps RG, Wever JJ, Veger HTC. Focal aortic dissection with significant stenosis: a rare long term complication after TEVAR for blunt traumatic aortic injury in an adolescent patient. *EJVES Vasc Forum* 2023;**60**:33–6.
- 5 Hostalrich A, Canaud L, Ozdemir BA, Chaufour X. Severe thoracic aorta stenosis after endovascular treatment of blunt thoracic aortic injury. *Semin Thorac Cardiovasc Surg* 2019;**31**:227–9.

Keywords:

Blunt thoracic aortic injury, BTAI, TEVAR, Thoracic endovascular stent graft stenosis

Available online 4 March 2024

© 2024 The Authors. Published by Elsevier B.V. on behalf of European Society for Vascular Surgery. This is an open access article under the CC BY license (<http://creativecommons.org/licenses/by/4.0/>).

<https://doi.org/10.1016/j.ejvs.2024.03.001>