



HAL
open science

Pattern and Impact of Pesticide Poisoning: A Review of Published Case Reports

Oche Joseph Otokpa, Chinenye Oche Otokpa, Helen Shnada Auta, Andy Anyalewachi Ukah

► To cite this version:

Oche Joseph Otokpa, Chinenye Oche Otokpa, Helen Shnada Auta, Andy Anyalewachi Ukah. Pattern and Impact of Pesticide Poisoning: A Review of Published Case Reports. *TEXILA INTERNATIONAL JOURNAL OF PUBLIC HEALTH*, 2024, 12 (2), 10.21522/TIJPH.2013.12.02.Art016 . hal-04628849

HAL Id: hal-04628849

<https://hal.science/hal-04628849v1>

Submitted on 28 Jun 2024

HAL is a multi-disciplinary open access archive for the deposit and dissemination of scientific research documents, whether they are published or not. The documents may come from teaching and research institutions in France or abroad, or from public or private research centers.

L'archive ouverte pluridisciplinaire **HAL**, est destinée au dépôt et à la diffusion de documents scientifiques de niveau recherche, publiés ou non, émanant des établissements d'enseignement et de recherche français ou étrangers, des laboratoires publics ou privés.



Distributed under a Creative Commons Attribution 4.0 International License

Pattern and Impact of Pesticide Poisoning: A Review of Published Case Reports

Oche Joseph Otorkpa^{1*}, Chinenye Oche Otorkpa², Helen Shnada Auta³, Andy Anyalewachi Ukah⁴

¹*Department of Public Health, School of Public Health, Texila American University, Georgetown, Guyana*

²*Department of Physiology, College of Health Sciences, Federal University, Lokoja, Nigeria*

³*Department of Microbiology, School of Life Sciences, Federal University of Technology, Minna, Nigeria*

⁴*National Institute of Environmental Health, Abuja, Nigeria*

Abstract

Pesticides are essential in agriculture and public health, but their use is associated with many adverse health outcomes. The objective of the current study was to review published case reports to elucidate the pattern and health impacts of exposure to various pesticide classes, including organochlorines, organophosphates, carbamates, pyrethroids, organosulfur, botanicals, and biopesticides. We conducted a review of case reports focusing on the health effects of pesticide exposure across different chemical classes. Searches were performed in major scientific databases, and relevant articles were selected based on predetermined inclusion criteria. Data extraction and synthesis were carried out to identify common health outcomes associated with each pesticide class. Organochlorines, despite being largely phased out, still pose risks due to their persistence and bioaccumulation, with links to neurodegenerative diseases and cancer. Organophosphates, known for cholinergic overstimulation, can lead to respiratory distress and seizures. Carbamates, affecting cholinesterase activity, may cause respiratory paralysis and coma. Pyrethroids disrupt the nervous system and can induce convulsions and alter consciousness. Organosulfur can induce liver damage and renal dysfunction. Botanical pesticides and biopesticides, while generally considered safer, can also cause severe toxicity, including methemoglobinemia and multiorgan failure, as evidenced by rare cases of poisoning. This review highlights the diverse health impacts of pesticide exposure across different chemical classes. It exposes the need for systematic surveillance, longitudinal studies, and comparative assessments between conventional pesticides and biopesticides. Interdisciplinary collaborations are crucial for comprehensive risk assessment and the development of targeted interventions to mitigate these detrimental effects.

Keywords: *Chemical Classes, Case Reports, Health Effects, Pesticides, Pesticide Poisoning.*

Introduction

Pesticides constitute a diverse array of chemical compounds designed to mitigate the adverse impact of pests on agriculture, public health, and the environment [1]. Pesticides include insecticides (for controlling insects),

herbicides (for controlling weeds), fungicides (for controlling fungi), rodenticides (for controlling rodents), and bactericides (for controlling bacteria), among others [2]. While their efficacy in pest control is well-established, the potential for adverse health effects resulting from pesticide exposure has

garnered increasing attention [3, 4]. According to updated estimates, over 385 million cases of unintentional acute pesticide poisoning occur annually resulting in the death of more than 11,000 people each year [5].

Among the various classes of pesticides, herbicides represent a significant category by volume due to their wide spread use in agriculture and other weed management practices [6]. Despite stringent regulations and guidelines governing their use, instances of pesticide poisoning, both acute and chronic, continue to pose significant public health challenges across the globe [7].

Despite numerous studies examining the health impacts of pesticide poisoning, there remains a need for a comprehensive review focusing on the distinct health effects associated with various chemical classes of pesticides. In this study, we undertook a review of published case reports to elucidate the various health effects that arise from exposure to different chemical classes of pesticides. By synthesizing available evidence, we aim to discern patterns, trends, and associations between pesticide exposure and specific health outcomes across different chemical classes, thereby enhancing our understanding of the risks posed by pesticide exposure and helping in the formulation of evidence-based strategies for prevention, intervention, management and regulatory oversight.

Methodology

We conducted an internet search of electronic databases, including PubMed, Scopus, Web of Science, and Google Scholar, to identify relevant case reports and studies published from 2004 up to the present date. Keywords such as "pesticides," "pesticide poisoning," "chemical classes," "health effects," and "case reports" were used in various combinations to maximize the retrieval of relevant articles. The search was limited to studies published in English, but efforts were

made to include articles from diverse geographical regions to capture a broad spectrum of pesticide exposures and associated health effects. Articles were screened based on predefined inclusion and exclusion criteria. Case reports or case series studies documenting pesticide poisoning in humans as well as studies reporting specific health effects associated with the exposure to different chemical classes of pesticides were included.

Studies focusing solely on acute pesticide poisoning without documenting specific health effects, non-human studies or studies not relevant to human health outcomes were excluded. The qualities of the included studies were assessed using established criteria for case reports and case series studies. Factors such as clarity of case descriptions, adequacy of diagnostic criteria, and consideration of potential confounders were evaluated to determine the overall reliability and validity of the evidence presented.

Health Effects Based on Chemical Class

Organochlorines

Organochlorine pesticides (OCPs) are pesticides that contain carbon, chlorine, and hydrogen atoms in their chemical structure. They were widely used in the past but have been largely phased out in most countries due to their persistence in the environment and potential for bioaccumulation [8, 9]. OCPs have been reported in human body tissues including blood, breast milk and fatty tissues where they build up and persist for a long period and have been implicated in several chronic conditions including Parkinson's disease [10].

Exposure to OCPs can cause various symptoms such as headache, nausea, vomiting, incoordination, dizziness, tremors, and mental confusion. In more severe cases, poisoning can lead to myoclonic jerking movements, often followed by generalized tonic-clonic convulsions. Coma and respiratory depression may ensue after the seizures [11, 12]. OCPs

can disrupt the molecular circuitry of the endocrine system, potentially resulting in various other health issues. They are known to be carcinogenic and neurotoxic and have been associated with increased risks of hormone-related cancers such as breast, prostate, stomach, and lung cancer [13].

According to a published case report, a father and son, aged 52 and 24 years respectively, were brought to the emergency department after mistakenly using Dichlorodiphenyltrichloroethane (DDT) a common OCP instead of flour while preparing fish for a meal. Shortly after ingestion, they developed symptoms including recurrent convulsions and loss of consciousness. Both patients were promptly intubated endotracheally and admitted to the intensive care unit (ICU) for further management. Upon admission, physical examination revealed signs of severe metabolic acidosis in both cases. Laboratory investigations on the second day of admission showed acute oliguric renal failure (ARF) in the son, with elevated blood urea nitrogen (BUN) levels of 47 mg/dl and creatinine levels of 6.4 mg/dl. Urinalysis performed on the third day disclosed abundant red blood cells (RBCs), indicating renal injury. Both patients received vigorous fluid resuscitation and were closely monitored in the ICU. Over ten days, their clinical condition gradually improved, with the reversal of metabolic acidosis and resolution of renal failure. By the end of the second week, both patients had fully recovered and were discharged from the hospital without any sequelae [14].

A unique case of OCP poisoning involved a 61-year-old woman who was poisoned due to ingestion of endosulfan, an off-patent OCP. She was brought to the state hospital emergency department in an unresponsive state and was pronounced dead upon arrival. According to her husband, she had consumed homemade pastry approximately one hour before the onset of symptoms, which included

nausea, vomiting, and dizziness. Subsequently, she experienced generalized tonic-clonic seizures that persisted for one hour before her demise, approximately four hours after ingesting the pastry. Initial assessment suggested respiratory failure and status epilepticus as potential causes of death. Upon autopsy, external examination of the corpse revealed no traumatic lesions. However, extensive congestion and spotty bleeding areas were observed on the surface and cross-sections of the brain and cerebellum. These findings raised suspicion of an underlying neurological pathology contributing to the patient's demise [15].

Another case of OCP poisoning reported the endosulfan poisoning of a 2.5-year-old child who accidentally ingested an unknown quantity of endosulfan from a 20-ounce soft drink bottle. Shortly after ingestion, the child developed generalized tonic-clonic seizure activity and became unresponsive. He was initially transferred to the local hospital and later to a tertiary children's hospital, where his seizures proved resistant to treatment despite the administration of multiple anticonvulsants. The child's condition deteriorated, resulting in hypotension necessitating vasopressor support. On the third day, an MRI revealed cerebral edema and a nuclear medicine flow scan failed to detect blood flow to the brain. Tragically, the child succumbed to these complications and was pronounced dead [16].

Organophosphates

Organophosphate pesticides (OP) contain phosphorus and oxygen atoms in their chemical structure, they work by inhibiting the activity of enzymes in the nervous system of pests [17]. The classic symptoms associated with organophosphate poisoning are described by the acronym SLUDGE: Salivation, Lacrimation, Urination, Defecation, Gastric cramps, and Emesis. These manifestations reflect the cholinergic overstimulation caused by OP compounds [18]. In severe cases,

patients may present with additional symptoms, including unresponsiveness, muscle fasciculations, pinpoint pupils and diaphoresis [19].

A 43-year-old male with no significant medical history presented to the emergency department with sudden-onset nausea, vomiting, and diarrhoea, accompanied by abdominal discomfort. He admitted to self-applying malathion, an organophosphate pesticide for scabies over three days before presentation, with symptoms occurring shortly after the last application. No excessive lacrimation or salivation was reported but he was admitted for observation. Treatment focused on symptomatic relief, with resolution of gastrointestinal symptoms within 12 hours. Diagnostic tests revealed decreased cholinesterase levels, consistent with pesticide exposure. The psychiatric evaluation led to a diagnosis of delusional parasitosis. The patient was discharged after five days with outpatient psychiatric follow-up [20].

A rare case of organophosphate (OP) poisoning in pregnancy involved a 22-year-old woman in her 29th week of gestation who presented to King Edward VIII Hospital in Durban, South Africa, after experiencing multiple generalized tonic-clonic seizures at home. Initially, a presumptive diagnosis of eclampsia was made, and treatment with intravenous magnesium sulfate was initiated. However, further assessment revealed signs of OP toxicity, including a garlic odour, vomiting, diarrhoea, faecal incontinence, excessive secretions leading to airway compromise, diffuse rhonchi, muscle weakness, fasciculations and pinpoint pupils. The patient responded to intravenous atropine, as oximes were not available. While the mother survived, the infant was born prematurely and died two days after birth without exhibiting any signs of OP poisoning. This case highlights the potential for OP poisoning to mimic acute complications in pregnancy, such as eclampsia and seizures,

underscoring the importance of considering toxicological etiologies in such scenarios [21].

In another published case report, a 51-year-old farmer was admitted to the hospital after ingesting an unspecified amount of parathion, an organophosphorus compound. He had a history of diabetes managed with oral hypoglycemic medication for six years but had no other significant medical conditions or prior hospitalizations. Upon admission, he presented himself as drowsy and only partially responsive, unable to follow commands. Gastric lavage was performed, and chemical analysis of the lavage material indicated the presence of the toxin. Subsequently, he developed a myocardial infarction, but unfortunately, he did not respond to treatment and passed away [22].

A unique case involved a 29-year-old male who presented to the emergency department after ingesting 50 to 100mL of methyl parathion. Despite the substantial dose, the patient showed almost no clinical effects. Laboratory analysis revealed delayed and prolonged suppression of acetylcholinesterase activity, indicating the toxicological impact of the ingestion. Absorption of methyl parathion was predicted to occur over 30 hours, suggesting a slow release of the toxin into the bloodstream. However, the bioavailability appeared to be very low, resulting in minimal systemic effects despite the significant amount ingested [23].

Carbamates

Carbamate pesticides also target the nervous system of pests but act through a different mechanism than organophosphates, they inhibit the activity of enzymes called cholinesterases [24]. Common symptoms of carbamate pesticide poisoning include difficulty in breathing, muscle weakness and twitching but in severe cases, patients may experience respiratory paralysis, seizures and coma [25].

Suicidal poisoning by exposure of a 43-year-old farmer with Carbofuran, a carbamate pesticide, was reported. The poisoning resulted in sudden respiratory and cardiac arrest characterized by bradycardia asystole. In addition, he was diagnosed with metabolic acidosis and extensive aspiration pneumonia. Following treatment, the patient's overall condition improved, achieving alignment in the efficiency of both respiratory and circulatory systems [26].

In another case report, a two-year-old child was exposed to pesticide residues following the application of pesticides at home for cockroach control. The child, presenting with a semi-conscious status, was brought to the European Hospital in South Gaza accompanied by his father, who carried the empty container of the pesticide used. Analysis revealed Carbaryl, a carbamate insecticide, as the causative agent of poisoning. Upon admission to the intensive care unit, the child underwent decontamination with clean water, and their clothing was removed to mitigate potential hazards. Blood analysis indicated moderate inhibition of acetylcholinesterase (AChE) activity upon initial testing, which progressed to more severe inhibition over time. Despite administration of several doses of atropine, there was no improvement in AChE activity. Subsequently, the child was administered Obidoxime as an antidote, resulting in significant improvement in AChE activity. Daily administration of Obidoxime was continued until AChE activity returned to the normal range [27].

An analysis of 60 cases involving Aldicarb-related suicide attempts in France spanning from 2012 to 2021 revealed that most cases exhibited pathognomonic symptomatology. Among these cases, 35 victims (58.3%) presented with muscarinic syndrome, 14 (23.3%) with nicotinic syndrome, and 37 (61.7%) with central nervous system impairment. Hospitalization was required for

44 cases (73.3%), resulting in 2 fatalities. Diagnosis relied on blood cholinesterase activities. Among the 25 cases with toxicology results, 45.8% exhibited a moderate decrease in acetylcholinesterase activity, while 87.5% showed a significant decrease in butyrylcholinesterase activity. While the detection of aldicarb and its metabolites in blood or urine may be considered in therapeutic management, its quantification is unlikely to alter emergency medical care [28].

Pyrethroids

Pyrethroid pesticides are synthetic chemicals derived from natural compounds found in chrysanthemum flowers, they disrupt the nervous system of insects by affecting sodium channels [29]. Reported symptoms of Pyrethroid pesticide poisoning include headache, nausea, vomiting, facial paraesthesia, dizziness, skin itching, skin burning, muscle fasciculations reduced energy, convulsions, changes in awareness and loss of consciousness [30, 31].

A reported case of pyrethroid pesticide poisoning involved a 36-year-old male from a rural town in the Eastern Cape province of South Africa who was diagnosed with intentional cypermethrin poisoning following a suicide attempt. Initially, he was misdiagnosed with suspected organophosphate poisoning, leading to a coma. However, he achieved full recovery after receiving mechanical ventilation and symptomatic treatment with a low dose of the muscarinic antagonist, atropine sulfate [32].

In a similar case report, a 30-year-old male presented with symptoms indicative of organophosphate poisoning, including vomiting, pain, and respiratory distress, following ingestion of a liquid during a family dispute. No other toxins or drugs were ingested, and there were no relevant medical or mental health histories. Clinical examination revealed typical signs of poisoning, such as swollen lips and tremors,

leading to a diagnosis of organophosphate poisoning. Treatment included oxygen therapy and a single dose of atropine. Furthermore, cypermethrin ingestion was later discovered after the patient's wife presented 3 containers of "Danger-10" pesticide containing 10% cypermethrin/100ml. Despite delayed presentation, gastric lavage was performed, and the patient received symptomatic treatment. He showed significant improvement within 24 hours, with subsequent resolution of symptoms and discharge from the hospital [33].

Another case report involved the poisoning of a 12-year-old Afghan girl with permethrin, a type of pyrethroid pesticide. Despite having no previous medical issues, she was brought to the emergency room two hours after ingestion, showing no signs of breathing or heartbeat. Immediate cardiopulmonary resuscitation (CPR) was initiated, and her spontaneous circulation was restored after a few minutes. She was subsequently intubated, received intravenous normal saline for volume resuscitation, and was placed on mechanical ventilation upon transfer to the ICU. The patient remained comatose with bilateral mydriasis, and central diabetes insipidus developed three days later due to apnea and hypoxic brain damage from the insecticide ingestion. Chemical analysis of the insecticide bottle revealed 10% permethrin without organophosphates, contrary to initial expectations. Unfortunately, despite treatment, the patient passed away after seven days due to resistant hypotension and severe brain damage [34].

Organosulfurs

These are pesticides that contain sulfur atoms in their chemical structure, they work by interfering with various metabolic processes in pests [35]. Studies have shown that cause short- and medium-term human exposure to organosulfur pesticides can cause liver damage and renal dysfunction [36].

A classic case of organosulfur pesticide poisoning is seen in a reported case of a 48-year-old man who presented to the emergency department with fever and widespread skin and mucous lesions, which emerged after using Mancozeb, a dithiocarbamate fungicide on cucumbers in his garden. Despite wearing some protective clothing during application, he experienced severe symptoms including fever, skin itching and pain, swelling of lips and tongue, and extensive skin and mucous membrane damage. Upon admission, he showed signs of dehydration and significant skin and mucosal damage. Lab tests revealed elevated inflammatory markers, hyperglycemia, kidney dysfunction, and electrolyte imbalances. His condition was severe, with a high risk of mortality. Treatment involved supportive care, corticosteroids, antibiotics, and wound management. Despite initial improvement, he experienced a setback with recurrent fever and positive bacterial cultures, necessitating transfer to a specialized burns center for further treatment, including antibiotic adjustment and wound care. Over the following weeks, his condition gradually improved, with complete healing of skin and mucosal lesions. However, he developed fingernail abnormalities and recurrent obstructions in his tear ducts, requiring periodic surgical interventions. After 2 years, while his skin lesions had healed without scarring, he continued to experience nail abnormalities and tear duct issues, highlighting some lasting consequences of the fungicide exposure [37]. While there is a limited number of case reports and studies concerning the toxicological effects of organosulfurs, the available evidence suggests that exposure to this class of pesticide can inhibit vital enzymes responsible for proper physiological function leading to alterations in thyroid hormones, neurotoxicity and teratogenesis [38].

Botanicals

Botanical pesticides or natural insecticides are a group of pesticides derived from plants and contain natural compounds that have pesticidal properties [39]. The popularity of botanical pesticides in organic farming is on the rise, due to their safety profile in food crop production [40].

However, this has not prevented poisoning-related events with botanical pesticides as was the case with a 47-year-old woman with type 2 diabetes who ingested a significant amount of rotenone a pesticide derived from plants in the Leguminosae family, leading to collapse and unconsciousness. Despite prompt medical intervention, including intubation and ventilation, she developed severe metabolic acidosis, liver dysfunction, and cardiovascular instability. Treatment attempts with intravenous NAC, antioxidants, and other medications were unsuccessful. Her condition deteriorated rapidly, ultimately resulting in multiorgan failure and asystolic cardiac arrest, with postmortem findings indicating extensive organ damage [41].

Another reported case of botanical pesticides poisoning involved 32-year-old woman who was admitted to the emergency department after ingesting an insecticide. Although she was initially stable, she quickly deteriorated, becoming drowsy, agitated, and cyanosed upon arrival in the intensive care unit (ICU). Suspected organophosphorus poisoning led to intubation and mechanical ventilation. Further investigation revealed methemoglobinemia, likely caused by the ingested insecticide "NIMOLIN" a zadirachtin oil-based pesticide. Treatment with Pralidoxamine and atropine was stopped, and conservative management was initiated, including mechanical ventilation and supportive care. Over the following days, her condition gradually improved, with oxygen saturation levels increasing and methemoglobin levels decreasing. She was

successfully weaned off the ventilator and discharged after six days of hospitalization [42].

In addition, some case reports have also implicated plants with pesticidal potential like *Colchicum persicum*, also known as Persian autumn crocus or Persian meadow which was implicated in the death of a 39-year-old man who presented to the emergency room with symptoms of nausea, vomiting, and diarrhoea after ingesting wild garlic, initially attributed to food poisoning. Despite supportive care and discharge, he was readmitted due to severe gastrointestinal symptoms. After a brief period of stability, he suddenly developed respiratory distress and died from cardiopulmonary arrest. Postmortem examination revealed the presence of colchicine, a toxic compound found in plants like *Colchicum persicum*, suggesting accidental poisoning as the cause of death [43].

Biopesticides

Biopesticides are derived from natural materials such as bacteria, fungi, viruses, or biochemicals. They can control pests through various mechanisms such as microbial activity, interference with insect growth, or attraction and repulsion [44]. In recent times, there has been a growing demand for the prohibition of carcinogens, mutagens, and toxic substances, particularly endocrine disruptors, in pesticides in favour of biopesticides which are considered safer and degrade rapidly in the environment, reducing the risk of pesticide residues in food and lowering the associated risks for consumers [45]. Case reports of biopesticide poisoning are rare because of their low toxicity rate, for example, *Bacillus thuringiensis* (Bt) one of the most common biopesticides is non-toxic and non-infective to vertebrates, including humans [46].

Spinosad a biopesticide derived from the fermentation of the bacterium *Saccharopolyspora spinosa* has an extremely

low risk of toxicity rate on humans [47]. However, a rare case report documented the poisoning of an 80-year-old woman who attempted suicide by ingesting a mixture of Conserve, a Taiwanese brand of Spinosad along with flonicamid. Upon arrival at the hospital, she was unconscious, in shock, and breathing irregularly. Immediate interventions included intubation, gastric lavage, activated charcoal administration, fluid challenge, and dopamine infusion. Blood tests revealed leukocytosis and metabolic acidosis with respiratory compensation. Chest radiography showed lung infiltrations. Successful

resuscitation was achieved, leading to the patient's consciousness recovery and extubation within a few days. Post-extubation, she experienced general malaise, multiple oral ulcerations, pneumonitis, and urinary retention. Endoscopy revealed corrosive esophageal injury. Electroencephalography indicated diffuse cortical dysfunction, while spirometry showed restrictive lung disease. Urodynamic study indicated neurogenic bladder. After an uneventful hospitalization, she was discharged after five weeks without chronic sequelae [48].

Summary of Results and Effects

Table 1. Showing the Summary of Reported Systemic Health Effects of Pesticides Across Chemical Classes

Chemical Class	Summary of Reported Systemic Health Effects
Organochlorines	Neurological: Headache, nausea, vomiting, incoordination, dizziness, tremors, convulsions, coma
	Endocrine disruption
	Carcinogenic
Organophosphates	Cholinergic Overstimulation: Salivation, lacrimation, urination, defecation, gastric cramps, emesis
Carbamates	Neurological: Unresponsiveness, muscle fasciculations, pinpoint pupils, diaphoresis
	Respiratory distress
	Cardiovascular complications
	Respiratory: Difficulty breathing, respiratory paralysis
Pyrethroids	Neurological: Muscle weakness, twitching, seizures, coma
	Cardiovascular complications
	Renal dysfunction
	Neurological: Headache, nausea, vomiting, dizziness, muscle fasciculations, convulsions
	Dermatological: Skin itching, burning
	Respiratory distress
Organosulfurs	Hepatic: Liver damage
	Renal dysfunction
	Dermatological: Skin lesions
	Respiratory: Difficulty breathing, pulmonary complications
Botanicals	Neurological: Loss of consciousness, seizures
	Respiratory distress
	Cardiac complications
Biopesticides	Generally low toxicity rates
	Rare cases of poisoning may include neurological, respiratory, dermatological, and cardiac effects

Discussion

The findings of this study highlight the complex and varied health impacts of pesticide exposure across different chemical classes. Each class of pesticides—organochlorines, organophosphates, carbamates, pyrethroids, organosulfurs, botanicals, and biopesticides—presents unique risks and manifestations of toxicity as shown in table 1, which highlights the importance of understanding these distinctions for effective risk assessment and management.

Despite being largely phased out, organochlorines continue to pose significant health risks due to their persistence in the environment and bioaccumulation. They have been linked to chronic conditions such as neurodegenerative diseases and various forms of cancer [49]. However, this is in contrast with the finding of another study published in the Journal of the American Cancer Society which reported that organochlorine exposure is not believed to be causally related to breast cancer one of the commonest forms of cancer [50]. Nevertheless, these findings reinforce the need for ongoing monitoring of organochlorine residues in the environment and in human tissues, even years after their use has been discontinued.

Similarly, Organophosphates and Carbamates are known for their cholinergic effects, but organophosphates tend to cause more severe symptoms including respiratory distress and seizures, while carbamates can lead to respiratory paralysis and coma. The cases reviewed demonstrate the acute nature of poisoning incidents, often resulting from either occupational exposure or misuse [51]. However, this finding is slightly at variance with the conclusion of a similar study which

reported that the brain and skeletal muscles are the major target organs [52]. Notwithstanding, given the high toxicity and potential for severe outcomes, there is a clear need for stringent regulations and protective measures for individuals working with these substances.

Pyrethroids are generally considered safer than organophosphates and carbamates, yet they still cause significant health effects, particularly neurological symptoms such as convulsions and altered consciousness [53]. The case reports emphasize the importance of proper handling and awareness of the risks, considering that they account for more than one-third of the insecticides currently marketed in the world with their distinct biochemical and neurological manifestations [53].

The reviewed cases relating to organosulfur pesticides indicate that exposure can lead to serious health issues, including liver damage and renal dysfunction [54], but there is substantial toxicologic evidence that repeated low-level exposure may affect neurodevelopment and growth [55]. Although less commonly discussed than other pesticide classes, the potential for severe toxicity warrants more attention and research to fully understand the long-term health impacts.

Botanicals and Biopesticides are often marketed as safer alternatives to synthetic pesticides, the case reports reveal that they can still cause severe toxicity in rare instances as shown in Fig 1 below and Table 1 above [56]. Cases of poisoning from botanical pesticides and biopesticides like rotenone and Spinosad suggest that despite their natural origins, they require careful handling and regulation to prevent adverse health outcomes.

PATTERN AND IMPACT OF PESTICIDE POISONING

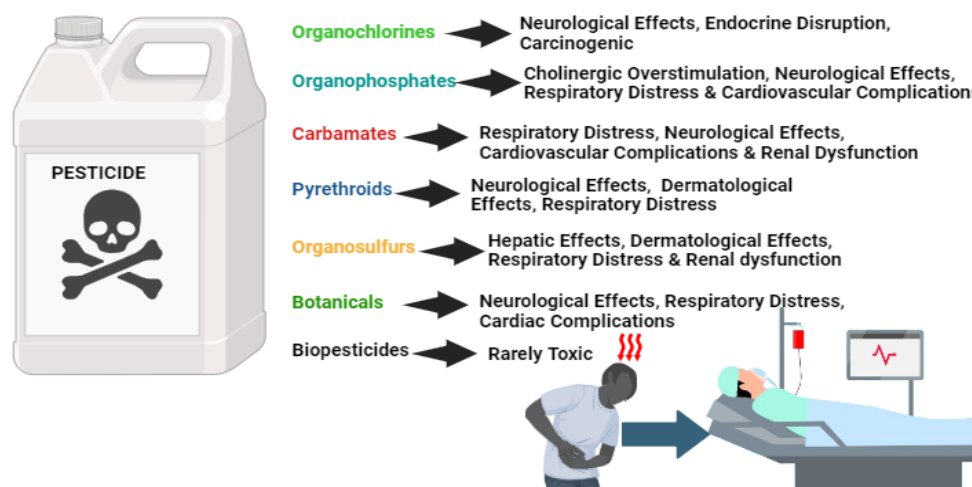


Figure 1. Displays the Patterns and Impacts of Pesticide Poisoning Across Various Chemical Classes

Further Research Needs

There is a need for more systematic surveillance and reporting of pesticide poisoning cases, particularly in regions with high agricultural activity and pesticide use. Enhanced data collection efforts would facilitate the identification of emerging trends, geographical variations, and high-risk populations vulnerable to pesticide exposure. In addition, longitudinal studies are necessary to assess the long-term health effects of pesticide poisoning, including chronic conditions such as neurodegenerative diseases, cancer, and reproductive disorders. Furthermore, comparative studies evaluating the efficacy and safety profiles of conventional pesticides versus biopesticides are needed to facilitate evidence-based decision-making in pesticide regulation and management.

Finally, interdisciplinary collaborations involving physicians, toxicologists, epidemiologists, agricultural scientists, and public health experts are crucial for conducting comprehensive risk assessments and developing targeted interventions to mitigate the adverse health effects of pesticide exposure.

Conclusion

In conclusion, this review of published case reports sheds light on the diverse and often severe health effects associated with pesticide poisoning across various chemical classes. From organochlorines to biopesticides, each class of pesticide presents unique risks and manifestations of toxicity. Despite the phased-out use of certain pesticides like organochlorines, their ability to persist in the environment and bioaccumulate continues to pose health risks, while newer alternatives such as biopesticides, though generally safer, are not without their instances of poisoning. Addressing the gaps identified in this study, including the need for systematic surveillance and interdisciplinary collaboration, is essential for improving our understanding of pesticide toxicity and developing targeted and effective interventions to mitigate its adverse health effects.

Declarations

Ethics Approval and Consent to Participate

This study is a review and does not require ethical approval.

Consent for Publication

Not applicable.

Availability of Data and Material

All data generated or analyzed during this study are included in this published article and its supplementary information files.

Reference

- [1]. Kalyabina, V. P., Esimbekova, E. N., Kopylova, K. V., & Kratasyuk, V. A. (2021). Pesticides: Formulants, Distribution Pathways and Effects on Human Health—A Review. *Toxicology Reports*, 8, 1179-1192. Doi:10.1016/j.toxrep.2021.06.004.
- [2]. Abubakar, Y., Tijjani, H., Egbuna, C., Adetunji, C. O., Kala, S., Kryeziu, T. L., et al. (2020). Pesticides, history, and classification. In H. Tijjani, C. Egbuna, & S. Kala (Eds.), *Natural Remedies for Pest, Disease and Weed Control* (pp. 29-42). *Academic Press*. Doi:10.1016/B978-0-12-819304-4.00003-8.
- [3]. Leoci, R., & Ruberti, M. (2021). Pesticides: An Overview of the Current Health Problems of their Use. *Journal of Geosciences and Environment Protection*, 9(8), 1-20. Doi:10.4236/gep.2021.98001.
- [4]. Leemans, M., Couderq, S., Demeneix, B., & Fini, J. B. (2019). Pesticides with Potential Thyroid Hormone-Disrupting Effects: A Review of Recent Data. *Frontiers in Endocrinology*, 10, 468622. Doi:10.3389/fendo.2019.00743.
- [5]. Moebus, S., & Boedeker, W. (2021). Case Fatality as an Indicator for the Human Toxicity of Pesticides—A Systematic Scoping Review on the Availability and Variability of Severity Indicators of Pesticide Poisoning. *International Journal of Environmental Research and Public Health*, 18(16), 8307. Doi:10.3390/ijerph18168307.
- [6]. Duke, S. O. (2023). Dihydroorotate Dehydrogenase as an Herbicide Target. *Proceedings of the National Academy of Sciences*, 120(51), e2319097120. Doi:10.1073/pnas.2319097120.
- [7]. Zikankuba, V. L., Mwanyika, G., Ntwenya, J. E., & James, A. (2019). Pesticide Regulations and their Malpractice Implications on Food and Environment Safety. *Cogent Food & Agriculture*, 5(1), 1601544. Doi:10.1080/23311932.2019.1601544.
- [8]. Shi, L. L., Shan, Z. J., Kong, D. Y., & Cai, D. J. (2006). The Health and Ecological Impacts of Organochlorine Pesticide Pollution in China: Bioaccumulation of Organochlorine Pesticides in Human and Fish Fats. *Human Ecology Risk Assessment*, 12(2), 402-407. Doi:10.1080/10807030500536843.
- [9]. Chopra, A. K., Sharma, M. K., & Chamoli, S. (2011). Bioaccumulation of Organochlorine Pesticides in Aquatic System—An Overview. *Environmental Monitoring and Assessment*, 173, 905-916. Doi:10.1007/s10661-010-1433-4.
- [10]. Taiwo, A. M. (2019). A Review of Environmental and Health Effects of Organochlorine Pesticide Residues in Africa. *Chemosphere*, 220, 1126-1140. Doi:10.1016/j.chemosphere.2019.01.001.
- [11]. Singh, Z., Kaur, J., Kaur, R., & Hundal, S. S. (2016). Toxic Effects of Organochlorine Pesticides: A Review. *American Journal of BioScience*, 4(3), 11. Doi:10.11648/j.ajbio.s.2016040301.13.
- [12]. Arora, S. K., Batra, P., Sharma, T., Banerjee, B. D., & Gupta, S. (2013). Role of Organochlorine Pesticides in Children with Idiopathic Seizures. *International Scholarly Research Notices*. Doi:10.1155/2013/849709

Conflicts of Interest

The authors declare no conflict of interest.

Funding

No funds, grants, or other support was received.

Acknowledgements

Not applicable.

- [13]. Pattnaik, M., Pany, B. K., Dena, J., Pal, A. K., & Sahu, G. (2020). Effect of Organochlorine Pesticides on Living Organisms and Environment. *Chemical Science Review Letters*, 9, 682-686. Doi:10.37273/chesci.CS2051063.
- [14]. Ozucelik, D. N., Karcioğlu, O., Topacoglu, H., & Fowler, J. R. (2004). Toxicity Following Unintentional DDT Ingestion. *Journal of Toxicology and Clinical Toxicology*, 42(3), 299-303. Doi:10.1081/CLT-120037432.
- [15]. Kucuker, H., Sahin, O., Yavuz, Y., & Yürümez, Y. (2009). Fatal Acute Endosulfan Toxicity: A Case Report. *Basic & Clinical Pharmacology & Toxicology*, 104(1), 49-51. Doi:10.1111/j.1742-7843.2008.00216.x.
- [16]. Parbhu, B., Rodgers, G., & Sullivan, J. E. (2009). Death in a Toddler Following Endosulfan Ingestion. *Clinical Toxicology*, 47(9), 899-901. Doi:10.3109/15563650903328879.
- [17]. Sidhu, G. K., Singh, S., Kumar, V., Dhanjal, D. S., Datta, S., & Singh, J. (2019). Toxicity, Monitoring and Biodegradation of Organophosphate Pesticides: A Review. *Critical Reviews in Environmental Science and Technology*, 49(13), 1135-1187. Doi:10.1080/10643389.2019.1565554.
- [18]. Peter, J. V., Sudarsan, T. I., & Moran, J. L. (2014). Clinical Features of Organophosphate Poisoning: A Review of Different Classification Systems and Approaches. *Indian Journal of Critical Care Medicine*, 18(11), 735. Doi:10.4103/0972-5229.144017.
- [19]. Robb, E. L., Regina, A. C., & Baker, M. B. *Organophosphate Toxicity*. PMID: 29261901.
- [20]. Chua, J. J. L., & Kuan, K. K. (2022). Organophosphate Poisoning From Inappropriate Topical Use of Malathion Pesticide: A Case Report. *Proceedings Singapore Healthcare*, 31, 20101058211068593. Doi:10.1177/20101058211068593.
- [21]. Solomon, G. M., & Moodley, J. (2007). Acute Chlorpyrifos Poisoning in Pregnancy: A Case Report. *Clinical Toxicology*, 45(4), 416-419. Doi:10.1080/15563650601117988.
- [22]. Kidiyoor, Y., Nayak, V. C., Devi, V., Bakkannavar, S. M., Kumar, G. P., & Menezes, R. G. (2009). A Rare Case of Myocardial Infarction due to Parathion Poisoning. *Journal of Forensic and Legal Medicine*, 16(8), 472-474. Doi:10.1016/j.jflm.2009.05.003.
- [23]. Isbister, G. K., Mills, K., Friberg, L. E., Hodge, M., O'Connor, E., Patel, R., et al. (2007). Human Methyl Parathion Poisoning. *Clinical Toxicology*, 45(8), 956-960. Doi:10.1080/15563650701232745.
- [24]. Gupta, R. C., Malik, J. K., & Milatovic, D. (2011). Organophosphate and Carbamate Pesticides. In *Reproductive and Developmental Toxicology*. Academic Press. Doi:10.1016/B978-0-12-382032-7.10037-2.
- [25]. Silberman, J., & Taylor, A. *Carbamate Toxicity*. PMID: 29489157
- [26]. Klatka, B. Z., Terpilowski, M., Orzel, A. K., Janeczko, D., Holowczuk, M., Tchórz, M., et al. (2021). Severe Carbamates Intoxication of 43-year-old Farmer-Case Report. *Annals of Agricultural and Environmental Medicine*, 28(2). doi:10.26444/aaem/121067
- [27]. El-Nahhal, Y. (2018). Successful Management of Carbamate Poisoning Among Children: Case Report from Gaza Strip. *Occupational Diseases and Environmental Medicine*, 6(3), 95-106. Doi:10.4236/odem.2018.63008.
- [28]. Lenski, M., Letrillart, A., Gish, A., Nisse, P., Gaulier, J. M., & Allorge, D. (2022). Aldicarb-related Suicide Attempt Cases in North of France (2012–2021). *Toxicology Research*, 11(3), 529-536. Doi:10.1093/toxres/tfac031.
- [29]. Bhardwaj, K., Sharma, R., Abraham, J., & Sharma, P. (2020). Pyrethroids: A Natural Product for Crop Protection. In *Natural Bioactive Products in Sustainable Agriculture*. Academic Press. Doi:10.1007/978-981-15-3024-1_8.
- [30]. Bradberry, S. M., Cage, S. A., Proudfoot, A. T., & Vale, J. A. (2005). Poisoning due to Pyrethroids. *Toxicological Reviews*, 24, 93-106. Doi:10.2165/00139709-200524020-00003.
- [31]. Ramchandra, A. M., Chacko, B., & Victor, P. J. (2019). Pyrethroid Poisoning. *Indian Journal of Critical Care Medicine*. Doi:10.5005/jp-journals-10071-23304.

- [32]. Scheepers, L. D., Freercks, R., & van der Merwe, E. (2023). Acute Cypermethrin and Other Pyrethroid Poisoning—An Organophosphate-Like Poisoning: A Case Report and Review. *Toxicology Reports*, 11, 107-110. Doi:10.1016/j.toxrep.2023.06.013.
- [33]. Aggarwal, P., Jamshed, N., Ekka, M., & Imran, A. (2015). Suicidal Poisoning with Cypermethrin: A Clinical Dilemma in the Emergency Department. *Journal of Emergencies, Trauma, and Shock*, 8(2), 123-125. Doi:10.4103/0974-2700.145424.
- [34]. Atashi, H. A., Arani, H. Z., Ghorani, S. M., Khorasani, M. S. T., & Moalem, M. (2022). Cardiac and Respiratory Arrest in a 12-Year-Old Girl with Acute Permethrin Toxicity: A Case Report. Doi:10.21203/rs.3.rs-305921/v2.
- [35]. Araújo, M. F., Castanheira, E. M., & Sousa, S. F. (2023). The Buzz on Insecticides: A Review of Uses, Molecular Structures, Targets, Adverse Effects, and Alternatives. *Molecules*, 28(8), 3641. Doi:10.3390/molecules28083641.
- [36]. Huang, X., Zhang, C., Hu, R., Li, Y., Yin, Y., Chen, Z., et al. (2016). Association Between Occupational Exposures to Pesticides with Heterogeneous Chemical Structures and Farmer Health in China. *Scientific Reports*, 6(1), 25190. Doi: 10.1038/srep25190.
- [37]. Zakharov, S., Csomor, J., Urbanek, P., & Pelclova, D. (2016). Toxic Epidermal Necrolysis After Exposure to Dithiocarbamate Fungicide Mancozeb. *Basic & Clinical Pharmacology & Toxicology*, 118(1), 87-91. <https://doi.org/10.1038/srep25190>
- [38]. Romoli, J. C., Scarferla, D. T. P., Aguera, R. G., Lini, R. S., Pante, G. C., Bueno Junior, C. R., et al. (2022). Analytical and Toxicological Aspects of Dithiocarbamates: An Overview of the Last 10 Years. *Toxicology Mechanisms and Methods*, 32(9), 637-649. <https://doi.org/10.1080/15376516.2022.2063096>
- [39]. El-Wakeil, N. E. (2013). Botanical Pesticides and Their Mode of Action. *Gesunde Pflanzen*, 65(4). <https://doi.org/10.1007/s10343-013-0308-3>
- [40]. Ngegba, P. M., Cui, G., Khalid, M. Z., & Zhong, G. (2022). Use of Botanical Pesticides in Agriculture as an Alternative to Synthetic Pesticides. *Agriculture*, 12(5), 600. <https://doi.org/10.3390/agriculture12050600>
- [41]. Wood, D. M., Alshahaf, H., Streete, P., Dargan, P. I., & Jones, A. L. (2005). Fatality After Deliberate Ingestion of the Pesticide Rotenone: A Case Report. *Critical Care*, 9, 1-5. <https://doi.org/10.1186/cc3528>
- [42]. Gupta, P., & Verma, P. K. (2020). A Rare Cause of Methemoglobinemia: How Safe are So-called Biopesticide? *Indian Journal of Critical Care Medicine*, 24(3), 208. <https://doi.org/10.5005/jp-journals-10071-23373>
- [43]. Amrollahi-Sharifabadi, M., Seghatoleslami, A., Amrollahi-Sharifabadi, M., Bayani, F., & Mirjalili, M. (2013). Fatal Colchicine Poisoning by Accidental Ingestion of Colchicum Persicum: A Case Report. *American Journal of Forensic Medicine & Pathology*, 34(4), 295-298. <https://doi.org/10.1097/PAF.0000000000000059>
- [44]. Sahayaraj, K., & Hassan, E. (2023). Biocompatibility of Biopesticides with Predatory Insects. in *Worldwide Predatory Insects in Agroecosystems* (pp. 785-820). Singapore: Springer Nature Singapore. https://doi.org/10.1007/978-981-99-1000-7_21
- [45]. Egbuna, C., Sawicka, B., Tijjani, H., Kryeziu, T. L., Ifemeje, J. C., Skiba, D., et al. (2020). Biopesticides, Safety Issues and Market Trends. In *Natural Remedies for Pest, Disease and Weed Control* (pp. 43-53). Academic Press. <https://doi.org/10.1016/B978-0-12-819304-4.00004-X>
- [46]. Then, C., & Bauer-Panskus, A. (2017). Possible Health Impacts of Bt Toxins and Residues from Spraying with Complementary Herbicides in Genetically Engineered Soybeans and Risk Assessment as Performed by the European Food Safety Authority EFSA. *Environmental Sciences Europe*, 29, 1-11. <https://doi.org/10.1186/s12302-016-0099-0>
- [47]. Santos, V. S. V., & Pereira, B. B. (2020). Properties, Toxicity and Current Applications of The Biolarvicide Spinosad. *Journal of Toxicology and Environmental Health, Part B*, 23(1), 13-26. <https://doi.org/10.1080/10937404.2019.1689878>

- [48]. Su, T. Y., Lin, J. L., Lin-Tan, D. T., Tseng, H. H., & Yen, T. H. (2011). Human Poisoning with Spinosad and Flonicamid Insecticides. *Human & Experimental Toxicology*, 30(11), 1878-1881. <https://doi.org/10.1177/09603271114016>
- [49]. Zaynab, M., Fatima, M., Sharif, Y., Sughra, K., Sajid, M., Khan, K. A., . & Li, S. (2021). Health and Environmental Effects of Silent Killers Organochlorine Pesticides and Polychlorinated Biphenyl. *Journal of King Saud University-Science*, 33(6), 101511. <https://doi.org/10.1016/j.jksus.2021.101511>
- [50]. Calle, E. E., Frumkin, H., Henley, S. J., Savitz, D. A., & Thun, M. J. (2002). Organochlorines and Breast Cancer Risk. *CA: A Cancer Journal for Clinicians*, 52(5), 301-309. <https://doi.org/10.3322/canjclin.52.5.301>
- [51]. King, A. M., & Aaron, C. K. (2015). Organophosphate and Carbamate Poisoning. *Emergency Medicine Clinics*, 33(1), 133-151. <https://doi.org/10.1016/j.emc.2014.09.010>
- [52]. Gupta, R. C., & Milatovic, D. (2012). Toxicity of Organophosphates and Carbamates. <https://doi.org/10.1039/9781849733007-00104>
- [53]. Martín Reina, J., Duarte, J. A., Cerrillos, L., Bautista Palomas, J. D., & Moreno Navarro, I. M. (2017). Insecticide Reproductive Toxicity Profile: Organophosphate, Carbamate and Pyrethroids. *Journal of Toxins*, 4 (1), 1-7.
- [54]. Abdollahi, M., Ranjbar, A., Shadnia, S., Nikfar, S., & Rezaie, A. (2004). Pesticides and Oxidative Stress: A Review. *Med Sci Monit*, 10(6), 141-147.
- [55]. Eskenazi, B., Bradman, A., & Castorina, R. (1999). Exposures of Children to Organophosphate Pesticides and their Potential Adverse Health Effects. *Environmental Health Perspectives*, 107(suppl 3), 409-419. <https://doi.org/10.1289/ehp.99107s3409>
- [56]. Khursheed, A., Rather, M. A., Jain, V., Rasool, S., Nazir, R., Malik, N. A., & Majid, S. A. (2022). Plant Based Natural Products as Potential Ecofriendly and Safer Biopesticides: A Comprehensive Overview of their Advantages Over Conventional Pesticides, Limitations and Regulatory Aspects. *Microbial Pathogenesis*, 173, 105854. <https://doi.org/10.1016/j.micpath.2022.105854>