



HAL
open science

First head and neck radiotherapy planning based on MRI quantitative proton density images

Sayaque Laura, Leporq Benjamin, Pilleul Frank, Hamelin Olivier, Bouyer Charlène, Vincent Gregoire, Beuf Olivier

► To cite this version:

Sayaque Laura, Leporq Benjamin, Pilleul Frank, Hamelin Olivier, Bouyer Charlène, et al.. First head and neck radiotherapy planning based on MRI quantitative proton density images. ESTRO, May 2024, Glasgow, United Kingdom. hal-04628126

HAL Id: hal-04628126

<https://hal.science/hal-04628126>

Submitted on 28 Jun 2024

HAL is a multi-disciplinary open access archive for the deposit and dissemination of scientific research documents, whether they are published or not. The documents may come from teaching and research institutions in France or abroad, or from public or private research centers.

L'archive ouverte pluridisciplinaire **HAL**, est destinée au dépôt et à la diffusion de documents scientifiques de niveau recherche, publiés ou non, émanant des établissements d'enseignement et de recherche français ou étrangers, des laboratoires publics ou privés.

Head and neck MRI for radiotherapy

In radiotherapy of the head and neck, MRI is of great interest due to the high contrast between soft tissues, offering an easier depiction of tumor volumes and organs at risk. The lack of information on electron density requires the generation of a synthetic CT (sCT), and classical methods have limitations in this complicated area such as the need for a lot of data, the wide variety of morphologies and the high number of organs at risk.

UTE sequence for proton density quantification

Demol et al.¹ proposed to perform the dose planning based on the knowledge of the hydrogen content of the tissues. Since MRI is based on the resonance properties of the proton, specific sequences² allow direct proton density³ measurement.

The UTE spiralVIBE sequence allows a very short echo time, which gives access to the magnetization at the origin, considering the short T2-species such as cortical bone. The MR images are subject to the receiver coil non uniformities, several algorithms were assessed to correct it.

Dosimetry was performed for 25 patients from a reference CT and on the sCT, dose for 2 percent of the volume of the organs at risk and the median dose of the tumor volumes were computed.

Coils sensitivity correction in MRI

2 in-line and 3 off-line algorithms were tested for coils sensitivity correction. The results of the experiments performed on a phantom are shown in figure 1.

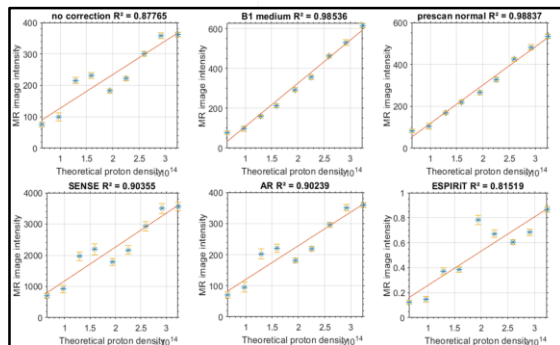


Figure 1. Linear regression between theoretical and experimental proton density, without coil sensitivity correction and with 5 different algorithms.

Comparison of the dosimetry results on CT and sCT

Figure 2 shows axial slice of the sCT and the corresponding CT for a male patient with a larynx tumor, with the superimposed dose planning. Figure 3 gives detailed results of the dose-volume histogram: CT corresponds to dose resulting from the CT-based dosimetry and sCT corresponds to the dose resulting from the proton density-based sCT dosimetry. The organ POST corresponds to the area containing the cervical spinal cord and the base of the neck.

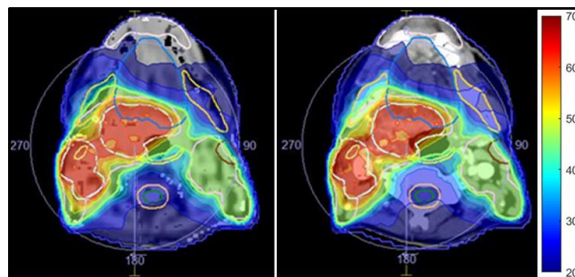


Figure 2. Dosimetry on the CT (top) and the sCT images (bottom) for a patient with laryngeal cancer; doses range from 20 (blue) to 70 (red) Gray.

Organs	D ₂ (in Gy)	CT (in Gy)	sCT (in Gy)
Brainstem	54	18.8	18.7
Lips	30	27.3	28.1
POST	30	29.9	30.2
Spinal cord	45	32.5	32.6
Trachea	80	47.6	47.0
Target volumes	D _{med} (in Gy)	CT (in Gy)	sCT (in Gy)
PTV BR	54.25	60.3	60.2
PTV HR	70	70.4	70.2

Figure 3. Doses for OARs (dose for 2 percent of the volume) and tumor volumes (dose for 50 percent of the volume) for the CT-based and the sCT-based dosimetry.

A new approach for a difficult area

Our work demonstrated for the first time that PD quantification assessed by MRI could be used for radiotherapy planning. This work focuses on the head and neck area. Due to the large number of OARs (brainstem, optic nerves...) in this region and the large field of view required (from the top of the head to the upper part of the humerus), it has not been much explored in the literature. The encouraging results obtained on this first patient need to be confirmed with more patients.

Acknowledgments

LabEx PRIMES (ANR-11-LABX-0063), LyRICan (INCa-DGOS-INSERM-ITMO cancer 1803) and HERESP ANR (ANR-22-CE19-0027-01).

References

- Demol B et al. Monte Carlo calculation based on hydrogen composition of the tissue for MV photon radiotherapy. J Appl Clin Med Phys. 2015;16(5):117-130. doi:10.1120/jacmp.v16i5.5586
- Largent A et al. Head-and-Neck MRI-only radiotherapy treatment planning: From acquisition in treatment position to pseudo-CT generation. Cancer/Radiothérapie. 2020;24(4):288-297. doi:10.1016/j.canrad.2020.01.008
- Mezer A et al. Evaluating quantitative proton-density-mapping methods: Proton-Density Mapping. Hum Brain Mapp. 2016;37(10):3623-3635. doi:10.1002/hbm.23264