



HAL
open science

A call for evidence in connective tissue diseases-associated interstitial lung disease

Vincent Cottin, Jean-Christophe Lega, Fabienne Coury, Mouhamad Nasser

► To cite this version:

Vincent Cottin, Jean-Christophe Lega, Fabienne Coury, Mouhamad Nasser. A call for evidence in connective tissue diseases-associated interstitial lung disease. *Joint Bone Spine*, 2022, 89 (1), pp.105274. 10.1016/j.jbspin.2021.105274 . hal-04627774

HAL Id: hal-04627774

<https://hal.science/hal-04627774v1>

Submitted on 16 Jul 2024

HAL is a multi-disciplinary open access archive for the deposit and dissemination of scientific research documents, whether they are published or not. The documents may come from teaching and research institutions in France or abroad, or from public or private research centers.

L'archive ouverte pluridisciplinaire **HAL**, est destinée au dépôt et à la diffusion de documents scientifiques de niveau recherche, publiés ou non, émanant des établissements d'enseignement et de recherche français ou étrangers, des laboratoires publics ou privés.

A call for evidence in connective tissue diseases-associated interstitial lung disease

ARTICLE INFO

Keywords:

Sjogren disease
Interstitial Lung Disease
Pulmonary fibrosis
Guidelines
Recommendations
Evidence

Interstitial lung diseases (ILD) encompass a large number of conditions, with a wide range of causes, clinical manifestations, and imaging and pathological features. Most of the ILDs share pathologic abnormalities predominating in the lung interstitium, which is infiltrated by various combinations of inflammatory cells and fibrosis. Despite the intrinsic heterogeneity of this group of diseases, a large proportion of ILDs are *fibrotic* [1], i.e. associated with excessive deposition in the lung interstitium of extracellular matrix. Fibrotic ILDs may be limited to the lung as in idiopathic pulmonary fibrosis, or may occur in the context of underlying systemic disease especially sarcoidosis and connective tissue disease (CTD). Sarcoidosis-associated ILDs, CTD-ILD, and idiopathic pulmonary fibrosis are the most common fibrotic ILDs, with an estimated prevalence of 30.2, 12.1, and 8.2 cases per 100,000, respectively [2].

Idiopathic pulmonary fibrosis, the archetypal fibrotic ILD, is a chronic and irreversible disease progressing to respiratory failure and death within a median of 3 years [3]. In contrast, many fibrotic ILDs associated with CTD are stable or indolent chronic diseases, or improve with treatment. However, a proportion of patients with CTD-ILD will experience progressive disease despite management considered appropriate to the underlying systemic disease, that usually includes immunomodulatory therapy. This so-called progressive fibrosing phenotype of ILD leads to worsening respiratory symptoms (exertional dyspnea, cough and exercise limitation), decline in lung function, decreased quality of life, and increased risk of mortality [4–6]. It corresponds to an exaggerated cascade of fibrotic tissue remodeling and extracellular matrix deposition, comparable to abnormal wound repair [7]. In CTD-ILD, chronic inflammation and vasculopathy resulting from auto-immunity play a key role in the initiation of fibrogenesis, in the context of environmental, genetic and epigenetic risk factors [7]. The later phase of fibrogenesis, shared by other fibrotic ILDs, consists of extracellular matrix production by fibroblasts, self-perpetuating lung tissue

remodeling and microscopic honeycombing, with various imaging and pathologic phenotypes of fibrosis.

All patients with CTD are at risk of developing ILD with various phenotypes, most frequently in the setting of an established CTD. ILD can also be the first clinically apparent manifestation of occult CTD. Clinically relevant ILD manifests in approximately 30–40% of patients with systemic sclerosis, idiopathic inflammatory myositis, or Sjögren disease [8], and in ~10% of those with rheumatoid arthritis or systemic lupus erythematosus [9]. By definition, fibrotic ILD is also present in all patients with the research definition of interstitial pneumonia with autoimmune features (IPAF), a term coined to designate cases with ILD and autoimmune features, but who do not fulfill the diagnostic criteria for a definite CTD [10,11]. Among CTD-ILDs, the proportion of those at risk of a progressive fibrosing phenotype is not known precisely, and was estimated to 40% of those with systemic sclerosis-ILD [12], 32% of those with rheumatoid arthritis-ILD [13], and 16% of those with idiopathic inflammatory myositis [14]. Only estimates based on interviews and surveys of physicians are available for ILD associated with Sjögren disease, systemic lupus erythematosus and mixed CTD [15].

The evidence available varies greatly from one CTD-ILD to another. In systemic sclerosis-ILD, consensus guidelines are available, active clinical research is being conducted, and drugs have been approved: nintedanib is licensed in many countries for the treatment of SSc-ILD and chronic fibrosing ILDs with a progressive phenotype in adults, and tocilizumab is licensed in U.S.A. for slowing the rate of decline in pulmonary function in adult patients with SSc-ILD. To some extent, rheumatoid arthritis-ILD has been recently the focus of increased attention [16], with landmark studies that have characterized the pattern of usual interstitial pneumonia (UIP) as the predominant pattern on CT, associated with an increased risk of mortality [17–19]. In sharp contrast, other CTD-ILDs have infrequently been the focus of dedicated, prospective studies. Only a few observational small-size studies have been dedicated to chronic ILD associated with mixed CTD or systemic lupus erythematosus.

Sjögren disease is the second common CTD. ILD associated to Sjögren disease is associated to increased mortality [20]. Fatal acute exacerbation of ILD can occur [21]. A recent systematic review of the literature identified a critical need for early diagnosis and improve quality and consistency of care [22]. In small series, up to two thirds of patients without pulmonary symptoms have abnormalities on chest CT [23]. Conversely, Sjögren disease may be limited and detected only by systematic salivary gland biopsy in patients with ILD [24]. Aside from ILD, patients with Sjögren

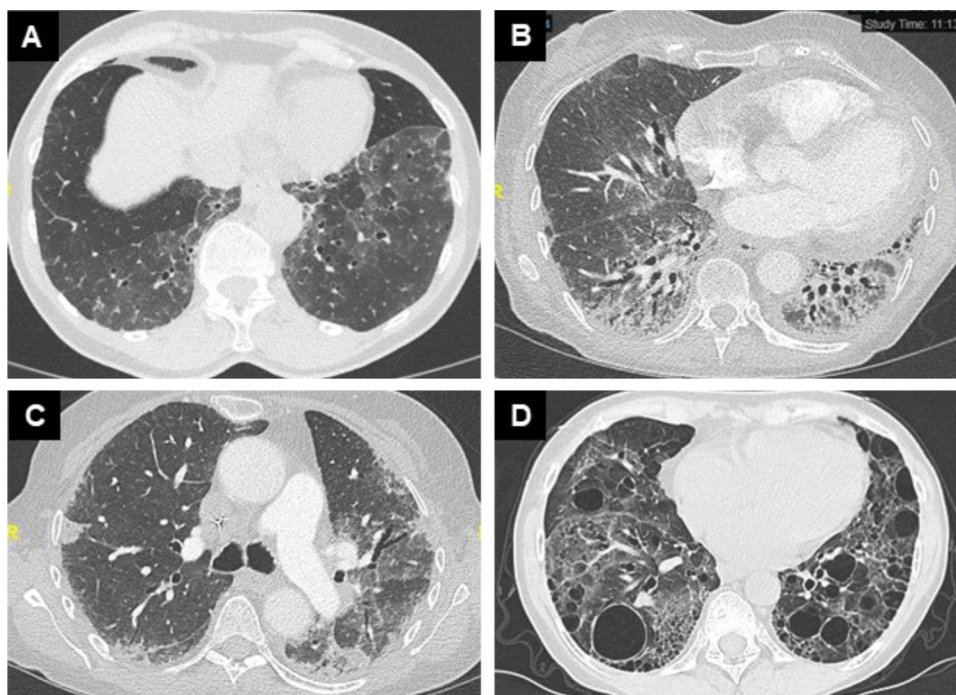


Fig. 1. Chest CT (axial view, parenchymal window) of patients with Sjögren disease-associated ILD, with patterns of nonspecific interstitial pneumonia pneumonia (confirmed by histopathology) (A), fibrotic nonspecific interstitial pneumonia (B), organising pneumonia (C), and lymphoid interstitial pneumonia (D).

disease may have cystic lung disease, amyloidosis, or develop B-cell pulmonary lymphoma [22,25]. Despite the high prevalence of pulmonary abnormalities in subjects with Sjögren disease, available data are limited to small series in academic pulmonology or radiology centres [21,23,26–34], most of them antedating the current classification and description of interstitial pneumonias [35]. One further complexity in Sjögren disease is represented by the common admixture of ILD with small airways disease [33], as in rheumatoid arthritis [16].

In a previous issue of *Joint Bone Spine*, Manfredi et al. [36] report on a cross-sectional study of consecutive patients with Sjögren disease with a new or previous diagnosis of ILD at CT. Imaging patterns were analysed according to current criteria and assessed for the presence of a fibrotic pattern. Out of 34 patients with ILD, 18 (53%) had a fibrotic pattern, including imaging patterns of UIP, fibrotic nonspecific interstitial pneumonia, and fibrotic organizing pneumonia. Lymphoid interstitial pneumonia and respiratory bronchiolitis-ILD were not observed. Patients who had a fibrotic pattern on CT were younger and had a shorter duration of Sjögren disease as compared to those with a non-fibrotic pattern at imaging, suggesting that ILD may later have an impact on outcome and quality of life. Patients were seen by a multidisciplinary team but, as expected, patients referred by pulmonologists had more frequently lung-dominant disease and less frequent systemic manifestations. No difference was observed by treatment received, but the sample size and the design did not allow to assess whether prior immunosuppressive therapy may have an effect on the risk of developing fibrotic ILD.









These findings are informative, as they confirm the variety of ILD patterns associated with Sjögren disease (Fig. 1). About half of patients had a fibrotic pattern on CT, and were at risk of disease progression. These subjects need to have pulmonary function tests (including spirometry, lung volumes, and diffusing capacity of the lung for carbon monoxide [DLco]) [22] and to have a proper evaluation and monitoring by a pulmonologist with expertise in ILD. The study was limited by its retrospective design and relatively small sample size. It is also important to emphasize that, apart from

the UIP pattern, the diagnostic accuracy of the imaging pattern to predict histopathology is generally poor. Classification of patterns based on imaging alone must therefore be interpreted with caution. In rheumatoid arthritis-ILD, however, the UIP pattern [17–19] and the extent of ILD on HRCT [18] are associated with an increased risk of mortality; in systemic sclerosis-ILD, the extent of disease (but not the pattern) is associated with mortality [37], supporting the concept that the chest CT helps predicting the outcome in subjects with CTD-ILD. Whether this is also true in Sjögren disease-ILD remains to be studied.

As is often the case, this study leaves us with more questions than answers: how to separate which cases will have an indolent course from those which can be progressive and portend a worse prognosis? Can the risk of a poor outcome of Sjögren disease-ILD be predicted by the pattern and the extent of disease on CT, by baseline lung function, and/or by decline in serial lung function tests over 6–12 months? Does immunomodulatory therapy have any effect on the risk of onset of ILD or on its outcome in subjects with Sjögren disease? What is the proportion of those with fibrotic ILD who will experience a progressive phenotype despite appropriate management? These topics are open to research.

The consensus guidelines from European League Against Rheumatism (EULAR) and American College of Chest Physicians (ACCP) are now available for the detection, diagnosis and management of lung disease associated with Sjögren disease [22,38]. One key recommendation is to perform a two-view chest radiograph and full pulmonary function tests in any patient with Sjögren disease, and a baseline chest CT in those with pulmonary symptoms or abnormal pulmonary function or chest radiograph [22]. The recommendations of ACCP were made in favor of moderate doses of glucocorticoids and of immunosuppressive drugs to treat Sjögren disease-ILD [22]. According to the EULAR guidelines, glucocorticoids at 0.5 mg/kg/day were indicated in moderate forms of Sjögren disease-ILD, especially for lymphocytic interstitial pneumonitis, organising pneumonia, and nonspecific interstitial pneumonia pneumonia. In severe forms, oral immunosuppressive drugs (mainly azathioprine, mycophenolate, and cyclosporine)

	All CTD-ILDs*	SSc-ILD	RA-ILD	MCTD-ILD	IIM-ILD	SjS-ILD	SLE-ILD
Glucocorticoids ¹⁻³							
Cyclophosphamide ⁴⁻⁷							
MMF ^{2,8-11}							
Tocilizumab ^{12,13}							
Azathioprine ^{7,14,15}							
Nintedanib ¹⁶⁻¹⁸							
Pirfenidone ¹⁹							
Lung transplant ^{20,21}							
Stem cell transplant ^{6,22-24}							

Evidence available	
	RCT, placebo-controlled, positive primary endpoint. Licensed by regulatory authorities in this indication
	RCT, positive primary endpoint but safety profile limitations or not positive primary endpoint but finding suggestive of effect, or not licenced in the indication
	RCT positive primary endpoint but safety profile limitations or trial prematurely terminated (futility) or not positive primary endpoint but findings suggestive of effect or long-term experiences, retrospective studies, and small-scale case series or case reports
	Observational or small trials with positive primary endpoints
	No evidence / very limited evidence
	Some evidence of safety profile limitations
	Evidence of limitations on safety in this population
	Not recommended

1. Iudici M, et al. <i>Clin Rheumatol</i> 2016; 35(8): 1985-91.
2. Barba T, et al. <i>Autoimmun Rev</i> 2019; 18(2): 113-22.
3. Maher TM, et al. 2019; 36(7): 1518-31.
4. Tashkin DP, et al. <i>N Engl J Med</i> 2006; 354(25): 2655-66.
5. Hoyles RK, et al. <i>Arthritis Rheum</i> 2006; 54(12): 3962-70.
6. Kowal-Bielecka O, et al. <i>Ann Rheum Dis</i> 2017; 76(8): 1327-39.
7. Berezne A, et al. <i>J Rheumatol</i> 2008; 35(6): 1064-72.
8. Mathai SC, et al. <i>BMJ</i> 2016; 352: h6819.
9. Highland KB, et al. <i>Lancet Respir Med</i> 2021; 9(1): 96-106.
10. Tashkin DP, et al. <i>Lancet Respir Med</i> 2016; 4(9): 708-19.
11. Volkmann ER, et al. <i>Arthritis Rheumatol</i> 2017; 69(7): 1451-60.
12. Khanna D, et al. <i>Lancet</i> 2016; 387(10038): 2630-40.
13. Khanna D, et al. <i>Lancet Respir Med</i> 2020; 8(10): 963-74.
14. Paone C, et al. <i>Clin Exp Rheumatol</i> 2007; 25(4): 613-6.
15. Huapaya JA, et al. <i>Chest</i> 2019.
16. Distler O, et al. <i>N Engl J Med</i> 2019; 380(26): 2518-28.
17. Flaherty KR, et al. <i>N Engl J Med</i> 2019; 381(18): 1718-27.
18. Wells AU, et al. <i>Lancet Respir Med</i> 2020; 8(5): 453-60.
19. Behr J, et al. <i>Lancet Respir Med</i> 2021; 9(5): 476-86.
20. Weill D, et al. <i>J Heart Lung Transplant</i> 2015; 34(1): 1-15.
21. Pradère P, et al. <i>J Heart Lung Transplant</i> 2018; 37(7): 903-11.
22. van Laar JM, et al. <i>JAMA</i> 2014; 311(24): 2490-8.
23. Sullivan KM, et al. <i>N Engl J Med</i> 2018; 378(1): 35-47.
24. Sullivan KM, et al. <i>Biol Blood Marrow Transplant</i> 2018; 24(10): 1961-4.

Fig. 2. Summary of evidence available for the management of CTD-ILD. *Fibrotic ILDs with a progressive phenotype. CTD: connective tissue disease; ILD: interstitial lung disease, IIM: idiopathic inflammatory myositis; MCTD: mixed connective tissue disease; SjS: Sjögren syndrome; SLE: systemic lupus erythematosus; SSc: systemic sclerosis.

could be added in case of failure of high dose of glucocorticoids (i.e. 0.5–1 mg/kg/day). Rituximab and cyclophosphamide were proposed as rescue treatments [38]. Notably, very little evidence is available in support of immunomodulation to treat CTD-ILD apart from ILD associated with systemic sclerosis (Fig. 2). The two guidelines were based on expert opinion and on extrapolation of guidelines and literature on ILD in CTDs other than Sjögren disease.

To identify patients with ILD who have a progressive fibrosing phenotype despite appropriate treatment (often immunomodulation) is key, as the outcome may be similar to that of idiopathic

pulmonary fibrosis [39]. Patients with ILD and a progressive fibrosing phenotype have a poor outcome, regardless of the underlying entity [40–43], especially those with a pattern of UIP. Identifying the progressive fibrosing phenotype requires individual monitoring of ILD, with regular clinical evaluation, serial lung function performed at 3-to-6-month intervals, and chest CT repeated if necessary. Although there is no standard definition of disease progression in patients with fibrotic ILD, the assessment is usually multimodal and based on a combination of worsening lung function especially forced vital capacity, worsening respiratory symptoms,

and/or increase in disease extent on chest CT [6]. Recently, the antifibrotic drugs nintedanib and pirfenidone were demonstrated to slow down disease progression in patients with chronic fibrosing ILD and a progressive phenotype [44,45] regardless of the underlying specific disease and including patients with CTD-ILD [43]. The fact that this condition is amenable to antifibrotic therapy reinforces the need to monitor CTD-ILD and to identify subjects with a progressive fibrosing phenotype.

Time has come to increase our knowledge in CTD-ILD and to raise the level of evidence in the various conditions composing this group, especially for those CTDs that have been less studied so far and can be considered “orphan”, such as ILD associated to Sjögren disease, mixed CTD, and systemic lupus erythematosus. We herein call for arms to 1- constitute prospective collaborative registries of consecutive patients with CTD-ILD to study their variety of history of progression and clinical-imaging correlations; 2- and to design randomized trials assessing the efficacy and safety of treatment approaches, comparing or combining immunosuppressive versus antifibrotic therapy.

Disclosure of interest

Dr. Cottin reports grants, personal fees and non-financial support from Boehringer Ingelheim, personal fees and non-financial support from Actelion and Roche/Promedior, personal fees from Astra Zeneca, Bayer/MSD, Celgene/BMS, Fibrogen, Galapagos, Galecto, PureTech, RedX, Sanofi and Shionogi, outside the submitted work.

Dr. Lega declares that he has no competing interest.

Dr. Coury declares that she has no competing interest.

Dr. Nasser declares that he has no competing interest.

Acknowledgements

We thank Amiculum (United Kingdom) for their help in formatting Figure 2.

References

- Wijsenbeek M, Cottin V. Spectrum of Fibrotic Lung Diseases. *N Engl J Med* 2020;383:958–68.
- Duchemann B, Annesi-Maesano I, Jacobe de Naurois C, et al. Prevalence and incidence of interstitial lung diseases in a multi-ethnic county of Greater Paris. *Eur Respir J* 2017;50:1602419.
- Lederer DJ, Martinez FJ. Idiopathic Pulmonary Fibrosis. *N Engl J Med* 2018;378:1811–23.
- Cottin V, Hirani NA, Hotchkiss DL, et al. Presentation, diagnosis and clinical course of the spectrum of progressive-fibrosing interstitial lung diseases. *Eur Respir Rev* 2018;27.
- Cottin V, Wollin L, Fischer A, et al. Fibrosing interstitial lung diseases: knowns and unknowns. *Eur Respir Rev* 2019;28.
- George PM, Spagnolo P, Kreuter M, et al. Progressive fibrosing interstitial lung disease: clinical uncertainties, consensus recommendations, and research priorities. *Lancet Respir Med* 2020;8:925–34.
- Distler JHW, Gyorfi AH, Ramanujam M, et al. Shared and distinct mechanisms of fibrosis. *Nat Rev Rheumatol* 2019;15:705–30.
- Lin DF, Yan SM, Zhao Y, et al. Clinical and prognostic characteristics of 573 cases of primary Sjögren's syndrome. *Chin Med J (Engl)* 2010;123:3252–7.
- Fischer A, Streck ME, Cottin V, et al. Proceedings of the American College of Rheumatology/Association of physicians of Great Britain and Ireland connective tissue disease-associated interstitial lung disease summit: a multidisciplinary approach to address challenges and opportunities. *Arthritis Rheumatol* 2019;71:182–95.
- Fischer A, Antoniou KM, Brown KK, et al. An official European Respiratory Society/American Thoracic Society research statement: interstitial pneumonia with autoimmune features. *Eur Respir J* 2015;46:976–87.
- Fernandes L, Nasser M, Ahmad K, et al. Interstitial pneumonia with autoimmune features (IPAF). *Front Med (Lausanne)* 2019;6:209.
- Hoffmann-Vold AM, Aalokken TM, Lund MB, et al. Predictive value of serial high-resolution computed tomography analyses and concurrent lung function tests in systemic sclerosis. *Arthritis Rheumatol* 2015;67:2205–12.
- Zamora-Legoff JA, Krause ML, Crowson CS, et al. Progressive decline of lung function in rheumatoid arthritis-associated interstitial lung disease. *Arthritis Rheumatol* 2017;69:542–9.
- Marie I, Hatron PY, Dominique S, et al. Short-term and long-term outcomes of interstitial lung disease in polymyositis and dermatomyositis: a series of 107 patients. *Arthritis Rheum* 2011;63:3439–47.
- Olson A, Hartmann N, Patnaik P, et al. Estimation of the prevalence of progressive fibrosing interstitial lung diseases: systematic literature review and data from a physician survey. *Advances in therapy* 2021;38:854–67.
- Kadura S, Raghu G. Rheumatoid arthritis-interstitial lung disease: manifestations and current concepts in pathogenesis and management. *Eur Respir Rev* 2021;30.
- Solomon JJ, Chung JH, Cosgrove GP, et al. Predictors of mortality in rheumatoid arthritis-associated interstitial lung disease. *Eur Respir J* 2016;47:588–96.
- Jacob J, Hirani N, van Moersel CHM, et al. Predicting outcomes in rheumatoid arthritis related interstitial lung disease. *Eur Respir J* 2019;53.
- Kim EJ, Elicker BM, Maldonado F, et al. Usual interstitial pneumonia in rheumatoid arthritis-associated interstitial lung disease. *Eur Respir J* 2010;35:1322–8.
- Nannini C, Jebakumar AJ, Crowson CS, et al. Primary Sjogren's syndrome 1976–2005 and associated interstitial lung disease: a population-based study of incidence and mortality. *BMJ Open* 2013;3:e003569.
- Parambil JG, Myers JL, Lindell RM, et al. Interstitial lung disease in primary Sjogren syndrome. *Chest* 2006;130:1489–95.
- Lee AS, Scofield RH, Hammit KM, et al. Consensus guidelines for Evaluation and Management of Pulmonary Disease in Sjögren's. *Chest* 2021;159:683–98.
- Uffmann M, Kiener HP, Bankier AA, et al. Lung manifestation in asymptomatic patients with primary Sjögren syndrome: assessment with high resolution CT and pulmonary function tests. *J Thorac Imaging* 2001;16:282–9.
- Fischer A, Swigris JJ, du Bois RM, et al. Minor salivary gland biopsy to detect primary Sjogren syndrome in patients with interstitial lung disease. *Chest* 2009;136:1072–8.
- Mariette X, Criswell LA. Primary Sjögren's Syndrome. *N Engl J Med* 2018;378:931–9.
- Deheinzeln D, Capelozzi VL, Kairalla RA, et al. Interstitial lung disease in primary Sjogren's syndrome. Clinical-pathological evaluation and response to treatment. *Am J Respir Crit Care Med* 1996;154:794–9.
- Gardiner P, Ward C, Allison A, et al. Pleuropulmonary abnormalities in primary Sjögren's syndrome. *J Rheumatol* 1993;20:831–7.
- Shi JH, Liu HR, Xu WB, et al. Pulmonary manifestations of Sjogren's syndrome. *Respiration* 2009;78:377–86.
- Franquet T, Gimenez A, Monill JM, et al. Primary Sjögren's syndrome associated lung disease: C.T. findings in 50 patients. *AJR* 1997;169:655–8.
- Lohrmann C, Uhl M, Warnatz K, et al. imaging of the lung for patients with primary Sjogren's syndrome. *Eur J Radiol* 2004;52:137–43.
- Ito I, Nagai S, Kitaichi M, et al. Pulmonary manifestations of primary Sjogren's syndrome: a clinical, radiologic, and pathologic study. *Am J Respir Crit Care Med* 2005;171:632–8.
- Enomoto Y, Takemura T, Hagiwara E, et al. Prognostic factors in interstitial lung disease associated with primary Sjögren's syndrome: a retrospective analysis of 33 pathologically-proven cases. *PLoS One* 2013;8:e73774.
- Kampolis CF, Fragkioudaki S, Mavragani CP, et al. Prevalence and spectrum of symptomatic pulmonary involvement in primary Sjögren's syndrome. *Clin Exp Rheumatol* 2018;36 Suppl(112):94–101.
- Manfredi A, Sebastiani M, Cerri S, et al. Prevalence and characterization of non-sicca onset primary Sjögren syndrome with interstitial lung involvement. *Clin Rheumatol* 2017;36:1261–8.
- Travis WD, Costabel U, Hansell DM, et al. An official American Thoracic Society/European Respiratory Society statement: Update of the international multidisciplinary classification of the idiopathic interstitial pneumonias. *Am J Respir Crit Care Med* 2013;188:733–48.
- Manfredi A, Vacchi C, Della Casa G, et al. Fibrosing interstitial lung disease in primary Sjögren syndrome. *Joint Bone Spine* 2021;88:105237.
- Goh NS, Desai SR, Veeraraghavan S, et al. Interstitial lung disease in systemic sclerosis: a simple staging system. *Am J Respir Crit Care Med* 2008;177:1248–54.
- Ramos-Casals M, Brito-Zerón P, Bombardieri S, et al. EULAR recommendations for the management of Sjögren's syndrome with topical and systemic therapies. *Ann Rheum Dis* 2020;79:3–18.
- Brown KK, Martinez FJ, Walsh SLF, et al. The natural history of progressive fibrosing interstitial lung diseases. *Eur Respir J* 2020;55.
- Nasser M, Larrieu S, Si-Mohamed S, et al. Progressive fibrosing interstitial lung disease: a clinical cohort (the PROGRESS study). *Eur Respir J* 2021;57.
- Faverio P, Piluso M, De Giacomo F, et al. Progressive fibrosing interstitial lung diseases: prevalence and characterization in two Italian referral centers. *Respiration* 2020;99:838–45.
- Nasser M, Larrieu S, Bousset L, et al. Estimates of epidemiology, mortality and disease burden associated with progressive fibrosing interstitial lung disease in France (the PROGRESS study). *Respir Res* 2021;22:162.
- Wells AU, Flaherty KR, Brown KK, et al. Nintedanib in patients with progressive fibrosing interstitial lung diseases-subgroup analyses by interstitial lung disease diagnosis in the INBUILD trial: a randomised, double-blind, placebo-controlled, parallel-group trial. *Lancet Respir Med* 2020;8:453–60.
- Flaherty KR, Wells AU, Cottin V, et al. Nintedanib in Progressive Fibrosing Interstitial Lung Diseases. *N Engl J Med* 2019;381:1718–27.
- Behr J, Prasse A, Kreuter M, et al. Pirfenidone in patients with progressive fibrotic interstitial lung diseases other than idiopathic pulmonary fibrosis (RELIEF): a double-blind, randomised, placebo-controlled, phase 2b trial. *Lancet Respir Med* 2021.

Vincent Cottin^{a,*}
Jean-Christophe Lega^{b,c}
Fabienne Coury^{d,e}
Mouhamad Nasser^a

^a National Reference Centre for Rare Pulmonary Diseases, Louis Pradel Hospital, Hospices Civils de Lyon, IVPC, INRAE, Claude Bernard University Lyon 1, member of ERN-LUNG, 28, avenue Doyen Lepine, 69677 Lyon cedex, France

^b University of Lyon, UMR 5558, Laboratoire de Biométrie et Biologie Evolutive, CNRS, 69100 Villeurbanne, France

^c Department of Internal and Vascular Medicine, Centre Hospitalier Lyon Sud, Hospices Civils de Lyon, 69310 Pierre-Bénite, France

^d Inserm UMR1033 LYOS, University of Lyon I, 69003 Lyon, France

^e Department of Rheumatology, Lyon Sud Hospital, 69310 Pierre-Bénite, France

* Corresponding author.

E-mail address: vincent.cottin@chu-lyon.fr
(V. Cottin)

Accepted 2 September 2021
Available online 15 September 2021