



HAL
open science

Biliary tract cancers: French national clinical practice guidelines for diagnosis, treatments and follow-up (TNCD, SNFGE, FFCD, UNICANCER, GERCOR, SFCD, SFED, AFEF, SFRO, SFP, SFR, ACABi, ACHBPT)

Gael S. Roth, Loic Verlingue, Matthieu Sarabi, Jean Frédéric Blanc, Emmanuel Boleslawski, Karim Boudjema, Anne Laure Bretagne-Bignon, Marine Camus-Duboc, Romain Coriat, Gilles Créhange, et al.

► To cite this version:

Gael S. Roth, Loic Verlingue, Matthieu Sarabi, Jean Frédéric Blanc, Emmanuel Boleslawski, et al.. Biliary tract cancers: French national clinical practice guidelines for diagnosis, treatments and follow-up (TNCD, SNFGE, FFCD, UNICANCER, GERCOR, SFCD, SFED, AFEF, SFRO, SFP, SFR, ACABi, ACHBPT). *European Journal of Cancer*, 2024, 202, pp.114000. 10.1016/j.ejca.2024.114000 . hal-04626861

HAL Id: hal-04626861

<https://hal.science/hal-04626861>

Submitted on 11 Jul 2024

HAL is a multi-disciplinary open access archive for the deposit and dissemination of scientific research documents, whether they are published or not. The documents may come from teaching and research institutions in France or abroad, or from public or private research centers.

L'archive ouverte pluridisciplinaire **HAL**, est destinée au dépôt et à la diffusion de documents scientifiques de niveau recherche, publiés ou non, émanant des établissements d'enseignement et de recherche français ou étrangers, des laboratoires publics ou privés.



Distributed under a Creative Commons Attribution - NonCommercial 4.0 International License

Biliary Tract Cancers: French National Clinical Practice Guidelines for diagnosis, treatments and follow-up (TNCD, SNFGE, FFCD, UNICANCER, GERCOR, SFCD, SFED, AFEF, SFRO, SFP, SFR, ACABi, ACHBPT).

Running Title: French clinical practice guidelines for biliary tract cancer.

Gael S Roth¹, Loic Verlingue^{2*}, Matthieu Sarabi^{3*}, Jean-Frédéric Blanc⁴, Emmanuel Boleslawski⁵, Karim Boudjema⁶, Anne-Laure Bretagne-Bignon⁷, Marine Camus-Duboc⁸, Romain Coriat⁹, Gilles Créhange¹⁰, Thierry De Baere¹¹, Christelle de la Fouchardière¹², Clarisse Dromain¹³, Julien Edeline¹⁴, Maximiliano Gelli¹⁵, Boris Guiu¹⁶, Samy Horn¹⁷, Valérie Laurent-Croise¹⁸, Côme Lepage¹⁹, Astrid Lièvre²⁰, Anthony Lopez²¹, Sylvain Manfredi¹⁹, Julie Meilleroux²², Cindy Neuzillet²³, Valérie Paradis²⁴, Frédéric Prat²⁵, Maxime Ronot²⁶, Olivier Rosmorduc²⁷, Antonio Sa Cunha²⁷, Olivier Soubrane²⁸, Anthony Turpin²⁹, Christophe Louvet³⁰, Olivier Bouché³¹, David Malka^{30#}

on behalf of the Thésaurus National de Cancérologie Digestive (TNCD) (Société Nationale Française de Gastroentérologie (SNFGE), Fédération Francophone de Cancérologie Digestive (FFCD), Fédération Nationale des Centres de Lutte Contre le Cancer (UNICANCER), Groupe Coopérateur multidisciplinaire en Oncologie (GERCOR), Société Française de Chirurgie Digestive (SFCD), Société Française d'Endoscopie Digestive (SFED), Association Française pour l'Etude du Foie (AFEF), Société Française de Radiothérapie Oncologique (SFRO), Société Française de Pathologie (SFP), Société Française de Radiologie (SFR), ACABi (Association pour l'étude des Cancers et Affections des voies Biliaires), ACHBPT (Association de Chirurgie Hépto-Bilio-Pancréatique et Transplantation).

*equivalently contributed

#corresponding author:

Dr David MALKA, Département d'Oncologie Médicale, Institut Mutualiste Montsouris, 42 Boulevard Jourdan – 75674 PARIS CEDEX 14. Telephone: +33 (0)1 56 61 62 41. Mail: david.malka@imm.fr

Affiliations:

1. Univ. Grenoble Alpes / Hepato-Gastroenterology and Digestive Oncology department, CHU Grenoble Alpes / Institute for Advanced Biosciences, CNRS UMR 5309-INSERM U1209, Grenoble, France
2. Medical Oncology Department, Centre Léon Bérard, 28 rue Laennec, Lyon, France
3. Gastroenterology Department, Hopital privé Jean Mermoz, 69008 Lyon, France
4. Digestive Oncology unit, CHU Bordeaux, Bordeaux, France

5. Univ. Lille, INSERM U1189, CHU Lille, Service de Chirurgie Digestive et Transplantations, Lille, France.
6. Département de chirurgie viscérale hépatobiliaire, CHU de Rennes, Rennes, France
7. Hépatogastroenterology, CHU Caen, France
8. Endoscopie digestive, Hôpital Saint-Antoine, AP-HP/Sorbonne Université, Paris France
9. Service de gastroentérologie, d'endoscopie et d'oncologie digestive, Hôpital Cochin, APHP, Paris, France.
10. Radiation Oncology Department. Paris/Saint-Cloud/Orsay, Institut Curie. PSL Research University, Paris, France.
11. Département de Radiologie Interventionnelle, Gustave Roussy, 94805, Villejuif, France.
12. Medical Oncology Department, Institut Paoli Calmette, Marseille, France
13. Service de radiodiagnostic et radiologie interventionnelle, Centre hospitalier universitaire vaudois, Switzerland
14. Medical Oncology, Centre Eugene Marquis, Rennes, France
15. Département de Chirurgie Viscérale, Gustave Roussy, 94805, Villejuif, France.
16. Department of Radiology, St-Eloi University Hospital – Montpellier School of Medicine, Montpellier, France
17. Department of Radiation Oncology, Centre Hospitalier Lyon Sud, Pierre Benite, France
18. Department of Radiology, Centre Hospitalier Universitaire de Nancy, Hôpital de Brabois, 54500 Vandœuvre-lès-Nancy, France.
19. Université de Bourgogne, CHU Dijon-Bourgogne, INSERM U1231. BP 87 900, 14 rue Paul Gaffarel, 21079 Dijon, France
20. Department of Gastroenterology, Rennes University Hospital, University of Rennes 1, INSERM Unité 1242, Rennes, France
21. Department of Hepatology and Gastroenterology, Nancy University Hospital, University of Lorraine, 54500 Vandœuvre-lès-Nancy, France; INSERM U1256, NGERE, Faculty of Medicine, University of Lorraine, 54500 Vandœuvre-lès-Nancy, France.
22. Pathology and Cytology Department, CHU Toulouse, IUCT Oncopole, Toulouse Cedex 9, France.
23. GI Oncology, Department of Medical Oncology, Institut Curie - Site Saint Cloud, Versailles Saint-Quentin University, Paris Saclay University, Saint-Cloud, France
24. Université Paris Cité, APHP.Nord Sce d'Anatomie pathologique Hôpital Beaujon, Clichy, INSERM UMR 1149, France
25. Endoscopie digestive, Hôpital Beaujon, Clichy, France
26. Department of Medical Imaging, Beaujon University Hospital, Clichy, France.
27. AP-HP Hôpital Paul-Brousse, Centre Hépatobiliaire, INSERM U1193, Université Paris-Saclay, FHU Hépatinov, France

28. Department of Digestive Surgery, Institut Mutualiste Montsouris, Paris, France.
29. Department of Medical Oncology, CNRS UMR9020, Inserm UMR-S 1277-Canther-Cancer Heterogeneity, Plasticity and Resistance to Therapies, University Lille, CHU Lille, Lille; GERCOR, Paris, France
30. Department of Medical Oncology, Institute Mutualiste Montsouris, Paris, France.
31. Gastroenterology and Digestive Oncology Department, Robert-Debré University Hospital, Reims, France

Data availability statement: N/A

Funding statement: none

Ethics approval statement: N/A

Patient consent statement: N/A

Permission to reproduce material from other sources: N/A

Clinical trial registration: N/A

- **Main text: 5772 words**
- **Tables/Figures : 4 tables, 3 figures, 2 supplementary tables**
- **References: 161**

Abstract

Introduction: This document is a summary of the French intergroup guidelines of the management of biliary tract cancers (BTC) (intrahepatic, perihilar and distal cholangiocarcinomas, and gallbladder carcinomas) published in September 2023, available on the website of the French Society of Gastroenterology (SNFGE) (www.tncd.org).

Methods: This collaborative work was conducted under the auspices of French medical and surgical societies involved in the management of BTC. Recommendations were graded in three categories (A, B and C) according to the level of scientific evidence until August 2023.

Results: BTC diagnosis and staging is mainly based on enhanced computed tomography, magnetic resonance imaging and (endoscopic) ultrasound-guided biopsy. Treatment strategy depends on BTC subtype and disease stage. Surgery followed by adjuvant capecitabine is recommended for localised disease. No neoadjuvant treatment is validated to date. Cisplatin-gemcitabine chemotherapy combined to the anti-PD-L1 inhibitor durvalumab is the first-line standard of care for advanced disease. Early systematic tumour molecular profiling is recommended to screen for actionable alterations (*IDH1* mutations, *FGFR2* rearrangements, *HER2* amplification, *BRAF*^{V600E} mutation, MSI/dMMR status, etc.) and guide subsequent lines of treatment. In the absence of actionable alterations, FOLFOX chemotherapy is the only second-line standard-of-care. No third-line chemotherapy standard is validated to date.

Conclusion: These guidelines are intended to provide a personalised therapeutic strategy for daily clinical practice. Each individual BTC case should be discussed by a multidisciplinary team.

Keywords:

clinical practice guidelines, biliary tract cancer, cholangiocarcinoma, gallbladder carcinoma, surgery, chemotherapy, targeted therapy, immunotherapy.

Abbreviation list

18FDG-PET	18f-fluorodeoxyglucose positron emission tomography
5-FU	5-fluorouracil
BRAF	v-raf murine sarcoma viral oncogene homolog b
BSC	best supportive care
BTC	biliary tract cancers
CA	carbohydrate antigen
CAP	compassionate access programme
CBD	common bile duct
CCA	cholangiocarcinoma
CEA	carcinoembryonic antigen
CK	cytokeratin
CRP	c-reactive protein
CRT	chemoradiotherapy
dCCA	distal cholangiocarcinoma
dMMR	mismatch repair deficiency
EAP	early access programme
ECOG	Eastern cooperative oncology group
EMA	European medicines agency
ERC	endoscopic retrograde cholangiography
ESCAT	esmo scale for clinical actionability of molecular target
EUS	endoscopic ultrasonography
FDA	food and drug administration
FGFR2	fibroblast growth factor receptor 2
GBC	gallbladder carcinoma
HCC	hepatocellular carcinoma
HER2	human epidermal growth factor receptor 2

iCCA	intrahepatic cholangiocarcinoma
IDH1	isocitrate dehydrogenase 1
IHC	immuno-histochemistry
ISH	in situ hybridisation
KRAS	v-ki-ras2 Kirsten rat sarcoma viral oncogene homolog
MMR	mismatch repair
mOS	median OS
MRI	magnetic resonance imaging
MSI	microsatellite instability
NASH	non-alcoholic steatohepatitis
NGS	high-throughput sequencing
NSCLC	non small-cell lung cancer
NTRK	neurotrophic tyrosine receptor kinase
ORR	objective response rate
OS	overall survival
pCCA	perihilar cholangiocarcinoma
PCR	polymerase chain reaction
PDL-1	programmed cell death ligand-1
PFS	progression-free survival
PS	performance status
R1	microscopic invasion of the resection margins
R2	macroscopically incomplete resections
RET	rearranged during transfection
RFS	relapse-free survival
SBRT	stereotactic body radiation therapy
SIRT	selective internal radiation therapy
TACE	transarterial chemoembolisation

I. Introduction

A. Methodology

The present article is a summary of the French intergroup guidelines published in September 2023 (<http://www.tnkd.org>). These guidelines are a collaborative work written by a multidisciplinary committee (Thésaurus National de Cancérologie Digestive, TNCD) originating from 12 medical and surgical societies (SNFGE, FFCD, UNICANCER, GERCOR, SFCD, SFED, AFEF, SFRO, SFP, SFR, ACABi, ACHBPT) comprising experts from different specialties involved in the management of biliary tract cancers (BTCs) (oncologists, gastroenterologists, surgeons, pathologists, radiation oncologists and radiologists). These guidelines do not address ampullary carcinomas and combined hepato-cholangiocarcinomas, which are dealt with in dedicated chapters. The work is based on the extraction from the Medline database in August 2023 for randomised trials, meta-analyses, consensus conferences and recommendations for clinical practice with the keywords "biliary tract cancer", "gallbladder carcinoma" and "cholangiocarcinoma", in English or French, without date limitation.

Recommendations were graded according to the level of scientific evidence (from 'high' [e.g. several randomised controlled trials/meta-analysis] to 'very low' [expert opinion (agreement or not)]) following the French Health Authority guidelines (www.has-sante.fr) and scored according to the GRADE system (from A to D) (**Table 1**).

The document was reviewed and modified after further evaluation by a review committee followed by a final validation from the TNCD steering committee.

B. Epidemiology

BTCs include gallbladder carcinoma (GBC), cholangiocarcinoma (CCA) and ampullary adenocarcinoma. BTCs are uncommon cancers, with a worldwide estimated incidence of 2.1 in men and 2.4 in women per 100,000 person-years in 2018. Highest incidence areas are reported in Southeast Asia for CCA, and Northern India and Western South America for GBC [1,2]. In France, incidence was 2.1 in men (increase of 1.1%/year over the period 1990-2018) and 1.4 in women (decrease of 1.2%/year) in 2018, with incidence rates rising sharply from age 50 (median age at diagnosis, 72 years in men and 78 years in women) [3]. BTCs account for 2% of digestive cancers and 10-15% of primary liver cancers [4–6]. The main risk factors are cholelithiasis, biliary distomatoses (liver flukes) in Asia, chronic inflammatory diseases of bile ducts, metabolic syndrome with non-alcoholic steatohepatitis (NASH), tobacco consumption, hepatitis B and C virus chronic infections (relative risk: 5) and liver cirrhosis (relative risk: 20). In France as in other Western countries, the rise in incidence of intrahepatic cholangiocarcinoma (iCCA) – whereas the incidence of extrahepatic cholangiocarcinoma is stable – is likely mostly due to the increase of liver chronic diseases [7]. BTCs have a poor prognosis, which did not substantially improve over the past 30 years. In France, relative

survival rates at 1, 3 and 5 years after diagnosis (all stages) were estimated at 25%, 10% and 7%, respectively [5]. A recent analysis from the French nationwide database of the 3,650 patients with iCCA hospitalised in 2014 and 2015 in France showed that 65% of patients received only best supportive care at diagnosis [9].

II. Diagnosis and staging

A. Classification

The TNM-AJCC-UICC classification splits BTCs according to their location (**Figure 1**), into 1) CCA, subdivided in iCCA (10-20%), developed from second-order intrahepatic bile ducts, perihilar CCA (pCCA) (50%), developed from the right, left and/or common hepatic duct, and distal CCA (dCCA) (30-40%), developed from the common bile duct downstream the insertion of the cystic duct; 2) GBC; 3) ampullary adenocarcinoma [10]. TNM classifications and prognostic stages are detailed in **Supplementary Tables 1** and **2**.

The Bismuth-Corlette classification, based on the proximal level of tumour biliary extension, is used to assess the resectability of pCCA (**Figure 1**) [9]. However, it does not take into account vascular involvement, leading to underestimation of tumour invasion in 30% of cases. The XY classification distinguishes type X from type Y pCCA according to invasion or not of the confluence between left lateral ducts (B2 and B3) [11]. Type Y pCCAs are often resectable through extended right-sided hepatectomy, while type X is frequently associated with arterial invasion requiring complex vascular reconstructions (**Figure 1**).

B. Diagnosis and pre-treatment workup

While at early stages, diagnosis is often incidental, at advanced stages, the clinical presentation may include general health status deterioration, jaundice (especially for pCCA and dCCA), abdominal pain and hepatomegaly [12–14]. Recommended examinations at baseline, their indications and objectives are summarized in **Table 2**.

1. Imaging

Imaging is essential for diagnosis, staging and treatment decision. It determines the level of bile duct obstruction and the level of invasion of the liver, vessels, lymph nodes and distant sites.

Baseline explorations should include contrast-enhanced thoraco-abdomino-pelvic computed tomography (CT) for positive diagnosis and staging [15], contrast-enhanced liver magnetic

resonance imaging (MRI) in iCCA, and cholangio-MRI in pCCA/dCCA. CT and MRI should be performed before any biliary stent placement to optimally assess biliary extension [16,17]. Depending on the context, 18F-fluorodeoxyglucose positron emission tomography (¹⁸FDG-PET) for detection of potential extrahepatic lesions, and endoscopic ultrasonography (EUS) for locoregional staging and tissue sampling may be considered [18,19].

2. *Pathological diagnosis*

Percutaneous biopsy of both tumour tissue and non-tumour liver tissue is recommended in iCCA for positive diagnosis, molecular profiling, and assessment of an underlying chronic liver disease [20]. In pCCA/dCCA, samples are usually obtained through bile duct brushing, biopsies or bile aspiration during endoscopic retrograde cholangiography (ERC) when biliary drainage is needed, with sensitivities varying from 40% to 84%, or through fine needle aspiration during EUS [21–24]. After one or more ERC with negative samples, cholangioscopy should be considered, as well as IgG4 plasma level determination, especially in cases of indeterminate biliary strictures as cholangioscopy enables direct visualization of the biliary epithelium and targeted biopsies [25,26] with higher sensitivity than ERC-guided brushing (68.2% vs. 21.4%, $p < 0.01$) [27]. As up to 10–15% of resected pCCA strictures are eventually non-cancerous on pathological examination, pathological confirmation is essential before any treatment [28,29]; however, additional procedures should not delay treatment. Thus, if clinical and radiological presentation is typical, but cytopathological examination is only suspicious for cancer or remains negative after two attempts, surgery or palliative-intent treatment may be initiated after validation by a specialized multidisciplinary team (expert agreement). Molecular techniques (e.g., high-throughput sequencing [NGS], in situ hybridisation [ISH]) should be considered to improve chances of diagnosis (grade B).

3. *Serum biomarkers*

There are no circulating tumour markers specific to BTCs. Carbohydrate antigen (CA) 19.9 has a sensitivity and specificity of around 80% (studied mainly in primary sclerosing cholangitis) [30]. Carcinoembryonic antigen (CEA) and CA125 are less sensitive (30–50%) and no more specific [31]. All three markers may be elevated in benign biliary obstructions. Persistent elevation after effective biliary drainage is suggestive of cancer.

4. *Differential diagnosis*

The main differential diagnoses for iCCA are metastases from adenocarcinoma of another origin, hepatocellular carcinoma and hepatobiliary carcinoma. In case of doubt with liver metastases from a carcinoma of unknown primary or from a non-biliary origin, tumour immunohistochemistry (IHC) may be helpful for the diagnosis of CCA, which is typically cytokeratin (CK)7+, CK19+, CK20+/- . Colorectal adenocarcinoma metastases are often easily identifiable on standard morphology and on their immunophenotype, which is predominantly CK7-, CK20+, CDX2+ and SATB2+. On the other hand, differential diagnosis with metastases of pancreatic, gastric or extrahepatic biliary origin can be difficult, requiring the conjunction of several immunohistochemical markers (**Figure 2**). Other markers may help to better characterize tumour origin such as GATA3 (breast cancer), TTF1 (lung cancer), CDX2 (gastro-entero-colic differentiation marker) or HepPar1, glypican-3, Arginase-1 and AFP (hepatocytes and HCC markers). C-reactive protein (CRP) IHC, already used for the diagnosis of inflammatory hepatocellular adenomas, appears promising for differentiating iCCA (particularly of the “small-duct” type) from liver metastases of pancreatic and gastric adenocarcinoma. Its performance is better than that of N-cadherin with a sensitivity and specificity on surgical samples of 93.3% and 88.2%, respectively, versus 80.0% and 88.2% respectively for N-cadherin [32]. However, when possible, extensive IHC exploration should be avoided to preserve tissue samples for tumour molecular profiling. Additional investigations (e.g., mammography, PET, digestive tract endoscopies) may also be considered without delaying treatment’s initiation.

5. *Detection of familial predisposition*

Hereditary forms of BTCs have been reported with germline mutations in *BRCA* genes or mismatch repair deficiency (MMR) genes (Lynch syndrome). In a large cohort of 1292 patients with BTC, *BRCA* mutations were detected in 3.6% (n=46) of samples (*BRCA1*: 0.6%, *BRCA2*: 3%) and microsatellite instability (MSI)-high/ deficient(d)MMR in 2.4% of tumours [33]. Exceptional family aggregations of BTCs of unknown genetic substratum have also been reported [34]. No systematic germline screening for BTCs is recommended in France and worldwide.

III. **Management of local/locoregional disease**

Therapeutic recommendations and options according to BTC subtype and stage with levels of evidence are presented in **Figure 3** and **Table 3**.

A. Neoadjuvant setting

In the absence of randomised trial to date, neoadjuvant therapy should be restricted to the context of clinical trials. If an initially unresectable iCCA responds to systemic and/or locoregional therapy, surgery should be discussed again by a multidisciplinary team [35,36].

B. Surgery

Surgery objectives include complete surgical resection (R0 margin status) while preserving an adequate remaining liver volume. However, even after R0 resection, 5-year overall survival (OS) does not exceed 5-10% in GBC, except for early stages (Tis-T1a) (5-year OS, 95-100%) [37], and 12-40% in CCA [38–40]. Recommended surgical techniques according to BTC anatomical subtypes are summarized in **Figure 1**.

A standardized pathology report must be drawn up, depicting at least tumour type, associated (pre)neoplastic lesions, differentiation grade, stage, surgical margin status, lymphatic, vascular, perineural and lymph node invasion, and distant metastases.

Main poor prognostic factors are lymph node invasion, macrovascular invasion and microscopic invasion of the resection margins (R1). Since up to 65% of patients eligible to curative-intent surgery ultimately have metastatic or unresectable disease, local resectability assessment, and peritoneal cavity exploration by preoperative laparoscopy [41] are essential, as well as intraoperative frozen sections examination of the biliary margin(s) in pCCA, dCCA and GBC. 1-cm safety margins are advocated for iCCA, even though the level of evidence is low, since the prognosis for resection with <5 mm margins is close to that of R1 tumours [42]. Systematic locoregional lymphadenectomy (of ≥6 nodes in iCCA and >5 nodes in other BTCs) is recommended due to its major prognostic impact [43–46]. Lymphatic invasion beyond the first lymph node relay contraindicates resection; however, the sole suspicion of lymph node involvement on preoperative imaging should not contraindicate surgery due to the high false positive rate [47–49].

In most jaundiced patients with pCCA, preoperative biliary stenting is necessary. Before a left- or right-sided hepatectomy, the choice of the liver segments to be stented should be discussed with the surgical team beforehand, as the biliary clearance of the future liver remnant would be necessary and sufficient in most cases. Preoperative management should articulate biliary stenting and portal vein embolization, as necessary.

Bismuth type I pCCA requires resection of the common bile duct with regional lymphadenectomy. The benefit of extending lymphadenectomy to retro-pancreatic region has not been demonstrated. Bismuth type II, III or IV pCCAs require an extended (right or left-sided) hepatectomy, combined with vascular resection if needed [50]. Associated vascular

resections in case of tumour extension to portal vein and/or hepatic artery have been proved to safely extend resectability rates in selected patients [51]. Longitudinal biliary extension, unilateral vascular invasion and subsequent liver atrophy guide the choice of the type of surgery. Segment I resection is recommended for Bismuth type II or higher pCCA, since bile ducts directly originating from the upper limit of the hilar plate are invaded in approximately 90% of the cases. Right tri-segmentectomy extended to segment I is recommended if the tumour spares the B2-B3 convergence (type Y), as the left hepatic duct is longer and the right hepatic artery is often invaded [11].

dCCA requires pancreatoduodenectomy with standard lymphadenectomy and resection of the common bile duct [52].

>T1a GBC requires radical cholecystectomy, which consists in *en-bloc* resection of gallbladder and adjacent liver parenchyma (segments IVb + V) and regional lymphadenectomy, plus common bile duct resection in case of biliary extension beyond the cystic duct. The rate of lymph node invasion increases with stage (Tis, 0%; T1a, 2-5%; T1b, 15-20%; T2, 9-30%; T3, 39-72% and T4, 67-80%) [53–58]. In case of lymph node invasion, 5-year OS rate is very low to null [59,60]. Lymphadenectomy includes at least extensive dissection of hepatic pedicle nodes, but may be extended to anterior and posterior pancreatic nodes with "peeling" of the hepatic artery to its origin and potentially of the superior mesenteric artery descending along the anterior surface of the aorta [61]. Tumour location also strongly impacts recurrence rate with 23% of liver and 16% of lymph node recurrences in T2b (liver side) GBC despite complementary liver resection [62], whereas recurrences are rare (\approx 3%) in patients with T2a (peritoneal side) GBC after cholecystectomy alone [63]. Intraoperative gallbladder perforation conveys a very high risk of peritoneal recurrence even after gallbladder extraction in a protective bag, and cannot be considered as curative [64,65]. Liver resection remains controversial for \geq T3 GBC and may consist of IVb-V bi-segmentectomy, or tri-segmentectomy or meso-(I-IV-V-VIII) hepatectomy for GBC invading the hepatic pedicle. Direct invasion of colon, duodenum or liver does not absolutely contraindicate resection. Common bile duct resection is often performed and facilitates hepatic pedicle lymph node dissection in \geq T3 GBC. After incidental diagnosis of GBC during cholecystectomy, cholecystectomy alone is sufficient for Tis-T1a GBC (5-year OS, 95-100%) [37,66]. For later stages, early re-resection is recommended due to the high risk of local and metastatic spread [67], especially in T1b-T2 stages [68–70], for which it significantly reduces the risk of recurrence and increases OS [48,49,55]. However, a role for delayed re-resection has been suggested in patients without unresectable disease after restaging by CT and laparoscopy at 3 months after index cholecystectomy [47].

C. Percutaneous tumour ablation techniques

To date, no study has prospectively evaluated percutaneous tumour ablation techniques (e.g., radiofrequency, cryotherapy, irreversible electroporation, microwave) in BTCs. These techniques can only be considered for single (or few), small (<3cm) iCCA lesions, and are generally performed in patients considered as non-suitable for surgery (e.g., post-resection recurrence, liver cirrhosis). In a systematic review (645 patients), radiofrequency ablation was the most commonly used technique (7/15 studies) [71]. Median tumour size was 27 mm (range, 15-44), complete response rate was 93.9%, and median OS (mOS) was 30.2 months (95% confidence interval [CI]: 21.8-38.6).

D. Liver transplantation

In a retrospective American multicentre study of 287 patients with unresectable pCCA (mostly with underlying primary sclerosing cholangitis), the 5-year intention-to-treat (ITT) OS rate was 53% after neoadjuvant chemoradiotherapy, brachytherapy, chemotherapy, then exploratory laparotomy, and finally liver transplantation (Mayo Clinic protocol) [72]. A meta-analysis of 20 studies (428 patients) reported 5-year OS rates after liver transplantation for unresectable pCCA of 65.1% and 31.6% with and without neoadjuvant chemoradiotherapy, respectively (3-year recurrence rates: 51.7% and 24.1%, respectively) [73]. Liver transplantation following this preoperative protocol may be discussed for unresectable pCCA, taking into account the complexity of this therapeutic program, the high rate of radiation-induced postoperative vascular complications and the low ITT benefit resulting from the strict selection of candidates.

E. Adjuvant setting

The results of five randomised trials assessing adjuvant chemotherapy are available to date. The Asian BCAT [74] and the French PRODIGE 12 [75] randomised trials failed to demonstrate a significant improvement of relapse-free survival (RFS) and mOS with gemcitabine and gemcitabine-oxaliplatin (GEMOX), respectively, compared to surveillance. The British BILCAP trial randomised 447 patients to adjuvant capecitabine (8 cycles, 24 weeks) or surveillance [76]. The OS benefit (primary endpoint) in the primary ITT analysis (mOS: 51.1 vs. 36.4 months; hazard ratio (HR): 0.81; $p=0.097$) reached statistical significance only after a pre-specified adjustment on sex, histological grade and nodal status (HR: 0.71; $p=0.01$). The RFS benefit (median: 24.4 vs. 17.5 months; HR: 0.75; $p=0.033$) was only observed during the first 24 postoperative months. Tolerance was acceptable, and no deleterious effect on quality of life was observed. The South Korean phase II randomised STAMP trial failed to demonstrate a benefit of CISGEM over capecitabine after resection in 101 patients with N+ pCCA or dCCA

in DFS (primary endpoint; median: 14.3 vs. 11.1 months; HR: 0.96 [CI 0.71-1.30]; $p=0.43$) or OS [77]. The Japanese randomised phase III trial ASCOT compared in 440 patients S-1, an oral fluoropyrimidine widely used in Asia but not validated in the European population, with surveillance after R0 resection of BTC. A benefit in OS (primary endpoint) was observed (HR: 0.69 [CI 0.51-0.94]; 3-year OS: 77.1% vs. 67.6%; $p=0.008$), even though RFS was not significantly improved with S-1 (HR: 0.80 [CI 0.61-1.04]; 3-year RFS: 62.4% vs. 50.9%; $p=0.088$) [78]. This study, although not transposable to the European population, reinforces the rationale for fluoropyrimidines in the adjuvant setting.

No prospective randomised trials assessing adjuvant radiotherapy or chemoradiotherapy are available. Two meta-analyses of published data (mainly retrospective or registry studies) suggested a greater benefit of chemoradiotherapy (and chemotherapy) over radiotherapy alone, the benefit of adjuvant therapy overall seeming greater in N+ (OR: 0.49; $p=0.004$) or R1 (OR: 0.36; $p=0.002$) tumours [79,80]. A single-arm phase II trial evaluated 3 months of adjuvant gemcitabine-capecitabine combination chemotherapy followed by chemoradiotherapy with capecitabine in patients with resected extrahepatic CCA or GBC. Similar results in mOS (R0, 34 months; R1, 35 months) and 2y-OS between R0 and R1 tumors suggested a stronger benefit after R1 resection [81]. Grade 3 and 4 adverse events were observed in respectively 52% and 11% of patients.

IV. Management of advanced disease

The primary objective of advanced disease management is to maintain or improve quality of life (e.g., pain control, biliary drainage, nutritional support) and relies in any circumstances on best supportive care (BSC).

A. Palliative surgery

Macroscopically incomplete resections (R2 surgical margin status) have no palliative impact. Surgical biliary diversions (and transtumour intubations) are not superior to endoscopic or percutaneous biliary drainage [82] and convey significant mortality (exceeding 25% in several series) and morbidity. Non-surgical drainage techniques should be preferred even though surgical bypass may be considered in selected patients with relatively long survival expectancy and no possibility for optimal endoscopic or percutaneous drainage.

B. Endoscopic procedures

Biliary drainage is indicated in case of symptoms related to biliary obstruction (e.g., pruritus, cholangitis) and when necessary before starting antitumor therapy. Biliary drainage should be performed in a centre with endoscopic and interventional radiology expertise.

Cholangio-MRI is the examination of choice for planning biliary drainage, which must be as complete as possible and prioritize functional areas. Perioperative antibioprophylaxis is recommended [83]. The stenting procedure depends on the site and extent of the tumour(s) and is ideally performed by ERC [84,85]. Uncovered self-expandable metal stents are cheaper than covered metal stents and stay patent longer than plastic stents [86]. Hilar uncovered metallic stenting must be strictly reserved to cases for which surgery is definitively excluded. Unilateral hilar stenting, which seems as effective as bilateral stenting, must be considered with caution, as it may hamper subsequent procedures [87]. Local tumour destruction by endoscopic radiofrequency ablation may be discussed in cases of stenting difficulties or early tumoral stent obstruction [88,89]. When the endoscopic retrograde route fails or is impossible due to previous surgery, percutaneous radiological stenting or endoscopic ultrasound-guided choledocoduodenal or gastrohepatic stenting should be considered.

The analgesic efficacy of celiac neurolysis has not been demonstrated in BTCs.

C. Palliative (chemo)radiotherapy

No randomised controlled trial has demonstrated a survival benefit of radiotherapy, brachytherapy or chemoradiotherapy over biliary drainage alone in locally advanced BTCs. The randomised phase II-III trial FFCD-9902 compared chemoradiotherapy (50 Gy, 5-fluorouracil [5-FU] and cisplatin) to systemic chemotherapy with GEMOX in patients with unresectable, locally advanced BTC [90]. The trial was closed before completion due to slow recruitment (34 inclusions/72 scheduled), thereby reducing its statistical power. Survival was numerically shorter with chemoradiotherapy compared to chemotherapy (median progression-free survival [mPFS]: 5.8 vs. 11.0 months; HR: 0.65 [CI 0.32-1.33]; mOS was 13.5 vs. 19.9 months; HR: 0.69 [CI 0.31-1.55]).

A non-randomised multicentre study in 39 patients with unresectable iCCA showed that high-dose hypofractionated proton beam therapy achieved a 2-year OS rate of 46.5% (mOS, 22.5 months) and a 2-year PFS rate of 26% [91]. A retrospective study of 79 patients showed that higher doses of radiation therapy (biologic equivalent dose >80.5 Gy) were associated with a higher 3-year OS (73% vs. 38%, $p=0.017$) and local control (78% vs. 45%, $p=0.04$) rates compared to lower doses [92]. Stereotactic body radiation therapy can also be proposed for single tumours (<5 cm in diameter ideally) considered as non-operable and not accessible to percutaneous thermal ablation [93–96].

D. Hepatic intra-arterial therapies

Hepatic arterial treatments (e.g., hepatic arterial chemotherapy, transarterial embolisation, transarterial chemoembolisation [TACE], selective internal radiation therapy [SIRT]) may be proposed as a first-line treatment or after tumour progression under systemic treatment for patients with unresectable iCCA; however, the level of evidence is low, mostly based on non-randomised, small, single-centre or retrospective studies with heterogeneous populations regarding previous treatments, size and number of lesions, and presence of macrovascular invasion or extrahepatic disease [71]. The results of the only available randomised trial (TACE with irinotecan-loaded beads plus systemic gemcitabine-cisplatin vs. systemic gemcitabine-cisplatin alone) were in favour of the combination in terms of secondary resection/ablation rate (25% vs. 8%, $p < 0.005$) and OS (mOS: 33.7 vs. 12.6 months, $p = 0.048$) [97]. In a meta-analysis collecting data on SIRT (27 studies, 1232 patients), TACE (conventional or with drug eluting-beads; 22 studies, 1145 patients) and hepatic arterial chemotherapy (16 studies, 331 patients), ORR was 23.4%, 26.3%, and 41.3%, mPFS was 7.8, 15.0, and 10.1 months, and mOS was 14.1, 15.9, and 21.3 months, respectively [65]. Concomitant systemic chemotherapy was associated in 29.9%, 74.4%, and 96% of patients, respectively, making comparisons difficult. In a meta-analysis of six prospective studies, the combination of gemcitabine-platinum chemotherapy with SIRT significantly improved PFS (median: 8.4 vs. 4.3 months; HR: 0.52 [CI 0.31-0.89]; $p < 0.001$) and OS (median: 21.7 vs 15.9 months; HR: 0.59 [CI 0.34-0.99]; $p = 0.049$) compared to chemotherapy alone [98]. SIRT with yttrium 90 (Y90) microspheres (Therasphere®, Biocompatibles UK Limited, BTG International Group, UK) is reimbursed in France for the first-line treatment, with or without systemic chemotherapy, of patients with unresectable or recurrent iCCA provided that the following criteria are fulfilled: no extrahepatic disease; tumour burden $< 50\%$; preserved performance status (PS; 0-1 in combination with chemotherapy or 0-2 if Therasphere® alone); and preserved liver function.

E. Systemic treatments

1. First-line chemotherapy and immunotherapy

In 2010, the ABC-02 phase III trial demonstrated the superiority of the cisplatin-gemcitabine combination (CISGEM) administered for 24 weeks over gemcitabine alone (mOS: 11.7 vs. 8.1 months; HR: 0.64 [CI 0.52-0.80]; $p < 0.001$), regardless of tumour stage (locally advanced or metastatic) and location [99]. In subgroup analysis, the combination was only beneficial in patients with ECOG PS 0-1 (88% of the patients). Safety of CISGEM was acceptable, and the low doses of cisplatin (25 mg/m² on day [D]1 and D8, every 3 weeks) allow outpatient

administration with light hydration. Consistent results were observed in Asian trials [100,101]. Of note, gemcitabine maintenance after 6 months of CISGEM, although frequently administered worldwide, has not been prospectively validated so far [102,103].

All trials of triple chemotherapy regimens (e.g., FOLFIRINOX [104], CISGEM-nab-paclitaxel [105]) failed to demonstrate a superiority over CISGEM so far, with the exception of the combination of CISGEM to the oral fluoropyrimidine S-1 in a Japanese randomised phase III trial [106].

Capecitabine-oxaliplatin (CAPOX) and GEMOX regimens can be used instead of CISGEM in cases of contraindication, based on randomised phase II trials and cohort studies [90,107–111].

Two international, randomised, placebo-controlled phase III trials demonstrated an OS benefit of the addition of immunotherapy to CISGEM with the anti-programmed cell death ligand-1 (PDL-1) durvalumab (TOPAZ-1 trial [112]; mOS: 12.9 vs. 11.3 months; HR: 0.76 [CI 0.64-0.91]) or the anti-programmed cell death-1 (PD1) pembrolizumab (KEYNOTE-966 trial [113]; mOS: 12.7 vs. 10.9 months; HR: 0.83 [CI 0.72-0.95]) over CISGEM alone, leading to their approval by the FDA and – for durvalumab only to date – by the EMA. Durvalumab is currently available in France through an early access program.

2. *Chemotherapy in second line and beyond*

In 2019, the ABC-06 study – the only randomised phase III trial of second-line chemotherapy in BTC to date – showed an ORR of 5% and a modest OS benefit of the combination of 5-FU and oxaliplatin (FOLFOX regimen) over BSC alone (mOS: 6.2 vs. 5.3 months; HR: 0.69 [CI 0.50-0.97]; $p=0.031$) in 162 patients with advanced BTC whose disease had progressed after first-line CISGEM and with an ECOG PS of 0 to 1 [114]. In a South Korean randomised phase II trial in 118 patients with advanced BTC and an ECOG PS of 0 to 2, no difference was found between mFOLFIRI (5-FU plus irinotecan) and mFOLFOX in terms of ORR (4.0 vs. 5.9%; $p=0.663$), mPFS (2.1 vs. 2.8 months; $p=0.97$), or mOS (5.7 vs. 6.3 months, $p=0.68$) [115]. The combination of 5-FU and nanoliposomal irinotecan (NALIRI) was superior to 5-FU alone in terms of ORR (12.5% vs. 3.5%; $p=0.04$), PFS (median: 4.2 vs. 1.7 months; HR: 0.61 [CI 0.44-0.86]; $p=0.004$) and OS (median: 8.6 vs. 5.3 months; HR 0.68 [CI 0.48-0.95]; $p=0.02$) in the South Korean randomised phase II trial NIFTY [116], but not in the German randomised phase II trial NALIRICC [117] (mPFS: 2.6 vs. 2.3 months; HR: 0.87 [CI 0.56-1.35]; mOS: 6.9 vs. 8.2 months; HR: 1.08 [CI 0.68-1.72]), even though ORR was higher (14.3% vs. 3.9%); grade 3 or higher adverse events were more frequent in the combined arm (70.8% vs. 50%).

No randomized study has evaluated chemotherapy in third line and beyond in BTC to date.

3. *Molecular profiling and personalized medicine*

All randomised trials reported to date that evaluated the combination of chemotherapy with a targeted therapy in unselected patients with advanced BTC failed to demonstrate an OS benefit [109,118–121]. The richness of BTCs, notably iCCA, in tumour gene alterations accessible to therapeutic targeting, and the clinical successes observed with several targeted therapies, some of which are already available, plead for systematic molecular tumour profiling of advanced BTCs [122,123]. Molecular tumour profiling should ideally be performed during first line, as: 1) oncogenic driver alterations occur early during tumour oncogenesis, and persist throughout the course of the disease, without significant changes in the absence of selection by targeted therapy [124]; 2) the molecular tumour profiling turnaround time might not be compatible with the high attrition rate (up to 70%) from one line to another in BTC [125]. Molecular tumour profiling must be able to detect gene fusions/rearrangements, ideally by RNA NGS, and mutations of therapeutic interest according to the ESMO Scale for Clinical Actionability of Molecular Target (ESCAT) classification [126,127]. Besides molecular profiling, MSI/dMMR tumour status should be systematically searched for by IHC and/or polymerase chain reaction (PCR) given the prospects for immunotherapy, as well as HER2 overexpression/amplification (IHC ± ISH). The main actionable alterations, their matched targeted therapies, and their accessibility in US, Europe and France are detailed in **Table 4**.

- **Isocitrate dehydrogenase 1 (*IDH1*)**

Isocitrate dehydrogenase 1 (*IDH1*) mutations are found in approximately (and almost exclusively) 15% of patients with advanced iCCA [128]. The results of the ClarIDHy study – the only randomised Phase III trial of targeted therapy in BTC to date – showed a significant improvement with ivosidenib, an oral *IDH1* inhibitor, in PFS (the primary study endpoint) compared to placebo (median: 2.7 vs. 1.4 months; HR: 0.37 [CI 0.25-0.54]; $p < 0.001$) in 185 patients with an *IDH1*-mutated advanced CCA who previously progressed after one or two lines of chemotherapy and an ECOG PS of 0 or 1 [129]. An OS benefit was observed only after a statistical analysis taking into account the crossover of patients who received ivosidenib after progression in the placebo arm (71% of patients; mOS: 10.3 vs. 5.1 months; HR: 0.49; $p < 0.001$) [130]. Ivosidenib has been approved by FDA and EMA in adult patients with *IDH1*-mutated, previously treated, locally advanced or metastatic cholangiocarcinoma, and is reimbursed in France (albeit in third line only).

- **Fibroblast growth factor receptor 2 (*FGFR2*)**

Fusions and rearrangements of the fibroblast growth factor receptor 2 (*FGFR2*) gene are observed in approximately (and almost exclusively) 15% of iCCA [131]. Several non-

randomised phase I/II or II trials showed the activity of oral pan-FGFR or FGFR2 inhibitors in patients with advanced CCA harbouring a *FGFR2* fusion or rearrangement and previously treated by at least one line of systemic therapy [132–137]. In particular, pemigatinib and futibatinib respectively showed ORR of 35.5% and 42%, mPFS of 6.9 and 9.0 months, and mOS of 21.1 and 21.7 months in the single-arm phase II trials FIGHT-202 and FOENIX-CCA2 including 107 and 103 patients with *FGFR2*-rearranged CCA naive to FGFR inhibitors [132,138]. Tinengotinib, a new class FGFR2 inhibitor with specific binding to FGFR2 overcoming acquired resistances showed promising results with ORR of 34% and mPFS of 6.9 months in patients pre-treated by FGFR inhibitors [139]. Pemigatinib and futibatinib have been approved by FDA and EMA. Only pemigatinib is reimbursed in France to date. The phase III trials FIGHT-302 (first-line pemigatinib versus CISGEM) and FIRST-308 (tinengotinib versus investigator's choice standard chemotherapy in patients with *FGFR2*-altered CCA refractory to FGFR inhibitors) are ongoing.

- **Human epidermal growth factor receptor 2 (*HER2*)**

Alterations in the human epidermal growth factor receptor 2 (*HER2*) gene (e.g. amplification, overexpression, or more rarely mutations) are observed in around 15% of BTCs, mostly in GBC, pCCA, dCCA, and ampullary adenocarcinomas [131]. Several non-randomised phase I/II or II trials in patients with chemorefractory, *HER2*-overexpressed/amplified, advanced BTC showed ORR ranging from 23% to 47%, mPFS of 4.0 to 5.5 months, and mOS of 7.1 to 10.9 months with various *HER2* inhibition approaches [125], including the combination of the anti-*HER2* monoclonal antibodies trastuzumab and pertuzumab [140]; the *HER2* antibody-drug-conjugate trastuzumab-deruxtecan [141]; the combination of trastuzumab and modified FOLFOX [142]; the bispecific anti-*HER2* antibody zanidatamab [143], which is currently available in France through a compassionate access programme; and the combination of trastuzumab with tucatinib [144]. Of note, *HER2* inhibitors are currently tested in the first-line setting. A single-arm phase II trial showed an ORR of 55.5% and a mPFS of 7 months (mOS not specified; median follow up of 17.3 months) with the frontline combination of trastuzumab and CISGEM in 90 chemo-naïve BTC patients [145]. The phase III trial HERIZON-BTC assessing the addition of zanidatamab to first-line CISGEM-durvalumab is ongoing.

- **Microsatellite instability-high/mismatch repair deficiency**

MSI-high/dMMR, either constitutional (Lynch syndrome) or acquired (sporadic), is observed in approximately 2% of advanced BTCs [131]. A non-randomised phase II trial of immunotherapy with pembrolizumab (anti-PD-1 monoclonal antibody) including 22 previously treated, MSI/dMMR, advanced BTC patients with an ECOG PS of 0 or 1 showed an ORR of 40.9%, similar to the rate (34.3%) observed in the overall trial population of 233 patients with

advanced, non-colorectal MSI/dMMR cancer [146]. Pembrolizumab is FDA and EMA approved for MSI/dMMR BTCs, but not reimbursed in France.

- **Neurotrophic tropomyosin receptor tyrosine kinase (*NTRK*)**

Fusions involving neurotrophic tropomyosin receptor tyrosine kinase (*NTRK*) -1, -2 or -3 genes are observed in <1% of BTCs [147]. In a phase I-II trial evaluating the oral *NTRK* inhibitor larotrectinib in 55 patients with *NTRK* fusion-positive advanced cancer (17 tumour types), the ORR was 75%; an objective tumour response was observed in one of the two CCA patients included [148]. In a pooled analysis of three phase I-II trials with the oral *NTRK* inhibitor entrectinib, the ORR was 57%, including the only CCA patient included [149]. Larotrectinib and entrectinib have been approved by FDA and EMA for the treatment of solid tumours with an *NTRK* gene fusion, but are currently not reimbursed for adults in France (larotrectinib is only reimbursed in paediatric indications). According to recent European recommendations, NGS (preferably RNA), or IHC followed by sequencing of positive cases, should be performed in unselected populations where *NTRK* fusions are uncommon, such as patients with BTC [150].

- **Rearranged during transfection (*RET*)**

Rearranged during transfection gene (*RET*) fusions are found in various cancers, including 1% of BTC cases [151,152]. Non-randomised phase I/II trials showed the activity of the two oral *RET* inhibitors pralsetinib and selpercatinib in patients with *RET* fusion-positive solid tumours including BTC, with ORR of 57% and 43.9%, mPFS of 7.0 and 13.2 months, and mOS of 14.0 and 18.0 months, respectively [153,154]. Their EMA approval is currently restricted to *RET* fusion-positive advanced non small-cell lung cancer (NSCLC) for selpercatinib and pralsetinib and thyroid cancer including medullary thyroid cancer for selpercatinib; selpercatinib is currently reimbursed in France for NSCLC and medullary thyroid cancer only.

- **v-Raf murine sarcoma viral oncogene homolog B (*BRAF*)**

v-Raf murine sarcoma viral oncogene homolog B (*BRAF*) mutations, mostly V600E, are observed in approximately 5% of BTCs [155]. In the non-randomised phase II trial ROAR assessing the combination of the oral *BRAF* inhibitor dabrafenib and the MEK inhibitor trametinib in 43 patients with *BRAF*^{V600E}-mutated BTC. ORR, mPFS and mOS were respectively 58.1%, 9.0 and 13.5 months [156,157]. Agnostic FDA approval has been obtained; however, no approval was granted by the EMA nor access programme in France for the treatment of *BRAF*^{V600E}-mutated BTC.

- **V-Ki-ras2 Kirsten rat sarcoma viral oncogene homolog (*KRAS*)**

V-Ki-ras2 Kirsten rat sarcoma viral oncogene homolog (*KRAS*) mutations occur in approximately 20% of BTCs, of which *KRAS*^{G12C} mutations, the only currently targetable ones, account for approximately 5% of mutations (i.e. 1% of BTCs) [158]. In a phase I/II trial, the oral selective *KRAS*^{G12C} inhibitor adagrasib showed promising antitumor efficacy in 63 patients with *KRAS*^{G12C} mutated tumours including 12 patients with BTC. ORR, mPFS and mOS were respectively 47.1%, 8.6, and 15.1 months in the BTC cohort [159]. To date, there are no activity data in BTCs for the *KRAS*^{G12C} inhibitor sotorasib, which has been approved in Europe for the treatment of pre-treated, *KRAS*^{G12C}-mutated advanced NSCLC.

Even though molecular profiling is widely studied and brought several new targeted therapeutic options to BTC patients, available data to date are derived from non-randomised studies (with the exception of the CLARIDHY trial for *IDH1*-mutated cholangiocarcinoma). Moreover, randomized trials in first line are difficult to conduct owing to the rarity of the molecularly defined BTC subpopulations and the turnaround time of molecular profiling. The PRODIGE 80 SAFIR-ABC10 phase 3 trial (NCT05615818) will attempt to prove the feasibility and the benefit of an early molecular profiling guiding different maintenance targeted therapeutic options in patients responding or stable under CISGEM-durvalumab. To finish, further BTC-specific prospective studies are expected in other tumour gene alterations such as *BRCA*, *MET*, *HER3*, *BAP1*, *ARID1A*, *PIK3CA*, *NRG1* or *MDM2* to widen the panel of therapeutic options for patients.

V. Follow-up and long-term considerations

The value of repeat serum determinations of one or more tumour markers for follow-up during treatment or post-therapy monitoring has not been demonstrated. No standard surveillance protocol exists in BTCs after curative-intent resection. Clinical examination and imaging (thoraco-abdomino-pelvic CT or thoracic CT plus abdominal MRI) every 3 to 6 months for 2 years, then every 6 months for up to 5 years may be proposed, only to patients able to tolerate treatment for tumour recurrence (expert consensus).

Acknowledgments

We thank the TNCD review committee: T. Aparicio (Paris), S. Cattan (Lille), L. Chiche-Bensadoun (Bordeaux), M. Ducreux (Villejuif), A. Dupre (Lyon), H. Etienne (Albi), A. Heurgue (Reims), F. Huguet (Paris), J.-L. Jouve (Dijon), T. Lecomte (Tours), C. Louvet (Paris), N. Magne (Lyon), P. Mariani (Paris), B. Menahen (Caen), L. Mosser (Rodez), G. Passot (Lyon), C. Silvain (Poitiers), B. Suc (Toulouse).

References

- [1] Rungay H, Ferlay J, de Martel C, Georges D, Ibrahim AS, Zheng R, et al. Global, regional and national burden of primary liver cancer by subtype. *European Journal of Cancer* 2022;161:108–18. <https://doi.org/10.1016/j.ejca.2021.11.023>.
- [2] Rungay H, Arnold M, Ferlay J, Lesi O, Cabasag CJ, Vignat J, et al. Global burden of primary liver cancer in 2020 and predictions to 2040. *Journal of Hepatology* 2022;77:1598–606. <https://doi.org/10.1016/j.jhep.2022.08.021>.
- [3] Defossez G, Le Guyader-Peyrou S, Uhry Z, Grosclaude P, Colonna M, Dantony E, et al. Estimations nationales de l’incidence et de la mortalité par cancer en France métropolitaine entre 1990 et 2018 - Tumeurs solides : Étude à partir des registres des cancers du réseau Francim. Synthèse 2019.
- [4] Hundal R, Shaffer EA. Gallbladder cancer: epidemiology and outcome. *Clin Epidemiol* 2014;6:99–109. <https://doi.org/10.2147/CLEP.S37357>.
- [5] Manfredi S, Benhamiche AM, Isambert N, Prost P, Jouve JL, Faivre J. Trends in incidence and management of gallbladder carcinoma: a population-based study in France. *Cancer* 2000;89:757–62. [https://doi.org/10.1002/1097-0142\(20000815\)89:4<757::aid-cncr6>3.0.co;2-h](https://doi.org/10.1002/1097-0142(20000815)89:4<757::aid-cncr6>3.0.co;2-h).
- [6] Lepage C, Cottet V, Chauvenet M, Phelip J-M, Bedenne L, Faivre J, et al. Trends in the incidence and management of biliary tract cancer: a French population-based study. *J Hepatol* 2011;54:306–10. <https://doi.org/10.1016/j.jhep.2010.06.039>.
- [7] Banales JM, Marin JJG, Lamarca A, Rodrigues PM, Khan SA, Roberts LR, et al. Cholangiocarcinoma 2020: the next horizon in mechanisms and management. *Nat Rev Gastroenterol Hepatol* 2020;17:557–88. <https://doi.org/10.1038/s41575-020-0310-z>.
- [8] Flemming JA, Zhang-Salomons J, Nanji S, Booth CM. Increased incidence but improved median overall survival for biliary tract cancers diagnosed in Ontario from 1994 through 2012: A population-based study. *Cancer* 2016;122:2534–43. <https://doi.org/10.1002/cncr.30074>.
- [9] Neuzillet C, Emery C, Teissier C, Bouée S, Lièvre A. Patient healthcare trajectories of intrahepatic cholangiocarcinoma in France: A nationwide retrospective analysis. *The Lancet Regional Health – Europe* 2022;15. <https://doi.org/10.1016/j.lanepe.2022.100324>.
- [10] Amin MB, Greene FL, Edge SB, Compton CC, Gershenwald JE, Brookland RK, et al. The Eighth Edition AJCC Cancer Staging Manual: Continuing to build a bridge from a population-based to a more “personalized” approach to cancer staging. *CA Cancer J Clin* 2017;67:93–9. <https://doi.org/10.3322/caac.21388>.
- [11] Boudjema K, Sulpice L, Garnier S, Bretagne J-F, Gandon Y, Rohou T. A simple system to predict perihilar cholangiocarcinoma resectability. *J Gastrointest Surg* 2013;17:1247–56. <https://doi.org/10.1007/s11605-013-2215-4>.
- [12] Konstantinidis IT, Groot Koerkamp B, Do RKG, Gönen M, Fong Y, Allen PJ, et al. Unresectable intrahepatic cholangiocarcinoma: Systemic plus hepatic arterial infusion chemotherapy is associated with longer survival in comparison with systemic chemotherapy alone. *Cancer* 2016;122:758–65. <https://doi.org/10.1002/cncr.29824>.
- [13] Nagorney DM, Donohue JH, Farnell MB, Schleck CD, Ilstrup DM. Outcomes after curative resections of cholangiocarcinoma. *Arch Surg* 1993;128:871–7; discussion 877-879.
- [14] Hawkins WG, DeMatteo RP, Jarnagin WR, Ben-Porat L, Blumgart LH, Fong Y. Jaundice predicts advanced disease and early mortality in patients with gallbladder cancer. *Ann Surg Oncol* 2004;11:310–5.
- [15] Ruys AT, van Beem BE, Engelbrecht MRW, Bipat S, Stoker J, Van Gulik TM. Radiological staging in patients with hilar cholangiocarcinoma: a systematic review and meta-analysis. *Br J Radiol* 2012;85:1255–62. <https://doi.org/10.1259/bjr/88405305>.
- [16] Saleh M, Virarkar M, Bura V, Valenzuela R, Javadi S, Szklaruk J, et al. Intrahepatic

- cholangiocarcinoma: pathogenesis, current staging, and radiological findings. *Abdom Radiol (NY)* 2020;45:3662–80. <https://doi.org/10.1007/s00261-020-02559-7>.
- [17] Vilgrain V. Staging cholangiocarcinoma by imaging studies. *HPB (Oxford)* 2008;10:106–9. <https://doi.org/10.1080/13651820801992617>.
- [18] Weilert F, Bhat YM, Binmoeller KF, Kane S, Jaffee IM, Shaw RE, et al. EUS-FNA is superior to ERCP-based tissue sampling in suspected malignant biliary obstruction: results of a prospective, single-blind, comparative study. *Gastrointest Endosc* 2014;80:97–104. <https://doi.org/10.1016/j.gie.2013.12.031>.
- [19] Moura DTH, de Moura EGH, Matuguma SE, Dos Santos ME, Moura ETH, Baracat FI, et al. EUS-FNA versus ERCP for tissue diagnosis of suspect malignant biliary strictures: a prospective comparative study. *Endosc Int Open* 2018;6:E769–77. <https://doi.org/10.1055/s-0043-123186>.
- [20] Vogel A, Bridgewater J, Edeline J, Kelley RK, Klumpen HJ, Malka D, et al. Biliary tract cancer: ESMO Clinical Practice Guideline for diagnosis, treatment and follow-up☆. *Annals of Oncology* 2023;34:127–40. <https://doi.org/10.1016/j.annonc.2022.10.506>.
- [21] Navaneethan U, Njei B, Lourdasamy V, Konjeti R, Vargo JJ, Parsi MA. Comparative effectiveness of biliary brush cytology and intraductal biopsy for detection of malignant biliary strictures: a systematic review and meta-analysis. *Gastrointestinal Endoscopy* 2015;81:168–76. <https://doi.org/10.1016/j.gie.2014.09.017>.
- [22] Kobayashi M, Ryozaawa S, Araki R, Nagata K, Tanisaka Y, Fujita A, et al. Investigation of Factors Affecting the Sensitivity of Bile Duct Brush Cytology. *Internal Medicine* 2019;58:329–35. <https://doi.org/10.2169/internalmedicine.1551-18>.
- [23] Roth GS; B Philippe; Fior-Gozman, Michele; Roth, Hubert; Auroux, Jean; Risse, Olivier; Letoublon, Christian; Laverrière, Marie Hélène; Bricault, Ivan; Leroy, Vincent; Decaens, Thomas. Performance of bile aspiration plus brushing to diagnose malignant biliary strictures during endoscopic retrograde cholangiopancreatography. *Endosc Int Open* 2016;04:E997–1003. <https://doi.org/10.1055/s-0042-108854>.
- [24] Yoon SB, Moon S-H, Ko SW, Lim H, Kang HS, Kim JH. Brush Cytology, Forceps Biopsy, or Endoscopic Ultrasound-Guided Sampling for Diagnosis of Bile Duct Cancer: A Meta-Analysis. *Digestive Diseases and Sciences* 2022;67:3284–97. <https://doi.org/10.1007/s10620-021-07138-4>.
- [25] Frederic Prat, Sarah Leblanc, Frantz Foissac, Thierry Ponchon, René Laugier, Philippe Bichard, et al. Impact of peroral cholangioscopy on the management of indeterminate biliary conditions: a multicentre prospective trial. *Frontline Gastroenterol* 2019;10:236. <https://doi.org/10.1136/flgastro-2018-100985>.
- [26] Tyberg A, Rajman I, Siddiqui A, Arnelo U, Adler DG, Xu M, et al. Digital Pancreaticocholangioscopy for Mapping of Pancreaticobiliary Neoplasia: Can We Alter the Surgical Resection Margin? *Journal of Clinical Gastroenterology* 2019;53.
- [27] Gerges C, Beyna T, Tang RSY, Bahin F, Lau JYW, van Geenen E, et al. Digital single-operator peroral cholangioscopy-guided biopsy sampling versus ERCP-guided brushing for indeterminate biliary strictures: a prospective, randomized, multicenter trial (with video). *Gastrointestinal Endoscopy* 2020;91:1105–13. <https://doi.org/10.1016/j.gie.2019.11.025>.
- [28] Feng L, You Z, Ma D, Yan L, Cheng H, Gou J, et al. Immunoglobulin (Ig) G4-related sclerosing cholangitis in patients resected for presumed perihilar cholangiocarcinoma: a 10-year experience. *Annals of Translational Medicine*; Vol 9, No 5 (March 15, 2021): *Annals of Translational Medicine* 2021.
- [29] Roos E, Hubers LM, Coelen RJS, Doorenspleet ME, de Vries N, Verheij J, et al. IgG4-Associated Cholangitis in Patients Resected for Presumed Perihilar Cholangiocarcinoma: a 30-Year Tertiary care Experience. *Official Journal of the American*

College of Gastroenterology | ACG 2018;113.

- [30] Levy C, Lymp J, Angulo P, Gores GJ, Larusso N, Lindor KD. The value of serum CA 19-9 in predicting cholangiocarcinomas in patients with primary sclerosing cholangitis. *Dig Dis Sci* 2005;50:1734–40. <https://doi.org/10.1007/s10620-005-2927-8>.
- [31] Ramage JK, Donaghy A, Farrant JM, Iorns R, Williams R. Serum tumor markers for the diagnosis of cholangiocarcinoma in primary sclerosing cholangitis. *Gastroenterology* 1995;108:865–9.
- [32] Yeh Y-C, Lei H-J, Chen M-H, Ho H-L, Chiu L-Y, Li C-P, et al. C-Reactive Protein (CRP) is a Promising Diagnostic Immunohistochemical Marker for Intrahepatic Cholangiocarcinoma and is Associated With Better Prognosis. *The American Journal of Surgical Pathology* 2017;41.
- [33] Spizzo G, Puccini A, Xiu J, Goldberg RM, Grothey A, Shields AF, et al. Molecular profile of BRCA-mutated biliary tract cancers. *ESMO Open* 2020;5. <https://doi.org/10.1136/esmoopen-2020-000682>.
- [34] Hemminki K, Li X. Familial liver and gall bladder cancer: a nationwide epidemiological study from Sweden. *Gut* 2003;52:592–6.
- [35] Riby D, Mazzotta AD, Bergeat D, Verdure L, Sulpice L, Bourien H, et al. Downstaging with Radioembolization or Chemotherapy for Initially Unresectable Intrahepatic Cholangiocarcinoma. *Annals of Surgical Oncology* 2020;27:3729–37. <https://doi.org/10.1245/s10434-020-08486-7>.
- [36] Le Roy B, Gelli M, Pittau G, Allard M-A, Pereira B, Serji B, et al. Neoadjuvant chemotherapy for initially unresectable intrahepatic cholangiocarcinoma. *British Journal of Surgery* 2018;105:839–47. <https://doi.org/10.1002/bjs.10641>.
- [37] Fuks D, Regimbeau JM, Le Treut Y-P, Bachellier P, Raventos A, Pruvot F-R, et al. Incidental gallbladder cancer by the AFC-GBC-2009 Study Group. *World J Surg* 2011;35:1887–97. <https://doi.org/10.1007/s00268-011-1134-3>.
- [38] Wu L, Tsilimigras DI, Paredes AZ, Mehta R, Hyer JM, Merath K, et al. Trends in the Incidence, Treatment and Outcomes of Patients with Intrahepatic Cholangiocarcinoma in the USA: Facility Type is Associated with Margin Status, Use of Lymphadenectomy and Overall Survival. *World Journal of Surgery* 2019;43:1777–87. <https://doi.org/10.1007/s00268-019-04966-4>.
- [39] de Jong MC, Nathan H, Sotiropoulos GC, Paul A, Alexandrescu S, Marques H, et al. Intrahepatic Cholangiocarcinoma: An International Multi-Institutional Analysis of Prognostic Factors and Lymph Node Assessment. *JCO* 2011;29:3140–5. <https://doi.org/10.1200/JCO.2011.35.6519>.
- [40] Tan JCC, Coburn NG, Baxter NN, Kiss A, Law CHL. Surgical Management of Intrahepatic Cholangiocarcinoma - A Population-Based Study. *Annals of Surgical Oncology* 2008;15:600–8. <https://doi.org/10.1245/s10434-007-9627-x>.
- [41] Bird N, Elmasry M, Jones R, Elniel M, Kelly M, Palmer D, et al. Role of staging laparoscopy in the stratification of patients with perihilar cholangiocarcinoma. *Br J Surg* 2017;104:418–25. <https://doi.org/10.1002/bjs.10399>.
- [42] Spolverato G, Yakoob MY, Kim Y, Alexandrescu S, Marques HP, Lamelas J, et al. The Impact of Surgical Margin Status on Long-Term Outcome After Resection for Intrahepatic Cholangiocarcinoma. *Ann Surg Oncol* 2015;22:4020–8. <https://doi.org/10.1245/s10434-015-4472-9>.
- [43] Sposito C, Ratti F, Cucchetti A, Ardito F, Ruzzenente A, Di Sandro S, et al. Survival benefit of adequate lymphadenectomy in patients undergoing liver resection for clinically node-negative intrahepatic cholangiocarcinoma. *Journal of Hepatology* 2023;78:356–63. <https://doi.org/10.1016/j.jhep.2022.10.021>.
- [44] de Jong MC, Nathan H, Sotiropoulos GC, Paul A, Alexandrescu S, Marques H, et al.

- Intrahepatic cholangiocarcinoma: an international multi-institutional analysis of prognostic factors and lymph node assessment. *J Clin Oncol* 2011;29:3140–5.
<https://doi.org/10.1200/JCO.2011.35.6519>.
- [45] Weber SM, Ribero D, O'Reilly EM, Kokudo N, Miyazaki M, Pawlik TM. Intrahepatic cholangiocarcinoma: expert consensus statement. *HPB (Oxford)* 2015;17:669–80.
<https://doi.org/10.1111/hpb.12441>.
- [46] Valle JW, Borbath I, Khan SA, Huguet F, Gruenberger T, Arnold D. Biliary cancer: ESMO Clinical Practice Guidelines for diagnosis, treatment and follow-up. *Ann Oncol* 2016;27:v28–37. <https://doi.org/10.1093/annonc/mdw324>.
- [47] Jarnagin WR, Fong Y, DeMatteo RP, Gonen M, Burke EC, Bodniewicz BS J, et al. Staging, resectability, and outcome in 225 patients with hilar cholangiocarcinoma. *Ann Surg* 2001;234:507–17; discussion 517–519.
- [48] Burke EC, Jarnagin WR, Hochwald SN, Pisters PW, Fong Y, Blumgart LH. Hilar Cholangiocarcinoma: patterns of spread, the importance of hepatic resection for curative operation, and a presurgical clinical staging system. *Ann Surg* 1998;228:385–94.
- [49] Kitagawa Y, Nagino M, Kamiya J, Uesaka K, Sano T, Yamamoto H, et al. Lymph node metastasis from hilar cholangiocarcinoma: audit of 110 patients who underwent regional and paraaortic node dissection. *Ann Surg* 2001;233:385–92.
- [50] Neuhaus P, Jonas S, Bechstein WO, Lohmann R, Radke C, Kling N, et al. Extended resections for hilar cholangiocarcinoma. *Ann Surg* 1999;230:808–18; discussion 819.
- [51] Mizuno T, Ebata T, Yokoyama Y, Igami T, Yamaguchi J, Onoe S, et al. Combined Vascular Resection for Locally Advanced Perihilar Cholangiocarcinoma. *Annals of Surgery* 2022;275.
- [52] Dickson PV, Behrman SW. Distal cholangiocarcinoma. *Surg Clin North Am* 2014;94:325–42. <https://doi.org/10.1016/j.suc.2013.12.004>.
- [53] Yamaguchi K, Nishihara K. Long- and short-term survivors after pancreatoduodenectomy for ampullary carcinoma. *J Surg Oncol* 1992;50:195–200.
- [54] Shirai Y, Yoshida K, Tsukada K, Muto T. Inapparent carcinoma of the gallbladder. An appraisal of a radical second operation after simple cholecystectomy. *Ann Surg* 1992;215:326–31.
- [55] Wakai T, Shirai Y, Yokoyama N, Nagakura S, Watanabe H, Hatakeyama K. Early gallbladder carcinoma does not warrant radical resection. *Br J Surg* 2001;88:675–8.
<https://doi.org/10.1046/j.1365-2168.2001.01749.x>.
- [56] Toyonaga T, Chijiwa K, Nakano K, Noshiro H, Yamaguchi K, Sada M, et al. Completion radical surgery after cholecystectomy for accidentally undiagnosed gallbladder carcinoma. *World J Surg* 2003;27:266–71. <https://doi.org/10.1007/s00268-002-6609-9>.
- [57] Suzuki S, Yokoi Y, Kurachi K, Inaba K, Ota S, Azuma M, et al. Appraisal of surgical treatment for pT2 gallbladder carcinomas. *World J Surg* 2004;28:160–5.
<https://doi.org/10.1007/s00268-003-7080-y>.
- [58] Goetze TO, Paolucci V. The prognostic impact of positive lymph nodes in stages T1 to T3 incidental gallbladder carcinoma: results of the German Registry. *Surgical Endoscopy* 2012;26:1382–9. <https://doi.org/10.1007/s00464-011-2044-z>.
- [59] Dixon E, Vollmer CM, Sahajpal A, Cattral M, Grant D, Doig C, et al. An aggressive surgical approach leads to improved survival in patients with gallbladder cancer: a 12-year study at a North American Center. *Ann Surg* 2005;241:385–94.
- [60] Endo I, Shimada H, Tanabe M, Fujii Y, Takeda K, Morioka D, et al. Prognostic significance of the number of positive lymph nodes in gallbladder cancer. *J Gastrointest Surg* 2006;10:999–1007. <https://doi.org/10.1016/j.gassur.2006.03.006>.
- [61] Kondo S, Nimura Y, Hayakawa N, Kamiya J, Nagino M, Uesaka K. Regional and para-aortic lymphadenectomy in radical surgery for advanced gallbladder carcinoma. *Br J*

- Surg 2000;87:418–22. <https://doi.org/10.1046/j.1365-2168.2000.01384.x>.
- [62] Shindoh J, de Aretxabala X, Aloia TA, Roa JC, Roa I, Zimmitti G, et al. Tumor location is a strong predictor of tumor progression and survival in T2 gallbladder cancer: an international multicenter study. *Ann Surg* 2015;261:733–9. <https://doi.org/10.1097/SLA.0000000000000728>.
- [63] Lee H, Choi DW, Park JY, Youn S, Kwon W, Heo JS, et al. Surgical Strategy for T2 Gallbladder Cancer According to Tumor Location. *Ann Surg Oncol* 2015;22:2779–86. <https://doi.org/10.1245/s10434-014-4300-7>.
- [64] Tian Y-H, Ji X, Liu B, Yang G-Y, Meng X-F, Xia H-T, et al. Surgical treatment of incidental gallbladder cancer discovered during or following laparoscopic cholecystectomy. *World J Surg* 2015;39:746–52. <https://doi.org/10.1007/s00268-014-2864-9>.
- [65] Goetze TO, Paolucci V. Use of retrieval bags in incidental gallbladder cancer cases. *World J Surg* 2009;33:2161–5. <https://doi.org/10.1007/s00268-009-0163-7>.
- [66] Goetze TO, Paolucci V. Benefits of reoperation of T2 and more advanced incidental gallbladder carcinoma: analysis of the German registry. *Ann Surg* 2008;247:104–8. <https://doi.org/10.1097/SLA.0b013e318154bf5d>.
- [67] Sikora SS, Singh RK. Surgical strategies in patients with gallbladder cancer: nihilism to optimism. *J Surg Oncol* 2006;93:670–81. <https://doi.org/10.1002/jso.20535>.
- [68] Lee SE, Jang J-Y, Kim S-W, Han H-S, Kim H-J, Yun S-S, et al. Surgical strategy for T1 gallbladder cancer: a nationwide multicenter survey in South Korea. *Ann Surg Oncol* 2014;21:3654–60. <https://doi.org/10.1245/s10434-014-3527-7>.
- [69] Ogura Y, Mizumoto R, Isaji S, Kusuda T, Matsuda S, Tabata M. Radical operations for carcinoma of the gallbladder: Present status in Japan. *World J Surg* 1991;15:337–43. <https://doi.org/10.1007/BF01658725>.
- [70] de Aretxabala X, Roa I, Burgos L, Araya JC, Fonseca L, Wistuba I, et al. Gallbladder cancer in Chile. A report on 54 potentially resectable tumors. *Cancer* 1992;69:60–5. [https://doi.org/10.1002/1097-0142\(19920101\)69:1<60::aid-cnrcr2820690112>3.0.co;2-n](https://doi.org/10.1002/1097-0142(19920101)69:1<60::aid-cnrcr2820690112>3.0.co;2-n).
- [71] Edeline J, Lamarca A, McNamara MG, Jacobs T, Hubner RA, Palmer D, et al. Locoregional therapies in patients with intrahepatic cholangiocarcinoma: A systematic review and pooled analysis. *Cancer Treat Rev* 2021;99:102258. <https://doi.org/10.1016/j.ctrv.2021.102258>.
- [72] Darwish Murad S, Kim WR, Harnois DM, Douglas DD, Burton J, Kulik LM, et al. Efficacy of neoadjuvant chemoradiation, followed by liver transplantation, for perihilar cholangiocarcinoma at 12 US centers. *Gastroenterology* 2012;143:88-98.e3; quiz e14. <https://doi.org/10.1053/j.gastro.2012.04.008>.
- [73] Cambridge WA, Fairfield C, Powell JJ, Harrison EM, Søreide K, Wigmore SJ, et al. Meta-analysis and Meta-regression of Survival After Liver Transplantation for Unresectable Perihilar Cholangiocarcinoma. *Annals of Surgery* 2021;273.
- [74] Ebata T, Hirano S, Konishi M, Uesaka K, Tsuchiya Y, Ohtsuka M, et al. Randomized clinical trial of adjuvant gemcitabine chemotherapy versus observation in resected bile duct cancer. *Br J Surg* 2018;105:192–202. <https://doi.org/10.1002/bjs.10776>.
- [75] Edeline J, Benabdelghani M, Bertaut A, Watelet J, Hammel P, Joly J-P, et al. Gemcitabine and Oxaliplatin Chemotherapy or Surveillance in Resected Biliary Tract Cancer (PRODIGE 12-ACCORD 18-UNICANCER GI): A Randomized Phase III Study. *J Clin Oncol* 2019;37:658–67. <https://doi.org/10.1200/JCO.18.00050>.
- [76] Bridgewater J, Fletcher P, Palmer DH, Malik HZ, Prasad R, Mirza D, et al. Long-Term Outcomes and Exploratory Analyses of the Randomized Phase III BILCAP Study. *JCO* 2022;40:2048–57. <https://doi.org/10.1200/JCO.21.02568>.
- [77] Yoo C, Jeong H, Kim K-P, Hwang DW, Lee J-H, Kim K-H, et al. Adjuvant gemcitabine plus cisplatin (GemCis) versus capecitabine (CAP) in patients (pts) with resected

lymph node (LN)-positive extrahepatic cholangiocarcinoma (CCA): A multicenter, open-label, randomized, phase 2 study (STAMP). *Journal of Clinical Oncology* 2022;40:4019–4019.

- [78] Nakachi K, Ikeda M, Konishi M, Nomura S, Katayama H, Kataoka T, et al. Adjuvant S-1 compared with observation in resected biliary tract cancer (JCOG1202, ASCOT): a multicentre, open-label, randomised, controlled, phase 3 trial. *The Lancet* 2023;401:195–203. [https://doi.org/10.1016/S0140-6736\(22\)02038-4](https://doi.org/10.1016/S0140-6736(22)02038-4).
- [79] Chen Y, Zhang B, Liu C, Cao Y, Lyu C, Qiu M. Clinical efficacy of adjuvant treatments for patients with resected biliary tract cancer: a systematic review and network meta-analysis. *BMJ Open* 2022;12:e051421. <https://doi.org/10.1136/bmjopen-2021-051421>.
- [80] Horgan AM, Amir E, Walter T, Knox JJ. Adjuvant Therapy in the Treatment of Biliary Tract Cancer: A Systematic Review and Meta-Analysis. *JCO* 2012;30:1934–40. <https://doi.org/10.1200/JCO.2011.40.5381>.
- [81] Ben-Josef E, Guthrie KA, El-Khoueiry AB, Corless CL, Zalupski MM, Lowy AM, et al. SWOG S0809: A Phase II Intergroup Trial of Adjuvant Capecitabine and Gemcitabine Followed by Radiotherapy and Concurrent Capecitabine in Extrahepatic Cholangiocarcinoma and Gallbladder Carcinoma. *J Clin Oncol* 2015;33:2617–22. <https://doi.org/10.1200/JCO.2014.60.2219>.
- [82] Witzigmann H, Lang H, Lauer H. Guidelines for palliative surgery of cholangiocarcinoma. *HPB* 2008;10:154–60. <https://doi.org/10.1080/13651820801992567>.
- [83] Vienne A, Hobeika E, Gouya H, Lapidus N, Fritsch J, Choury AD, et al. Prediction of drainage effectiveness during endoscopic stenting of malignant hilar strictures: the role of liver volume assessment. *Gastrointest Endosc* 2010;72:728–35. <https://doi.org/10.1016/j.gie.2010.06.040>.
- [84] Sharaiha RZ, Khan MA, Kamal F, Tyberg A, Tombazzi CR, Ali B, et al. Efficacy and safety of EUS-guided biliary drainage in comparison with percutaneous biliary drainage when ERCP fails: a systematic review and meta-analysis. *Gastrointest Endosc* 2017;85:904–14. <https://doi.org/10.1016/j.gie.2016.12.023>.
- [85] Moryoussef F, Sportes A, Leblanc S, Bachet JB, Chaussade S, Prat F. Is EUS-guided drainage a suitable alternative technique in case of proximal biliary obstruction? *Therap Adv Gastroenterol* 2017;10:537–44. <https://doi.org/10.1177/1756283X17702614>.
- [86] Almadi MA, Barkun A, Martel M. Self-expandable metal stents versus plastic stents for malignant biliary obstruction. *Gastrointest Endosc* 2016;83:852–3. <https://doi.org/10.1016/j.gie.2015.10.035>.
- [87] Dumonceau J-M, Tringali A, Papanikolaou IS, Blero D, Mangiavillano B, Schmidt A, et al. Endoscopic biliary stenting: indications, choice of stents, and results: European Society of Gastrointestinal Endoscopy (ESGE) Clinical Guideline - Updated October 2017. *Endoscopy* 2018;50:910–30. <https://doi.org/10.1055/a-0659-9864>.
- [88] Camus M, Napoléon B, Vienne A, Le Rhun M, Leblanc S, Barret M, et al. Efficacy and safety of endobiliary radiofrequency ablation for the eradication of residual neoplasia after endoscopic papillectomy: a multicenter prospective study. *Gastrointest Endosc* 2018;88:511–8. <https://doi.org/10.1016/j.gie.2018.04.2332>.
- [89] Laquière A, Boustière C, Leblanc S, Penaranda G, Désilets E, Prat F. Safety and feasibility of endoscopic biliary radiofrequency ablation treatment of extrahepatic cholangiocarcinoma. *Surg Endosc* 2016;30:1242–8. <https://doi.org/10.1007/s00464-015-4322-7>.
- [90] Phelip J-M, Vendrely V, Rostain F, Subtil F, Jouve J-L, Gasmi M, et al. Gemcitabine plus cisplatin versus chemoradiotherapy in locally advanced biliary tract cancer: Fédération Francophone de Cancérologie Digestive 9902 phase II randomised study. *Eur J Cancer* 2014;50:2975–82. <https://doi.org/10.1016/j.ejca.2014.08.013>.

- [91] Hong TS, Wo JY, Yeap BY, Ben-Josef E, McDonnell EI, Blaszkowsky LS, et al. Multi-Institutional Phase II Study of High-Dose Hypofractionated Proton Beam Therapy in Patients With Localized, Unresectable Hepatocellular Carcinoma and Intrahepatic Cholangiocarcinoma. *J Clin Oncol* 2016;34:460–8. <https://doi.org/10.1200/JCO.2015.64.2710>.
- [92] Tao R, Krishnan S, Bhosale PR, Javle MM, Aloia TA, Shroff RT, et al. Ablative Radiotherapy Doses Lead to a Substantial Prolongation of Survival in Patients With Inoperable Intrahepatic Cholangiocarcinoma: A Retrospective Dose Response Analysis. *J Clin Oncol* 2016;34:219–26. <https://doi.org/10.1200/JCO.2015.61.3778>.
- [93] Tse RV, Hawkins M, Lockwood G, Kim JJ, Cummings B, Knox J, et al. Phase I study of individualized stereotactic body radiotherapy for hepatocellular carcinoma and intrahepatic cholangiocarcinoma. *J Clin Oncol* 2008;26:657–64. <https://doi.org/10.1200/JCO.2007.14.3529>.
- [94] Polistina FA, Guglielmi R, Baiocchi C, Francescon P, Scalchi P, Febbraro A, et al. Chemoradiation treatment with gemcitabine plus stereotactic body radiotherapy for unresectable, non-metastatic, locally advanced hilar cholangiocarcinoma. Results of a five year experience. *Radiother Oncol* 2011;99:120–3. <https://doi.org/10.1016/j.radonc.2011.05.016>.
- [95] Barney BM, Olivier KR, Miller RC, Haddock MG. Clinical outcomes and toxicity using stereotactic body radiotherapy (SBRT) for advanced cholangiocarcinoma. *Radiat Oncol* 2012;7:67. <https://doi.org/10.1186/1748-717X-7-67>.
- [96] Gkika E, Hallauer L, Kirste S, Adebahr S, Bartl N, Neeff HP, et al. Stereotactic body radiotherapy (SBRT) for locally advanced intrahepatic and extrahepatic cholangiocarcinoma. *BMC Cancer* 2017;17:781. <https://doi.org/10.1186/s12885-017-3788-1>.
- [97] Martin RCG, Simo KA, Hansen P, Rocha F, Philips P, McMasters KM, et al. Drug-Eluting Bead, Irinotecan Therapy of Unresectable Intrahepatic Cholangiocarcinoma (DELTAIC) with Concomitant Systemic Gemcitabine and Cisplatin. *Ann Surg Oncol* 2022;29:5462–73. <https://doi.org/10.1245/s10434-022-11932-3>.
- [98] Edeline J, Bridgewater J, Campillo-Gimenez B, Neveu E, Phelip J-M, Neuzillet C, et al. Chemotherapy with or without selective internal radiation therapy for intrahepatic cholangiocarcinoma: Data from clinical trials. *Hepatology* 9900.
- [99] Valle J, Wasan H, Palmer DH, Cunningham D, Anthoney A, Maraveyas A, et al. Cisplatin plus gemcitabine versus gemcitabine for biliary tract cancer. *N Engl J Med* 2010;362:1273–81. <https://doi.org/10.1056/NEJMoa0908721>.
- [100] Kang MJ, Lee J-L, Kim TW, Lee SS, Ahn S, Park DH, et al. Randomized phase II trial of S-1 and cisplatin versus gemcitabine and cisplatin in patients with advanced biliary tract adenocarcinoma. *Acta Oncol* 2012;51:860–6. <https://doi.org/10.3109/0284186X.2012.682628>.
- [101] Okusaka T, Nakachi K, Fukutomi A, Mizuno N, Ohkawa S, Funakoshi A, et al. Gemcitabine alone or in combination with cisplatin in patients with biliary tract cancer: a comparative multicentre study in Japan. *Br J Cancer* 2010;103:469–74. <https://doi.org/10.1038/sj.bjc.6605779>.
- [102] Sharma M, Talwar V, Maheshwari U, Koyyala VPB, Goel V, Goyal S, et al. Role of Maintenance Gemcitabine in Advanced Carcinoma Gallbladder. *South Asian J Cancer* 2020;9:204–8. <https://doi.org/10.1055/s-0040-1721216>.
- [103] Hyung J, Kim B, Yoo C, Kim K-P, Jeong JH, Chang H-M, et al. Clinical Benefit of Maintenance Therapy for Advanced Biliary Tract Cancer Patients Showing No Progression after First-Line Gemcitabine Plus Cisplatin. *Cancer Res Treat* 2019;51:901–9. <https://doi.org/10.4143/crt.2018.326>.
- [104] Phelip JM, Desrame J, Edeline J, Barbier E, Terrebonne E, Michel P, et al. Modified

- FOLFIRINOX Versus CISGEM Chemotherapy for Patients With Advanced Biliary Tract Cancer (PRODIGE 38 AMEBICA): A Randomized Phase II Study. *J Clin Oncol* 2022;40:262–71. <https://doi.org/10.1200/JCO.21.00679>.
- [105] Shroff RT, Guthrie KA, Scott AJ, Borad MJ, Goff LW, Matin K, et al. SWOG 1815: A phase III randomized trial of gemcitabine, cisplatin, and nab-paclitaxel versus gemcitabine and cisplatin in newly diagnosed, advanced biliary tract cancers. *JCO* 2023;41:LBA490–LBA490. https://doi.org/10.1200/JCO.2023.41.4_suppl.LBA490.
- [106] Ioka T, Kanai M, Kobayashi S, Sakai D, Eguchi H, Baba H, et al. Randomized phase III study of gemcitabine, cisplatin plus S-1 versus gemcitabine, cisplatin for advanced biliary tract cancer (KHBO1401- MITSUBA). *Journal of Hepato-Biliary-Pancreatic Sciences* 2023;30:102–10. <https://doi.org/10.1002/jhbp.1219>.
- [107] Sharma A, Dwary AD, Mohanti BK, Deo SV, Pal S, Sreenivas V, et al. Best supportive care compared with chemotherapy for unresectable gall bladder cancer: a randomized controlled study. *J Clin Oncol* 2010;28:4581–6. <https://doi.org/10.1200/JCO.2010.29.3605>.
- [108] André T, Tournigand C, Rosmorduc O, Provent S, Maindrault-Goebel F, Avenin D, et al. Gemcitabine combined with oxaliplatin (GEMOX) in advanced biliary tract adenocarcinoma: a GERCOR study. *Ann Oncol* 2004;15:1339–43. <https://doi.org/10.1093/annonc/mdh351>.
- [109] Malka D, Cervera P, Foulon S, Trarbach T, de la Fouchardière C, Boucher E, et al. Gemcitabine and oxaliplatin with or without cetuximab in advanced biliary-tract cancer (BINGO): a randomised, open-label, non-comparative phase 2 trial. *The Lancet Oncology* 2014;15:819–28. [https://doi.org/10.1016/S1470-2045\(14\)70212-8](https://doi.org/10.1016/S1470-2045(14)70212-8).
- [110] Fiteni F, Nguyen T, Vernerey D, Paillard M-J, Kim S, Demarchi M, et al. Cisplatin/gemcitabine or oxaliplatin/gemcitabine in the treatment of advanced biliary tract cancer: a systematic review. *Cancer Med* 2014;3:1502–11. <https://doi.org/10.1002/cam4.299>.
- [111] Nehls O, Oettle H, Hartmann JT, Hofheinz R-D, Hass HG, Horger MS, et al. Capecitabine plus oxaliplatin as first-line treatment in patients with advanced biliary system adenocarcinoma: a prospective multicentre phase II trial. *British Journal of Cancer* 2008;98:309–15. <https://doi.org/10.1038/sj.bjc.6604178>.
- [112] Oh D-Y, He AR, Qin S, Chen L-T, Okusaka T, Vogel A, et al. 78P Updated overall survival (OS) from the phase III TOPAZ-1 study of durvalumab (D) or placebo (PBO) plus gemcitabine and cisplatin (+ GC) in patients (pts) with advanced biliary tract cancer (BTC). *Annals of Oncology* 2022;33:S1462–3. <https://doi.org/10.1016/j.annonc.2022.10.114>.
- [113] Kelley RK, Ueno M, Yoo C, Finn RS, Furuse J, Ren Z, et al. Pembrolizumab in combination with gemcitabine and cisplatin compared with gemcitabine and cisplatin alone for patients with advanced biliary tract cancer (KEYNOTE-966): a randomised, double-blind, placebo-controlled, phase 3 trial. *The Lancet* 2023;401:1853–65. [https://doi.org/10.1016/S0140-6736\(23\)00727-4](https://doi.org/10.1016/S0140-6736(23)00727-4).
- [114] Lamarca A, Palmer D, Wasan HS, Ross P, Ma YT, Arora A, et al. 54MO Quality of life (QoL) and value of health (V-He) in advanced biliary cancers (ABC) treated with second-line active-symptom-control (ASC) alone or ASC with oxaliplatin/5-FU chemotherapy (ASC+FOLFOX) in the randomised phase III, multi-centre, open-label ABC-06 trial. *Annals of Oncology* 2022;33:S564–5. <https://doi.org/10.1016/j.annonc.2022.07.082>.
- [115] Choi IS, Kim KH, Lee JH, Suh KJ, Kim J-W, Park JH, et al. A randomised phase II study of oxaliplatin/5-FU (mFOLFOX) versus irinotecan/5-FU (mFOLFIRI) chemotherapy in locally advanced or metastatic biliary tract cancer refractory to first-line gemcitabine/cisplatin chemotherapy. *European Journal of Cancer* 2021;154:288–95. <https://doi.org/10.1016/j.ejca.2021.06.019>.
- [116] Hyung J, Kim I, Kim K, Ryoo B-Y, Jeong JH, Kang MJ, et al. Treatment With

- Liposomal Irinotecan Plus Fluorouracil and Leucovorin for Patients With Previously Treated Metastatic Biliary Tract Cancer: The Phase 2b NIFTY Randomized Clinical Trial. *JAMA Oncology* 2023;9:692–9. <https://doi.org/10.1001/jamaoncol.2023.0016>.
- [117] Vogel A, Wenzel P, Folprecht G, Schütt P, Wege H, Kretzschmar A, et al. 53MO Nal-IRI and 5-FU/LV compared to 5-FU/LV in patients with cholangio- and gallbladder carcinoma previously treated with gemcitabine-based therapies (NALIRICC – AIO-HEP-0116). *Annals of Oncology* 2022;33:S563–4. <https://doi.org/10.1016/j.annonc.2022.07.081>.
- [118] Chen JS, Hsu C, Chiang NJ, Tsai CS, Tsou HH, Huang SF, et al. A KRAS mutation status-stratified randomized phase II trial of gemcitabine and oxaliplatin alone or in combination with cetuximab in advanced biliary tract cancer. *Ann Oncol* 2015;26:943–9. <https://doi.org/10.1093/annonc/mdv035>.
- [119] Moehler M, Maderer A, Schimanski C, Kanzler S, Denzer U, Kolligs FT, et al. Gemcitabine plus sorafenib versus gemcitabine alone in advanced biliary tract cancer: a double-blind placebo-controlled multicentre phase II AIO study with biomarker and serum programme. *Eur J Cancer* 2014;50:3125–35. <https://doi.org/10.1016/j.ejca.2014.09.013>.
- [120] Santoro A, Gebbia V, Pressiani T, Testa A, Personeni N, Arrivas Bajardi E, et al. A randomized, multicenter, phase II study of vandetanib monotherapy versus vandetanib in combination with gemcitabine versus gemcitabine plus placebo in subjects with advanced biliary tract cancer: the VanGogh study. *Ann Oncol* 2015;26:542–7. <https://doi.org/10.1093/annonc/mdu576>.
- [121] Valle JW, Wasan H, Lopes A, Backen AC, Palmer DH, Morris K, et al. Cediranib or placebo in combination with cisplatin and gemcitabine chemotherapy for patients with advanced biliary tract cancer (ABC-03): a randomised phase 2 trial. *Lancet Oncol* 2015;16:967–78. [https://doi.org/10.1016/S1470-2045\(15\)00139-4](https://doi.org/10.1016/S1470-2045(15)00139-4).
- [122] Jain A, Javle M. Molecular profiling of biliary tract cancer: a target rich disease. *J Gastrointest Oncol* 2016;7:797–803. <https://doi.org/10.21037/jgo.2016.09.01>.
- [123] Farshidfar F, Zheng S, Gingras M-C, Newton Y, Shih J, Robertson AG, et al. Integrative Genomic Analysis of Cholangiocarcinoma Identifies Distinct IDH-Mutant Molecular Profiles. *Cell Rep* 2017;18:2780–94. <https://doi.org/10.1016/j.celrep.2017.02.033>.
- [124] van de Haar J, Hoes LR, Roepman P, Lolkema MP, Verheul HMW, Gelderblom H, et al. Limited evolution of the actionable metastatic cancer genome under therapeutic pressure. *Nature Medicine* 2021;27:1553–63. <https://doi.org/10.1038/s41591-021-01448-w>.
- [125] Roth GS, Neuzillet C, Sarabi M, Edeline J, Malka D, Lièvre A. Cholangiocarcinoma: what are the options in all comers and how has the advent of molecular profiling opened the way to personalised medicine ? *European Journal of Cancer* 2023;179:1–14. <https://doi.org/10.1016/j.ejca.2022.11.006>.
- [126] Mateo J, Chakravarty D, Dienstmann R, Jezdic S, Gonzalez-Perez A, Lopez-Bigas N, et al. A framework to rank genomic alterations as targets for cancer precision medicine: the ESMO Scale for Clinical Actionability of molecular Targets (ESCAT). *Ann Oncol* 2018;29:1895–902. <https://doi.org/10.1093/annonc/mdy263>.
- [127] Mosele F, Remon J, Mateo J, Westphalen CB, Barlesi F, Lolkema MP, et al. Recommendations for the use of next-generation sequencing (NGS) for patients with metastatic cancers: a report from the ESMO Precision Medicine Working Group. *Ann Oncol* 2020;31:1491–505. <https://doi.org/10.1016/j.annonc.2020.07.014>.
- [128] Jusakul A, Cutcutache I, Yong CH, Lim JQ, Huang MN, Padmanabhan N, et al. Whole-Genome and Epigenomic Landscapes of Etiologically Distinct Subtypes of Cholangiocarcinoma. *Cancer Discovery* 2017;7:1116–35. <https://doi.org/10.1158/2159-8290.CD-17-0368>.
- [129] Abou-Alfa GK, Macarulla T, Javle MM, Kelley RK, Lubner SJ, Adeva J, et al. Ivosidenib in IDH1-mutant, chemotherapy-refractory cholangiocarcinoma (ClarIDHy): a

- multicentre, randomised, double-blind, placebo-controlled, phase 3 study. *Lancet Oncol* 2020;21:796–807. [https://doi.org/10.1016/S1470-2045\(20\)30157-1](https://doi.org/10.1016/S1470-2045(20)30157-1).
- [130] Zhu AX, Macarulla T, Javle MM, Kelley RK, Lubner SJ, Adeva J, et al. Final Overall Survival Efficacy Results of Ivosidenib for Patients With Advanced Cholangiocarcinoma With IDH1 Mutation: The Phase 3 Randomized Clinical ClarIDHy Trial. *JAMA Oncology* 2021;7:1669–77. <https://doi.org/10.1001/jamaoncol.2021.3836>.
- [131] Valle JW, Lamarca A, Goyal L, Barriuso J, Zhu AX. New Horizons for Precision Medicine in Biliary Tract Cancers. *Cancer Discovery* 2017;7:943–62. <https://doi.org/10.1158/2159-8290.CD-17-0245>.
- [132] Abou-Alfa GK, Sahai V, Hollebecque A, Vaccaro G, Melisi D, Al-Rajabi R, et al. Pemigatinib for previously treated, locally advanced or metastatic cholangiocarcinoma: a multicentre, open-label, phase 2 study. *Lancet Oncol* 2020;21:671–84. [https://doi.org/10.1016/S1470-2045\(20\)30109-1](https://doi.org/10.1016/S1470-2045(20)30109-1).
- [133] Javle M, Roychowdhury S, Kelley RK, Sadeghi S, Macarulla T, Weiss KH, et al. Infigratinib (BGJ398) in previously treated patients with advanced or metastatic cholangiocarcinoma with FGFR2 fusions or rearrangements: mature results from a multicentre, open-label, single-arm, phase 2 study. *Lancet Gastroenterol Hepatol* 2021;6:803–15. [https://doi.org/10.1016/S2468-1253\(21\)00196-5](https://doi.org/10.1016/S2468-1253(21)00196-5).
- [134] Mazzaferro V, El-Rayes BF, Droz Dit Busset M, Cotsoglou C, Harris WP, Damjanov N, et al. Derazantinib (ARQ 087) in advanced or inoperable FGFR2 gene fusion-positive intrahepatic cholangiocarcinoma. *Br J Cancer* 2019;120:165–71. <https://doi.org/10.1038/s41416-018-0334-0>.
- [135] Meric-Bernstam F, Bahleda R, Hierro C, Sanson M, Bridgewater J, Arkenau H-T, et al. Futibatinib, an Irreversible FGFR1-4 Inhibitor, in Patients with Advanced Solid Tumors Harboring FGF/FGFR Aberrations: A Phase I Dose-Expansion Study. *Cancer Discov* 2022;12:402–15. <https://doi.org/10.1158/2159-8290.CD-21-0697>.
- [136] Nogova L, Sequist LV, Perez Garcia JM, Andre F, Delord J-P, Hidalgo M, et al. Evaluation of BGJ398, a Fibroblast Growth Factor Receptor 1-3 Kinase Inhibitor, in Patients With Advanced Solid Tumors Harboring Genetic Alterations in Fibroblast Growth Factor Receptors: Results of a Global Phase I, Dose-Escalation and Dose-Expansion Study. *J Clin Oncol* 2017;35:157–65. <https://doi.org/10.1200/JCO.2016.67.2048>.
- [137] Papadopoulos KP, El-Rayes BF, Tolcher AW, Patnaik A, Rasco DW, Harvey RD, et al. A Phase 1 study of ARQ 087, an oral pan-FGFR inhibitor in patients with advanced solid tumours. *Br J Cancer* 2017;117:1592–9. <https://doi.org/10.1038/bjc.2017.330>.
- [138] Goyal L, Meric-Bernstam F, Hollebecque A, Valle JW, Morizane C, Karasic TB, et al. Futibatinib for FGFR2-Rearranged Intrahepatic Cholangiocarcinoma. *N Engl J Med* 2023;388:228–39. <https://doi.org/10.1056/NEJMoa2206834>.
- [139] Javle M, Kankeu Fonkoua LA, Mahipal A, Liao C-Y, Fountzilias C, Li D, et al. 95MO Tinengotinib in patients with advanced, fibroblast growth factor receptor (FGFR) inhibitor refractory/relapsed cholangiocarcinoma. *Annals of Oncology* 2023;34:S215–6. <https://doi.org/10.1016/j.annonc.2023.09.1388>.
- [140] Javle M, Borad MJ, Azad NS, Kurzrock R, Abou-Alfa GK, George B, et al. Pertuzumab and trastuzumab for HER2-positive, metastatic biliary tract cancer (MyPathway): a multicentre, open-label, phase 2a, multiple basket study. *Lancet Oncol* 2021;22:1290–300. [https://doi.org/10.1016/S1470-2045\(21\)00336-3](https://doi.org/10.1016/S1470-2045(21)00336-3).
- [141] Ohba A, Morizane C, Kawamoto Y, Komatsu Y, Ueno M, Kobayashi S, et al. Trastuzumab deruxtecan (T-DXd; DS-8201) in patients (pts) with HER2-expressing unresectable or recurrent biliary tract cancer (BTC): An investigator-initiated multicenter phase 2 study (HERB trial). *JCO* 2022;40:4006–4006. https://doi.org/10.1200/JCO.2022.40.16_suppl.4006.

- [142] Lee C-K, Chon HJ, Cheon J, Lee MA, Im H-S, Jang J-S, et al. Trastuzumab plus FOLFOX for HER2-positive biliary tract cancer refractory to gemcitabine and cisplatin: a multi-institutional phase 2 trial of the Korean Cancer Study Group (KCSG-HB19-14). *Lancet Gastroenterol Hepatol* 2023;8:56–65. [https://doi.org/10.1016/S2468-1253\(22\)00335-1](https://doi.org/10.1016/S2468-1253(22)00335-1).
- [143] Harding JJ, Fan J, Oh D-Y, Choi HJ, Kim JW, Chang H-M, et al. Zanidatamab for HER2-amplified, unresectable, locally advanced or metastatic biliary tract cancer (HERIZON-BTC-01): a multicentre, single-arm, phase 2b study. *The Lancet Oncology* 2023;24:772–82. [https://doi.org/10.1016/S1470-2045\(23\)00242-5](https://doi.org/10.1016/S1470-2045(23)00242-5).
- [144] Nakamura Y, Mizuno N, Sunakawa Y, Canon J-L, Galsky MD, Hamilton E, et al. Tucatinib and Trastuzumab for Previously Treated Human Epidermal Growth Factor Receptor 2-Positive Metastatic Biliary Tract Cancer (SGNTUC-019): A Phase II Basket Study. *JCO* 2023;JCO.23.00606. <https://doi.org/10.1200/JCO.23.00606>.
- [145] Ostwal V, Mandavkar S, Bhargava P, Srinivas S, Kapoor A, Shetty O, et al. Trastuzumab Plus Gemcitabine-Cisplatin for Treatment-Naïve Human Epidermal Growth Factor Receptor 2-Positive Biliary Tract Adenocarcinoma: A Multicenter, Open-Label, Phase II Study (TAB). *JCO* 2023;JCO.23.01193. <https://doi.org/10.1200/JCO.23.01193>.
- [146] Marabelle A, Le DT, Ascierto PA, Di Giacomo AM, De Jesus-Acosta A, Delord J-P, et al. Efficacy of Pembrolizumab in Patients With Noncolorectal High Microsatellite Instability/Mismatch Repair-Deficient Cancer: Results From the Phase II KEYNOTE-158 Study. *J Clin Oncol* 2020;38:1–10. <https://doi.org/10.1200/JCO.19.02105>.
- [147] Boilève A, Verlingue L, Hollebecque A, Boige V, Ducreux M, Malka D. Rare cancer, rare alteration: the case of NTRK fusions in biliary tract cancers. *Expert Opin Investig Drugs* 2021;30:401–9. <https://doi.org/10.1080/13543784.2021.1896703>.
- [148] Drilon A, Laetsch TW, Kummar S, DuBois SG, Lassen UN, Demetri GD, et al. Efficacy of Larotrectinib in TRK Fusion-Positive Cancers in Adults and Children. *N Engl J Med* 2018;378:731–9. <https://doi.org/10.1056/NEJMoal714448>.
- [149] Doebele RC, Drilon A, Paz-Ares L, Siena S, Shaw AT, Farago AF, et al. Entrectinib in patients with advanced or metastatic NTRK fusion-positive solid tumours: integrated analysis of three phase 1-2 trials. *Lancet Oncol* 2020;21:271–82. [https://doi.org/10.1016/S1470-2045\(19\)30691-6](https://doi.org/10.1016/S1470-2045(19)30691-6).
- [150] Marchiò C, Scaltriti M, Ladanyi M, Iafrate AJ, Bibeau F, Dietel M, et al. ESMO recommendations on the standard methods to detect NTRK fusions in daily practice and clinical research. *Ann Oncol* 2019;30:1417–27. <https://doi.org/10.1093/annonc/mdz204>.
- [151] Kato S, Subbiah V, Marchlik E, Elkin SK, Carter JL, Kurzrock R. RET Aberrations in Diverse Cancers: Next-Generation Sequencing of 4,871 Patients. *Clin Cancer Res* 2017;23:1988–97. <https://doi.org/10.1158/1078-0432.CCR-16-1679>.
- [152] Thein KZ, Velcheti V, Mooers BHM, Wu J, Subbiah V. Precision therapy for RET-altered cancers with RET inhibitors. *Trends Cancer* 2021;7:1074–88. <https://doi.org/10.1016/j.trecan.2021.07.003>.
- [153] Subbiah V, Wolf J, Konda B, Kang H, Spira A, Weiss J, et al. Tumour-agnostic efficacy and safety of selpercatinib in patients with RET fusion-positive solid tumours other than lung or thyroid tumours (LIBRETTO-001): a phase 1/2, open-label, basket trial. *Lancet Oncol* 2022;23:1261–73. [https://doi.org/10.1016/S1470-2045\(22\)00541-1](https://doi.org/10.1016/S1470-2045(22)00541-1).
- [154] Subbiah V, Cassier PA, Siena S, Garralda E, Paz-Ares L, Garrido P, et al. Pan-cancer efficacy of pralsetinib in patients with RET fusion-positive solid tumors from the phase 1/2 ARROW trial. *Nat Med* 2022;28:1640–5. <https://doi.org/10.1038/s41591-022-01931-y>.
- [155] Jain A, Javle M. Molecular profiling of biliary tract cancer: a target rich disease. *Journal of Gastrointestinal Oncology*; Vol 7, No 5 (October 01, 2016): *Journal of Gastrointestinal Oncology (Genetic Diversity of Gastrointestinal Malignancies and Emerging Targets: A New World Order)* 2016.

- [156] Subbiah V, Lassen U, Élez E, Italiano A, Curigliano G, Javle M, et al. Dabrafenib plus trametinib in patients with BRAFV600E-mutated biliary tract cancer (ROAR): a phase 2, open-label, single-arm, multicentre basket trial. *Lancet Oncol* 2020;21:1234–43. [https://doi.org/10.1016/S1470-2045\(20\)30321-1](https://doi.org/10.1016/S1470-2045(20)30321-1).
- [157] Subbiah V, Kreitman RJ, Wainberg ZA, Gazzah A, Lassen U, Stein A, et al. Dabrafenib plus trametinib in BRAFV600E-mutated rare cancers: the phase 2 ROAR trial. *Nature Medicine* 2023;29:1103–12. <https://doi.org/10.1038/s41591-023-02321-8>.
- [158] Salem M, El-Refai S, Sha W, Puccini A, Grothey A, George T. Characterization of KRAS mutation variants and prevalence of KRAS-G12C in gastrointestinal malignancies. *ESMO Gastrointestinal Congress 2021*:0–3.
- [159] Pant S, Yaeger R, Spira AI, Pelster M, Sabari JK, Hafez N, et al. KRYSTAL-1: Activity and safety of adagrasib (MRTX849) in patients with advanced solid tumors harboring a KRASG12C mutation. *JCO* 2023;41:425082–425082. https://doi.org/10.1200/JCO.2023.41.36_suppl.425082.
- [160] Meric-Bernstam F, Beeram M, Hamilton E, Oh D-Y, Hanna DL, Kang Y-K, et al. Zanidatamab, a novel bispecific antibody, for the treatment of locally advanced or metastatic HER2-expressing or HER2-amplified cancers: a phase 1, dose-escalation and expansion study. *The Lancet Oncology* 2022;23:1558–70. [https://doi.org/10.1016/S1470-2045\(22\)00621-0](https://doi.org/10.1016/S1470-2045(22)00621-0).
- [161] Bekaii-Saab TS, Spira AI, Yaeger R, Buchschacher GL, McRee AJ, Sabari JK, et al. KRYSTAL-1: Updated activity and safety of adagrasib (MRTX849) in patients (Pts) with unresectable or metastatic pancreatic cancer (PDAC) and other gastrointestinal (GI) tumors harboring a KRASG12C mutation. *JCO* 2022;40:519–519. https://doi.org/10.1200/JCO.2022.40.4_suppl.519.

Figure legends

Figure 1. Classifications and surgical management.

Abbreviations: CBD, common biliary duct; dCCA, distal cholangiocarcinoma; GBC, gallbladder carcinoma; iCCA, intrahepatic cholangiocarcinoma; pCCA, perihilar cholangiocarcinoma.

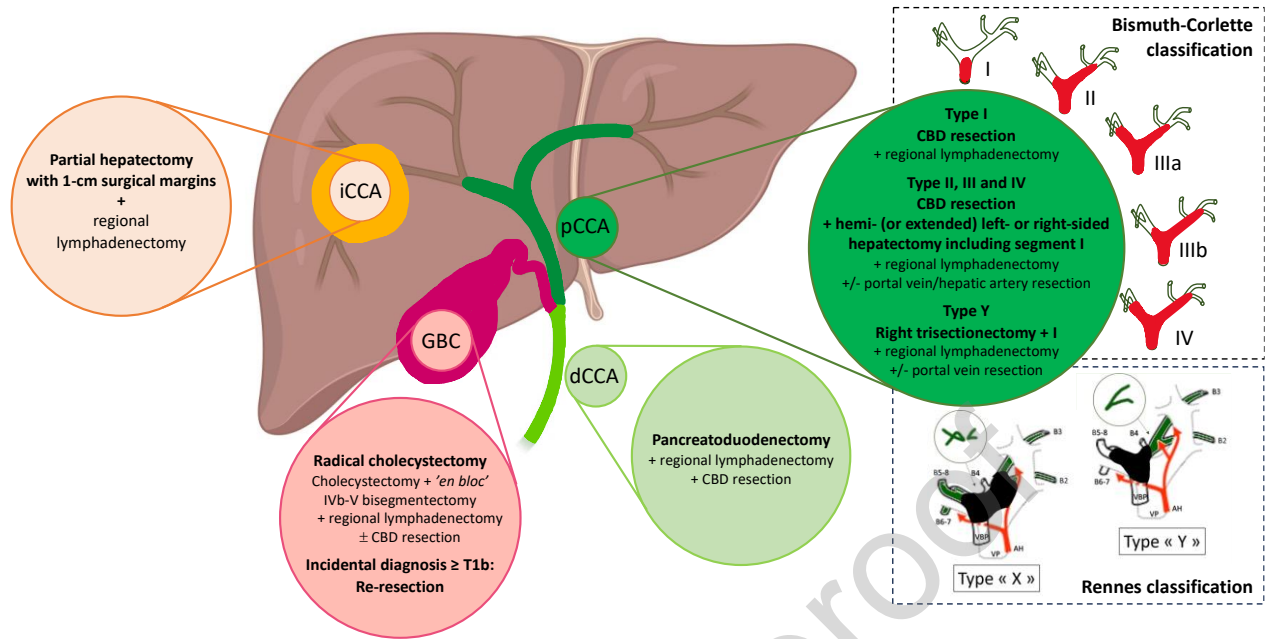


Figure 2. Intrahepatic adenocarcinoma: Immunohistochemistry analyses algorithm to determine the tumor origin.

Unusual profiles are possible, particularly on biopsy, for example:

- iCCA: CK7- (<5%), CK19- (<10%), GATA3+ (5%), HepPar1+/GLY-3+ (<10%), or even AFP+;
- HCC: CK7+, CK19+ (5-20%), CK20+ (<5%), HepPar1 or GLY-3 or arginase-, depending on differentiation and subtype.

Abbreviations: AdCa, adenocarcinoma; AFP, alpha-fetoprotein; CK, cytokeratin; CRP, C-reactive protein; GCDFP15, gross cystic disease fluid protein 15; GLY-3: glypican-3; HCC, hepatocellular carcinoma; iCCA, intrahepatic cholangiocarcinoma; OR, oestrogen receptors.

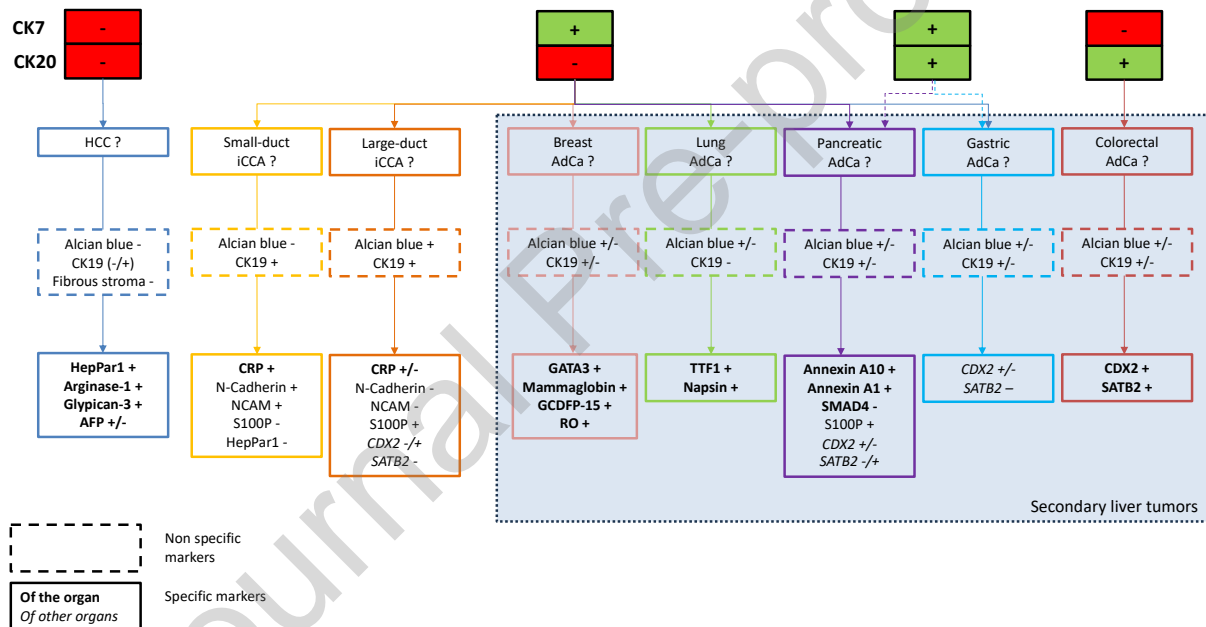


Figure 3. Treatment options and recommendations.

Grades of recommendation to the GRADE system are figured between brackets.

1-Consideration should be given to: the need for preoperative biliary drainage; assessment of the future remaining liver; complementary surgery in case of incidental stage \geq T1b GBC.

In case of clinical and radiological pattern suggestive of resectable p/dCCA where cytology/histology is negative on two occasions, and after cholangioscopy and IgG4 assay, surgical management should not be delayed.

Liver transplantation as part of a Mayo Clinic-type preoperative protocol (CRT, exploratory laparotomy/laparoscopy) is accepted in case of N0, \leq 3 cm, unresectable pCCA (grade B).

Percutaneous ablation may be considered for single iCCA < 3 cm without extrahepatic disease if surgical resection is not possible (grade B).

SBRT may be discussed for iCCA < 5 cm without extrahepatic disease when surgical resection or percutaneous ablation is not possible (grade C).

2- Hepatic arterial therapies (SIRT, TACE, hepatic arterial chemotherapy) and SBRT may be discussed in unresectable iCCA (or in non-operable patients) without extrahepatic disease (grade C). Hepatic arterial therapies should be combined with systemic chemotherapy as first-line therapy (EO). Surgical resection or percutaneous thermal ablation should be discussed in the event of tumor response in initially unresectable disease.

3- In case of clinical and radiological pattern suggestive of unresectable p/dCCA where cytology/histology is negative on two occasions, and after cholangioscopy and IgG4 assay, the possibility of starting chemotherapy must be validated by the multidisciplinary board (EO).

4- If contraindication for cisplatin: GEMOX; for gemcitabine: CAPOX.

5- Systematic molecular tumor portrait should be performed as soon as first-line treatment is started (or even before, for referral to clinical trials), including:

- MMR status (IHC and/or PCR)
- HER2 status (IHC; ISH if IHC 2+)
- NGS panel (DNA or RNA) including search for targetable tumor mutations (including *IDH1*, *BRAF*, *KRAS*)
- Search for fusions/rearrangements (RNA) including *FGFR2* and *NTRK* genes

Tumor molecular profiling on circulating DNA may be considered when no tumor tissue is available, re-biopsy is impossible, and/or tissue tumor molecular profiling failed (EO).

In case of a molecular alteration that can be targeted by a non-approved treatment and not accessible by early access or compassionate programs, or in case of multiple molecular alterations, the molecular results should be discussed and validated by an (ideally molecular) multidisciplinary board (EO).

6- Hepatic arterial therapies (SIRT, TACE, hepatic arterial chemotherapy) and SBRT may be discussed in unresectable iCCA (or in non-operable patients) without extrahepatic disease

(grade C). Hepatic arterial therapies should be used alone as an alternative treatment after failure of standard systemic therapies in the absence of extrahepatic progression (grade C). Surgical resection or percutaneous thermal ablation should be discussed in the event of tumor response in initially unresectable disease.

7- FOLFOX plus trastuzumab: no consensus agreement from the working group in the absence of Western population data (EO).

8- In the absence of first-line anti-PD1/PDL1 therapy. MSI/dMMR status should be confirmed by both IHC and PCR.

Abbreviations: CISGEM, cisplatin/gemcitabine; CRT, chemoradiotherapy; dCCA, distal cholangiocarcinoma; dMMR, deficient DNA mismatch repair; ECOG, Eastern Cooperative Oncology Group; EO, expert opinion; ESCAT, ESMO Scale for Clinical Actionability of molecular Targets; FOLFOX, leucovorin/fluorouracil/oxaliplatin; FP, fluoropyrimidine; GBC, gallbladder cancer; GEM, gemcitabine; iCCA, intrahepatic cholangiocarcinoma; IHC, immunohistochemistry; ISH, *in situ* hybridisation; MMR, DNA mismatch repair; MSI, microsatellite instability; Nal-Iri-5FU-LV, liposomal irinotecan/fluorouracil/leucovorin; NGS, next-generation sequencing; pCCA, perihilar cholangiocarcinoma; PCR, polymerase chain reaction; PS, performance status; R1, microscopically positive resection; SBRT, stereotactic body radiation therapy; SIRT, selective internal radiation therapy; TACE, trans-arterial chemo-embolisation.

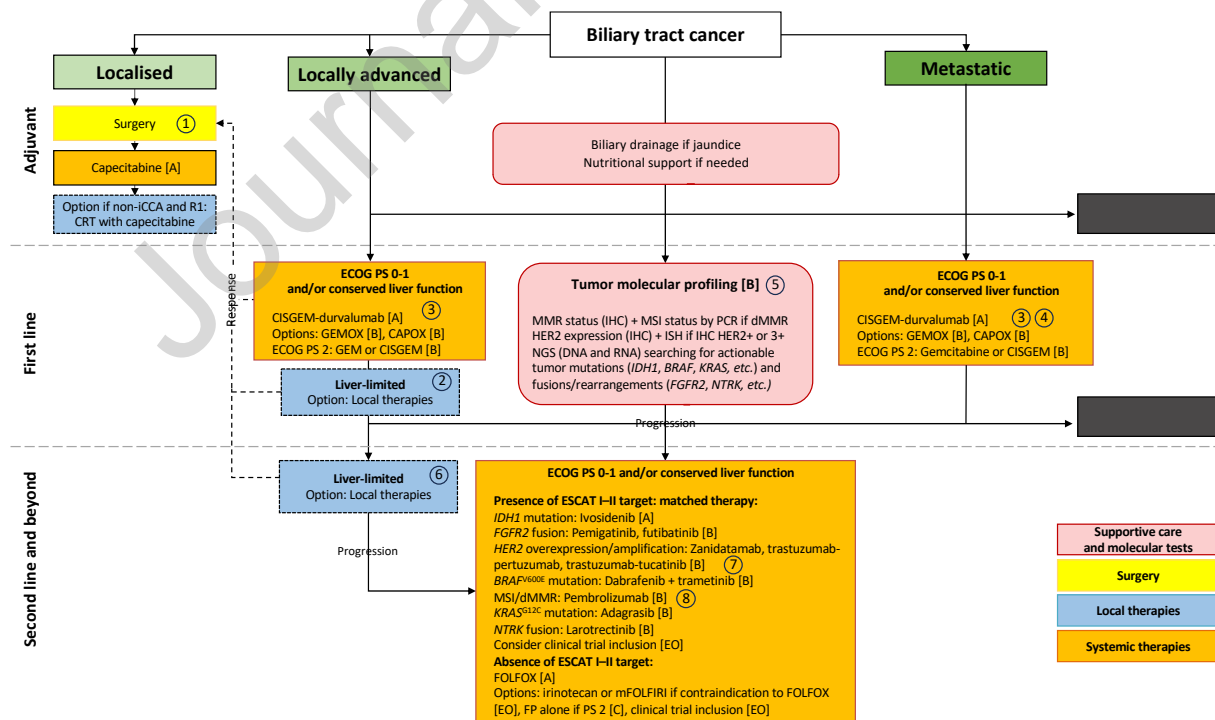


Table 1. Grade of recommendations.

Grade	Quality of evidence	Definition
A	High	Strongly recommended based on highly robust scientific evidence (e.g. several randomised controlled trials/meta-analysis). Further research is very unlikely to change our confidence in the estimate of effect.
B	Moderate	Usually recommended based on scientific presumption (e.g. one randomised controlled trial). Further research is likely to have an important impact on our confidence in the estimate of effect and may change the estimate.
C	Low	Option based on weak scientific evidence (e.g. one or several non-randomised trials). Further research is very likely to have an important impact on our confidence in the estimate of effect and is likely to change the estimate.
D	Very low	Expert opinion (agreement or not). Any estimate of effect is very uncertain.

Table 2. Biliary tract cancers: diagnostic and pretherapeutic work-up.

Abbreviations: ERCP, endoscopic retrograde cholangiopancreatography; FDG PET, fluorodeoxyglucose positron emission tomography; FNA, fine-needle aspiration; FNB, fine-needle biopsy; GI, gastrointestinal; IHC, immunohistochemistry; Ig, immunoglobulin; LT, liver transplantation; MR, magnetic resonance; TAP CT, thoraco-abdomino-pelvic computed tomography.

Examinations	Indications and Objectives
CT	TAP CT: first intention examination; should be performed before any endobiliary procedure. Liver volumetry prior to major hepatectomy.
Liver MR imaging	Should be performed in the absence of extrahepatic metastases to explore resectability before any endobiliary procedure. Resectable iCCA: should include diffusion and gadolinium-enhanced sequences.
MR cholangiography	pCCA and dCCA: should be performed before any endobiliary procedure
Liver biopsy	iCCA: <ul style="list-style-type: none"> • Biopsy of tumor and non-tumor liver parenchyma to search for underlying liver disease • If histology inconclusive, IHC study with CK7, CK20, CDX2/SATB2, TTF1, GATA3 (female); CRP as 2nd-line test pCCA: not recommended in the absence of metastasis.
ERCP	pCCA and dCCA: not recommended if biliary drainage not necessary. If performed: <ul style="list-style-type: none"> • Combine biliary brushing (with thin-layer cytology) and endobiliary biopsies (cytobloc technique ideally) • If samples are negative or atypical: rapid cytological review by expert pathologist • If diagnosis remains uncertain: 2nd ERCP in a specialised center with brushing, biopsies and cholangioscopy
Endoscopic ultrasonography	pCCA and dCCA - Resectable/transplantable tumor in an operable patient:

	<ul style="list-style-type: none"> ▪ FNA/FNB of the primary tumor must be discussed with an expert hepatobiliary surgeon due to the theoretical risk of tumor dissemination ▪ FNA/FNB of any suspicious lymph node - Unresectable/untransplantable tumour or inoperable patient: FNA/FNB of the primary tumour or suspicious lymph node(s) possible.
Cholangioscopy	Not recommended as 1 st -intention procedure
GI tract endoscopies	May be considered for differential diagnosis (iCCA).
FDG-PET	Not routinely recommended for extension work-up. May be considered for differential diagnosis.
IgG4 (serum assay, IHC)	May be considered for differential diagnosis (pCCA and dCCA)
Biological liver tests	Liver function evaluation (prothrombin time, albumin, bilirubin, etc) recommended, especially in iCCA
Laparoscopy	To be discussed if resection is envisaged (without delaying it), particularly if high risk of non-resectability

Table 3. Biliary tract cancers: therapeutic recommendations and options.

Options are figured in italics.

Abbreviations: best supportive care, BSC; CAP, Compassionate Access Programme; CBD, common bile duct; CISGEM, cisplatin and gemcitabine; CRT, chemoradiotherapy; dCCA, distal cholangiocarcinoma; EAP, Early Access Programme; EO, Experts' opinion; ESCAT, ESMO Scale for Clinical Actionability of Molecular Targets; ESMO, European Society of Medical Oncology; FGFR2, fibroblast growth factor receptor 2; GBC, gallbladder carcinoma; HER2, human epidermal growth factor receptor 2; iCCA, intrahepatic cholangiocarcinoma; IDH1, isocitrate dehydrogenase 1; IHC, immunohistochemistry; ISH, in situ hybridisation; MSI/dMMR, microsatellite instability/mismatch repair deficiency; N/A, not available; NGS, next-generation sequencing; NTRK, neurotrophic tyrosine receptor kinase; pCCA, perihilar cholangiocarcinoma; PCR, polymerase chain reaction; PD1, programmed cell death 1; PS, Eastern Cooperative Oncology Group (ECOG) performance status; SBRT, stereotactic body radiation therapy; SIRT, selective internal radiation therapy; TACE, trans-arterial chemo-embolisation.

Recommendations & Options		Level of evidence	
Localised/resectable BTC			
Neoadjuvant treatment	Should only be performed in the context of a clinical trial. If an initially inoperable tumour responds to first-line therapy, resection/ablation should be re-discussed.	C	
Surgery/transplantation/ablation	iCCA	R0 resection (margins ≥ 10 mm) of invaded liver segments + lymphadenectomy (≥ 6 nodes)	C
		<i>Single iCCA <3 cm, no extrahepatic disease: percutaneous thermal ablation if surgery not possible</i>	C
		<i>iCCA <5 cm, no extrahepatic disease: SBRT may be discussed if resection/ablation not feasible</i>	C
	pCCA	En-bloc resection of CBD and superior biliary convergence + hepatectomy including segments I and IVb + pedicle lymphadenectomy \pm vascular resection/reconstruction	C
		<i>≤ 3 cm, N0 and unresectable: liver transplantation acceptable as part of a Mayo Clinic-type preoperative protocol (CRT, exploratory laparotomy / laparoscopy)</i>	B
	dCCA	CBD middle third: CBD resection + pedicle lymphadenectomy	C
		CBD lower third: pancreatoduodenectomy + pedicle lymphadenectomy	C
	GBC	Tis, T1a: cholecystectomy (lymph node dissection not recommended if gallbladder is intact)	B
		T1b, T2: cholecystectomy + resection of segments IVb-V (tumour invading only the gallbladder bed and <20 mm) + pedicle lymph node dissection	B
<i>T3 or N+: benefit of surgery not demonstrated. Cholecystectomy + MBD resection + resection of invaded liver segments + pedicle lymphadenectomy \pm vascular resection/reconstruction</i>		B	

Adjuvant treatment	Adjuvant capecitabine within 16 weeks after surgery and for 24 weeks (8 cycles) in ECOG PS 0-1 patients with iCCA/pCCA/dCCA/GBC, > pT1, R0 or R1		B	
	<i>Adjuvant CRT with capecitabine after 4 to 6 months of adjuvant capecitabine may be discussed after R1 resection of pCCA/dCCA/GBC</i>		EO	
Locally advanced (unresectable) and metastatic BTC				
Biliary drainage	Endoscopic and/or percutaneous drainage if symptoms related to jaundice or if needed before starting antitumor therapy		A	
Molecular tumour profiling	Systematic tumour molecular profiling within first line, to identify: <ul style="list-style-type: none"> - MSI/dMMR (IHC, PCR; MSI/dMMR on NGS should be confirmed by IHC/PCR) - HER2 overexpression/amplification (IHC, ± ISH if IHC 2+; <i>HER2</i> amplification on NGS should be confirmed by IHC/ISH) - Targetable mutations (including <i>IDH1</i>, <i>BRAF</i>, <i>KRAS</i>) (DNA or RNA NGS) - Targetable fusions/rearrangements (including <i>FGFR2</i> and <i>NTRK</i>) (RNA NGS) 		B	
First line	Always consider inclusion in a clinical trial		EO	
	Preserved liver function	PS 0-1	CISGEM + durvalumab (EAP) or pembrolizumab (no access) CISGEM if contraindication to immunotherapy	A
			<i>GEMOX if contraindication to cisplatin</i> <i>CAPOX if contraindication to gemcitabine</i>	B
			<i>Hepatic intra-arterial treatments (SIRT, TACE, hepatic arterial chemotherapy) and SBRT may be discussed in unresectable iCCA (or in inoperable patients) without extrahepatic disease in addition to standard systemic therapy</i>	C
	PS 2	Single-agent gemcitabine (or CISGEM)	B	

	Altered liver function or PS 3-4	Exclusive BSC	EO
Second line and beyond	Always consider inclusion in a clinical trial		EO
	Targetable tumour molecular alteration (and PS 0-2)		
	- <i>IDH1</i> mutation: ivosidenib (reimbursed)		A
	- <i>FGFR2</i> fusion/rearrangement: pemigatinib (reimbursed), futibatinib (no access)		B
	- <i>HER2</i> amplification/overexpression: zanidatamab (CAP), trastuzumab + pertuzumab (no access), trastuzumab + tucatinib (no access), FOLFOX + trastuzumab (no access; no expert consensus)		B
	- <i>BRAF</i> ^{V600E} mutation: dabrafenib + trametinib (no access)		B
	- MSI/dMMR: pembrolizumab (no access) (if no anti-PD1/PDL-1 therapy in first line)		B
	- <i>KRAS</i> ^{G12C} mutation: adagrasib (no access)		C
	- <i>NTRK</i> fusion: larotrectinib (no access)		B
	No targetable tumour molecular alteration		
	Preserved liver function	PS 0-1	FOLFOX
<i>mFOLFIRI (or irinotecan) if contraindication to FOLFOX</i>			EO
<i>Hepatic arterial treatments (SIRT, TACE, hepatic arterial chemotherapy) and SBRT may be discussed in unresectable iCCA (or in inoperable patients) without extrahepatic disease</i>			C
PS 2		Single-agent fluoropyrimidine	C
	Altered liver function or PS 3-4	Exclusive BSC	EO
Secondary resection/ablation	<i>Resection/ablation should be discussed in case of tumour response of initially unresectable disease</i>		EO

Table 4. Precision medicine in cholangiocarcinoma: ESCAT-I alterations and their matched targeted therapies.

ESCAT tier, FDA/EMA approvals and availability in France are given as of December 2023.

Abbreviations: BTC, biliary tract cancer; CAP, Compassionate Access Program; dCCA, distal cholangiocarcinoma; EAP, Early Access Programme; EMA, European Medicines Agency; ESCAT, ESMO Scale for Clinical Actionability of Molecular Targets; ESMO, European Society of Medical Oncology; FDA, Food and Drug Administration; FGFR2, fibroblast growth factor receptor 2; GBC, gallbladder carcinoma; HER2, human epidermal growth factor receptor 2; iCCA, intrahepatic cholangiocarcinoma; IDH1, isocitrate dehydrogenase 1; MSI/dMMR, microsatellite instability/mismatch repair deficiency; NTRK, neurotrophic tyrosine receptor kinase; pCCA, perihilar cholangiocarcinoma.

* Breakthrough therapy designation.

** Orphan designation.

*** Tumour-agnostic approval.

Gene alteration	ESCAT tier	Frequency Preferential BTC subtypes	Drug name [key study reference]	Approval (BTC)		Availability in France
				FDA	EMA	
<i>IDH1</i> mutation	I-A	10-20% iCCA	Ivosidenib [129]	Yes	Yes	EAP
<i>FGFR2</i> fusions/ rearrangements	I-B	10-15% iCCA	Pemigatinib [132]	Yes	Yes	Reimbursed
			Futibatinib [138]	Yes	Yes	-
<i>HER2</i> overexpression/amplification	I-C	10-15% pCCA/dCCA/ GBC > iCCA	Trastuzumab- pertuzumab [140]	-	-	-
			FOLFOX- trastuzumab [142]	-	-	-

			Trastuzuma b- deruxtecan [141]	Yes*,* **	-	-
			Trastuzuma b-tucatinib [144]	-	-	-
			Zanidatama b [160]	Yes*	Yes* *	CAP
MSI/dMMR	I-C	<1%	Pembrolizu mab [146]	Yes** *	Yes* **	Denied
NRTK fusions	I-C	<1%	Larotrectinib [148]	Yes** *	Yes* **	-
			Entrectinib [149]	Yes** *	Yes* **	-
RET fusions	I-C	1%	Pralsetinib [154]	-	-	-
			Selpercatini b [153]	Yes** *	-	-
BRAF^{V600E} mutation	II-B	<5%	Dabrafenib- Trametinib [156]	Yes** *	-	-
KRAS^{G12C} mutation	II-B	1%	Adagrasib [161]	-	-	-

Declaration of Competing Interest

The authors declare that they have no known competing financial interests or personal relationships that could have appeared to influence the work reported in this paper.

The authors declare the following financial interests/personal relationships which may be considered as potential competing interests:

Gael Roth declares consulting or advisory role or invitation as a speaker for Servier, AstraZeneca, Bristol-Myers Squibb, MSD, Amgen, Ipsen, Accord Healthcare, Pierre Fabre, Incyte, Netris Pharma and Alpha Tau, as well as travel accommodations, or expenses from Servier, AstraZeneca, Bristol Myers Squibb, MSD, Roche, Amgen, Viartis, Pierre Fabre and Ipsen. Research funding by Genoscience Pharma, Netris Pharma.

Matthieu Sarabi declares consultancy/honoraria AstraZeneca, Servier, Roche and accommodations or expenses from Ipsen.

Jean-Frédéric Blanc declares declares honoraria from incyte, servier, AZ, Roche, Tahio oncology, MSD.

Anne-Laure Bretagne-Bignon declares consulting for Astra Zeneca, Servier, Ipsen and accommodations or congress registration support for Merck and Ipsen.

Romain Coriat declares honoraria for lectures and Advisory board for: BAYER, Servier, Pierre Fabre, AAA, Merck, Amgen.

Christelle de la Fouchardière declares holding an advisory role with Amgen, Bayer, BMS, Daichi-Sankyo, Eisai, Imescia, Incyte, Lilly, Merck, MSD, Pierre Fabre Oncologie, Roche, and Servier; receiving grants from Pierre Fabre and Servier outside of the submitted work; receiving fees from Ipsen, Eisai, Pierre Fabre, Servier, being an invited speaker outside of the submitted work.

Julien Edeline declares consulting or advisory role for BTG, Bristol Myers Squibb, AstraZeneca, Bayer, Ipsen, AstraZeneca, MSD, Eisai, Boston Scientific, Roche, Basilea, Merck Serono, Servier ; research Funding from Bristol Myers Squibb (Inst), BeiGene (Inst); travel, accommodations or expenses from Amgen, Bristol Myers Squibb, Roche.

Astrid Lièvre declares honoraria for lectures from Amgen, Astellas, Astra-Zeneca, Bayer, BMS, Incyte, Ipsen, Leo-pharma, Mylan, Novartis, Pierre Fabre, Roche, Servier and Viatris; consulting/advisory relationship from AAA, Astellas, Bayer, BMS, Incyte, Pierre Fabre and Servier; travel, accommodations or congress registration support from Bayer, Boehringer, Ipsen, Mylan, MSD, Pierre Fabre, Roche and Servier; research funding from Bayer (Inst), Lilly (Inst)

Sylvain Manfredi declares travel accommodation from MSD, AMGEN.

Cindy Neuzillet declares Honoraria and consulting from Amgen, AstraZeneca, Baxter, Bristol-Myers Squibb, Fresenius Kabi, Incyte Biosciences, Merck, MSD, Mundipharma, Novartis, Nutricia, OSE Immunotherapeutics, Pierre Fabre, Roche, Sanofi, Servier, Viatris, as well as research funding AstraZeneca, Bristol-Myers Squibb, Fresenius Kabi, Nutricia, OSE Immunotherapeutics, Roche, Servier, Viatris

Valérie Paradis declares honoraria for lectures from Incyte.

Anthony Turpin declares personal fees from Servier, Viatris, Incyte Bioscience, BMS, Merck and grants and personal fees from AstraZeneca and MSD.

Olivier Bouché declares consulting or advisory role for Pierre Fabre, Amgen, Bayer, Servier, MSD, Deciphera, Apmonia Therapeutics and Merck outside the submitted work.

David Malka declares honoraria for Roche, Amgen, Bayer, Merck Serono, Servier, Sanofi, Pierre Fabre, Viatris, Bristol Myers Squibb, MSD Oncology, LEO Pharma, Incyte, AstraZeneca; consulting or advisory role: Roche, Sanofi, Merck Serono, MSD, Servier, Bayer, Incyte, Amgen, Bristol Myers Squib, Taiho Oncology, AbbVie, AstraZeneca, Pierre Fabre; travel, accommodations or expenses from Roche, Bayer, Sanofi, Merck Serono, Amgen, Servier, Pierre Fabre, Bristol Myers Squibb/Pfizer, MSD, Viatris

All remaining authors have declared no conflicts of interest.

Highlights

- Surgical management of BTC depends on subtype
- CISGEM plus anti-PD1/PDL1 inhibitor is the first-line standard-care in advanced BTC
- Tumor molecular profiling should be performed at the diagnosis of advanced BTC
- Molecular profiling should search for actionable alterations (IDH1, FGFR2, etc.)