



HAL
open science

Complete remission after a single bisphosphonate infusion in isolated bone Langerhans cell histiocytosis lesion: a case report and a narrative review of the literature

Alexandra Kachaner, Raphaèle Seror, Fleur Cohen Aubart, Julien Henry, Thierry Lazure, Jean François Emile, Xavier Mariette, Samuel Bitoun

► To cite this version:

Alexandra Kachaner, Raphaèle Seror, Fleur Cohen Aubart, Julien Henry, Thierry Lazure, et al.. Complete remission after a single bisphosphonate infusion in isolated bone Langerhans cell histiocytosis lesion: a case report and a narrative review of the literature. *JBMR Plus*, 2024, 8 (5), pp.ziae043. 10.1093/jbmrpl/ziae043 . hal-04626829

HAL Id: hal-04626829

<https://hal.science/hal-04626829v1>

Submitted on 10 Jul 2024

HAL is a multi-disciplinary open access archive for the deposit and dissemination of scientific research documents, whether they are published or not. The documents may come from teaching and research institutions in France or abroad, or from public or private research centers.

L'archive ouverte pluridisciplinaire **HAL**, est destinée au dépôt et à la diffusion de documents scientifiques de niveau recherche, publiés ou non, émanant des établissements d'enseignement et de recherche français ou étrangers, des laboratoires publics ou privés.



Distributed under a Creative Commons Attribution - NonCommercial 4.0 International License

Complete remission after a single bisphosphonate infusion in isolated bone Langerhans cell histiocytosis lesion: a case report and a narrative review of the literature

Alexandra Kachaner^{1,*}, Raphaèle Seror¹, Fleur Cohen Aubart², Julien Henry¹, Thierry Lazure³, Jean François Emile⁴, Xavier Mariette¹, Samuel Bitoun¹

¹Department of Rheumatology, Paris Saclay University, Bicêtre Hospital, AP-HP, FHU Care, Le Kremlin Bicêtre 94270, France

²Internal Medicine Department 2, French National Referral Center for Rare Systemic Diseases and Histiocytosis, Sorbonne University AP-HP, Pitié-Salpêtrière Hospital, INSERM UMRS-1135 Team 7, Paris 75013, France

³Department of Pathology, Paris Saclay University, Bicêtre Hospital, AP-HP, Le Kremlin Bicêtre 94270, France

⁴Paris-Saclay University, Versailles SQY University, EA4340-BECCOH, Assistance Publique-Hôpitaux de Paris (AP-HP), Ambroise-Paré Hospital, Smart Imaging, Service de Pathologie, Boulogne 92100, France

*Corresponding author: Alexandra Kachaner, Department of Rheumatology, Paris Saclay University, Bicêtre Hospital, AP-HP, FHU Care, France (Alexandra.kachaner@gmail.com)

Abstract

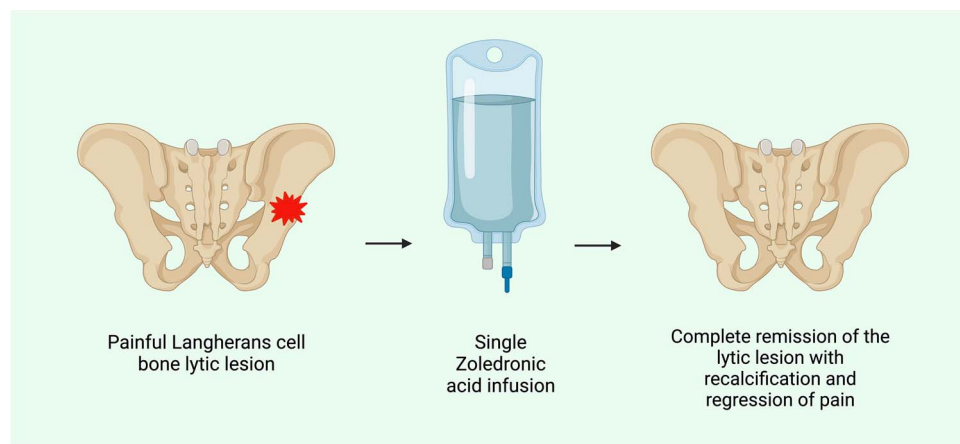
Langerhans cell histiocytosis (LCH) is a rare disease with limited treatment options. We present a case involving a 57-year-old woman afflicted with an isolated LCH bone osteolytic lesion. A single bisphosphonate infusion significantly alleviated pain, and follow-up scans via CT, PET-CT, and MRI revealed a substantial recalcification of the lesion. Conducting an extensive literature review, we identified 46 cases documenting the efficacy of bisphosphonates in the context of LCH. These findings have raised interest in bisphosphonate infusion as a simple therapeutic alternative in similar situations, with benefits in terms of bone recalcification and pain control for individuals with LCH.

Keywords: histiocytosis, Langerhans cell histiocytosis, bisphosphonates, bone lesion, review, case report

Lay Summary

Langerhans cell histiocytosis (LCH) is a rare disease with limited treatment options. We reported the case of a 57-year-old woman with an isolated LCH bone osteolytic lesion. The pain was greatly reduced, and the precise CT, PET-CT, and MRI follow-up scans showed recalcification the lesion after 1 single bisphosphonate infusion bot. A literature review was performed and it identified 46 cases of reported efficacy of bisphosphonates in LCH.

Graphical Abstract



Langerhans cell histiocytosis (LCH) is a rare disease that can affect all organs and particularly the bones, skin, lungs, and central nervous system. Diagnosing LCH might be

challenging due to its rarity and polymorphic presentation, and this relies on histological findings from a lesion on a biopsy done with the expertise of trained pathologists. On

Received: December 28, 2023. Revised: February 12, 2024. Accepted: February 15, 2024

© The Author(s) 2024. Published by Oxford University Press on behalf of the American Society for Bone and Mineral Research.

This is an Open Access article distributed under the terms of the Creative Commons Attribution Non-Commercial License (<https://creativecommons.org/licenses/by-nc/4.0/>), which permits non-commercial re-use, distribution, and reproduction in any medium, provided the original work is properly cited. For commercial re-use, please contact journals.permissions@oup.com

imaging studies, differential diagnosis of a single lytic lesion may include plasmocytoma, primary bone tumors, and fibrous dysplasia. Management of patients is mainly based on expert consensus.¹

The LCH results from the acquisition of a gain-of-function somatic genetic reassortment in the mitogen-activated protein kinases pathway and has a typical histology with CD1a + and CD207+ cells admixed with inflammatory cells, including eosinophils.² Clinical involvement varies from an isolated indolent lesion to an aggressive multisystemic disease.³ The LCH treatment mainly relies on systemic chemotherapy for patients with multisystem disease and observation or local treatment such as surgery or radiotherapy for patients with single lesion.^{1,2} In case of isolated bone lesion, bisphosphonates have been occasionally used in some cases, with mitigated outcomes. In other rare diseases with lytic bones lesions, such as Gorham Stout syndrome, Mazabraud syndrome, and other forms of bone fibrous dysplasia, bisphosphonates have been observed to stimulate bone turn over markers,⁴ to relieve pain and slow disease progression in some case series.⁵⁻⁸

A 57-year-old non-smoking female was referred to the rheumatology department in April 2021 for a right inguinal pain (VAS 7/10) lasting for 2 months and causing discomfort and walking difficulties. Her medical history revealed an anxiety disorder and gastroesophageal reflux. She had no fever, no weight loss, and no constitutional symptoms. The clinical examination revealed no hip pain. The X-ray of the pelvis was normal, as well as the biological work-up, including calcemia, serum protein electrophoresis, and acute phase reactants. The CT scan showed a purely lytic lesion of the middle branch of the right iliac wing (Figure 1A). The MRI displayed T1 hyposignal, T2 hypersignal of the lesion with oedema extended to adjacent muscles (Figure 1G). A biopsy was performed, and histological examination showed, within a polymorphic inflammatory infiltrate, cells with “coffee bean” nucleus, and it was positive for CD1a and CD207, without *BRAF*^{V600E} mutation (Figure 1I and J). The diagnosis of LCH was made. A ¹⁸F-fluorodeoxyglucose PET (¹⁸F-FDG-PET) found hypermetabolism of the lesion (Figure 1D) and no other bone lesions, but a worsening of the lesion with a fracture (Figure 1B). A brain MRI revealed an ischemic cerebellar lesion corresponding to a previous asymptomatic stroke and no other abnormality. The thoracic CT was normal. The diagnosis of isolated bone LCH was confirmed. Due to insufficient control of pain with analgesic and NSAIDs (diclofenac 75 mg BID), the patient received a bisphosphonate infusion of zoledronic acid (4 mg). Two months later, the NSAIDs could be stopped with stable pain. Five months later, the pain dramatically improved and the follow-up ¹⁸F-FDG-PET CT scan showed a complete metabolic response (Figure 1E). The CT scan also showed recalcification of the lesion (Figure 1C) and MRI showed a major improvement of the lesion (Figure 1H). At the latest outpatient visit, 2 years after treatment, she had no pain and persistence metabolic remission on TEP CT (Figure 1F), which confirmed persistent remission without further treatment.

Bisphosphonates inhibit osteoclastic activity.⁹ The rationale for the efficacy of bisphosphonates in LCH is based on the expression of RANKL and other osteoclast differentiation markers by cells in the lesion, which recruits osteoclast-like mononuclear giant cells that secrete osteoclastic factors.¹⁰ The RANKL represents a promising therapeutic target, given its

pronounced expression in active LCH lesions. Anti-RANKL treatment has demonstrated a 80% response rate in a phase II trial, highlighting its potential as an effective intervention.^{11,12} Interestingly, some patients with active LCH exhibit reduced BMD on X-ray absorptiometry. This phenomenon may be attributed to a global increase in bone turnover, given that bone marrow density was found to be lower in patients with active disease compared to controls and those with inactive disease.¹³ In a mouse model of LCH, a bisphosphonate infusion prevented the occurrence of bone lesions.¹⁴ These results are additional arguments for the use of bisphosphonates in this disease.

Previous reports of the efficacy of bisphosphonates in LCH (Table 1), suggested a benefit in terms of pain, functional improvement, and several cases of complete remission in the absence of other treatment.¹⁵⁻²⁵ Some of them even reported a beneficial effect of bisphosphonates on skin and soft tissue involvement.^{15,16} Forty-six patients were reported in 11 articles, 38 with multiple bone lesions and 8 with single bone lesions. Mainly, i.v. bisphosphonates were used, and these were principally pamidronate ($n=23$, 50%). Most patients responded to i.v. treatment with 19/23 with pamidronate and 9/15 for zoledronic acid (6/15 missing data), the most published regimen. Use of concomitant chemotherapy was scarce (4/45). Bisphosphonates appeared to have an analgesic effect when the effect on pain was assessed (14/14), and no active disease was reported just after bisphosphonates infusion in 34/38 patients. Radiological improvement with reduction of lesions and recalcifications was observed in 25/28 patients. Patients frequently had multisystem involvement, but bisphosphonates appeared to be ineffective in extraosseous damage, with only 1 case describing clinical improvement in extraosseous disease (soft tissues and skin lesions in 1 patient treated with pamidronate). Data concerning the risk of relapse are scarce. In a series of 13 patients, 10/13 maintained remission with no active disease for a median of 3.5 years [0.8–5].¹⁵ Another study showed a progression-free survival of $56.3 \pm 12.4\%$ at 3 years in 16 children treated with pamidronate.¹⁶ These data suggest long-term remission after bisphosphonate therapy.

In LCH, spontaneous remission might occur, but it seems to be infrequent. A few cases have been reported.¹³⁻¹⁵ Thus, it cannot be excluded that it occurred in our patient. Another potential scenario involves the healing of the LCH lesion through the biopsy procedure itself by triggering osteoblastic activity, similar to the reparative process observed after a fracture.²⁶ However, the aggravation of clinical signs and the radiological progression seen in the two months leading up to the zoledronic acid infusion, together with the swift improvement thereafter, make this last hypothesis unlikely.

Given the presence of several reports of dramatic efficacy and a pathophysiological rationale, bisphosphonates and anti-RANKL agents are good candidates to treat isolated bone involvement which are frequent and may require low toxicity treatments. Thus, it would seem useful to evaluate this treatment in a prospective study in LCH patients with predominantly bone involvement. The LCH is a disease for which few treatments have shown any benefit, which can be partly explained by the rarity of this condition¹⁻³. Finally, the integration of studies of bone turnover markers and phosphocalcium metabolism would provide valuable insights, further enhancing our understanding of the mechanisms underlying the action of bisphosphonates in this particular condition.

Table 1. Main characteristics of published cases of Langerhans cell histiocytosis treated by bisphosphonates.

Type of bisphosphonate	Author, year	Number of patients Sex ratio (F/M) Age—median (IQR)	Organs involved	Number of bisphosphonates administration if i.v.—median (IQR)—or duration of treatment if PO (months)	Clinical response	No active disease after treatment at last assessment	Extra-osseous lesion improvement	Bone lesion: imaging improvement	Bone lesion: pain regression	Chemotherapy concomitant to bisphosphonate treatment
Pamidronate (i.v.)	Takpradit, 2015 ⁹	23	MBL (18/23), single bone lesion (5/23)	6 infusions ²⁻⁵ administered monthly	Complete (2/23)	Yes (18/22)	Yes (1/4)	Yes (4/6)	Yes (3/3)	Yes (4/23)
	Chellapandian, 2016 ⁶	F8/M15	bone lesion (5/23)		Partial (17/23)	N/A (1/23)	N/A (19/23)	N/A (17/23)	N/A (20/23)	No (18/23)
	Arzo, 2001 ¹¹	8 years ⁴⁻¹³	skin (4/23), soft tissues (5/23), DI (3/23), neurological involvement (2/23)		None (4/23)					N/A (1/23)
	Farran, 2001 ¹² Morimoto, 2011 ⁷									
Zoledronate (i.v.)	Chellapandian 2016 ⁶	15	MBL (12/15), single bone lesion (3/15), DI (6/15), lungs (1/15)	1 infusion ¹⁻¹²	Partial (8/15)	Yes (8/8)	N/A (15/15)	Yes (13/14)	Yes (9/9)	No (15/15)
	Montella, 2009 ¹⁰	F7/M8			None (1/15)	N/A (7/15)		N/A (1/15)	N/A (6/15)	
	Kikkawa, 2013 ¹³	27 years (23-37)			N/A (6/15)					
	Sivendran, 2011 ¹⁴ Tsuda, 2011 ⁸ Chellapandian 2016 ⁶	4	MBL (4/4), skin (1/4) and DI (2/4)	5 months (1/4) N/A (3/4)	Complete (1/4) Partial (3/4)	Yes (4/4)	Yes (0/2) N/A (2/4)	Yes (4/4)	N/A (4/4)	No (4/4)
Etidronate (PO)	Kamizono, 2002 ¹⁵	2	MBL (2/2), skin (2/2), adenopathy (2/2)	6 months ⁶	Partial (2/2)	Yes (2/2)	N/A (2/2)	Yes (2/2)	N/A (2/2)	No (2/2)
		F2/M0								
Clodronate (PO)	Elomaa, 1989 ¹⁶	2	MBL (2/2), DI (1/2) and hypopituitarism (1/2)	6 months (2/2)	None (2/2)	Yes (2/2)	N/A (2/2)	Yes (2/2)	Yes (2/2)	No (2/2)
		F1/M1								

Abbreviations: DI: diabetes insipidus; MBL: multiple bone lesions; N/A: not available.

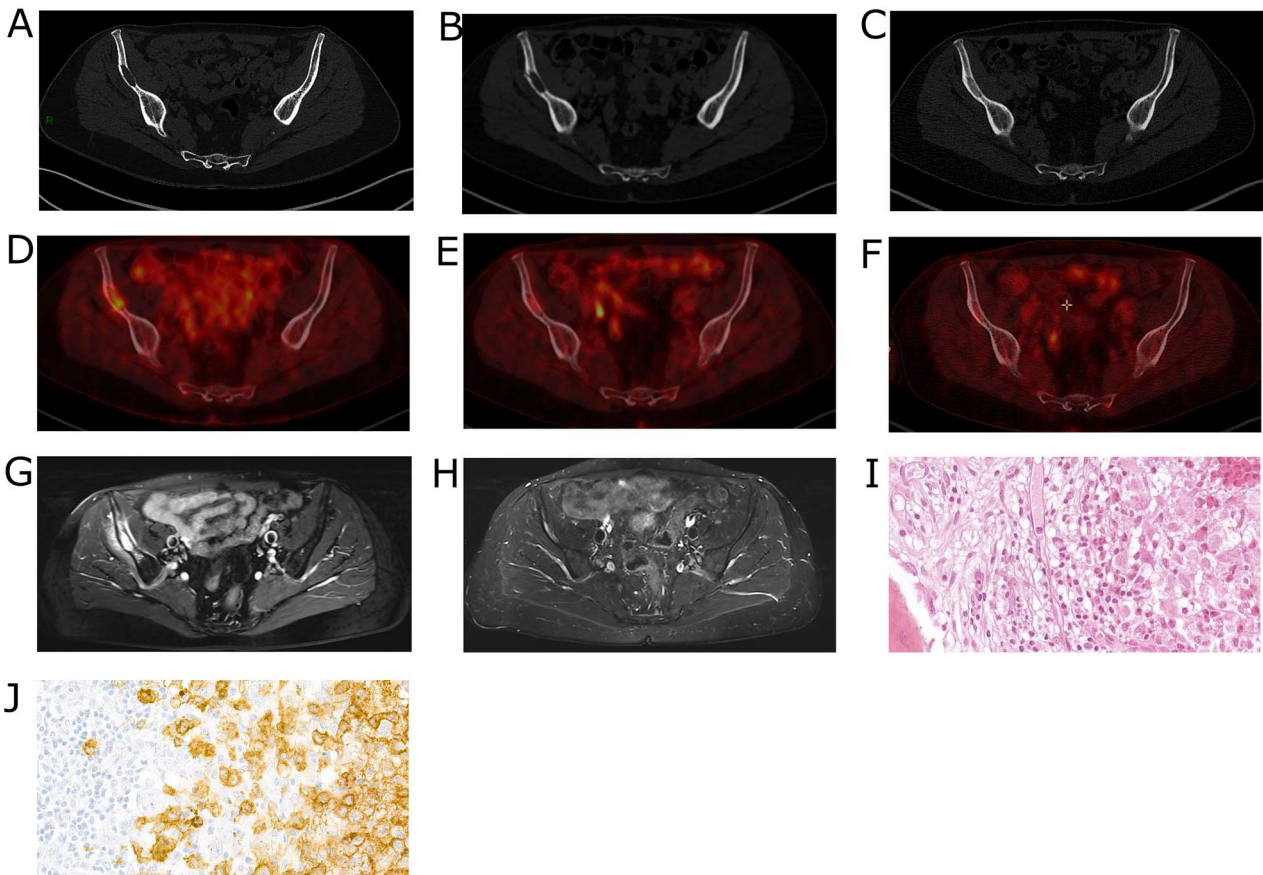


Figure 1. Histiocytosis bone involvement with complete remission after 1 single infusion of bisphosphonate CT scan: (A) before treatment, (B) before treatment with worsening with fracture, and (C) after treatment, showing recalcification of the lesion. PET CT (D) before treatment and (E) after treatment showed recalcification and metabolic response (F) 2 years after treatment. (G) T2 fat sat MRI before treatment, (H) STIR MRI after treatment showing improvement of the lesion, (I) H&E-stained section of the bone biopsy, and (J) anti-CD1a staining of the histiocytes within the bone lesion.

Acknowledgements

A.K. and S.B. analyzed the data and wrote the paper. T.L. and J.F.E. analyzed the histological data. X.M., F.C.A., R.S., J.H., T.L., and J.F.E. gave expert advices and added corrections to the manuscript.

Author contributions

Alexandra Kachaner (Conceptualization, Data curation, Writing—original draft, Writing—review & editing), Raphaelae Seror (Conceptualization, Data curation, Supervision, Writing—review & editing), Fleur Cohen Aubart (Validation, Writing—review & editing), Julien Henry (Data curation, Validation, Writing—review & editing), Thierry Lazure (Resources, Validation, Writing—review & editing), Jean François Emile (Resources, Writing—review & editing), Xavier Mariette (Conceptualization, Validation, Writing—review & editing), and Samuel Bitoun (Conceptualization, Data curation, Investigation, Resources, Validation, Writing—review & editing).

Funding

None declared.

Conflicts of interest

None declared.

Data availability

Data are accessible upon reasonable request.

Patient consent statement

Written consent was obtained from the patient.

References

- Goyal G, Tazi A, Go RS, et al. International expert consensus recommendations for the diagnosis and treatment of Langerhans cell histiocytosis in adults. *Blood*. 2022;139(17):2601–2621. <https://doi.org/10.1182/blood.2021014343>.
- Emile JF, Cohen-Aubart F, Collin M, et al. Histiocytosis. *Lancet*. 2021;398(10295):157–170. [https://doi.org/10.1016/S0140-6736\(21\)00311-1](https://doi.org/10.1016/S0140-6736(21)00311-1).
- Rodriguez-Galindo C, Allen CE. Langerhans cell histiocytosis. *Blood*. 2020;135(16):1319–1331. <https://doi.org/10.1182/blood.2019000934>.
- Jreige M, Hall N, Becce F, et al. A novel approach for fibrous dysplasia assessment using combined planar and quantitative SPECT/CT analysis of Tc-99m-diphosphonate bone scan in correlation with biological bone turnover markers of disease activity. *Front Med*. 2022;9:1050854. <https://doi.org/10.3389/fmed.2022.1050854>.
- Liu Y, Zhong DR, Zhou PR, et al. Gorham-Stout disease: radiological, histological, and clinical features of 12 cases and review of literature. *Clin Rheumatol*. 2016;35(3):813–823. <https://doi.org/10.1007/s10067-014-2780-2>.
- Schneider KN, Masthoff M, Gosheger G, et al. Gorham-Stout disease: good results of bisphosphonate treatment in 6 of 7 patients. *Acta Orthop*. 2020;91(2):209–214. <https://doi.org/10.1080/17453674.2019.1709716>.

7. Wu D, Ma J, Bao S, Guan H. Continuous effect with long-term safety in zoledronic acid therapy for polyostotic fibrous dysplasia with severe bone destruction. *Rheumatol Int.* 2015;35(4):767–772. <https://doi.org/10.1007/s00296-014-3132-x>.
8. Lane JM, Khan SN, O'Connor WJ, et al. Bisphosphonate therapy in fibrous dysplasia. *Clin Orthop Relat Res.* 2001;382:6–12. <https://doi.org/10.1097/00003086-200101000-00003>.
9. Drake MT, Clarke BL, Khosla S. Bisphosphonates: mechanism of action and role in clinical practice. *Mayo Clin Proc.* 2008;83(9):1032–1045. <https://doi.org/10.4065/83.9.1032>.
10. da Costa CET, Annelis NE, Faaij CMJM, Forsyth RG, Hogendoorn PCW, Egeler RM. Presence of osteoclast-like multinucleated giant cells in the bone and nonostotic lesions of Langerhans cell histiocytosis. *J Exp Med.* 2005;201(5):687–693. <https://doi.org/10.1084/jem.20041785>.
11. Makras P, Salagianni M, Revelos K, et al. Rationale for the application of RANKL inhibition in the treatment of Langerhans cell histiocytosis. *J Clin Endocrinol Metab.* 2015;100(2):E282–E286. <https://doi.org/10.1210/jc.2014-2654>.
12. Makras P, Yavropoulou MP, Chatziioannou SN, et al. Efficacy of denosumab monotherapy among adults with Langerhans cell histiocytosis: a prospective clinical trial. *Am J Hematol.* 2023;98(7):E168–E171. <https://doi.org/10.1002/ajh.26936>.
13. Makras P, Terpos E, Kanakis G, et al. Reduced bone mineral density in adult patients with Langerhans cell histiocytosis: LCH and bone density. *Pediatr Blood Cancer.* 2012;58(5):819–822. <https://doi.org/10.1002/pbc.23166>.
14. Grosjean F, Nasi S, Schneider P, et al. Dendritic cells cause bone lesions in a new mouse model of histiocytosis. Malaval L, editor. *PLoS One.* 2015;10(8):e0133917.
15. Chellapandian D, Makras P, Kaltsas G, et al. Bisphosphonates in Langerhans cell histiocytosis: an international retrospective case series. *Mediterr J Hematol Infect Dis.* 2016;8:2016033. <https://doi.org/10.4084/mjihid.2016.033>.
16. Morimoto A, Shioda Y, Imamura T, et al. Nationwide survey of bisphosphonate therapy for children with reactivated Langerhans cell histiocytosis in Japan: pamidronate for childhood LCH. *Pediatr Blood Cancer.* 2011;56(1):110–115. <https://doi.org/10.1002/pbc.22703>.
17. Tsuda H, Yamasaki H, Tsuji T. Resolution of bone lysis in Langerhans cell histiocytosis by bisphosphonate therapy. *Br J Haematol.* 2011;154(3):287–287. <https://doi.org/10.1111/j.1365-2141.2011.08654.x>.
18. Takpradit C, Vathana N, Narkbunnam N, Sanpakit K, Buaboonnam J. Bisphosphonate therapy for refractory Langerhans cell histiocytosis: a case report. *J Med Assoc Thai.* 2015;98(11):1145–1149.
19. Montella L, Merola C, Merola G, Petillo L, Palmieri G. Zoledronic acid in treatment of bone lesions by Langerhans cell histiocytosis. *J Bone Miner Metab.* 2009;27(1):110–113. <https://doi.org/10.1007/s00774-008-0001-2>.
20. Farran RP, Zaretski E, Egeler RM. Treatment of Langerhans cell histiocytosis with pamidronate. *J Pediatr Hematol Oncol.* 2001;23(1):54–56. <https://doi.org/10.1097/00043426-200101000-00013>.
21. Kikkawa I, Aihara T, Morimoto A, Watanabe H, Furukawa R. Langerhans cell histiocytosis case with dense metaphyseal band sign: LCH case treated with zoledronic acid. *Pediatr Int.* 2013;55(1):96–98. <https://doi.org/10.1111/j.1442-200X.2012.03618.x>.
22. Sivendran S, Harvey H, Lipton A, Drabick J. Treatment of Langerhans cell histiocytosis bone lesions with zoledronic acid: a case series. *Int J Hematol.* 2011;93(6):782–786. <https://doi.org/10.1007/s12185-011-0839-2>.
23. Kamizono J, Okada Y, Shirahata A, Tanaka Y. Bisphosphonate induces remission of refractory Osteolysis in Langerhans cell histiocytosis. *J Bone Miner Res.* 2002;17(11):1926–1928. <https://doi.org/10.1359/jbmr.2002.17.11.1926>.
24. Elomaa I, Blomqvist C, Porkka L, Holmström T. Experiences of clodronate treatment of multifocal eosinophilic granuloma of bone. *J Intern Med.* 1989;225(1):59–61. <https://doi.org/10.1111/j.1365-2796.1989.tb00038.x>.
25. Arzoo K, Sadeghi S, Pullarkat V. Pamidronate for bone pain from osteolytic lesions in Langerhans' cell histiocytosis. *N Engl J Med.* 2001;345(3):225–225. <https://doi.org/10.1056/NEJM200107193450318>.
26. Einhorn TA, Gerstenfeld LC. Fracture healing: mechanisms and interventions. *Nat Rev Rheumatol.* 2015;11(1):45–54. <https://doi.org/10.1038/nrrheum.2014.164>.