



**HAL**  
open science

# Management of Bilateral Vocal Fold Paralysis: A Systematic Review

Jérôme René Lechien, Stéphane Hans, Ted Mau

► **To cite this version:**

Jérôme René Lechien, Stéphane Hans, Ted Mau. Management of Bilateral Vocal Fold Paralysis: A Systematic Review. *Otolaryngology - Head and Neck Surgery*, 2024, 170 (3), pp.724-735. 10.1002/ohn.616 . hal-04626779

**HAL Id: hal-04626779**

**<https://hal.science/hal-04626779v1>**

Submitted on 29 Aug 2024

**HAL** is a multi-disciplinary open access archive for the deposit and dissemination of scientific research documents, whether they are published or not. The documents may come from teaching and research institutions in France or abroad, or from public or private research centers.

L'archive ouverte pluridisciplinaire **HAL**, est destinée au dépôt et à la diffusion de documents scientifiques de niveau recherche, publiés ou non, émanant des établissements d'enseignement et de recherche français ou étrangers, des laboratoires publics ou privés.

# Management of Bilateral Vocal Fold Paralysis: A Systematic Review

Jérôme R. Lechien, MD, PhD, MS<sup>1,2,3,4</sup>,  
 Stéphane Hans, MD, PhD, MS<sup>2</sup>, and Ted Mau, MD, PhD<sup>5</sup>

Otolaryngology–  
 Head and Neck Surgery  
 2024, Vol. 170(3) 724–735  
 © 2023 American Academy of  
 Otolaryngology–Head and Neck  
 Surgery Foundation.  
 DOI: 10.1002/ohn.616  
<http://otojournal.org>

WILEY

## Abstract

**Objective.** To review the current literature about epidemiology, etiologies and surgical management of bilateral vocal fold paralysis (BVFP).

**Data Sources.** PubMed, Scopus, and Cochrane Library.

**Review Methods.** A systematic review of the literature on epidemiology, etiologies, and management of adult patients with BVFP was conducted through preferred reporting items for systematic reviews and meta-analyses statements by 2 investigators.

**Results.** Of the 360 identified papers, 245 were screened, and of these 55 were considered for review. The majority (76.6%) of BVFP cases are iatrogenic. BVFP requires immediate tracheotomy in 36.2% of cases. Laterofixation of the vocal fold was described in 9 studies and is a cost-effective alternative procedure to tracheotomy while awaiting potential recovery. Unilateral and bilateral posterior transverse cordotomy outcomes were reported in 9 and 7 studies, respectively. Both approaches are associated with a 95.1% decannulation rate, adequate airway volume, but voice quality worsening. Unilateral/bilateral partial arytenoidectomy data were described in 4 studies, which reported lower decannulation rate (83%) and better voice quality outcome than cordotomy. Revision rates and complications vary across studies, with complications mainly involving edema, granuloma, fibrosis, and scarring. Selective posterior cricoarytenoid reinnervation is being performed by more surgeons and should be a promising addition to the BVFP surgical armamentarium.

**Conclusion.** Depending on techniques, the management of BVFP may be associated with several degrees of airway improvements while worsened or unchanged voice quality. The heterogeneity between studies, the lack of large-cohort controlled randomized studies and the confusion with posterior glottic stenosis limit the draw of clear conclusion about the superiority of some techniques over others.

## Keywords

head neck surgery, immobility, laryngeal, larynx, nerve, otolaryngology, palsy, paresis, vocal fold paralysis, voice, reinnervation

Received June 22, 2023; accepted November 27, 2023.

**B**ilateral vocal fold paralysis (BVFP) is a neurological condition associated with reduced or absent movement of both vocal folds. BVFP is related to processes affecting the neurological control of vocal fold movement, including neuropathies of the vagus nerve or the recurrent laryngeal nerve (RLN), neuromyopathies, or central neurologic problems.<sup>1</sup> The most frequent etiologies include iatrogenic injury, cancer, or neurological diseases.<sup>2,3</sup> The clinical presentation depends on the functional impairments (paralysis vs paresis) and the position of paralyzed vocal folds, which are in paramedian position in most cases.<sup>4</sup> The reduction of the glottal area results in inspiratory dyspnea and noisy breathing, while reduced vocal fold adduction can lead to dysphonia.<sup>5</sup> Some compromised airways require urgent intervention such as tracheotomy, while the long-term intervention depends on the degree of recovery of active vocal fold abduction. The primary objective of surgery for BVFP is to relieve the dyspnea while maintaining the voice quality as much as possible. A host of endoscopic procedures have been developed for patients with persistent paramedian BVFP and related dyspnea, including laterofixation, partial or total arytenoidectomy, posterior transverse cordotomy, or combined procedures.<sup>5,6</sup> While there is a fair amount of literature on the individual surgical techniques, few papers have attempted to provide an overview of the literature and compare the various techniques.<sup>7</sup> Such a review would be a valuable resource for laryngeal surgeons managing patients with BVFP.

<sup>1</sup>Department of Otolaryngology, Elsan Hospital, Paris, France

<sup>2</sup>Department of Otolaryngology–Head & Neck Surgery, Foch Hospital, School of Medicine, UFR Simone Veil, Université Versailles Saint-Quentin-en-Yvelines (Paris Saclay University), Paris, France

<sup>3</sup>Division of Laryngology and Bronchoesophagology, Department of Otolaryngology Head Neck Surgery, EpiCURA Hospital, UMONS Research Institute for Health Sciences and Technology, Faculty of Medicine, University of Mons (UMons), Mons, Belgium

<sup>4</sup>Department of Otolaryngology–Head & Neck Surgery, CHU Saint-Pierre (CHU de Bruxelles), Brussels, Belgium

<sup>5</sup>Department of Otolaryngology–Head and Neck Surgery, Clinical Center for Voice Care, University of Texas Southwestern Medical Center, Dallas, Texas, USA

## Corresponding Author:

Jérôme R. Lechien, MD, PhD, MS, Department of Otolaryngology and Head and Neck Surgery, EpiCURA Hospital, University of Mons, Mons, Belgium.  
 Email: [Jerome.Lechien@umons.ac.be](mailto:Jerome.Lechien@umons.ac.be)

The objective of the present paper is to review the current literature about the epidemiology, etiologies and surgical management of BVFP in the adult population.

## Methods

### Search Strategy

A PubMed, Scopus, and Cochrane Library database research was conducted by 2 investigators (S.H. and J.R.L.) for relevant peer-reviewed publications in the English language related to epidemiology (incidence and prevalence), etiologies, and surgical management of BVFP. PubMed, Cochrane Library, and Scopus were used as search database. The following keywords were used “vocal cord,” “vocal cord paralysis/epidemiology,” “vocal cord paralysis/etiology,” “vocal cord paralysis/surgery,” “bilateral,” “management,” and “procedure,” to identify clinical prospective/retrospective studies, reviews and meta-analyses. Case reports were excluded. Studies were considered if they had database abstracts, available full-texts, or titles containing the search terms. Results of the search strategy were reviewed for relevance and the reference lists of these articles were examined for additional pertinent studies.

### Study Selection and Data Synthesis

The criteria for consideration of study inclusion for the systematic review were based on the population, intervention, comparison, outcome, timing, and setting framework. The review was conducted regarding the preferred reporting items for systematic reviews and meta-analyses (PRISMA) checklist for systematic reviews.<sup>8</sup> For each included study, 2 authors independently reviewed and extracted the data. Any discrepancies in synthesized data were discussed and resolved by the remaining co-authors.

### Types of Studies

Papers were selected for inclusion in the final review if they reported data on epidemiology, etiologies, or surgical treatment of BVFP. Studies including data from combined surgical approaches (eg, association of posterior transverse cordotomy and arytenoidectomy) were excluded.

### Populations, Inclusion/exclusion Criteria

Authors should report inclusion/exclusion criteria, the definition of BVFP, diagnostic approach, management, and therapeutic outcomes. Studies including patients with unspecified laryngeal immobility, or posterior glottic stenosis were excluded. The authors needed to support the BVFP diagnosis through the clinical history of the patient (eg, immediate postsurgical paralysis) and/or the absence of clinical, electromyography (EMG), or endoscopic findings of posterior glottic stenosis. The positions of the vocal folds were defined as median, intermediate, or lateral. Paresis was diagnosed if movement was sluggish, while paralysis was diagnosed if no volitional movement was observed.

### Outcomes

The following outcomes were reviewed: study design; number of patients; age; gender; etiologies; baseline tracheotomy (prior to definitive surgical procedure); surgical procedures; number of procedures per patients; postsurgical procedure decannulation rate; voice, swallowing, or airway outcomes; complications; and revision features.

### Intervention and Comparison

The following surgical procedures were considered: tracheotomy; unilateral or bilateral laterofixation of the vocal folds; unilateral or bilateral posterior transverse cordotomy; unilateral or bilateral partial and total arytenoidectomy; selective laryngeal reinnervation; and laryngeal pacing. Studies including both posterior glottic stenosis and BVCP were excluded. Heterogeneity among included articles in decannulation, postoperative functional, and surgical revision outcomes precluded statistically pooling the data into a formal meta-analysis, thereby limiting the analysis to a qualitative rather than quantitative summary of the available information.

### Timing and Setting

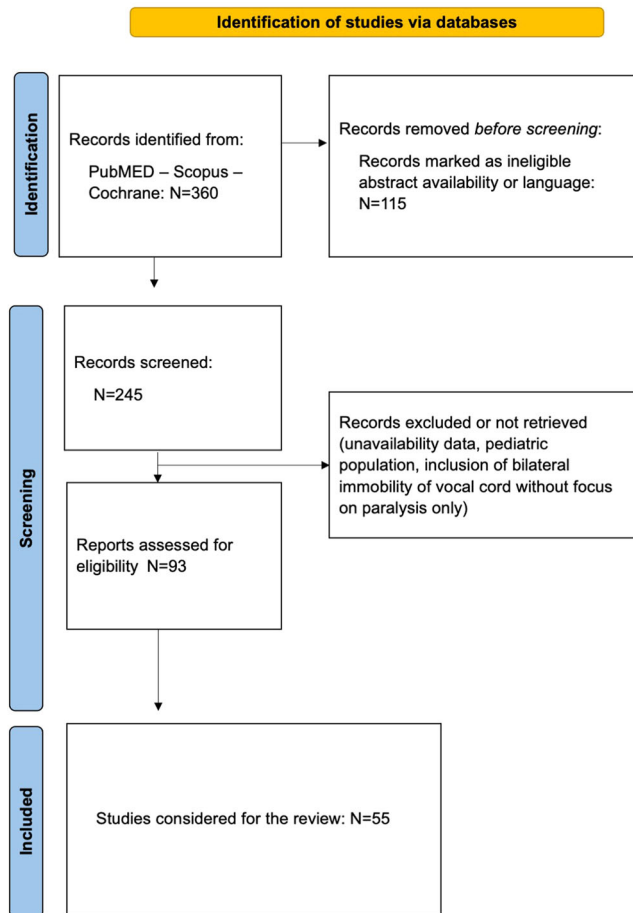
There were no criteria for specific stage or timing in the “disease process” of the study population.

## Results

Article selection is summarized in the PRISMA flow chart (**Figure 1**). Of the 360 identified papers, 245 were screened, and of these 55 were considered for review. Among them, 9 studies were dedicated to laterofixation of the vocal folds. Unilateral and bilateral posterior transverse cordotomy outcomes were reported in 9 and 7 studies, respectively. Unilateral/bilateral partial arytenoidectomy data were described in 4 studies, while 6 studies investigating total arytenoidectomy were included. Epidemiology, etiologies, and treatment outcomes were systematically described. The treatment findings were subdivided into reversible treatments for acute airway distress (tracheotomy and laterofixation of the vocal folds); botulinum toxin injections; and permanent surgery (unilateral or bilateral posterior transverse cordotomies, partial and total arytenoidectomies, laryngeal pacing and reinnervation).

### Epidemiology

The prevalence and incidence of BVFP remain uninvestigated in the general adult population.<sup>9</sup> As the primary etiology of BVFP is postsurgical nerve injuries, a few population-based cohort studies reported epidemiological findings in specific populations, such as patients with primary thyroid cancer,<sup>10</sup> thyroidectomy,<sup>11,12</sup> or esophagectomy.<sup>13</sup> A large database analysis from 14,934 patients suggested an incidence of BVFP in 0.2% to 0.6% of thyroidectomy cases.<sup>12</sup> Francis



**Figure 1.** Preferred reporting items for systematic reviews and meta-analyses flow chart.

et al reviewed data from 5670 Medicare patients and reported that 1.3% of total thyroidectomies for well-differentiated thyroid carcinoma were complicated by BVFP with 28% of cases requiring surgical management.<sup>10</sup> The median diagnostic time was 6.7 months postoperatively with a 9% annual reduction in rate of BVFP over the past 2 decades. The authors showed that advanced age, non-Caucasian race, particular histologic types, and advanced stage increased the risk of bilateral paralysis.<sup>10</sup> The middle age, female sex, and an increased length of hospital stay were additional factors associated with an increased incidence of BVFP according to a recent Taiwanese study.<sup>14</sup> The potential influence of female sex was supported by Aspinall et al who reported a slight predominance of idiopathic causes in females.<sup>15</sup> However, the sex susceptibility remains controversial because thyroid diseases occur more frequently in females<sup>12</sup> and, consequently, females are more at risk to postoperative complications. The lack of neuromonitoring during surgery increases the incidence of BVFP.<sup>16</sup> Indeed, Goretzki et al reported in a retrospective chart review of over 1300 total thyroidectomies that the 17% rate of BVFP decreased to 0% rate when surgeons proceeded to the second lobectomy with a known or

**Table 1.** Etiology of Bilateral Vocal Cord Paralysis

Etiology	N (1182)	Percentage
Postsurgery	905	76.6
Thyroidectomy	879	97.1
Esophagectomy	13	1.4
Brain/skull base surgery	6	0.7
Tracheal/chest surgery	5	0.6
Bilateral glomus surgery	1	0.1
Thymic surgery	1	0.1
Idiopathic	82	6.9
Trauma	36	3.0
Neurological diseases	29	2.5
Unspecified	19	65.5
Neuromyopathies	2	6.9
Stroke	2	6.9
Guillain-Barré	2	6.9
Neurofibromatosis	1	3.4
Brain metastases	1	3.4
Parkinson	1	3.4
Bulbar disease	1	3.4
Cancers	19	1.6
Primary thyroid cancer	13	68.4
Laryngeal cancer	3	15.7
Lung cancer	1	5.3
Esophageal cancer	1	5.3
Neck metastasis	1	5.3
Congenital	14	1.2
Viral	4	0.3
Strangulation	4	0.3
Tuberculosis	2	0.2
Granulomatosis with polyangitis	1	0.1

Abbreviation: N = number.

unrecognized nerve injury on the first side.<sup>16</sup> Among patients who underwent transthoracic and thoracoscopic esophagectomy, the BVFP prevalence is around 33% in a cohort study including 206 patients.<sup>17</sup>

### Etiologies

Etiologies of BVCP were available in 36 papers (Table 1).<sup>18-54</sup> Surgical procedures were known for a long-time as responsible for most of the cases of BVFP. The data of studies were pooled to highlight the main etiologies of BVFP (Table 1).<sup>18-54</sup> Surgery (76.6%), idiopathic (6.9%), traumas (3.0%), and neurological diseases (2.5%) are the most common causes of BVFP. The surgical procedures associated with an increased risk of BVFP include thyroidectomy (97.1%),<sup>18-25,27,28,31-54</sup> esophagectomy (1.4%),<sup>18,25,27</sup> brain or skull base surgeries (0.7%),<sup>28,31</sup> tracheal or chest surgeries (0.6%),<sup>25,48</sup> bilateral glomus resection (0.1%),<sup>52</sup> and thymectomy (0.1%).<sup>36</sup> In most studies, authors did not specify the neurological conditions associated with BVFP (65.5%),<sup>20,21,28</sup> whereas others identified neuromyopathies (6.9%),<sup>47</sup> Guillain-Barré (6.9%),<sup>22,42</sup> stroke (6.9%),<sup>40</sup>

Parkinson disease (3.4%),<sup>32</sup> ataxia (3.4%),<sup>48</sup> bulbar disease (3.4%),<sup>23</sup> brain metastases (3.4%),<sup>18</sup> and neurofibromatosis (3.4%),<sup>48</sup> as potentially responsible of BVFP. Chest and head and neck cancers that may lead to BVFP are related to thyroid (68.4%),<sup>18,22</sup> larynx (15.7%),<sup>18</sup> lung (5.3%),<sup>27</sup> esophagus (5.3%),<sup>40</sup> or may consist of bilateral neck metastases (5.3%).<sup>22</sup> The other etiologies of BVFP are congenital (1.2%),<sup>22,27,32</sup> infectious (postviral,<sup>19,25</sup> or tuberculosis<sup>27</sup>), ischemic (strangulation, 0.3%),<sup>19,24</sup> or inflammatory (Wegener).<sup>32</sup> Radiation<sup>28,33</sup> and prolonged intubation<sup>24,25,32,38</sup> were suggested as potential etiologies of BVFP but authors included patients with bilateral vocal fold immobility, which may include posterior glottic stenoses. Similarly, others only focused on patients with only 1 possible cause of BVFP, for example, esophagectomy,<sup>13</sup> or thyroidectomy,<sup>11,55-57</sup> and, therefore, were not included in the assessment of the prevalence of BVFP etiologies.

### Reversible Treatments for Acute Airway Distress

The occurrence of BVFP often results in acute airway distress necessitating urgent airway intervention. The dyspnea concerns the majority of patients with BVFP according to the 4 times greater fibers of adductor muscle compared to abductor muscle fibers, which explains the paramedian position of both paralyzed vocal cords.<sup>58</sup> From a medical standpoint, oxygen therapy, the use of Heliox, and the administration of intravenous and aerosol corticosteroids consist of the emergent steps to reduce dyspnea.<sup>57,59</sup> Surgically, tracheotomy and laterofixation of the vocal fold are reversible surgical procedures to address acute airway distress due to BVFP.

#### Tracheotomy

Tracheotomy has long-time been the preferred approach to restore the airway while maintaining the structural integrity of the glottic larynx. Tracheotomy is a rapid and effective procedure that does not require laryngological skills. This is particularly important because thyroid surgery is commonly performed by nonhead and neck surgeons in many world regions (eg, endocrine, digestive, or thoracic surgeons), who are not familiar with endoscopic laryngeal procedures.<sup>60</sup> According to studies reviewed, tracheotomy is required in 36.2% of cases (Table 2). Decannulation is achieved in 20% to 100% of cases depending on the surgical procedure (Table 2).<sup>11,19,58</sup> However, tracheotomy is associated with decreased quality of life, psychological and social problems, and requires continual postoperative care.<sup>61-63</sup> Currently, tracheotomy may be considered as an emergent surgical procedure for patients with severe dyspnea related to BVFP while awaiting recovery of movements of 1 or both vocal folds, which can take as long as 6 to 9 months postinjury.<sup>11</sup> Since the development of endoscopic laryngeal procedures since the beginning of the 20th century, the laterofixation of the vocal fold was proposed as an alternative procedure to tracheotomy<sup>64</sup> and has gained in popularity over the past 3 decades.

#### Laterofixation of the Vocal Cord

The laterofixation of the vocal fold consists of the laterofixation of 1 vocal fold or vocal process of arytenoid through external or endoscopic surgical approach for several months (Figure 2). The feasibility, airway, and voice quality outcomes, complications, and revisions of laterofixation were reported in 9 studies (Table 2).<sup>11,18-23,65,66</sup> The decannulation rate ranges from 95% to 100% (mean: 97.0%) in studies with a 2-to-60-month follow-up period. Laterofixation is associated with adequate postoperative airway volume measurements, including forced inspiratory volume,<sup>65</sup> forced expiratory volume 1 s (FEV1),<sup>11,22</sup> and peak expiratory flow (PEF) rate,<sup>11,22</sup> and endoscopic glottic findings.<sup>20,23</sup> The complications of laterofixation include aspiration,<sup>21,65</sup> edema of arytenoid and vocal cord,<sup>18,23,65,66</sup> posterior glottic stenosis,<sup>19</sup> lateral migration of suture,<sup>20</sup> granuloma,<sup>20</sup> airway obstruction related to fibrin,<sup>18</sup> or hematoma.<sup>23</sup> The revision rate ranged from 4.0% to 7.7%.<sup>19,20,65,66</sup> The 3 most prevalent reported complications consisted of laterofixation rupture/releasing fixed fold (7.7%-36.0%), postoperative laryngeal edema (7.7%-17.1%), and aspiration (4.0%-9.1%; Table 3). To date, laterofixation of the vocal fold may be considered as an alternative and cost-effective<sup>67</sup> endoscopic surgical procedure to tracheotomy in patients with severe dyspnea related to BVFP.<sup>18,20</sup>

#### Botulinum Toxin Injection

Nonsurgical treatments of BVCP included voice therapy and botulinum toxin injection.<sup>61</sup> Voice therapy is mainly indicated for patients with dysphonia related to BVCP. Botulinum toxin injections are commonly performed in cases of aberrant reinnervation of the adductor muscles by inspiratory motoneurons to improve the glottic opening.<sup>68,69</sup> To date, there are 2 case reports or small case series of patients treated with botulinum toxin injection.<sup>68,69</sup> According to the case series of Ekbohm et al, the use of botulinum toxin type A in patients with respiratory compromise due to bilateral vocal fold motion impairment may result in a long-term patient-reported symptom improvement in most cases after an average of 9 injections over 10-year period of study.<sup>68</sup>

#### Permanent Surgeries

If recovery does not occur and the patient remains symptomatic, there are several endoscopic surgical options to increase the glottic aperture. Because it remains complicated to draw conclusion from retrospective nonrandomized studies in which authors compared several procedures, we mainly reported findings of single-surgical procedure studies. The main permanent procedures include unilateral or bilateral posterior transverse cordotomy, unilateral or bilateral partial or total arytenoidectomy, or a combination of several approaches (Figure 2). Studies investigating outcomes, complications, and revisions of single procedures are

**Table 2.** Summary of Studies as Grouped by Surgical Approach

Type of surgery	Design	N	M/F	Age (A/M)	Tracheot.	Deca.	Timing	Follow-up	Outcomes	Effective rate
<b>Laterofixation</b>										
Geterud et al <sup>21</sup>	Retrospective	11	4/7	65	NP	NP	NP	60 mo	Airway volume	Pre = postsurgery
Rovo et al <sup>65</sup>	Retrospective	15	1/14	33-73	2/15	2/2	6 mo <sup>b</sup>	17 mo	Airway volume	Post > presurgery
Rovo et al <sup>19</sup>	Prospective	25	5/20	33-81	5/25	5/5	1-6 mo	25 mo	Dyspnea	96%
Leitersdorfer et al <sup>11</sup>	Retrospective	92	18/74	56	NP	NP	NP	2-6 mo	Airway volume	Post > preurgery
Hyodo et al <sup>22</sup>	Prospective	11	3/8	11	6/11	6/6	NP	2 mo	Airway volume	91%, post > presurgery
Ezzat et al <sup>20</sup>	Prospective	21	8/13	36	21/21	20/21	>1 wk	6 mo	Endoscopic findings	76%
Oysu et al <sup>66</sup>	Retrospective	13	0/13	52	0/13	NP	8 mo <sup>b</sup>	24 mo	Dyspnea	92%
Korkmaz et al <sup>23</sup>	Retrospective	47	3/44	NP	NP	NP	NP	19 mo	Dyspnea	94%
Wiegand et al <sup>18</sup>	Retrospective	35	13/22	64	3/35	3/3	>1 wk	NP	Decannulation	100%
<b>Posterior unilateral cordotomy</b>										
Laccourreye et al <sup>40</sup>	Retrospective	25	6/19	63	NP	NP	NP	5 years	Endoscopic findings	68%
Segas et al <sup>45</sup>	Retrospective	20	8/12	50	12/20	18/20	>3 mo	5 mo	Dyspnea	90%
Yagudin et al <sup>46</sup>	Prospective	21	0/21	56	21/21	21/21	>12 mo	3 mo	Airway volume	Post > presurgery
Oysu et al <sup>42</sup>	Retrospective	11	1/10	NP	2/11	2/2	>6 mo	6-15 mo	Exercise tolerance	Post > presurgery
Ozdemir et al <sup>34</sup>	Retrospective	66	8/58	48	7/66	NP	NP	40 mo	Airway restoration	88%
Khalil and Tawab <sup>39</sup>	Prospective	18	8/10	47	NP	NP	6 mo <sup>b</sup>	12 mo	Airway volume	72%
Ozturk et al <sup>43</sup>	Controlled	30	12/18	53	NP	NP	6 mo <sup>a</sup>	6 mo	Airway volume	Post > presurgery
Mohamed et al <sup>41</sup>	RCT	20	4/16	50	2/20	NP	12 mo <sup>b</sup>	12 mo	Dyspnea score	Post > presurgery
Rashid et al <sup>44</sup>	Retrospective	34	10/24	39	NP	NP	6 mo <sup>b</sup>	6 wk	Dyspnea	Post > presurgery
<b>Posterior bilateral cordotomy</b>										
Khalifa <sup>74</sup>	Prospective	22	8/14	41	18/22	12/22	>1 mo	1-2 mo	Decannulation	54%
Dursun and Gökcan <sup>75</sup>	Retrospective	22	8/14	45	6/22	NP	NP	12 mo	Dyspnea score	95%
Bajaj et al <sup>36</sup>	Retrospective	9	3/6	27-85	3/9	3/3	12 mo <sup>a</sup>	3-28 mo	Dyspnea and voice	100%-78%
Asik et al <sup>35</sup>	Prospective	11	2/9	46	0/11	0/0	48 mo <sup>b</sup>	2 mo	Airway volume	Post > presurgery
Basterra et al <sup>37</sup>	Retrospective	18	3/6	27-85	7/18	7/7	NP	2-5 years	Airway volume	74%-91%
Benninger et al <sup>38</sup>	Retrospective	15	4/11	57	3/15	2/3	NP	18 mo	Stridor	83%
Karkos et al <sup>62</sup>	Prospective	12	2/10	56	12/12	12/12	12 mo <sup>b</sup>	24 mo	Decannulation	100%
<b>Partial uni/bilateral arytenoidectomy</b>										
Crumley <sup>47</sup>	Retrospective	8	NP	NP	6/8	2/6	NP	6 mo	Exercise tolerance	100%
Gorphe et al <sup>50</sup>	Prospective	20	7/13	52	5/20	5/5	NP	3 mo	Dyspnea	100%
Yilmaz et al <sup>53</sup>	RCT	20	5/15	52	4/20	NP	NP	12 mo	Airway volume	Pre = postsurgery
Yilmaz <sup>48</sup>	Prospective	64	8/56	52	9/50	9/9	NP	12 mo	Airway restoration	88%
<b>Total uni/bilateral arytenoidectomy</b>										
Ossof et al <sup>49</sup>	Retrospective	11	1/10	59	6/11	10/11	NP	6-36 mo	Decannulation	91%
Szmeja and Wójtowicz <sup>52</sup>	Retrospective	30	NP	47	3/30	3/3	NP	NP	Dyspnea	100%
Li et al <sup>63</sup>	Prospective	9	0/9	53	NP	NP	NP	10 mo	Airway index	Post > presurgery
Misiolek et al <sup>54</sup>	Prospective	36	3/33	52	22/36	35/36	NP	1 mo	Airway volume	Post > presurgery
Yilmaz et al <sup>5</sup>	Retrospective	50	9/41	50	40/50	37/40	NP	1 mo	Dyspnea	Post > presurgery
Hu et al <sup>51</sup>	Retrospective	14	8/6	44	14/14	13/14	NP	6 mo	Decannulation	93%

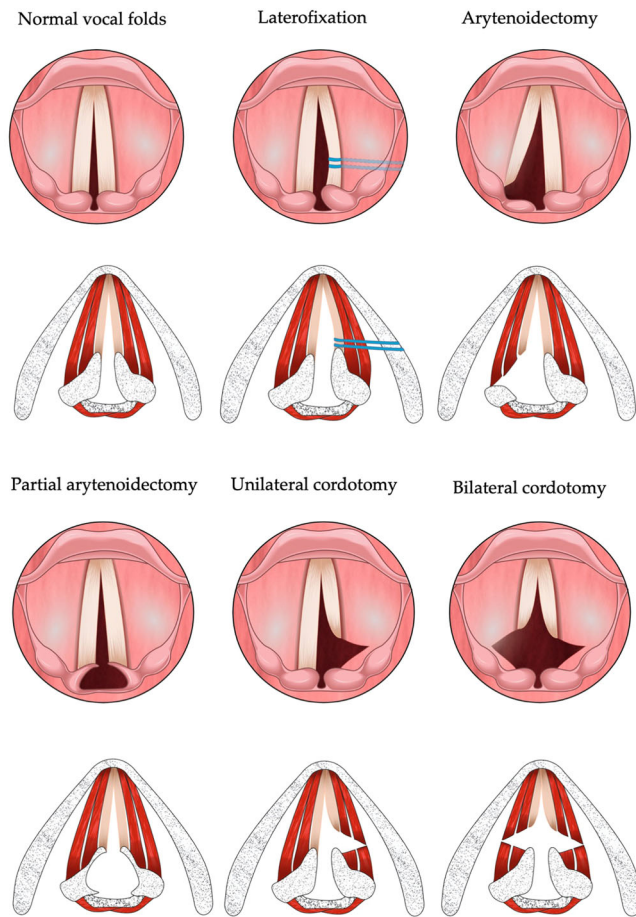
Effective rate data are related to outcomes considered in the studies.

Abbreviations: A/M, average/mean; M/F, male/female; mo, month; NP, not provided; RCT, randomized controlled trial; wk, week.

<sup>a</sup>Median (for timing).

<sup>b</sup>Mean (for timing).





**Figure 2.** Surgical techniques.

summarized in **Tables 2** and **3**. Some studies reported the pre- to postoperative findings of patients treated with several procedures with,<sup>32,70-72</sup> or without,<sup>29-31,33,54</sup> comparison of outcome procedures.

#### Posterior Transverse Cordotomy

Posterior transverse cordotomy is one of the most common endoscopic procedures for BVFP. Outcomes were available in 16 studies.<sup>35-46,60-62</sup> The section of mucosa, ligament, and muscle of the vocal fold is carried out with cold instruments, CO<sub>2</sub> laser,<sup>40,41,43</sup> potassium-titanyl-phosphate laser,<sup>45</sup> diode laser,<sup>73</sup> coblation,<sup>38</sup> or radiofrequency monopolar.<sup>42</sup> The degree of posterior transverse cordotomy may vary based on the degree of muscle section.<sup>31</sup> The CO<sub>2</sub> laser-assisted cordotomy is the most used approach and did not report significant respiratory or voice outcome differences than the diathermy-assisted procedure in unilateral or bilateral posterior cordotomy.<sup>43</sup>

The decannulation rates of unilateral posterior cordotomy were reported in 3 studies and ranged from 90% to 100% (mean: 95.1%).<sup>42,45,46</sup> From a respiratory standpoint, unilateral posterior cordotomy is effective and improved subjective perceived respiratory/dyspnea score,<sup>34,41-45</sup> peak expiratory or inspiratory flow,<sup>43,46</sup> FEV<sub>1</sub>,<sup>39,43</sup> or maximum phonation time (MPT).<sup>41</sup> From

a voice quality outcome, the approach may lead to worsening of perceptual voice quality,<sup>44</sup> while others did not find significant differences in pre- to postoperative voice handicap index (VHI),<sup>34,42</sup> and acoustic measurements.<sup>41,43</sup> The revision rates ranged from 0% to 45% (**Table 3**) and mainly concerned the management of postoperative dyspnea (laryngeal edema)<sup>34,45</sup> or granuloma.<sup>34,45,46</sup> Aspiration was reported in 5.6% of patients in the study of Khalil et al,<sup>39</sup> while others did not report aspiration cases.<sup>40,42</sup>

In case of insufficient benefit from unilateral posterior cordotomy, bilateral posterior cordotomy could be considered. Many authors proposed bilateral posterior cordotomy as the first procedure for patients with BVFP.<sup>35-38,73-75</sup> The mean decannulation rate of bilateral posterior transverse cordotomy was 76.6% (range: 0%-100%). The decannulation rate of bilateral cordotomy appears as lower than the mean decannulation rate of unilateral posterior cordotomy (95.1%) but the populations included in studies were substantially different. Thus, 31.9% of patients of unilateral cordotomy studies had baseline tracheotomy<sup>34,41,42,45,46</sup> versus 44.5% of individuals treated with bilateral cordotomy; whereas the severity of baseline airway outcomes was higher in bilateral versus unilateral cordotomy study populations (**Table 2**).<sup>35-38,60-62</sup> This difference may support the existence of different inclusion criteria, which makes the comparison difficult. Most authors reported that the patient-reported or physician perception of dyspnea,<sup>35,36,38,61</sup> MPT,<sup>35,61</sup> forced vital capacity,<sup>35</sup> PIF, FEV<sub>1</sub>,<sup>35,37,61</sup> VO<sub>2</sub> max,<sup>35</sup> improved postsurgery. The voice quality findings were more controversial with worsening (VHI,<sup>35</sup> grade, roughness, breathiness, asthenia, strain<sup>35,37</sup>) or unchanged<sup>73</sup> voice quality outcomes after surgery. A study reported improvements of VHI 516 days after surgery.<sup>38</sup> The swallowing improved<sup>73</sup> or did not change from pre- to postsurgery.<sup>37</sup> The revision rate of bilateral posterior cordotomy ranged from 0% to 46.7% and was mostly related to the management of granuloma,<sup>38</sup> or fibrosis/scarring of the sectioned vocal cord.<sup>74</sup>

#### Total Arytenoidectomy

Total arytenoidectomy is an old external or endoscopic approach that gained in popularity with the development of CO<sub>2</sub> laser. The technique consists of the resection of 1 arytenoid cartilage to enlarge the glottic space (**Figure 2**). Outcomes were reported in 6 studies.<sup>5,49,51,52,54,63</sup> Some teams associated total arytenoidectomy with transverse cordotomy to improve the airway of patients with severe dyspnea.<sup>29,31,76</sup>

The decannulation rate is excellent (95.3%) in studies with a 1- to 10-month follow-up.<sup>5,49,51,52,54,63</sup> From a respiratory standpoint, the total arytenoidectomy was associated with significant improvements of patient-reported dyspnea,<sup>52</sup> FEV<sub>1</sub>,<sup>54</sup> vital capacity,<sup>54</sup> and PEF.<sup>54</sup> The voice quality outcomes of patients with total

Table 3. Complications

Type of surgery	Aspiration	Laryngeal Edema	Hematoma	Postop. Dyspnea	Fibrosis/ Scarring	PGS	Granuloma	Laterofixation Rupture	Suture Migration	Releasing Fixed cord	Surgical Revision
Laterofixation											
Geterud et al <sup>21</sup>	1/11										
Rovo et al <sup>65</sup>	1/15	3/15									1/15
Rovo et al <sup>19</sup>	1/25	4/25				1/25		3/25		9/25	1/25
Ezzat et al <sup>20</sup>							1/21		1/21		1/21
Oysu et al <sup>66</sup>		1/13						1/13			1/13
Korkmaz et al <sup>23</sup>		2/47	1/47								
Wiegand et al <sup>18</sup>		6/35		3/35						2/35	
Posterior unilateral cordotomy											
Laccourreye et al <sup>40</sup>	0/25	0/25	0/25	0/25			0/25	-	-	-	6/25
Segas et al <sup>45</sup>		8/20					7/20	-	-	-	9/20
Yagudin et al <sup>46</sup>							3/21	-	-	-	0/21
Oysu et al <sup>42</sup>	0/25	0/25	0/25	0/25			0/25	-	-	-	2/11
Ozdemir et al <sup>34</sup>		7/66		4/66			4/66	-	-	-	12/66
Khalil and Tawab <sup>39</sup>	1/18						3/18	-	-	-	0/30
Ozturk et al <sup>43</sup>							6/30	-	-	-	6/34
Rashid et al <sup>44</sup>								-	-	-	4/22
Posterior bilateral cordotomy											
Khalifa <sup>74</sup>					4/22			-	-	-	4/22
Dursun and Gökcan <sup>75</sup>								-	-	-	0/9
Bajaj et al <sup>36</sup>				1/9				-	-	-	0/11
Asik et al <sup>35</sup>	0/11	0/11	0/11	0/11			0/11	-	-	-	7/15
Basterra et al <sup>37</sup>								-	-	-	
Benninger et al <sup>38</sup>							4/15	-	-	-	
Karkos et al <sup>69</sup>								-	-	-	
Partial uni/bilateral arytenoidectomy											
Crumley <sup>47</sup>	0/8	0/8	0/8	0/8			0/8	-	-	-	0/8
Gorphe et al <sup>50</sup>							1/20	-	-	-	5/20
Yilmaz et al <sup>53</sup>								-	-	-	8/64
Yilmaz <sup>48</sup>								-	-	-	
Total arytenoidectomy											
Ossof et al <sup>49</sup>					1/30			-	-	-	1/30
Szmeja and Wójtowicz <sup>52</sup>								-	-	-	
Li et al <sup>70</sup>	0/9	0/9	0/9	0/9			0/9	-	-	-	3/50
Misiolek et al <sup>54</sup>								-	-	-	1/14
Yilmaz <sup>5</sup>		1/50		1/50				-	-	-	1/14
Hu et al <sup>51</sup>								-	-	-	



arytenoidectomy were reported in single-procedure study,<sup>5</sup> or in studies combining several approaches, for example, arytenoidectomy and posterior transverse cordotomy,<sup>31</sup> or arytenoidectomy with vocal cord lateralization.<sup>32</sup> Motta et al<sup>31</sup> reported worsening of MPT and acoustic measurements from pre- to postsurgery, while Anand et al<sup>32</sup> reported postoperative dysphonia in most patients. VHI-30, MPT, and acoustic parameters significantly worsened after total arytenoidectomy in the study of Yilmaz.<sup>5</sup>

The complications of total arytenoidectomy were poorly described in studies reporting data of total arytenoidectomy as single approach. Thus, laryngeal web,<sup>49</sup> scarring,<sup>51</sup> and laryngeal edema requiring tracheotomy,<sup>5</sup> were reported but in most studies, authors did not investigate the occurrence of aspiration and pneumonia. However, aspiration and related pneumonia appear to be prevalent, reaching 50% of cases according to some report.<sup>71</sup> The revision rate may reach 7% of cases, and is related to the development of scarring.<sup>51,52</sup>

The total arytenoidectomy is not a preferred procedure because of the poor postoperative voice quality outcomes and the risk of aspiration and related pneumonia, which are less prevalent in partial arytenoidectomy or posterior transverse cordotomy (0% vs 50%).<sup>71</sup> Total arytenoidectomy may be carried out for primary BVFP cases when partial arytenoidectomy or bilateral transverse cordotomy fail.

#### Partial Arytenoidectomy

Partial arytenoidectomy was developed by Crumley in 1993<sup>47</sup> and Remacle et al<sup>77</sup> in 1996. This approach consists of the unilateral or bilateral resection of the antero-median part of the arytenoid (vocal process) to enlarge the respiratory glottis, while preserving the phonatory glottis (**Figure 2**). Four studies were included in the present review.<sup>47,48,50,53</sup> The decannulation rate was 83% (range: 33%-100%)<sup>47,48,50,53</sup> at 3- to 12-month follow-up time. This technique is associated with significant improvements of respiratory outcomes (eg, exercise tolerance,<sup>47</sup> patient-reported dyspnea,<sup>50</sup> FEV1,<sup>48</sup> FIV,<sup>48</sup> airway volume,<sup>53</sup> airway resistance,<sup>48</sup> or physician-reported airway restoration<sup>48</sup>).

The voice quality is not worsened according to patients,<sup>47,50</sup> but conflicting data exist regarding the objective voice measurements. Yilmaz et al<sup>48</sup> reported worsening of VHI, MPT, voice intensity, and acoustic measurements at 12 months postsurgery, while Gorphe et al<sup>50</sup> did not show pre- to postsurgery significant differences in VHI and acoustic measurements. The complications of partial arytenoidectomy are rare or poorly reported, and mainly consist of postoperative granuloma.<sup>50</sup> The revision was needed in 14.1% for persistent dyspnea after surgery.<sup>47,48,50</sup> For these cases, framework laryngeal surgery may be discussed but patient comorbidities and the risk of complications (around 5%),

such as fibrosis and posterior glottic stenosis, need to be considered in the benefit-risk ratio.<sup>78,79</sup>

The partial arytenoidectomy is a safe procedure according to the low rate of complication, the good postoperative airway outcomes, and the potential preservation of voice quality.<sup>50,79</sup> The advantage of partial arytenoidectomy over cordotomy is the preservation of the soft vocal cord tissue, which theoretically provides better voice quality outcomes.<sup>79</sup> However, to date, there is no randomized controlled trial comparing posterior transverse cordotomy versus partial arytenoidectomy in the management of definitive BVFP.

#### Laryngeal Pacing and Reinnervation

The ansa cervicalis-to-RLN, the hypoglossal-to-RLN, or the phrenic-to-RLN anastomoses are the main unilateral<sup>80,81</sup> or bilateral<sup>82,83</sup> laryngeal reinnervation approaches to restore the posterior cricoarytenoid muscle function and the vocal cord abduction.<sup>80-83</sup> Most case-series of laryngeal recurrent reinnervation for BVFP were reported in children.<sup>82</sup> In adults, the first case of phrenic-to-RLN anastomosis was reported in 1983 by Crumley who showed an improvement of glottic diameter but no active arytenoid movement.<sup>83</sup> Variations on the phrenic technique were described involving an extralaryngeal neurotomy between the main trunk of the RLN and concomitant intralaryngeal transection of the adductor branches of the recurrent nerve.<sup>84</sup> Li et al reported that phrenic-based RLN reinnervation was associated with 93% recovery of vocal cord movement and 87% of decannulation.<sup>85</sup> In another case-series of 39 patients, this team used upper root of phrenic nerve and hypoglossal nerve branch to carry out the reinnervation.<sup>86</sup> Authors reported a recovery and decannulation rate of moderate-to-severe abduction in 89.7%. Patients reported a significant improvement of grade of dysphonia, VHI-10, acoustic measurements, and MPT at 12 months postsurgery, while most of the respiratory parameters returned to the normal reference level at 3 months postoperatively. Other reinnervation techniques were reported, including the use of the superior laryngeal nerve,<sup>87</sup> or the thyrohyoid nerve,<sup>88</sup> but the lack of cohort studies makes difficult the establishment of reliable conclusion.

As for laryngeal pacing, the usefulness of the functional electrical stimulation of paralyzed laryngeal muscles through a pacing device was investigated in few case-series.<sup>89,90</sup> Briefly, unilateral pacing appeared to be associated with significant respiratory outcomes without negative effect on voice quality. However, the lack of large cohort-controlled study limits the conclusion that can be drawn.

#### Discussion

The finding of the present systematic review highlighted that some surgical techniques were combined in numerous

studies but few authors compared the procedure outcomes. In 1994, Eckel et al reported the results of a prospective randomized controlled trial comparing posterior transverse cordotomy and arytenoidectomy in 18 and 10 patients with BVFP, respectively.<sup>71</sup> Results showed that plethysmography, flow volume, and spirometry outcomes were similarly improved from pre- to postsurgery in both groups.<sup>71</sup> Patients with arytenoidectomy reported a 50% rate of aspiration, while those with cordotomy did not report aspiration. Revision was needed in only 1/18 patients with cordotomy. Dispenza et al<sup>55</sup> observed decannulation rates of 60% and 96% in patients who underwent CO<sub>2</sub> arytenoidectomy versus CO<sub>2</sub> arytenoidectomy and posterior cordotomy, respectively.<sup>55</sup> Anand et al retrospectively compared posterior cordotomy, a modified cordoplasty approach, and combined arytenoidectomy and vocal cord lateralization in a cohort of 54 patients with BVFP.<sup>32</sup> Authors reported decannulation rates of 90%, 100%, and 77% in cordotomy, cordoplasty, and arytenoidectomy groups, respectively. The patient-reported dyspnea assessment was better in cordotomy and cordoplasty groups compared with arytenoidectomy group; while patients with posterior cordotomy reported higher prevalence of postoperative aspiration than others.<sup>32</sup> In a prospective randomized controlled study, Abdelhamid et al treated patients with laser cordotomy (N = 20) or concurrent laser cordotomy and laterofixation (N = 20).<sup>72</sup> The association of laser cordotomy and concurrent laterofixation was associated with significant better improvements of acoustic parameters and MPT, whereas there were no significant differences between groups for VHI and aspiration rates.<sup>72</sup>

To date, it is not straightforward to establish the superiority of 1 technique over others for many reasons. First, most studies are retrospective case-series with a low number of patients. Second, the inclusion and exclusion criteria may substantially vary from 1 study to another, some techniques being favored for patients with more severe dyspnea. The heterogeneity across studies also concerns the delay of procedure and the follow-up time. Note that the details about diagnostic approach for BVFP was not provided by authors in most studies because they based the diagnosis on the etiological findings. Thus, only a few authors used laryngeal EMG prior to surgery,<sup>32,61,70,75,85</sup> while many teams proposed surgery in the few weeks following the laryngeal paralysis without waiting for a potential recovery of vocal fold motion. The lack of description of diagnostic approach or use of EMG have limited us in the diagnosis approach analysis. The follow-up was shorter (<1 month) in some studies<sup>44,54,55,72,74</sup> to observe voice quality changes or delayed complications (eg, aspirations, posterior glottic stenosis, or scarring). Third, many authors do not differentiate BVFP from posterior glottic stenosis, both being grouped as laryngeal immobility in many studies in the literature. In the present paper, we only focused on

BVFP but some studies with interesting findings were not reviewed because lack of details about the origin of vocal cord immobility. Finally, the pre- to postsurgery voice quality changes were reported without information about the potential postoperative speech therapy, which may significantly influence voice outcomes.

## Conclusion

The management of BVFP may involve several surgical procedures that are associated with significant improvements of respiratory outcomes, adequate decannulation rate, and low complication rates. To date, the heterogeneity between studies and the lack of large cohort-controlled randomized studies limits the ability to draw reliable conclusions about the superiority of 1 technique over others in terms of surgical, voice, and respiratory outcomes, complication, and revision. Future studies are needed to improve the patient criteria selection for surgical procedures, and which procedures may be favored according to patient features.

## Acknowledgments

Alain Lechien for the figure.

## Author Contributions

**Jérôme R. Lechien**, design, acquisition of data, data analysis and interpretation, drafting, final approval, and accountability for the work; final approval of the version to be published; agreement to be accountable for all aspects of the work in ensuring that questions related to the accuracy or integrity of any part of the work are appropriately investigated and resolved; **Stephane Hans**, design, acquisition of data, data analysis and interpretation, drafting, final approval, and accountability for the work; final approval of the version to be published; agreement to be accountable for all aspects of the work in ensuring that questions related to the accuracy or integrity of any part of the work are appropriately investigated and resolved; **Ted Mau**, design, acquisition of data, data analysis and interpretation, drafting, final approval, and accountability for the work; final approval of the version to be published; agreement to be accountable for all aspects of the work in ensuring that questions related to the accuracy or integrity of any part of the work are appropriately investigated and resolved.

## Disclosures

**Competing interests:** Authors have no conflict of interest.

**Funding source:** None.

## References

1. Eskew JR, Bailey BJ. Laser arytenoidectomy for bilateral vocal cord paralysis. *Otolaryngol Head Neck Surg*. 1983; 91(3):294-298.
2. Remsen K, Lawson W, Patel N, Biller HF. Laser lateralization for bilateral vocal cord abductor paralysis. *Otolaryngol Head Neck Surg*. 1985;93(5):645-649.

3. Thorpe RK, Kanotra SP. Surgical management of bilateral vocal fold paralysis in children: a systematic review and meta-analysis. *Otolaryngol Head Neck Surg.* 2021;164(2):255-263.
4. Otto RA, Davis W. Functional electrical stimulation for the treatment of bilateral recurrent laryngeal nerve paralysis. *Otolaryngol Head Neck Surg.* 1986;95(1):47-51.
5. Yilmaz T. Endoscopic total arytenoidectomy for bilateral abductor vocal fold paralysis: a new flap technique and personal experience with 50 cases. *Laryngoscope.* 2012;122:2219-2226.
6. Amedee RG, Mann WJ. A functional approach to lateral fixation in bilateral abductor cord paralysis. *Otolaryngol Head Neck Surg.* 1989;100(6):542-545.
7. Titulaer K, Schlattmann P, Guntinas-Lichius O. Surgery for bilateral vocal fold paralysis: Systematic review and meta-analysis. *Front Surg.* 2022;9:956338. doi:10.3389/fsurg.2022.956338
8. Page MJ, McKenzie JE, Bossuyt PM, et al. The PRISMA 2020 statement: an updated guideline for reporting systematic reviews. *BMJ.* 2021;372:n71.
9. Salik I, Winters R. Bilateral vocal cord paralysis. *StatPearls [Internet].* StatPearls Publishing; 2023.
10. Francis DO, Pearce EC, Ni S, Garrett CG, Penson DF. Epidemiology of vocal fold paralyses after total thyroidectomy for well-differentiated thyroid cancer in a Medicare population. *Otolaryngol Head Neck Surg.* 2014;150(4):548-557.
11. Leitersdorfer S, Lichtenberger G, Bihari A, Kovacs I. Evaluation of the lung function test in reversible glottic-dilating operations. *Eur Arch Otorhinolaryngol.* 2005;262: 289-293.
12. Rosato L, Avenia N, Bernante P, et al. Complications of thyroid surgery: analysis of a multicentric study on 14,934 patients operated on in Italy over 5 years. *World J Surg.* 2004;28:271-276.
13. Jeon YJ, Cho JH, Lee HK, et al. Management of patients with bilateral recurrent laryngeal nerve paralysis following esophagectomy. *Thorac Cancer.* 2021;12(12):1851-1856.
14. Lai YT, Chao PZ, Chang YK, et al. Iatrogenic vocal fold paralysis: a population-based cohort study in Taiwan. *Ann Otol Rhinol Laryngol.* 2022;131(7):767-774.
15. Aspinall S, Oweis D, Chadwick D. Effect of surgeons' annual operative volume on the risk of permanent Hypoparathyroidism, recurrent laryngeal nerve palsy and Haematoma following thyroidectomy: analysis of United Kingdom registry of endocrine and thyroid surgery (UKRETS). *Langenbecks Arch Surg.* 2019;404(4):421-430.
16. Goretzki PE, Schwarz K, Brinkmann J, Wirowski D, Lammers BJ. The impact of intraoperative neuromonitoring (IONM) on surgical strategy in bilateral thyroid diseases: is it worth the effort? *World J Surg.* 2010;34:1274-1284.
17. Sato Y, Kosugi S, Aizawa N, et al. Risk factors and clinical outcomes of recurrent laryngeal nerve paralysis after esophagectomy for thoracic esophageal carcinoma. *World J Surg.* 2016;40(1):129-136.
18. Wiegand S, Teymoortash A, Hanschmann H. Endo-extralaryngeal laterofixation of the vocal folds in patients with bilateral vocal fold immobility. *In Vivo.* 2017;31(6): 1159-1162.
19. Rovó L, Matievics V, Sztanó B, et al. Functional results of endoscopic arytenoid abduction lateropexy for bilateralvocal fold palsy. *Eur Arch Otrhinolaryngol.* 2022;279(4):1995-2002.
20. Ezzat WF, Shehata M, Kamal I, Riad MA. Adjustable laterofixation of the vocal fold in bilateral vocal fold paralysis. *Laryngoscope.* 2010;120:731-733.
21. Geterud A, Ejnell H, Stenborg R, Bake B. Long-term results with a simple surgical treatment of bilateral vocal cord paralysis. *Laryngoscope.* 1990;100:1005-1008.
22. Hyodo M, Nishikubo K, Motoyoshi K. Laterofixation of the vocal fold using an endo-extralaryngeal needle carrier for bilateral vocal fold paralysis. *Auris Nasus Larynx.* 2009;36(2): 181-186.
23. Korkmaz MH, Bayır Ö, Çadallı Tatar E, et al. Glottic airway gain after 'suture arytenoid laterofixation' in bilateral vocal cord paralysis. *Acta Otolaryngol.* 2015;135(9):931-936.
24. Vajpayee D, Vaid D, Saha R, Goyal A. Surgical management of bilateral abductor palsy: comparative study between posterior cordotomy and partial arytenoidectomy. *Indian J Otolaryngol Head Neck Surg.* 2021;73(3):340-345.
25. El-Sobki A, El-Deeb ME, El-Kholy NA, Elzayat S. Management of bilateral abductor paralysis: posterior cordectomy with partialarytenoidectomy using diode laser. *Eur Arch Otrhinolaryngol.* 2021;278(4):1145-1151.
26. Filauro M, Vallin A, Marcenaro E, et al. Quality of life after transoral CO<sub>2</sub> laser posterior cordotomy with or without partial arytenoidectomy for bilateral adductor vocal cord paralysis. *Eur Arch Otrhinolaryngol.* 2021;278(11):4391-4401.
27. Oswal VH, Gandhi SS. Endoscopic laser management of bilateral abductor palsy. *Indian J Otolaryngol Head Neck Surg.* 2009;61(suppl 1):47-51.
28. Shvero J, Koren R, Stern Y, Segal K, Feinmesser R, Hadar T. Laser posterior ventriculocordectomy with partial arytenoidectomy for the treatment of bilateral vocal fold immobility. *J Laryngol Otol.* 2003;117(7):540-543.
29. Gadkaree SK, Gelbard A, Best SR, Akst LM, Brodsky M, Hillel AT. Outcomes in bilateral vocal fold immobility: a retrospective cohort analysis. *Otolaryngol Head Neck Surg.* 2018;159(6):1020-1027.
30. Nawka T, Sittel C, Gugatschka M, et al. Permanent transoral surgery of bilateral vocal fold paralysis: a prospective multicenter trial. *Laryngoscope.* 2015;125(6):1401-1408.
31. Motta S, Moscillo L, Imperiali M, Carra P, Motta G. CO<sub>2</sub> laser treatment of bilateral vocal cord paralysis in adduction. *ORL J Otorhinolaryngol Relat Spec.* 2003;65(6):359-365.
32. Anand V, Kumaran BR, Chenniappan S. Cordoplasty: a new technique for managing bilateral vocal cord paralysis and its comparison with posterior cordotomy and external procedure in a large study group. *Indian J Otolaryngol Head Neck Surg.* 2015;67(suppl 1):40-46.
33. Rinne J. Late results of laterofixation in the treatment of bilateral abductor paralysis of the vocal cords: a clinical study with long-term follow-up. *Clin Otolaryngol.* 1991;16:436-441.
34. Özdemir S, Tuncer Ü, Tarkan Ö, Kara K, Sürmelioglu Ö. Carbon dioxide laser endoscopic posterior cordotomy technique for bilateralabductor vocal cord paralysis: a 15-year experience. *JAMA Otolaryngol Head Neck Surg.* 2013;139(4):401-404.

35. Asik MB, Karasimav O, Birkent H, Merati AL, Gerek M, Yildiz Y. Impact of unilateral carbon dioxide laser posterior transverse cordotomy on vocal and aerodynamic parameters in bilateral vocal fold paralysis. *J Laryngol Otol.* 2016;130(4):373-379.
36. Bajaj Y, Sethi N, Shayah A, et al. Vocal fold paralysis: role of bilateral transverse cordotomy. *J Laryngol Otol.* 2009;123(12):1348-1351.
37. Basterra J, Castillo-Lopez Y, Reboll R, et al. Posterior cordotomy in bilateral vocal cord paralysis using monopolar microelectrodes and radiofrequency in 18 patient. *Clin Otolaryngol.* 2018;43(1):340-343.
38. Benninger MS, Xiao R, Osborne K, Bryson PC. Outcomes following cordotomy by coblation for bilateral vocal fold immobility. *JAMA Otolaryngol Head Neck Surg.* 2018;144(2):149-155.
39. Khalil MA, Tawab HMA. Laser posterior cordotomy: is it a good choice in treating bilateral vocal fold abductor paralysis? *Clin Med Insights Ear Nose Throat.* 2014;7:13-17.
40. Laccourreye O, Escovar MIP, Gerhardt J, Hans S, Biacabe B, Brasnu D. CO<sub>2</sub> laser endoscopic posterior partial transverse cordotomy for bilateral paralysis of the vocal fold. *Laryngoscope.* 1999;109(3):415-418.
41. Mohamed NN, Sorour SS, El-Anwar MW, Quriba AS, Mahdy MA. Comparison between laser- and diathermy-assisted posterior cordotomy for bilateral vocal cord abductor paralysis. *JAMA Otolaryngol Head Neck Surg.* 2013;139(9):923-930.
42. Oysu C, Toros SZ, Tepe-Karaca Ç, Şahin S, Sahin-Yilmaz A. Endoscopic posterior cordotomy with microdissection radiofrequency electrodes for bilateral vocal cord paralysis. *Otolaryngol Head Neck Surg.* 2014;150(1):103-106.
43. Ozturk K, Turhal G, Kaya I, et al. A comparison of two endoscopic posterior cordotomy techniques: laser cordotomy vs diathermy-assisted cordotomy. *Clin Otolaryngol.* 2018;43(1):256-260.
44. Rashid M, Ayaz SB, Saleem H, Hussain R, Zaman S. Results of carbon dioxide laser-assisted posterior cordotomy in cases of bilateral vocal cord paralysis: an analysis of 34 cases. *J Pak Med Assoc.* 2019;69(10):1539-1542.
45. Segas J, Stavroulakis P, Manolopoulos L, Yiotakis J, Adamopoulos G. Management of bilateral vocal fold paralysis: experience at the University of Athens. *Otolaryngol Head Neck Surg.* 2001;124(1):68-71.
46. Yagudin RK, Demenkov VR, Yagudin KF. Plastic cordotomy in the treatment of bilateral vocal fold immobility. *Head Neck.* 2012;34(12):1753-1758.
47. Crumley RL. Endoscopic laser medial arytenoidectomy for airway management in bilaterally laryngeal paralysis. *Ann Otol Rhinol Laryngol.* 1993;102(2):81-84.
48. Yilmaz T. Endoscopic partial arytenoidectomy for bilateral vocal fold paralysis: medially based mucosal flap technique. *J Voice.* 2019;33(5):751-758.
49. Ossoff RH, Duncavage JA, Krespi YP, Shapshay SM, Sisson Sr. GA. Endoscopic laser arytenoidectomy revisited. *Ann Otol Rhinol Laryngol.* 1990;99(10 Pt 1):764-771.
50. Gorphe P, Hartl D, Primov-Fever A, Hans S, Crevier-Buchman L, Brasnu D. Endoscopic laser medial arytenoidectomy for treatment of bilateral vocal fold paralysis. *Eur Arch Otorhinolaryngol.* 2013;270(5):1701-1705.
51. Hu Y, Cheng L, Liu B, Ming H, Tian A, Ma M. The assistance of coblation in arytenoidectomy for vocal cord paralysis. *Acta Otolaryngol.* 2019;139(1):90-93.
52. Szmaja Z, Wójtowicz JG. Laser arytenoidectomy in the treatment of bilateral vocal cord paralysis. *Eur Arch Otorhinolaryngol.* 1999;256(8):388-389.
53. Yilmaz T, Süslü N, Atay G, Özer S, Günaydin RÖ, Bajin MD. Comparison of voice and swallowing parameters after endoscopic total and partial arytenoidectomy for bilateral abductor vocal fold paralysis: a randomized trial. *JAMA Otolaryngol Head Neck Surg.* 2013;139(7):712-718.
54. Misiolek M, Namyslowski G, Warmuzinski K, Karpe J, Rauer R, Misiolek H. The influence of laser arytenoidectomy on ventilation parameters in patients with bilateral vocal cord paralysis. *Eur Arch Otorhinolaryngol.* 2003;260(7):381-385.
55. Dispenza F, Dispenza C, Marchese D, Kulamarva G, Saraniti C. Treatment of bilateral vocal cord paralysis following permanent recurrent laryngeal nerve injury. *Am J Otolaryngol.* 2012;33(3):285-288.
56. Maurizi M, Paludetti G, Galli J, Cosenza A, Di Girolamo S, Ottaviani F. CO<sub>2</sub> laser subtotal arytenoidectomy and posterior true and false cordotomy in the treatment of post-thyroidectomy bilateral laryngeal fixation in adduction. *Eur Arch Otorhinolaryngol.* 1999;256:291-295.
57. Sarkis LM, Zaidi N, Norlén O, Delbridge LW, Sywak MS, Sidhu SB. Bilateral recurrent laryngeal nerve injury in a specialized thyroid surgery unit: would routine intraoperative neuromonitoring alter outcomes? *ANZ J Surg.* 2017;87(5):364-367.
58. Misono S, Merati AL. Evidence-based practice. *Otolaryngol Clin North Am.* 2012;45(5):1083-1108.
59. Maresch KJ. AANA Journal course—vocal cord paralysis: implications for anesthesia care. *AANA J.* 2021;89(5):443-448.
60. Witzel K, Messenbaeck F, Weitzendorfer M, Benhidjeb T. Transoral thyroidectomy: limitations, patients' safety, and own experiences. *Updates in Surgery.* 2017;69(2):193-198.
61. Li Y, Garrett G, Zelear D. Current treatment options for bilateral vocal fold paralysis: a state-of-the-art review. *Clin Exp Otorhinolaryngol.* 2017;10(3):203-212.
62. Davis RK, Shapshay SM, Vaughan CW, Strong MS. Pretreatment airway management in obstructing carcinoma of the larynx. *Otolaryngol Head Neck Surg.* 1981;89(2):209-214.
63. Gilony D, Gilboa D, Blumstein T, et al. Effects of tracheostomy on well-being and body-image perceptions. *Otolaryngol Head Neck Surg.* 2005;133(3):366-371.
64. Ejnell H, Mansson I, Bake B, Hallén O, Stenborg R, Lindström J. A simple operation for bilateral vocal cord paralysis. *Laryngoscope.* 1984;94(7):954-958.
65. Rovó L, Jóri J, Iván L, Brzózka M, Czigner J. "Early" vocal cord laterofixation for the treatment of bilateral vocal cord immobility. *Eur Arch Otorhinolaryngol.* 2001;258:509-513.

66. Oysu C, Sahin-Yilmaz A, Uslu C. Emergency endoscopic vocal cord lateralization as an alternative to tracheotomy for patients with bilateral abductor vocal cord paralysis. *Eur Arch Otorhinolaryngol.* 2012;269:2525-2529.
67. Naunheim MR, Song PC, Franco RA, Alkire BC, Shrime MG. Surgical management of bilateral vocal fold paralysis: a cost-effectiveness comparison of two treatments. *Laryngoscope.* 2017;127(3):691-697.
68. Ekblom DC, Garrett CG, Yung KC, et al. Botulinum toxin injections for new onset bilateral vo-cal fold motion impairment in adults. *Laryngoscope.* 2010;120(4):758-763.
69. Zealear DL, Billante CR, Sant'anna GD, Courey MS, Netterville JL. Electrically stimulated glottal opening combined with adductor muscle botox blockade restores both ventilation and voice in a patient with bilateral laryngeal paralysis. *Ann Otol Rhinol Laryngol.* 2002;111(6):500-506.
70. Bosley B, Rosen CA, Simpson CB, McMullin BT, Gartner-Schmidt JL. Medial arytenoidectomy versus transverse cordotomy as a treatment for bilateral vocal fold paralysis. *Ann Otol Rhinol Laryngol.* 2005;114(12):922-926.
71. Eckel HE, Thumfart M, Vössing M, Wassermann K, Thumfart WF. Cordectomy versus arytenoidectomy in the management of bilateral vocal cord paralysis. *Ann Otol Rhinol Laryngol.* 1994;103(11):852-857.
72. Abdelhamid MA, El-Badrawy A, Eldin OA, Hady AFA, Yousef A. A comparative study of laser posterior cordotomy and combined laser posterior cordotomy with suture lateralization in bilateral vocal cords abductor paralysis. *Am J Otolaryngol.* 2022;43(2):103334.
73. Karkos PD, Stavrakas M, Koskinas I, Markou K, Triaridis S, Constantinidis J. 5 Years of diode laser "II" technique for bilateral vocal fold immobility: a technique that improves airway and is friendly to the voice. *Ear Nose Throat J.* 2021;100(1\_suppl):83S-86S.
74. Khalifa MC. Simultaneous bilateral posterior cordectomy in bilateral vocal fold paralysis. *Otolaryngol Head Neck Surg.* 2005;132:249-250.
75. Dursun G, Gökcan MK. Aerodynamic, acoustic and functional results of posterior transverse laser cordotomy for bilateral abductor vocal fold paralysis. *J Laryngol Otol.* 2006;120(4):282-288.
76. Bizakis JG, Papadakis CE, Karatzanis AD, et al. The combined endoscopic CO(2) laser posterior cordectomy and total arytenoidectomy for treatment of bilateral vocal cord paralysis. *Clin Otolaryngol Allied Sci.* 2004;29(1):51-54.
77. Remacle M, Mayné A, Lawson G, Jamart J. Subtotal carbon dioxide laser arytenoidectomy by endoscopic approach for treatment of bilateral cord immobility in adduction. *Ann Otol Rhinol Laryngol.* 1996;105(6):438-445.
78. Garber D, Wandell GM, Gobillot TA, Merati A, Bhatt NK, Giliberto JP. Safety and predictors of 30-day adverse events of laryngeal framework surgery: an analysis of ACS-NSQIP data. *Laryngoscope.* 2022;132(7):1414-1420.
79. Mahieu R, Heuveling D, Mahieu H. Superomedial partial arytenoidectomy for voice improvement by correction of posterior glottic insufficiency. *Eur Arch Otorhinolaryngol.* 2020;277(5):1417-1426.
80. Marvin K, Coulter M, Johnson C, Friesen T, Morris K, Brigger MT. Dysphagia outcomes following surgical management of unilateral vocal fold immobility in children: a systematic review. *Otolaryngol Head Neck Surg.* 2023;168(4):602-610.
81. Aynehchi BB, McCoul ED, Sundaram K. Systematic review of laryngeal reinnervation techniques. *Otolaryngol Head Neck Surg.* 2010;143(6):749-759.
82. Hoey AW, Hall A, Butler C, Frauenfelder C, Wyatt M. Laryngeal reinnervation for paediatric vocal cord palsy: a systematic review. *Eur Arch Otorhinolaryngol.* 2022;279(12):5771-5781.
83. Crumley RL. Phrenic nerve graft for bilateral vocal cord paralysis. *Laryngoscope.* 1983;93:425-428.
84. Fancello V, Nouraei SAR, Heathcote KJ. Role of reinnervation in the management of recurrent laryngeal nerve injury: current state and advances. *Curr Opin Otolaryngol Head Neck Surg.* 2017;25(6):480-485.
85. Li M, Chen S, Zheng H, et al. Reinnervation of bilateral posterior cricoarytenoid muscles using the left phrenic nerve in patients with bilateral vocal fold paralysis. *PLoS One.* 2013;8(10):e77233.
86. Li M, Zheng HL, Chen SC, et al. Clinical analysis of selective laryngeal reinnervation using upper root of phrenic nerve and hypoglossal nerve branch in the treatment of bilateral vocal fold paralysis. *Zhonghua Er Bi Yan Hou Tou Jing Wai Ke Za Zhi.* 2020;55(11):1016-1021.
87. Orestes MI, Chhetri DK, Berke G. Selective reinnervation for bilateral vocal cord paralysis using the superior laryngeal nerve. *Laryngoscope.* 2015;125:2547-2550.
88. Marie JP, Laquerriere A, Choussy O, et al. Thyrohyoid branch of the hypo- glossal nerve in the canine: perspectives for larynx reinnervation. *Eur Arch Otorhinolaryngol.* 2000;257:S1-S11.
89. Zealear DL, Billante CR, Courey MS, et al. Reanimation of the paralyzed human larynx with an implantable electrical stimulation device. *Laryngoscope.* 2003;113(7):1149-1156.
90. Mueller AH, Hagen R, Foerster G, Grossmann W, Baumbusch K, Pototschnig C. Laryngeal pacing via an implantable stimulator for the rehabilitation of subjects suffering from bilateral vocal fold paralysis: a prospective first-in-human study. *Laryngoscope.* 2016;126(8):1810-1816.