



HAL
open science

Coronary artery embolism and acute coronary syndrome: A critical appraisal of existing data

Antoine Monin, Romain Didier, Thibault Leclercq, Frédéric Chagué, Luc Rochette, Nicolas Danchin, Marianne Zeller, Laurent Fauchier, Alexandre Cochet, Yves Cottin

► To cite this version:

Antoine Monin, Romain Didier, Thibault Leclercq, Frédéric Chagué, Luc Rochette, et al.. Coronary artery embolism and acute coronary syndrome: A critical appraisal of existing data. Trends in Cardiovascular Medicine, 2024, 34 (1), pp.50 - 56. 10.1016/j.tcm.2022.07.004 . hal-04626354

HAL Id: hal-04626354

<https://hal.science/hal-04626354>

Submitted on 26 Jun 2024

HAL is a multi-disciplinary open access archive for the deposit and dissemination of scientific research documents, whether they are published or not. The documents may come from teaching and research institutions in France or abroad, or from public or private research centers.

L'archive ouverte pluridisciplinaire **HAL**, est destinée au dépôt et à la diffusion de documents scientifiques de niveau recherche, publiés ou non, émanant des établissements d'enseignement et de recherche français ou étrangers, des laboratoires publics ou privés.



Contents lists available at ScienceDirect

Trends in Cardiovascular Medicine

journal homepage: www.elsevier.com/locate/tcm

Coronary artery embolism and acute coronary syndrome: A critical appraisal of existing data ☆☆☆

Antoine Monin^{a,1}, Romain Didier^{a,1}, Thibault Leclercq^a, Frédéric Chagué^a, Luc Rochette^b, Nicolas Danchin^c, Marianne Zeller^{a,b}, Laurent Fauchier^d, Alexandre Cochet^e, Yves Cottin^{a,*}^a Department of Cardiology, University Teaching Hospital of Dijon Bourgogne, Dijon, France^b PEC2, EA 7460, University of Burgundy, Dijon, France^c Department of Cardiology, University Teaching Hospital of Georges Pompidou, Paris, France^d Department of Cardiology, University Teaching Hospital of Trousseau and François Rabelais University, Tours, France^e Department of Magnetic Resonance Imaging, University Teaching Hospital of Dijon Bourgogne, Dijon, France

ARTICLE INFO

Keywords:

Coronary artery embolism
Acute coronary syndrome, Atrial fibrillation
Type 1 and type 2 Myocardial Infarction
Cardio-cerebral Infarction
Prognosis

ABSTRACT

The occurrence of coronary artery embolism (CE) has been associated with various clinical conditions, including aortic and mitral prosthetic heart valve implantation, atrial fibrillation (AF), dilated cardiomyopathy, neoplasia, infective endocarditis, atrial septal defect, cardiac tumors, and hypercoagulable states. CE is also a rare cause of myocardial infarction (MI), with a prevalence of about 5%, a figure probably underestimated. The purpose of this article was to determine the current state of knowledge on acute coronary syndrome (ACS) related to CE. We thus performed a comprehensive structured literature search of the MEDLINE database for articles published between 1 January 1990 and 31 December 2021. The diagnosis of CE remains difficult despite the currently used Shibata classification, which is based on major criteria, including angiographic characteristics: globular filling defects, saddle thrombi or multiple filling defects and absence of atherosclerosis in the coronary arteries. Suspected or confirmed CE requires the identification of an etiology. There are only two published series on CE, including about 50 cases each. The three main causes in these series were: 1) atrial fibrillation (73% vs 28.3%), 2) cardiomyopathy (9.4% vs 25%) and 3) malignancy (9.6% vs 15.1%). Finally, 26.3% of the MI patients with CE had no identifiable cause of CE. When anatomically possible, analyzing the thrombus after thrombectomy may help. MI due to CE requires systematic assessment of other locations, i.e. multiple coronary and extracardiac locations. Simultaneous systemic embolization to the brain (67%), limbs (25%), kidneys (25%) or spleen (4%) is frequent, occurring in approximately 25% of CE-related MI. In the setting of acute MI, CE is associated with significant morbidity and mortality. Coronary artery thromboembolism is a rare, non-atherosclerotic, cause of ACS, and prospective studies are needed to evaluate a systematic diagnostic approach and personalized therapeutic strategies.

© 2022 The Authors. Published by Elsevier Inc.

This is an open access article under the CC BY license (<http://creativecommons.org/licenses/by/4.0/>)

Introduction

Abbreviations: ACS, acute coronary syndrome; AF, atrial fibrillation; CA, coronary angiogram; CCI, cardio-cerebral infarction; CE, coronary artery embolism; CMR, cardiac magnetic resonance imaging; IVUS, intravascular ultrasound; MI, myocardial infarction; MINOCA, myocardial infarction with non-obstructive coronary artery disease; NSTEMI, non ST-elevation myocardial infarction; OCT, optic coherence tomography; STEMI, ST-elevation myocardial infarction; T1MI, type 1 myocardial infarction; T2MI, type 2 myocardial infarction.

* **Funding:** This work was supported by the Dijon-Bourgogne University Hospital, the Association de Cardiologie de Bourgogne, and by grants from the Agence Régionale de Santé (ARS) de Bourgogne Franche-Comté, and from the Regional Council of Bourgogne Franche-Comté.

☆☆ **Declaration of competing interest:** No conflict of interest to disclose for the other authors.

* Corresponding author.

E-mail address: yves.cottin@chu-dijon.fr (Y. Cottin).¹ These authors contributed equally to this work.

Plaque rupture followed by intracoronary thrombus formation is the most common underlying mechanism of myocardial infarction (MI) [1]. However, MI with nonobstructive coronary artery disease (MINOCA) is a group of conditions that share common angiographic findings. MINOCA is characterized by the absence of $\geq 50\%$ coronary stenosis and no evidence of ruptured atherosclerotic plaque, and it is reported in 5–8% of ACS [2–4]. Coronary embolism (CE) is currently addressed in the classification proposed by De Lemos, derived from The Fourth Universal Definition of MI, to classify CE as a type C subgroup in Type 1 MI (i.e. with acute coronary obstruction) [1,5]. Acute MI secondary to CE was first reported in 1856 by Rudolf Virchow, initially clas-

sified as a precipitating factor for type 2 MI, and is now recognized as a cause of MINOCA [4]. The prevalence, clinical features, and clinical outcome of CE, however, remain poorly investigated. The objective of this article was thus to provide an overview of what is currently known about MI related to CE (Type 1C MI), including frequency, etiologies, diagnostic approaches, therapy, and prognosis.

Methods

We performed a comprehensive structured literature search using the MEDLINE database (PubMed; National Library of Medicine, NIH, Bethesda, MD, USA). We analyzed publications dated 1 January 1990 through 31 December 2021 with the following search terms, individually and in combination: *coronary artery embolism, thromboembolism, myocardial infarction, acute coronary syndrome, follow-up, prognosis, endocarditis, atrial fibrillation, extracardiac embolism.*

Epidemiology of coronary embolism

CE is recognized as a nonatherosclerotic cause of ST-segment-elevation or non-ST-segment-elevation MI (STEMI and NSTEMI) with a prevalence ranging from 4% to 13% according to angiographic or autopsy studies [6].

The prevalence of CE was first estimated from an autopsy series of 55 patients with acute MI [6]: 13% were considered related to CE, since thrombotic material was found in the coronary arteries, without evidence of acute plaque rupture, thereby suggesting an embolic source. Most of the patients had underlying valvular heart disease, cardiomyopathy, or atrial fibrillation [6].

However, the majority of cases are limited to clinical observations and only three series addressed CE prevalence [7–9]. In 2015, Shibata et al. reported a prevalence of 2.9% (n = 52) in a cohort of 1776 consecutive patients with a first acute MI, including eight patients with multivessel CE (15% of CE cases, 0.4% of the total cohort) (Table 1) [8].

The second cohort published in 2018 included 1232 patients with ST-segment elevation MI; 53 patients were diagnosed with CE

(4.3%), including 12 (22.6% of CE cases) patients with multisite CE and 9 patients with concomitant extracoronary locations (Table 1) [7].

In 2020, Schoepfer et al. reported a very low prevalence of CE, with only 2 patients among 1364 patients presenting with a first acute MI (0.2%) (Table 1) [9].

This 20-fold difference in the prevalence of CE emphasizes the need for more accurate tools than coronary angiography to reliably establish the diagnosis of CE.

Because of the limited number of patients with CE in these three cohorts, no significant differences for age and cardiovascular risk factors were observed between patients with CE and other MI subtypes.

Criteria for the diagnosis of CE

CE is rarely described as a cause of acute MI, and the diagnosis of CE, based on both angiographic and clinical criteria, remains difficult. The proposed criteria for the clinical diagnosis of coronary artery embolism are based on angiographic features and/or the presence of predisposing factors or comorbidities [8]. The Shibata classification is based on major criteria including the angiographic characteristics of CE such as: globular filling defects, saddle thrombi or multiple filling defects and no atherosclerotic findings in the coronary trees (Fig. 1) [8]. The existence of concomitant systemic embolization without left ventricular thrombus attributable to acute MI is also a major criterion, i.e., aortic and mitral prosthetic heart valves, atrial fibrillation (AF), dilated cardiomyopathy, neoplasia, infective endocarditis, atrial septal defect, cardiac tumor, and hypercoagulable states. Also, according to Shibata’s criteria, the diagnosis can be definite (two or more major criteria, or one major criterion plus ≥2 minor criteria, or three minor criteria) or probable (one major criterion plus one minor criterion, or two minor criteria) (Table 2) [8]. In the Shibata cohort, only 32 out of 52 cases were classified as definite (61.5%), highlighting the difficulty of confirming the diagnosis of CE. Likewise, in the Popovic STEMI cohort, 53 were identified as having CE, with 33 definite (62%) and 20 probable cases (38%) [7]. While CE remains challenging to diagnose, future intravascular imaging studies are ex-

Table 1
Major findings of published series on coronary embolism.

Study	Study Period	Number of Patients	Number of CE (%)	Underlying cause of CE	Multisite CE	Simultaneous systemic Embolization
Shibata T, et al. [8]	2001–2013	1776 patients with ACS	52 patients (2.9%)	AF = 73% Intracardiac tumor = 0% Dilated Cardiomyopathy = 25% Valvular Prosthesis = 7.7% Embolism from a deep vein thrombus = 3.8% Thoracic aorta thrombus = 0% Malignancy = 9.6% Antiphospholipid syndrome = 0% Septic emboli from endocarditis = 3.8%	15%	23%
Popovic B, et al. [7]	2006–2015	1232 NSTEMI-ACS	53 patients (4.3%)	AF = 28.3% Intracardiac tumor = 5.7% Dilated Cardiomyopathy = 9.4% Valvular Prosthesis = 3.8% Embolism from a deep vein thrombus = 1.9% Thoracic aorta thrombus = 3.8% Malignancy = 15.1% Antiphospholipid syndrome = 7.5% Septic emboli from endocarditis = 7.5%	22.6%	22.6%
Schoepfer H, et al. [9]	NA	1364 patients with ACS	2 patients (0.2%)	NA	NA	NA

CE: Coronary artery Embolism.
AF: Atrial Fibrillation.
ACS: Acute Coronary Syndrome.

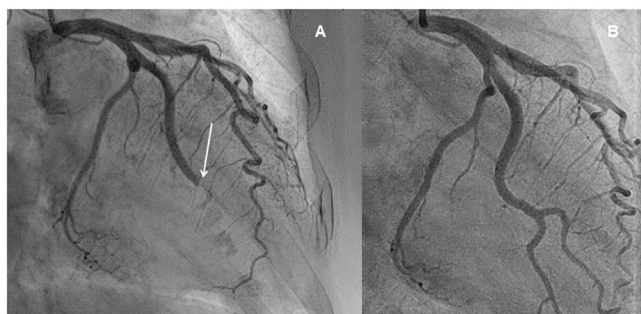

Fig. 1. An example of the angiographic aspect of Coronary artery Embolism. Coronary angiogram showing distal occlusion of the left circumflex branch (white arrow) (A). Normalization of coronary flow after thrombectomy without angioplasty or stenting (B).

pected to improve its identification. Most studies had a number of exclusion factors suggesting that the prevalence of CE may be underestimated, including (1) pathological evidence of atherosclerotic thrombus, (2) coronary artery ectasia, (3) plaque disruption or coronary erosion detected by intravascular ultrasound (IVUS) or optic coherence tomography (OCT) on the proximal site of the culprit lesion, (4) history of coronary revascularization, and (5) patients with $\geq 25\%$ coronary artery stenosis outside of the culprit lesion on coronary angiography [7,8,10]. Underdiagnosing CE cases may also be due to additional factors such as the time between coronary angiography and clinical symptomatology; the anticoagulants and/or thrombolytic used for ischemic stroke, which can contribute to the dissolution of a coronary thrombus. Also, small size CE, which would not lead to STEMI, but which could be revealed by cardiac magnetic resonance imaging (CMR) with gadolinium injection and a late enhancement sequence analysis [11].

When possible, thrombus analysis after manual thrombectomy has been suggested to improve diagnosis. In the Popovic cohort, 40% of the 53 CE cases underwent manual thrombectomy; histopathological analysis was performed in 5 cases, identifying septic embolism ($n = 2$), neoplasia tissue ($n = 1$) and thrombus ($n = 2$) [7].

Table 2

Proposed criteria for the clinical diagnosis of coronary artery embolism (CE) according to Shibata, et al. [8].

Major criteria

- Angiographic evidence of coronary artery embolism and thrombosis without atherosclerotic components
- Concomitant coronary artery embolization at multiple sites*
- Concomitant systemic embolization without left ventricular thrombus attributable to acute myocardial infarction

Minor criteria

- $< 25\%$ stenosis on coronary angiography, except for the culprit lesion
- Evidence of an embolic source based on transthoracic echocardiography, transesophageal echocardiography, computed tomography, or MRI
- Presence of embolic risk factors: atrial fibrillation, cardiomyopathy, rheumatic valve disease, prosthetic heart valve, patent foramen ovale, atrial septal defect, history of cardiac surgery, infective endocarditis, or hypercoagulable state

Definite CE: Two or more major criteria, or one major criterion plus ≥ 2 minor criteria, or three minor criteria

Probable CE: One major criterion plus 1 minor criterion, or two minor criteria

CE: Coronary artery Embolism, MRI: Magnetic Resonance Imaging.

* Indicates multiple vessels within 1 coronary artery territory or multiple vessels in the coronary tree.

Among patients presenting with ACS, it is estimated that 5% have normal and 25% have near normal ($< 50\%$ stenosis) coronary arteries on coronary angiography, and that two-thirds of the patients present with non-ST elevation MI (NSTEMI) versus one-third with ST-elevation MI (STEMI) [12–14]. In the Shibata cohort, 65% of the 52 patients with CE-related acute coronary syndrome present with ST-elevation MI (STEMI), suggesting a higher prevalence of STEMI in CE-related ACS population.

MINOCA and coronary artery embolism

Coronary artery emboli represent a frequent and recognized cause of MINOCA. However, the angiographic diagnostic criteria may underestimate the frequency of coronary emboli causing acute myocardial injury detected by a rise in troponins, while the angiographic aspect may remain normal. Indeed, in the absence of obstructive coronary artery disease or angiographic appearance in favor of an embolic origin, the criteria proposed by Shibata et al. are not met. The current resolution of coronary angiography techniques does not allow detection of small thrombi, limiting visual analysis to the epicardial coronary vascularization.

Contribution of cardiac MRI

Cardiac MRI is recognized as a key examination in the etiological assessment of MINOCA [4]. Similarly, its interest in the etiological assessment of embolic ACS appears major. Analysis of fibrotic zones within the myocardium is based on the distribution of the contrast agent at 10 min of injection of Gadolinium chelate. The diagnosis of myocardial infarction is based on a distribution of the contrast agent in the subendocardial region (subendocardial late gadolinium enhancement), either partial or transmural; contrasting with a differential diagnosis based on a preferential distribution in the mesomyocardial and/or subepicardial region. The most common etiology of myocardial infarction is acute rupture of an atheromatous plaque in the coronary artery. Therefore, late enhancement on cardiac MRI is distributed along a coronary territory corresponding to several segments of the "Bull's Eye". On cardiac MRI performed for a MINOCA, localized late enhancement < 1 segment but nevertheless transmural is suggestive of a localized infarct of small extent, suspicious of an acute and abrupt occlusion of the distal coronary tree. The presence of a possible "no-flow" in such a localized transmural area reinforces the acute and abrupt character of this infarction. Because of its frequency, the occlusion of a distal branch suggests an embolic origin in the first place. This hypothesis is reinforced in the presence of a double location corresponding to 2 distinct coronary territories.

Causes of coronary artery embolism

CE observed in ACS can be divided into three categories:

- 1) Direct CE secondary to thrombus originating from the left atrial appendage, left ventricle, the aortic or mitral valves, pulmonary veins, or aorta [12,15–20]. Direct CE may result from endocarditis and more rarely from cardiac tumors. Clinically significant CE has been reported in 1.5% of cases with infective endocarditis, and microemboli in the coronary arterial trees were present in more than 60% of cases on postmortem examination [12,21,22].
- 2) Paradoxical emboli through a patent foramen ovale, atrial septal defect, or pulmonary arteriovenous malformations, from the venous circulation into the systemic circulation, most commonly originating from deep vein thrombosis [12]. The incidence of paradoxical embolism is currently unknown.

3) Iatrogenic emboli may occur following interventional procedures, usually aortic valve replacements and percutaneous coronary interventions. Due to the acute or right angle taken from the aortic root, the probability of CE decreases when compared with other systemic embolisms. From an anatomical point of view, the coronary arteries appear to be relatively protected from embolic events compared with other emboli to the systemic circulation [12,13]. Although rare, coronary air embolism remains one of the inevitable complications of percutaneous coronary interventions (PCI), with an incidence estimated from 0.1% to 0.3% [23]. This is a potentially fatal complication, given the risk of abrupt vessel occlusion, usually resulting from incomplete aspiration of catheters or balloon rupture. In most cases, the volume of air is extremely small, and devoided of consequence to the patient. When an air lock develops, therapy is directed at maintaining coronary blood flow while attempting to promote dissipation of the air bubble: ventilation with 100% oxygen, increasing the mean arterial pressure, forceful injection of contrast and saline. Embolization of devices such as coronary stents is very rare but a dramatic complication of PCI, with a prevalence of 0.32%, favored by the tortuous coronary anatomy and coronary calcifications [23]. Embolization of intraplaque debris or of microthrombi during primary PCI for STEMI is less unusual, but can be considered a different entity.

Some patients may have thrombus with underlying atherosclerosis, complicating the diagnosis. If aspiration results in full restoration of coronary flow and a normal angiographic appearance, IVUS or OCT can be used to further assess the potential embolic source of isolated plaque erosion [13,24,25].

To date, only two publications on CE, limited to about 50 cases each, have reported the causes of CE [7,8]. Table 1 presents the causes of CE in each series, showing wide variations in the percentage of causes, in particular for atrial fibrillation (73% and 28.3%), cardiomyopathy (25% and 9.4%) and malignancy (9.6% and 15.1%) (Table 1) [7,8,11]. In addition, the Popovic STEMI cohort had a high rate (26.3%) of CE without any identifiable cause [7].

Specific mention should be made of MI with the presence of left intraventricular thrombus: in such cases, CE may be either the cause (MI resulting in the development of ventricular thrombus) or consequence (CE might originate from a pre-existing ventricular thrombus).

Other rarer causes of CE have been reported, generally as clinical cases, confirming the need to carry out an exhaustive assessment of the origin of CE.

Multivessel CE and other extracoronary localization

ACS attributable to multiple CE appears to be frequent since it has been reported in 15% and 23% of cases [7,8], and the presence of multiple CE is considered to be a major diagnostic criterion. In both studies, simultaneous systemic embolization was frequent (approximately 25% of cases), mainly to the brain (67%), limbs (25%), kidneys (25%) and spleen (4%) [7,8]. However, in these studies, in the absence of clinical signs, the additional sites were brought to light by systematic extension assessment.

Simultaneous cerebral and myocardial infarction, so-called cardio-cerebral infarction (CCI), is only rarely reported. In addition, because of the narrow time frame for the concomitance of the two events and the complex pathophysiology, diagnosis and management are challenging.

Extracoronary localization in patients with AF

As mentioned above, CCI is a rare clinical entity, with a prevalence rate of about 0.25% among patients admitted for acute myocardial or cerebral infarctions [35]. A recent review from our

group comprehensively analyzed the 10 published clinical cases reporting coexisting acute MI and ischemic stroke in patients with AF [11,26–34]. These cases had clinical signs of stroke and indisputable clinical and/or electrocardiographic signs of acute cardiac syndrome, of whom most were STEMI. However, in the largest institutional study on this subject, angiographic data was not available, in particular regarding the presence of CE.

So far, only one prospective study has systematically searched for MI caused by CE in patients with embolic stroke associated with de novo AF. The frequency of simultaneous cardiac and cerebral ischemia diagnosed according to the Shibata criteria was as high as 35% (12/34 patients), and CE was identified in 3/12 (25%) patients who underwent coronary angiography [36]. These findings suggest that CE are probably underestimated for multiple reasons: a) the disappearance of visualized CEs due to anticoagulation/thrombolysis used to treat the ischemic stroke; b) the difficulty of diagnosing NSTEMI since changes in the ST segment are frequent (24%) at the acute stage of ischemic stroke and coronary angiography is not routinely performed [37–40]; c) the presence of distal coronary emboli that are not picked up by coronary imaging [7,8]. In our observational study, coronary angiography was done in 44% of the patients, and a CT scan was performed in the remaining patients (85%) to eliminate coronary artery disease [36]. However, CT may be of limited interest for detecting CE, particularly if the emboli are distal. In addition, myocardial injury at the acute phase of ischemic stroke linked to AF, may correspond to type 2 MI due to tachy-arrhythmia or brady-arrhythmia [41].

Extracoronary localization in patients with other CE etiologies

In patients without atrial fibrillation, other extracoronary situations can be associated with CE, such as infective endocarditis, CE related to aortic or mitral prosthesis and aortic thrombus.

In an older case series of 586 patients with infective endocarditis (IE), the incidence of ACS was 2.9% (14 patients) [42] and risk factors associated with CE included mobile vegetation, vegetation >10 mm, staphylococcus aureus or non-Viridans streptococcal infections, and previous embolism [43,44]. In addition, ACS usually occurred within the first 15 days of infectious disease onset [42]. CE can be also an iatrogenic complication of coronary angiography; current guidelines recommend coronary multi-slice computer tomography as an alternative in case of high embolic risk [45–47].

There are only four reported cases of simultaneous coronary and cerebral embolization related to thrombus in the ascending aorta [15,18,48,49]. However, thrombus of the ascending aorta is more frequently associated with distal embolization, particularly with acute lower limb ischemia, or discovered by chance.

Prosthetic valve obstruction can be caused by pannus and/or thrombus. In cases of acute presentation, treatment by fibrinolytic therapy or surgery is recommended [50]. There are no data available of the prevalence of ACS in acute prosthetic valve obstruction.

Therapeutic strategy

The therapeutic approach to CE should be individualized, and must be directly linked to 1) the patient's characteristics; 2) the time of presentation (the time elapsed since symptom onset); 3) the etiology (atrial fibrillation, endocarditis, prosthetic thrombosis); and 4) the presence or absence of simultaneous extracoronary embolic sites [51].

Algorithm for disease management

Aoun et al. suggested an algorithm for the management of CE [52]. Small and distal CE with no hemodynamic instability should lead to anticoagulation alone, whereas high intracoronary thrombus burden with instability should lead to thrombus aspiration.

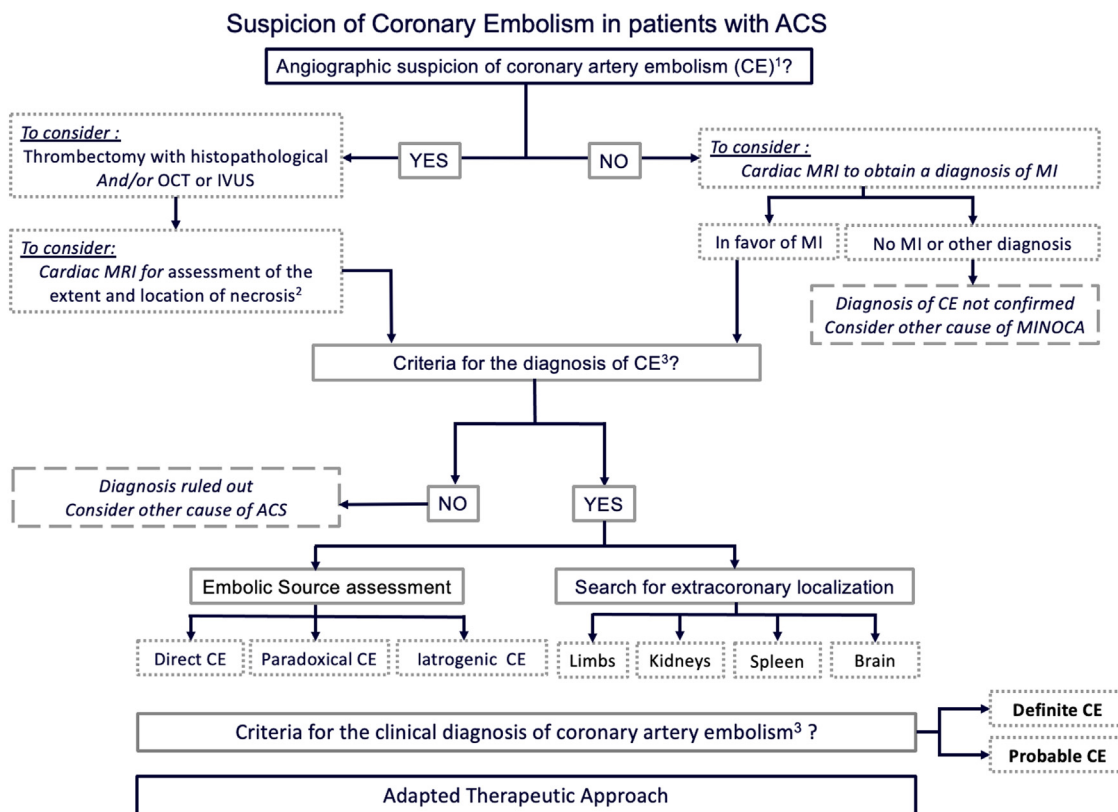


Fig. 2. Proposal of diagnostic management strategy in case of suspicion of coronary embolism in patients with ACS.

ACS: Acute Coronary Syndrome, CE: Coronary artery Embolism, OCT: Optical Coherence Tomography, IVUS: Intravascular Ultrasound, MI: Myocardial Infarction, MINOCA: Myocardial Infarction with NonObstructive Coronary Artery disease, MRI: Magnetic Resonance Imaging ¹Consider coronary multi-slice computed tomography as an alternative in case of high embolic risk. ²In particular small sequelae or older embolisms that would not have clinical consequences. ³According to Shibata's criteria

If the angiography is suggestive of a coronary embolism and if coronary anatomy is favorable, thrombectomy can be attempted; importantly, the fragments removed should be analyzed. The role of intracoronary thrombolysis or glycoprotein IIb/IIIa inhibitors has not been investigated in randomized clinical trials but is very frequently described in clinical cases. In addition, Popovic et al. emphasize that interventional coronary procedures were characterized by a higher use of glycoprotein IIb/IIIa inhibitors and a lower use of angioplasty in the CE group compared to the non-CE group, respectively, 73.9% vs 37.7% and 45.3% vs 95.5% [7].

Primary stenting may be considered if TIMI is <2 after thrombus aspiration. IVUS or OCT may be considered if TIMI is ≥2 after thrombus aspiration and the clinical team wishes to look for plaque erosion [52]. A minimalistic revascularization procedure should be preferred to obtain a TIMI flow grade 3, without stenting if possible [7].

In case of CE related to AF, long term anticoagulation is required. In the Shibata cohort, only 15 (39%) of the 38 AF patients in the CE group had been treated with a vitamin K antagonist before the CE event, and their median international normalized ratio (INR) was 1.42 (range, 0.95–1.80) [8]. No patients were on direct oral anticoagulants; of the 30 patients with new onset AF, 18 (60%) had a CHADS2 score of 0 or 1 before CE occurred [8].

Specific considerations depending on etiology

Ascendant aortic thrombosis, aortic mobile vegetation, and aortic prosthetic thrombosis should contraindicate coronarography for obvious reasons. Surgery should be considered in case of infective endocarditis, fibroelastoma, or cardiac tumor. Prosthetic valve thrombosis should be treated with fibrinolysis or emergency surgery [44,47,52].

Specific considerations in the case of simultaneous cerebral embolization

CCI may limit the use of thrombolysis or anticoagulation therapy if the stroke is at risk of hemorrhage. Moreover, the rupture of the blood-brain barrier contraindicates extracorporeal circulation.

In case of simultaneous cardio-cerebral embolization, presentation with STEMI should lead to a minimalistic cardiac revascularization procedure associated with cerebral thrombectomy and/or thrombolysis, if eligible. In all cases, given the risk of intracerebral hemorrhage, the therapeutic strategy must be discussed with the neurology team.

Long-term follow-up after CE

After 5 years of follow-up, Shibata et al. found a recurrence of thromboembolism after a CE in 5/52 patients (10.4%), including two new cases of CE (4.2%) and three case of stroke (6.3%), but no cases of clinical embolism to other organs [8].

Popovic et al., detected but no recurrent MI or thromboembolism after a median follow-up of 45.1 months; 11 deaths were observed [7]. Among those, 7 (64%) had a cardiovascular cause, and sepsis and neoplasia caused the other deaths. In addition, CE was associated with a higher risk of death (crude hazard ratio, 4.87; 95% confidence interval, 2.52–9.39; P < 0.0001), compared with patients without CE [7].

CE is an under-recognized etiology of MI, but it is associated with significant morbidity and mortality. Cardiac MRI can identify ischemic myocardial sequelae when there is a suspicion of CE, in particular without obstructive chronic coronary syndrome. In addition, CMR can detect small sequelae that would not cause STEMI or older embolisms that would not have clinical consequences.

Conclusions

Coronary artery thromboembolism is a rare nonatherosclerotic cause of ACS that remains a clinical challenge. Accurate etiological diagnosis is required in order to offer tailored treatment (Fig. 2). In the future, the association of CE and ACS warrants investigation in prospective multicenter studies.

Acknowledgments

YC reports having received grants, consulting fees, honoraria and/or delivering lectures for Servier, Novartis, Boehringer, Pfizer, and BMS. MZ received research grants from Amarin Corp.

LF reports having received grants, consulting fees, honoraria and/or delivering lectures for Novartis, Boehringer, Pfizer, BMS and Medtronic. ND reports having received grants, consulting fees, honoraria from and/or delivering lectures for Amgen, AstraZeneca, Bayer, BMS, Boehringer Ingelheim, MSD, Novo-Nordisk, Sanofi, Servier, UCB, Vifor.

References

- Thygesen K, Alpert JS, Jaffe AS, Chaitman BR, Bax JJ, Morrow DA, et al. Fourth universal definition of myocardial infarction (2018). *J. Am. Coll. Cardiol.* 2018;72:2231–64.
- Pasupathy S, Air T, Dreyer RP, Tavella R, Beltrama JF. Systematic review of patients presenting with suspected myocardial infarction and nonobstructive coronary arteries. *Circulation* 2015;131:861–70.
- Tamis-Holland JE, Jneid H, Reynolds HR, Agewall S, Brilakis ES, Brown TM, et al. Contemporary diagnosis and management of patients with myocardial infarction in the absence of obstructive coronary artery disease: a scientific statement from the American Heart Association. *Circulation* 2019;139:e891–908.
- Agewall S, Beltrame JF, Reynolds HR, Niessner A, Rosano G, Caforio ALP, et al. ESC working group position paper on myocardial infarction with nonobstructive coronary arteries. *Eur. Heart J.* 2017;38:143–53.
- De Lemos JA, Newby LK, Mills NL. A proposal for modest revision of the definition of type 1 and type 2 myocardial infarction. *Circulation* 2019;140:1773–5.
- Prizel KR, Hutchins GM, Bulkley BH. Coronary artery embolism and myocardial infarction. *Ann. Intern. Med.* 1978;88:155.
- Popovic B, Agrinier N, Bouchahda Pinelli S, Maigrat CH, Metzendorf PA, et al. Coronary embolism among ST-segment-elevation myocardial infarction patients mechanisms and management. *Circ Cardiovasc Interv* 2018;11:e005587.
- Shibata T, Kawakami S, Noguchi T, Tanaka T, Asaumi Y, Kanaya T, et al. Prevalence, clinical features, and prognosis of acute myocardial infarction attributable to coronary artery embolism. *Circulation* 2015;132:241–50.
- Schoepfer H, Nestlberger T, Boeddinghaus J, Twerenbold R, Lopez-Ayala P, Koechlin L, et al. Effect of a proposed modification of the type 1 and type 2 myocardial infarction definition on incidence and prognosis. *Circulation* 2020;142:2083–5.
- Hernández F, Pombo M, Dalmau R, Andreu J, Alonso M, Albarrán A, et al. Acute coronary embolism: angiographic diagnosis and treatment with primary angioplasty. *Catheter. Cardiovasc. Interv.* 2002;55:491–4.
- Mione V, Yao H, Laurent G, Zeller M, Fauchier L, Cottin Y. Simultaneous cardio-cerebral embolization in patients with atrial fibrillation. *Arch Cardiovasc Dis* 2020;113:821–7.
- Raphael CE, Heit JA, Reeder GS, Bois MC, Maleszewski Tilbury RT, et al. Coronary embolus. an underappreciated cause of acute coronary syndromes. *JACC Cardiovasc Interv* 2018;11:172–80.
- Sucato V, Testa G, Puglisi S, Evola S, Galassi AR, Novo G. Myocardial infarction with non-obstructive coronary arteries (MINOCA): intracoronary imaging-based diagnosis and management. *J. Cardiol.* 2021;77:444–51.
- Safdar B, Spatz ES, Dreyer RP, Beltrame JF, Lichtman JH, Spertus JA, et al. Presentation, clinical profile, and prognosis of young patients with myocardial infarction with nonobstructive coronary arteries (MINOCA): results from the virgo study. *J. Am. Heart Assoc.* 2018;7:e009174.
- Issa R, Gallissot F, Cochet A, Cottin Y. Hyperacute simultaneous cardiocerebral infarction related to floating thrombus in the ascending aorta: a case report. *European Heart Journal - Case Reports* 2021;5:1–8.
- Colombo GM, Albi F, Salvini P, Sacco T, Cicchinelli M. Ischemic stroke with cardiac involvement in aortic thromboembolism. *Minerva Cardioangi.* 2006;54:779–81.
- Rawashdeh SI, Al-Mistarehi AH, Yassin A, Rabab'ah W, Skaff H, Ibdah R. A concurrent ischemic stroke, myocardial infarction, and aortic thrombi in a young patient with hyperhomocysteinemia: a case report. *Int Med Case Rep J* 2020;13:581–90.
- Jaafari A, Benyoussef S, Selmi K, Boukhriss B, Boujnef MR. Infarctus du myocarde associé à un accident vasculaire ischémique révélateur d'un thrombus de l'aorte thoracique ascendante [Myocardial infarction associated with stroke revealing a thrombus of the ascending aorta]. *Ann. Cardiol. Angeiol. (Paris)* 2004;53:105–8.
- Chen YY, Yen HT, Wu CC, Huang KR, Sheu JJ, Lee FY. Aortic thrombus in a nonaneurysmal ascending aorta. *Ann. Vasc. Surg.* 2021;72:617–26.
- Fayad ZY, Semaan E, Fahoum B, Briggs M, Tortolani A, D'Alaya M. Aortic mural thrombus in the normal or minimally atherosclerotic aorta. *Ann. Vasc. Surg.* 2013;27:282–90.
- Brunson JG. Coronary embolism in bacterial endocarditis. *Am. J. Pathol.* 1953;29:689–701.
- Saphir O, Katz LN, Gore I. The myocardium in subacute bacterial endocarditis. *Circulation* 1950;1:1155–67.
- Dash D. Complications of coronary intervention: device embolisation, no-reflow, air embolism. *Heart Asia* 2013;5:54–8.
- Alfonso F, Canales E, Aleong G. Spontaneous coronary artery dissection: diagnosis by optical coherence tomography. *Eur. Heart J.* 2009;30:385.
- Cohoon KP, Heit JA. Inherited and secondary thrombophilia: clinician update. *Circulation* 2014;129:254–7.
- Abe S, Tanaka K, Yamagami H, Sonoda K, Hayashi H, Yoneda S, et al. Simultaneous cardio-cerebral embolization associated with atrial fibrillation: a case report. *BMC Neurol.* 2019;19:152.
- Chlapoutakis GN, Kafkas NV, Katsanos SM, Kiriakou LG, Floros GV, Mpampalis DK. Acute myocardial infarction and transient ischemic attack in a patient with lone atrial fibrillation and normal coronary arteries. *Int. J. Cardiol.* 2010;139:e1–4.
- Hashimoto O, Sato K, Numasawa Y, Hosokawa J, Endo M. Simultaneous onset of myocardial infarction and ischemic stroke in a patient with atrial fibrillation: multiple territory injury revealed on angiography and magnetic resonance. *Int. J. Cardiol.* 2014;172:e338–40.
- Kijpaisalratana N, Chutinet A, Suwanwela NC. Hyperacute simultaneous cardiocerebral infarction: rescuing the brain or the heart first? *Front Neurol* 2017;8:664.
- Kim HL, Seo JB, Chung WY, Zo JH, Kim MA, Kim SH. Simultaneously presented acute ischemic stroke and non-ST elevation myocardial infarction in a patient with paroxysmal atrial fibrillation. *Korean Circ J* 2013;43:766–9.
- Kleczyński P, Dziejewicz A, Rakowski T, Rzeszutko L, Sorysz D, Legutko J, et al. Cardioembolic acute myocardial infarction and stroke in a patient with persistent atrial fibrillation. *Int. J. Cardiol.* 2012;161:e46–7.
- Maciel R, Palma R, Sousa P, Ferreira F, Nzwalo H. Acute stroke with concomitant acute myocardial infarction: will you thrombolysate? *J Stroke* 2015;17:84–6.
- Omar HR, Fathy A, Rashad R, Helal E. Concomitant acute right ventricular infarction and ischemic cerebrovascular stroke; possible explanations. *Int Arch Med* 2010;3:25.
- Tokuda K, Shindo S, Yamada K, Shirakawa M, Uchida K, Horimatsu T, et al. Acute embolic cerebral infarction and coronary artery embolism in a patient with atrial fibrillation caused by similar thrombi. *J Stroke Cerebrovasc Dis* 2016;25:1797–9.
- De Castillo LLC, Diestro JDB, Tuazon CAM, Sy MCC, Añonuevo JC, San Jose MCZ. Cardiocerebral infarction: a single institutional series. *J Stroke Cerebrovasc Dis* 2021;30:105831.
- Artus A, Didier R, Blain M, Comby P, Leclercq T, Debeaumarché H, et al. Detection of myocardial infarction by cardiac magnetic resonance in embolic stroke related to first diagnosed atrial fibrillation. *J Stroke Cerebrovasc Dis* 2021;30:105753.
- Jensen JK, Bak S, Flemming Høilund-Carlsen P, Mickley H. Prevalence of electrocardiographic st-t changes during acute ischemic stroke in patients without known ischemic heart disease. *Int. J. Cardiol.* 2008;128:137–8.
- Kerr G, Ray G, Wu O, Stott DJ, Langhorne P. Elevated troponin after stroke: a systematic review. *Cerebrovasc. Dis.* 2009;28:220–6.
- Yaghi S, Chang AD, Ricci BA, Jayaraman MV, McTaggart RA, Hemendinger M, et al. Early elevated troponin levels after ischemic stroke suggests a cardioembolic source. *Stroke* 2018;49:121–6.
- Barber M, Barlow N, Macfarlane PW, Barlow N, Roditi G, Stott DJ. Elevated troponin levels are associated with sympathoadrenal activation in acute ischaemic stroke. *Cerebrovasc. Dis.* 2007;23:260–6.
- Hartikainen TS, Sörensen NA, Haller PM, Goßling A, Lehmacher J, Zeller T, et al. Clinical application of the 4th universal definition of myocardial infarction. *Eur. Heart J.* 2020;41:2209–16.
- Manzano M, Vilacosta I, Román JAS, Aragoncillo P, Sarriá C, López D, et al. Acute coronary syndrome in infective endocarditis. *Rev. Esp. Cardiol.* 2007;60:24–31.
- Faluk MA, Vuu S, Kathi K, Abdelmaseih R, Cignoni C, Tarasiuk-Rusek A, et al. Challenges in managing acute myocardial infarction associated with infective endocarditis: a case report. *J Investig Med High Impact Case Rep* 2020;8:2324709620960001.
- Habib G, Lancellotti P, Antunes MJ, Bongiorno MG, Casalta J-P, Del Zotti F, et al. 2015 ESC guidelines for the management of infective endocarditis: the task force for the management of infective endocarditis of the European Society of Cardiology (ESC). endorsed by: European Association for Cardio-Thoracic Surgery (EACTS), the European association of nuclear medicine (EANM). *Eur. Heart J.* 2015;36:3075–128.
- Laperche C, Lairez O, Ferrieres J, Robin G, Gautier M, Badie YL, et al. Coronary angiography in the setting of acute infective endocarditis requiring surgical treatment. *Arch Cardiovasc Dis* 2020;113:50–8.
- Shamsham F, Safi AM, Pomerenko I, Salciccioli L, Feit A, Clark LT, et al. Fatal left main coronary artery embolism from aortic valve endocarditis following cardiac catheterization. *Catheter. Cardiovasc. Interv.* 2000;50:74–7.
- Otti CM, Nishimura RA, Bonow RO, Carabello BA, Erwin JP 3rd, Gentile F, et al. 2020 ACC/AHA guideline for the management of patients with valv-

- lar heart disease: a report of the American college of Cardiology/American Heart Association Joint Committee on clinical practice guidelines. *Circulation* 2021;143:e72–e227.
- [48] Colombo GM, Albi F, Salvini P, Sacco T, Cicchinelli M. Ischemic stroke with cardiac involvement in aortic thromboembolism. *Minerva Cardioangiol.* 2006;54:779–81.
- [49] Rawashdeh SI, Al-Mistarehi AH, Yassin A, Rabab'ah W, Skaff H, Ibdah R. A concurrent ischemic stroke, myocardial infarction, and aortic thrombi in a young patient with hyperhomocysteinemia: a case report. *Int Med Case Rep J* 2020;13:581–90.
- [50] Otti CM, Nishimura RA, Bonow RO, Carabello BA, Erwin JP 3rd, Gentile F, et al. 2020 ACC/AHA guideline for the management of patients with valvular heart disease: a report of the American college of cardiology/American Heart Association Joint Committee on clinical practice guidelines. *Circulation* 2021;143:e72–e227.
- [51] Niccoli G, Scalone G, Crea F. Acute myocardial infarction with no obstructive coronary atherosclerosis: mechanisms and management. *Eur. Heart J.* 2015;36:475–81.
- [52] Aoun J, Assaker JP, Faza N, Kleiman NS, Zacca N, Little SH, et al. Mechanical prosthetic aortic valve thrombosis complicated by an acute coronary syndrome during fibrinolysis. *JACC Case Rep* 2020;2:2186–90.