



HAL
open science

Post Traumatic Membranous Cystic Lipodystrophy: A Case Report and Review of Literature

Achraf Saoudi, Rafed Laouiti, Alia Zehani, Mohamed Ali, Riadh Maala

► **To cite this version:**

Achraf Saoudi, Rafed Laouiti, Alia Zehani, Mohamed Ali, Riadh Maala. Post Traumatic Membranous Cystic Lipodystrophy: A Case Report and Review of Literature. Asian Journal of Research in Surgery, 2024, 7 (2), pp.154-159. hal-04620155

HAL Id: hal-04620155

<https://hal.science/hal-04620155>

Submitted on 24 Jun 2024

HAL is a multi-disciplinary open access archive for the deposit and dissemination of scientific research documents, whether they are published or not. The documents may come from teaching and research institutions in France or abroad, or from public or private research centers.

L'archive ouverte pluridisciplinaire **HAL**, est destinée au dépôt et à la diffusion de documents scientifiques de niveau recherche, publiés ou non, émanant des établissements d'enseignement et de recherche français ou étrangers, des laboratoires publics ou privés.

Copyright



Post Traumatic Membranous Cystic Lipodystrophy: A Case Report and Review of Literature

A. Saoudi ^{a*}, R. Laouiti ^a, A. Zehani ^b, MA. Sbai ^c
and R. Maala ^a

^a Plastic, Reconstructive and Aesthetic Surgery Department, University Hospital La Rabta, Tunis, Tunisia.

^b Anatomical Pathology Department, University Hospital La Rabta, Tunis, Tunisia.

^c Department of Orthopedics and Traumatology, Mohamed Taieb Maamouri University Hospital, Nabeul, Tunisia.

Authors' contributions

This work was carried out in collaboration among all authors. All authors read and approved the final manuscript.

Article Information

Open Peer Review History:

This journal follows the Advanced Open Peer Review policy. Identity of the Reviewers, Editor(s) and additional Reviewers, peer review comments, different versions of the manuscript, comments of the editors, etc are available here: <https://www.sdiarticle5.com/review-history/117670>

Case Report

Received: 06/04/2024

Accepted: 10/06/2024

Published: 19/06/2024

ABSTRACT

Membranous Cystic Lipodystrophy (MCL) is a rare form of panniculitis diagnosed histologically by the presence of cystic cavities bordered by eosinophilic crenated hyaline membranes, which stain positively with Periodic Acid-Schiff (PAS).

It was first described as a morphological characteristic of Nasu-Hakola disease (NHD). Subsequently, this panniculitis has been reported in several other clinical circumstances, predominantly associated with vascular disorders.

We present a rare case of post-traumatic membranous cystic lipodystrophy.

*Corresponding author: E-mail: achrafsaoudi97@gmail.com;

Cite as: Saoudi, A., R. Laouiti, A. Zehani, MA. Sbai, and R. Maala. 2024. "Post Traumatic Membranous Cystic Lipodystrophy: A Case Report and Review of Literature". *Asian Journal of Research in Surgery* 7 (2):154-59. <https://journalajrs.com/index.php/AJRS/article/view/206>.

Keywords: Membranous cystic lipodystrophy; panniculitis; adipocyte; necrosis; traumatic.

1. INTRODUCTION

Membranous cystic lipodystrophy (MCL) is a rare form of panniculitis diagnosed histologically by the presence of an eosinophilic and hyaline crenulated membrane formations that stain positively with Periodic Acid-Schiff (PAS) [1,2].

It was first described in Nasu-Hakola disease (NHD), which combines dementia, sclerosing leukoencephalopathy, and polycystic bone lesions [3].

Subsequently, membranous cystic lipodystrophy has been reported in various other conditions, including vascular disorders, autoimmune diseases, and, more rarely, post-traumatic cases [4].

2. CASE PRESENTATION

We report the case of a 19-year-old female patient, born from a non-consanguineous marriage, with no prior medical history, who presented with a slightly painful swelling on the posterior aspect of her right thigh, which had been gradually increasing in size.

Upon questioning, she revealed a history of trauma (a fall down the stairs) that occurred one year before consultation. Additionally, the patient reported no other associated functional signs.

Clinical examination revealed a firm, adherent swelling measuring 6 centimeters. The overlying skin exhibited mild induration and tenderness.

An ultrasound examination was performed, suggesting an atypical lipomatous tumor. Intraoperative findings revealed an adherent, non-encapsulated tumor, from which a whitish fluid was expressed. (Fig. 1)

Histopathological examination confirmed the diagnosis of membranous cystic lipodystrophy. (Fig. 2).

3. DISCUSSION

MCL is a rare form of fat necrosis characterized microscopically by the presence of cystic cavities of fat necrosis lined by an eosinophilic and crenulated hyaline membrane formations that stain positively with Periodic Acid-Schiff (PAS) [1,2].

It was first described in 1973 as a morphological characteristic of NHD. It combines a sclerosing leukoencephalopathy with membranocystic degeneration of bones and fat tissue [3].

It is a rare hereditary condition with autosomal recessive transmission, caused by a mutation in the *TYROBP* or *TREM2* genes. These genes are involved in the regulation of immune responses, the differentiation of dendritic cells and osteoclasts, and the phagocytic activity of microglia [3–5].

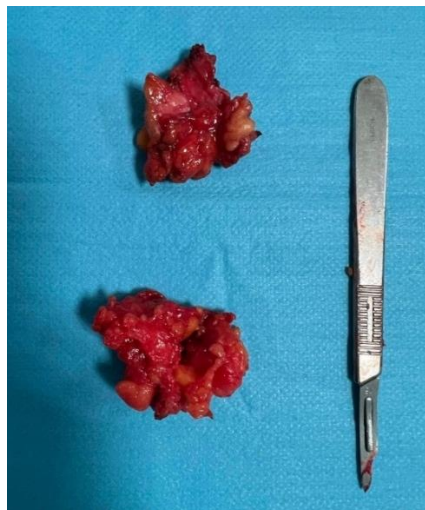

Fig. 1. Resected Specimen

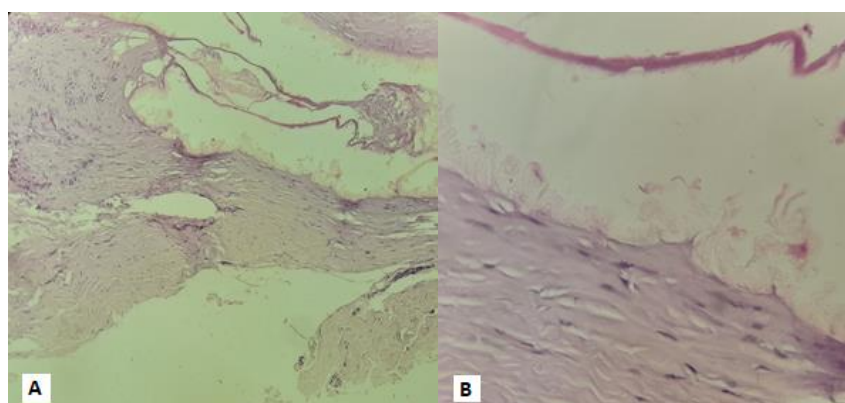


Fig. 2. Hematoxylin and Eosin (H&E) stain. A. (x 10): Fibrous tissue with cystic cavities bordered by hyaline membranes. B (x40) 40: Acellular eosinophilic membranes with crenated appearance lining the cystic cavities

It typically begins manifesting during adolescence with pain or recurrent bone fractures in the distal extremities, skin indurations, and later a presentation of presenile dementia. Four clinical stages have been proposed for NHD: latent, osseous, early neuropsychiatric and late neuropsychiatric. However, Paloneva et al.'s findings show that these stages are not successive, and consequently, some patients may present with neuropsychiatric signs without any preceding osseous symptoms [5].

Subsequently, this alteration of adipose tissue has been reported in various local or systemic

conditions [4]. Furthermore, very few cases of post-traumatic MCL have been reported [2,4,6,7]. Table 1 summarizes the different conditions associated with MCL reported in the literature.

The mechanisms that cause pseudomembrane formation remain unknown.

Machinami, based on ultrastructural and cytochemical studies of MCL, believes that the pseudomembranous aspect is the result of the deposit of degenerated cell membranes from macrophages and necrotic adipocytes [8–10].

Table 1. Different conditions associated with MCL

Condition	Source
Vascular	
Venous insufficiency	[4,9,10,12,13]
Arteriosclerosis	[13]
Thromboangiitis obliterans	[13]
Thrombophlebitis	[4,12,14]
Diabetes	[4,11,12,14]
Autoimmune	
Lupus	[4,9,12,15]
Scleroderma / Morphea	[4,16,17]
Dermatomyositis	[18]
Vasculitis	[4,12,17]
Behçet disease	[4,10]
Rheumatoid arthritis	[19]
Infectious	
Tuberculosis	[4,8,9,20]
Erysipelas	[4,9,17]
Neoplastic	
T-cell lymphoma	[4,8]
Drug-induced	
Chemotherapy	[2,4]
Post traumatic	[2,4,6,7]

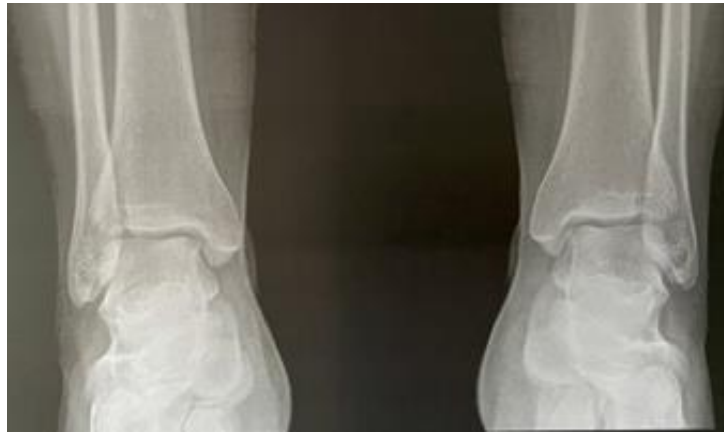

Fig. 3. Absence of polycystic lesions in X-Ray

This is suggested by the observation of free fat droplets released from disrupted fat cells, processed by macrophages in connection with a histiocytic infiltrate [8–11].

Other possible pathogenic mechanisms include inappropriate phagocytosis, a disproportioned proliferation of fat cell membranes, fibrinogen deposition, lipid metabolism disorders, interactions between connective tissue and free fat droplets, etc. [8,11].

The mechanisms underlying adipocyte alteration and subsequently pseudomembrane formation are also unclear.

Based on histologic examination, Alegre et al. suggest that MCL can occur as a nonspecific result of a compromise in the blood supply [12].

This hypothesis, supporting adipose tissue ischemia, is also endorsed by Machinami and Sueki et al. [10,13].

The role of ischemic injury has also been suggested in infectious, autoimmune, and traumatic conditions [8].

In our case, Nasu-Hakola syndrome was ruled out after a normal neurological and radiological examination (Fig. 3). Other vascular, autoimmune, and infectious causes were also excluded based on normal clinical and immunological assessments [21-23].

Therefore, we conclude a post-traumatic origin for MCL. We consider that the fall down the stairs likely caused a vascular disturbance leading to ischemic injury to the fat tissue, which caused, at

the cellular level, an alteration of the adipocyte membrane and metabolism and an interaction between its contents and surrounding tissues, resulting in phagocytosis and pseudomembrane formation.

4. CONCLUSION

Membranous cystic lipodystrophy is a rare and nonspecific form of panniculitis that can occur in various clinical conditions, rarely in post-traumatic cases. Its diagnosis relies on histology. Physiopathology remains poorly understood. Ischemic origin is the most widely supported hypothesis.

DISCLAIMER (ARTIFICIAL INTELLIGENCE)

Author(s) hereby declare that NO generative AI technologies such as Large Language Models (ChatGPT, COPILOT, etc) and text-to-image generators have been used during writing or editing of manuscripts.

CONSENT

As per international standards or university standards, patient(s) written consent has been collected and preserved by the author(s).

ETHICAL APPROVAL

As per international standards or university standards written ethical approval has been collected and preserved by the author(s).

COMPETING INTERESTS

Authors have declared that no competing interests exist.

REFERENCES

1. Elder DE, Elenitsas R, Murphy GF, Rosenbach M, Rubin AI, Seykora JT, et al. *Lever's Dermatopathology: Histopathology of the Skin*. Lippincott Williams & Wilkins; 2022.
2. Agharbi F. La lipodystrophie membranokystique: A propos d'un cas. *PAMJ-CM* [Internet]. 2020 [cited 2024 Mar 16];2. Available:<https://www.clinical-medicine.panafrican-med-journal.com/content/article/2/134/full/>
3. Kaneko M, Sano K, Nakayama J, Amano N. Nasu-Hakola disease: The first case reported by Nasu and review: The 50th Anniversary of Japanese Society of Neuropathology. *Neuropathology*. 2010;30:463–70.
4. Matsukuma S, Matsunaga A, Takahashi O, Ogata S. Lipomembranous fat necrosis: A distinctive and unique morphology (Review). *Exp Ther Med*. 2022;24:759.
5. Samanci B, Bilgiç B, Gelişin Ö, Tepgeç F, Guven G, Tüfekçioğlu Z, et al. *TREM2* variants as a possible cause of frontotemporal dementia with distinct neuroimaging features. *Euro J of Neurology*. 2021;28:2603–13.
6. Moreno A, Marcoval J, Peyri J. Traumatic Panniculitis. *Dermatologic Clinics*. 2008;26:481–3.
7. Lee JW, Bak H, Park IH, Choi EH, Ahn SK. Membranous Lipodystrophy-Like Changes in Two Cases of Traumatic Lipogranuloma Caused by Safety Belts. *The Journal of Dermatology*. 2005;32:38–42.
8. Segura S, Pujol RM. Lipomembranous Fat Necrosis of the Subcutaneous Tissue. *Dermatologic Clinics*. 2008;26:509–17.
9. Diaz-Cascajo C, Borghi S. Subcutaneous pseudomembranous fat necrosis: New observations/linkr>. *J Cutan Pathol*. 2002;29:5–10.
10. Machinami R. Degenerative change of adipose tissue; the so-called membranous lipodystrophy. *Vichows Archiv A Pathol Anat*. 1990;416:373–4.
11. Sueki H, Shinmura Y, Fujisawa R, Jitsukawa K, Sato S. Ultrastructural study of the histogenesis of membranocystic lesions (Nasu) in diabetics. *J Cutan Pathol*. 1986;13:390–401.
12. Alegre VA, Winkelmann RK, Aliaga A. Lipomembranous changes in chronic panniculitis. *Journal of the American Academy of Dermatology*. 1988;19:39–46.
13. Machinami R. Incidence of membranous lipodystrophy-like change among patients with limb necrosis caused by chronic arterial obstruction. *Arch Pathol Lab Med*. 1984;108:823–6.
14. Ahn S, Yoo M, Lee S, Choi E. A clinical and histopathological study of 22 patients with membranous lipodystrophy. *Clinical and Experimental Dermatology*. 1996;21:269–72.
15. Suda T, Hara H, Okada T, Suzuki H. Coexistence of extensive calcification and membrano-cystic changes in lupus erythematosus panniculitis associated with systemic lupus erythematosus. *Eur J Dermatol*. 2007;17:86–8.
16. Chun SI, Chung K-Y. Membranous lipodystrophy: Secondary type. *Journal of the American Academy of Dermatology*. 1994;31:601–5.
17. Snow JL, Su WPD, Gibson LE. Lipomembranous (membranocystic) changes associated with morphea: A clinicopathologic review of three cases. *Journal of the American Academy of Dermatology*. 1994;31:246–50.
18. Ishikawa O, Tamura A, Ryuzaki K, Kurosawa M, Miyachi Y. Membranocystic changes in the panniculitis of dermatomyositis. *Br J Dermatol*. 1996;134:773–6.
19. Asadi-Kani Z, Moravvej H, Gaisari M, Kavand S, Saeedi M. A Case of Lipomembranous Panniculitis Associated with Rheumatoid Arthritis. 2009;12.
20. Yeh LJ, Shively NR, Isacke RN, Dowling CA, Stogsdill PB. Miliary tuberculosis characterised by lipomembranous fat necrosis. *The Lancet Infectious Diseases*. 2015;15:1497.
21. Boughdir M, Nechi S, Bellila S, Maamatou W, Jarray L, Hellal Y, Sebai MA. The Mangement of Splenic Cysts in Children. *Journal of Advances in Medicine and Medical Research*. 2021;33(18):188–195. Available:<https://doi.org/10.9734/jammr/2021/v33i1831070>
22. Elbakouri A, Bachar A, Elazhary A, Elhattabi K, Bensardi F, Fadil A. Unusual cause of colonic occlusion: Large, twisted ovarian cyst compressing the

sigmoid colon. Asian Journal of Case Reports in Surgery. 2020;3(1):76–79.
Available: <https://journalajcrs.com/index.php/AJCRS/article/view/42>

23. Chun SI, Chung KY. Membranous lipodystrophy: Secondary type. Journal of the American Academy of Dermatology. 1994 Oct 1;31(4):601-5.

© Copyright (2024): Author(s). The licensee is the journal publisher. This is an Open Access article distributed under the terms of the Creative Commons Attribution License (<http://creativecommons.org/licenses/by/4.0>), which permits unrestricted use, distribution, and reproduction in any medium, provided the original work is properly cited.

Peer-review history:

The peer review history for this paper can be accessed here:

<https://www.sdiarticle5.com/review-history/117670>