



**HAL**  
open science

## **Meningioma: International Consortium on Meningiomas (ICOM) consensus review on scientific advances & treatment paradigms for clinicians, researchers, and patients**

Justin Wang, Alexander Landry, David Raleigh, Felix Sahm, Kyle Walsh, Roland Goldbrunner, Leeor Yefet, Jörg Tonn, Chloe Gui, Quinn Ostrom, et al.

### **► To cite this version:**

Justin Wang, Alexander Landry, David Raleigh, Felix Sahm, Kyle Walsh, et al.. Meningioma: International Consortium on Meningiomas (ICOM) consensus review on scientific advances & treatment paradigms for clinicians, researchers, and patients. *Neuro-Oncology*, In press, 10.1093/neuonc/noae082 . hal-04615777

**HAL Id: hal-04615777**

**<https://hal.science/hal-04615777>**

Submitted on 3 Jul 2024

**HAL** is a multi-disciplinary open access archive for the deposit and dissemination of scientific research documents, whether they are published or not. The documents may come from teaching and research institutions in France or abroad, or from public or private research centers.

L'archive ouverte pluridisciplinaire **HAL**, est destinée au dépôt et à la diffusion de documents scientifiques de niveau recherche, publiés ou non, émanant des établissements d'enseignement et de recherche français ou étrangers, des laboratoires publics ou privés.

## **Meningioma: International Consortium on Meningiomas (ICOM) consensus review on scientific advances & treatment paradigms for clinicians, researchers, and patients**

Justin Z. Wang MD<sup>1,2,3\*</sup>, Alexander P. Landry MD<sup>1,2,3\*</sup>, David R. Raleigh MD PhD<sup>4</sup>, Felix Sahm MD PhD<sup>5</sup>, Kyle M. Walsh PhD<sup>6</sup>, Roland Goldbrunner MD PhD<sup>7</sup>, Leeor S. Yefet MD<sup>2</sup>, Jörg C. Tonn MD<sup>8</sup>, Chloe Gui MD<sup>1,2,3</sup>, Quinn T. Ostrom PhD<sup>6,9,10</sup>, Jill Barnholtz-Sloan PhD<sup>9,11,12</sup>, Arie Perry MD<sup>13</sup>, Yosef Ellenbogen MD<sup>1,2,3</sup>, C Oliver Hanemann MD PhD<sup>14</sup>, Gerhard Jungwirth MD PhD<sup>15</sup>, Michael D Jenkinson MB ChB, PhD<sup>16,17</sup>, Ghazaleh Tabatabai MD PhD<sup>18,19,20</sup>, Tiit I. Mathiesen MD<sup>21</sup>, Michael W. McDermott MD<sup>22</sup>, Marcos Tatagiba MD PhD<sup>18,23</sup>, Christian la Fougère MD<sup>19,24</sup>, Sybren L. N. Maas MD PhD<sup>25,26</sup>, Norbert Galldiks MD<sup>27</sup>, Nathalie L. Albert MD<sup>28</sup>, Priscilla K. Brastianos MD<sup>29</sup>, Felix Ehret MD<sup>30</sup>, Giuseppe Minniti MD PhD<sup>31</sup>, Katrin Lamszus MD<sup>32</sup>, Franz L. Ricks MD<sup>33</sup>, Jens Schittenhelm MD<sup>18,34</sup>, Katharine J. Drummond MD<sup>35</sup>, Ian F. Dunn MD<sup>36</sup>, Omar N. Pathmanaban MB ChB, PhD<sup>37</sup>, Aaron Cohen-Gadol MD<sup>38</sup>, Erik P. Sulman MD PhD<sup>39</sup>, Emeline Tabouret MD PhD<sup>40</sup>, Emelie Le Rhun MD PhD<sup>41</sup>, Christian Mawrin MD PhD<sup>42</sup>, Jennifer Moliterno MD<sup>43</sup>, Michael Weller MD<sup>44</sup>, Wenya (Linda) Bi MD PhD<sup>45</sup>, Andrew Gao MD MSc<sup>46</sup>, Stephen Yip MD PhD<sup>47</sup>, Maximilian Niyazi MD MSc<sup>18,48</sup>, The International Consortium on Meningiomas (ICOM), Kenneth Aldape MD<sup>49</sup>, Patrick Y. Wen MD<sup>50</sup>, Susan Short MBBS PhD<sup>51†</sup>, Matthias Preusser MD<sup>52†</sup>, Farshad Nassiri MD PhD<sup>1,2,3†</sup>, Gelareh Zadeh MD PhD<sup>1,2,3†</sup>

<sup>1</sup> MacFeeters Hamilton Neuro-Oncology Program, Princess Margaret Cancer Centre, University Health Network and University of Toronto, Toronto, ON, Canada

<sup>2</sup> Division of Neurosurgery, Department of Surgery, University of Toronto, Toronto, ON, Canada

<sup>3</sup> Princess Margaret Cancer Centre, University Health Network, Toronto, ON, Canada

<sup>4</sup> Department of Radiation Oncology, Neurological Surgery, and Pathology, University of California San Francisco, San Francisco, CA, USA

<sup>5</sup> Department of Neuropathology, University Hospital Heidelberg and German Consortium for Translational Cancer Research (DKTK), German Cancer Research Center (DKFZ), Heidelberg, Germany

<sup>6</sup> Department of Neurosurgery, Duke University, Durham, NC, USA

<sup>7</sup> Center of Neurosurgery, Department of General Neurosurgery, University of Cologne, Cologne, Germany

<sup>8</sup> Department of Neurosurgery, University Hospital Munich LMU, Munich, Germany

<sup>9</sup> Central Brain Tumor Registry of the United States, Hinsdale, IL, USA

<sup>10</sup> Duke Cancer Institute, Duke University School of Medicine, Durham, NC, USA

<sup>11</sup> Trans Divisional Research Program (TDRP), Division of Cancer Epidemiology and Genetics (DCEG), National Cancer Institute, Bethesda, MD, USA

© The Author(s) 2024. Published by Oxford University Press on behalf of the Society for Neuro-Oncology.

This is an Open Access article distributed under the terms of the Creative Commons Attribution License (<https://creativecommons.org/licenses/by/4.0/>), which permits unrestricted reuse, distribution, and reproduction in any medium, provided the original work is properly cited.

- <sup>12</sup> Center for Biomedical Informatics & Information Technology (CBIIT), National Cancer Institute, Bethesda, MD, USA
- <sup>13</sup> Department of Pathology, University of California San Francisco, San Francisco, California, USA
- <sup>14</sup> Peninsula Schools of Medicine, University of Plymouth University, Plymouth, UK
- <sup>15</sup> Division of Experimental Neurosurgery, Department of Neurosurgery, Heidelberg University, Heidelberg, Germany
- <sup>16</sup> Institute of Translational Medicine, University of Liverpool, UK
- <sup>17</sup> The Walton Centre NHS Foundation Trust, Liverpool, UK
- <sup>18</sup> Center for Neuro-Oncology, Comprehensive Cancer Center Tübingen-Stuttgart, University Hospital Tübingen, Tübingen, Germany
- <sup>19</sup> Cluster of Excellence (EXC 2180) "Image Guided and Functionally Instructed Tumor Therapies", Eberhard Karls University Tübingen, Tübingen, Germany
- <sup>20</sup> Department of Neurology and Interdisciplinary Neuro-Oncology, University Hospital Tübingen, Hertie Institute for Clinical Brain Research, Eberhard Karls University Tübingen, Tübingen, Germany
- <sup>21</sup> Department of Clinical Medicine, University of Copenhagen, Copenhagen, Denmark; Department of Clinical Neuroscience, Karolinska Institute, Stockholm, Sweden
- <sup>22</sup> Miami Neuroscience Institute, Baptist Health of South Florida, Miami, FL, United States; Division of Neuroscience, Herbert Wertheim College of Medicine, Florida International University, Miami, FL, USA
- <sup>23</sup> Department of Neurosurgery, University of Tübingen, Tübingen, Germany
- <sup>24</sup> Nuclear Medicine and Clinical Molecular Imaging, University Hospital Tübingen, Germany
- <sup>25</sup> Department of Pathology, Leiden University Medical Center, Leiden, The Netherlands
- <sup>26</sup> Department of Pathology, Erasmus Medical Center, Rotterdam, The Netherlands
- <sup>27</sup> Department of Neurology, Faculty of Medicine and University Hospital Cologne, University of Cologne, Cologne, Germany and Institute of Neuroscience and Medicine (IMN-3), Research Center Juelich, Juelich, Germany
- <sup>28</sup> Department of Nuclear Medicine, Ludwig Maximilians-University of Munich, Munich, Germany
- <sup>29</sup> Massachusetts General Hospital Cancer Center, Harvard Medical School, Boston, MA, USA
- <sup>30</sup> Berlin Institute of Health, Charité - Universitätsmedizin Berlin, Berlin, Germany; Department of Radiation Oncology, Charité - Universitätsmedizin Berlin, Corporate Member of Freie Universität Berlin and Humboldt-Universität zu Berlin, Berlin, Germany
- <sup>31</sup> Department of Radiological Sciences, Oncology and Anatomical Pathology, Sapienza University of Rome, Rome; IRCCS Neuromed (IS), Italy

- <sup>32</sup> Laboratory for Brain Tumor Biology, University Hospital Eppendorf, Martinistrasse 52, 20246 Hamburg, Germany
- <sup>33</sup> Department of Neurosurgery, University Medical Center Hamburg-Eppendorf, 20251 Hamburg, Germany
- <sup>34</sup> Department of Neuropathology, University Hospital Tübingen, Eberhard-Karls-University Tübingen, 72076 Tübingen, Germany
- <sup>35</sup> Department of Neurosurgery, The Royal Melbourne Hospital, Melbourne, Victoria, Australia
- <sup>36</sup> Department of Neurosurgery, University of Oklahoma Health Sciences Center, Oklahoma City, OK, USA
- <sup>37</sup> Manchester Centre for Clinical Neurosciences, Geoffrey Jefferson Brain Research Centre, Division of Neuroscience and Experimental Psychology, University of Manchester, Manchester, UK.
- <sup>38</sup> Department of Neurological Surgery, Indiana University, Indianapolis, IN, USA
- <sup>39</sup> Department of Radiation Oncology, NYU Grossman School of Medicine, New York, NY, USA
- <sup>40</sup> Aix-Marseille University, CNRS, INP, Inst Neurophysiopathol, Marseille, France
- <sup>40</sup> Department of Neurology & Brain Tumor Center, University Hospital and University of Zurich, Zurich, Switzerland
- <sup>41</sup> Department of Neuropathology, University Hospital Magdeburg, Magdeburg, Germany
- <sup>42</sup> Department of Neurosurgery, Yale School of Medicine, New Haven, CT, USA
- <sup>43</sup> Department of Neurology & Brain Tumor Center, University Hospital and University of Zurich, Zurich, Switzerland
- <sup>44</sup> Department of Neurosurgery, Brigham and Women's Hospital, Dana-Farber Cancer Institute, Harvard Medical School, Boston, MA, USA
- <sup>45</sup> Department of Laboratory Medicine and Pathobiology, University Health Network, Toronto, ON, Canada
- <sup>46</sup> Department of Pathology & Laboratory Medicine, University of British Columbia, Vancouver, BC, Canada
- <sup>47</sup> Department of Radiation Oncology, University Hospital, LMU Munich, Munich, Germany; German Cancer Consortium (DKTK), partner site Munich, Munich, Germany; Bavarian Cancer Research Center (BZKF), Munich, Germany
- <sup>48</sup> Center for Cancer Research, National Cancer Institute, Bethesda, MD, USA
- <sup>49</sup> Dana-Farber Cancer Institute, Brigham and Women's Hospital and Harvard Medical School, Boston, Massachusetts, USA
- <sup>50</sup> Leeds Institute of Medical Research, St James's University Hospital, Leeds, UK
- <sup>51</sup> Department of Medicine I, Division of Oncology, Medical University of Vienna, Vienna, Austria

\* Equal contribution authors

† Co-corresponding authors

**Correspondence can be directed to:**

Gelareh Zadeh, MD, PhD

Division of Neurosurgery, University of Toronto

MacFeeters Hamilton Neuro-Oncology Program, Princess Margaret Cancer Centre, University Health Network

Toronto, Ontario, Canada

Phone: (416) 634-8728

E-mail: [gelareh.zadeh@uhn.ca](mailto:gelareh.zadeh@uhn.ca)

Farshad Nassiri, MD, PhD

Division of Neurosurgery, University of Toronto

MacFeeters Hamilton Neuro-Oncology Program, Princess Margaret Cancer Centre, University Health Network

Toronto, Ontario, Canada

Phone: (647) 204-9729

E-mail: [farshad.nassiri@mail.utoronto.ca](mailto:farshad.nassiri@mail.utoronto.ca)

Matthias Preusser MD

Department of Medicine I, Division of Oncology, Medical University of Vienna,

Vienna, Austria

Phone: 43 1 40400 44450

E-mail: [matthias.preusser@meduniwien.ac.at](mailto:matthias.preusser@meduniwien.ac.at)

ORCID: 0000-0003-3541-2315

Susan Short MBBS, PhD

Leeds Institute of Cancer and Pathology, St James's University Hospital,

Leeds, United Kingdom

Phone: 44(0)113 343 8434

E-mail: S.C.Short@leeds.ac.uk

Accepted Manuscript

## Abstract

Meningiomas are the most common primary intracranial tumors in adults and are increasing in incidence due to the aging population and the rising availability of neuroimaging. While most exhibit non-malignant behaviour, a subset of meningiomas are biologically aggressive and lead to significant neurological morbidity and mortality. In recent years, meaningful advances in our understanding of the biology of these tumors have led to the incorporation of molecular biomarkers into their grading and prognostication. However, unlike other central nervous system tumors, a unified molecular taxonomy for meningiomas has not yet been established and remains an overarching goal of the Consortium to Inform Molecular and Practical Approaches to CNS Tumor Taxonomy-Not Official WHO (cIMPACT-NOW) working group. There also remains clinical equipoise on how specific meningioma cases and patient populations should be optimally managed. To address these existing gaps, members of the International Consortium on Meningiomas (ICOM) including field-leading experts, have prepared a comprehensive consensus narrative review directed towards clinicians, researchers, and patients. Included in this manuscript are detailed overviews of proposed molecular classifications, novel biomarkers, contemporary treatment strategies, trials on systemic therapies, health-related quality of life studies, and management strategies for unique meningioma patient populations. In each section we discuss the current state of knowledge as well as ongoing clinical and research challenges to road map future directions for further investigation.

## Introduction

Meningioma is the most common primary intracranial tumor in adults. Historically, investigation into its molecular biology and pathogenesis has trailed other central nervous system (CNS) tumors. Since 2016, through the efforts of independent research groups and consortia including but not limited to the International Consortium on Meningiomas (ICOM) and the German Consortium on Aggressive Meningiomas (KAM), there has been a surge in molecular studies on meningiomas that have uncovered novel diagnostic and prognostic alterations. Despite these advances, meningioma treatments remain largely limited to surgery and radiotherapy (RT). Systemic medical therapies are largely reserved for otherwise treatment-refractory meningiomas in the context of clinical trials. There is a pressing need to translate findings from the current molecular era of meningioma research into meaningful improvements in decision making and novel therapies. In this comprehensive narrative review, key advances in the understanding of meningioma biology will be discussed, with a focus on recent breakthroughs. Each section will also discuss ongoing controversies, critical knowledge gaps and areas of unmet need for clinicians, researchers, and patients that could be targeted for future research and investigation.

## Epidemiology and Risk Factors

Meningiomas make up 40.8% of all primary brain tumors in the United States (U.S.) and 56.2% of “non-malignant” primary brain tumors (**Figure 1A, B**).<sup>1</sup> Incidence rates of non-malignant meningioma are the highest amongst all CNS tumors at 9.73 per 100 000 population in the US. These rates increase after age 65 and again after age 85. Age-adjusted incidence rates of non-malignant meningiomas continue to increase across different sexes, ethnicities, and races (**Figure 1C**). Meningiomas also account



for the largest proportion of intradural spinal tumors in patients 20 years of age and older (39.9%), although spinal meningiomas represent only 4.2% of all diagnosed meningiomas.<sup>1</sup>

By World Health Organization (WHO) 2021 grading, 80.1% of reported meningiomas are CNS WHO grade 1, 18.3% are grade 2, and 1.5% are grade 3.<sup>1,2</sup> “Non-malignant” meningiomas (represented in the SEER database in the following proportions: 81.4% CNS WHO grade 1 and 18.4% CNS WHO grade 2) are 2.3 times more commonly diagnosed in females than in males, and this disparity is the largest between the ages of 35-44 (**Figure 1D, E**). Ten-year relative survival for non-malignant meningioma is 83.4%. Although the SEER database quotes a ten-year survival rate of 60% for “malignant” meningiomas, this group is not exclusively comprised of CNS WHO grade 3 cases (63.6%) but also includes a sizeable proportion of CNS WHO grade 1 (20.4%) and grade 2 (15%) cases. Notably, the designation of a “malignant” meningioma in this context is imprecisely defined and based on ICD coding instead of central neuropathological review. Non-registry data of exclusively CNS WHO grade 3 malignant or anaplastic meningiomas show far more dismal outcomes with a 5-year overall survival of 66% in one cohort and an estimated 10-year overall survival of 14-24%.<sup>1,3-5</sup>

The incidence of intracranial meningiomas is higher in Black patients compared to White patients and this disparity increases with higher tumor grade (**Figure 1F, G**).<sup>3,6</sup> In turn, the incidence of “non-malignant” meningiomas is higher in white patients compared to Asian-Pacific Islanders (API), although there may be a higher incidence of “malignant meningiomas” in the latter group (**Figure 1F**). The reasons behind these racial and ethnic differences remain unknown and the limitations of reporting based on population-based epidemiological data need to be considered, particularly for comparisons between different countries and/or continents.

Heritable genetic polymorphisms in *MLLT10* (MLLT10 histone lysine methyltransferase DOT1L cofactor) have also been robustly associated with increased meningioma risk.<sup>7,8</sup> Distinct from germline

variants that cause hereditary syndromes associated with meningiomas, *MLLT10* risk alleles are common at the population level and confer a comparatively modest increase in meningioma risk. These variants also increase risk for ovarian cancer and estrogen receptor-positive breast cancer, and pan-cancer analyses implicate a potential estrogenic mechanism connecting *MLLT10* variation to risk of diverse tumor types.<sup>9</sup> Despite progress in identifying exogenous and endogenous factors conferring meningioma risk, relatively few modifiable risk factors have been definitively identified. These include ionizing radiation, elevated body mass index, methotrexate treatment, and cigarette smoking (where increased risk is restricted to men).<sup>10-21</sup> The most well validated of these risk factors is cranial irradiation, with a linear dose-response association between the radiation dose received and the risk of subsequent meningioma development, particularly in those who were treated under the age of 10 (to be discussed in the ***Radiation-Induced Meningiomas*** section).<sup>19,20</sup> Despite the fact that meningiomas are known to commonly express progesterone receptors, estrogen receptor expression is rare and there are conflicting results on the risk of meningioma growth or development in response to endogenous and exogenous sex hormones.<sup>22-28</sup> Several large retrospective studies have demonstrated a positive association between current or past use of hormone replacement therapy and the diagnosis of a meningioma.<sup>21,29</sup> On a population-level, pregnancy does not appear to be a risk factor for meningioma development, although accelerated growth of an existing meningioma during pregnancy has long been described.<sup>30-32</sup> While multiple risk factors for meningioma have been identified as delineated above, there is currently insufficient evidence to support a standardized screening approach such as germline genetic testing or routine neuroimaging, even in higher risk cohorts such as female relatives of meningioma patients with the *MLLT10* risk allele, or women on hormone replacement therapy. This does remain an area of active investigation and guidelines may change and evolve with emerging evidence.

## Genomics and Biology

The neurofibromatosis-2 (*NF2*) gene was the first gene to be implicated in meningioma development. It remains the most common genetic abnormality in sporadic meningiomas, inclusive of short structural or copy number variants, and is found in up to 60% of all meningioma cases. As a tumor suppressor gene on chromosome 22q12.2, *NF2* encodes the protein Merlin which has been implicated in the inhibition of signals from the PI3K/Akt, Raf/MEK/ERK, and mTOR signaling pathways in non-meningioma cells.<sup>33-35</sup> In meningioma cells, loss of Merlin may also be associated with overexpression of Yes-associated protein 1 (*YAP1*) and deregulation of the Hippo signaling pathway, leading to increased cell proliferation and anchorage-independent growth.<sup>36</sup> *NF2*/Merlin loss may also increase the apoptotic threshold of meningioma cells and decrease susceptibility to cytotoxic therapies through interferon regulatory factor (IRF) mediated gene expression pathways.<sup>37</sup> Consequently, meningiomas with *NF2* alterations have increased risk of higher grade and more biologically aggressive forms, although benign *NF2*-mutant cases are still observed. Specifically, one study found the rate of *NF2* mutations to be 37% in WHO grade 1 meningiomas (81/220), 60% of grade 2 cases (265/441) and 69% of grade 3 tumors (122/176).<sup>38</sup>

More recently, recurrent mutations in *TRAF7* (tumor necrosis factor receptor-associated factor 7), *KLF4* (Kruppel-like factor 4), *AKT1* (AKT serine/threonine kinase 1), *SMO* (Smoothed), *SUFU* (Suppressor of fused homolog), *PRKAR1A* (protein kinase cAMP-dependent type I regulatory subunit alpha), *PIK3CA* (phosphatidylinositol-4,5-bisphosphate 3-kinase catalytic subunit alpha), and *POLR2A* (RNA Polymerase II Subunit A) have been discovered in meningiomas without any *NF2* alterations.<sup>39-44</sup> Compared to *NF2*-altered meningiomas, meningiomas with these mutations tend to be lower WHO grade, have fewer chromosomal abnormalities, and generally have better clinical outcomes with standard therapies.

Interestingly, the anatomic location of meningiomas also appear to have genomic underpinnings. Meningiomas with *NF2* loss tend to be located along the cerebral convexities or posterior/lateral skull base; those with non-*NF2* mutations (e.g. *TRAF7*, *SMO*, *SUFU*, *PRKAR1A*) are more common around the anterior skull base. Meningiomas with combined *NF2/SMARCB1* mutations (two genes in close physical proximity to one another on chromosome 22q) may have a proclivity to occur along the anterior falx.<sup>39,45</sup> Alterations in several meningioma driver genes (including *NF2* and *TRAF7*) have also been found in normal leptomeninges with similar anatomic predilection.<sup>46</sup>

Mutations in *SMARCE1* (SWI/SNF-related matrix-associated actin-dependent regulator of chromatin subfamily B member 1), *BAP1* (BRCA1 associated protein-1), and *PBRM1* are associated with different meningioma histologic subtypes. *SMARCE1* loss is found in almost all cases of clear cell meningioma, which are by definition CNS WHO grade 2.<sup>47-51</sup> *SMARCE1* encodes for a protein involved in the SWI/SNF chromatin remodeling complex and therefore, *SMARCE1*-deficient cells may be susceptible to SWI/SNF inhibition.<sup>50</sup> Inactivation of *BAP1* has been associated with rhabdoid and papillary histology and is almost universally associated with poor prognosis, although fewer than 30 of these cases have been reported in the literature.<sup>52,53</sup> *PBRM1* mutations often co-occur with *BAP1* mutations and are associated with papillary or sometimes rhabdoid histology.<sup>54</sup> Notably, alterations in *SMARCE1* and *BAP1* appear to be independent of *NF2* mutation or loss, identifying a small, rare group of *NF2*-wildtype meningiomas that are unusually aggressive.

Finally, mutations in the *TERT* (telomerase reverse transcriptase) promoter (*TERTp*) have been added to the most recent iteration of the WHO classification as an independent marker of grade 3 meningiomas.<sup>2</sup> While rare in meningiomas, this alteration is associated with significantly worse PFS and overall survival when present.<sup>55,56</sup> *TERT* functions to maintain DNA telomere ends, resulting in immortalization of cancer cells. Successful downstream blockade of *TERTp* activity via E26 transformation-specific (ETS) transcription factor inhibition is a potential therapeutic strategy for these

tumors.<sup>57,58</sup> Other rare mutations associated with higher grade meningiomas include *ARID1A*, *PTEN*, and *PBRM1*.<sup>38,54,59-64</sup>

Some of these mutations may occur in the germline and correspond with hereditary meningioma syndromes. The most common of these is germline mutation of *NF2* resulting in what was historically referred to as syndromic Neurofibromatosis type 2, an autosomal dominant condition characterized by the growth of multiple schwannomas and meningiomas with a prevalence of approximately 1 in 60,000.<sup>65</sup> Due to the overlapping phenotypes of Neurofibromatosis type 2 and schwannomatosis, the latter a tumor predisposition syndrome also characterized by the development of multiple schwannomas, the diagnostic criteria and disease nomenclature for *NF2* and schwannomatosis was updated in 2022. “Schwannomatosis” is now an umbrella term referring to the phenotype of multiple schwannomas, and the individual syndromes are named by their underlying genetic mutation. The *NF2* syndrome has now been renamed *NF2*-related schwannomatosis (*NF2*-SWN) and this is the term which will be used in the rest of this manuscript. Schwannomatosis is designated as *SMARCB1*-related, *LZTR1*-related, or 22q-related.<sup>66</sup> Importantly, meningiomas are uncommon in non-*NF2*-related schwannomatosis and not part of the diagnostic criteria of *LZTR1*-related schwannomatosis and *SMARCB1*-related schwannomatosis despite the presence of *SMARCB1* mutations in sporadic clear cell meningiomas.<sup>67</sup> Meningiomas in *NF2*-SWN patients will be discussed in more detail in a later section.

Other hereditary syndromes associated with meningiomas are less common and there is an overall lack of data supporting these germline mutations driving meningioma tumorigenesis. A rare autosomal dominant inheritance pattern of *SMARCE1* mutations predisposing to intracranial and spinal meningiomas with clear cell histology has been reported.<sup>68,69</sup> Germline *BAP1* loss causes a hereditary cancer predisposition syndrome prototypically associated with mesothelioma and uveal melanoma; sporadic and hereditary germline *BAP1* mutations have also been linked to the development of rhabdoid and papillary meningiomas in small case series, which may have an increased risk of extracranial

metastasis.<sup>53,70-73</sup> Other meningioma-associated tumor predisposition syndromes include: Werner syndrome, an autosomal recessive condition caused by biallelic loss of *WRN*, characterized by premature aging; Gorlin syndrome (or familial multiple meningioma), an autosomal dominant condition resulting from germline mutations in Sonic Hedgehog (Hh) pathway genes including *PTCH1* or *SUFU*, characterized by multiple basal cell carcinomas and biologically aggressive meningiomas<sup>74-76</sup>; and Cowden syndrome, another autosomal dominant condition resulting from germline *PTEN* mutation, characterized by multiple cancers including of the breast and thyroid.<sup>62</sup> Notably, there are all rare entities and only a subset of patients with each disease will develop meningiomas. Specifically, the overall prevalence is estimated to be between 1 in 20,000 (in some Japanese populations) to as few as 1 in 1,000,000 for Werner syndrome, between 1 in 30,000 and 1 in 250,000 for Gorlin syndrome,<sup>77-79</sup> and between 1 in 200,000 and 1 in 250,000 for Cowden syndrome.<sup>77-79</sup> The specific prevalence of germline *SMARCE1* and *BAP1* mutations is unclear given their rarity.

In addition to single-gene alterations, somatic copy number alterations (other than loss of 22q) have also been implicated in meningioma development. Deletions of chromosome 1p were identified early in meningiomas, where it was associated with shorter progression-free survival (PFS).<sup>80-86</sup> Multiple genomic targets of 1p loss have been proposed including *CDKN2C*, *RAD54*, *EPB41*, *GADD45A*, *ALPL*, *MUTYH*, *PRDX1*, *FOXD2*, *FOXE3*, and *PTCH2*, but their independent prognostic contributions to a more aggressive meningioma phenotype remain relatively unknown.<sup>87,88</sup> This remains an area of active study. Losses of chromosomal arms 6p, 10q, 14q, 18q, and gains of 17q and 20q were found to be recurrent across high-grade meningiomas and additional studies have linked losses of 4q, 6, and 19p with poorer PFS.<sup>89-94</sup> In cases without chromosome 22q loss, several unique somatic copy number alterations including those affecting chromosomes 2q and 7q were found to be associated with dysregulated Hh signaling activation in otherwise mutation-negative meningiomas.<sup>95</sup>

Importantly, homozygous loss of the *CDKN2A/B* (cyclin-dependent kinase inhibitor 2A/B) locus on chromosome 9p21 was incorporated into the 2021 WHO classification as a defining feature of CNS WHO grade 3 meningioma.<sup>2</sup> *CDKN2A/B* encodes for multiple tumor suppressor proteins including p16, which inhibits G1-to-S transition in the cycle cell through the inactivation of CDK4 and CDK6. Its loss has been implicated in dysregulated cell cycle progression in multiple cancers.<sup>96,97</sup> In meningioma, homozygous deletion of *CDKN2A/B* is associated with shorter PFS, and even heterozygous deletion appears to result in similarly poor outcomes in some studies.<sup>98-101</sup> In meningiomas with an intact *CDKN2A/B* locus, higher mRNA expression of *CDKN2A* is associated with significantly shorter PFS and increased rates of resistance to CDK inhibitors.<sup>98</sup>

The integration of prognostic copy number alterations with contemporary histological grading has resulted in the development of “integrated” or “molecular-morphologic” grading schemes. For example, a nomogram whereby one point is assigned to each of the following copy number alterations if present: 1p-, 3p-, 4p/q-, 6p/q-, 10p/q-, 14q-, 18p/q-, 19p/q-, *CDKN2A/B*- in addition to one point for 4-19 mitoses per 10 high-powered fields or two points for more than 20 mitoses. A total of 0-1 points would constitute an Integrated Grade 1 meningioma, 2-3 points an Integrated Grade 2 meningioma, and 4 or more points an Integrated Grade 3 case. This Integrated Grade was able to predict recurrence more accurately than standard WHO grading alone.<sup>92</sup> Similar models have been developed by assigning scores based on WHO grade, DKFZ methylation-class family (benign, intermediate, or malignant; to be described further below), and the presence of only three prognostic CNVs: 1p-, 6q-, and/or 14q-. This integrated score also had significantly better accuracy in outcome prediction compared to WHO grade, particularly for meningiomas bordering the threshold between CNS WHO grade 1 and 2.<sup>93</sup>

## Histopathologic Classification

The histopathologic characteristics of meningioma have been the main correlate to outcome for decades and still form the basis of WHO grading. Released in 2021, the 5<sup>th</sup> edition of the WHO CNS classification is the first to include molecular criteria for the definition of a CNS WHO grade 3 meningioma: presence of a *TERT*<sup>p</sup> hotspot mutation or homozygous loss of *CDKN2A/B*. These molecular alterations are both rare in meningiomas, particularly in cases that do not have other worrisome histologic findings. In the absence of these alterations, which automatically impart a CNS WHO grade 3 designation, grading is assigned based on histopathologic features such as the number of mitoses or identification of at least 3 out of 5 “soft” criteria for atypia (sheeting architecture, hypercellularity, small cell formation, macronucleoli, spontaneous necrosis) (**Figure 2**).<sup>2,102</sup> While the presence of brain invasion alone is now sufficient for a designation of CNS WHO grade 2 meningioma, its association with outcome in the absence of any other higher grade histopathological features (e.g. without elevated mitotic index, hypercellularity, loss of architecture, small cell change, spontaneous necrosis, or prominent nucleoli) remains unclear.<sup>103-105</sup> Given that cases of brain invasion alone as a solitary atypical feature is rare, only a minority of meningioma cases will likely require re-grading retrospectively.<sup>104</sup> More work is needed to understand the biological significance and mechanism of brain invasion in meningioma.<sup>106</sup> Furthermore, current intraoperative sampling methods vary significantly between neurosurgical departments worldwide and this requires standardization.<sup>107,108</sup> A systematic, structured method of safely sampling areas suspicious for brain invasion during surgery may be needed to optimize the diagnostic yield for detecting CNS invasion. While chordoid or clear cell histology still mandate a grade 2 classification, rhabdoid or papillary histology alone without other features of anaplasia or malignancy are now insufficient to render a grade 3 designation (**Figure 2**).<sup>2,102</sup>



## Biomarkers and Molecular Classification

Given the prognostic alterations uncovered in meningiomas, significant efforts have been made to develop a unified molecular classification system like those for glioma and medulloblastoma. In 2017, the first landmark studies on genome-wide DNA methylation-based classification systems for meningioma were published. These models were capable of stratifying meningiomas into groups at high- or low-risk of recurrence and further identified six unique subgroups (benign-1, benign-2, benign-3, intermediate-A, intermediate-B, malignant) that appeared to reflect tumor biology more accurately than WHO grade alone.<sup>109,110</sup> In a different study, the DNA methylation profiles of meningiomas could be further combined with prognostic clinical variables including histologic grade and extent of resection to produce a readily useable clinical nomogram that could robustly predict clinical outcome and help guide decisions on adjuvant treatment after surgery for individualized patients.<sup>111</sup>

Later, the integration of genome-wide DNA methylation, mRNA expression, and copy number alterations resulted in the discovery of four stable molecular groups (MGs) of meningioma (**Figure 3**).<sup>64</sup> Classification by MG was found to have improved prognostication potential and biological relevancy compared to WHO grade and classification using any single epigenomic or genomic platform alone. MG1 or “immunogenic” meningiomas are *NF2*-mutant, copy number neutral cases enriched in immune-related transcriptomic pathways. MG2 meningiomas are enriched for non-*NF2* mutations and angiogenic processes, earning the “*NF2*-wildtype” designation. MG3 and MG4 meningiomas are enriched for prognostically unfavorable alterations including *TERT*<sub>p</sub> mutation and homozygous loss of *CDKN2A/B*, in addition to novel somatic mutations in *KDM6A*, *CHD2*, and *PTEN*, and a higher degree of chromosomal instability. On transcriptomic analysis, MG3 meningiomas showed upregulation of several metabolic pathways including those involved in nucleotide and lipid metabolism, giving this group its “hypermetabolic” name. MG4 or “proliferative” meningiomas are enriched for cell cycling pathways

including *MYC*, *FOXM1*, and *E2F* pathways, have the highest mutational and copy number burden, and were associated with the worst clinical outcomes.<sup>64,112-116</sup>

Other molecular classifications were also independently developed by others with some differences between them that could be attributed to the use of different genomic/epigenomic platforms and bioinformatic methods used. Choudhury et al. uncovered three stable methylation groups with unique clinical outcomes and biology: Merlin-intact (MI), immune-enriched (IE), and hypermitotic (HM). MI meningiomas, analogous to MG2 (NF2-wildtype), are largely benign cases enriched for non-*NF2* driver mutations such as *TRAF7*, *AKT1*, and *KLF4*. IE meningiomas, similar to MG1 (immunogenic), are cases found to have significant immune cell infiltration and increased expression of *HLA* and meningeal lymphatic genes including *LYVE1*, *CCL21*, and *CD3E*. HM meningiomas are clinically aggressive cases with poor outcomes enriched for *FOXM1* cell proliferation pathways.<sup>37</sup> Subsequent reanalysis of the HM group revealed two distinct subgroups within it: one enriched in pathways related to macromolecule metabolism (resembling the MG3 hypermetabolic meningiomas with intermediate to poor outcomes) and one enriched for cell cycle pathways that had the worst clinical outcomes (similar to the MG4 proliferative meningiomas). These findings seem to support the concept of either four distinct molecular groups matching those by Nassiri et al. or three epigenetic groups with one group that could be further split into two subgroups with distinct outcomes.<sup>117</sup> Bayley et al. also found three methylation groups based on integration of DNA methylation, RNA expression, *NF2* status, and degree of chromosomal instability in a cohort of primary CNS WHO grade 1 and 2 meningiomas. By their classification, MenG A meningiomas are almost entirely CNS WHO grade 1, have no cytogenetic changes, and are *NF2*-wildtype, corresponding to the MG2 and MI groups described above. MenG B meningiomas are all *NF2*-deficient, have a low degree of chromosomal instability, and have overall good clinical outcomes, seemingly matching the MG1 and IE groups. MenG C meningiomas are *NF2*-deficient, have a high burden of copy number alterations including 1p loss, and like the MG3, MG4, and HM

groups, have the worst clinical outcomes.<sup>118</sup> Each of these molecular classification systems tend to complement and/or outperform contemporary WHO grading alone in predicting clinical outcome. Despite differences in naming, these molecular classifications share a significant degree of common biology (**Figure 3**). These studies together have also not only proven the value of utilizing orthogonal bioinformatic methods to independently produce stable, somewhat analogous molecular groups, but have also generated a wealth of genomic data as a valuable resource for future studies. An important caveat is that these classifiers may be insufficiently powered to include rare subsets of poor-performing *NF2*-wildtype tumours including meningiomas with *BAP1* mutations, and management of these unusual, but clinically important cases should be carefully considered on an individual patient basis. Upcoming efforts, including those by the cIMPACT-NOW group will focus on reconciling the nomenclature of these different molecular classifications to reach a consensus that can be hopefully implemented into a unified, contemporary grading system.

One of the additional challenges hindering the routine implementation of these molecular classifications is the requirement for sequencing and/or methylation array technology that may not be accessible at all centers. This is in addition to other barriers to genomic testing that include: financial reimbursement, site-dependent experience in data analysis and interpretation, and uncertainty in selecting the specific test to perform. One method of circumventing some of these challenges may be with proteomics to identify not only immunohistochemical (IHC) markers enriched in each molecular group, but to identify specific markers or combination of markers unique to each group such that tumors can be molecularly subtyped without the need for genomic analyses. For this to be clinically validated, IHC stains will need to be multiplexed in large, molecularly annotated meningioma cohorts, and analyzed by experienced neuropathologists blinded to molecular data.

Additional uncertainty may arise in deciding on which molecular classification or integrated grading system to use. Whilst there are differences in classification or prognostication through models

that are trained on or incorporate different clinical endpoints (e.g. integrated molecular-morphological meningioma classification or integrated WHO grade) versus the unbiased molecular group classifications detailed above, these methods all provide some degree of additive prognostic information to traditional grading and for the time being, may be utilized interchangeably based on the available resources of each site.<sup>64,92,93,117-119</sup> Efforts to expand access to genomic and methylation testing for meningiomas will not only aid in prognostication, but help ensure continued progress in better understanding the clinical and biological behavior of these tumors. To this point, while the DNA methylation and gene expression patterns of some meningiomas appear to remain stable between the primary and recurrent case, the effect of accumulating epigenetic and genomic alterations including progressive chromosomal instability with multiply recurrent cases (including cases that were completely resected at one point), metastatic meningiomas, and cases following RT still need to be further investigated.<sup>109,120,121</sup>

An emerging area of promise for meningiomas is the use of liquid biopsy for diagnosis and subtyping. The use of cell-free methylated DNA immunoprecipitation and high throughput sequencing on patient plasma could effectively differentiate meningiomas from other radiographic mimickers such as solitary fibrous tumors, dural-based metastases, and chordomas.<sup>122,123</sup> Extracellular vesicles from the plasma of meningioma patients quantitatively correlate with extent of resection and their contents were found to reliably recapitulate the methylation signatures of the parent tumor, including copy number and mutational profile.<sup>124</sup> Plasma-based DNA methylation signatures of meningioma patients may have similar prognostic potential as the tumor tissue itself for differentiating between cases at high- and low-risk of recurrence, although these findings still need to be further validated in larger, external validation cohorts with matched tissue profiling.<sup>125</sup>

## Diagnosis and Imaging

Many meningiomas are diagnosed when patients become symptomatic from either mass effect or seizures.<sup>126-128</sup> On non-contrast computed tomography (CT), up to 25% will contain some degree of calcification, which may be associated with slower tumor growth and lower WHO grade in some cases.<sup>129</sup> Magnetic resonance imaging (MRI) is the preferred modality for confirming the radiographic diagnosis with most meningiomas being isodense to cortex on all sequences, and approximately 50% may be associated with some perilesional edema.<sup>130</sup> Secretory, microcystic, angiomatous, and lymphoplasmacyte-rich meningiomas are histologic subtypes that are all known to cause a disproportionately large degree of edema relative to tumor size and may portend increased risk of postoperative complications.<sup>131,132</sup> Almost all meningiomas avidly enhance with gadolinium contrast and up to 72% have a dural tail.<sup>133</sup> Whether the dural tail consistently contains neoplastic meningioma cells requiring treatment or simply represents reactive or inflammatory thickening is controversial.<sup>134-138</sup> Vascular imaging, often CT- or MR-angiogram (CTA, MRA) and/or CT/MR-venogram (CTV, MRV) can help assess the involvement of nearby vascular structures for treatment planning, which is particularly important around the skull base or dural venous sinuses. Formal cerebral angiography is more rarely performed but may be indicated if non-invasive vascular imaging provides insufficient information or if preoperative embolization is planned. There is some controversy regarding whether preoperative embolization reliably leads to decreased blood loss intraoperatively and there may be an association with increased risk of postoperative venous thromboembolism.<sup>139,140</sup> Therefore, preoperative embolization is not a recommended strategy for all meningiomas and decisions surrounding its use must be made on a case-by-case basis.

There are currently no standardized response criteria or clinical trial endpoints for meningioma studies. Previous trials have used a modification of the Macdonald criteria (initially developed for high grade gliomas), the Response Assessment in Neuro-Oncology (RANO) criteria for high-grade gliomas, or

the Response Evaluation Criteria in Solid Tumors (RECIST) criteria for systemic cancers.<sup>141-146</sup> While some trials have used a reduction in lesion size as a radiographic endpoint, meningioma control is better encapsulated by lack of growth (size stabilization) as a decrease in size occurs in only a relative minority of cases treated with RT over time (approximately 20-30% of cases).<sup>147-149</sup> Additionally, while overall survival is often the gold standard for determining treatment efficacy, the long follow-up time required to reach this endpoint for all but the most aggressive meningiomas presents a significant challenge, particularly for clinical trials. The Response Assessment in Neuro-Oncology (RANO) Working Group instead proposed that 6-month progression-free survival (PFS6) could be a viable endpoint for meningioma drug trials with a 25% increase in the tumor's bidimensional product representing definitive progression.<sup>141</sup> For patients enrolling in clinical trials, collection of pre-treatment MRIs will be important to confirm adequate progression of the tumor during trial follow-up. In the future, measurement of tumor volume and assessing changes in the rate of tumor volume growth before and after treatment may be another method of evaluating the efficacy of novel therapies.<sup>150</sup> For reporting in retrospective studies, the International Consortium on Meningiomas (ICOM) proposed the definition of tumor progression to be any radiographic progression that leads to a change in the clinical management of the tumor (e.g. from observation to consideration for surgery, RT, or stereotactic radiosurgery (SRS)), thereby excluding cases of minimal radiographic growth or small volume increases followed by a long plateau of stability that may not ultimately be of any clinical significance.<sup>151</sup>

An emerging imaging tool for meningiomas is positron emission tomography (PET) using somatostatin receptor (SSTR) ligands such as Gallium-68-labelled DOTATATE given that nearly all meningiomas express SSTR1/2 (**Figure 4**).<sup>152</sup> Recently published guidelines from the RANO Working Group suggest that [<sup>68</sup>Ga]Ga-DOTATATE PET can be used for diagnosis, surgical resection and RT treatment volume planning, as well as post-treatment surveillance (**Figure 4**).<sup>153,154</sup> When compared to conventional MRI, [<sup>68</sup>Ga]Ga-DOTATOC PET had improved sensitivity for detecting meningiomas

particularly in areas of tumor invading bone, locations obscured by calcifications or radiographic abnormalities, tumors centered at the skull base, or those located next to the falx.<sup>155</sup> The ability to image the entire body is also advantageous for detecting systemic metastases in multiply recurrent higher grade or malignant meningiomas that although rare, will dramatically influence patient prognosis and treatment planning if identified. When correlated with SSTR2 immunohistochemistry and tumor histology, [<sup>68</sup>Ga]Ga-DOTATATE PET was found to be capable of differentiating between meningioma and tumor-free tissue with high accuracy, suggesting that it can be reliably used to demarcate tumor invaded bone that may require additional drilling to maximize extent resection (particularly in the skull base; **Figure 4**) and inform adjustments in RT target volumes in addition to potential response assessment after RT.<sup>152,156-160</sup> Postoperatively, PET imaging may also better define residual tumor and therefore extent of resection more accurately than traditional MRI and may also differentiate true tumor progression/recurrence from treatment effect.<sup>153,161,162</sup> Recently, Fluorine-18-labelled SSTR-tracers such as [<sup>18</sup>F]SiTATE have been developed which demonstrate similarly high uptake in meningiomas while boasting lower radiation exposure and less logistic constraints for transport and clinical use compared to [<sup>68</sup>Ga]Ga-DOTATATE PET given its longer half-life (110 vs 68 minutes).<sup>163,164</sup> Although PET imaging is a promising addition to the armamentarium for meningioma diagnosis and treatment, its limitations include the still sparse data on cost effectiveness, physiologic uptake near certain anatomic structures such as the pituitary gland, and tracer uptake by other tumors or non-neoplastic diseases that may also express SSTR.<sup>153,165</sup> Furthermore, additional prospective work and multicentre clinical trials are needed to link these positive findings from often single institution retrospective studies with demonstrable improvements in clinical outcomes.<sup>152</sup>

While many meningiomas are diagnosed symptomatically, approximately 20% are found incidentally, a proportion likely to increase with an aging population with increased access to neuroimaging.<sup>128,166</sup> Incidental meningiomas can be a source of significant anxiety for patients, an

economic burden due to the need for regular follow-up imaging, and a clinical dilemma for clinicians due to their unpredictable biology given the absence of diagnostic tissue.<sup>128,166-168</sup> Natural history studies on incidental meningiomas typically only extend to the 10-year follow-up mark and most have found a relatively slow growth rate (average <5% volumetric increase per year). Approximately 5-8% of patients will develop new symptoms during a mean follow-up period of 4.1 years (standard deviation 2.4 years).<sup>167</sup> Imaging features that may portend a higher risk of progression of an incidental meningioma include: lack of calcification, hyperintensity on T2-weighted MRI, presence of peritumoral edema, large tumor volume at diagnosis (>10 cm<sup>3</sup>), non-skull base location, and closer proximity to a venous sinus.<sup>39,114,167,169-175</sup> There are currently no standardized guidelines for the interval or duration of monitoring for incidental meningiomas. Although most meningiomas that progress will do so within 5 years of observation, some cases can remain indolent for a longer period before demonstrating accelerated recurrence or growth. Consequently, many clinicians may follow incidental meningiomas in younger patients for a longer duration of time, progressively lengthening the interval between neuroimaging while elderly patients may be discharged from follow-up earlier after a confirmatory period of radiographic stability.<sup>128,167</sup> Several prognostic models such as IMPACT (Incidental Meningioma: Prognostic Analysis Using Patient Comorbidity and MRI Tests) have been developed to assist clinicians in tailoring follow-up to a specific patient based on individualized clinical and tumor factors but these models all require prospective validation.<sup>128,166,176-178</sup> Upfront treatment of incidental meningiomas is also an option, with surgical resection for often larger tumors, and SRS as a reasonable option for smaller volume cases or for patients with contraindications to surgery.<sup>179-181</sup> Decisions to treat usually hinges on a combination of patient wishes, clinician preference, and tumors factors including proximity of the meningioma to critical neurovascular structures such that further enlargement or growth could make later resection more challenging or higher risk. Newer technologies such as liquid biopsy or <sup>18</sup>F-FLT PET could be used to help predict risk of recurrence non-invasively and better



individualize management for these cases.<sup>125,182</sup> While SRS improves radiographic local control of asymptomatic meningiomas compared to observation, this may not translate to a reduced risk of developing new symptoms over time.<sup>181</sup> Furthermore, even though a subset of incidental meningiomas will grow radiographically, these changes may not become clinically significant until tumor size reaches a certain threshold or nears eloquent brain areas. As usual, treatment decisions should weigh the risks of progression versus the risks of intervention, while also taking into consideration the psychosocial, neurocognitive, and socioeconomic effects of active surveillance for the patient versus upfront treatment.<sup>183,184</sup>

### **Surgical Management**

Surgery remains the mainstay of treatment for growing or symptomatic meningiomas (**Figure 5**). Goals of surgery, as defined by the 2021 EANO guidelines, are predominantly to obtain a tissue diagnosis, relieve mass effect, and alleviate neurologic symptoms if present.<sup>127</sup> Notably, extent of resection is an important correlate of outcome, and maximal safe resection should be sought while minimizing neurologic morbidity for all cases. To this end, surgical adjuncts including neuronavigation, ultrasonography, and intraoperative neuromonitoring are critical for tumors located in highly eloquent areas such as the cerebellopontine angle or foramen magnum, to reduce the risk of incurring permanent neurologic injury. Since some meningiomas are intimately associated with critical neurovascular structures, complete resection without unacceptable morbidity is not always possible; it is therefore important to standardize a maximally beneficial degree of resection for these cases in a meaningful way.

The Simpson grade, first introduced in 1957, describes surgeons' assessment of the extent of resection for meningioma. It ranges from Simpson grade 1 (complete resection of tumor, affected dural attachment, and bone) to 5 (decompression/biopsy only) with higher grades associated with higher

rates of recurrence.<sup>185-188</sup> Complete tumor resection may be designated as Simpson grade 1, 2, or 3 depending on whether the underlying dura is resected, coagulated in situ, or left intact respectively. While the Simpson grade has historically been a major predictor of postoperative PFS, its role in modern meningioma surgery has become somewhat controversial.<sup>161,186,187,189-191</sup> For example, recent studies have shown that resecting the underlying dura (Simpson grade 1 resection) may not be associated with improved outcomes compared to other Simpson grades.<sup>190,191</sup> This is important in cases of meningiomas originating from the skull base, wherein aggressive dural resection may be associated with increased risk of complications such as CSF leak or for meningiomas involving dural venous sinuses wherein hemorrhage, venous infarct, or air embolism are notable risks.<sup>186,190</sup> In these cases, achieving maximal tumor resection without excising the underlying dura may decrease morbidity without affecting PFS. Additionally, skull base meningiomas are more likely to exhibit more benign biology, which is used as evidence for opposing viewpoints: on one hand, striving for a Simpson grade 1 resection in these complex cases may confer unnecessary surgical risk, thereby supporting a more conservative approach; on the other hand, complete resection in the context of a meningioma with benign biology may provide an opportunity for robust oncologic cure, obviating the need for adjuvant RT and supporting a more aggressive surgical approach.<sup>192-194</sup> The optimal strategy in these cases will depend largely on the surgeon's comfort level, experience, and of course, the patient's wishes and their risk tolerance for neurologic deficits, temporary or permanent, that may be incurred in an effort to achieve a potential cure. As an additive step to a Simpson grade 1 excision, "Simpson grade 0" resection, whereby an additional 2-cm margin of surrounding dura is removed, has been proposed primarily for convexity located meningiomas where this is most feasible.<sup>195</sup> However, there are currently no well-established guidelines for the extent of dural resection recommended to optimally prolong time to recurrence and adjunctive technologies such as Raman spectroscopy or SSTR PET may help to better define this moving forward.<sup>152,156,161,196-198</sup>

Considering these limitations in Simpson grading in meningioma, there has been movement towards defining extent of resection as either gross total resection (GTR), indicating cases where all tumor is removed regardless of how the underlying dura is handled (Simpson grades 1-3), and subtotal resection (STR), indicating cases where a portion of gross tumor is left behind (Simpson grades 4/5). This definition has been adopted by organizations such as the European Organization for Research and Treatment of Cancer (EORTC) and the Radiation Therapy Oncology Group (RTOG).<sup>127</sup> However, the role of Simpson grading and extent of resection in the context of meningioma molecular classifications has yet to be adequately explored.

The different surgical approaches to intracranial meningiomas are vast and a comprehensive review of each approach is beyond the scope of this paper. The latest evolution in surgical techniques for these tumors emerged with improvements in endoscopic technologies, permitting endoscopic expanded endonasal approaches (EEA) for anterior skull base including olfactory groove and tuberculum sellae meningiomas (or, less commonly, tumors in the middle fossa, posterior fossa, or orbit) for appropriately selected patients. Tuberculum sellae meningiomas (TSM) are the prototypical candidates for endoscopic resection through an EEA and there is a trend toward better visual outcomes but higher rates of CSF leaks for these patients when compared to open, transcranial approaches.<sup>199-201</sup> TSM selected for EEA tend to be smaller in size with less perilesional edema and no vascular encasement.<sup>201</sup> Overall, there is insufficient evidence demonstrating universal superiority of one approach over another, and each case should be individualized based on patient and tumor factors in addition to the surgeon's comfort and expertise.<sup>127</sup>

## External Beam Radiotherapy for Meningiomas

In addition to surgical resection, RT is the only currently established treatment for meningioma. This may be done as primary treatment or as an adjunct to surgery, either as adjuvant therapy or salvage treatment at the time of progression/recurrence. However, the optimal timing of adjuvant RT is currently unknown. The recent EANO guidelines suggest RT can be utilized as primary treatment for symptomatic patients or those with sufficiently large tumors who cannot undergo surgery due to underlying comorbidities, surgical risk, or patient preference. These guidelines also recommend RT as an adjunct to surgery in all patients with CNS WHO grade 3 meningiomas or CNS WHO grade 2 cases following subtotal resection. Recent evidence suggests that RT may have a role even for patients with CNS WHO grade 1 meningiomas that cannot be completely resected, a cohort that had worse PFS than completely resected and irradiated CNS WHO grade 2 meningiomas in the non-randomized RTOG-0539 phase II clinical trial (**Figure 5**).<sup>127,202</sup>

The use of adjuvant RT in all CNS WHO grade 3 meningiomas and partially resected CNS WHO grade 2 meningiomas (so called “high-risk” cases) however is supported by the same RTOG-0539 trial, which treated these cases with intensity modulated RT (IMRT) in 60 Gy over 30 fractions.<sup>203</sup> This achieved a 3-year progression-free survival of 58.8% and overall survival of 78.6% in 51 enrolled patients, with minimal adverse effects (one grade-5 necrosis related complication in a patient with a large RT treatment field, all others grades 1-3). Additionally, EORTC 22042-26042, a non-randomized phase II study of patients with WHO grade 2 meningioma who underwent complete resection and postoperative RT (60Gy), achieved an encouraging 3-year PFS of 88.7%.<sup>204</sup> With improvements in RT technology, dose escalation has been proposed as a strategy for higher grade (WHO grade 2 or 3) meningiomas. The phase II MARCIE trial utilized a carbon-ion (C12) boost of 18 Gy over 6 fractions combined with IMRT or fractionated stereotactic RT of 50.4 Gy/28 fractions for incompletely resected WHO grade 2 meningiomas, with resultant 3-year PFS and local control rates of 80.3% and 86.7%

respectively. However, a higher-than-expected proportion of patients developed radiation-induced contrast enhancement post-treatment and the study was prematurely terminated due to one treatment-associated death.<sup>205</sup> A large, single-center retrospective study from Toronto found that dose escalation of conventional photon-based RT to 66-70 Gy over 33-35 fractions for WHO grade 2 and 3 meningiomas (both as adjuvant and salvage treatment) led to improvements in local control and PFS compared to standard dose RT (59.4-60 Gy/30-33 Fr), without a significant difference in treatment-related adverse events, although the authors acknowledged likely underreporting of these toxicities.<sup>206</sup> A randomized controlled trial is likely warranted to help answer the question of optimal RT dosing for these higher grade cases. Several other retrospective studies also support the use of adjuvant RT in CNS WHO grade 2 and 3 meningiomas but are limited by small sample sizes, non-standardized RT doses/techniques, lack of distinction between local and out-of-field treatment failures, and evolving WHO criteria.<sup>207,208</sup> There continues to be controversy on the benefit of adjuvant RT in patients with completely resected CNS WHO grade 2 tumors, a group wherein the guidelines remain equivocal. This critical question is being addressed with the ongoing phase III randomized trials NRG BN-003 (NCT03180268) and ROAM/EORTC-1308 (ISRCTN71502099) and results are pending.<sup>209-212</sup>

The use of WHO grading to stratify meningiomas into different treatment arms should also be considered carefully. The WHO criteria for CNS WHO grade 2 and 3 meningiomas (the cases that are most often selected for adjuvant RT) have undergone several updates of varying degrees from 2000 to 2021.<sup>2,213-215</sup> Clinical trials that accrue over several years will therefore require central pathological review or be limited by this confounder. Furthermore, apart from the most recent 2021 classification, all previous WHO grading systems were almost entirely based on histopathology alone and in some instances may be susceptible to differences in interpretation between pathologists.<sup>216,217</sup> Additionally, in this emergent molecular era of meningioma classification, the WHO grade has been shown to be less predictive of outcome than nearly all molecular classifications although robust, large scale validation of

these classifications are still needed, particularly as it pertains to response to RT. Despite the associated challenges, it will be important to consider prognostic molecular alterations when it comes to optimal selection of patients for adjuvant RT after surgery. When DNA methylation was performed on 38 CNS WHO grade 2 and 3 meningiomas from the phase II EORTC 22042–26042 clinical trial that received different degrees of surgical resection, loss of chromosome 1p and unfavorable DKFZ methylation class were found to be associated with worse 3-year PFS, although statistical significance was not met.<sup>218</sup> Recently, a 34-gene targeted gene-expression signature was developed that appeared to outperform WHO grade and several different molecular-based grading systems in accurately predicting 5-year PFS. Using this signature, which was also validated using cases from the RTOG-0539 trial, meningiomas were able to be stratified into cases at high- and low-risk of recurrence.<sup>219</sup> Although this gene expression biomarker was robustly validated in large external cohorts where postoperative management for up to 29.8% of cases could be refined, these cohorts spanned multiple decades of time and included only 210 patients who received postoperative RT. Therefore, further validation will still be needed to translate this and other molecular predictors of RT response to clinical practice.<sup>220</sup>

Finally, patients undergoing primary RT for meningioma in lieu of surgery may undergo either SRS or fractionated external beam RT. While both have been associated with excellent rates of tumor control, the latter may be preferred for larger tumors (typically larger than 2-3 cm in maximum diameter but may be institution-dependent) or those close to radiation-sensitive structures such as the brainstem or optic nerves since fractionation optimizes normal tissue tolerance.<sup>221-224</sup> Nevertheless, recent non-randomized evidence suggests that larger meningiomas may have worse outcomes with fractionated RT.<sup>223,225,226</sup> Small cavernous sinus meningiomas and optic nerve sheath meningiomas, however, tend to be well controlled with primary fractionated RT and have similarly excellent rates of symptomatic improvement after treatment.<sup>223,227,228</sup>

## Stereotactic Radiosurgery for Meningiomas

SRS is defined as treatment with a single fraction of radiation, typically using doses ranging from 12-18 Gy to the 50% isodose line for Gamma Knife, 60-70% isodose line for CyberKnife, or up to 80% for other linear accelerator (LINAC) based methods. Delivery of SRS in multiple fractions using frameless image-guided SRS systems, termed hypofractionated stereotactic radiotherapy (HSRT), has also been implemented and typically applies a dose per fraction of  $\geq 5$  Gy not exceeding 5 fractions. The multicenter retrospective IMPASSE study on small asymptomatic/incidental meningiomas demonstrated that in a large cohort matched for patient age, tumor volume, location, and imaging follow-up, meningiomas that received SRS had a tumor control rate of 99.4% compared to 62.1% in the observation arm. This suggests that SRS likely does change the natural history of some meningiomas, with the caveat that most incidental and asymptomatic meningiomas do not demonstrate clinically significant growth on long-term follow-up and can be safely observed without any treatment.<sup>128,167,177</sup> Treatment may be warranted in meningiomas that are adjacent to critical structures such that growth may lead to significant neurologic deficits, particularly in younger patients, although this decision too must be balanced against long-term RT-associated sequelae.<sup>208</sup>

In a meta-analysis of non-cavernous sinus CNS WHO grade 1 meningiomas treated with SRS or hypofractionated stereotactic radiotherapy, local control rates ranged from 71-100% (median 94.2%) while progression-free survival (PFS) ranged from 55%-97% (median 89.4%) with a median follow-up of at least 3-years.<sup>229</sup> Factors associated with improved tumor control included smaller volume and patient age under 65.<sup>229</sup> Local control and PFS rates for cavernous sinus meningiomas are more favorable, with 5-year PFS rates ranging from 86-99% and 10-year PFS rates ranging from 69-97%.<sup>229</sup> Factors associated with improved local control following SRS included higher marginal dose, small-to-medium sized tumors, CNS WHO grade 1, primary SRS (vs adjuvant), treatment within 1 year of symptom onset, female sex, younger age, and less conformal plans. By contrast, tumor volume  $>10$  cc, parasagittal/parafalcine

location, and venous sinus invasion were associated with worse tumor control and an increased rate of complications after SRS.<sup>207,208,224,230-232</sup>

The evidence on SRS for higher grade meningiomas (CNS WHO grades 2 and 3) is limited. However, tumor control in histologically-confirmed higher grade meningiomas is typically poor, with one series reporting rates of 50% and 17% at 2-2.5 years for WHO grade 2 and 3 tumors, respectively.<sup>233</sup> A recent multicenter study of 233 WHO grade 2 meningiomas found a similar 3-year PFS rate of 53.9% after SRS, with a 5-year PFS of 33.1%. When recursive partitioning analysis was performed, two subgroups were identified with divergent prognoses. Poor outcomes were associated with patient age over 50, multiple prior resections or prior RT, and treatment volume >11.5 cm<sup>3</sup>.<sup>234</sup> There are limited data on whether higher SRS doses or hypofractionated treatment regimens are advantageous for higher grade meningiomas and existing evidence is confounded by clinical factors such as pre-treatment clinical history, treatment timing, and RT field. Therefore, prospective studies are needed for cases with treatment equipoise. Importantly, as with external beam RT, given the lack of molecular stratification in the current SRS literature, future studies should focus on incorporating these modern classification schemes in retrospective and prospective studies.

### **SSTR-Targeted Peptide Receptor Radionuclide Therapy**

Given the fact that SSTR2 ligands can be utilized for either diagnostic (e.g. <sup>68</sup>Ga) or therapeutic purposes (e.g. <sup>177</sup>Lu or Y), the novel concept of theranostics has gained traction in meningiomas.<sup>235</sup> Several mostly single- or bi-center retrospective studies have been completed with promising results in terms of achieving stable disease in progressive, pretreated meningiomas.<sup>236,237</sup> The uptake of the diagnostic tracer might be suitable as a prognostic marker for the efficacy of this therapy given its usually high sensitivity and specificity for its target.<sup>238</sup> Recently, an EMA- and FDA-approved



radiopharmaceutical for SSTR2-radioligand therapy became available for the treatment of neuroendocrine tumors, which like meningiomas, are characterized by high SSTR expression.<sup>239</sup> A recent single-arm phase II study (NCT03971461) on the use of <sup>177</sup>Lu-DOTATATE for progressive, intracranial meningiomas saw 6/14 patients achieving the PFS-6 threshold required for the study to progress to its second stage, currently open for enrolment in the US.<sup>240,241</sup> A randomized clinical trial to evaluate the efficacy in <sup>177</sup>Lu-DOTATATE in recurrent meningioma is in preparation within the EORTC Brain Tumor Group network. Other radioligands are also currently being developed for similar applications.

### **Systemic Therapies for Meningiomas**

Classically, meningioma treatment has centered on surgical resection and RT. However, novel systemic agents have emerged as a possible option for recurrent or aggressive tumors, all of which remain under investigation.<sup>242</sup> These include tyrosine kinase inhibitors and monoclonal antibodies targeting vascular endothelial growth factor (VEGF) signaling pathways given the established role of angiogenesis in the pathophysiology of meningiomas.<sup>243-247</sup> A phase II trial of the multikinase inhibitor sunitinib which targets the VEGF and platelet-derived growth factor receptors, among others, in grade 2 and 3 meningiomas showed a 6-month progression free survival (PFS6) rate of 42%, meeting the primary endpoint.<sup>243</sup> A phase II trial of bevacizumab in recurrent meningiomas showed a PFS6 of 77% in grade 2 and 46% in grade 3 meningiomas suggesting possible activity.<sup>248</sup> The Alliance A071401 trial is the first genome-driven platform phase II study in which patients with recurrent meningiomas are genotyped and assigned to treatment with vismodegib for tumors with *SMO* mutations, abemaciclib for CDK alterations, capivasertib for *AKT* or *PI3K* mutations and a FAK inhibitor (GSK2256098) for *NF2*-mutant cases. GSK2256098 was well tolerated and demonstrated promise in achieving a PFS-6 in progressive WHO grade 1 of 83% and 33% in WHO grades 2/3 meningiomas. Cytotoxic and hormonal agents,

including trabectedin, somatostatin agonists and progesterone antagonists, have demonstrated less clinical efficacy.<sup>247,249-257</sup>

Immunotherapy has shown promise in treating solid organ tumors, and recently there has been growing interest in its role in meningiomas despite the challenges of their usually immunologically quiet microenvironment and low tumor mutational burden.<sup>258</sup> In a single-arm, open-label phase II trial (NCT03279692), patients with progressive CNS WHO grade 2 and 3 meningiomas were treated with pembrolizumab, a PD-1 inhibitor, which met primary endpoint and achieved a PFS of 48% at 6 months with a median PFS of 7.6 months.<sup>259</sup> In the same trial, 20% of patients experienced one or more grade-3 or higher adverse events associated with treatment. A trial of nivolumab monotherapy in similarly progressive high grade meningiomas failed to demonstrate improvement in PFS at 6 months (PFS-6 42.4%); however, two patients with high tumor mutational burden had increased immune cell proliferation and were long-term survivors.<sup>260</sup>

Thus far, more trials are needed to identify better systemic therapies for meningioma patients. Results from several published and completed clinical trials are summarized in **Table 3**. Given the lack of options for treatment-refractory meningiomas, additional agents are needed. The results from ongoing trials may highlight the importance of molecular classification on patient selection for targeted therapies as opposed to stratification based on WHO grade alone. There are several ongoing clinical immunotherapy trials on the use of nivolumab, ipilimumab, and avelumab (NCT03173950, NCT04659811, NCT03267836) for meningiomas and other CNS tumors, the results of which may yield interesting treatment insights for the future (**Table 4**).

## Quality of Life for Meningioma Patients

The impact of a meningioma diagnosis on patients is often underestimated and standardized methods and tools to assess health-related quality of life (HRQoL) in meningioma patients are still lacking. Many present with symptoms that can profoundly impair HRQoL such as seizures, motor and sensory deficits, cognitive impairment, cranial neuropathies, neuropsychiatric symptoms, and systemic symptoms such as fatigue.<sup>261,262</sup> Many of these symptoms may persist long after treatment, with some patients reporting considerable effects on HRQoL as long as 10 years after surgery.<sup>263</sup> Therefore, even if long-term tumor control is achieved, patients may require additional targeted interventions to help them return to their pre-morbid quality of life. Even surveillance imaging may be associated with significant anxiety and negative effects on HRQoL.

After surgery, patients with symptomatic meningiomas often experience a significant improvement in their symptoms and improved HRQoL in the short term. However, most demonstrate persistently reduced long-term HRQoL when compared to healthy controls.<sup>264-266</sup> Of note, achieving seizure control plays a significant role in improving HRQoL, whereas multiple surgical resections and the use of adjuvant RT are associated with reduced HRQoL scores, although these results may be confounded by tumor location and extent of resection. Other predictors of lower postoperative HRQoL include lower preoperative HRQoL, larger tumor size, skull base location, and the presence of peritumoral edema.<sup>267</sup> Fatigue is the most common symptom that has been reported to worsen in the post-treatment period following either surgery or radiosurgery.<sup>267,268</sup> Patients who receive RT may demonstrate improvement in some domains of HRQoL in the short term but may also experience delayed and progressive cognitive decline in the long term. Much of this data, however, is based on older RT treatment paradigms, with modern treatment plans likely to show more favorable long-term cognitive outcomes.<sup>266,269-271</sup> Increased patient support resources and counselling should be directed towards patients at high risk of persisting impairments in HRQoL both before and after treatment.<sup>268</sup>

There is currently a critical lack of a standardized, externally validated questionnaire targeting HRQoL for meningioma patients as well as specific interventions outside of standard tumor treatments designed to improve different HRQoL domains.<sup>266</sup> The correlation between quality of life and molecular subgroups also remains largely unexplored despite key differences in tumor behavior between these groups (e.g. *NF2*-wildtype tumours are more likely to grow in the skull base resulting in cranial nerve deficits whereas *NF2*-altered meningiomas are more common along the convexity and may be more commonly associated with seizures). Subgroup-specific quality of life metrics may provide an opportunity for further improvements in personalized and patient-centric care.

### Seizures in Meningioma Patients

Seizures are a common presenting symptom in patients with meningioma, occurring in up to 30% of cases preoperatively.<sup>272,273</sup> Risk factors associated with an increased seizure risk include recurrent disease, larger tumor size, non-skull base location, higher WHO grade, presence of peritumoral edema, and postoperative RT.<sup>4,274,275</sup> The presence of brain invasion and peritumoral edema are associated with neurotransmitter alterations, ionic channel changes, and blood-brain barrier disruption, all of which may contribute to development of a cortical epileptogenic focus.<sup>276-279</sup> One study found that *NF2*-mutated meningiomas had an increased risk of preoperative seizures but only when associated with atypical histology and peritumoral edema. They additionally found that mutations in genes of the Hedgehog signaling pathway (*SMO*, *PRKAR1A*, *SUFU*) in CNS WHO grade 1 meningiomas were associated with postoperative seizures.<sup>274</sup> Additional work is needed to ascertain whether specific molecular alterations can independently predict perioperative seizure risk or if the postoperative course is mainly affected by the anatomic location associated with meningiomas harboring *SMO*, *PRKAR1A*, or *SUFU* mutations.

The primary treatment for meningioma-related seizures is surgical resection, ideally GTR.<sup>280</sup> For patients for whom surgery or GTR may not be feasible, or for those whose seizures persist despite surgical resection, antiepileptic medications are often used following a similar treatment protocol as for idiopathic epilepsy. There are currently no recommendations regarding the first-line antiepileptic drug of choice for these patients, although levetiracetam is the most commonly prescribed option.<sup>280,281</sup> The optimal duration of perioperative antiepileptic therapy for meningioma patients with seizures is also highly variable and there are no current guidelines or level 1 evidence to support specific practices that are often institution or provider specific. In general, the literature supports continuing seizure medications postoperatively for 1-2 years before tapering off in the setting of ongoing seizure freedom.<sup>280,282,283</sup> The use of antiepileptic medication as prophylaxis is controversial but is generally not recommended given a lack of conclusive evidence demonstrating reduction in postoperative seizure risk.<sup>284,285</sup> Nevertheless, it may be considered in patients with one or more seizure risk factors such as significant peritumoral edema.<sup>272,286</sup> Furthermore, results from the ongoing multicentre, randomized controlled trial “STOP ‘EM” in the United Kingdom on prophylactic levetiracetam for seizure naïve meningioma patients may help inform changes in clinical practice.<sup>287</sup>

### **Meningiomas in Patients with NF2-Related Schwannomatosis**

Pathogenic germline alterations in the *NF2* gene, whether inherited or acquired (e.g. new germline variant), result in the development of the tumor predisposition syndrome neurofibromatosis type 2 or NF2-SWN.<sup>66</sup> NF2-SWN is a highly penetrant autosomal dominant condition with an incidence of 1 in 25 000 to 33 000.<sup>288-290</sup> While classically characterized by the development of bilateral vestibular schwannomas, 48-75% of patients with NF2-SWN will develop meningiomas at some point in their clinical course.<sup>291</sup> Comparatively, patients with NF2-SWN typically develop meningiomas at a younger

age and are at higher risk for developing multiple meningiomas.<sup>75,292</sup> Therefore, patients presenting with a meningioma at young age and/or multiple meningiomas should be screened for germline *NF2* and *SMARCE1* mutations. The majority of NF2-SWN-associated meningiomas are asymptomatic and often diagnosed during the work up for NF2-SWN or over the course of routine radiographic surveillance. When present, approximately 10% of these meningiomas will grow rapidly (defined as  $\geq 2$  cm<sup>3</sup>/year by one study) while the remainder will demonstrate no or very slow growth. New meningiomas will develop in 20% of patients.<sup>293-295</sup> Importantly, patients with NF2-SWN that have a meningioma may have a significantly increased risk of death.<sup>296</sup>

Given their complexity, management of patients with NF2-SWN by multidisciplinary teams at high volume centers has been demonstrated to improve both their quality of life and life expectancy.<sup>296</sup> The majority of NF2-SWN-associated meningiomas can be safely observed including those that demonstrate slow growth. Surgery remains the primary treatment for symptomatic or rapidly enlarging tumors, though its risks must be weighed against the anticipated risks of other operative procedures NF2-SWN patients may need to undergo for other tumors.<sup>296</sup> Maximizing extent of resection remains important but must be balanced against the risk of incurring a significant neurologic deficit.<sup>294</sup> Importantly, NF2-SWN-associated meningiomas that are resected tend to be more biologically aggressive than sporadic meningiomas (52% are WHO grades 2 or 3), though this may be confounded by a relative hesitancy to resect slow growing tumors in these patients.<sup>290,293</sup>

SRS has also been proposed as a viable treatment strategy for enlarging meningiomas in NF2-SWN patients with 5-year local control rates generally greater than 90%. However, distant failure rates ranged from 27-51%, and studies are limited to small institutional case series.<sup>297-300</sup> Additionally, malignant transformation remains a rare but important concern with SRS in this patient population with a significantly higher risk of malignant progression in previously benign tumors of NF2-SWN patients (up to 5-6% absolute risk increase) compared to patients with irradiated sporadic disease.<sup>301</sup> Furthermore,

the quality of life of NF2-SWN patients may be negatively impacted by the use of RT.<sup>270,302,303</sup> Therefore, radiotherapy should be used with caution in this patient population and reserved for recurrent meningiomas or those associated with unacceptable surgical risk.<sup>290</sup>

Given the challenges related to NF2-SWN associated tumors, several clinical trials have been undertaken to identify better treatment options. The AZD2014 trial in NF2-SWN patients with progressive or symptomatic meningiomas (NCT02831257) used a dual mTORC1/mTORC2 inhibitor but had 12 out of 18 patients withdraw due to adverse effects. The RAD001 trial (NCT01419639) was a phase II trial using everolimus, an mTOR inhibitor, as monotherapy for NF2-SWN patients which appeared to slow tumor growth but did not demonstrate any reduction in size. The phase II CEVOREM trial (NCT02333565) combined octreotide, a somatostatin analogue, with everolimus for the treatment of aggressive and otherwise treatment-refractory meningiomas, though only 4 of 20 patients had a germline *NF2* mutation. This trial demonstrated significant reduction in the median tumor growth rate at 3- and 6-months, with 4 patients withdrawing due to adverse effects.<sup>256</sup> A retrospective review also found slowing of meningioma growth with the EGFR/ErbB2 inhibitor lapatinib (NCT00973739) in 8 NF2-SWN patients with 17 tumors.<sup>304</sup> The phase II INTUITT-NF2 trial (NCT04374305) utilized brigatinib, a potent anaplastic lymphoma kinase inhibitor in combination with INK-128, a dual mTORC1/2 inhibitor for NF2-SWN associated tumors, with interim results of the brigatinib arm demonstrating radiographic response of 28% in meningiomas.<sup>305</sup> While some of these treatments show promise, additional prospective trials are needed before any systemic therapies become standard of care. Furthermore, translational studies incorporating radiography, molecular biomarkers (including non-invasive biomarkers), histopathology, and quality of life will be critical for improving treatment paradigms for NF2-SWN patients.

## Radiation-Induced Meningiomas

Exposure to ionizing radiation is a well-known risk factor for meningioma development. While RT improves the survival of many childhood cancers, some long-term survivors are left with secondary neoplasms as a consequence of their treatment, most commonly radiation-induced meningiomas (RIMs).<sup>306,307</sup> Other less common sources of exposure include low-dose RT for tinea capitis which was employed in the first half of the 20<sup>th</sup> century and survivors of the atomic bombs of World War 2.<sup>13,15,308,309</sup> The latency period between initial RT exposure and the development of RIMs typically varies between 10-40 years and may be inversely associated with the initial exposure dose.<sup>11,13,15,310</sup> Given that most RIMs in childhood cancer survivors are diagnosed 40 years after their initial treatment, imaging follow-up at fixed intervals, with more frequent follow-up for those who received high-intensity treatment may be warranted.<sup>306,307</sup>

RIMs are biologically and clinically distinct from their sporadic counterparts and while rare (making up only 1-2% of all meningiomas), they present a significant clinical challenge due to their increased biological aggressiveness, multiplicity, and resistance to standard therapies. They also have a much higher burden of cytogenetic changes compared to sporadic meningiomas including frequent losses of chromosomes 1p (over 50% of cases), 9p, 19q, 18q, 10p, and 22q.<sup>10,14,311</sup> Notably, RIMs were less frequently found to have loss of chromosome 22q or *NF2* point mutations compared to sporadic meningiomas but had more frequent *NF2* gene fusion events. These fusions are likely secondary to misrepair of RT-associated double-stranded DNA breaks, providing an alternative mechanism of *NF2* disruption. Non-*NF2* driver mutations including in *AKT1*, *SMO*, *TRAF7*, and *KLF4* were not observed in RIMs.<sup>10,41</sup>

Standard treatment guidelines for RIMs do not currently differ from sporadic meningiomas, with surgical resection as first line therapy for symptomatic cases. When multiple RIMs are present in the



same patient, surgery should target the largest and/or symptomatic tumors first. Otherwise, active surveillance remains a safe initial strategy for these tumors, with a low rate of neurological morbidity.<sup>312</sup> The role of adjuvant RT for RIMs is unclear but may be utilized in cases of subtotally resected meningiomas or those with higher WHO grade. However, even CNS WHO grade 1 RIMs can demonstrate aggressive behavior and many of these cases are RT-resistant. SRS appears to be safe and well tolerated for RIMs that are not amenable to resection or in patients with multiple RIMs. Overall, tumor control rates are lower for RIMs than for sporadic meningiomas, and larger treatment volume is associated with worse PFS.<sup>313-316</sup>

### Spinal Meningiomas

Although rarer than their intracranial counterparts (with an incidence of approximately 0.193-0.33 cases per 100 000), spinal meningiomas are the most common intradural spinal tumor, representing 25-45% of these cases.<sup>317-319</sup> CNS WHO grade 2 and 3 cases are also comparatively less common in the spine.<sup>318-320</sup> Spinal meningiomas appear to differ from intracranial meningiomas on a molecular basis as well and are generally more biologically benign.<sup>321-323</sup> A novel classification was recently proposed with two major subgroups: one with predominantly *NF2* mutations and the other with *AKT1* mutations (mutually exclusive to *NF2* mutations). While both subgroups were predominantly comprised of meningiomas from benign methylation subclasses, the *NF2*-mutated subgroup was associated with comparatively intermediate outcomes and more strongly associated with female sex, thoracic spine location, and frequent tumor calcification.<sup>109,321,322</sup> *AKT1*-mutated spinal meningiomas had no sex predilection and were associated with meningotheial subtype, cervical spine location, and absence of tumor calcification.<sup>321,322</sup> Interestingly, there was a small subset of spinal meningiomas with a much higher degree of cytogenetic changes that did not show a clear association with either of the

above subgroups and instead more closely resembled intermediate and malignant methylation subclasses of intracranial meningioma.<sup>322</sup> This suggests that as more clinically aggressive spinal meningiomas are profiled, additional molecular subgroups may be elucidated.

Treatment guidelines for spinal meningiomas are the same as for intracranial meningiomas, with gross total resection as the usual goal of surgery. In cases where a Simpson grade 1 resection (including dural resection with patch reconstruction) may not be feasible such as for tumors with a ventral origin, a Simpson grade 2 resection with extensive dural coagulation may have comparable outcomes.<sup>319,320,324</sup> Careful anatomic planning of surgical corridors may avoid the need for instrumentation in many of these cases.<sup>325</sup> The role of RT for spinal meningiomas is unclear, particularly given their largely benign behavior. A review of the National Cancer Database showed that only 2.5% of 10 458 patients with spinal meningiomas received radiotherapy. Older patients with higher WHO grade, larger tumors, and recurrent cases were more likely to receive RT. Interestingly, this study also reported an unexpected increase in mortality risk among borderline and malignant tumors that received RT following surgery compared to those that did not.<sup>326</sup> Further study is needed in order to fully resolve the role of adjuvant RT or primary stereotactic body radiation therapy (SBRT) for spinal meningiomas.<sup>327-329</sup>

### **Pediatric Meningiomas**

Unlike in adults, meningiomas are rare in the pediatric population and account for only 2.2-3.6% of all brain tumors in this group and 0.4-2.5% of all diagnosed meningiomas.<sup>330-334</sup> Also dissimilar to their adult counterparts, pediatric meningiomas affect males and females relatively equally with a greater incidence of tumors in an intraventricular and spinal location.<sup>333-335</sup> There is also a higher proportion of CNS WHO grade 2 and 3 meningiomas in pediatric patients compared to adults<sup>330,333,336</sup> and a larger proportion with clear cell (CNS WHO grade 2) or papillary (associated with CNS WHO grade 3)

histology.<sup>335-337</sup> However, grading is less predictive of overall outcome in these cases.<sup>330,333,338</sup> Patients under 3 years old or over 12 years old may have worse overall survival; the former group may be associated with higher operative morbidity and mortality while the latter have meningiomas that more closely resemble adult cases.<sup>330</sup> Pediatric patients with meningiomas are more likely to have NF2-SWN than adults and these cases have a much shorter time to progression and higher mortality rate compared to non-NF2-SWN cases.<sup>330,335</sup> Therefore, pediatric patients who are diagnosed with a meningioma should be screened for *NF2* mutations and other associated rare genetic conditions.<sup>339</sup> Spinal meningiomas are also more common in the pediatric population warranting the consideration of full craniospinal imaging at the time of diagnosis.<sup>332,333,335,340,341</sup>

As in adult cases, extent of resection appears to be the most important prognostic factor, with GTR conferring both a PFS and overall survival benefit.<sup>330,339,340</sup> The role of adjuvant RT is controversial, with insufficient literature to assess its utility. One meta-analysis showed no clear demonstrated benefit for PFS or OS, though there was likely a high selection bias for aggressive tumors.<sup>330</sup> Clinical decisions should be made with multidisciplinary discussion on a case-by-case basis, keeping in mind that cranial radiation is associated with significant morbidity in children. Some clinicians advocate for second-look surgery if residual tumor is detected on postoperative imaging though evidence to support this approach is not well established.<sup>332,342-344</sup>

Similar to adult meningiomas, *NF2* mutations and loss of chromosome 22 are the most common alterations in pediatric meningiomas, found in 47-72% of cases.<sup>336,341,345</sup> However, other classical non-*NF2* driver mutations such as *AKT1*, *SMO*, *KLF4*, and *TRAF7* have not been described in the pediatric population.<sup>336,341,346</sup> Various *YAP1*-fusions have been described in non-*NF2* altered pediatric meningiomas (*YAP1-MAML2*; *YAP1-PYGO1*; *YAP1-LMO1*) and have been proposed as an alternative oncogenic driver to *NF2* inactivation.<sup>347,348</sup> Preclinical studies have shown that the YAP component of

these gene fusions is likely the critical driver of these tumors and the *YAP1-MAML2* fusion may be targetable through pharmacologic disruption of the YAP1-TEAD interaction.<sup>348</sup>

The majority of clear cell meningiomas in this population expectedly harbour *SMARCE1* mutations.<sup>47,49-51</sup> DNA methylation profiling largely segregates pediatric meningioma cases from adult cases and may further separate them into three methylation subgroups: one comprised almost exclusively of *SMARCE1*-mutated clear cell meningiomas, one driven by *NF2* or chromosome 22q loss, and one mixed group containing all cases with rhabdoid histology, allelic loss of chromosome 11 and rare loss of chromosome 22.<sup>336</sup> The prognostic significance of these groups remain uncertain given the rarity of cases with both molecular profiling and annotated clinical data.

### **Preclinical Models of Meningioma**

Historically, there has been a paucity of cell models for meningiomas due to the slow growth rates of most primary cell lines and the tendency of most cell lines to senesce after several passages. More recently though, there have been increased efforts by laboratories worldwide to optimize primary meningioma cell cultures to better study the functional impact of specific genomic alterations and create higher fidelity preclinical models.<sup>349,350</sup> IOMM-Lee is an established meningioma cell line derived from an intraosseous CNS WHO grade 3 meningioma that is still commonly utilized due to its ability to readily form heterotopic and orthotopic xenografts.<sup>351-353</sup> Although it harbors *CDKN2A/B* loss as a hallmark of proliferation in addition to a high burden of copy number changes, it lacks the biallelic *NF2* inactivation seen in the majority of biologically aggressive meningiomas and also contains unusual chromosomal gains of 3q, 5, and 9 that are not commonly found in meningiomas. The NCH93 meningioma cell line is similarly derived from a CNS WHO grade 3 meningioma, but unlike IOMM-Lee, contains an *NF2* frameshift mutation making it a potentially more serviceable aggressive *NF2*-mutant

meningioma model that also reliably forms xenografts.<sup>354,355</sup> KT21-MG1 is another aggressive meningioma cell line established from a human malignant meningioma that demonstrates *c-myc* amplification and monosomy of chromosome 22, with the ability to produce xenografts in nude mice.<sup>116,356,357</sup> Similarly, MN3 is another serially transplantable orthotopic cell model derived from a recurrent malignant meningioma which can also produce xenografts in nude mice and harbors several pathological hallmarks of aggressive meningioma including elevated Ki-67, vimentin expression, and *NF2* inactivation.<sup>358</sup>

One of the first benign meningioma cell lines, Ben-Men-1, was derived from a WHO grade 1 meningioma by transducing tumor cells with the human *TERT* gene to overcome cellular senescence. However, while Ben-Men-1 proliferated rapidly in vitro, orthotopic xenografts using this cell line grew slowly, making it suboptimal for testing therapeutic agents.<sup>359</sup> Furthermore, introducing alterations such as the human *TERT* gene or disruption of p53 and pRb pathways necessary to immortalize meningioma cell lines may also alter how closely these cell lines recapitulate their tumor of origin.<sup>360</sup>

To date, orthotopic xenograft models have been the gold standard for evaluating treatment efficacy in vivo, with tumor volumes readily evaluable by MRI or bioluminescence.<sup>361,362</sup> However, these models are limited by the requirement for immunodeficient mice as hosts, which may be missing important immune cell populations for the study of tumor microenvironment interactions. Genetically engineered mouse models have attempted to overcome this shortcoming and different groups have leveraged conditional homozygous *NF2* knockout models, with and without *CDKN2A/B* loss or *SMO* activation, amongst other models. However, most of these models are hindered by similar limitations of prolonged tumor formation time, reduced animal survival due to secondary malignancies, low rates of induction, and complex time- and resource-intensive methodologies.<sup>363,364</sup>

Recently, two other novel ex-vivo meningioma models have gained popularity: organotypic tumor slices and patient-derived spherical cell culture models (which include spheroids and organoids), both of which represent patient-derived 3D tumor models that closely recapitulate the genetic and epigenetic alterations of its parent tumor while also preserving cell type heterogeneity including immune and endothelial cells. While the former method enables meningioma tumor to remain in its original structure and within its native microenvironment, it requires larger amounts of intact tissue that cannot be damaged during sectioning and must account for the potential confounding of intratumoral heterogeneity within and between slices, making this technique challenging to standardize.<sup>365,366</sup> Meningioma organoids, however, can be established from smaller amounts of tissue and can be readily multiplexed in order to perform rapid drug screening and other molecular assays such as DNA- or RNA-sequencing, flow cytometry, and immunohistochemistry.<sup>367-370</sup> They also successfully establish in 60-100% of cases. Moreover, meningioma organoids and spheroids tend to express tumor markers such as progesterone receptor, more closely mimic the cell proliferation rate of human meningiomas than two-dimensional cultures, and may have increased transcriptomic markers for the epithelial-to-mesenchymal transition compared to traditional monolayer cultures.<sup>371,372</sup> Variants identified in meningioma organoids such as *NF2* or *TRAF7* alterations are found at similar allele frequencies to their parental tumors, and the CNV profiles of the organoids also closely resemble those of the original tumor.<sup>373</sup> The intratumoral heterogeneity and tumor microenvironment of the parental meningioma can also be recapitulated in organoid models, including retainment of immune cells (CD68+ macrophages, CD3+ T cells) and specific neoplastic cell subpopulations.<sup>368</sup> Importantly, for organoids or spheroids, specific cell culture conditions need to be established in order to maintain tumor microenvironment cells over time. While these innovations are promising, additional studies are needed to better characterize both existing and novel preclinical meningioma models to assess their capability to guide treatment decisions for patients in the future.

## Future clinical trial design and other future directions

Meningioma clinical trials face several challenges related largely to tumor heterogeneity. One issue is that despite a growing body of evidence demonstrating the superiority of molecular classification systems compared to histopathology, there has yet to be a unified schematic that can be readily adopted by the WHO. The ideal classification should have a strong biological foundation and be readily implementable in most pathology laboratories. This standardization will ensure that patients are grouped based on clinically meaningful biological criteria that may overcome the interrater reliability issues implicit in histopathologic analysis. Immunohistochemical correlates that can reliably identify molecular group on a one-to-one basis would also be helpful, particularly in expanding trial access beyond tertiary referral centers and high-income countries. These measures may ultimately improve the homogeneity of trial arms and decrease biologic heterogeneity, particularly amongst CNS WHO grade 2 cases.

In addition to classification, standardization of outcomes reporting is crucial to develop clinically meaningful trials for meningiomas.<sup>151,374</sup> For instance, while PFS-6 has been considered the primary endpoint in most meningioma trials, the control benchmarks are largely based on historical cases which may be graded differently today. To account for this, there is a need retrospectively determine PFS-6 amongst molecularly defined meningioma cohorts, which would contribute to establishing a set of modern control cases for future prospective trial cases, which will likely also be molecularly driven, to benchmark against. Additionally, the relative improvement in PFS-6 that can be considered clinically meaningful should be standardized and these criteria will require subsequent validation. Lastly, as suggested by the RANO group, if PFS is to be used as the primary endpoint, neuroimaging over the last 6-12 months prior to trial enrolment is critical to establish a baseline rate of growth for comparison.<sup>141</sup>

Defining the appropriate interval and type of surveillance needed for each meningioma subgroup will also enable clinicians to detect tumor progression or recurrence at an early stage, leading to timely interventions and improved outcomes. Given the poor reliability of historic benchmarks such as PFS-6, ideally randomized trials should be conducted whenever possible. Additionally, the implementation of adaptive clinical trial designs, which allow for real-time adjustments based on novel data, could enhance the efficiency of clinical trials and accelerate the identification of novel treatments. Addressing these challenges through collaborative efforts among researchers, clinicians, and regulatory bodies will pave the way for more robust meningioma clinical trials, enhancing the precision and impact of future treatments.

## Summary

Meningiomas are the most common primary intracranial tumors, and recent years have witnessed an increasing number of important discoveries that have shed light into their molecular underpinnings and heterogeneity. Nevertheless, some unique groups of patients including those with *NF2*-associated schwannomatosis, radiation-induced meningiomas, and pediatric patients with meningiomas have been largely excluded from contemporary molecular studies. Furthermore, lack of access to sequencing resources and a relative dearth of high-fidelity preclinical models have also contributed to slower translation of encouraging findings to routine clinical implementation. While surgery and radiotherapy remain the only current standard of care options for patients, several promising systemic therapies have demonstrated evidence of potential efficacy in progressive or recurrent meningiomas and several important clinical trials are ongoing. Molecular profiling of meningiomas from these clinical trial cases including both responders and non-responders to systemic therapies may uncover novel insights that can be leveraged in future studies. Additionally, in this current



molecular era of meningioma research, there is a need to unify the many classification models that have been discovered. Achieving this will require a data-driven approach and consensus amongst experts in the field, including cooperation amongst those who originally developed these classification systems. This remains a high priority goal of the cIMPACT-NOW working group and consortia such as ICOM and KAM. Implementation of a standardized molecular taxonomy for these tumors will ultimately serve as an important benchmark for future discovery and clinical trial design as well as have a significant impact on patient care.

Accepted Manuscript

## References

1. Ostrom QT, Price M, Neff C, et al. CBTRUS Statistical Report: Primary Brain and Other Central Nervous System Tumors Diagnosed in the United States in 2016—2020. *Neuro-Oncology*. 2023; 25(Supplement\_4):iv1-iv99.
2. Louis DN, Perry A, Wesseling P, et al. The 2021 WHO Classification of Tumors of the Central Nervous System: a summary. *Neuro Oncol*. 2021; 23(8):1231-1251.
3. Walsh KM, Price M, Neff C, et al. The joint impacts of sex and race/ethnicity on incidence of grade 1 versus grades 2-3 meningioma across the lifespan. *Neurooncol Adv*. 2023; 5(Suppl 1):i5-i12.
4. Maier AD, Mirian C, Haslund-Vinding J, et al. Granular clinical history and outcome in 51 patients with primary and secondary malignant meningioma. *J Neurosurg*. 2022:1-11.
5. Tosefsky K, Rebchuk AD, Wang JZ, et al. Grade 3 meningioma survival and recurrence outcomes in an international multicenter cohort. *J Neurosurg*. 2023:1-11.
6. Kshetry VR, Hsieh JK, Ostrom QT, Kruchko C, Benzel EC, Barnholtz-Sloan JS. Descriptive Epidemiology of Spinal Meningiomas in the United States. *Spine (Phila Pa 1976)*. 2015; 40(15):E886-889.
7. Claus EB, Cornish AJ, Broderick P, et al. Genome-wide association analysis identifies a meningioma risk locus at 11p15.5. *Neuro Oncol*. 2018; 20(11):1485-1493.
8. Dobbins SE, Broderick P, Melin B, et al. Common variation at 10p12.31 near MLLT10 influences meningioma risk. *Nat Genet*. 2011; 43(9):825-827.
9. Walsh KM, Zhang C, Calvocoressi L, et al. Pleiotropic MLLT10 variation confers risk of meningioma and estrogen-mediated cancers. *Neurooncol Adv*. 2022; 4(1):vdac044.
10. Agnihotri S, Suppiah S, Tonge PD, et al. Therapeutic radiation for childhood cancer drives structural aberrations of NF2 in meningiomas. *Nat Commun*. 2017; 8(1):186.
11. Al-Mefty O, Topsakal C, Pravdenkova S, Sawyer JR, Harrison MJ. Radiation-induced meningiomas: clinical, pathological, cytokinetic, and cytogenetic characteristics. *J Neurosurg*. 2004; 100(6):1002-1013.
12. Yamanaka R, Hayano A, Kanayama T. Radiation-Induced Meningiomas: An Exhaustive Review of the Literature. *World Neurosurg*. 2017; 97:635-644.e638.
13. Wang JZ, Agnihotri S, Zadeh G. Radiation-Induced Meningiomas. *Adv Exp Med Biol*. 2023; 1416:159-173.
14. Shoshan Y, Chernova O, Jeun S-S, et al. Radiation-induced meningioma: a distinct molecular genetic pattern? *Journal of Neuropathology & Experimental Neurology*. 2000; 59(7):614-620.
15. Umansky F, Shoshan Y, Rosenthal G, Fraifeld S, Spektor S. Radiation-induced meningioma. *Neurosurg Focus*. 2008; 24(5):E7.
16. Schildkraut JM, Calvocoressi L, Wang F, et al. Endogenous and exogenous hormone exposure and the risk of meningioma in men. *J Neurosurg*. 2014; 120(4):820-826.
17. Claus EB, Calvocoressi L, Bondy ML, Wrensch M, Wiemels JL, Schildkraut JM. Exogenous hormone use, reproductive factors, and risk of intracranial meningioma in females. *J Neurosurg*. 2013; 118(3):649-656.

18. Claus EB, Walsh KM, Calvocoressi L, et al. Cigarette smoking and risk of meningioma: the effect of gender. *Cancer Epidemiol Biomarkers Prev.* 2012; 21(6):943-950.
19. Taylor AJ, Little MP, Winter DL, et al. Population-Based Risks of CNS Tumors in Survivors of Childhood Cancer: The British Childhood Cancer Survivor Study. *Journal of Clinical Oncology.* 2010; 28(36):5287-5293.
20. Withrow DR, Anderson H, Armstrong GT, et al. Pooled Analysis of Meningioma Risk Following Treatment for Childhood Cancer. *JAMA Oncology.* 2022; 8(12):1756-1764.
21. Blitshteyn S, Crook JE, Jaeckle KA. Is There an Association Between Meningioma and Hormone Replacement Therapy? *Journal of Clinical Oncology.* 2008; 26(2):279-282.
22. Schlehofer B, Blettner M, Wahrendorf J. Association between brain tumors and menopausal status. *JNCI: Journal of the National Cancer Institute.* 1992; 84(17):1346-1349.
23. Ryan P, Lee MW, North JB, McMichael AJ. Risk factors for tumors of the brain and meninges: results from the Adelaide Adult Brain Tumor Study. *International journal of cancer.* 1992; 51(1):20-27.
24. Jhawar BS, Fuchs CS, Colditz GA, Stampfer MJ. Sex steroid hormone exposures and risk for meningioma. *Journal of neurosurgery.* 2003; 99(5):848-853.
25. Wigertz A, Lönn S, Mathiesen T, Ahlbom A, Hall P, Feychting M. Risk of brain tumors associated with exposure to exogenous female sex hormones. *American journal of epidemiology.* 2006; 164(7):629-636.
26. Hatch EE, Linet MS, Zhang J, et al. Reproductive and hormonal factors and risk of brain tumors in adult females. *International journal of cancer.* 2005; 114(5):797-805.
27. Custer B, Longstreth W, Phillips LE, Koepsell TD, Van Belle G. Hormonal exposures and the risk of intracranial meningioma in women: a population-based case-control study. *BMC cancer.* 2006; 6(1):1-9.
28. Lee E, Grutsch J, Persky V, Glick R, Mendes J, Davis F. Association of meningioma with reproductive factors. *International journal of cancer.* 2006; 119(5):1152-1157.
29. Weill A, Nguyen P, Labidi M, et al. Use of high dose cyproterone acetate and risk of intracranial meningioma in women: cohort study. *Bmj.* 2021; 372:n37.
30. Pettersson-Segerlind J, Mathiesen T, Elmi-Terander A, et al. The risk of developing a meningioma during and after pregnancy. *Sci Rep.* 2021; 11(1):9153.
31. Laviv Y, Ohla V, Kasper EM. Unique features of pregnancy-related meningiomas: lessons learned from 148 reported cases and theoretical implications of a prolactin modulated pathogenesis. *Neurosurg Rev.* 2018; 41(1):95-108.
32. Lulis EA, Scheithauer BW, Yachnis AT, et al. Meningiomas in pregnancy: a clinicopathologic study of 17 cases. *Neurosurgery.* 2012; 71(5):951-961.
33. Li W, You L, Cooper J, et al. Merlin/NF2 suppresses tumorigenesis by inhibiting the E3 ubiquitin ligase CRL4(DCAF1) in the nucleus. *Cell.* 2010; 140(4):477-490.
34. Xiao GH, Chernoff J, Testa JR. NF2: the wizardry of merlin. *Genes Chromosomes Cancer.* 2003; 38(4):389-399.
35. Bachir S, Shah S, Shapiro S, et al. Neurofibromatosis Type 2 (NF2) and the Implications for Vestibular Schwannoma and Meningioma Pathogenesis. *Int J Mol Sci.* 2021; 22(2).
36. Baia GS, Caballero OL, Orr BA, et al. Yes-associated protein 1 is activated and functions as an oncogene in meningiomas. *Mol Cancer Res.* 2012; 10(7):904-913.

37. Choudhury A, Magill ST, Eaton CD, et al. Meningioma DNA methylation groups identify biological drivers and therapeutic vulnerabilities. *Nat Genet.* 2022; 54(5):649-659.
38. Williams EA, Santagata S, Wakimoto H, et al. Distinct genomic subclasses of high-grade/progressive meningiomas: NF2-associated, NF2-exclusive, and NF2-agnostic. *Acta Neuropathol Commun.* 2020; 8(1):171.
39. Clark VE, Erson-Omay EZ, Serin A, et al. Genomic analysis of non-NF2 meningiomas reveals mutations in TRAF7, KLF4, AKT1, and SMO. *Science.* 2013; 339(6123):1077-1080.
40. Clark VE, Harmanlı AS, Bai H, et al. Recurrent somatic mutations in POLR2A define a distinct subset of meningiomas. *Nature genetics.* 2016; 48(10):1253-1259.
41. Brastianos PK, Horowitz PM, Santagata S, et al. Genomic sequencing of meningiomas identifies oncogenic SMO and AKT1 mutations. *Nature genetics.* 2013; 45(3):285-289.
42. Abedalthagafi M, Bi WL, Aizer AA, et al. Oncogenic PI3K mutations are as common as AKT1 and SMO mutations in meningioma. *Neuro Oncol.* 2016; 18(5):649-655.
43. Bujko M, Kober P, Tysarowski A, et al. EGFR, PIK3CA, KRAS and BRAF mutations in meningiomas. *Oncol Lett.* 2014; 7(6):2019-2022.
44. Zadeh G, Karimi S, Aldape KD. PIK3CA mutations in meningioma. *Neuro Oncol.* 2016; 18(5):603-604.
45. Youngblood MW, Duran D, Montejó JD, et al. Correlations between genomic subgroup and clinical features in a cohort of more than 3000 meningiomas. *J Neurosurg.* 2019:1-10.
46. Boetto J, Plu I, Ducos Y, et al. Normal meninges harbor oncogenic somatic mutations in meningioma-driver genes. *Acta Neuropathol.* 2023; 146(6):833-835.
47. Evans LT, Van Hoff J, Hickey WF, et al. SMARCE1 mutations in pediatric clear cell meningioma: case report. *Journal of Neurosurgery: Pediatrics.* 2015; 16(3):296-300.
48. Gerkes E, Fock J, den Dunnen W, et al. A heritable form of SMARCE1-related meningiomas with important implications for follow-up and family screening. *Neurogenetics.* 2016; 17(2):83-89.
49. Tauziède-Espariat A, Parfait B, Besnard A, et al. Loss of SMARCE1 expression is a specific diagnostic marker of clear cell meningioma: a comprehensive immunophenotypical and molecular analysis. *Brain Pathology.* 2018; 28(4):466-474.
50. St. Pierre R, Collings CK, Samé Guerra DD, et al. SMARCE1 deficiency generates a targetable mSWI/SNF dependency in clear cell meningioma. *Nature Genetics.* 2022; 54(6):861-873.
51. Sievers P, Sill M, Blume C, et al. Clear cell meningiomas are defined by a highly distinct DNA methylation profile and mutations in SMARCE1. *Acta Neuropathol.* 2021; 141(2):281-290.
52. Landry AP, Wang JZ, Nassiri F, Patil V, Gao A, Zadeh G. BAP1-deficient meningioma presenting with trabecular architecture and cytokeratin expression: a report of two cases and review of the literature. *J Clin Pathol.* 2021.
53. Shankar GM, Santagata S. BAP1 mutations in high-grade meningioma: implications for patient care. *Neuro-oncology.* 2017; 19(11):1447-1456.
54. Williams EA, Wakimoto H, Shankar GM, et al. Frequent inactivating mutations of the PBAF complex gene PBRM1 in meningioma with papillary features. *Acta Neuropathol.* 2020; 140(1):89-93.

55. Mirian C, Duun-Henriksen AK, Juratli T, et al. Poor prognosis associated with TERT gene alterations in meningioma is independent of the WHO classification: an individual patient data meta-analysis. *J Neurol Neurosurg Psychiatry*. 2020; 91(4):378-387.
56. Sahm F, Schimpf D, Olar A, et al. TERT promoter mutations and risk of recurrence in meningioma. *Journal of the National Cancer Institute*. 2016; 108(5):djv377.
57. Chiba K, Lorbeer FK, Shain AH, et al. Mutations in the promoter of the telomerase gene TERT contribute to tumorigenesis by a two-step mechanism. *Science*. 2017; 357(6358):1416-1420.
58. Spiegl-Kreinecker S, Lötsch D, Neumayer K, et al. TERT promoter mutations are associated with poor prognosis and cell immortalization in meningioma. *Neuro-oncology*. 2018; 20(12):1584-1593.
59. Abedalthagafi MS, Bi WL, Merrill PH, et al. ARID1A and TERT promoter mutations in dedifferentiated meningioma. *Cancer genetics*. 2015; 208(6):345-350.
60. Chaluts D, Dullea JT, Ali M, et al. ARID1A mutation associated with recurrence and shorter progression-free survival in atypical meningiomas. *J Cancer Res Clin Oncol*. 2023; 149(8):5165-5172.
61. Gill CM, Loewenstern J, Rutland JW, et al. SWI/SNF chromatin remodeling complex alterations in meningioma. *J Cancer Res Clin Oncol*. 2021; 147(11):3431-3440.
62. Kerr K, Qualmann K, Esquenazi Y, Hagan J, Kim DH. Familial Syndromes Involving Meningiomas Provide Mechanistic Insight Into Sporadic Disease. *Neurosurgery*. 2018; 83(6):1107-1118.
63. Pain M, Darbinyan A, Fowkes M, Shrivastava R. Multiple Meningiomas in a Patient with Cowden Syndrome. *J Neurol Surg Rep*. 2016; 77(3):e128-133.
64. Nassiri F, Liu J, Patil V, et al. A clinically applicable integrative molecular classification of meningiomas. *Nature*. 2021; 597(7874):119-125.
65. Evans DG. Neurofibromatosis type 2 (NF2): a clinical and molecular review. *Orphanet J Rare Dis*. 2009; 4:16.
66. Plotkin SR, Messiaen L, Legius E, et al. Updated diagnostic criteria and nomenclature for neurofibromatosis type 2 and schwannomatosis: An international consensus recommendation. *Genet Med*. 2022; 24(9):1967-1977.
67. Merker VL, Esparza S, Smith MJ, Stemmer-Rachamimov A, Plotkin SR. Clinical features of schwannomatosis: a retrospective analysis of 87 patients. *Oncologist*. 2012; 17(10):1317-1322.
68. Smith MJ, Wallace AJ, Bennett C, et al. Germline SMARCE1 mutations predispose to both spinal and cranial clear cell meningiomas. *J Pathol*. 2014; 234(4):436-440.
69. Smith MJ, O'Sullivan J, Bhaskar SS, et al. Loss-of-function mutations in SMARCE1 cause an inherited disorder of multiple spinal meningiomas. *Nature genetics*. 2013; 45(3):295-298.
70. Prasad RN, Gardner UG, Yaney A, et al. Germline BAP1 Mutation in a Family With Multi-Generational Meningioma With Rhabdoid Features: A Case Series and Literature Review. *Front Oncol*. 2021; 11:721712.
71. Shankar GM, Abedalthagafi M, Vaubel RA, et al. Germline and somatic BAP1 mutations in high-grade rhabdoid meningiomas. *Neuro Oncol*. 2017; 19(4):535-545.

72. Biczok A, Thorsteinsdottir J, Karschnia P, et al. Mutational signature of extracranial meningioma metastases and their respective primary tumors. *Acta Neuropathol Commun.* 2023; 11(1):12.
73. Carbone M, Ferris LK, Baumann F, et al. BAP1 cancer syndrome: malignant mesothelioma, uveal and cutaneous melanoma, and MBAITs. *J Transl Med.* 2012; 10:179.
74. Aavikko M, Li S-P, Saarinen S, et al. Loss of SUFU function in familial multiple meningioma. *The American Journal of Human Genetics.* 2012; 91(3):520-526.
75. Pathmanaban ON, Sadler KV, Kamaly-Asl ID, et al. Association of Genetic Predisposition With Solitary Schwannoma or Meningioma in Children and Young Adults. *JAMA Neurol.* 2017; 74(9):1123-1129.
76. Smith MJ, Beetz C, Williams SG, et al. Germline mutations in SUFU cause Gorlin syndrome-associated childhood medulloblastoma and redefine the risk associated with PTCH1 mutations. *J Clin Oncol.* 2014; 32(36):4155-4161.
77. Oshima J, Martin GM, Hisama FM. Werner Syndrome. In: Adam MP, Feldman J, Mirzaa GM, et al., eds. *GeneReviews*(®). Seattle (WA): University of Washington, Seattle Copyright © 1993-2024, University of Washington, Seattle. GeneReviews is a registered trademark of the University of Washington, Seattle. All rights reserved.; 1993.
78. Fujii K, Miyashita T. Gorlin syndrome (nevoid basal cell carcinoma syndrome): update and literature review. *Pediatr Int.* 2014; 56(5):667-674.
79. Farooq A, Walker LJ, Bowling J, Audisio RA. Cowden syndrome. *Cancer Treat Rev.* 2010; 36(8):577-583.
80. Lindblom A, Rutledge M, Collins VP, Nordenskjöld M, Dumanski JP. Chromosomal deletions in anaplastic meningiomas suggest multiple regions outside chromosome 22 as important in tumor progression. *Int J Cancer.* 1994; 56(3):354-357.
81. Sulman EP, Dumanski JP, White PS, et al. Identification of a consistent region of allelic loss on 1p32 in meningiomas: correlation with increased morbidity. *Cancer Res.* 1998; 58(15):3226-3230.
82. Cai DX, Banerjee R, Scheithauer BW, Lohse CM, Kleinschmidt-Demasters BK, Perry A. Chromosome 1p and 14q FISH analysis in clinicopathologic subsets of meningioma: diagnostic and prognostic implications. *Journal of Neuropathology & Experimental Neurology.* 2001; 60(6):628-636.
83. Espinosa AB, Taberner MD, Maíllo A, et al. The cytogenetic relationship between primary and recurrent meningiomas points to the need for new treatment strategies in cases at high risk of relapse. *Clin Cancer Res.* 2006; 12(3 Pt 1):772-780.
84. Maíllo A, Orfao A, Sayagues JM, et al. New classification scheme for the prognostic stratification of meningioma on the basis of chromosome 14 abnormalities, patient age, and tumor histopathology. *J Clin Oncol.* 2003; 21(17):3285-3295.
85. Ketter R, Rahnenführer J, Henn W, et al. Correspondence of tumor localization with tumor recurrence and cytogenetic progression in meningiomas. *Neurosurgery.* 2008; 62(1):61-69; discussion 69-70.
86. Ketter R, Urbschat S, Henn W, et al. Application of oncogenetic trees mixtures as a biostatistical model of the clonal cytogenetic evolution of meningiomas. *Int J Cancer.* 2007; 121(7):1473-1480.

87. Sulman EP, White PS, Brodeur GM. Genomic annotation of the meningioma tumor suppressor locus on chromosome 1p34. *Oncogene*. 2004; 23(4):1014-1020.
88. Choy W, Kim W, Nagasawa D, et al. The molecular genetics and tumor pathogenesis of meningiomas and the future directions of meningioma treatments. *Neurosurgical focus*. 2011; 30(5):E6.
89. Bi WL, Greenwald NF, Abedalthagafi M, et al. Genomic landscape of high-grade meningiomas. *NPJ genomic medicine*. 2017; 2(1):1-14.
90. Lee Y, Liu J, Patel S, et al. Genomic landscape of meningiomas. *Brain Pathology*. 2010; 20(4):751-762.
91. Bi WL, Abedalthagafi M, Horowitz P, et al. Genomic landscape of intracranial meningiomas. *J Neurosurg*. 2016; 125(3):525-535.
92. Driver J, Hoffman SE, Tavakol S, et al. A Molecularly Integrated Grade for Meningioma. *Neuro Oncol*. 2021.
93. Maas SLN, Stichel D, Hielscher T, et al. Integrated Molecular-Morphologic Meningioma Classification: A Multicenter Retrospective Analysis, Retrospectively and Prospectively Validated. *J Clin Oncol*. 2021; 39(34):3839-3852.
94. Urbschat S, Rahnenführer J, Henn W, et al. Clonal cytogenetic progression within intratumorally heterogeneous meningiomas predicts tumor recurrence. *Int J Oncol*. 2011; 39(6):1601-1608.
95. Youngblood MW, Erson-Omay Z, Li C, et al. Super-enhancer hijacking drives ectopic expression of hedgehog pathway ligands in meningiomas. *Nature Communications*. 2023; 14(1):6279.
96. Boström J, Meyer-Puttlitz B, Wolter M, et al. Alterations of the tumor suppressor genes CDKN2A (p16(INK4a)), p14(ARF), CDKN2B (p15(INK4b)), and CDKN2C (p18(INK4c)) in atypical and anaplastic meningiomas. *Am J Pathol*. 2001; 159(2):661-669.
97. Zhao R, Choi BY, Lee MH, Bode AM, Dong Z. Implications of Genetic and Epigenetic Alterations of CDKN2A (p16(INK4a)) in Cancer. *EBioMedicine*. 2016; 8:30-39.
98. Wang JZ, Patil V, Liu J, et al. Increased mRNA expression of CDKN2A is a transcriptomic marker of clinically aggressive meningiomas. *Acta Neuropathol*. 2023; 146(1):145-162.
99. Khan AB, English CW, Chen WC, et al. Even heterozygous loss of CDKN2A/B greatly accelerates recurrence in aggressive meningioma. *Acta Neuropathol*. 2023; 145(4):501-503.
100. Perry A, Banerjee R, Lohse CM, Kleinschmidt-DeMasters BK, Scheithauer BW. A role for chromosome 9p21 deletions in the malignant progression of meningiomas and the prognosis of anaplastic meningiomas. *Brain Pathol*. 2002; 12(2):183-190.
101. Sievers P, Hielscher T, Schimpf D, et al. CDKN2A/B homozygous deletion is associated with early recurrence in meningiomas. *Acta Neuropathol*. 2020; 140(3):409-413.
102. Torp SH, Solheim O, Skjulsvik AJ. The WHO 2021 Classification of Central Nervous System tumours: a practical update on what neurosurgeons need to know-a minireview. *Acta Neurochir (Wien)*. 2022; 164(9):2453-2464.
103. Brokinkel B, Hess K, Mawrin C. Brain invasion in meningiomas-clinical considerations and impact of neuropathological evaluation: a systematic review. *Neuro Oncol*. 2017; 19(10):1298-1307.

104. Rebchuk AD, Chaharyn BM, Alam A, et al. The impact of brain invasion criteria on the incidence and distribution of WHO grade 1, 2, and 3 meningiomas. *Neuro-Oncology*. 2022; 24(9):1524-1532.
105. Li HY, Ying YZ, Zheng D, et al. Is brain invasion sufficient as a stand-alone criterion for grading atypical meningioma? *J Neurosurg*. 2023; 139(4):953-964.
106. von Spreckelsen N, Kessler C, Brokinkel B, Goldbrunner R, Perry A, Mawrin C. Molecular neuropathology of brain-invasive meningiomas. *Brain Pathol*. 2022; 32(2):e13048.
107. Behling F, Fodi C, Gepfner-Tuma I, et al. CNS Invasion in Meningioma-How the Intraoperative Assessment Can Improve the Prognostic Evaluation of Tumor Recurrence. *Cancers (Basel)*. 2020; 12(12).
108. Behling F, Hempel JM, Schittenhelm J. Brain Invasion in Meningioma-A Prognostic Potential Worth Exploring. *Cancers (Basel)*. 2021; 13(13).
109. Sahm F, Schimpf D, Stichel D, et al. DNA methylation-based classification and grading system for meningioma: a multicentre, retrospective analysis. *The lancet oncology*. 2017; 18(5):682-694.
110. Olar A, Wani KM, Wilson CD, et al. Global epigenetic profiling identifies methylation subgroups associated with recurrence-free survival in meningioma. *Acta Neuropathol*. 2017; 133(3):431-444.
111. Nassiri F, Mamatjan Y, Suppiah S, et al. DNA methylation profiling to predict recurrence risk in meningioma: development and validation of a nomogram to optimize clinical management. *Neuro-oncology*. 2019; 21(7):901-910.
112. Vasudevan HN, Braunstein SE, Phillips JJ, et al. Comprehensive Molecular Profiling Identifies FOXM1 as a Key Transcription Factor for Meningioma Proliferation. *Cell Rep*. 2018; 22(13):3672-3683.
113. Kim H, Park KJ, Ryu BK, et al. Forkhead box M1 (FOXM1) transcription factor is a key oncogenic driver of aggressive human meningioma progression. *Neuropathol Appl Neurobiol*. 2020; 46(2):125-141.
114. Patel AJ, Wan YW, Al-Ouran R, et al. Molecular profiling predicts meningioma recurrence and reveals loss of DREAM complex repression in aggressive tumors. *Proc Natl Acad Sci U S A*. 2019; 116(43):21715-21726.
115. Parada CA, Osbun J, Kaur S, et al. Kinome and phosphoproteome of high-grade meningiomas reveal AKAP12 as a central regulator of aggressiveness and its possible role in progression. *Sci Rep*. 2018; 8(1):2098.
116. Tanaka K, Sato C, Maeda Y, et al. Establishment of a human malignant meningioma cell line with amplified c-myc oncogene. *Cancer*. 1989; 64(11):2243-2249.
117. Choudhury A, Chen WC, Lucas CG, et al. Hypermitotic meningiomas harbor DNA methylation subgroups with distinct biological and clinical features. *Neuro Oncol*. 2022.
118. Bayley JCT, Hadley CC, Harmanci AO, Harmanci AS, Klisch TJ, Patel AJ. Multiple approaches converge on three biological subtypes of meningioma and extract new insights from published studies. *Sci Adv*. 2022; 8(5):eabm6247.
119. Hielscher T, Sill M, Sievers P, et al. Clinical implementation of integrated molecular-morphologic risk prediction for meningioma. *Brain Pathol*. 2022:e13132.



120. Maier AD, Meddis A, Mirian C, et al. Gene expression analysis during progression of malignant meningioma compared to benign meningioma. *J Neurosurg.* 2023; 138(5):1302-1312.
121. San-Miguel T, Megías J, Monleón D, et al. Matched Paired Primary and Recurrent Meningiomas Points to Cell-Death Program Contributions to Genomic and Epigenomic Instability along Tumor Progression. *Cancers (Basel).* 2022; 14(16).
122. Nassiri F, Chakravarthy A, Feng S, et al. Detection and discrimination of intracranial tumors using plasma cell-free DNA methylomes. *Nat Med.* 2020; 26(7):1044-1047.
123. Zuccato JA, Patil V, Mansouri S, et al. DNA methylation-based prognostic subtypes of chordoma tumors in tissue and plasma. *Neuro Oncol.* 2022; 24(3):442-454.
124. Ricklefs FL, Maire CL, Wollmann K, et al. Diagnostic potential of extracellular vesicles in meningioma patients. *Neuro Oncol.* 2022; 24(12):2078-2090.
125. Herrgott GA, Snyder JM, She R, et al. Detection of diagnostic and prognostic methylation-based signatures in liquid biopsy specimens from patients with meningiomas. *Nat Commun.* 2023; 14(1):5669.
126. Chamoun R, Krisht KM, Couldwell WT. Incidental meningiomas. *Neurosurgical focus.* 2011; 31(6):E19.
127. Goldbrunner R, Stavrinou P, Jenkinson MD, et al. EANO guideline on the diagnosis and management of meningiomas. *Neuro Oncol.* 2021; 23(11):1821-1834.
128. Islim AI, Millward CP, Mills SJ, et al. The management of incidental meningioma: An unresolved clinical conundrum. *Neurooncol Adv.* 2023; 5(Suppl 1):i26-i34.
129. Zeng L, Liang P, Jiao J, Chen J, Lei T. Will an Asymptomatic Meningioma Grow or Not Grow? A Meta-analysis. *J Neurol Surg A Cent Eur Neurosurg.* 2015; 76(5):341-347.
130. Lyndon D, Lansley JA, Evanson J, Krishnan AS. Dural masses: meningiomas and their mimics. *Insights Imaging.* 2019; 10(1):11.
131. Regelsberger J, Hagel C, Emami P, Ries T, Heese O, Westphal M. Secretory meningiomas: a benign subgroup causing life-threatening complications. *Neuro Oncol.* 2009; 11(6):819-824.
132. Reuss DE, Piro RM, Jones DT, et al. Secretory meningiomas are defined by combined KLF4 K409Q and TRAF7 mutations. *Acta neuropathologica.* 2013; 125(3):351-358.
133. O'Leary S, Adams WM, Parrish RW, Mukonoweshuro W. Atypical imaging appearances of intracranial meningiomas. *Clin Radiol.* 2007; 62(1):10-17.
134. Bourekas EC, Wildenhain P, Lewin JS, et al. The dural tail sign revisited. *AJNR Am J Neuroradiol.* 1995; 16(7):1514-1516.
135. Slot KM, Verbaan D, Uitdehaag BM, et al. Can excision of meningiomas be limited to resection of tumor and radiologically abnormal dura mater? Neuronavigation-guided biopsies of dural tail and seemingly normal dura mater, with a review of the literature. *World Neurosurg.* 2014; 82(6):e832-836.
136. Sotoudeh H, Yazdi HR. A review on dural tail sign. *World J Radiol.* 2010; 2(5):188-192.
137. Wallace EW. The dural tail sign. *Radiology.* 2004; 233(1):56-57.
138. Wen M, Jung S, Moon KS, et al. Immunohistochemical profile of the dural tail in intracranial meningiomas. *Acta Neurochir (Wien).* 2014; 156(12):2263-2273.
139. Wirsching HG, Richter JK, Sahm F, et al. Post-operative cardiovascular complications and time to recurrence in meningioma patients treated with versus without pre-operative

- embolization: a retrospective cohort study of 741 patients. *J Neurooncol.* 2018; 140(3):659-667.
140. Iacobucci M, Danieli L, Visconti E, et al. Preoperative embolization of meningiomas with polyvinyl alcohol particles: The benefits are not outweighed by risks. *Diagn Interv Imaging.* 2017; 98(4):307-314.
  141. Huang RY, Bi WL, Weller M, et al. Proposed response assessment and endpoints for meningioma clinical trials: report from the Response Assessment in Neuro-Oncology Working Group. *Neuro Oncol.* 2019; 21(1):26-36.
  142. Watanabe S, Nonaka T, Maeda M, et al. Efficacy Endpoints in Phase II Clinical Trials for Meningioma: An Analysis of Recent Clinical Trials. *Ther Innov Regul Sci.* 2023; 57(3):603-610.
  143. Huang RY, Unadkat P, Bi WL, et al. Response assessment of meningioma: 1D, 2D, and volumetric criteria for treatment response and tumor progression. *Neuro Oncol.* 2019; 21(2):234-241.
  144. Kaley T, Barani I, Chamberlain M, et al. Historical benchmarks for medical therapy trials in surgery- and radiation-refractory meningioma: a RANO review. *Neuro Oncol.* 2014; 16(6):829-840.
  145. Macdonald DR, Cascino TL, Schold SC, Jr., Cairncross JG. Response criteria for phase II studies of supratentorial malignant glioma. *J Clin Oncol.* 1990; 8(7):1277-1280.
  146. Wen PY, Macdonald DR, Reardon DA, et al. Updated response assessment criteria for high-grade gliomas: response assessment in neuro-oncology working group. *J Clin Oncol.* 2010; 28(11):1963-1972.
  147. Hall JT, Opalak CF, Carr MT, Harris TJ, Broaddus WC. The Effect of Radiation on Meningioma Volume Change. *World Neurosurg.* 2021; 153:e141-e146.
  148. Fega KR, Fletcher GP, Waddle MR, et al. Analysis of MRI Volumetric Changes After Hypofractionated Stereotactic Radiation Therapy for Benign Intracranial Neoplasms. *Adv Radiat Oncol.* 2019; 4(1):43-49.
  149. Harrison G, Kano H, Lunsford LD, Flickinger JC, Kondziolka D. Quantitative tumor volumetric responses after Gamma Knife radiosurgery for meningiomas. *J Neurosurg.* 2016; 124(1):146-154.
  150. Tabouret E, Furtner J, Graillon T, et al. 3D volume growth rate evaluation in the EORTC-BTG-1320 clinical trial for recurrent WHO grade 2 and 3 meningiomas. *Journal of Clinical Oncology.* 2023; 41(16\_suppl):2075-2075.
  151. Nassiri F, Wang JZ, Au K, et al. Consensus core clinical data elements for meningiomas (v2021.1). *Neuro Oncol.* 2022; 24(5):683-693.
  152. Prasad RN, Perlow HK, Bovi J, et al. (68)Ga-DOTATATE PET: The Future of Meningioma Treatment. *Int J Radiat Oncol Biol Phys.* 2022; 113(4):868-871.
  153. Galldiks N, Albert NL, Sommerauer M, et al. PET imaging in patients with meningioma-report of the RANO/PET Group. *Neuro Oncol.* 2017; 19(12):1576-1587.
  154. Kong MJ, Yang AF, Vora SA, Ross JS, Yang M. The Complementary Role of (68)Ga-DOTATATE PET/CT in Diagnosis of Recurrent Meningioma. *J Nucl Med Technol.* 2022.
  155. Afshar-Oromieh A, Giesel FL, Linhart HG, et al. Detection of cranial meningiomas: comparison of <sup>68</sup>Ga-DOTATOC PET/CT and contrast-enhanced MRI. *Eur J Nucl Med Mol Imaging.* 2012; 39(9):1409-1415.

156. Rachinger W, Stoecklein VM, Terpolilli NA, et al. Increased <sup>68</sup>Ga-DOTATATE uptake in PET imaging discriminates meningioma and tumor-free tissue. *Journal of Nuclear Medicine*. 2015; 56(3):347-353.
157. Perlow HK, Siedow M, Gokun Y, et al. (<sup>68</sup>Ga)-DOTATATE PET-Based Radiation Contouring Creates More Precise Radiation Volumes for Patients With Meningioma. *Int J Radiat Oncol Biol Phys*. 2022; 113(4):859-865.
158. Kessel KA, Weber W, Yakushev I, et al. Integration of PET-imaging into radiotherapy treatment planning for low-grade meningiomas improves outcome. *European journal of nuclear medicine and molecular imaging*. 2020; 47:1391-1399.
159. Mahase SS, Roth O'Brien DA, No D, et al. [<sup>68</sup>Ga]-DOTATATE PET/MRI as an adjunct imaging modality for radiation treatment planning of meningiomas. *Neuro-oncology advances*. 2021; 3(1):vdab012.
160. Kowalski ES, Khairnar R, Gryaznov AA, et al. (<sup>68</sup>Ga)-DOTATATE PET-CT as a tool for radiation planning and evaluating treatment responses in the clinical management of meningiomas. *Radiat Oncol*. 2021; 16(1):151.
161. Ueberschaer M, Vettermann FJ, Forbrig R, et al. Simpson grade revisited—intraoperative estimation of the extent of resection in meningiomas versus postoperative somatostatin receptor positron emission tomography/computed tomography and magnetic resonance imaging. *Neurosurgery*. 2021; 88(1):140-146.
162. Teske N, Biczok A, Quach S, et al. Postoperative [<sup>68</sup>Ga]Ga-DOTA-TATE PET/CT imaging is prognostic for progression-free survival in meningioma WHO grade 1. *Eur J Nucl Med Mol Imaging*. 2023.
163. Unterrainer M, Kunte SC, Unterrainer LM, et al. Next-generation PET/CT imaging in meningioma-first clinical experiences using the novel SSTR-targeting peptide [(<sup>18</sup>F)]SiTATE. *Eur J Nucl Med Mol Imaging*. 2023; 50(11):3390-3399.
164. Wängler C, Beyer L, Bartenstein P, Wängler B, Schirmacher R, Lindner S. Favorable SSTR subtype selectivity of SiTATE: new momentum for clinical [(<sup>18</sup>F)]SiTATE PET. *EJNMMI Radiopharm Chem*. 2022; 7(1):22.
165. Rodriguez J, Martinez G, Mahase S, et al. Cost-Effectiveness Analysis of (<sup>68</sup>Ga)-DOTATATE PET/MRI in Radiotherapy Planning in Patients with Intermediate-Risk Meningioma. *AJNR Am J Neuroradiol*. 2023; 44(7):783-791.
166. Islim AI, Kolamunnage-Dona R, Mohan M, et al. A prognostic model to personalize monitoring regimes for patients with incidental asymptomatic meningiomas. *Neuro Oncol*. 2020; 22(2):278-289.
167. Islim AI, Mohan M, Moon RDC, et al. Incidental intracranial meningiomas: a systematic review and meta-analysis of prognostic factors and outcomes. *J Neurooncol*. 2019; 142(2):211-221.
168. Bui KT, Liang R, Kiely BE, Brown C, Dhillon HM, Blinman P. Scanxiety: a scoping review about scan-associated anxiety. *BMJ Open*. 2021; 11(5):e043215.
169. Niuro M, Yatsushiro K, Nakamura K, Kawahara Y, Kuratsu J. Natural history of elderly patients with asymptomatic meningiomas. *J Neurol Neurosurg Psychiatry*. 2000; 68(1):25-28.
170. Go RS, Taylor BV, Kimmel DW. The natural history of asymptomatic meningiomas in Olmsted County, Minnesota. *Neurology*. 1998; 51(6):1718-1720.

171. Nakamura M, Roser F, Michel J, Jacobs C, Samii M. The natural history of incidental meningiomas. *Neurosurgery*. 2003; 53(1):62-70; discussion 70-61.
172. Nakasu S, Nakasu Y, Fukami T, Jito J, Nozaki K. Growth curve analysis of asymptomatic and symptomatic meningiomas. *J Neurooncol*. 2011; 102(2):303-310.
173. Kim KH, Kang SJ, Choi J-W, et al. Clinical and radiological outcomes of proactive Gamma Knife surgery for asymptomatic meningiomas compared with the natural course without intervention. *Journal of neurosurgery*. 2018; 130(5):1740-1749.
174. Romani R, Ryan G, Benner C, Pollock J. Non-operative meningiomas: long-term follow-up of 136 patients. *Acta Neurochir (Wien)*. 2018; 160(8):1547-1553.
175. Suppiah S, Nassiri F, Bi WL, et al. Molecular and translational advances in meningiomas. *Neuro-oncology*. 2019; 21(Supplement\_1):i4-i17.
176. Lee EJ, Kim JH, Park ES, et al. A novel weighted scoring system for estimating the risk of rapid growth in untreated intracranial meningiomas. *J Neurosurg*. 2017; 127(5):971-980.
177. Islim AI, Mohan M, Moon RDC, et al. Treatment Outcomes of Incidental Intracranial Meningiomas: Results from the IMPACT Cohort. *World Neurosurg*. 2020; 138:e725-e735.
178. Islim AI, Millward CP, Piper RJ, et al. External validation and recalibration of an incidental meningioma prognostic model - IMPACT: protocol for an international multicentre retrospective cohort study. *BMJ Open*. 2022; 12(1):e052705.
179. Reinert M, Babey M, Curschmann J, Vajtai I, Seiler RW, Mariani L. Morbidity in 201 patients with small sized meningioma treated by microsurgery. *Acta Neurochir (Wien)*. 2006; 148(12):1257-1265; discussion 1266.
180. Näslund O, Skoglund T, Farahmand D, Bontell TO, Jakola AS. Indications and outcome in surgically treated asymptomatic meningiomas: a single-center case-control study. *Acta Neurochir (Wien)*. 2020; 162(9):2155-2163.
181. Sheehan J, Pikis S, Islim AI, et al. An international multicenter matched cohort analysis of incidental meningioma progression during active surveillance or after stereotactic radiosurgery: the IMPASSE study. *Neuro Oncol*. 2022; 24(1):116-124.
182. Bashir A, Vestergaard MB, Marner L, et al. PET imaging of meningioma with 18F-FLT: a predictor of tumour progression. *Brain*. 2020; 143(11):3308-3317.
183. Kalasauskas D, Keric N, Abu Ajaj S, von Cube L, Ringel F, Renovanz M. Psychological burden in meningioma patients under a wait-and-watch strategy and after complete resection Is high—results of a prospective single center study. *Cancers*. 2020; 12(12):3503.
184. Maurer R, Daggubati L, Ba DM, et al. Mental health disorders in patients with untreated meningiomas: an observational cohort study using the nationwide MarketScan database. *Neuro-Oncology Practice*. 2020; 7(5):507-513.
185. Simpson D. The recurrence of intracranial meningiomas after surgical treatment. *Journal of neurology, neurosurgery, and psychiatry*. 1957; 20(1):22.
186. Gousias K, Schramm J, Simon M. The Simpson grading revisited: aggressive surgery and its place in modern meningioma management. *J Neurosurg*. 2016; 125(3):551-560.
187. Nanda A, Bir SC, Maiti TK, Konar SK, Missios S, Guthikonda B. Relevance of Simpson grading system and recurrence-free survival after surgery for World Health Organization Grade I meningioma. *Journal of neurosurgery*. 2017; 126(1):201-211.

188. Behling F, Fodi C, Hoffmann E, et al. The role of Simpson grading in meningiomas after integration of the updated WHO classification and adjuvant radiotherapy. *Neurosurg Rev.* 2021; 44(4):2329-2336.
189. Gallagher MJ, Jenkinson MD, Brodbelt AR, Mills SJ, Chavredakis E. WHO grade 1 meningioma recurrence: Are location and Simpson grade still relevant? *Clinical neurology and neurosurgery.* 2016; 141:117-121.
190. Schwartz TH, McDermott MW. The Simpson grade: abandon the scale but preserve the message. *J Neurosurg.* 2020:1-8.
191. Sughrue ME, Kane AJ, Shangari G, et al. The relevance of Simpson Grade I and II resection in modern neurosurgical treatment of World Health Organization Grade I meningiomas. *Journal of neurosurgery.* 2010; 113(5):1029-1035.
192. Mansouri A, Klironomos G, Taslimi S, et al. Surgically resected skull base meningiomas demonstrate a divergent postoperative recurrence pattern compared with non-skull base meningiomas. *J Neurosurg.* 2016; 125(2):431-440.
193. Zador Z, Landry AP, Balas M, Cusimano MD. Landscape of immune cell gene expression is unique in predominantly WHO grade 1 skull base meningiomas when compared to convexity. *Sci Rep.* 2020; 10(1):9065.
194. McGovern SL, Aldape KD, Munsell MF, Mahajan A, DeMonte F, Woo SY. A comparison of World Health Organization tumor grades at recurrence in patients with non-skull base and skull base meningiomas. *J Neurosurg.* 2010; 112(5):925-933.
195. Kinjo T, al-Mefty O, Kanaan I. Grade zero removal of supratentorial convexity meningiomas. *Neurosurgery.* 1993; 33(3):394-399; discussion 399.
196. Chotai S, Schwartz TH. The Simpson Grading: Is It Still Valid? *Cancers (Basel).* 2022; 14(8).
197. Qi ST, Liu Y, Pan J, Chotai S, Fang LX. A radiopathological classification of dural tail sign of meningiomas. *J Neurosurg.* 2012; 117(4):645-653.
198. Koljenović S, Schut TB, Vincent A, Kros JM, Puppels GJ. Detection of meningioma in dura mater by Raman spectroscopy. *Anal Chem.* 2005; 77(24):7958-7965.
199. Qian K, Nie C, Zhu W, et al. Surgical management of tuberculum sellae meningioma: Transcranial approach or endoscopic endonasal approach? *Front Surg.* 2022; 9:979940.
200. Komotar RJ, Starke RM, Raper DM, Anand VK, Schwartz TH. Endoscopic endonasal versus open transcranial resection of anterior midline skull base meningiomas. *World Neurosurg.* 2012; 77(5-6):713-724.
201. Magill ST, Schwartz TH, Couldwell WT, et al. International Tuberculum Sellae Meningioma Study: Surgical Outcomes and Management Trends. *Neurosurgery.* 2023.
202. Rogers L, Zhang P, Vogelbaum MA, et al. Intermediate-risk meningioma: initial outcomes from NRG Oncology RTOG 0539. *J Neurosurg.* 2018; 129(1):35-47.
203. Rogers CL, Won M, Vogelbaum MA, et al. High-risk Meningioma: Initial Outcomes From NRG Oncology/RTOG 0539. *Int J Radiat Oncol Biol Phys.* 2020; 106(4):790-799.
204. Weber DC, Ares C, Villa S, et al. Adjuvant postoperative high-dose radiotherapy for atypical and malignant meningioma: A phase-II parallel non-randomized and observation study (EORTC 22042-26042). *Radiother Oncol.* 2018; 128(2):260-265.
205. Deng MY, Maas SLN, Hinz F, et al. Efficacy and toxicity of bimodal radiotherapy in WHO grade 2 meningiomas following subtotal resection with carbon ion boost: prospective phase 2 MARCIE trial. *Neuro Oncol.* 2023.

206. Zeng KL, Soliman H, Myrehaug S, et al. Dose-Escalated Radiation Therapy Is Associated With Improved Outcomes for High-Grade Meningioma. *Int J Radiat Oncol Biol Phys*. 2023.
207. Chen WC, Perlow HK, Choudhury A, et al. Radiotherapy for meningiomas. *J Neurooncol*. 2022; 160(2):505-515.
208. Chen WC, Lucas C-HG, Magill ST, Rogers CL, Raleigh DR. Radiotherapy and radiosurgery for meningiomas. *Neuro-Oncology Advances*. 2023; 5(Supplement\_1):i67-i83.
209. Jenkinson MD, Javadpour M, Haylock BJ, et al. The ROAM/EORTC-1308 trial: Radiation versus Observation following surgical resection of Atypical Meningioma: study protocol for a randomised controlled trial. *Trials*. 2015; 16:519.
210. Jenkinson MD, Weber DC, Haylock BJ, Mallucci CL, Zakaria R, Javadpour M. Radiotherapy versus observation following surgical resection of atypical meningioma (the ROAM trial). *Neuro Oncol*. 2014; 16(11):1560-1561.
211. Fleming CW, Parsai S, Suh JH. A management dilemma: adjuvant radiotherapy after gross total resection of atypical meningioma. *Translational Cancer Research*. 2019; 8(1):1.
212. Okoye C, Rogers L. Atypical and Malignant Meningioma. *Intracranial and Spinal Radiotherapy: A Practical Guide on Treatment Techniques*. 2021:13-17.
213. Louis DN, Perry A, Reifenberger G, et al. The 2016 World Health Organization classification of tumors of the central nervous system: a summary. *Acta neuropathologica*. 2016; 131(6):803-820.
214. Louis DN, Ohgaki H, Wiestler OD, et al. The 2007 WHO classification of tumours of the central nervous system. *Acta Neuropathol*. 2007; 114(2):97-109.
215. Kleihues P, Louis DN, Scheithauer BW, et al. The WHO classification of tumors of the nervous system. *J Neuropathol Exp Neurol*. 2002; 61(3):215-225; discussion 226-219.
216. Perry A. The definition and role of brain invasion in meningioma grading: Still controversial after all these years. *Free Neuropathol*. 2021; 2.
217. Ammendola S, Bariani E, Eccher A, et al. The histopathological diagnosis of atypical meningioma: glass slide versus whole slide imaging for grading assessment. *Virchows Arch*. 2021; 478(4):747-756.
218. Maas SLN, Sievers P, Weber DC, et al. Independent prognostic impact of DNA methylation class and chromosome 1p loss in WHO grade 2 and 3 meningioma undergoing adjuvant high-dose radiotherapy: comprehensive molecular analysis of EORTC 22042-26042. *Acta Neuropathol*. 2023; 146(6):837-840.
219. Chen WC, Choudhury A, Youngblood MW, et al. Targeted gene expression profiling predicts meningioma outcomes and radiotherapy responses. *Nat Med*. 2023.
220. Raleigh DR, Preusser M. A 34-gene expression biomarker predicts meningioma outcomes and radiotherapy responses. *Neuro Oncol*. 2023.
221. Di Franco R, Borzillo V, Ravo V, et al. Radiosurgery and stereotactic radiotherapy with cyberknife system for meningioma treatment. *Neuroradiol J*. 2018; 31(1):18-26.
222. McGregor JM, Sarkar A. Stereotactic radiosurgery and stereotactic radiotherapy in the treatment of skull base meningiomas. *Otolaryngol Clin North Am*. 2009; 42(4):677-688.
223. Wang JZ, Landry AP, Nassiri F, et al. Outcomes and predictors of response to fractionated radiotherapy as primary treatment for intracranial meningiomas. *Clin Transl Radiat Oncol*. 2023; 41:100631.

224. Kaprealian T, Raleigh DR, Sneed PK, Nabavizadeh N, Nakamura JL, McDermott MW. Parameters influencing local control of meningiomas treated with radiosurgery. *J Neurooncol.* 2016; 128(2):357-364.
225. Onodera S, Aoyama H, Katoh N, et al. Long-term outcomes of fractionated stereotactic radiotherapy for intracranial skull base benign meningiomas in single institution. *Jpn J Clin Oncol.* 2011; 41(4):462-468.
226. Biau J, Khalil T, Verrelle P, Lemaire JJ. Fractionated radiotherapy and radiosurgery of intracranial meningiomas. *Neurochirurgie.* 2018; 64(1):29-36.
227. Kheir V, Faouzi M, Borruat FX. Visual Outcomes of Fractionated Radiotherapy in Optic Nerve Sheath Meningioma: A Retrospective Study. *Klin Monbl Augenheilkd.* 2019; 236(4):526-529.
228. Lesser RL, Knisely JP, Wang SL, James BY, Kupersmith MJ. Long-term response to fractionated radiotherapy of presumed optic nerve sheath meningioma. *British journal of ophthalmology.* 2010; 94(5):559-563.
229. Marchetti M, Sahgal A, De Salles AAF, et al. Stereotactic Radiosurgery for Intracranial Noncavernous Sinus Benign Meningioma: International Stereotactic Radiosurgery Society Systematic Review, Meta-Analysis and Practice Guideline. *Neurosurgery.* 2020; 87(5):879-890.
230. DiBiase SJ, Kwok Y, Yovino S, et al. Factors predicting local tumor control after gamma knife stereotactic radiosurgery for benign intracranial meningiomas. *Int J Radiat Oncol Biol Phys.* 2004; 60(5):1515-1519.
231. Park HR, Lee JM, Park KW, et al. Fractionated Gamma Knife Radiosurgery as Initial Treatment for Large Skull Base Meningioma. *Exp Neurobiol.* 2018; 27(3):245-255.
232. Sheehan JP, Lee CC, Xu Z, Przybylowski CJ, Melmer PD, Schlesinger D. Edema following Gamma Knife radiosurgery for parasagittal and parafalcine meningiomas. *J Neurosurg.* 2015; 123(5):1287-1293.
233. Kondziolka D, Mathieu D, Lunsford LD, et al. Radiosurgery as definitive management of intracranial meningiomas. *Neurosurgery.* 2008; 62(1):53-58; discussion 58-60.
234. Kowalchuk RO, Shepard MJ, Sheehan K, et al. Treatment of WHO Grade 2 Meningiomas With Stereotactic Radiosurgery: Identification of an Optimal Group for SRS Using RPA. *Int J Radiat Oncol Biol Phys.* 2021; 110(3):804-814.
235. Burkett BJ, Bartlett DJ, McGarrah PW, et al. A Review of Theranostics: Perspectives on Emerging Approaches and Clinical Advancements. *Radiol Imaging Cancer.* 2023; 5(4):e220157.
236. Bailey DL, Willowson KP, Harris M, et al. (64)Cu Treatment Planning and (67)Cu Therapy with Radiolabeled [(64)Cu/(67)Cu]MeCOSar-Octreotate in Subjects with Unresectable Multifocal Meningioma: Initial Results for Human Imaging, Safety, Biodistribution, and Radiation Dosimetry. *J Nucl Med.* 2023; 64(5):704-710.
237. Mirian C, Duun-Henriksen AK, Maier A, et al. Somatostatin Receptor-Targeted Radiopeptide Therapy in Treatment-Refractory Meningioma: Individual Patient Data Meta-analysis. *J Nucl Med.* 2021; 62(4):507-513.
238. Boursier C, Zaragori T, Bros M, et al. Semi-automated segmentation methods of SSTR PET for dosimetry prediction in refractory meningioma patients treated by SSTR-targeted peptide receptor radionuclide therapy. *Eur Radiol.* 2023.

239. Strosberg J, El-Haddad G, Wolin E, et al. Phase 3 Trial of (177)Lu-Dotatate for Midgut Neuroendocrine Tumors. *N Engl J Med*. 2017; 376(2):125-135.
240. Urso L, Nieri A, Uccelli L, et al. Lutathera<sup>®</sup> Orphans: State of the Art and Future Application of Radioligand Therapy with (177)Lu-DOTATATE. *Pharmaceutics*. 2023; 15(4).
241. Kurz S, Zan E, Cordova C, et al. CTNI-57. Radionuclide therapy with 177Lu-DOTATATE (Lutathera) in adults with advanced intracranial meningioma- interim results of a single-arm open-label multicenter phase II study multicenter study. *Neuro-Oncology*. 2022; 24(Supplement\_7):vii85-vii85.
242. Mair MJ, Berghoff AS, Brastianos PK, Preusser M. Emerging systemic treatment options in meningioma. *J Neurooncol*. 2023; 161(2):245-258.
243. Kaley TJ, Wen P, Schiff D, et al. Phase II trial of sunitinib for recurrent and progressive atypical and anaplastic meningioma. *Neuro Oncol*. 2015; 17(1):116-121.
244. Raizer JJ, Grimm SA, Rademaker A, et al. A phase II trial of PTK787/ZK 222584 in recurrent or progressive radiation and surgery refractory meningiomas. *J Neurooncol*. 2014; 117(1):93-101.
245. Nayak L, Iwamoto FM, Rudnick JD, et al. Atypical and anaplastic meningiomas treated with bevacizumab. *J Neurooncol*. 2012; 109(1):187-193.
246. Shih KC, Chowdhary S, Rosenblatt P, et al. A phase II trial of bevacizumab and everolimus as treatment for patients with refractory, progressive intracranial meningioma. *J Neurooncol*. 2016; 129(2):281-288.
247. Preusser M, Silvani A, Le Rhun E, et al. Trabectedin for recurrent WHO grade 2 or 3 meningioma: A randomized phase II study of the EORTC Brain Tumor Group (EORTC-1320-BTG). *Neuro Oncol*. 2022; 24(5):755-767.
248. Kumthekar P, Grimm SA, Aleman RT, et al. A multi-institutional phase II trial of bevacizumab for recurrent and refractory meningioma. *Neuro-Oncology Advances*. 2022; 4(1).
249. Chamberlain MC. Hydroxyurea for recurrent surgery and radiation refractory high-grade meningioma. *J Neurooncol*. 2012; 107(2):315-321.
250. Chamberlain MC, Tsao-Wei DD, Groshen S. Salvage chemotherapy with CPT-11 for recurrent meningioma. *J Neurooncol*. 2006; 78(3):271-276.
251. Belanger K, Ung TH, Damek D, Lillehei KO, Ormond DR. Concomitant Temozolomide plus radiotherapy for high-grade and recurrent meningioma: a retrospective chart review. *BMC Cancer*. 2022; 22(1):367.
252. Chamberlain MC. Adjuvant combined modality therapy for malignant meningiomas. *J Neurosurg*. 1996; 84(5):733-736.
253. Norden AD, Ligon KL, Hammond SN, et al. Phase II study of monthly pasireotide LAR (SOM230C) for recurrent or progressive meningioma. *Neurology*. 2015; 84(3):280-286.
254. Simó M, Argyriou AA, Macià M, et al. Recurrent high-grade meningioma: a phase II trial with somatostatin analogue therapy. *Cancer Chemother Pharmacol*. 2014; 73(5):919-923.
255. Marincek N, Radojewski P, Dumont RA, et al. Somatostatin receptor-targeted radiopeptide therapy with 90Y-DOTATOC and 177Lu-DOTATOC in progressive meningioma: long-term results of a phase II clinical trial. *J Nucl Med*. 2015; 56(2):171-176.



256. Graillon T, Sanson M, Campello C, et al. Everolimus and Octreotide for Patients with Recurrent Meningioma: Results from the Phase II CEVOREM Trial. *Clin Cancer Res.* 2020; 26(3):552-557.
257. Cossu G, Levivier M, Daniel RT, Messerer M. The Role of Mifepristone in Meningiomas Management: A Systematic Review of the Literature. *Biomed Res Int.* 2015; 2015:267831.
258. Du Z, Abedalthagafi M, Aizer AA, et al. Increased expression of the immune modulatory molecule PD-L1 (CD274) in anaplastic meningioma. *Oncotarget.* 2015; 6(7):4704-4716.
259. Brastianos PK, Kim AE, Giobbie-Hurder A, et al. Phase 2 study of pembrolizumab in patients with recurrent and residual high-grade meningiomas. *Nat Commun.* 2022; 13(1):1325.
260. Bi WL, Nayak L, Meredith DM, et al. Activity of PD-1 blockade with nivolumab among patients with recurrent atypical/anaplastic meningioma: phase II trial results. *Neuro Oncol.* 2022; 24(1):101-113.
261. Gyawali S, Sharma P, Mahapatra A. Meningioma and psychiatric symptoms: An individual patient data analysis. *Asian J Psychiatr.* 2019; 42:94-103.
262. Wu A, Garcia MA, Magill ST, et al. Presenting Symptoms and Prognostic Factors for Symptomatic Outcomes Following Resection of Meningioma. *World Neurosurg.* 2018; 111:e149-e159.
263. Nassiri F, Price B, Shehab A, et al. Life after surgical resection of a meningioma: a prospective cross-sectional study evaluating health-related quality of life. *Neuro Oncol.* 2019; 21(Suppl 1):i32-i43.
264. Jakola AS, Gulati M, Gulati S, Solheim O. The influence of surgery on quality of life in patients with intracranial meningiomas: a prospective study. *J Neurooncol.* 2012; 110(1):137-144.
265. Miao Y, Lu X, Qiu Y, Jiang J, Lin Y. A multivariate analysis of prognostic factors for health-related quality of life in patients with surgically managed meningioma. *J Clin Neurosci.* 2010; 17(4):446-449.
266. Zamanipoor Najafabadi AH, Peeters MCM, Dirven L, et al. Impaired health-related quality of life in meningioma patients-a systematic review. *Neuro Oncol.* 2017; 19(7):897-907.
267. Nassiri F, Suppiah S, Wang JZ, et al. How to live with a meningioma: experiences, symptoms, and challenges reported by patients. *Neurooncol Adv.* 2020; 2(1):vdad086.
268. Haider S, Taphoorn MJB, Drummond KJ, Walbert T. Health-related quality of life in meningioma. *Neurooncol Adv.* 2021; 3(1):vdab089.
269. van Nieuwenhuizen D, Klein M, Stalpers LJ, Leenstra S, Heimans JJ, Reijneveld JC. Differential effect of surgery and radiotherapy on neurocognitive functioning and health-related quality of life in WHO grade I meningioma patients. *J Neurooncol.* 2007; 84(3):271-278.
270. Lisowski D, Trömel J, Lutyj P, et al. Health-related quality of life and clinical outcome after radiotherapy of patients with intracranial meningioma. *Sci Rep.* 2022; 12(1):19730.
271. Henzel M, Fokas E, Sitter H, Wittig A, Engenhart-Cabillic R. Quality of life after stereotactic radiotherapy for meningioma: a prospective non-randomized study. *J Neurooncol.* 2013; 113(1):135-141.

272. Chen WC, Magill ST, Englot DJ, et al. Factors Associated With Pre- and Postoperative Seizures in 1033 Patients Undergoing Supratentorial Meningioma Resection. *Neurosurgery*. 2017; 81(2):297-306.
273. Englot DJ, Magill ST, Han SJ, Chang EF, Berger MS, McDermott MW. Seizures in supratentorial meningioma: a systematic review and meta-analysis. *J Neurosurg*. 2016; 124(6):1552-1561.
274. Gupte TP, Li C, Jin L, et al. Clinical and genomic factors associated with seizures in meningiomas. *J Neurosurg*. 2020; 135(3):835-844.
275. Elbadry Ahmed R, Tang H, Asemota A, Huang L, Boling W, Bannout F. Meningioma Related Epilepsy- Pathophysiology, Pre/postoperative Seizures Predicators and Treatment. *Front Oncol*. 2022; 12:905976.
276. Dincer A, Jalal MI, Gupte TP, et al. The clinical and genomic features of seizures in meningiomas. *Neurooncol Adv*. 2023; 5(Suppl 1):i49-i57.
277. Kawaguchi T, Kameyama S, Tanaka R. Peritumoral edema and seizure in patients with cerebral convexity and parasagittal meningiomas. *Neurol Med Chir (Tokyo)*. 1996; 36(8):568-573; discussion 573-564.
278. Haglund MM, Berger MS, Kunkel DD, Franck JE, Ghatan S, Ojemann GA. Changes in gamma-aminobutyric acid and somatostatin in epileptic cortex associated with low-grade gliomas. *J Neurosurg*. 1992; 77(2):209-216.
279. Lobato RD, Alday R, Gómez PA, et al. Brain oedema in patients with intracranial meningioma. Correlation between clinical, radiological, and histological factors and the presence and intensity of oedema. *Acta Neurochir (Wien)*. 1996; 138(5):485-493; discussion 493-484.
280. Peart R, Melnick K, Cibula J, et al. Clinical management of seizures in patients with meningiomas: Efficacy of surgical resection for seizure control and patient-tailored postoperative anti-epileptic drug management. *Neurooncol Adv*. 2023; 5(Suppl 1):i58-i66.
281. Avila EK, Tobochnik S, Inati SK, et al. Brain tumor-related epilepsy management: A Society for Neuro-oncology (SNO) consensus review on current management. *Neuro Oncol*. 2023.
282. Islim AI, McKeever S, Kusu-Orkar TE, Jenkinson MD. The role of prophylactic antiepileptic drugs for seizure prophylaxis in meningioma surgery: A systematic review. *J Clin Neurosci*. 2017; 43:47-53.
283. Lieu AS, Howng SL. Intracranial meningiomas and epilepsy: incidence, prognosis and influencing factors. *Epilepsy Res*. 2000; 38(1):45-52.
284. Skardelly M, Rother C, Noell S, et al. Risk Factors of Preoperative and Early Postoperative Seizures in Patients with Meningioma: A Retrospective Single-Center Cohort Study. *World Neurosurg*. 2017; 97:538-546.
285. Sughrue ME, Rutkowski MJ, Chang EF, et al. Postoperative seizures following the resection of convexity meningiomas: are prophylactic anticonvulsants indicated? Clinical article. *J Neurosurg*. 2011; 114(3):705-709.
286. Islim AI, Ali A, Bagchi A, et al. Postoperative seizures in meningioma patients: improving patient selection for antiepileptic drug therapy. *J Neurooncol*. 2018; 140(1):123-134.

287. Jenkinson M, Helmy A, Huckey H, et al. RTID-10. Surgeons trial of prophylaxis for epilepsy in seizure naïve patients with meningioma: a randomized controlled trial (STOP 'EM). *Neuro Oncol*. 2020; 22(Suppl 2):ii195.
288. Evans DG, Huson SM, Donnai D, et al. A genetic study of type 2 neurofibromatosis in the United Kingdom. I. Prevalence, mutation rate, fitness, and confirmation of maternal transmission effect on severity. *J Med Genet*. 1992; 29(12):841-846.
289. Evans DG, Moran A, King A, Saeed S, Gurusinge N, Ramsden R. Incidence of vestibular schwannoma and neurofibromatosis 2 in the North West of England over a 10-year period: higher incidence than previously thought. *Otol Neurotol*. 2005; 26(1):93-97.
290. Gregory GE, Islim AI, Hannan CJ, et al. The clinical, genetic, and immune landscape of meningioma in patients with NF2-schwannomatosis. *Neurooncol Adv*. 2023; 5(Suppl 1):i94-i104.
291. Mautner VF, Lindenau M, Baser ME, et al. The neuroimaging and clinical spectrum of neurofibromatosis 2. *Neurosurgery*. 1996; 38(5):880-885; discussion 885-886.
292. Hannan CJ, Hammerbeck-Ward C, Pathmanaban ON, et al. Multiple Meningiomas as a Criterion for the Diagnosis of Neurofibromatosis Type 2 and Other Tumor Predisposition Syndromes. *Neurosurgery*. 2022; 90(6):793-799.
293. Abi Jaoude S, Peyre M, Degos V, Goutagny S, Parfait B, Kalamarides M. Validation of a scoring system to evaluate the risk of rapid growth of intracranial meningiomas in neurofibromatosis type 2 patients. *J Neurosurg*. 2020; 134(5):1377-1385.
294. Goutagny S, Bah AB, Henin D, et al. Long-term follow-up of 287 meningiomas in neurofibromatosis type 2 patients: clinical, radiological, and molecular features. *Neuro Oncol*. 2012; 14(8):1090-1096.
295. Evers S, Verbaan D, Sanchez E, Peerdeman S. 3D Volumetric Measurement of Neurofibromatosis Type 2-Associated Meningiomas: Association Between Tumor Location and Growth Rate. *World Neurosurg*. 2015; 84(4):1062-1069.
296. Forde C, King AT, Rutherford SA, et al. Disease course of neurofibromatosis type 2: a 30-year follow-up study of 353 patients seen at a single institution. *Neuro Oncol*. 2021; 23(7):1113-1124.
297. Gao F, Li M, Wang Z, Shi L, Lou L, Zhou J. Efficacy and Safety of Gamma Knife Radiosurgery for Meningiomas in Patients with Neurofibromatosis Type 2: A Long-Term Follow-Up Single-Center Study. *World Neurosurg*. 2019; 125:e929-e936.
298. Mohammed N, Hung YC, Xu Z, et al. Neurofibromatosis type 2-associated meningiomas: an international multicenter study of outcomes after Gamma Knife stereotactic radiosurgery. *J Neurosurg*. 2022; 136(1):109-114.
299. Birckhead B, Sio TT, Pollock BE, Link MJ, Laack NN. Gamma Knife radiosurgery for neurofibromatosis type 2-associated meningiomas: a 22-year patient series. *J Neurooncol*. 2016; 130(3):553-560.
300. Liu A, Kuhn EN, Lucas JT, Jr., Laxton AW, Tatter SB, Chan MD. Gamma Knife radiosurgery for meningiomas in patients with neurofibromatosis Type 2. *J Neurosurg*. 2015; 122(3):536-542.
301. Evans DG, Halliday D, Obholzer R, et al. Radiation treatment of benign tumors in NF2-related-schwannomatosis: A national study of 266 irradiated patients showing a

- significant increase in malignancy/malignant progression. *Neurooncol Adv.* 2023; 5(1):vdad025.
302. Ferner RE, Shaw A, Evans DG, et al. Longitudinal evaluation of quality of life in 288 patients with neurofibromatosis 2. *J Neurol.* 2014; 261(5):963-969.
  303. Cosetti MK, Golfinos JG, Roland JT, Jr. Quality of Life (QoL) Assessment in Patients with Neurofibromatosis Type 2 (NF2). *Otolaryngol Head Neck Surg.* 2015; 153(4):599-605.
  304. Osorio DS, Hu J, Mitchell C, et al. Effect of lapatinib on meningioma growth in adults with neurofibromatosis type 2. *J Neurooncol.* 2018; 139(3):749-755.
  305. Plotkin S, Allen J, Babovic-Vuksanovic D, et al. CTNI-65. INTUITT-NF2, an adaptive platform-basket trial for neurofibromatosis 2 patients with progressive tumors: interim results of the brigatinib treatment arm. *Neuro-Oncology.* 2022; 24(Supplement\_7):vii88-vii88.
  306. Kok JL, Teepen JC, van Leeuwen FE, et al. Risk of benign meningioma after childhood cancer in the DCOG-LATER cohort: contributions of radiation dose, exposed cranial volume, and age. *Neuro Oncol.* 2019; 21(3):392-403.
  307. Bowers DC, Moskowitz CS, Chou JF, et al. Morbidity and Mortality Associated With Meningioma After Cranial Radiotherapy: A Report From the Childhood Cancer Survivor Study. *Journal of Clinical Oncology.* 2017; 35(14):1570-1576.
  308. Sadetzki S, Chetrit A, Freedman L, Stovall M, Modan B, Novikov I. Long-term follow-up for brain tumor development after childhood exposure to ionizing radiation for tinea capitis. *Radiat Res.* 2005; 163(4):424-432.
  309. Maeda Y, Onishi S, Yamasaki F, et al. Secondary meningioma after cranial irradiation: case series and comprehensive literature review. *Jpn J Clin Oncol.* 2023; 53(3):212-220.
  310. Strojan P, Popović M, Jereb B. Secondary intracranial meningiomas after high-dose cranial irradiation: report of five cases and review of the literature. *Int J Radiat Oncol Biol Phys.* 2000; 48(1):65-73.
  311. Bello MJ, Leone PE, Nebreda P, et al. Allelic status of chromosome 1 in neoplasms of the nervous system. *Cancer Genet Cytogenet.* 1995; 83(2):160-164.
  312. Xu M, Lasocki A, Bressel M, et al. Favourable outcomes with an initial active surveillance strategy for asymptomatic radiation-induced meningiomas in long-term survivors of paediatric and young adult malignancies. *Radiother Oncol.* 2023; 189:109916.
  313. Jensen AW, Brown PD, Pollock BE, et al. Gamma knife radiosurgery of radiation-induced intracranial tumors: local control, outcomes, and complications. *Int J Radiat Oncol Biol Phys.* 2005; 62(1):32-37.
  314. Bunevicius A, Suleiman M, Patel S, et al. Stereotactic radiosurgery for treatment of radiation-induced meningiomas: a multiinstitutional study. *J Neurosurg.* 2021; 135(3):862-870.
  315. Kondziolka D, Kano H, Kanaan H, et al. Stereotactic radiosurgery for radiation-induced meningiomas. *Neurosurgery.* 2009; 64(3):463-469; discussion 469-470.
  316. Kuhn EN, Chan MD, Tatter SB, Ellis TL. Gamma knife stereotactic radiosurgery for radiation-induced meningiomas. *Stereotact Funct Neurosurg.* 2012; 90(6):365-369.
  317. Helseth A, Mørk SJ. Primary intraspinal neoplasms in Norway, 1955 to 1986. A population-based survey of 467 patients. *J Neurosurg.* 1989; 71(6):842-845.

318. Elsamadicy AA, Reeves BC, Craft S, et al. A current review of spinal meningiomas: epidemiology, clinical presentation and management. *J Neurooncol.* 2023; 161(2):395-404.
319. Kobayashi K, Ando K, Matsumoto T, et al. Clinical features and prognostic factors in spinal meningioma surgery from a multicenter study. *Sci Rep.* 2021; 11(1):11630.
320. Hua L, Zhu H, Deng J, et al. Clinical and prognostic features of spinal meningioma: a thorough analysis from a single neurosurgical center. *J Neurooncol.* 2018; 140(3):639-647.
321. Hua L, Alkhatib M, Podlesek D, et al. Two predominant molecular subtypes of spinal meningioma: thoracic NF2-mutant tumors strongly associated with female sex, and cervical AKT1-mutant tumors originating ventral to the spinal cord. *Acta Neuropathol.* 2022; 144(5):1053-1055.
322. Ricklefs FL, Fita KD, Mohme M, et al. Genetic and epigenetic profiling identifies two distinct classes of spinal meningiomas. *Acta Neuropathol.* 2022; 144(5):1057-1059.
323. Sayagués JM, Taberero MD, Maíllo A, et al. Microarray-based analysis of spinal versus intracranial meningiomas: different clinical, biological, and genetic characteristics associated with distinct patterns of gene expression. *J Neuropathol Exp Neurol.* 2006; 65(5):445-454.
324. Nakamura M, Tsuji O, Fujiyoshi K, et al. Long-term surgical outcomes of spinal meningiomas. *Spine (Phila Pa 1976).* 2012; 37(10):E617-623.
325. Misra SN, Morgan HW. Avoidance of structural pitfalls in spinal meningioma resection. *Neurosurg Focus.* 2003; 14(6):e1.
326. Yolcu YU, Goyal A, Alvi MA, Moinuddin FM, Bydon M. Trends in the utilization of radiotherapy for spinal meningiomas: insights from the 2004-2015 National Cancer Database. *Neurosurg Focus.* 2019; 46(6):E6.
327. Golanov AV, Konovalov NA, Antipina NA, et al. Stereotactic radiotherapy for spinal meningiomas and neurinomas. *Zh Vopr Neurokhir Im N N Burdenko.* 2015; 79(1):4-13.
328. Kufeld M, Wowra B, Muacevic A, Zausinger S, Tonn JC. Radiosurgery of spinal meningiomas and schwannomas. *Technol Cancer Res Treat.* 2012; 11(1):27-34.
329. Hwang L, Okoye CC, Patel RB, et al. Stereotactic body radiotherapy for benign spinal tumors: Meningiomas, schwannomas, and neurofibromas. *J Radiosurg SBRT.* 2019; 6(3):167-177.
330. Kotecha RS, Pascoe EM, Rushing EJ, et al. Meningiomas in children and adolescents: a meta-analysis of individual patient data. *Lancet Oncol.* 2011; 12(13):1229-1239.
331. Ostrom QT, Price M, Neff C, et al. CBTRUS Statistical Report: Primary Brain and Other Central Nervous System Tumors Diagnosed in the United States in 2015-2019. *Neuro Oncol.* 2022; 24(Suppl 5):v1-v95.
332. Lin DD, Lin JL, Deng XY, et al. Trends in intracranial meningioma incidence in the United States, 2004-2015. *Cancer Med.* 2019; 8(14):6458-6467.
333. Dudley RWR, Torok MR, Randall S, et al. Pediatric versus adult meningioma: comparison of epidemiology, treatments, and outcomes using the Surveillance, Epidemiology, and End Results database. *J Neurooncol.* 2018; 137(3):621-629.
334. Tauziède-Espariat A, Pfister SM, Mawrin C, Sahn F. Pediatric meningiomas: A literature review and diagnostic update. *Neurooncol Adv.* 2023; 5(Suppl 1):i105-i111.

335. Thuijs NB, Uitdehaag BM, Van Ouwerkerk WJ, van der Valk P, Vandertop WP, Peerdeman SM. Pediatric meningiomas in The Netherlands 1974-2010: a descriptive epidemiological case study. *Childs Nerv Syst.* 2012; 28(7):1009-1015.
336. Kirches E, Sahm F, Korshunov A, et al. Molecular profiling of pediatric meningiomas shows tumor characteristics distinct from adult meningiomas. *Acta Neuropathol.* 2021; 142(5):873-886.
337. Wang Y, Qin X, Liu M, et al. Clear Cell Meningioma in the Central Nervous System: Analysis of Surveillance, Epidemiology, and End Results Database. *Front Oncol.* 2020; 10:592800.
338. Cahill KS, Claus EB. Treatment and survival of patients with nonmalignant intracranial meningioma: results from the Surveillance, Epidemiology, and End Results Program of the National Cancer Institute. Clinical article. *J Neurosurg.* 2011; 115(2):259-267.
339. Szychoł E, Goodden J, Whitfield G, Curry S. Children's Cancer and Leukaemia Group (CCLG): review and guidelines for the management of meningioma in children, teenagers and young adults. *Br J Neurosurg.* 2020; 34(2):142-153.
340. El Beltagy MA, Enayet AE, Atteya MME, et al. Management of pediatric CNS meningiomas: CCH-57357 experience in 39 cases. *Childs Nerv Syst.* 2019; 35(8):1323-1331.
341. Toland A, McNulty SN, Pekmezci M, et al. Pediatric meningioma: a clinicopathologic and molecular study with potential grading implications. *Brain Pathol.* 2020; 30(6):1134-1143.
342. Blakeley JO, Evans DG, Adler J, et al. Consensus recommendations for current treatments and accelerating clinical trials for patients with neurofibromatosis type 2. *Am J Med Genet A.* 2012; 158a(1):24-41.
343. Norden AD, Drappatz J, Wen PY. Advances in meningioma therapy. *Curr Neurol Neurosci Rep.* 2009; 9(3):231-240.
344. Wen PY, Quant E, Drappatz J, Beroukhi R, Norden AD. Medical therapies for meningiomas. *J Neurooncol.* 2010; 99(3):365-378.
345. Battu S, Kumar A, Pathak P, et al. Clinicopathological and molecular characteristics of pediatric meningiomas. *Neuropathology.* 2018; 38(1):22-33.
346. Perry A, Giannini C, Raghavan R, et al. Aggressive phenotypic and genotypic features in pediatric and NF2-associated meningiomas: a clinicopathologic study of 53 cases. *J Neuropathol Exp Neurol.* 2001; 60(10):994-1003.
347. Sievers P, Chiang J, Schimpf D, et al. YAP1-fusions in pediatric NF2-wildtype meningioma. *Acta Neuropathol.* 2020; 139(1):215-218.
348. Szulzewsky F, Arora S, Arakaki AKS, et al. Both YAP1-MAML2 and constitutively active YAP1 drive the formation of tumors that resemble NF2 mutant meningiomas in mice. *Genes Dev.* 2022; 36(13-14):857-870.
349. Maze EA, Agit B, Reeves S, et al. Human Endogenous Retrovirus Type K Promotes Proliferation and Confers Sensitivity to Antiretroviral Drugs in Merlin-Negative Schwannoma and Meningioma. *Cancer Res.* 2022; 82(2):235-247.
350. Ferluga S, Baiz D, Hilton DA, et al. Constitutive activation of the EGFR-STAT1 axis increases proliferation of meningioma tumor cells. *Neurooncol Adv.* 2020; 2(1):vdaa008.
351. Mawrin C. Animal models of meningiomas. *Chin Clin Oncol.* 2017; 6(Suppl 1):S6.

352. Ragel BT, Couldwell WT, Gillespie DL, Wendland MM, Whang K, Jensen RL. A comparison of the cell lines used in meningioma research. *Surg Neurol*. 2008; 70(3):295-307; discussion 307.
353. Baia GS, Dinca EB, Ozawa T, et al. An orthotopic skull base model of malignant meningioma. *Brain Pathology*. 2008; 18(2):172-179.
354. Jungwirth G, Yu T, Moustafa M, et al. Identification of KIF11 As a Novel Target in Meningioma. *Cancers (Basel)*. 2019; 11(4).
355. Jungwirth G, Yu T, Liu F, et al. Pharmacological Landscape of FDA-Approved Anticancer Drugs Reveals Sensitivities to Ixabepilone, Romidepsin, Omacetaxine, and Carfilzomib in Aggressive Meningiomas. *Clin Cancer Res*. 2023; 29(1):233-243.
356. Negroni C, Hilton DA, Ercolano E, et al. GATA-4, a potential novel therapeutic target for high-grade meningioma, regulates miR-497, a potential novel circulating biomarker for high-grade meningioma. *EBioMedicine*. 2020; 59:102941.
357. Iwami K, Natsume A, Ohno M, et al. Adoptive transfer of genetically modified Wilms' tumor 1-specific T cells in a novel malignant skull base meningioma model. *Neuro-Oncology*. 2013; 15(6):747-758.
358. Nigim F, Esaki S, Hood M, et al. A new patient-derived orthotopic malignant meningioma model treated with oncolytic herpes simplex virus. *Neuro Oncol*. 2016; 18(9):1278-1287.
359. Püttmann S, Senner V, Braune S, et al. Establishment of a benign meningioma cell line by hTERT-mediated immortalization. *Laboratory investigation*. 2005; 85(9):1163-1171.
360. Baia GS, Slocum AL, Hyer JD, et al. A genetic strategy to overcome the senescence of primary meningioma cell cultures. *J Neurooncol*. 2006; 78(2):113-121.
361. Ragel BT, Elam IL, Gillespie DL, et al. A novel model of intracranial meningioma in mice using luciferase-expressing meningioma cells. *Laboratory investigation*. *J Neurosurg*. 2008; 108(2):304-310.
362. Peyre M, Stemmer-Rachamimov A, Clermont-Tarancon E, et al. Meningioma progression in mice triggered by Nf2 and Cdkn2ab inactivation. *Oncogene*. 2013; 32(36):4264-4272.
363. Jungwirth G, Hanemann CO, Dunn IF, Herold-Mende C. Preclinical Models of Meningioma. *Adv Exp Med Biol*. 2023; 1416:199-211.
364. Choudhury A, Raleigh DR. Preclinical models of meningioma: Cell culture and animal systems. *Handb Clin Neurol*. 2020; 169:131-136.
365. Meijer TG, Naipal KA, Jager A, van Gent DC. Ex vivo tumor culture systems for functional drug testing and therapy response prediction. *Future Sci OA*. 2017; 3(2):Fso190.
366. Sivakumar R, Chan M, Shin JS, et al. Organotypic tumor slice cultures provide a versatile platform for immuno-oncology and drug discovery. *Oncoimmunology*. 2019; 8(12):e1670019.
367. Chan HSC, Ng HK, Chan AK, et al. Establishment and characterization of meningioma patient-derived organoid. *J Clin Neurosci*. 2021; 94:192-199.
368. Huang M, Xu S, Li Y, et al. Novel Human Meningioma Organoids Recapitulate the Aggressiveness of the Initiating Cell Subpopulations Identified by ScRNA-Seq. *Adv Sci (Weinh)*. 2023; 10(15):e2205525.
369. Yamazaki S, Ohka F, Hirano M, et al. Newly established patient-derived organoid model of intracranial meningioma. *Neuro Oncol*. 2021; 23(11):1936-1948.

370. Magill ST, Vasudevan HN, Seo K, et al. Multiplatform genomic profiling and magnetic resonance imaging identify mechanisms underlying intratumor heterogeneity in meningioma. *Nat Commun.* 2020; 11(1):4803.
371. Tonn JC, Ott MM, Bouterfa H, et al. Inverse correlation of cell proliferation and expression of progesterone receptors in tumor spheroids and monolayer cultures of human meningiomas. *Neurosurgery.* 1997; 41(5):1152-1159.
372. van de Weijer LL, Ercolano E, Zhang T, et al. A novel patient-derived meningioma spheroid model as a tool to study and treat epithelial-to-mesenchymal transition (EMT) in meningiomas. *Acta Neuropathol Commun.* 2023; 11(1):198.
373. Kim D, Park J, Park HC, et al. Establishment of tumor microenvironment-preserving organoid model from patients with intracranial meningioma. *Cancer Cell Int.* 2024; 24(1):36.
374. Millward CP, Armstrong TS, Barrington H, et al. Development of 'Core Outcome Sets' for Meningioma in Clinical Studies (The COSMIC Project): protocol for two systematic literature reviews, eDelphi surveys and online consensus meetings. *BMJ Open.* 2022; 12(5):e057384.
375. Abedalthagafi M, Bi WL, Aizer AA, et al. Oncogenic PI3K mutations are as common as AKT1 and SMO mutations in meningioma. *Neuro-oncology.* 2016; 18(5):649-655.
376. Bleeker F, Felicioni L, Buttitta F, et al. AKT1 E17K in human solid tumours. *Oncogene.* 2008; 27(42):5648-5650.
377. Carpten JD, Faber AL, Horn C, et al. A transforming mutation in the pleckstrin homology domain of AKT1 in cancer. *Nature.* 2007; 448(7152):439-444.
378. Sahm F, Bissel J, Koelsche C, et al. AKT1E17K mutations cluster with meningotheial and transitional meningiomas and can be detected by SFRP1 immunohistochemistry. *Acta neuropathologica.* 2013; 126(5):757-762.
379. Strickland MR, Gill CM, Nayyar N, et al. Targeted sequencing of SMO and AKT1 in anterior skull base meningiomas. *Journal of neurosurgery.* 2017; 127(2):438-444.
380. Cheung M, Testa JR. BAP1, a tumor suppressor gene driving malignant mesothelioma. *Translational Lung Cancer Research.* 2017; 6(3):270.
381. Behling F, Barrantes-Freer A, Skardelly M, et al. Frequency of BRAF V600E mutations in 969 central nervous system neoplasms. *Diagn Pathol.* 2016; 11(1):55.
382. Schindler G, Capper D, Meyer J, et al. Analysis of BRAF V600E mutation in 1,320 nervous system tumors reveals high mutation frequencies in pleomorphic xanthoastrocytoma, ganglioglioma and extra-cerebellar pilocytic astrocytoma. *Acta Neuropathol.* 2011; 121(3):397-405.
383. Bao Z, Hua L, Ye Y, et al. MEF2C silencing downregulates NF2 and E-cadherin and enhances Erastin-induced ferroptosis in meningioma. *Neuro Oncol.* 2021; 23(12):2014-2027.
384. Nikuseva-Martić T, Beros V, Pećina-Slaus N, Pećina HI, Bulić-Jakus F. Genetic changes of CDH1, APC, and CTNNB1 found in human brain tumors. *Pathol Res Pract.* 2007; 203(11):779-787.
385. Collord G, Tarpey P, Kurbatova N, et al. An integrated genomic analysis of anaplastic meningioma identifies prognostic molecular signatures. *Scientific reports.* 2018; 8(1):1-13.



386. Chapman EJ, Harnden P, Chambers P, Johnston C, Knowles MA. Comprehensive analysis of CDKN2A status in microdissected urothelial cell carcinoma reveals potential haploinsufficiency, a high frequency of homozygous co-deletion and associations with clinical phenotype. *Clin Cancer Res.* 2005; 11(16):5740-5747.
387. Goutagny S, Yang HW, Zucman-Rossi J, et al. Genomic profiling reveals alternative genetic pathways of meningioma malignant progression dependent on the underlying NF2 status. *Clin Cancer Res.* 2010; 16(16):4155-4164.
388. Guyot A, Duchesne M, Robert S, et al. Analysis of CDKN2A gene alterations in recurrent and non-recurrent meningioma. *Journal of Neuro-Oncology.* 2019; 145(3):449-459.
389. Guyot A, Duchesne M, Robert S, et al. Analysis of CDKN2A gene alterations in recurrent and non-recurrent meningioma. *J Neurooncol.* 2019; 145(3):449-459.
390. Ruas M, Peters G. The p16INK4a/CDKN2A tumor suppressor and its relatives. *Biochim Biophys Acta.* 1998; 1378(2):F115-177.
391. Yang HW, Kim TM, Song SS, et al. Alternative splicing of CHEK2 and codeletion with NF2 promote chromosomal instability in meningioma. *Neoplasia.* 2012; 14(1):20-28.
392. Gutmann DH, Donahoe J, Perry A, et al. Loss of DAL-1, a protein 4.1-related tumor suppressor, is an important early event in the pathogenesis of meningiomas. *Hum Mol Genet.* 2000; 9(10):1495-1500.
393. Martinez-Glez V, Bello MJ, Franco-Hernandez C, et al. Mutational analysis of the DAL-1/4.1B tumour-suppressor gene locus in meningiomas. *Int J Mol Med.* 2005; 16(4):771-774.
394. Perry A, Cai DX, Scheithauer BW, et al. Merlin, DAL-1, and progesterone receptor expression in clinicopathologic subsets of meningioma: a correlative immunohistochemical study of 175 cases. *J Neuropathol Exp Neurol.* 2000; 59(10):872-879.
395. Harmanci AS, Youngblood MW, Clark VE, et al. Integrated genomic analyses of de novo pathways underlying atypical meningiomas. *Nat Commun.* 2017; 8:14433.
396. Zeng J, Sun L, Huang J, Yang X, Hu W. Enhancer of zeste homolog 2 is a negative prognostic biomarker and correlated with immune infiltrates in meningioma. *Front Neurosci.* 2022; 16:1076530.
397. Pereira BJA, Marcondes Lerario A, Sola PR, et al. Impact of a cell cycle and an extracellular matrix remodeling transcriptional signature on tumor progression and correlation with EZH2 expression in meningioma. *J Neurosurg.* 2023; 138(3):649-662.
398. Kar R, Jha SK, Ojha S, et al. The FBXW7-NOTCH interactome: A ubiquitin proteasomal system-induced crosstalk modulating oncogenic transformation in human tissues. *Cancer Rep (Hoboken).* 2021; 4(4):e1369.
399. Barresi V, Simbolo M, Fioravanzo A, et al. Molecular Profiling of 22 Primary Atypical Meningiomas Shows the Prognostic Significance of 18q Heterozygous Loss and CDKN2A/B Homozygous Deletion on Recurrence-Free Survival. *Cancers (Basel).* 2021; 13(4).
400. Johnson MD, O'Connell MJ, Pilcher W, Reeder JE. Fibroblast growth factor receptor-3 expression in meningiomas with stimulation of proliferation by the phosphoinositide 3 kinase-Akt pathway. *J Neurosurg.* 2010; 112(5):934-939.

401. AlSahlawi A, Aljelaify R, Magrashi A, et al. New insights into the genomic landscape of meningiomas identified FGFR3 in a subset of patients with favorable prognoses. *Oncotarget*. 2019; 10(53):5549-5559.
402. Maggio I, Franceschi E, Tosoni A, et al. Meningioma: not always a benign tumor. A review of advances in the treatment of meningiomas. *CNS Oncol*. 2021; 10(2):Cns72.
403. Di Giammartino DC, Kloetgen A, Polyzos A, et al. KLF4 is involved in the organization and regulation of pluripotency-associated three-dimensional enhancer networks. *Nature Cell Biology*. 2019; 21(10):1179-1190.
404. Parada CA, Osburn JW, Busald T, et al. Phosphoproteomic and Kinomic Signature of Clinically Aggressive Grade I (1.5) Meningiomas Reveals RB1 Signaling as a Novel Mediator and Biomarker. *Clin Cancer Res*. 2020; 26(1):193-205.
405. Tang H, Zhu H, Wang X, et al. KLF4 is a tumor suppressor in anaplastic meningioma stem-like cells and human meningiomas. *Journal of molecular cell biology*. 2017; 9(4):315-324.
406. von Spreckelsen N, Waldt N, Poetschke R, et al. KLF4 K409Q-mutated meningiomas show enhanced hypoxia signaling and respond to mTORC1 inhibitor treatment. *Acta neuropathologica communications*. 2020; 8(1):1-11.
407. Youngblood MW, Miyagishima DF, Jin L, et al. Associations of meningioma molecular subgroup and tumor recurrence. *Neuro Oncol*. 2021; 23(5):783-794.
408. Shapiro IM, Kolev VN, Vidal CM, et al. Merlin deficiency predicts FAK inhibitor sensitivity: a synthetic lethal relationship. *Science translational medicine*. 2014; 6(237):237ra268-237ra268.
409. Stamenkovic I, Yu Q. Merlin, a “magic” linker between the extracellular cues and intracellular signaling pathways that regulate cell motility, proliferation, and survival. *Current Protein and Peptide Science*. 2010; 11(6):471-484.
410. Leone PE, Bello MJ, de Campos JM, et al. NF2 gene mutations and allelic status of 1p, 14q and 22q in sporadic meningiomas. *Oncogene*. 1999; 18(13):2231-2239.
411. Cômes PC, Le Van T, Tran S, et al. Respective roles of Pik3ca mutations and cyproterone acetate impregnation in mouse meningioma tumorigenesis. *Cancer Gene Ther*. 2023; 30(8):1114-1123.
412. Peyre M, Miyagishima D, Bielle F, et al. Somatic PIK3CA Mutations in Sporadic Cerebral Cavernous Malformations. *N Engl J Med*. 2021; 385(11):996-1004.
413. Hadfield KD, Smith MJ, Trump D, Newman WG, Evans D. SMARCB1 mutations are not a common cause of multiple meningiomas. *Journal of medical genetics*. 2010; 47(8):567-568.
414. Dhamija R, Plotkin S, Gomes A, Babovic-Vuksanovic D. LZTR1- and SMARCB1-Related Schwannomatosis. In: Adam MP, Mirzaa GM, Pagon RA, et al., eds. *GeneReviews*(®). Seattle (WA): University of Washington, Seattle
- Copyright © 1993-2023, University of Washington, Seattle. GeneReviews is a registered trademark of the University of Washington, Seattle. All rights reserved.; 1993.
415. Boetto J, Bielle F, Sanson M, Peyre M, Kalamarides M. SMO mutation status defines a distinct and frequent molecular subgroup in olfactory groove meningiomas. *Neuro-oncology*. 2017; 19(3):345-351.

416. Findakly S, Choudhury A, Daggubati V, Pekmezci M, Lang UE, Raleigh DR. Meningioma cells express primary cilia but do not transduce ciliary Hedgehog signals. *Acta Neuropathol Commun.* 2020; 8(1):114.
417. Askaner G, Lei U, Bertelsen B, Venzo A, Wadt K. Novel SUFU Frameshift Variant Leading to Meningioma in Three Generations in a Family with Gorlin Syndrome. *Case Reports in Genetics.* 2019; 2019.
418. Smith MJ. Germline and somatic mutations in meningiomas. *Cancer Genet.* 2015; 208(4):107-114.
419. Biczok A, Kraus T, Suchorska B, et al. TERT promoter mutation is associated with worse prognosis in WHO grade II and III meningiomas. *Journal of neuro-oncology.* 2018; 139(3):671-678.
420. Horn S, Figl A, Rachakonda PS, et al. TERT promoter mutations in familial and sporadic melanoma. *Science.* 2013; 339(6122):959-961.
421. Juratli TA, Thiede C, Koerner MV, et al. Intratumoral heterogeneity and TERT promoter mutations in progressive/higher-grade meningiomas. *Oncotarget.* 2017; 8(65):109228.
422. Zotti T, Scudiero I, Vito P, Stilo R. The emerging role of TRAF7 in tumor development. *Journal of cellular physiology.* 2017; 232(6):1233-1238.
423. Chamberlain MC, Tsao-Wei DD, Groshen S. Temozolomide for treatment-resistant recurrent meningioma. *Neurology.* 2004; 62(7):1210-1212.
424. Wen PY, Yung WK, Lamborn KR, et al. Phase II study of imatinib mesylate for recurrent meningiomas (North American Brain Tumor Consortium study 01-08). *Neuro Oncol.* 2009; 11(6):853-860.
425. Norden AD, Raizer JJ, Abrey LE, et al. Phase II trials of erlotinib or gefitinib in patients with recurrent meningioma. *J Neurooncol.* 2010; 96(2):211-217.
426. Reardon DA, Norden AD, Desjardins A, et al. Phase II study of Gleevec® plus hydroxyurea (HU) in adults with progressive or recurrent meningioma. *J Neurooncol.* 2012; 106(2):409-415.
427. Ji Y, Rankin C, Grunberg S, et al. Double-Blind Phase III Randomized Trial of the Antiprogestin Agent Mifepristone in the Treatment of Unresectable Meningioma: SWOG S9005. *J Clin Oncol.* 2015; 33(34):4093-4098.
428. Karsy M, Hoang N, Barth T, et al. Combined Hydroxyurea and Verapamil in the Clinical Treatment of Refractory Meningioma: Human and Orthotopic Xenograft Studies. *World Neurosurg.* 2016; 86:210-219.
429. Brastianos PK, Twohy EL, Gerstner ER, et al. Alliance A071401: Phase II Trial of Focal Adhesion Kinase Inhibition in Meningiomas With Somatic NF2 Mutations. *Journal of Clinical Oncology.* 2023; 41(3):618-628.
430. Jordan JT, Orr CC, Thalheimer RD, et al. Prospective phase II trial of the dual mTORC1/2 inhibitor vistusertib for progressive or symptomatic meningiomas in persons with neurofibromatosis 2. *Neurooncol Adv.* 2023; 5(1):vdad041.

## Figure Legends:

**Figure 1.** (A) Distribution of all primary brain tumors (malignant and non-malignant combined; five-year total = 453,623; annual average cases = 90,725) by histopathology. (B) Distribution of all non-malignant primary brain tumors (five-year total = 326,894; average annual cases = 65,379) by histopathology. (C) Annual age-adjusted incidence rates of meningioma based on sex, ethnicity, and race. (D) Incidence rate ratios by sex (female-to-male) for selected primary brain and other CNS tumor histopathologies with malignant and non-malignant meningiomas highlighted. (E) Female-to-male incidence rate ratios and 95% confidence intervals (CI) for meningioma, by age group at diagnosis and stratified by WHO tumor grade. (F) Incidence rate ratios by race (White:Black and White:Asian or Pacific Islander [API]) for selected primary brain and other CNS tumor histopathologies with malignant and non-malignant meningiomas highlighted. (G) Average annual age-adjusted incidence rate and 95% confidence interval (CI) for meningioma by race/ethnicity and stratified by grade. Incidence rate ratios (IRR) and their 95% CI appear above bars and are calculated relative to non-Hispanic White individuals as the reference. Rates are age-adjusted to the 2000 US standard population. CBTRUS statistical report: US Cancer Statistics – National Program of Cancer Registries (NPCR) and the Surveillance, Epidemiology, and End Results (SEER), 2016-2020.<sup>1,3</sup> Image panels A-D, F reused with permission from Ostrom et al. (2023)<sup>1</sup>. Image panels E, G reused with permission from Walsh et al. (2023)<sup>3</sup>. GBM- glioblastoma; CBTRUS- Central Brain Tumor Registry of the United States.

**Figure 2.** Updated 2021 World Health Organization (WHO) Grading criteria for meningiomas including histological subtypes for CNS WHO grade 1 cases: (A) meningothelial, (B) fibrous, (C) transitional, (D) psammomatous, (E) secretory, (F) angiomatous, (G) microcystic, (H) lymphoplasmacyte-rich, (I) metaplastic; CNS WHO grade 2 cases: (J) atypical, (K) clear cell, (L) chordoid; and CNS WHO grade 3 cases: (M) anaplastic, (N) papillary, (O) rhabdoid. HPF- high-powered fields; N:C- nuclear to cytoplasm. Histological image panels (A-O) used with permission from Bi et al. (2016).<sup>91</sup> CNS- central nervous system; HPF- high powered fields; N:C- nuclear to cytoplasm; TERT- telomerase reverse transcriptase.

**Figure 3.** (A) Different meningioma molecular/methylation classifications discovered by independent groups arranged based on approximately how they correlate with one another based on common biology, alterations, and outcome (read from top to bottom). (B) Relative distribution of meningiomas belonging to each WHO grade in each molecular or methylation group. (C) Relative proportion of meningiomas based on location in either a skull base or non-skull base location in the supratentorial or infratentorial compartment in datasets where tumor location was available. (D) Key transcriptomic pathways found to be overexpressed in meningiomas belonging to each molecular or methylation group, grouped into 4 main set of pathways. (E) Relative distribution of common meningioma driver mutations found in cases with more benign biology (left) and more biologically aggressive cases (right). (F) Proportion of different chromosomal alterations seen in each molecular or methylation group. (G) PFS of meningiomas belonging to each recently published molecular or methylation groups based on the original publication's cohort. These groups may not correlate with one another precisely on a one-to-one basis and as a result, the PFS curves of different groups may be repeated in different panels. For instance, while many meningiomas from the Ben-3 methylation subclass share commonalities with Merlin-intact or NF2-wildtype cases (e.g. absence of 22q deletions, presence of chromosome 5 gain,

angiomatous histology), some cases may classify into other molecular groups e.g. immunogenic or hypermetabolic groups. Similarly, some cases of Ben-3 do have 22q deletions as well. Int-A and Int-B meningiomas may not precisely separate into hypermetabolic and proliferative cases. PMCRT- Princess Margaret Cancer Research Tower; DKFZ- German Cancer Research Center; UCSF- University of California San Francisco; MM-FAV- meningioma methylation group favorable; MM-UNFAV- meningioma methylation group unfavorable; Ben- benign; Int- intermediate; Mal- malignant; MG- Molecular Group; MenG- Meningioma Group; NF2- neurofibromatosis 2; TRAF7- Tumor necrosis factor receptor associated factor 7; KLF4- Krüppel-like factor 4; AKT1- RAC(Rho family)-alpha serine/threonine-protein kinase; SMO- Smoothed; PIK3CA- phosphatidylinositol-4,5-bisphosphate 3-kinase, catalytic subunit alpha; DNA-directed RNA polymerase II subunit RPB1; TERTp- Telomerase reverse transcriptase promoter; CDKN2A/B- cyclin-dependent kinase inhibitor 2A/B

**Figure 4:** (A) Postoperative magnetic resonance imaging suggesting a gross total resection with contrast enhancing reactive changes only. (B) Positron emission tomography (PET) imaging showing focal uptake along the cribriform plate (standardized uptake value 7.43, white arrow) suspicious for residual disease. (C) Follow-up MRI 2-years later after patient declined to pursue recommended adjuvant radiotherapy with increased enhancing soft tissue signal (green arrow). (D) Increased focal PET uptake in the cribriform plate suggesting progression of residual disease (standardized uptake value 8.96, yellow arrow). (E) Axial brain MRI of a 54-year-old woman with newly diagnosed breast cancer metastatic to axillary lymph nodes who was noted to have asymmetric photopenia in the left cerebellum on a staging fluorodeoxyglucose (FDG)-position emission tomography (PET) and computer tomography (CT) scan (left). T1 post-contrast brain magnetic resonance imaging (MRI) showed a multilobulated, homogeneously enhancing extra-axial mass adjacent to the left petrous temporal bone with associated edema and mass effect in the left cerebellum and cerebellar peduncle (middle). Leading differential diagnoses included a distant metastasis or a meningioma. DOTATATE PET/MRI showed markedly avid uptake in the intracranial mass (right), but not in the right breast or ipsilateral lymph nodes (not shown). A diagnosis of synchronous meningioma and locoregionally advanced breast cancer was made. The meningioma was treated with stereotactic radiosurgery. The patient underwent lumpectomy, sentinel lymph node biopsy, and adjuvant whole breast radiotherapy. At 24 months after meningioma treatment and 13 months after breast cancer treatment, the patient had no evidence of disease. (F) Sagittal T1 post-contrast brain MRI (left) and DOTATATE PET (right) of a 61-year-old male with recurrent atypical meningioma, CNS WHO grade 2, status post resection and stereotactic radiosurgery 8 years before developing multiple vertex recurrences that were treated with subtotal resection. Planning DOTATATE PET imaging revealed extensive tumor infiltration of the sagittal sinus from the vertex to the torcula. Part of this figure was originally published in *The International Journal of Radiation Oncology, Biology, Physics*. Prasad et al. <sup>68</sup>Ga-DOTATATE PET: The Future of Meningioma Treatment (2022).<sup>152</sup> FDG- fluorodeoxyglucose; MRI- magnetic resonance imaging; PET- positron emission tomography; used with permission.

**Figure 5.** Summary of most contemporary treatment guidelines for the management of meningiomas based on WHO grade, extent of resection, with the incorporation of molecular data if available. Content for this figure was partly adopted from Goldbrunner et al. EANO Guideline on The Diagnosis and Treatment of Meningiomas (2021) published in *Neuro-Oncology*.<sup>127</sup> Used with permission. MRI- magnetic resonance imaging; SRS- stereotactic radiosurgery; fRT- fractionated external beam radiotherapy; GTR- gross total resection; STR- subtotal resection

Accepted Manuscript

**Table 1.** Recurrent mutations associated with meningiomas. While some genes and their alterations have been well investigated by multiple independent groups, others may have been identified in only single or small cohorts of meningiomas. Consequently, the overall frequencies of less studied mutations may be confounded by smaller cohorts biased to include either more benign or clinically aggressive cases from which the data is obtained.

Gene	Location	Protein	Gene status	Frequency (%)	WHO Grade	Modification	Associated Meningioma Phenotype	Effect of Modification	Reference
<b>AKT1</b>	14q32.33	protein kinase B alpha, beta, and gamma	Oncogene	10	1	Point mutation	Anterior/middle skull base location, NF2-wildtype meningiomas	Conformational change in protein, altering its localization from the cytoplasm to the plasma membrane, resulting in constitutive activation of the AKT1 kinase and activation of mTOR and ERK1/2 signalling pathways	38,39,41,375-379
<b>ARID1A</b>	1p36.11	AT-rich interaction domain 1A	Tumor suppressor	5	2, 3	Frameshift mutation	Recurrent and high-grade cases	Destabilizes SWI/SNF complex which normally modulates DNA accessibility for cellular processes involved in chromatin structure including transcription, DNA replication and repair,	38,59-61,89

								resulting in global deregulation of gene transcription	
<b>BAP1</b>	3p21.1	BRCA1 associated protein 1	Tumor suppressor	<1	2, 3	Splice site, nonsense, frameshift mutation	Rhabdoid and papillary histology	Impaired nuclear localization of a ubiquitin carboxy-terminal hydrolase that normally has tumor suppressor activity when bound to BRCA1 or BARD1	38,45,53,62,70,71,380
<b>BRAF (V600E)</b>	7p34	B-Raf proto-oncogene	Oncogene	<1	3	Point mutation	Rhabdoid histology	Mimics phosphorylation of nearby serine and threonine residues resulting in BRAF activation and subsequent activation of the MAP kinase/ERK-signaling pathway	43,93,381,382
<b>CDH1</b>	16q22	E-cadherin	Tumor suppressor	30	1-3	Deletion, nonsense mutation	Unknown	Activation of wnt signaling via dysregulation of $\beta$ -catenin and the APC protein, resulting in upregulation of cell cycling programs including c-myc and cyclin D1 pathways	383-385



<b><i>CDKN2A/B</i></b>	9p21.3	p16, p15 <sup>INK4b</sup>	Tumor suppressor	1-5	3	Deletion	Anaplastic, biologically aggressive meningiomas	Loss of inhibition of CDK4 and CDK6 mediated phosphorylation of retinoblastoma family of proteins, leading to unchecked cell cycle progression from G1 to S-phase	2,38,92,93,96,98,101,119,386-390
<b><i>CDKN2C</i></b>	1p32.3	Cyclin-dependent kinase 4 inhibitor C (p18)	Tumor suppressor	1	2	Nonsense mutation	Atypical and anaplastic meningiomas	Activation of CDK4 and CDK6 resulting in loss of control of cell growth regulation and subsequent cell cycle G1 progression	92,96
<b><i>CHEK2</i></b>	22q12.1	Checkpoint kinase 2 (Chk2)	Tumor suppressor	50	1-3	Deletion, frameshift mutation	NF2-altered meningiomas	Defect in DNA homologous recombination or nonhomologous end joining pathways following DNA damage including double-stranded DNA breaks resulting in increased chromosomal instability	341,391
<b><i>Dal-1</i></b>	18p11.3	Protein 4.1B	Tumor suppressor	50-80	1-3	Deletion, nonsense mutation	Multiple meningiomas, sporadic meningiomas	Dysregulation of cell-cell contact inhibition growth arrest normally mediated through actin cytoskeletal-	346,392-394

								associated proteins resulting in similar downstream effects as NF2 inactivation	
<b>EZH2</b>	7q36.1	Enhancer of zeste homolog 2	Oncogene	1-5	2-3	Point mutation, amplification	Higher grade meningiomas	Dysregulation of catalytic subgroup of PRC2 complex, upregulation of proliferative genes in the cell cycle-retinoblastoma-E2F pathway	395-397
<b>FBXW7</b>	4q31.3	F-box and WD repeat domain containing 7	Tumor suppressor	1-5	1-3	Frameshift mutation	NF2-altered meningiomas	Deregulation of ubiquitin-mediated proteolysis of oncoproteins such as cyclin E, notch, c-Jun, c-Myc, mTOR resulting in increased tumorigenesis	398,399
<b>FGFR3</b>	4p16.3	Fibroblast growth factor receptor 3	Oncogene	15	1-2	Missense mutation	Skull base location, NF2-wildtype meningiomas	Increased mitogenic signaling from FGF receptors/kinases via activation of the PI3K-Akt-p70 <sup>S6K</sup> pathway and activation of STAT3	400,401
<b>KDM6A</b>	Xp11.3	Lysine demethylase 6A (UTX)	Tumor suppressor	5	2-3	Deletion	NF2-altered, higher grade meningiomas	Dysregulation of polycomb repressive complex (PRC2) catalyzed histone	38,402

								methylation including of H3K27	
<b><i>KLF4</i></b>	9p31	Krüppel-like factor 4	Tumor suppressor	10-15	1	Missense mutation	Skull base location, secretory meningiomas (when combined with <i>TRAF7</i> mutation)	Deactivation of CDKN1A (cyclin-dependent kinase inhibitor p21) resulting in cell proliferation, and loss of inhibition of CDK1 transcription	10,39,45,132,403-407
<b><i>NF2</i></b>	22q12.2	Merlin	Tumor suppressor	40-60	1-3	Deletion, nonsense mutation	Non-skull base location	Dysregulation of several essential cell proliferation and survival pathways including loss of cell-to-cell contact inhibition, activation of hippo pathway, mTOR/PI3K/AKT pathway and receptor tyrosine kinases	33-35,37,64,91,92,109,175,346,387,394,408-410
<b><i>PIK3CA</i></b>	3q26.32	Phosphatidylinositol-4,5-bisphosphate 3-kinase, catalytic subunit alpha (p110 $\alpha$ protein)	Oncogene	5	1	Point, missense mutation	Skull base location, benign WHO grade 1, progesterin-related meningiomas	Activation of PI3 kinase and PI3K/AKT pathway resulting in downstream signaling cascades mediating cell survival. Apoptosis, transformation, metastasis, and cell migration	42-44,411,412

<b>POLR2A</b>	17p13.1	RNA polymerase II subunit A	Oncogene	5	1	Missense mutation	Skull base, tuberculum sellae location, benign WHO grade 1 meningiomas, meningothelial histology	Activation of catalytic subunit of RNA polymerase II, hijacking enzyme and driving cell proliferation and neoplastic progression	40,45,407
<b>PBRM1</b>	3p21.1	Protein polybromo-1	Tumor suppressor	1	3	Nonsense mutation, deletion	Papillary histology	Dysregulation of SWI/SNF chromatin remodeling complex, dysfunctional repair of DNA double-stranded breaks via ATM phosphorylation	38,54
<b>PTEN</b>	10q23.31	Phosphatase and tensin homolog	Tumor suppressor	2-6	2, 3	Frameshift mutation, deletion, rearrangement	Biologically aggressive, proliferative meningiomas	Dysregulation of AKT/PI3K pathway in the cell cytoplasm resulting from loss of feedback inhibition of AKT and subsequent uncontrolled cell cycle progression	38,62-64
<b>SMARCB1</b>	22q11.23	SWI/SNF-related matrix-associated actin-dependent regulator of chromatin subfamily B member 1	Tumor suppressor	<5	2, 3	Missense mutation	NF2-altered, atypical meningiomas	Inactivation of core subunit of SWI/SNF chromatin remodeling complex resulting in aberrant enhancer and promoter regulation and subsequent loss of transcriptional control	61,413,414

<b>SMARCE1</b>	17q21.2	SWI/SNF-related matrix-associated actin-dependent regulator of chromatin subfamily E member 1	Tumor suppressor	<1	1	Splice site, nonsense, frameshift mutation	Clear cell histology	Inactivation of subunit of SWI/SNF chromatin remodeling complex resulting in loss of apoptosis induction via tumor suppressor gene <i>CYLD</i> and other pathways	47-51,69
<b>SMO</b>	7p32.1	Smoothed	Oncogene	3-5	1	Point mutation	Anterior medial skull base location	Activation of the sonic hedgehog (SHH) signalling pathway resulting in cell proliferation, differentiation, and angiogenesis	39,41,42,379,415,416
<b>SUFU</b>	10q24.32	Suppressor of fused homolog	Tumor suppressor	1-2	2-3	Frameshift mutation	Familial multiple meningiomas	Abnormal constitutive upregulation of downstream Gli mediated transcription factors in SHH pathway	74,75,417,418
<b>TERTp</b>	5p15.33	Telomerase reverse transcriptase promoter	Oncogene	5.5	3	Point mutation	Biologically aggressive, high grade meningiomas	Activation of telomerase-mediated telomere stabilization resulting in delayed replicative senescence and increased telomere-driven genomic instability	56-59,419-421

<b>TRAF7</b>	16p13.3	TNF receptor associated factors 7	Tumor suppressor	20-25	1	Missense mutation	Skull base location, brain invasion	Disruption of catalytic activity of E3 ubiquitin ligase interaction with MAPK pathway and RAS GTPases, altering actin dynamics and promoting anchorage-independent growth	39,132,422
--------------	---------	-----------------------------------	------------------	-------	---	-------------------	-------------------------------------	---	------------

**Table 2.** Recurrent copy number alterations observed in meningiomas and their association with clinical prognosis (when known).

Chromosome arm/gene	Loss/Gain	Approximate frequency in all meningiomas	Associated clinical prognosis
1p	Loss	30-50%	Intermediate to poor
1q	Gain	5%	Poor
3p	Loss	10-15%	Intermediate
4p/q	Loss	5-10%	Intermediate to poor
5p/q	Gain	2-3%	Good
6q	Loss	15-20%	Poor
7p	Loss	<5%	Intermediate-poor
8p	Gain	<5%	Unknown
10q	Loss	10%	Poor
11q	Loss	5%	Intermediate
12p/q	Gain	2-3%	Good
14q	Loss	20%	Poor
15q	Gain	<5%	Unknown
16q	Gain	5%	Unknown
17q	Gain	5-10%	Unknown
18q	Loss	15-20%	Poor
20q	Gain	10%	Unknown
22q	Loss	50-60%	Intermediate to poor

**Table 3.** Selected completed and published clinical trials on systemic therapy in meningiomas. WHO- World Health Organization; KPS- Karnofsky performance score; PFS-6/24 progression free survival at 6/24 months; PO- per os; IM- intramuscular; IV- intravenous; EORTC- European Organization for Research and Treatment of Cancer; NF2- neurofibromatosis-2 (NF2-SWN); BID- twice per day

Corresponding Author	Year	Study Title	Study Population and Key Eligibility Criteria	Total patients	Systemic/Experimental Agent	Primary Endpoint	Outcome	+/- Primary Outcome	Ref
Chamberlain	2004	Temozolomide for treatment-resistant recurrent meningioma	Progressive WHO grade 1 meningiomas and KPS $\geq$ 60	16	Temozolomide (75 mg/m <sup>2</sup> for 42 days followed by 28 day break)	PFS-6	0%	-	423
Wen	2009	Phase II study of imatinib mesylate for recurrent meningiomas (North American Brain Tumor Consortium study 01-08)	Recurrent meningiomas with KPS $\geq$ 60	23 (13 benign (WHO grade 1), 5 atypical (WHO grade 2), 5 malignant (WHO grade 3))	Imatinib (600-800 mg PO daily)	PFS-6	29.4% (45% for benign, 0% for atypical or malignant)	-	424
Wen	2010	Phase II trials of erlotinib or gefitinib in patients with recurrent meningioma	Recurrent meningiomas and KPS $\geq$ 60	25 (16 gefitinib, 9 erlotinib)	Gefitinib (500-1000 mg PO daily), erlotinib (150 mg PO daily)	PFS-6	28% (25% gefitinib, 33% erlotinib)	-	425
Reardon	2011	Phase II study of Gleevec <sup>®</sup> plus hydroxyurea (HU) in adults with progressive or recurrent meningioma	Progressive/recurrent meningioma and KPS $\geq$ 60	21	Hydroxyurea (500 mg PO BID) and Imatinib (400-800 mg PO daily)	PFS-6	61.9% (87.5% WHO grade 1, 46.2% WHO grade 2/3)	+	426
Wen	2014	Phase II study of monthly pasireotide LAR (SOM230C) for recurrent or progressive meningioma	Recurrent or progressive meningioma with KPS $\geq$ 60	34 (18 cohort A/malignant, 16 cohort B/benign)	Pasireotide (60 mg LAR IM monthly)	PFS-6	17% cohort A, 50% cohort B	-	253
Kaley	2014	Phase II trial of sunitinib for recurrent and progressive atypical and anaplastic meningioma	Refractory recurrent WHO grade 2-3 meningiomas	36	Sunitinib 50 mg PO daily	PFS-6	42%	+	243



Raizer	2014	A phase II trial of PTK787/ZK 222584 in recurrent or progressive radiation and surgery refractory meningiomas	Surgery and radiotherapy refractory recurrent meningiomas and KPS $\geq$ 60	22 (14 WHO grade 2, 8 WHO grade 3)	PTK787/ZK 222584 (500 mg PO BID)	PFS-6	54.4% (64.3% WHO grade 2, 37.5% WHO grade 3)	+	244
Versc hraeg en	2015	Double-Blind Phase III Randomized Trial of the Antiprogestin Agent Mifepristone in the Treatment of Unresectable Meningioma: SWOG S9005	Progressive or refractory meningioma with prior radiotherapy, PS 0-2	164 (80 mifepristone, 84 placebo)	Mifepristone (200 mg PO daily)	PFS-24	30% mifepristone, 33% placebo	-	427
Jense n	2016	Combined Hydroxyurea and Verapamil in the Clinical Treatment of Refractory Meningioma: Human and Orthotopic Xenograft Studies	Refractory recurrent/progressive meningiomas with KPS $\geq$ 90	7	Hydroxyurea (20 mg/kg/day PO BID), Verapamil (120-240 mg PO daily)	PFS-6	85%	-	428
Grail on	2020	Everolimus and Octreotide for Patients with Recurrent Meningioma: Results from the Phase II CEVOREM Trial	Progressive meningioma ineligible for further surgery/radiotherapy with KPS $>$ 50	20	Everolimus (10 mg PO daily) and octreotide (30 mg LAR IM monthly)	PFS-6	55%	+	256
Reard on	2021	Activity of PD-1 blockade with nivolumab among patients with recurrent atypical/anaplastic meningioma: phase II trial results	WHO grade 2 or 3 recurrent meningiomas with KPS $\geq$ 70	25	Nivolumab (240mg IV q2weeks)	PFS-6	42.40%	-	260
Preus ser	2022	Trabectedin for recurrent WHO grade 2 or 3 meningioma: A randomized phase II study of the EORTC Brain Tumor Group (EORTC-1320-BTG)	Recurrent WHO grade 2 or 3 meningiomas with PS 0-2	90 (61 trabectedin, 29 standard of care)	Trabectedin (1.5 mg/m <sup>2</sup> q3weeks)	PFS-6	2.4 months Trabectedin, 4.2 months standard of care	-	247
Kumt hekar	2022	A multi-institutional phase II trial of bevacizumab for recurrent and refractory meningioma	Progressive meningiomas with KPS $\geq$ 60	42 (10 WHO grade 2, 20 WHO grade 2, 12 WHO grade 3)	Bevacizumab (10 mg/kg IV q2weeks for 6 months, then 15 mg/kg IV q3weeks)	PFS-6	90% WHO grade 1, 76% WHO grade 2, 45% WHO grade 3	+	248

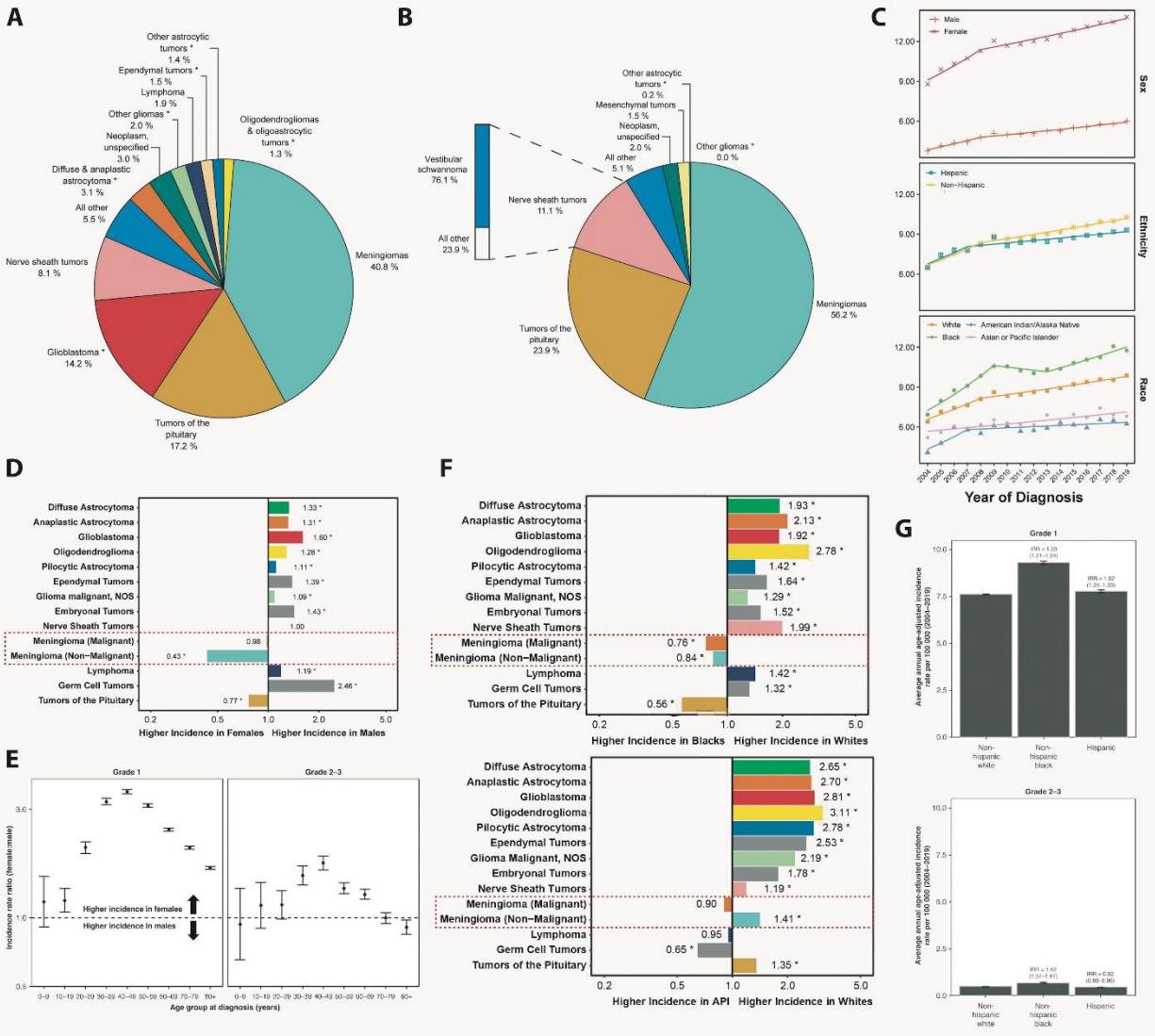
Brastianos	2022	Alliance A071401: Phase II Trial of Focal Adhesion Kinase Inhibition in Meningiomas with Somatic <i>NF2</i> Mutations	WHO grade 1-3 recurrent or progressive meningiomas with <i>NF2</i> mutation	36 (12 WHO grade 1, 24 WHO grade 2/3)	GSK2256098 750 mg PO BID	PFS-6	83% WHO grade 1, 33% WHO grades 2/3	+	429
Plotkin	2023	Prospective phase II trial of the dual mTORC1/2 inhibitor vistusertib for progressive or symptomatic meningiomas in persons with neurofibromatosis 2	<i>NF2</i> patients with progressive or symptomatic meningiomas	18	Vistusertib (125 mg PO BID for 2 days per week)	Volume decrease > 20%	6% partial response, 94% stable disease	-	430

**Table 4.** Selected ongoing clinical trials on systemic therapies in meningiomas. WHO- World Health Organization; NCT- National Clinical Trial; CGE- Cobalt Gray Equivalent; KPS- Karnofsky Performance Score; PFS-6/12- Progression-free survival at 6/12 months; CR- complete response; PR- partial response; CNS- central nervous system; PO- per os; BID- twice per day.

Principal Investigator	Estimated Completion	Study Design	Study Population and Key Eligibility Criteria	Systemic/Experimental Agent	Primary Endpoint	NCT #
Jiayi Huang	2023	Neoadjuvant Avelumab and Hypofractionated Proton Radiation Therapy Followed by Surgery for Recurrent Radiation-refractory Meningioma	WHO grade 1-3 meningioma which has failed maximal safe resection + radiation therapy	Avelumab (10 mg/kg IV q2weeks for 3 months), proton therapy (20 CGE/5 daily fractions of 4 CGE per day)	CD8+/CD4 + tumor infiltrating lymphocytes	NC T03 267 836
David A. Reardon	2024	An Open-Label Phase II Study of Nivolumab and Ipilimumab in Adult Participants with Progressive/Recurrent Meningioma	Progressive or recurrent meningiomas with KPS $\geq$ 70	Nivolumab (240 mg q2 weeks), Ipilimumab 1 mg/kg q3weeks)	PFS-6	NC T02 648 997
Priya Kumthekar	2024	Optune Delivered Electric Field Therapy and Bevacizumab in Treating Patients with Recurrent or Progressive Grade 2 or 3 Meningioma	Progressive or recurrent meningiomas KPS $\geq$ 60	Bevacizumab IV dose not specified, electric field therapy using Optune daily over 18 hours	PFS-6	NC T02 847 559
Priscilla K. Brastianos	2024	Vismodegib, Capivasertib, and Abemaciclib in Treating Patients with Progressive Meningiomas	Progressive or recurrent meningiomas	Vismodegib (PO once daily), capivasertib (PO BID days 1-4, treatment q7days), abemaciclib (PO q12h), FAK inhibitor GSK2256098 (PO BID)	PFS-6	NC T02 523 014
Erik P. Sulman	2025	A Phase II trial of <sup>177</sup> Lu-DOTATATE for recurrent/progressive meningioma	Progressive meningioma (any grade) with KPS $\geq$ 60	<sup>177</sup> Lu-DOTATATE intravenously every 8 weeks up to 4 cycles	PFS-6	NC T03 971 461
Recursion Pharm	2027	Efficacy and Safety of REC-2282 in Patients with Progressive	Progressive and recurrent NF2 meningiomas	Small molecule HDAC inhibitor REC 2282 (30-60 mg PO 3 times per week, for 3 of 4 weeks)	PFS-6	NC T05

aceuticals		Neurofibromatosis Type 2 (NF2) Mutated Meningiomas (POPLAR-NF2)				130 866
Marta Penas-Prado	2027	Phase II Trial of the Immune Checkpoint Inhibitor Nivolumab in Patients with Recurrent Select Rare CNS Cancers	Atypical or malignant meningioma	Nivolumab (240 mg IV q2weeks for cycles 1-2, then 480 mg q4weeks for 14 additional doses)	PFS-6, CR/PR	NC T03 173 950
Rupesh R. Kotecha	2028	A Phase II Study of Cabozantinib for Patients with Recurrent or Progressive Meningioma	Progressive or recurrent meningiomas with KPS $\geq$ 50	Cabozantinib (60 mg PO daily for 28 days)	PFS-6	NC T05 425 004
Nancy Ann Oberheim Bush	2028	Stereotactic Radiosurgery (SRS) and Immunotherapy (Pembrolizumab) for the Treatment of Recurrent Meningioma	Recurrent WHO grade 2 or 3 meningioma	SRS (15-20 Gy/1 Fr or 25-30 Gy/5 Fr) combined with pembrolizumab (200 mg IV on day 1 to -1 of radiation then q3weeks)	PFS-12	NC T04 659 811

Figure 1

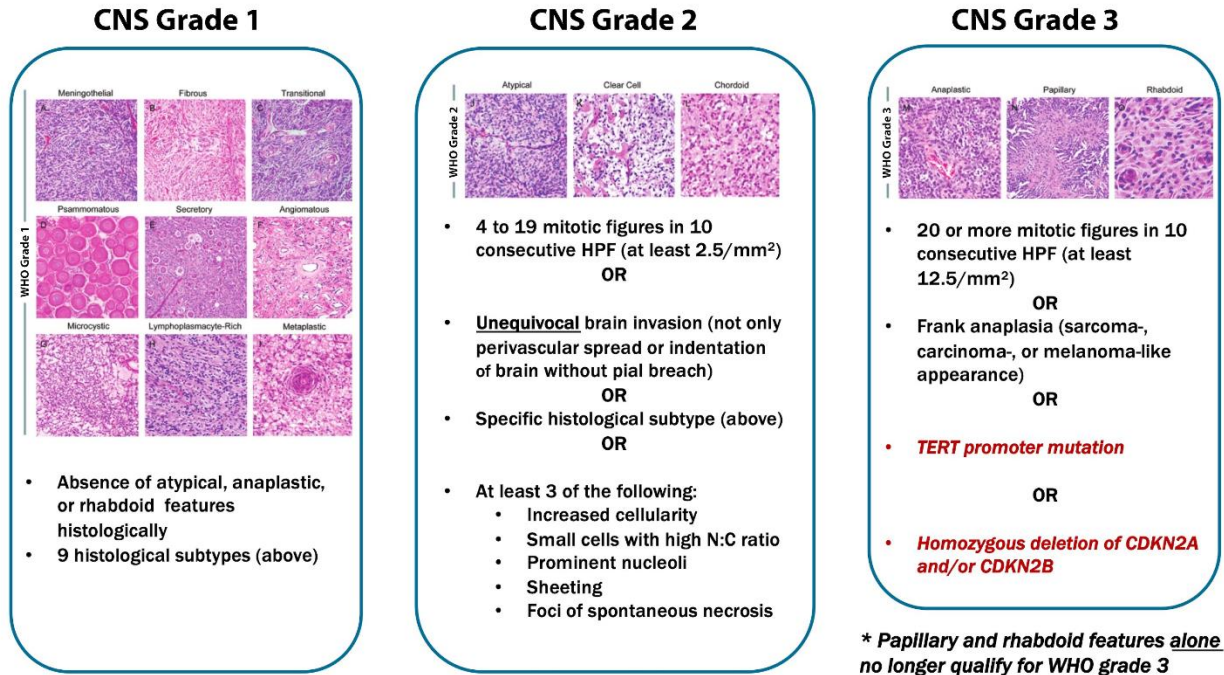


\* Incidence Rate is significantly different between groups at the  $p < 0.05$  level.  
 Abbreviations: CBTRUS, Central Brain Tumor Registry of the United States; US, United States; NPCR, National Program of Cancer Registries; SEER, Surveillance, Epidemiology, and End Results; NOS, not otherwise specified.

AC

Figure 2

## World Health Organization (WHO) Grading 2021



Accepted

Figure 3

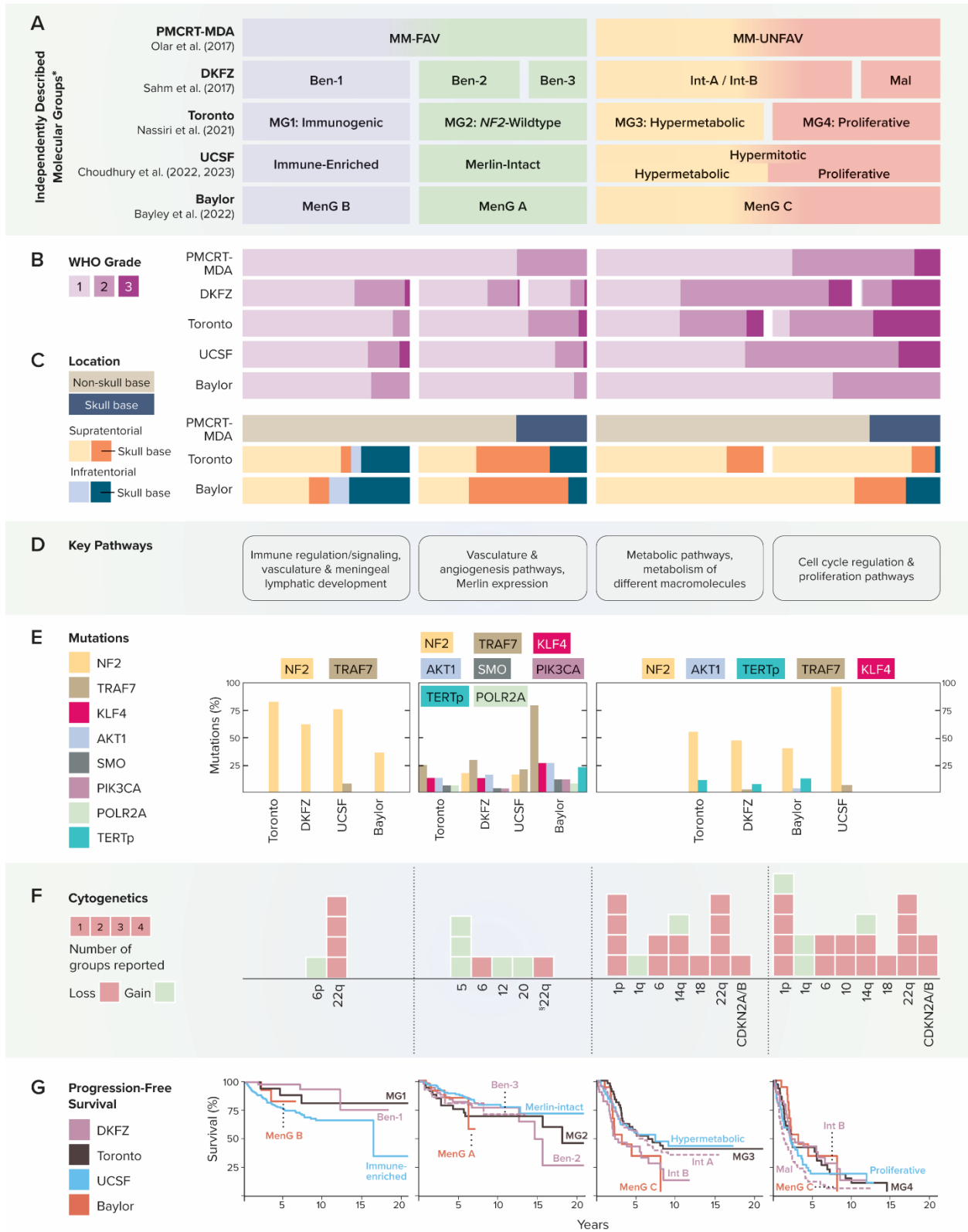
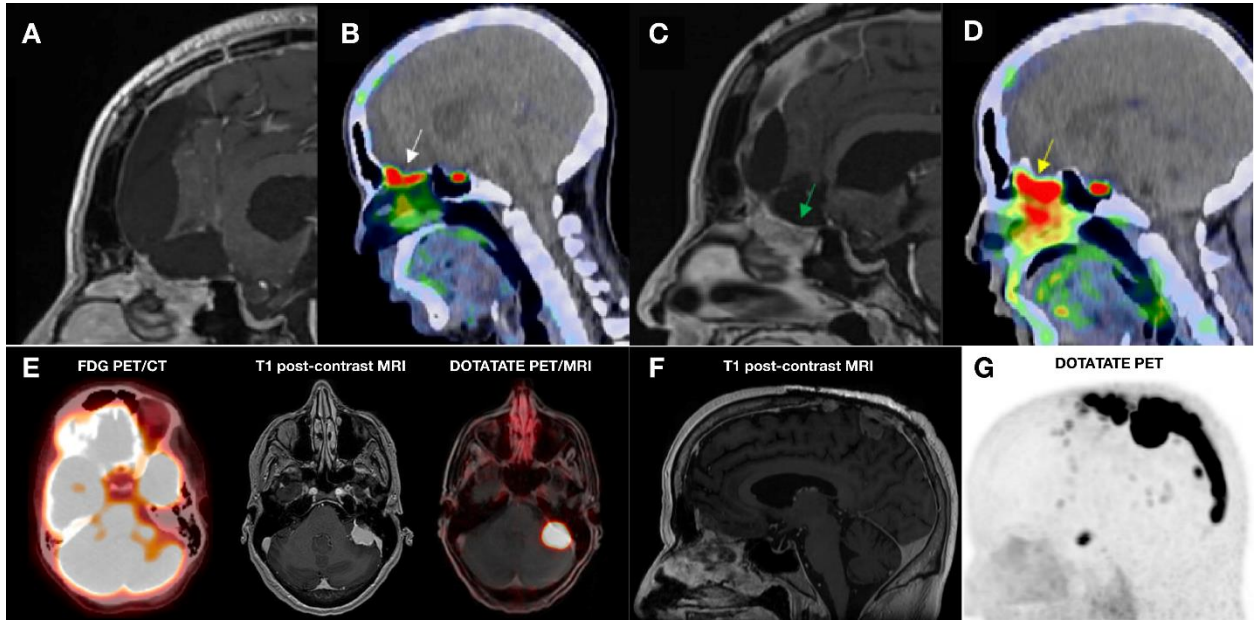


Figure 4



Accepted Manuscript



Figure 5

