



HAL
open science

Dermatological manifestations in Costello syndrome: A prospective multicentric study of 31 HRAS-positive variant patients

Didier Bessis, Anne-claire Bursztejn, Fanny Morice-picard, Yline Capri, Sébastien Barbarot, Hélène Aubert, Damien Bodet, Emmanuelle Bourrat, Christine Chiaverini, Laura Poujade, et al.

► To cite this version:

Didier Bessis, Anne-claire Bursztejn, Fanny Morice-picard, Yline Capri, Sébastien Barbarot, et al.. Dermatological manifestations in Costello syndrome: A prospective multicentric study of 31 HRAS-positive variant patients. *Journal of the European Academy of Dermatology and Venereology*, 2024, 10.1111/jdv.19996 . hal-04613110

HAL Id: hal-04613110

<https://hal.science/hal-04613110>

Submitted on 15 Jun 2024

HAL is a multi-disciplinary open access archive for the deposit and dissemination of scientific research documents, whether they are published or not. The documents may come from teaching and research institutions in France or abroad, or from public or private research centers.











L'archive ouverte pluridisciplinaire **HAL**, est destinée au dépôt et à la diffusion de documents scientifiques de niveau recherche, publiés ou non, émanant des établissements d'enseignement et de recherche français ou étrangers, des laboratoires publics ou privés.



Distributed under a Creative Commons Attribution - NonCommercial - NoDerivatives 4.0 International License

ORIGINAL ARTICLE

Dermatological manifestations in Costello syndrome: A prospective multicentric study of 31 *HRAS*-positive variant patients

Didier Bessis^{1,2,3}  | Anne-Claire Bursztejn⁴  | Fanny Morice-Picard^{2,5}  | Yline Capri^{6,7} | Sébastien Barbarot⁸  | Hélène Aubert⁸  | Damien Bodet⁹ | Emmanuelle Bourrat^{2,10} | Christine Chiaverini^{2,11}  | Laura Poujade^{1,2} | Marjolaine Willems^{12,13} | Jacques Rouanet¹⁴  | Anne Domp martin-Blanchère¹⁵ | David Geneviève^{12,13} | Marion Gerard¹⁶ | Emmanuelle Ginglinger¹⁷ | Smaïl Hadj-Rabia^{2,18}  | Ludovic Martin^{2,19} | Juliette Mazereeuw-Hautier^{2,20} | Nathalie Bibas²⁰ | Nicolas Molinari²¹ | Fanchon Herman²¹ | Alice Phan²² | Julien Rod²³ | Hugues Roger²⁴ | Sabine Sigaudy^{7,25} | Alban Ziegler²⁶ | Yoann Vial^{7,27}  | Alain Verloes^{6,7} | Hélène Cave^{7,27}  | Didier Lacombe^{28,29,30}

Correspondence

Didier Bessis, Department of Dermatology, St Eloi Hospital, 80 avenue A. Fliche, 34295 Montpellier cedex 5, France.
Email: didierbessis@gmail.com

Abstract

Background: Data on dermatological manifestations of Costello syndrome (CS) remain heterogeneous and lack in validated description.

Objectives: To describe the dermatological manifestations of CS; compare them with the literature findings; assess those discriminating CS from other RASopathies, including cardiofaciocutaneous syndrome (CFCS) and the main types of Noonan syndrome (NS); and test for dermatological phenotype–genotype correlations.

Methods: We performed a 10-year, large, prospective, multicentric, collaborative dermatological and genetic study.

Results: Thirty-one patients were enrolled. Hair abnormalities were ubiquitous, including wavy or curly hair and excessive eyebrows, respectively in 68% and 56%. Acral excessive skin (AES), papillomas and keratotic papules (PKP), acanthosis nigricans (AN), palmoplantar hyperkeratosis (PPHK) and ‘cobblestone’ papillomatous papules of the upper lip (CPPUL), were noted respectively in 84%, 61%, 65%, 55% and 32%. Excessive eyebrows, PKP, AN, CCPUL and AES best differentiated CS from CFCS and NS. Multiple melanocytic naevi (>50) may constitute a new marker of attenuated CS associated with intragenic duplication in *HRAS*. Oral acitretin may be highly beneficial for therapeutic management of PPHK. No significant dermatological phenotype–genotype correlation was determined between patients with and without *HRAS* c.34G>A (p.G12S).

Conclusions and Relevance: This validated phenotypic characterization of a large number of patients with CS will allow future researchers to make a positive diagnosis, and to differentiate CS from CFCS and NS.

For affiliations refer to page 7.

This is an open access article under the terms of the [Creative Commons Attribution-NonCommercial-NoDerivs](https://creativecommons.org/licenses/by-nc-nd/4.0/) License, which permits use and distribution in any medium, provided the original work is properly cited, the use is non-commercial and no modifications or adaptations are made.

© 2024 The Authors. *Journal of the European Academy of Dermatology and Venereology* published by John Wiley & Sons Ltd on behalf of European Academy of Dermatology and Venereology.

INTRODUCTION

Costello syndrome (CS) is a very rare RASopathy characterized by distinctive craniofacial features, congenital heart defects, neurodevelopmental disorders, failure to thrive and other anomalies including, for the most prevalent, dermatological and musculoskeletal anomalies and an increased risk of cancer.¹ CS is caused by heterozygous gain-of-function germline variants in *HRAS*,² almost always involving the amino acid glycine at Position 12 or 13 in exon 2, including c.34G>A (p.G12S) and c.35G>C (p.G12A) missense, and accounting for approximately 80% of the pathogenic variants in CS. The molecular genetic individualization of CS helped to define its phenotype among the other RASopathies, particularly those closely related on a phenotypic level, such as cardiofaciocutaneous syndrome (CFCS) and Noonan syndrome with pathogenic variant in the *SOS1* gene (*SOS1*-NS).² Although dermatological manifestations are common in patients with CS, they are still poorly described, with limitations due to the small number of cutaneous manifestations studied and the small number of cases of CS resulting in a lack of dermatological expertise (Table S1).

In this French multicentre and multidisciplinary prospective study, our primary objective was to better define the dermatological manifestations of CS by studying a cohort of children and adults with molecularly defined CS and comparing them with the findings in the literature. Our secondary objective was to search for a dermatological phenotype–genotype correlation based on the presence of the p.G12S missense pathogenic variants and other pathogenic variants.

PATIENTS AND METHODS

We prospectively enrolled children and adults (>18 years) with CS seen in French departments of medical genetics, dermatology and paediatric dermatology [i.e. Angers, Bordeaux, Caen, Clermont-Ferrand, Lyon, Marseille (AP-HM), Montpellier, Nancy, Nantes, Nice, Paris: Necker-Enfants Malades Hospital (AP-HP) and Robert-Debré Hospital (AP-HP), and Toulouse] between March 2013 and December 2022 and at four workshops organized by the French Costello & CFC Association in the years 2015, 2017, 2019 and 2022 in Bordeaux.

This work was approved by the clinical research department of the university hospital of the principal investigator (DB), the Consultative Committee for the Processing of Health Research Data (CCTIRS; 12.750) and the National Commission on Informatics and Liberty (CNIL; 913041). Consent was obtained from all individuals or their parents.

Inclusion and evaluation criteria

Eligible patients were consecutively included if they had a clinically confirmed diagnosis of CS evaluated by clinical

geneticists and the presence of a pathogenic variant of *HRAS*. For each patient, demographic information, medical history and dermatological manifestations were documented prospectively on a standardized proforma.

The data were collected during consultation with an experienced dermatologist and then classified following an exhaustive literature review: (i) hair abnormalities including temporal alopecia, scarcity of global scalp hair (excluding isolated temporal alopecia), wavy or curly hair considered pathological only when absent among first-degree relatives, scarcity or absence of eyebrows and eyelashes and excessive eyebrows including thick eyebrows and/or excessive hairiness of the glabella (latter, based exclusively on examination of clinical photographs by DB); (ii) keratinization disorders including keratosis pilaris, ulerythema ophryogenes (UO) defined by chronic keratotic follicular papules with perifollicular erythema and associated with scarring and/or atrophy and/or alopecia, palmar and/or plantar hyperkeratosis (PPHK), acanthosis nigricans (AN), ichthyosis, papilloma and/or keratotic papules (PKP) with appraisal of the following locations: periocular, perioral and perinasal (examination of the genital and anal region was not systematic); (iii) melanocytic naevi ≥ 3 mm in diameter, in order to avoid confusion with freckles or lentigines, with appraisal of the number (>50 or not) and palmar and/or plantar locations; (iv) pigmentary disorders including café-au-lait macules (0.5 cm or larger), multiple lentigines (2–4 mm in diameter) and hyperpigmentation defined as skin colour darker than that of other family members; (v) connective tissue disorders including hyperelastic skin and acral excess skin (AES); and (vi) other cutaneous manifestations including easy bruising and hyperhidrosis (whatever the location), all determined by questioning parents and examining the child's health record, palmoplantar linearity, deep palmoplantar creases and lymphoedema.

After obtaining patient and/or parental agreement, non-standardized photographs of the dermatological lesions were taken during the visit and reviewed by the principal investigators (DB, DL).

Molecular screening

Genotyping of *HRAS* exons and flanking intron-exon boundaries was performed on genomic DNA obtained from peripheral leukocytes by bidirectional Sanger sequencing, as previously described,³ or by next-generation sequencing (NGS). Briefly, direct sequencing of PCR products by the Sanger method was performed using the Big Dye Terminator Cycle Sequencing Ready Reaction Kit (ABI, Foster City, CA, USA). The reaction products were run on an automated capillary sequencer (ABI 3130 Genetic Analyzer, ABI). Sequences were aligned using Seqscape® analysis software (ABI) and compared with reference sequences for genomic DNA and mRNA.

NGS was performed using capture-based target enrichment (Custom SureSelect XTBS2, Agilent) and sequencing on a NextSeq 500 (High Output Kit v2, 2*150bp) (Illumina). Bioinformatic alignment was performed using Pipeline Local Run Manager v.2.4.0 (Illumina). Variant calling was performed using VarScan v.2.3.5. Variant classification was performed using Alissa Interpret (Agilent Technologies). The average sequencing depth was 100×.

Variants were named according to the NCBI reference transcript sequence with the following GenBank accession number HRAS (NC_000011.10). Previous reports of single nucleotide variants were checked by consulting the Ensembl genome browser (<http://www.ensembl.genome.org>). The pathogenicity of amino acid variants was interpreted according to international expert consensus.⁴

Statistical analysis

Statistical analysis was performed using SAS® version 8.2 (SAS Enterprise Guide). The characteristics of CS patients with positive-p.G12S HRAS mutation versus negative-p.G12S HRAS mutations were compared using Pearson's chi-squared test or Fisher's exact test (if theoretical numbers < 5) for the qualitative variables. For the quantitative variables, Student's *t*-test was used if normality was respected; otherwise, a non-parametric test (Wilcoxon Mann–Whitney test) was used. *p*-Value was adjusted with the false discovery rate method. A *p*-value ≤ 0.05 was considered significant.

RESULTS

Thirty-one patients were recruited, including three patients previously reported.⁵ Pertinent characteristics of the 31 patients are summarized in Table 1 (further details of clinical and molecular findings are provided in Table S2). Patients were almost exclusively Caucasian (90.3%, data not shown), mostly male (55%), with age at consultation ranging from 0.2 to 25 years (median age of 8 years). HRAS variants c.34G>A (p.G12S), c.35G>C (p.G12A), c.34G>T (p.G12C), c.64C>A (p.Q22K) and, duplication c.187_207dup21 (p.Glu63_Asp69dup) were identified in respectively 67.8% (21/31), 22.6% (7/31), 3.2% (1/31), 3.2% and 3.2%.

Hair abnormalities

Hair abnormalities were present in 90.3%, including wavy or curly hair, scarcity of global scalp hair and temporal alopecia (Figure 1a) respectively in 67.7%, 38.7% and 38.7%. Scarcity or absence of eyebrows and eyelashes occurred respectively in 16.1% and 0.3%. Conversely, excessive eyebrows were noted in 58% (14/24), sometimes as early as the age of 2 years.

Keratinization disorders

Papillomas (Figure 1b) and/or round and dome-shaped keratotic papules (Figure 1c), sometimes with a horn centre, 1–4 mm in diameter, were present in 61.3% at any age, in 83.3% after the beginning of adolescence (>10 years), and consistently observed in adults. These were mostly located on the perinasal, periocular and perioral areas respectively in 41.9%, 22.6% and 22.6%, while extracephalic locations were noted in 33.3%, predominantly on the neck (Figure 1d) and the axillary folds (data not shown).

AN characterized by hyperpigmented and velvety plaques, sometimes associated with acrochordons, was present from 6 months onward, with a frequency of 64.5% at any age, increasing to 77% after the beginning of adolescence and consistently observed in adults. It was always distributed over the neck and axillae and associated with an orange thickening and stippled appearance of the dermatoglyphics (pachydermatoglyphia) on the fingertips (Figure 1e) and palms (tripe palms).

Multiple coalescent millimetre-size papules—smooth-surfaced, flesh-coloured and ‘cobblestone’ appearance with a linear distribution on the vermilion of the upper lip (Figure 1f)—were noted in 32.3%. These were almost always associated, to various degrees, with a thickened, pleated ‘in ladder rung’ and sometimes brownish mucosal lip suggestive of a labial localization of AN (Figure 1g).

PPHK was present in 54.8%. Bilateral and symmetric plantar involvement was constant, characterized by painful, thick, yellow-to-orange, patchy keratotic plaques prominent in pressure areas (Figure 1h). Association with palmar pseudo-ainhum was noted in one case (Figure 2a). Due to functional limitations in walking, three male patients had been treated since the age of 8, 12 and 22 years with oral acitretin 0.3–0.5 mg/kg/day for a minimum period of 6 months, intermittently. Marked reduction in the thickness and pain of the plantar callosities was observed, with routine care reduced to a daily application of emollient. Substantial improvement of palmar pseudo-ainhum was also noted after 7 months of treatment with oral acitretin (0.4 mg/kg/day, 10 mg/day) (Figure 2b). Good long-term clinical and biological tolerance, including regular blood haematologic, hepatic and lipid monitoring, was noted.

Connective tissue disorders

AES characterized by loose, wrinkled and/or redundant skin on the palmoplantar and dorsal surface of the hands and feet was present in 83.9%, associated with deep palmoplantar creases and hyperlinearity (Figure 1i) respectively in 77.4% and 61.3%.

Additional cutaneous features

All relevant data regarding other cutaneous features are summarized in Table 1. An atypical observation is briefly

TABLE 1 Baseline characteristics and dermatological manifestations of the 31 patients with Costello syndrome and positive *HRAS* mutation and the clinical characteristics associated with the pG12S mutation (univariate analysis).

	Total	Costello syndrome with p.G12S pathogenic variant in <i>HRAS</i>	Costello syndrome without p.G12S pathogenic variant in <i>HRAS</i>	Global <i>p</i> -value Costello syndrome with G12S pathogenic variant in <i>HRAS</i> versus Costello syndrome without G12S pathogenic variant in <i>HRAS</i> ^{a,b}	Corrected <i>p</i> -value (false discovery rate) ^c
Baseline characteristics					
Number of patients	31	20	11		
Median age at evaluation (range), years	8 (0.2–25)	10.5 (0.2–25)	6 (2–22)	0.06	0.47
Sex ratio (<i>n</i> female, male)	0.8 (14, 17)	1.2 (11, 9)	0.4 (3, 8)	0.26	0.90
Dermatological manifestations					
Hair abnormalities	90.3 (28/31)	85.0 (17/20)	100 (11/11)	0.54	1.00
Scarcity or absence of eyebrows	16.1 (5/31)	10.0 (2/20)	27.3 (3/11)	0.32	0.90
Scarcity or absence of eyelashes	3.2 (1/31)	5.0 (1/20)	0 (0/11)	1.00	1.00
Excessive eyebrows	58 (14/24)	61.5 (8/13)	54.5 (6/11)	1.00	1.00
Scarcity of scalp hair	38.7 (12/31)	30.0 (6/20)	54.5 (6/11)	0.26	0.90
Wavy or curly hair	67.7 (21/31)	70.0 (14/20)	63.6 (7/11)	1.00	1.00
Temporal alopecia	38.7 (12/31)	30.0 (6/20)	54.5 (6/11)	0.26	0.90
Hypertrichosis	16.1 (5/31)	5.0 (1/20)	36.4 (4/11)	0.04	0.47
Keratinization disorders	71.0 (22/31)	75.0 (15/20)	63.6 (7/11)	0.68	1.00
Keratosis pilaris	12.9 (4/31)	20 (4/20)	0 (0/11)	0.27	0.90
Ulerythema ophryogenes	6.5 (2/31)	5.0 (1/20)	9.1 (1/11)	1.00	1.00
Palmar and/or plantar hyperkeratosis	54.8 (17/31)	55.0 (11/20)	54.5 (6/11)	1.00	1.00
Acanthosis nigricans	64.5 (20/31)	65.0 (13/20)	63.6 (7/11)	1.00	1.00
Ichthyosis	3.2 (1/31)	5.0 (1/20)	0 (0/11)	1.00	1.00
Papilloma	61.3 (19/31)	60.0 (12/20)	63.6 (7/11)	1.00	1.00
Peri-ocular	22.6 (7/31)	25.0 (5/20)	18.2 (2/11)	1.00	1.00
Peri-oral	22.6 (7/31)	25.0 (5/20)	18.2 (2/11)	1.00	1.00
Peri-nasal	41.9 (13/31)	45.0 (9/20)	36.4 (4/11)	0.72	1.00
Linear papules of the upper lip	32.3 (10/31)	45.0 (9/20)	9.1 (1/11)	0.06	0.47
Melanocytic naevi					
<i>n</i> > 50	3.2 (1/31)	0 (0/20)	9.1 (1/11)	0.35	0.90
Acral location	9.7 (3/31)	10.0 (2/20)	9.1 (1/11)	1.00	1.00
Pigmentary disorders					
Café-au-lait macules (>2)	0 (0/31)	0 (0/20)	0 (0/11)	–	–
Multiple lentigines	0 (0/31)	0 (0/20)	0 (0/11)	–	–
Hyperpigmentation	14.3 (4/28)	0 (0/19)	44.4 (4/9)	<0.01	0.31
Connective tissue disorders					
Skin hyperlaxity	67.7 (21/31)	65.0 (13/20)	72.7 (8/11)	1.00	1.00
Acral excess skin (hands and feet)	83.9 (26/31)	75.0 (15/20)	100 (11/11)	0.13	0.81
Other					
Easy bruising	16.1 (5/31)	20.0 (4/20)	9.1 (1/11)	0.63	1.00
Hyperhidrosis	54.8 (17/31)	50.0 (10/20)	63.6 (7/11)	0.71	1.00
Lymphoedema	3.2 (1/31)	0.0 (0/20)	9.1 (1/11)	0.35	0.90
Palmoplantar linearity	61.3 (19/31)	60.0 (12/20)	63.6 (7/11)	1.00	1.00
Deep palmoplantar creases	77.4 (24/31)	75.0 (15/20)	21.8 (9/11)	1.00	1.00

^aPearson's chi-squared test or Fisher's exact test was used to compare qualitative variables.

^bFor the quantitative variables, the Student's *t*-test was used if normality was respected, otherwise a non-parametric test (Wilcoxon Mann–Whitney test) was used.

^cFalse discovery rate correction for multiple testing.

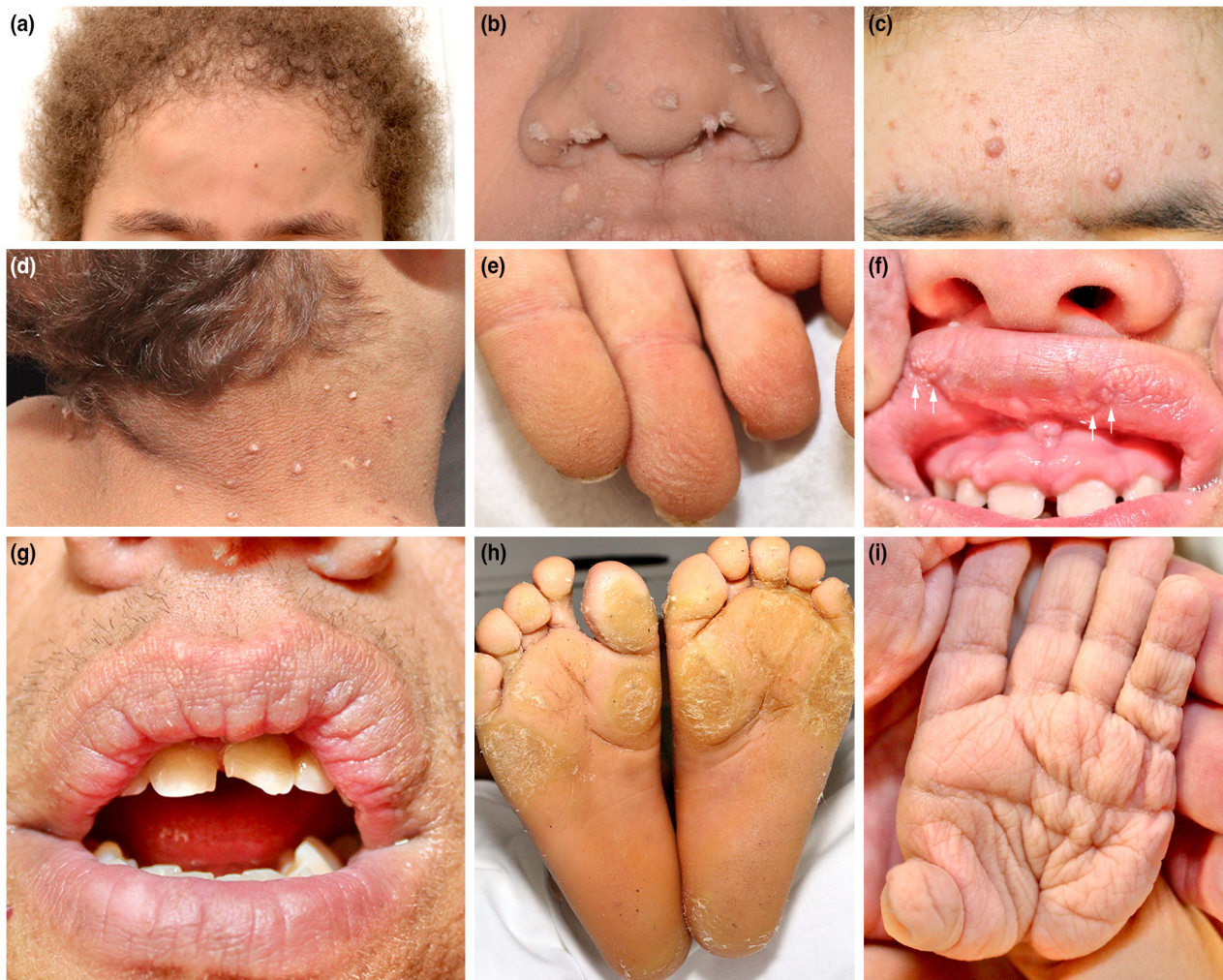

FIGURE 1 CS and characteristic dermatological abnormalities. (a) Curly hair, temporal alopecia and thick eyebrows of a 10-year-old girl with p.G12S *HRAS* variant. (b) Multiple papillomas located on the nasal and perinasal areas of a 15-year-old boy with p.G12C *HRAS* variant. (c) Multiple round and dome-shaped keratotic papules of the forehead in a 26-year-old girl with p.G12S *HRAS* variant. (d) Acanthosis nigricans (AN) and multiple acrochordons on the posterior and lateral sides of the neck in a 14-year-old boy with p.G12A *HRAS* variant. (e) Orange, thickened and stippled appearance of the dermatoglyphics (pachydermatoglyphia) on the fingertips of a 26-year-old girl with p.G12S *HRAS* variant. (f) 'Cobblestone' papillomatous linear papules (white arrows) of the upper lip in a 10-year-old girl with p.G12S *HRAS* variant. (g) Thickened, pleated 'in ladder rung' and brownish mucosal lip suggestive of a labial localization of AN in a 25-year-old boy with p.G12S *HRAS* variant. (h) Plantar bilateral keratoderma with thick and orange patchy plaques, predominant in areas of pressure in an 8-year-old boy with p.G12S *HRAS* variant. (i) Palmar excess skin (*cutis laxa*) with deep creases and hyperlinearity in a 7-year-old boy with p.G12A *HRAS* variant.

summarized herein. A 22-year-old man, without relevant family medical history, was seen for the management of multiple melanocytic naevi (MMN) present since early childhood. His personal history included surgical correction of craniosynostosis at the age of 4, delayed puberty, osteoporosis at the age of 20, severe lower limb lymphoedema post-surgery for high arches and mild intellectual disabilities. On clinical examination, he exhibited a Noonan-like facial features (Figure 3a) with a long and broad neck and pectus excavatum (Figure 3b). Dermatological manifestations included (i) diffuse scalp alopecia with thin, sparse, short and slow-growing hair; (ii) several hundred small multiple melanocytic naevi (Figure 3b–d), distributed diffusely on the scalp, forehead,

cheeks, neck, trunk, limbs, and more sparsely on the dorsal and palmar aspects of the hands and feet and the major folds; (iii) AN over the neck and axillae with multiple acrochordons (Figure 3a), and pachydermatoglyphia predominantly on the fingertip pulp (Figure 3e); (iv) PKP on the perinasal and periocular regions (Figure 3f); (v) mild acral loose skin on the dorsum of the hands (Figure 3g); (vi) generalized hyperpigmentation with a skin colour significantly darker than that of his parents; (vii) orange callosities in pressure areas of the sole; and (viii) severe bilateral lower limb lymphoedema (Figure 3h). Cardiological investigations were normal except for a prolonged QT interval on electrocardiography. Brain and spinal cord MRI were normal. Molecular genetic diagnosis revealed a 21-nucleotide duplication insertion

(c.187_207dup) in codons 63 and 69 in the exon of the *HRAS* gene, predicted to result in an in-frame duplication of the amino acids 63–69 [p.(Glu63_Asp69dup)] and suggestive of a mild phenotype of CS.

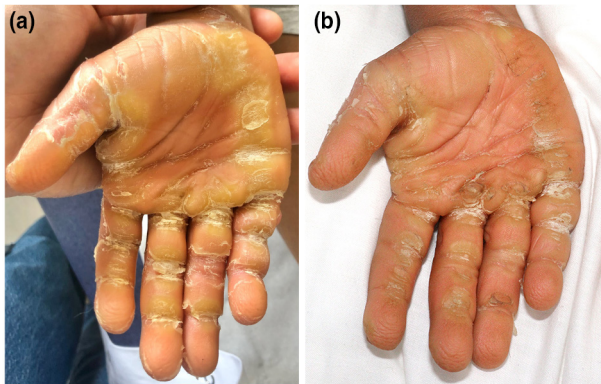


FIGURE 2 Successful treatment of palmar keratoderma with pseudo-ainhum in an 8-year-old boy with Costello syndrome. (a) Initial state before treatment. (b) Substantial improvement of pseudo-ainhum and marked reduction in the thickness and area of callosities after 7 months of treatment with acitretin at a dosage of about 0.4 mg/kg/day (10 mg/day).

Dermatological phenotype–genotype correlation

The pertinent characteristics of patients with and without *HRAS* variants c.34G>A (p.G12S) are shown in Table 1. No dermatological manifestation was significantly discriminating.

DISCUSSION

Analysis of the clinical features in the present series of patients confirms the high prevalence of dermatological manifestations in CS, whatever the pathogenic variant of *HRAS*. These skin abnormalities were specifically related to the presence of hair abnormalities, connective tissue and keratinization disorders in 90.3%, 83.9% and 71%, respectively, and in accordance with the literature review.^{2,5–47}

Wavy or curly hair and scarcity of scalp hair were present respectively in 67.7% and 38.7%, an overall lower frequency than previously reported in previous dermatological studies and pooled data, respectively varying from 77%^{5–25,27–47} to 96%²⁶ and 64%⁵ to 81%,^{6–47} respectively. The difference may be explained by the prospective design of our study distinguishing scarcity of global scalp hair from isolated

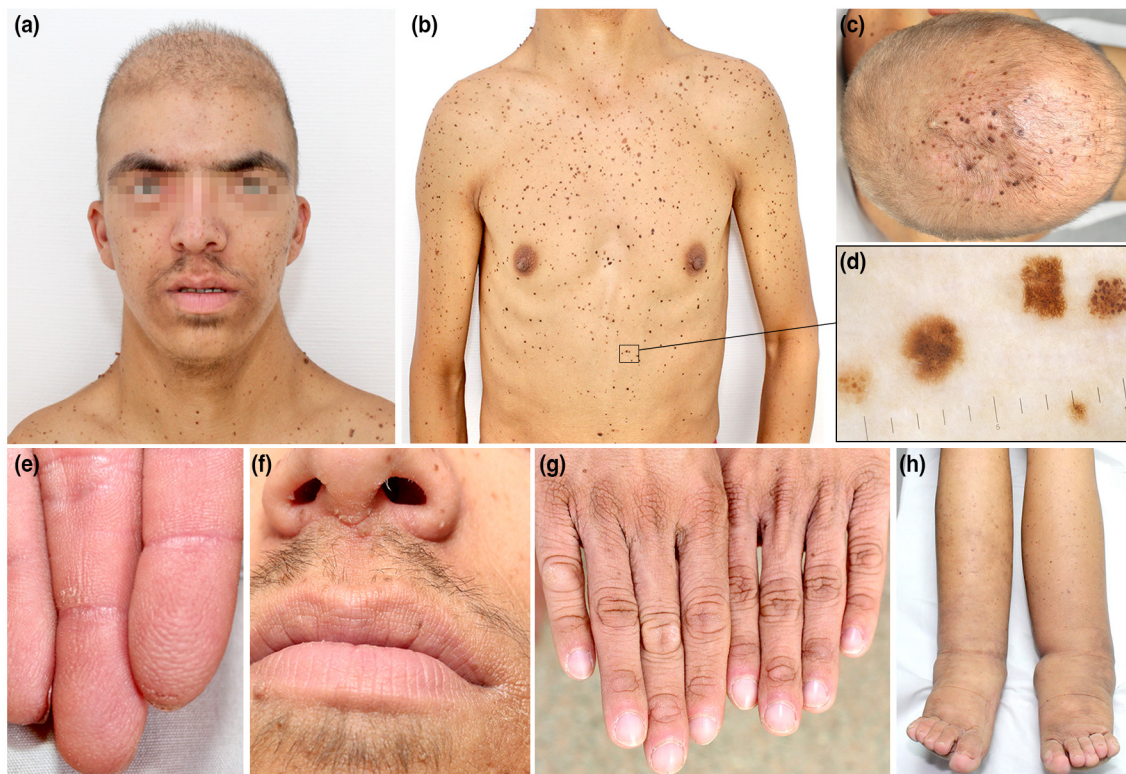


FIGURE 3 Main dermatological manifestations in a 22-year-old-man with duplication p.(Glu63_Asp69dup) in *HRAS*. (a) Noonan-like facial dysmorphism with a high and narrow forehead with temporal constriction, thick eyebrows, a bulbous nasal tip, full lips and wide ears set low. Multiple melanocytic naevi (MMN) are present on the face associated with multiple acrochordons of the lateral parts of the neck. (b) MMN on the anterior surface of the trunk. (c) MMN on the scalp. (d) MMN with a close-up dermoscopic view. (e) Thickening and stippled appearance of the dermatoglyphs (pachydermatoglyphia) on the fingertips. (f) Multiple papillomas located on the perinasal and perioral areas. (g) Moderate loose, wrinkled and redundant dorsal part of the hands. (h) MMN on the lower limbs with severe lymphoedema.

temporal alopecia and considering wavy or curly hair pathological only in the absence among first-degree relatives. Wavy or curly hair and scarcity of scalp hair are also common in CFCS with frequencies respectively close to 86%,^{48,49} and 74%,^{48,49} and thus appeared poorly discriminating (Table S3). On the other hand, a low frequency of scarcity or absence of eyebrows was noted in 16.1%, within the ranges of 9%²⁶ to 24%,^{5-25,27-47} and appeared highly relevant in distinguishing CS from CFCS and *SOSI-NS* where frequencies are respectively close to 81%^{48,49} and 66%.⁵⁰ Similarly, excessive hairiness of the eyebrows appeared as an early and common sign of CS present in 58%, consistent with the frequency of 47.8% previously described in a large dermatological series,²⁶ and particularly discriminating from CFCS where this sign is uncommon, noted in less than 2%.^{48,49}

Several keratinization disorders appeared as classic manifestations of CS, and this might be particularly useful in distinguishing it from other RASopathies. The rate of facial PKP, AN and dermatoglyphia was moderately higher than reported in previous studies, respectively 61.3%, 64.5% and 64.5% versus 49%,^{2,5-47} 48%^{2,5-47} and 31%,²⁶ a difference possibly due to our data collection method based on systematic clinical examination. The high frequencies of PKP and AN, their onset from early childhood, and the constant presence in adults appeared to be useful distinctive signs of CS as opposed to CFCS and *PTPN11*- and *SOSI-NS*, where they are unusual and present respectively in 1.2%⁴⁸ and 11%⁴⁸ for CFCS, and 0%⁵⁰ to 2.7%⁵⁰ for the main types of NS.

We noted the presence of 'cobblestone' papillomatous papules of the upper lip in 32.3%, always located at the lower part of a thickened, pleated and sometimes brownish mucosa suggestive of labial localization of AN. These mucosal lesions, previously described by our team in one case,⁵¹ may constitute a new underrecognized and clinical sign of CS distinguishing it from other RASopathies including CFCS and various types of Noonan syndrome, where they have never been reported. This might represent a particular linear form of florid mucosal oral papillomatosis associated with AN of the upper lip⁵² but, in absence of available histological data, no definitive conclusion could be drawn.

We observed PPHK in 54.8%, which is within the range of 46% to 76% reported in the main dermatological studies^{5,26} and more common than in CFCS and NS (*PTPN11*- and *SOSI-NS*) with frequencies respectively noted in about 28%^{48,49} and 1%–12%.⁵⁰ We described the second case of pseudo-ainhum associated with PPHK of CS⁵² and, although few patients were treated, our results confirm that oral acitretin may be a useful and well-tolerated treatment for the PPHK of CS, associated or not with pseudo-ainhum.⁵² Our series highlights the uncommon presence of UO in CS in 6.5%, a sign hitherto unreported in dermatological series,^{5,26} but no UO-PPHK association was noted. This association remains highly indicative of CFCS, where it is present in 20% of adult patients⁴⁸ and discriminating from the other RASopathies, while PPHK is unusual in all genotypic forms of NS, including *SOSI-NS*, where UO-PPHK has not previously been described.⁵⁰

AES and deep palmoplantar creases were respectively present in 83.9% and 77.4%, which was close to the findings from the pooled data of 301 patients.^{2,5-47} AES, although sometimes subjective in mild form, especially in young children, appeared highly indicative of clinical CS diagnosis and relevant in distinguishing it from CFCS and various forms of NS, where it was noted respectively in 18%⁴⁸ and 10%–18%.⁵⁰

The observation of MMN in RASopathies remains classically associated with NS with multiples lentiginos and CFCS, respectively in 46% and 26% in contrast to CS where they were observed in 3.2% (1/31) in our series and 4.3%–9% in the two dermatological studies that specifically investigated it.^{5,26} The presence of MMN in CS may be a phenotypic marker for rare pathogenic variants in *HRAS*, especially the intragenic duplication p.(Glu63_Asp69dup), an attenuated phenotype of CS with mild intellectual disability and a lower tumour risk than in 'typical' p.(Gly12Ser) or other specific missense pathogenic variants of *HRAS*-associated CS.³² Two other previously reported cases of *HRAS* intragenic duplication, p.Glu63_Asp69dup and p.Glu62_Arg68dup, were also possibly associated with MMN rather than multiple lentiginos, as the relative low density and sparse distribution of the pigmented lesions documented with images seems to support this hypothesis.^{28,40}

The limitations of our study are inherent to the rarity of CS, with a limited number of enrolled patients. The cohort of patients may have been too small to allow definitive conclusions on more specific genotype–phenotype correlations in rare patients. For example, we were unable to analyse patients with the pathogenic variants c.37G>T transversion in *HRAS* p.G13C and, thus, to confirm the specific association with loose anagen hairs and dolichocilia as previously described.^{1,20}

CONCLUSIONS

Excessive hairiness of the eyebrows, PKP, AN, 'cobblestone' papillomatous papules of the upper lip and AES appear to be pertinent manifestations in positively diagnosing CS in its typical or emerging attenuated forms^{46,47} and differentiating it from CFCS and the main types of NS. Oral acitretin may be highly beneficial for therapeutic management of PPHK. No significant dermatological phenotype–genotype correlation in the presence or absence of p.G12S or p.G12A pathogenic variant of *HRAS* could be determined.

AFFILIATIONS

¹Department of Dermatology, Saint-Eloi Hospital, University of Montpellier, Montpellier, France

²French National Reference Centre for Rare Diseases of the Skin and Mucous Membranes of Genetic Origin (MAGEC), University hospital of Montpellier, Montpellier, France

³INSERM U1058, Montpellier, France

⁴Department of Dermatology, Brabois Hospital, University of Nancy, Nancy, France

⁵Department of Paediatric Dermatology, Pellegrin University Hospital of Bordeaux, Bordeaux, France

⁶Department of Clinical Genetics, Robert-Debré Hospital, Paris, France

⁷French National Reference Centre for Developmental Anomalies and Malformative Syndromes – Ile de France, Robert-Debré Hospital, AP-HP, Paris, France

- ⁸Department of Dermatology, Hotel Dieu Hospital, University of Nantes, Nantes, France
- ⁹Department of Paediatric Haematology-Immunology-Oncology, Caen Normandie Hospital and University of Caen, Caen, France
- ¹⁰Department of Paediatric Dermatology, Robert-Debré Hospital, AP-HP, Paris, France
- ¹¹Department of Dermatology, l'Archet 2 Hospital, University of Nice, Nice, France
- ¹²Department of Clinical Genetics, Arnaud de Villeneuve Hospital, University of Montpellier, Montpellier, France
- ¹³French National Reference Centre for Developmental Anomalies – and Malformative Syndromes Sud Ouest Occitanie, University hospital of Montpellier, Montpellier, France
- ¹⁴Department of Dermatology, d'Estaing Hospital and University Hospital of Clermont-Ferrand, Clermont-Ferrand, France
- ¹⁵Department of Dermatology, Caen Normandie Hospital and University of Caen, Caen, France
- ¹⁶Department of Clinical Genetics, Caen Normandie Hospital and University of Caen, Caen, France
- ¹⁷Department of Clinical Genetics, Émile Muller Hospital, Mulhouse, France
- ¹⁸Department of Paediatric Dermatology, Necker-Enfants Malades Hospital, AP-HP, Paris, France
- ¹⁹Department of Dermatology, Angers Hospital University, Angers, France
- ²⁰Department of Dermatology, Larrey Hospital, University of Toulouse, Toulouse, France
- ²¹Department of Statistics, La Colombière Hospital and University of Montpellier, Montpellier, France
- ²²Department of Paediatric Dermatology, Femme-Mère-Enfant Hospital-HCL, University of Lyon, Lyon, France
- ²³Department of Paediatric Surgery, Caen Normandie Hospital and University of Caen, Caen, France
- ²⁴Doctor's Office, Clermont-Ferrand, France
- ²⁵Department of Clinical Genetics, La Timone Hospital, AP-HM and University of Marseille, Marseille, France
- ²⁶Department of Clinical Genetics, Hospital and University of Angers, Angers, France
- ²⁷Department of Molecular Genetics, Robert-Debré Hospital, AP-HP, Paris, France
- ²⁸Department of Clinical Genetics, Pellegrin University Hospital of Bordeaux, Bordeaux, France
- ²⁹French National Reference Centre for Developmental Anomalies – and Malformative Syndromes SOOR, University Hospital of Bordeaux, Bordeaux, France
- ³⁰INSERM U1211, Bordeaux, France

ACKNOWLEDGEMENTS

We thank the patients who participated in the study and their parents. The principal investigators also thank Serge Arnoulet and François Dupuy of the French Costello & CFC Association for their kindness and warm welcome to the five meetings with their association and C Stott for editorial assistance.

CONFLICT OF INTEREST STATEMENT

The authors declare no conflict of interest regarding this manuscript.

FUNDING INFORMATION

None.

ETHICS STATEMENT

The patients in this manuscript have given written informed consent for publication of their case details. This work was approved by the clinical research department of the university hospital of the principal investigator (D.B), the Consultative Committee for the Processing of Health Research Data (CCTIRS; 12.750) and the National Commission on Informatics and Liberty (CNIL; 913041).

DATA AVAILABILITY STATEMENT

The data that support the findings of this study are available from the corresponding author upon reasonable request.

ORCID

- Didier Bessis*  <https://orcid.org/0000-0002-3815-5417>
- Anne-Claire Bursztejn*  <https://orcid.org/0000-0002-3281-7299>
- Fanny Morice-Picard*  <https://orcid.org/0000-0002-4316-916X>
- Sébastien Barbarot*  <https://orcid.org/0000-0002-6629-9100>
- Hélène Aubert*  <https://orcid.org/0000-0003-1688-9900>
- Christine Chiaverini*  <https://orcid.org/0000-0002-6063-5409>
- Jacques Rouanet*  <https://orcid.org/0000-0002-5821-0786>
- Smail Hadj-Rabia*  <https://orcid.org/0000-0001-6801-7106>
- Yoann Vial*  <https://orcid.org/0000-0003-1437-0427>
- Hélène Cavé*  <https://orcid.org/0000-0003-2840-1511>

REFERENCES

- Gripp KW, Morse LA, Axelrad M, Chatfield KC, Chidekel A, Dobyns W, et al. Costello syndrome: clinical phenotype, genotype, and management guidelines. *Am J Med Genet A.* 2019;179:1725–44.
- Aoki Y, Niihori T, Kawame H, Kurosawa K, Ohashi H, Tanaka Y, et al. Germline mutations in HRAS proto-oncogene cause Costello syndrome. *Nat Genet.* 2005;37:1038–40.
- Nava C, Hanna N, Michot C, Pereira S, Pouvreau N, Nihori T, et al. Cardio-facio-cutaneous and Noonan syndromes due to mutations in the RAS/MAPK signalling pathway: genotype-phenotype relationships and overlap with Costello syndrome. *J Med Genet.* 2007;44:763–71.
- Gelb BD, Cavé H, Dillon MW, Gripp KW, Lee JA, Mason-Suares H, et al. ClinGen's RASopathy expert panel consensus methods for variant interpretation. *Genet Med.* 2018;20:1334–45.
- Morice-Picard F, Ezzedine K, Delrue MA, Arveiler B, Fergelot P, Taieb A, et al. Cutaneous manifestations in Costello and cardiofacio-cutaneous syndrome: report of 18 cases and literature review. *Pediatr Dermatol.* 2013;30:665–73.
- Gripp KW, Lin AE, Stabley DL, Nicholson L, Scott CI, Doyle D, et al. HRAS mutation analysis in Costello syndrome: genotype and phenotype correlation. *Am J Med Genet A.* 2006;140:1–7.
- Kerr B, Delrue MA, Sigaudy S, Perveen R, Marche M, Burgelin I, et al. Genotype-phenotype correlation in Costello syndrome: HRAS mutation analysis in 43 cases. *J Med Genet.* 2006;43:401–5.
- van Steensel MA, Vreeburg M, Peels C, van Ravenswaaij-Arts CM, Bijlsma E, Schrandt-Stumpel CT, et al. Recurring HRAS mutation G12S in Dutch patients with Costello syndrome. *Exp Dermatol.* 2006;15:731–4.
- Gripp KW, Stabley DL, Nicholson L, Hoffman JD, Sol-Church K. Somatic mosaicism for an HRAS mutation causes Costello syndrome. *Am J Med Genet A.* 2006;140:2163–9.
- Estep AL, Tidyman WE, Teitell MA, Cotter PD, Rauen KA. HRAS mutations in Costello syndrome: detection of constitutional activating mutations in codon 12 and 13 and loss of wild-type allele in malignancy. *Am J Med Genet A.* 2006;140:8–16.
- Søvik O, Schubbert S, Houge G, Steine SJ, Norgård G, Engelsen B, et al. De novo HRAS and KRAS mutations in two siblings with short stature and neuro-cardio-facio-cutaneous features. *J Med Genet.* 2007;44:e84.
- Zampino G, Pantaleoni F, Carta C, Cobellis G, Vasta I, Neri C, et al. Diversity, parental germline origin, and phenotypic spectrum of de novo HRAS missense changes in Costello syndrome. *Hum Mutat.* 2007;28:265–72.

13. Digilio MC, Sarkozy A, Capolino R, Chiarini Testa MB, Esposito G, de Zorzi A, et al. Costello syndrome: clinical diagnosis in the first year of life. *Eur J Pediatr*. 2008;167:621–8.
14. Gripp KW, Innes AM, Axelrad ME, Gillan TL, Parboosingh JS, Davies C, et al. Costello syndrome associated with novel germline HRAS mutations: an attenuated phenotype? *Am J Med Genet A*. 2008;146A:683–90.
15. Lo IF, Brewer C, Shannon N, Shorto J, Tang B, Black G, et al. Severe neonatal manifestations of Costello syndrome. *J Med Genet*. 2008;45:167–71.
16. Piccione M, Piro E, Pomponi MG, Matina F, Pietrobono R, Candela E, et al. A premature infant with Costello syndrome due to a rare G13C HRAS mutation. *Am J Med Genet A*. 2009;149A:487–9.
17. Sol-Church K, Stabley DL, Demmer LA, Agbulos A, Lin AE, Smoot L, et al. Male-to-male transmission of Costello syndrome: G12S HRAS germline mutation inherited from a father with somatic mosaicism. *Am J Med Genet A*. 2009;149A:315–21.
18. Girisha KM, Lewis LE, Phadke SR, Kutsche K. Costello syndrome with severe cutis laxa and mosaic HRAS G12S mutation. *Am J Med Genet A*. 2010;152A:2861–4.
19. Gremer L, De Luca A, Merbitz-Zahradnik T, Dallapiccola B, Morlot S, Tartiglia M, et al. Duplication of Glu37 in the switch I region of HRAS impairs effector/GAP binding and underlies Costello syndrome by promoting enhanced growth factor-dependent MAPK and AKT activation. *Hum Mol Genet*. 2010;19:790–802.
20. Gripp KW, Hopkins E, Sol-Church K, Stabley DL, Axelrad ME, Doyle D, et al. Phenotypic analysis of individuals with Costello syndrome due to HRAS p.G13C. *Am J Med Genet A*. 2011;155A:706–16.
21. Digilio MC, Lepri F, Baban A, Dentici ML, Versacci P, Capolino R, et al. RASopathies: clinical diagnosis in the first year of life. *Mol Syndromol*. 2011;1:282–9.
22. Gripp KW, Stabley DL, Geller PL, Hopkins E, Stevenson DA, Carey JC, et al. Molecular confirmation of HRAS p.G12S in siblings with Costello syndrome. *Am J Med Genet A*. 2011;155A:2263–8.
23. Niihori T, Aoki Y, Okamoto N, Ohashi H, Mizuno S, Kawame H, et al. HRAS mutants identified in Costello syndrome patients can induce cellular senescence: possible implications for the pathogenesis of Costello syndrome. *J Hum Genet*. 2011;56:707–15.
24. Abe Y, Aoki Y, Kuriyama S, Okamoto N, Kurosawa K, Ohashi H, et al. Prevalence and clinical features of Costello syndrome and cardiofacio-cutaneous syndrome in Japan: findings from a nationwide epidemiological survey. *Am J Med Genet A*. 2012;158A:1083–94.
25. Lorenz S, Petersen C, Kordaß U, Seidel H, Zenker M, Kutsche K. Two cases with severe lethal course of Costello syndrome associated with HRAS p.G12C and p.G12D. *Eur J Med Genet*. 2012;55:615–9.
26. Siegel DH, Mann JA, Krol AL, Rauen KA. Dermatological phenotype in Costello syndrome: consequences of Ras dysregulation in development. *Br J Dermatol*. 2012;166:601–7.
27. Şimşek-Kiper PÖ, Alanay Y, Gülhan B, Lisowski C, Türkyilmaz D, Alehan D, et al. Clinical and molecular analysis of RASopathies in a group of Turkish patients. *Clin Genet*. 2013;83:181–6.
28. Lorenz S, Lisowski C, Simsek-Kiper PO, Alanay Y, Boduroglu K, Zenker M, et al. Functional analysis of a duplication (p.E63_D69dup) in the switch II region of HRAS: new aspects of the molecular pathogenesis underlying Costello syndrome. *Hum Mol Genet*. 2013;22:1643–53.
29. Triantafyllou P, Christoforidis A, Vargiami E, Zafeiriou DI. Growth hormone replacement therapy in Costello syndrome. *Growth Horm IGF Res*. 2014;24:271–5.
30. Sriboonnark L, Arora H, Falto-Aizpurua L, Choudhary S, Connelly EA. Costello syndrome with severe nodulocystic acne: unexpected significant improvement of acanthosis nigricans after oral isotretinoin treatment. *Case Rep Pediatr*. 2015;2015:934865.
31. Gripp KW, Sol-Church K, Smpokou P, Graham GE, Stevenson DA, Hanson H, et al. An attenuated phenotype of Costello syndrome in three unrelated individuals with a HRAS c.179G>A (p.Gly60Asp) mutation correlates with uncommon functional consequences. *Am J Med Genet A*. 2015;167A:2085–97.
32. Xu F, Wang HJ, Lin ZM, Yu B. Recurrent duplication mutation in HRAS causing mild Costello syndrome in a Chinese patient. *Clin Exp Dermatol*. 2015;40:404–7.
33. Blachowska E, Petriczko E, Horodnicka-Józwa A, Skórka A, Pelc P, Krajewska-Walasek M, et al. Recombinant growth hormone therapy in a girl with Costello syndrome: a 4-year observation. *Ital J Pediatr*. 2016;42:10.
34. Marukian NV, Levinsohn JL, Craiglow BG, Milstone LM, Choate KA. Palmoplantar keratoderma in Costello syndrome responsive to acitretin. *Pediatr Dermatol*. 2017;34:160–2.
35. Pelc M, Ciara E, Jezela-Stanek A, Cieślakowska A, Jurkiewicz D, Janeczko M, et al. Novel pathogenic variant in the HRAS gene with lethal outcome and a broad phenotypic spectrum among polish patients with Costello syndrome. *Clin Dysmorphol*. 2017;26:83–90.
36. Sánchez-Montenegro C, Vilanova-Sánchez A, Barrena-Delfa S, Tenorio J, Santos-Simarro F, García-Miñaur S, et al. Costello syndrome and umbilical ligament rhabdomyosarcoma in two pediatric patients: case reports and review of the literature. *Case Rep Genet*. 2017;2017:1587610.
37. Bertola D, Buscarilli M, Stabley DL, Baker L, Doyle D, Bartholomew DW, et al. Phenotypic spectrum of Costello syndrome individuals harboring the rare HRAS mutation p.Gly13Asp. *Am J Med Genet A*. 2017;173:1309–18.
38. Lloreda-Garcia JM, Pina-Molina JM, Fernández-Fructuoso JR. Deep palmar and plantar creases in Costello syndrome. *J Pediatr*. 2018;201:292.
39. Choi N, Ko JM, Shin SH, Kim EK, Kim HS, Song MK, et al. Phenotypic and genetic characteristics of five Korean patients with Costello syndrome. *Cytogenet Genome Res*. 2019;158:184–91.
40. Gripp KW, Baker L, Robbins KM, Stabley DL, Bellus GA, Kolbe V, et al. The novel duplication HRAS c.186_206dup p.(Glu62_Arg68dup): clinical and functional aspects. *Eur J Hum Genet*. 2020;28:1548–54.
41. Vuralli D, Kosukcu C, Taskiran E, Simsek-Kiper PO, Utine GE, Boduroglu K, et al. Hyperinsulinemic hypoglycemia in a patient with Costello syndrome: an etiology to consider in hypoglycemia. *Mol Syndromol*. 2020;11:207–16.
42. Qian W, Zhang M, Huang H, Chen Y, Park G, Zeng N, et al. Costello syndrome with special cutaneous manifestations and HRAS G12D mutation: a case report and literature review. *Mol Genet Genomic Med*. 2021;9:e1690.
43. Nagai K, Niihori T, Okamoto N, Kondo A, Suga K, Ohhira T, et al. Duplications in the G3 domain or switch II region in HRAS identified in patients with Costello syndrome. *Hum Mutat*. 2022;43:3–15.
44. Ríos-González BE, Rodríguez-Ortiz JF, Castro-Martínez AG, Magaña-Torres MT, Barros-Núñez P. Clinical and molecular characterization of Costello syndrome in unrelated Mexican patients. *Clin Dysmorphol*. 2022;31:55–8.
45. Syu YM, Lee HC, Chang JH, Lee C-L, Chuang CK, Chiu HC, et al. Rapid weight loss and severe failure to thrive mimicking lipodystrophy syndrome in a 1-year-old Taiwanese girl with Costello syndrome. *Children (Basel)*. 2022;9:905.
46. Lindsey-Temple S, Edwards M, Rickassel V, Rickassel V, Nauth T, Rosenberger G. A novel HRAS c.466C>T p.(Phe156Leu) variant in two patients with attenuated features of Costello syndrome. *Eur J Hum Genet*. 2022;30:1088–93.
47. Frey T, Ivanovski I, Bahr A, Zweier M, Laube J, Luchsinger I, et al. A very mild phenotype in six individuals of a three-generation family with the novel HRAS variant c.176C>G p.(Ala59Gly): emergence of a new HRAS-related RASopathy distinct from Costello syndrome. *Am J Med Genet A*. 2023;191:2074–82.
48. Bessis D, Morice-Picard F, Bourrat E, Abadie C, Aouinti S, Baumann C, et al. Dermatological manifestations in cardiofaciocutaneous syndrome: a prospective multicentric study of 45 mutation-positive patients. *Br J Dermatol*. 2019;180:172–80.
49. Siegel DH, McKenzie J, Frieden IJ, Rauen KA. Dermatological findings in 61 mutation-positive individuals with cardiofaciocutaneous syndrome. *Br J Dermatol*. 2011;164:521–9.
50. Bessis D, Miquel J, Bourrat E, Chiaverini C, Morice-Picard F, Abadie C, et al. Dermatological manifestations in Noonan syndrome: a

- prospective multicentric study of 129 patients positive for mutation. *Br J Dermatol.* 2019;180:1438–48.
51. Pernet C, Baumann C, Cavé H, Guillot B, Bessis D. ‘Cobblestone’ papillomatous linear papules of the upper lip: a new sign of Costello syndrome. *Br J Dermatol.* 2013;168:903–4.
 52. Tyler MT, Ficarra G, Silverman S Jr, Odom RB, Regezi JA. Malignant acanthosis nigricans with florid papillary oral lesions. *Oral Surg Oral Med Oral Pathol Oral Radiol Endod.* 1996;81:445–9.

SUPPORTING INFORMATION

Additional supporting information can be found online in the Supporting Information section at the end of this article.

How to cite this article: Bessis D, Bursztejn A-C, Morice-Picard F, Capri Y, Barbarot S, Aubert H, et al. Dermatological manifestations in Costello syndrome: A prospective multicentric study of 31 *HRAS*-positive variant patients. *J Eur Acad Dermatol Venereol.* 2024;00:1–10. <https://doi.org/10.1111/jdv.19996>