



HAL
open science

Human papillomavirus DNA and p16 expression in head and neck squamous cell carcinoma in young French patients

Chloé Molimard, Virginie L'huillier, Alexis Overs, Christine Soret, Marie-Paule Algros, Christiane Mougin, David Guenat, Olivier Mauvais, Jean-Luc Prétet

► To cite this version:

Chloé Molimard, Virginie L'huillier, Alexis Overs, Christine Soret, Marie-Paule Algros, et al.. Human papillomavirus DNA and p16 expression in head and neck squamous cell carcinoma in young French patients. *Journal of International Medical Research*, 2021, 49 (7), pp.030006052110225. 10.1177/03000605211022534 . hal-04602296

HAL Id: hal-04602296

<https://hal.science/hal-04602296>

Submitted on 8 Aug 2024

HAL is a multi-disciplinary open access archive for the deposit and dissemination of scientific research documents, whether they are published or not. The documents may come from teaching and research institutions in France or abroad, or from public or private research centers.

L'archive ouverte pluridisciplinaire **HAL**, est destinée au dépôt et à la diffusion de documents scientifiques de niveau recherche, publiés ou non, émanant des établissements d'enseignement et de recherche français ou étrangers, des laboratoires publics ou privés.

Human papillomavirus DNA and p16 expression in head and neck squamous cell carcinoma in young French patients

Journal of International Medical Research

49(7) 1–11

© The Author(s) 2021


Article reuse guidelines:

sagepub.com/journals-permissions

DOI: 10.1177/03000605211022534

journals.sagepub.com/home/imr



Chloé Molimard^{1,2}, Virginie L'Huillier³,
Alexis Overs⁴, Christine Soret¹,
Marie-Paule Algros², Christiane Mougin¹,
David Guenat^{1,5}, Olivier Mauvais³ and
Jean-Luc Prétet^{1,5} 

Abstract

Objectives: Human papillomavirus (HPV) is a risk factor for head and neck squamous cell carcinoma (HNSCC), which is currently increasing worldwide. We evaluated the prevalence of HPV DNA and p16 expression in HNSCC patients age <45 years compared with patients aged ≥45 years.

Methods: Thirty-nine patients aged <45 years who presented at Besançon University Hospital with HNSCC since 2005 were included in this retrospective study. HPV DNA was detected by HPV genotyping and p16 expression was determined by immunohistochemistry using paraffin-embedded tissues. A matched-group of 38 patients aged ≥45 years from Besançon University Hospital was included.

Results: The overall prevalence of HPV infection was 11.7%. HPV16 was the only genotype detected in 4/39 and 5/38 patients, and p16 was expressed in 6/39 and 4/38 patients aged <45 years and ≥45 years, respectively.

¹Centre National de Référence Papillomavirus, CHU Besançon, Besançon, France

²Service d'Anatomie et Cytologie Pathologiques, CHU Besançon, Besançon, France

³Service d'Oto-Rhino-Laryngologie, CHU Besançon, Besançon, France

⁴Laboratoire de Biochimie, CHU Besançon, Besançon, France

⁵EA3181, UFC, Université Bourgogne-Franche-Comté, LabEx LipSTIC ANR-11-LABEX-0021, Besançon, France

Corresponding author:

Jean-Luc Prétet, Centre National de Référence Papillomavirus, CHU Besançon, Bd Fleming, Besançon 25000, France.

Email: jean_luc.pretet@univ-fcomte.fr



Conclusions: HPV-positivity and p16 expression were similar in both age groups. The results suggest that p16 immunohistochemistry may provide a prognosis biomarker for all HNSCCs, not only oropharyngeal cancers, and this should be addressed in large clinical trials.

Keywords

Head and neck squamous cell carcinoma, human papillomavirus, p16 expression, young patient, biomarker, virus DNA

Date received: 28 October 2020; accepted: 13 May 2021

Introduction

More than 90% of all head and neck cancers are squamous cell carcinomas (SCCs), and head and neck SCCs (HNSCCs) constitute approximately 4% of all cancers, with more than 800,000 new cases diagnosed each year worldwide.¹ HNSCC arises in various anatomical sites, including the oral cavity, oropharynx, hypopharynx, and larynx, and mainly affects men in their fifth and sixth decades of life. However, the incidence of these tumors has tended to increase in developing countries since the 1980s,^{2,3} especially in patients <45 years old.⁴⁻⁶

Universally, the main risk factors for HNSCC remain tobacco exposure (either smoking or chewing tobacco) and, to a lesser extent, alcohol consumption. In 2007, the International Agency for Research on Cancer also recognized an increasing incidence of high-risk human papillomavirus (hrHPV)-associated HNSCC, and de Martel and collaborators estimated that HPV was present in approximately 7% of all HNSCCs worldwide and was responsible for 30% of oropharyngeal SCCs (OPSCCs) and 2.2% and 2.4% of oral cavity and laryngeal cancers, respectively.⁷ HPV16 accounts for most (85%) HPV+ HNSCCs.⁷ HPV-associated HNSCC are also more frequent in younger individuals, associated with an increased number of oral-sex partners and minimal or no exposure to tobacco.^{8,9}

HPV-related and HPV-unrelated HNSCCs present with different molecular carcinogenic pathways¹⁰ and show different treatment responses,^{8,11} and patients with HPV-related OPSCC having better survival than those with HPV-unrelated tumors.^{12,13} Consequently, the 2017 World Health Organization (WHO) Classification of Head and Neck Tumors included a new chapter on OPSCC related to HPV.¹⁴ The better outcome of HPV-associated HNSCC raises the issue of how best to distinguish between HPV- and non-HPV-associated SCCs.¹⁵ However, there is currently no consensus regarding the optimal method of detection of HPV,¹⁵ involving *in situ* hybridization to detect HPV DNA or RNA, HPV polymerase chain reaction (PCR) assays, reverse transcription-PCR, DNA/RNA microarrays, and immunohistochemical detection of p16.¹⁶ The WHO recently defined diffuse cytoplasmic and nuclear immunoreactivity for p16 as a reliable surrogate marker for the presence of hrHPV in OPSCC.¹⁴ The College of American Pathologists also recommends that pathologists test for hrHPV by p16 immunohistochemistry in all cases diagnosed as OPSCC.¹⁷ However, although the scoring system for defining p16 expression is well established in OPSCC,¹³ this is not the case for non-OPSCC.

Given that the epidemiology of HNSCC is changing, with an ever-increasing

incidence in young patients, it is important to conduct bioclinical studies in this population. The present study thus aimed to evaluate and compared the prevalence of HPV DNA and p16 expression in young (<45 years) and old (≥ 45 years) patients with HNSCC.

Materials and methods

The reporting of this study conformed to the REMARK statement.¹⁸

Patients

This retrospective study included all patients aged <45 years who were diagnosed with HNSCC and treated at the Otorhinolaryngology Department of the University Hospital of Besançon from January 2005 to June 2018. Oropharyngeal cancers were localized at the base of the tongue, the tonsils, and included one patients with regional lymph node metastasis of an unknown primary.¹⁹ Non-oropharyngeal cancers were localized at the mobile tongue, floor of mouth, retromolar trigone, and larynx. Patients with cancer of the nasopharynx, salivary glands, parotid glands, nasal cavity, middle ear, or sinus, and patients with non-SCC of the head and neck were excluded.

Information on patient characteristics and treatment methods were collected. Clinicopathologic data, including age at diagnosis, sex, tobacco and alcohol consumption, histopathological data, WHO performance status, tumor size, nodal stage, metastases, and anatomic site (oropharynx vs. other) were obtained by reviewing medical records. Data on the number of sexual partners were not available. All patient details were de-identified.

The age threshold for defining young and old patients was set at 45 years. Patients aged <45 years were compared with a matched group of patients aged ≥ 45 years (from University Hospital of

Besançon), according to tumor location, except for one patient aged <45 years with regional lymph node metastasis of an unknown primary, for whom no matched patient aged ≥ 45 years could be retrieved from the medical records.

Archival formalin-fixed paraffin-embedded (FFPE) tumor samples consisting of core biopsies or resections were provided by the regional biobank of Franche-Comté.

DNA extraction

DNA was extracted from FFPE tissue sections using a QIAamp DNA FFPE Tissue Kit[®] (Qiagen, Courtaboeuf, France) according to the manufacturer's instructions. Briefly, the paraffin was dissolved in xylene and samples were digested by proteinase K at 56°C overnight in ATL buffer. The lysates were then filtered through the columns provided in the kit, and DNA was eluted using 100 μ L of elution solution and was quantified by spectrophotometry.

HPV DNA testing

HPV genotyping was performed using an INNO-LiPA[®] HPV Genotyping Extra II assay (Fujirebio, Gent, Belgium), which allowed the identification of 32 different HPV genotypes based on PCR amplification followed by reverse hybridization. The amplicons were genotyped by hybridization to HPV type-specific oligonucleotide probes targeting the HPV L1 gene, and detected by alkaline-streptavidin conjugation and colorimetric analysis, according to the manufacturer's instructions. The strips were scanned and interpreted using Line Reader and Analysis Software (LiRAS[®]) (Fujirebio).

Immunohistochemical detection of p16

Immunohistochemical detection of p16 was performed using 3- μ m FFPE tissue sections,

with the monoclonal antibody clone E6H4 (Roche Diagnostics, Meylan, France) and a Benchmark automated system (Roche Diagnostics, Meylan, France), following the manufacturer's instructions. According to the guidelines from the College of American Pathologists, p16 was defined as positive when $\geq 70\%$ of tumor cells showed diffuse and strong cytoplasmic and nuclear staining¹⁷ (Figure 1). Staining in the cytoplasm alone, diffuse but weak staining, and/or focal/patchy staining were scored as negative.

Statistical analysis

Differences between the two age groups were evaluated by χ^2 test, Yates correction, and Fisher's test. Concordance between

HPV test presence/absence and p16 expression results was assessed by kappa score. All tests were two-tailed and the statistical significance threshold was set as $P < 0.05$. Statistical analysis was performed using R software version 3.5.1 (<https://www.r-project.org>) with the Survival Analysis package version 2.42-6.

Ethics

The regional biobank of Franche-Comté, France (registration number BB-0033-00024, Tumorothèque Régionale de Franche-Comté) ensured that all patients provided written informed consent. The project was approved by the scientific board of the biobank on 20 October 2018.

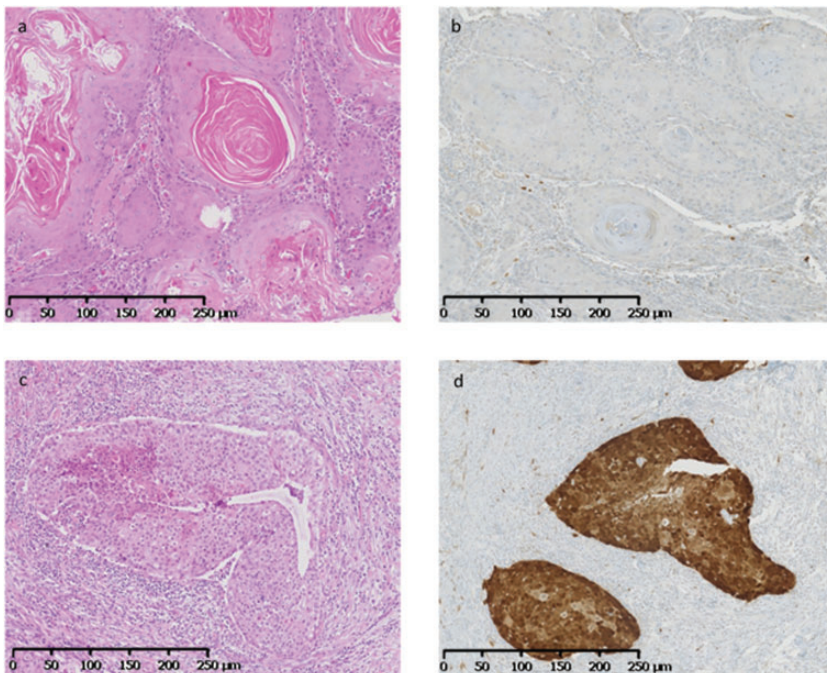


Figure 1. Immunostaining for p16. (a) Oral tongue squamous cell carcinoma with keratinization (hematoxylin and eosin (HE) $\times 100$); (b) lack of p16 expression in tumor cells (immunohistochemistry $\times 100$). (c) Regional lymph node metastasis of unknown primary, with non-keratinizing squamous cell carcinoma (HE $\times 100$); (d) expression of p16 in tumor cells indicated by diffuse nuclear and strong cytoplasmic staining (immunohistochemistry $\times 100$).

Results

Patient characteristics

The sociodemographic and clinicopathologic characteristics of the patients are shown in Table 1. There were 39 patients aged <45 years and 38 aged \geq 45 years. The overall male to female ratio was 0.97 (0.95 for younger patients and 1.1 for older patients). Data on tobacco and alcohol consumption were available for 70 and 68 patients, respectively, but there was no difference in tobacco or alcohol consumption between the two groups.

Most patients had non-OPSCC (79%). There were no significant differences in T and N classifications between the groups, but older patients had a significantly worse WHO performance status than younger patients ($P=0.004$). There was no difference in the treatments received by patients in the two age groups.

Regarding the histopathological characteristics of the tumors, keratinizing carcinoma, well-differentiated carcinoma, positive margins, perineural invasion, and vascular invasion occurred in 82% vs. 89%, 54% vs. 42%, 35% vs. 16%, 20.5% vs. 10.5%, and 20.5% vs. 13% of younger and older patients, respectively.

HPV status and p16 expression

The overall prevalence of HPV infection was 11.7%. HPV DNA was detected in 4 of 39 (10.2%) tumors in patients aged <45 years and in 5 of 38 (13.1%) tumors in patients aged \geq 45 years. Genotyping revealed that HPV16 was the only genotype in positive cases. Among the nine HPV16+ cases, six patients (66.7%) had oropharyngeal tumors, two (22.3%) had oral cavity tumors, and one (11.1%) had a laryngeal tumor (Table 1). HPV-positivity was significantly associated with oropharyngeal compared with non-oropharyngeal tumors

($P=0.002$). Tobacco and alcohol consumption were similar between patients with HPV+ and HPV- tumors.

Ten patients were positive for p16, including six younger and four older patients. Five p16+ cases corresponded to oropharyngeal tumors (50%) and five to oral cavity tumors (50%) (Table 2). There was no significant correlation between p16 expression and anatomical site.

Five tumors were HPV16+/p16+, four were HPV16+/p16-, and five were HPV16-/p16+. Given that p16 expression represents a surrogate marker of HPV infection, we calculated the agreement between HPV presence/absence and p16 detection, and showed a concordance of 88.3%. The kappa score was 0.46, indicating moderate agreement according to the Landis-Koch reference value. The detailed characteristics of the HPV16/p16-concordant and non-concordant cases are presented in Table 3.

Finally, the proportion of HPV+ samples in this small series of HNSCC increased from 7% (2/30) in 2005 to 2011 to 15% (7/47) in 2012 to 2018.

Discussion

We conducted a retrospective study including 39 patients aged <45 years and a matched group of 38 patients aged \geq 45 years with HNSCC treated at our University Hospital over a period of 13 years. There is currently no consensus in the literature regarding the threshold for differentiating between young and old patients, with previous authors using either 40 or 45 years.^{6,20-22} We therefore chose 45 years as the age threshold to define young and old patients.

HPV DNA was detected in 11.7% of HNSCCs in the present study, and HPV16 was the only genotype detected. This low prevalence may be explained by the localization of the tumors, which were mostly in

Table 1. Sociodemographic and clinicopathologic characteristics of patients with head and neck squamous cell carcinoma.

Characteristic	Age <45 years (n = 39)	Age ≥45 years (n = 38)	P-value
Age, years			
Median	39	65.3	
Range	25–44	48–85	
Sex			
Male	19	20	0.731
Female	20	18	
Tobacco consumption			
No	7	7	0.904
Yes	29	27	
Unknown	3	4	
Alcohol consumption			
No	17	12	0.418
Yes	19	20	
Unknown	3	6	
WHO Performance status			
0	27	12	0.004
1	10	17	
2–3	2	8	
Unknown	0	1	
T classification			
1	7	5	0.178
2	11	16	
3	9	3	
4	10	14	
Unknown	2	0	
N classification			
0	11	14	0.464
1–3	27	24	
Unknown	1	0	
M classification			
0	28	33	not evaluable
1	0	0	
Unknown	11	5	
Anatomic site			
Oropharyngeal	8	8	0.953
Non-oropharyngeal	31	30	
Treatment			
Surgery	9	13	0.279
Chemotherapy and/or radiotherapy	15	12	0.527
Surgery + adjuvant treatment	15	11	0.377
No treatment	0	2	0.240
HPV status			
HPV16+	4	5	0.967
HPV16–	35	33	
p16 expression			
p16+	6	4	0.768
p16–	33	34	

HPV, human papillomavirus, WHO, World Health Organization.

Table 2. Number of HPV16+ and p16+ tumors according to patient age group and localization.

Tumor location	Age <45 years			Age ≥45 years		
	n = 39	HPV16	p16	n = 38	HPV16	p16
Oropharynx						
Tonsil	7	1	1	7	3	2
Base of tongue	1	1	1	1	0	0
Regional lymph node metastasis of unknown primary	1	1	1	0	0	0
Non-oropharynx						
Mobile tongue	17	0	2	14	1	1
Floor of mouth	6	0	1	8	1	1
Retromolar trigone	3	0	0	2	0	0
Larynx	5	1	0	6	0	0

HPV, human papillomavirus.

Table 3. Clinicopathological characteristics of HPV/p16 concordant and non-concordant cases.

Case	HPV status	p16 staining	Anatomic site	Age (years)	Sex	Tobacco consumption	Alcohol consumption	Year of diagnosis
# 1	+	+	Base of tongue	44	F	Yes	No	2014
# 2	+	+	Tonsil	43	M	Yes	Yes	2009
# 3	+	+	RLNMUP	43	F	Yes	No	2014
# 8	+	+	Tonsil	67	F	No	No	2015
# 9	+	+	Tonsil	53	M	Yes	Yes	2015
# 4	+	-	Larynx	32	M	Yes	No	2016
# 10	+	-	Floor of mouth	52	M	NA	NA	2011
# 11	+	-	Mobile tongue	64	F	No	No	2014
# 12	+	-	Tonsil	63	M	No	No	2014
# 5	-	+	Mobile tongue	28	M	No	No	2015
# 6	-	+	Mobile tongue	44	M	Yes	Yes	2014
# 7	-	+	Floor of mouth	40	M	Yes	No	2013
# 13	-	+	Floor of mouth	65	M	Yes	Yes	2012
# 14	-	+	Mobile tongue	70	F	No	No	2016

HPV, human papillomavirus; F, female; M, male; NA, not available; RLNMUP: regional lymph node metastasis of unknown primary.

the oral cavity (79% of cases). The distribution of HPV+ tumors has accordingly been previously associated with specific anatomic sites in the head and neck and geographic regions.²³ In addition, HPV16 is the most common HPV type in these tumors worldwide.²³ The overall HPV prevalence in Europe is 41.4% for oropharyngeal

cancers, 17.5% for oral cavity cancers, and 20.9% for laryngeal cancers;²³ However, the prevalence in France is lower, including 34% of HPV+ oropharyngeal cancers and 4% of HPV+ oral cavity and laryngeal cancers.²⁴ In the current study, HPV DNA was detected in 5% of non-oropharyngeal tumors and 37.5% of

oropharyngeal tumors, in line with the French data.^{24,25} It has been postulated that HPV would be more prevalent in younger patients or in patients with less exposure to other known carcinogens, such as tobacco smoke or ethanol;²⁶ however, we found no difference in age at diagnosis or sex between HPV+ and HPV- patients. The clinicopathologic characteristics were also similar in both age groups, except for WHO performance status, which was significantly better in younger patients, as expected.²⁷ The current study found no difference in tobacco and alcohol consumption, as the two major risk factors for HNSCC development,²⁶ between the two groups of patients. However, tobacco (number of cumulative pack-years) and alcohol (quantity, frequency) consumption were not quantified in the medical records, and we therefore cannot exclude the possibility that the older patients had longer/higher exposures to tobacco and alcohol than the younger patients.²⁶

In this study, the proportion of HPV+ tumors increased approximately two-fold after 2011, in line with previous observations.^{28,29} However, this result must be interpreted cautiously because of the small number of HPV+ cases in this small series.

The cellular tumor suppressor protein p16^{INK4a} (p16) has been identified as a biomarker for transforming HPV infections.³⁰ In addition, p16 immunostaining has previously been assessed as a method for improving the interpretation of cervical lesions, triaging women with atypical squamous cell cytology of undetermined significance or low-grade squamous intraepithelial lesions, and for increasing the specificity of HPV testing.³¹ Overexpression of p16 has been widely accepted as a surrogate marker for HPV-positivity in OPSCC.³² In the present study, positive p16 immunostaining (defined by the College of American Pathologists¹⁷) was observed in 13% of HNSCCs, with an overall concordance of

88.3% between HPV detection and p16 expression in the analyzed samples. This high concordance was consistent with the findings of a meta-analysis by Albers et al., which showed a concordance of 86%.³³ However, Cohen's kappa coefficient only revealed a moderate agreement in the current study, possibly because of the high number of HPV-/p16- samples and the small number of HPV+ and/or p16+ samples. Interestingly, the five HPV+/p16+ cases had tumors in the oropharynx, which were caused by HPV.³⁴ Indeed, p16-positivity in this case is considered as a good marker of transcriptionally active HPV in oropharyngeal carcinogenesis.³⁵ In contrast, all but one HPV-/p16+ and one HPV+/p16- case were non-oropharyngeal tumors, for which the role of HPV infection in the carcinogenic process remains questionable, especially in HPV+/p16- cases.

Although HPV-related HNSCCs are associated with a better prognosis than HPV-unrelated HNSCCs, there is no consensus on the routine methods that should be used to identify HPV-induced HNSCC,¹⁵ or if HPV-based tests are more relevant than p16 staining.³⁶ Detection of HPV E6 and E7 mRNA by reverse transcriptase-PCR is currently considered to be the reference test for detecting transcriptionally active hrHPV infection.¹⁵ However, although the INNO-LiPA assay allows the detection of HPV DNA, it provides information about the virus presence but not about the infection state.¹⁵ HPV DNA-positivity may thus be less clinically valuable for identifying HPV-related HNSCC compared with E6/E7 oncogene mRNA, which stimulates cancerous lesion development.^{15,37} Nevertheless, Mena and collaborators³⁴ proposed that double positivity for HPV DNA and p16 was the optimal prognostic biomarker for HNSCC in clinical practice.

A preliminary analysis showed that younger patients with p16+ or HPV+

HNSCC tended to have a better prognosis in terms of overall and progression-free survival compared with patients with p16– or HPV– HNSCC (data not shown). This observation is consistent with the validation of p16 as a biomarker of good prognosis in OPSCC,¹⁷ and to a lesser extent in non-OPSCC.^{38–40}

This study had some limitations. First, it included a small series of patients from a single center, and this cohort may not be representative of French patients presenting with HNSCC overall. Second, this was a retrospective study, and follow-up of prospectively recruited patients would increase the robustness of this preliminary observation. In addition, further large clinical studies are needed, especially in patients <45 years, to determine if these biomarkers have a prognostic value regardless of the tumor location.

This study found no difference in HPV/p16 prevalence in HNSCC tumors between old and young patients. However, the high sensitivity of p16 immunostaining means that it would be interesting to extend its use for the clinical management of all HNSCCs (OPSCC and non-OPSCC), with subsequent confirmation of the viral etiology by the detection of HPV DNA.

Acknowledgments

The authors would like to thank the technicians and engineers from the HPV National Reference Center and the Cellular and Molecular Biology Laboratory and Pathology Department of the University Hospital of Besançon for excellent technical assistance. They also acknowledge the Tumorothèque Régionale de Franche-Comté for biobanking. Dr Julie Guillet is gratefully acknowledged for her critical comments on the manuscript.

Declaration of conflicting interest

The authors declared the following potential conflicts of interest with respect to the research, authorship, and/or publication of this

article: CMO, VL, AO, CS, MPA, DG, OM, and JLP declared that they have no competing interests. CM has received honoraria from MSD unrelated to this work.

Funding

This research received no specific grant from any funding agency in the public, commercial, or not-for-profit sectors.

ORCID iD

Jean-Luc Prétet  <https://orcid.org/0000-0002-8430-214X>

References

1. Bray F, Ferlay J, Soerjomataram I, et al. Global cancer statistics 2018: GLOBOCAN estimates of incidence and mortality worldwide for 36 cancers in 185 countries. *CA Cancer J Clin* 2018; 68: 394–424. Doi: 10.3322/caac.21492.
2. Chaturvedi AK, Anderson WF, Lortet-Tieulent J, et al. Worldwide trends in incidence rates for oral cavity and oropharyngeal cancers. *J Clin Oncol* 2013; 31: 4550–4559. Doi: 10.1200/JCO.2013.50.3870.
3. Van Dyne EA, Henley SJ, Saraiya M, et al. Trends in human papillomavirus-associated cancers - United States, 1999–2015. *MMWR Morb Mortal Wkly Rep* 2018; 67: 918–924. Doi: 10.15585/mmwr.mm6733a2.
4. Myers JN, Elkins T, Roberts D, et al. Squamous cell carcinoma of the tongue in young adults: increasing incidence and factors that predict treatment outcomes. *Otolaryngol Head Neck Surg* 2000; 122: 44–51. Doi: 10.1016/S0194-5998(00)70142-2.
5. Majchrzak E, Szybiak B, Wegner A, et al. Oral cavity and oropharyngeal squamous cell carcinoma in young adults: a review of the literature. *Radiol Oncol* 2014; 48: 1–10. Doi: 10.2478/raon-2013-0057.
6. Hussein AA, Helder MN, De Visscher JG, et al. Global incidence of oral and oropharynx cancer in patients younger than 45 years versus older patients: A systematic review. *Eur J Cancer* 2017; 82: 115–127. Doi: 10.1016/j.ejca.2017.05.026.

7. De Martel C, Plummer M, Vignat J, et al. Worldwide burden of cancer attributable to HPV by site, country and HPV type. *Int J Cancer* 2017; 141: 664–670. Doi: 10.1002/ijc.30716.
8. Gillison ML, D'Souza G, Westra W, et al. Distinct risk factor profiles for human papillomavirus type 16-positive and human papillomavirus type 16-negative head and neck cancers. *J Natl Cancer Inst* 2008; 100: 407–420. Doi: 10.1093/jnci/djn025.
9. Timbang MR, Sim MW, Bewley AF, et al. HPV-related oropharyngeal cancer: a review on burden of the disease and opportunities for prevention and early detection. *Hum Vaccin Immunother* 2019; 15: 1920–1928. Doi: 10.1080/21645515.2019.1600985.
10. Kobayashi K, Hisamatsu K, Suzui N, et al. A review of HPV-related head and neck cancer. *J Clin Med* 2018; 7: 241. Doi: 10.3390/jcm7090241.
11. You EL, Henry M and Zeitouni AG. Human papillomavirus-associated oropharyngeal cancer: review of current evidence and management. *Curr Oncol* 2019; 26: 119–123. Doi: 10.3747/co.26.4819.
12. Lacau St Guily J, Rousseau A, Baujat B, et al. Oropharyngeal cancer prognosis by tumour HPV status in France: The multicentric Papillophar study. *Oral Oncol* 2017; 67: 29–36. Doi: 10.1016/j.oraloncology.2017.01.012.
13. Ang KK, Harris J, Wheeler R, et al. Human papillomavirus and survival of patients with oropharyngeal cancer. *N Engl J Med* 2010; 363: 24–35. Doi: 10.1056/NEJMoa0912217.
14. Katabi N and Lewis JS. Update from the 4th Edition of the World Health Organization Classification of Head and Neck Tumours: What is new in the 2017 WHO Blue Book for tumors and tumor-like lesions of the neck and lymph nodes. *Head Neck Pathol* 2017; 11: 48–54. Doi: 10.1007/s12105-017-0796-z.
15. Kim KY, Lewis JS and Chen Z. Current status of clinical testing for human papillomavirus in oropharyngeal squamous cell carcinoma. *J Pathol Clin Res* 2018; 4: 213–226. Doi: 10.1002/cjp2.111.
16. Venuti A and Paolini F. HPV detection methods in head and neck cancer. *Head Neck Pathol* 2012; 6: S63–S74. Doi: 10.1007/s12105-012-0372-5.
17. Lewis JS, Beadle B, Bishop JA, et al. Human Papillomavirus Testing in Head and Neck Carcinomas: Guideline from the College of American Pathologists. *Arch Pathol Lab Med* 2018; 142: 559–597. Doi: 10.5858/arpa.2017-0286-CP.
18. Altman DG, McShane LM, Sauerbrei W, et al. Reporting recommendations for tumor marker prognostic studies (REMARK): explanation and elaboration. *BMC Med* 2012; 10: 51. Doi: 10.1186/1741-7015-10-51.
19. Schroeder L, Boscolo-Rizzo P, Dal Cin E, et al. Human papillomavirus as prognostic marker with rising prevalence in neck squamous cell carcinoma of unknown primary: A retrospective multicentre study. *Eur J Cancer* 2017; 74: 73–81. Doi: 10.1016/j.ejca.2016.12.020.
20. Martinez RCP, Sathasivam HP, Cosway B, et al. Clinicopathological features of squamous cell carcinoma of the oral cavity and oropharynx in young patients. *Br J Oral Maxillofac Surg* 2018; 56: 332–337. Doi: 10.1016/j.bjoms.2018.03.011.
21. Miranda Galvis M, Freitas Jardim J, Kaminagakura E, et al. Expression of cell cycle proteins according to HPV status in oral squamous cell carcinoma affecting young patients: a pilot study. *Oral Surg Oral Med Oral Pathol Oral Radiol* 2018; 125: 317–325. Doi: 10.1016/j.oooo.2018.01.003.
22. Young D, Xiao CC, Murphy B, et al. Increase in head and neck cancer in younger patients due to human papillomavirus (HPV). *Oral Oncol* 2015; 51: 727–730. Doi: 10.1016/j.oraloncology.2015.03.015.
23. Ndiaye C, Mena M, Alemany L, et al. HPV DNA, E6/E7 mRNA, and p16INK4a detection in head and neck cancers: a systematic review and meta-analysis. *Lancet Oncol* 2014; 15: 1319–1331. Doi: 10.1016/S1470-2045(14)70471-1.
24. Shield KD, Marant Micallef C, De Martel C, et al. New cancer cases in France in 2015 attributable to infectious agents: a systematic review and meta-analysis. *Eur J Epidemiol*

- 2018; 33: 263–274. Doi: 10.1007/s10654-017-0334-z.
25. Mirghani H, Bellera C, Delaye J, et al. Prevalence and characteristics of HPV-driven oropharyngeal cancer in France. *Cancer Epidemiol* 2019; 61: 89–94. Doi: 10.1016/j.canep.2019.05.007.
26. Dhull AK, Atri R, Dhankhar R, et al. Major risk factors in head and neck cancer: a retrospective analysis of 12-year experiences. *World J Oncol* 2018; 9: 80–84. Doi: 10.14740/wjon1104w.
27. Van Monsjou HS, Lopez-Yurda MI, Hauptmann M, et al. Oral and oropharyngeal squamous cell carcinoma in young patients: the Netherlands Cancer Institute experience. *Head Neck* 2013; 35: 94–102. Doi: 10.1002/hed.22935.
28. Chaturvedi AK, Engels EA, Anderson WF, et al. Incidence trends for human papillomavirus-related and -unrelated oral squamous cell carcinomas in the United States. *J Clin Oncol* 2008; 26: 612–619. Doi: 10.1200/JCO.2007.14.1713.
29. Chaturvedi AK, Engels EA, Pfeiffer RM, et al. Human papillomavirus and rising oropharyngeal cancer incidence in the United States. *J Clin Oncol* 2011; 29: 4294–4301. Doi: 10.1200/JCO.2011.36.4596.
30. Klaes R, Friedrich T, Spitkovsky D, et al. Overexpression of p16INK4a as a specific marker for dysplastic and neoplastic epithelial cells of the cervix uteri. *Int J Cancer* 2001; 92: 276–284.
31. Carozzi F, Confortini M, Dalla Palma P, et al. Use of p16-INK4A overexpression to increase the specificity of human papillomavirus testing: a nested substudy of the NTCC randomised controlled trial. *Lancet Oncol* 2008; 9: 937–945. Doi: 10.1016/S1470-2045(08)70208-0.
32. Khanal S, Ferraris ED, Zahin M, et al. Targeting synthetic Human Papillomavirus (HPV) L2 disulfide-induced N-terminus conformational epitopes for pan-HPV vaccine development. *Exp Mol Pathol* 2015; 99: 330–334. Doi: 10.1016/j.yexmp.2015.06.021.
33. Albers AE, Qian X, Kaufmann AM, et al. Meta analysis: HPV and p16 pattern determines survival in patients with HNSCC and identifies potential new biologic subtype. *Sci Rep* 2017; 7: 16715. Doi: 10.1038/s41598-017-16918-w.
34. Mena M, Taberna M, Tous S, et al. Double positivity for HPV-DNA/p16ink4a is the biomarker with strongest diagnostic accuracy and prognostic value for human papillomavirus related oropharyngeal cancer patients. *Oral Oncol* 2018; 78: 137–144. Doi: 10.1016/j.oraloncology.2018.01.010.
35. Taberna M, Mena M, Pavón MA, et al. Human papillomavirus-related oropharyngeal cancer. *Ann Oncol* 2017; 28: 2386–2398. Doi: 10.1093/annonc/mdx304.
36. Craig SG, Anderson LA, Schache AG, et al. Recommendations for determining HPV status in patients with oropharyngeal cancers under TNM8 guidelines: a two-tier approach. *Br J Cancer* 2019; 120: 827–833. Doi: 10.1038/s41416-019-0414-9.
37. Augustin J, Outh-Gauer S, Mandavit M, et al. Evaluation of the efficacy of the 4 tests (p16 immunochemistry, polymerase chain reaction, DNA, and RNA in situ hybridization) to evaluate a human papillomavirus infection in head and neck cancers: a cohort of 348 French squamous cell carcinomas. *Hum Pathol* 2018; 78: 63–71. Doi: 10.1016/j.humphath.2018.04.006.
38. Vitzthum LK and Mell LK. The role of p16 as a biomarker in nonoropharyngeal head and neck cancer. *Oncotarget* 2018; 9: 33247–33248. Doi: 10.18632/oncotarget.26053.
39. Bryant AK, Sojourner EJ, Vitzthum LK, et al. Prognostic role of p16 in nonoropharyngeal head and neck cancer. *J Natl Cancer Inst* 2018; 110: 1393–1399. Doi: 10.1093/jnci/djy072.
40. Harris SL, Thorne LB, Seaman WT, et al. Association of p16(INK4a) overexpression with improved outcomes in young patients with squamous cell cancers of the oral tongue. *Head Neck* 2011; 33: 1622–1627. Doi: 10.1002/hed.21650.