



**HAL**  
open science

## **Bilateral simultaneous chronic exertional compartment syndrome of the lateral forefoot: A case report (compartment syndrome of the forefoot)**

Guillaume Villatte, Edouard Fadlallah, Roger Erivan, Pierre-Louis Fournier, Stéphane Descamps, Stéphane Boisgard

### ► To cite this version:

Guillaume Villatte, Edouard Fadlallah, Roger Erivan, Pierre-Louis Fournier, Stéphane Descamps, et al.. Bilateral simultaneous chronic exertional compartment syndrome of the lateral forefoot: A case report (compartment syndrome of the forefoot). *Journal of Orthopaedic Surgery*, 2019, 27 (2), pp.230949901983964. 10.1177/2309499019839647. hal-04601864

**HAL Id: hal-04601864**

**<https://hal.science/hal-04601864>**

Submitted on 5 Jun 2024

**HAL** is a multi-disciplinary open access archive for the deposit and dissemination of scientific research documents, whether they are published or not. The documents may come from teaching and research institutions in France or abroad, or from public or private research centers.

L'archive ouverte pluridisciplinaire **HAL**, est destinée au dépôt et à la diffusion de documents scientifiques de niveau recherche, publiés ou non, émanant des établissements d'enseignement et de recherche français ou étrangers, des laboratoires publics ou privés.

# Bilateral simultaneous chronic exertional compartment syndrome of the lateral forefoot: A case report (compartment syndrome of the forefoot)

Guillaume Villatte<sup>1,2</sup> , Edouard Fadlallah<sup>1</sup>, Roger Erivan<sup>1,2</sup>, Pierre-Louis Fournier<sup>3</sup>, Stéphane Descamps<sup>1,2</sup> and Stéphane Boisgard<sup>1,2</sup>

## Abstract

A 20-year-old patient came to the sport medicine clinic for bilateral forefoot pain during sport activities (running) progressing for the last 3 months. Thanks to a positive measurement of the compartment pressure during a running test reproducing the symptomatology and exclusion of classical differential diagnosis, a bilateral chronic compartment syndrome of the lateral forefoot was confirmed. Three months after a surgical fasciotomy, the patient fully recovered. No previous study described this specific compartment of the forefoot.

**Level of evidence:** IV.

## Keywords

chronic, compartment syndrome, fasciotomy, lateral forefoot, pressure, sport

Date received: 20 November 2018; Received revised 28 February 2019; accepted: 4 March 2019

## Introduction

Compartment syndrome refers to all symptoms linked to an elevation of intra-compartmental pressure in a closed non-elastic muscle compartment surrounded by fascia and bone.

Common aetiologies of compartment syndromes are classified into two categories: acute (fractures, direct traumas, vascular problems, burnings, casts) or chronic (exertion induced).

Even if compartment syndrome can occur in all compartments of the body, it is mainly famous after fracture of the lower leg (1.2% after closed tibial diaphyseal fracture) and the forearm.<sup>1,2</sup> Concerning the forefoot, acute syndromes are largely unrecognized but some authors<sup>3</sup> reported a rate of 25% in Chopart dislocations and 34% in Lisfranc dislocations. Chronic syndromes seem to be far more infrequent with only few case reports in the literature.<sup>4–10</sup>

The anatomy and the number of compartments have been discussed for a long, but a most recent publication described nine compartments in the forefoot.<sup>11</sup> This case report is dealing with a non-previous described location of

<sup>1</sup>Service d'Orthopédie-Traumatologie, Hôpital Gabriel Montpied, CHU de Clermont Ferrand BP 69, Clermont Ferrand, France

<sup>2</sup>Institut de Chimie de Clermont-Ferrand, Université Clermont Auvergne, SIGMA Clermont, Clermont-Ferrand, France

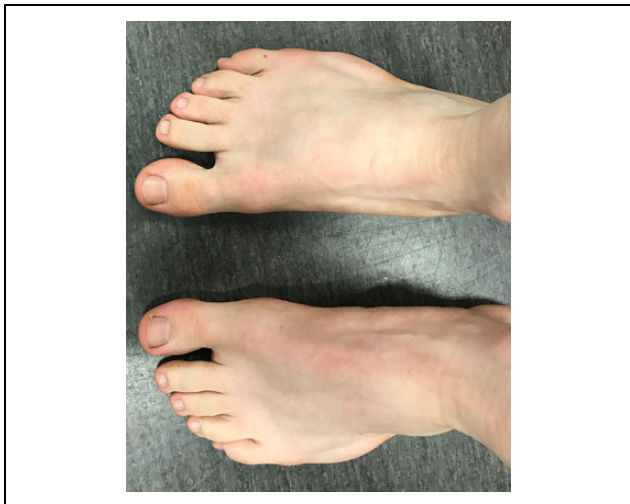<sup>3</sup>Service d'orthopédie, Clinique Pôle Santé République, Clermont Ferrand, France

## Corresponding author:

Guillaume Villatte, Service d'Orthopédie-Traumatologie, Hôpital Gabriel Montpied, CHU de Clermont Ferrand BP 69, 63003 Clermont Ferrand Cedex 01, France.

Email: guivillatte@gmail.com





**Figure 1.** Aspect of the feet (bulge aspect of the lateral part) on clinical examination.

chronic bilateral lateral compartment syndrome of the forefoot induced by exertion.

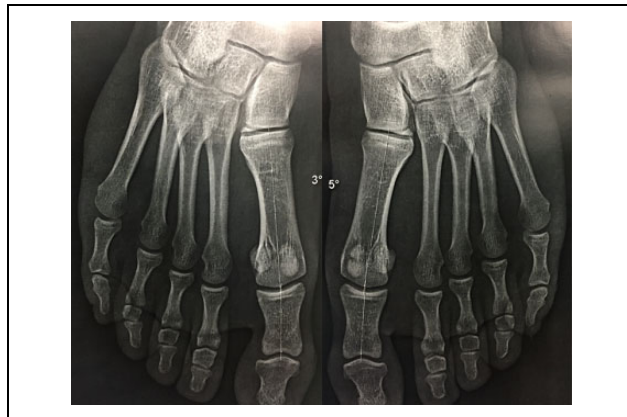## Case report

A 20-year-old man studying in Sport Science and Physical Activity, without any past medical history of trauma or disease, came to the sport medicine clinic for focused pain of the lateral part of the forefeet occurring with exertion especially after 10 to 20 min of running. His symptoms lasted for 3 months despite the use of ice and non-steroidal anti-inflammatory drugs and avoiding his regular sport training. The patient is a well-fit young man practising lots of sports including rugby and cycling at a non-competitive level. No recent changes in activities and sports devices have been reported by the patient during the previous months.

Clinical examination only showed a bulge aspect of the lateral part of the feet (Figure 1).

X-rays (Figure 2) and MRI (Figure 3) were carried out to eliminate frequent diagnoses like stress fracture and periostitis or less usual conditions like tenosynovitis, vascular and neurological entrapment syndrome, primary muscular disorders, and tumours.

A running test on a treadmill reproducing the symptomatology was undertaken to measure the compartment pressures of the painful location. Bilateral pain of the lateral part of the forefeet occurred after 10 min running and was evaluated with Visual Analog Scale (VAS) 8/10. Compartment pressure measurements (using the Stryker Pressure Monitor) exhibited a major increase of pressure for both forefeet lateral compartment (Figure 4) from 12 mmHg at rest to 58 mmHg after 10 min of running. The diagnosis of chronic bilateral lateral compartment syndrome of the forefoot induced by exertion was asserted.



**Figure 2.** X-rays (antero-posterior view) of the feet, showing soft tissue swelling at the lateral aspect of the forefeet.

After general information, patient's consent was obtained and surgery was performed 1 month later.

Following an ultrasound-guided locoregional anaesthesia, the procedure was performed on both sides. Tourniquet on the legs was insufflated (for 25 min on the right side and 20 min on the left one), and the procedure was carried out through a dorsolateral approach of the lateral compartment. Firstly, the fascia of the Abductor digiti quint and Flexor digiti minimi muscles was completely split (Figure 5), and secondly these muscles were retracted to perform the fasciotomy of the lateral intermuscular septum. Finally, skin was directly sutured.

Postoperative care consisted in standard dressings, full-weight bearing, and rest. Exertion was prohibited for 1 month.

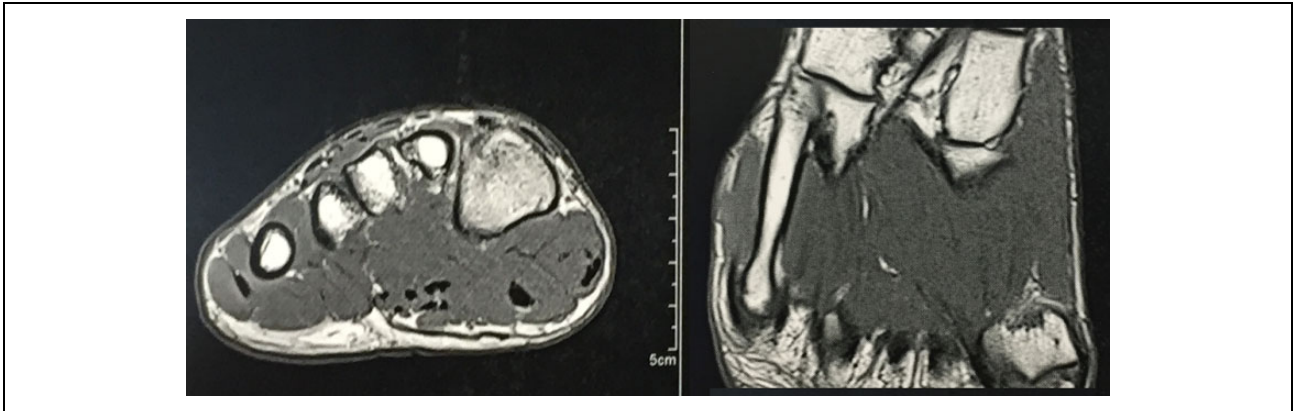
No complication occurred in the postoperative period. One month later, the patient started non micro-trauma activities and at 3 months, was able to run for nearly 1 hour without pain. At 6 months, he fully recovered and new compartment pressure measurements exhibited a decrease of more than 60% compared to preoperative measurements (around 22 mmHg after 10 min of running; Figure 6).

## Discussion

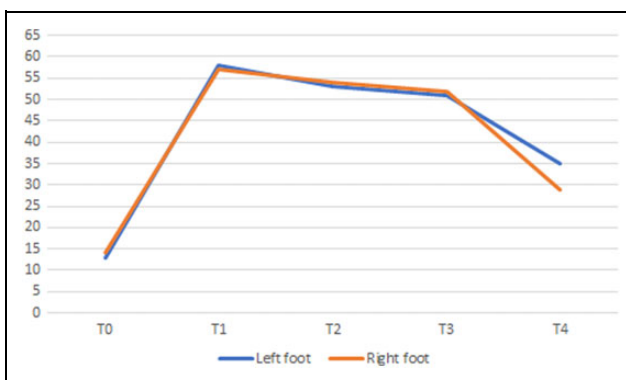
The clinical entity of chronic exertional compartment syndrome has been described for a long, but the pathophysiology remains unclear.<sup>12</sup> Different phenomena seem to be involved: increased muscle bulk, fascia thickness and stiffness, stimulation of fascial sensory stretch-receptors, poor venous return, micromuscular injuries, and small clinical myopathic abnormalities. The most affected compartment is the anterior compartment of the lower leg,<sup>13,14</sup> but there are also case reports and case series describing a chronic exertional compartment syndrome of the foot.<sup>4-9</sup>

The positive diagnosis is asserted on a body of evidence including:

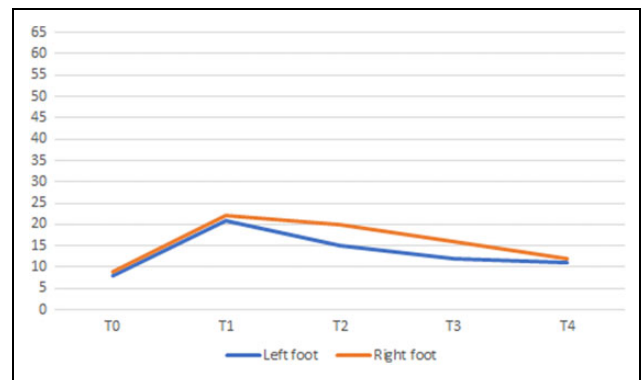
- systematic and reproducible exertion-related pain;



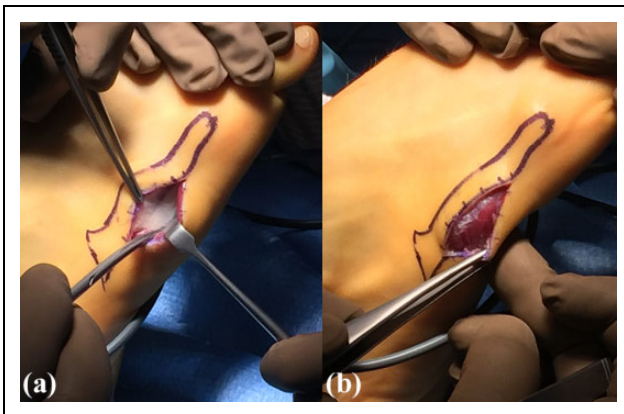
**Figure 3.** MRI imaging (axial and coronal views) of the right foot with a bulge aspect of the soft tissues in the lateral compartment.



**Figure 4.** Compartment pressure measurements (in mmHg) for both forefeet lateral compartment before surgery. At rest (T0), at maximum pain (T1), 1 min (T2) to 3 min (T3) and 20 min (T4) after running stop.



**Figure 6.** Compartment pressure measurements (in mmHg) for both forefeet lateral compartment after surgery. At rest (T0), at maximum pain (T1), 1 min (T2) to 3 min (T3) and 20 min (T4) after running stop.



**Figure 5.** Intraoperative views: (a) before and (b) splitting of the fascia of the abductor digiti quinti and flexor digiti minimi muscles.

- presence of risk factors such as sex (male), young age (20–25 years), active wealthy person (athlete), and microtrauma activities (running);
- elimination of classic differential diagnosis like stress fracture (at least with X-rays); and

- positive compartment pressure measurements during an exertional test. This method is considered as the gold standard, even if, since its first description in 1975,<sup>15</sup> no consensual criterion for interpretation have been established.<sup>4</sup>

Medical treatment consisting in rest, ice, non-steroidal anti-inflammatory drugs and physiotherapy is known. Nevertheless, results are inconstant and usually inferior to surgical fasciotomy. Moreover, surgical treatment must be recommended if symptoms are recurrent because some cases of progression to acute syndrome leading to urgent surgery have been described. Today, the indication for fasciotomy should rely on either clinical symptoms or risk factors because no cut-off is known for pressure measurement in chronic syndrome. In acute syndrome, a differential pressure between compartment pressure and diastolic pressure of less than 30 mmHg is frequently chosen.<sup>4,16</sup>

## Conclusion

Chronic compartment syndrome is an underestimated aetiology for exertion-related pain in athletes. It must be evoked

each time other diagnosis such as stress fracture is eliminated even if the location is uncommon. Compartment pressure measurements could be helpful to strengthen this diagnosis.


### Declaration of conflicting interests

The author(s) declared no potential conflicts of interest with respect to the research, authorship, and/or publication of this article.

### Funding

The author(s) received no financial support for the research, authorship, and/or publication of this article.

### ORCID iD

Guillaume Villatte  <https://orcid.org/0000-0002-4322-6304>

### References

- DeLee JC and Stiehl JB. Open tibia fracture with compartment syndrome. *Clin Orthop* 1981; 160: 175–184.
- Gondolini G, Schiavi P, Pogliacomi F, et al. Long-term outcome of mini-open surgical decompression for chronic exertional compartment syndrome of the forearm in professional motorcycling riders. *Clin J Sport Med Off J Can Acad Sport Med* 2017; 10: 48–55. DOI: 10.1097/JSM.0000000000000539.
- Richter M, Wippermann B, Krettek C, et al. Fractures and fracture dislocations of the midfoot: occurrence, causes and long-term results. *Foot Ankle Int* 2001; 22(5): 392–398.
- Frink M, Hildebrand F, Krettek C, et al. Compartment syndrome of the lower leg and foot. *Clin Orthop* 2010; 468(4): 940–950.
- Jowett A, Birks C and Blackney M. Chronic exertional compartment syndrome in the medial compartment of the foot. *Foot Ankle Int* 2008; 29(8): 838–841.
- Lokiec F, Siev-Ner I and Pritsch M. Chronic compartment syndrome of both feet. *J Bone Joint Surg Br* 1991; 73(1): 178–179.
- Mollica MB. Chronic exertional compartment syndrome of the foot. A case report. *J Am Podiatr Med Assoc* 1998; 88(1): 21–24.
- Muller GP and Masquelet AC. Chronic compartment syndrome of the foot. A case report. *Rev Chir Orthop Repar Appar Mot* 1995; 81(6): 549–552.
- Seiler R and Guziec G. Chronic compartment syndrome of the feet. A case report. *J Am Podiatr Med Assoc* 1994; 84(2): 91–94.
- Vajapey S and Miller TL. Evaluation, diagnosis, and treatment of chronic exertional compartment syndrome: a review of current literature. *Phys Sportsmed* 2017; 45(4): 391–398.
- Manoli A and Weber TG. Fasciotomy of the foot: an anatomical study with special reference to release of the calcaneal compartment. *Foot Ankle* 1990; 10(5): 267–275.
- Shah SN, Miller BS and Kuhn JE. Chronic exertional compartment syndrome. *Am J Orthop Belle Mead NJ* 2004; 33(7): 335–341.
- Bong MR, Polatsch DB, Jazrawi LM, et al. Chronic exertional compartment syndrome: diagnosis and management. *Bull Hosp Jt Dis* 2005; 62(3–4): 77–84.
- Fouasson-Chailloux A, Menu P, Alloreant J, et al. Determination of the predictive clinical parameters to diagnose chronic exertional compartment syndrome. *Eur J Sport Sci* 2018; 18(2): 279–285.
- Reach JS, Amrami KK, Felmlee JP, et al. Anatomic compartments of the foot: a 3-Tesla magnetic resonance imaging study. *Clin Anat* 2007; 20(2): 201–208.
- McQueen MM and Court-Brown CM. Compartment monitoring in tibial fractures. The pressure threshold for decompression. *J Bone Joint Surg Br* 1996; 78(1): 99–104.