



**HAL**  
open science

## **Assessment of Meibomian glands morphology and tear film quality in dogs diagnosed with idiopathic sebaceous adenitis or leishmaniosis: a pilot study**

Coline Jondeau, Adrien Caillon, Matthieu Bott, Renald Bonte, Helene Dropsy, Amaury Briand, Odile Crosaz, Noëlle Cochet-Faivre, Charline Pressanti, Jean-Yves Douet, et al.

### ► **To cite this version:**

Coline Jondeau, Adrien Caillon, Matthieu Bott, Renald Bonte, Helene Dropsy, et al.. Assessment of Meibomian glands morphology and tear film quality in dogs diagnosed with idiopathic sebaceous adenitis or leishmaniosis: a pilot study. ECVO Annual Conference, May 2024, Amsterdam, Netherlands. hal-04601332

**HAL Id: hal-04601332**

**<https://hal.science/hal-04601332v1>**

Submitted on 4 Jun 2024

**HAL** is a multi-disciplinary open access archive for the deposit and dissemination of scientific research documents, whether they are published or not. The documents may come from teaching and research institutions in France or abroad, or from public or private research centers.

L'archive ouverte pluridisciplinaire **HAL**, est destinée au dépôt et à la diffusion de documents scientifiques de niveau recherche, publiés ou non, émanant des établissements d'enseignement et de recherche français ou étrangers, des laboratoires publics ou privés.

# Assessment of Meibomian glands morphology and tear film quality in dogs diagnosed with idiopathic sebaceous adenitis or leishmaniosis: a pilot study

C. Jondeau<sup>1</sup>, A. Caillon<sup>2</sup>, M. Bott<sup>1</sup>, R. Bonte<sup>2</sup>, H. Dropsy<sup>3</sup>, A. Briand<sup>3</sup>, O. Crosaz<sup>3</sup>, N. Cochet-Faivre<sup>3</sup>, C. Pressanti<sup>2</sup>, J.-Y. Douet<sup>2,4</sup>, M. Delverdier<sup>5</sup>, S. Chahory<sup>1</sup>

<sup>1</sup> Ecole Nationale Vétérinaire d'Alfort, CHUVA, Department of Veterinary Ophthalmology, Maisons-alfort, France

<sup>2</sup> Ecole Nationale Vétérinaire de Toulouse, CHUVAC, Université de Toulouse, Toulouse, France

<sup>3</sup> Ecole Nationale Vétérinaire d'Alfort, CHUVA, Department of Veterinary Dermatology, Maisons-alfort, France

<sup>4</sup> Ecole Nationale Vétérinaire de Toulouse, IHAP, INRAE, Toulouse, France

<sup>5</sup> Ecole Nationale Vétérinaire de Toulouse, Anatomical Pathology Department, Toulouse, France

## Introduction

Meibomian glands are holocrine, modified sebaceous glands, located in the tarsal plate of the eyelids. They provide the oily component to the precorneal tear film, thus retarding evaporation of tears over the cornea. Interest in meibomian gland dysfunction (MGD) is growing in veterinary medicine and has been identified in 70% of eyes with ocular surface disorders. MGD is a multifactorial condition and research on potential role of comorbidities is lacking. As meibomian and sebaceous glands share similar anatomy and physiology, this study focus on idiopathic sebaceous adenitis (SA) and canine leishmaniosis (CL), two diseases with skin disorders related to inflammatory infiltration of sebaceous glands.

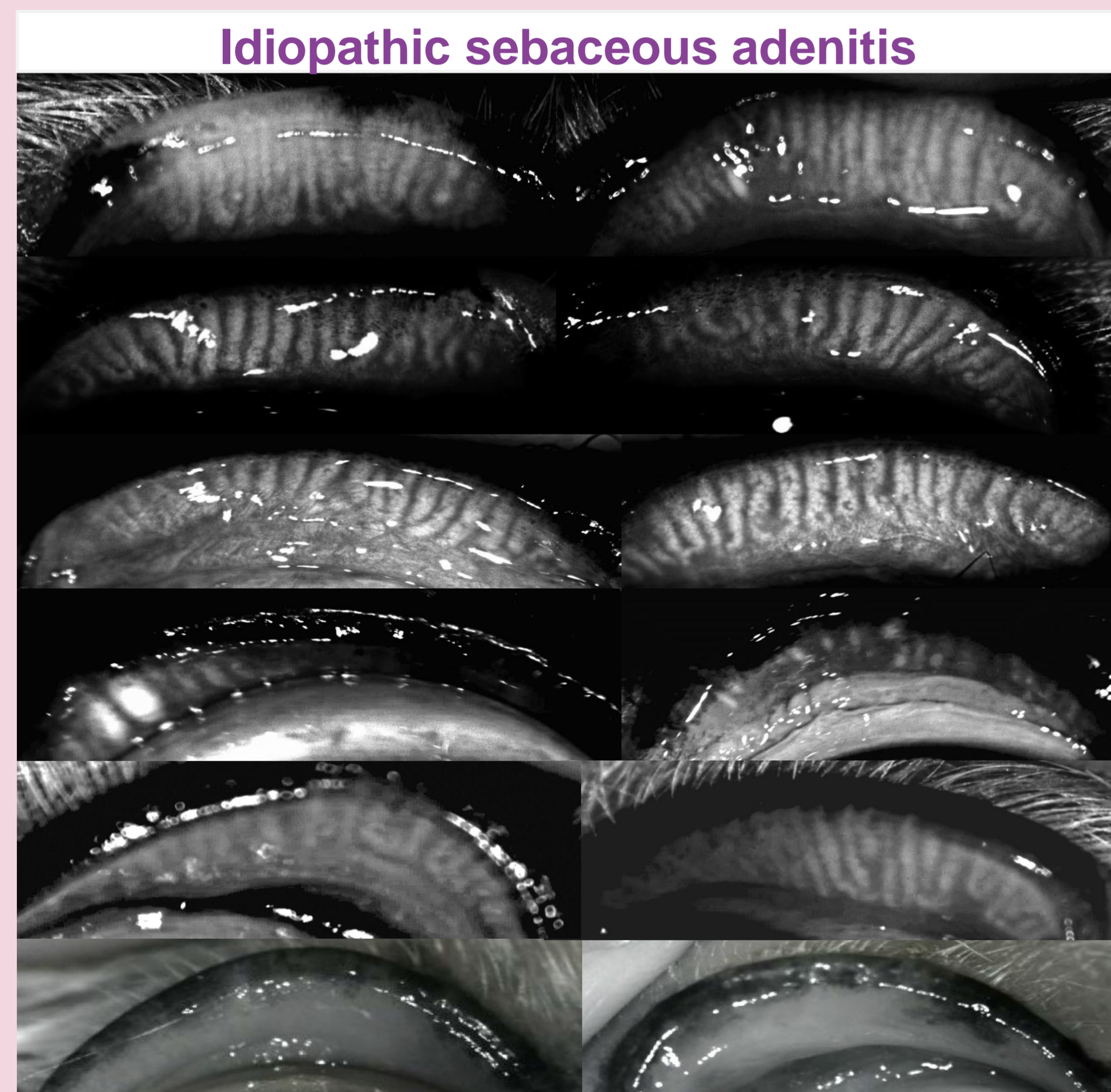
## Methods

**Idiopathic sebaceous adenitis**  
Histopathology

**Leishmaniosis**  
Serology  
+/- Histopathology

- Ophthalmic examination
- Dermatologic examination
- Tear film interferometry (OSA-VET<sup>ND</sup>)
- Noncontact infrared meibography (OSA-VET<sup>ND</sup>)
- Schirmer tear test 1
- Fluorescein staining

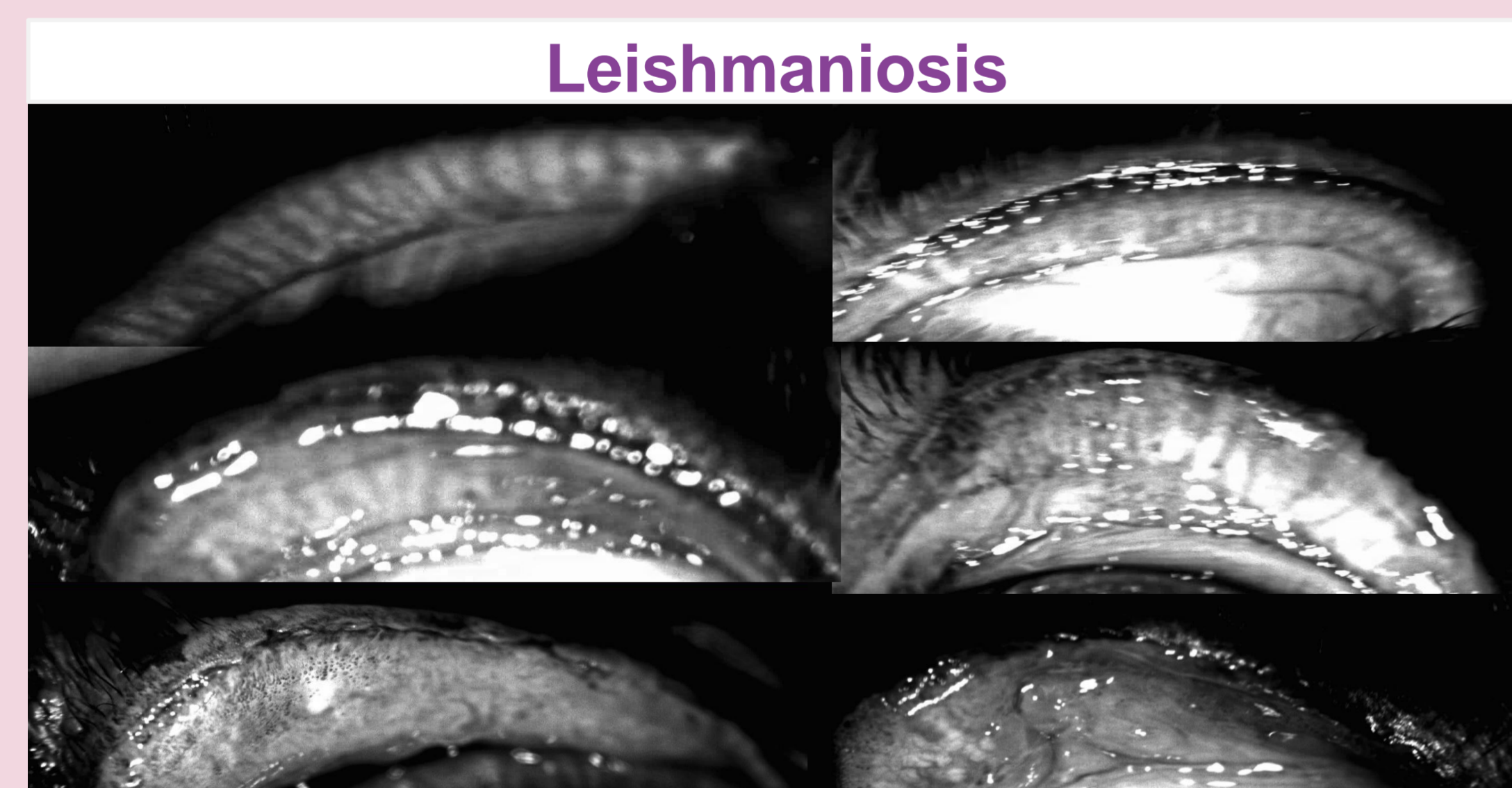## Meibography



Morphological abnormalities

< 25 %

> 75 %



< 25 %

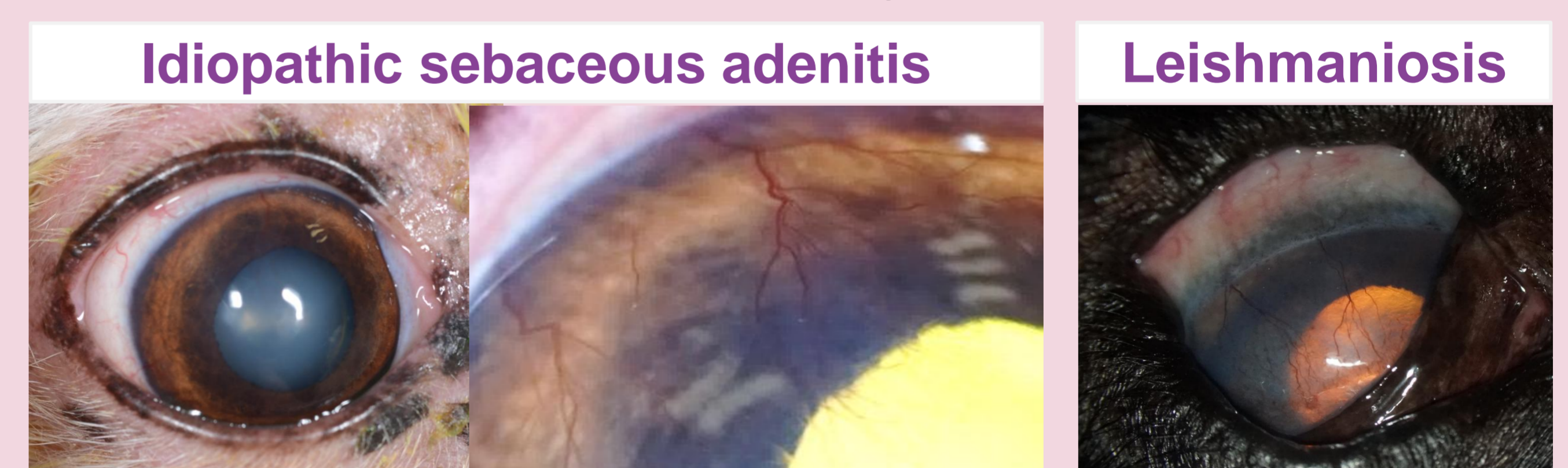> 75 %

## Results

### Clinical examination

MG morphological change	< 25%	> 75%
Mild ocular pruritus	4/7	2/2
Epiphora	3/7	2/2
Conjunctival hyperemia	3/7	2/2
Corneal neovascularization / fibrosis	0	2/2
Corneal ulceration	0	0
Punctate superficial fluorescein staining	0	2/2
STT-1 values < 15mm/min	0	0

### Severe cases Meibomian gland abnormalities > 75%



### Interferometry

Score of 1 for all dogs



## Conclusion

Meibography detects various level of meibomian gland atrophy in dogs affected with idiopathic SA or CL. In most cases, the clinical impact was inconsequential, but in two cases, severe ocular surface alteration was observed. History of chronic disease (1 SA, 1 CL) without adequate therapy was reported for the two severely affected cases.

## References

- Giuliano EA. Diseases and surgery of the canine lacrimal secretory system. In: *Veterinary Ophthalmology*. Vol 1. 6th ed. John Wiley & Sons; 2021:1008.
- Viñas M, Maggio F, D'Anna N, Rabozzi R, Peruccio C. Meibomian gland dysfunction (MGD), as diagnosed by non-contact infrared Meibography, in dogs with ocular surface disorders (OSD): a retrospective study. *BMC Vet Res*. 2019
- Kitamura Y, Maehara S, Nakade T, et al. Assessment of meibomian gland morphology by noncontact infrared meibography in Shih Tzu dogs with or without keratoconjunctivitis sicca. *Vet Ophthalmol*. 2019
- Jeong D, Kang S, Shim J, Lee E, Jeong Y, Seo K. Evaluation of ocular surface parameters in dogs with and without meibomian gland dysfunction. *Vet Rec*. 2022
- Sartori R, Peruccio C. A Case of Sebaceous Adenitis and Concurrent Meibomian Gland Dysfunction in a Dog. *Vet Sci*.
- Naranjo C, Fondevila D, Leiva M, Roura X, Peña T. Characterization of lacrimal gland lesions and possible pathogenic mechanisms of keratoconjunctivitis sicca in dogs with leishmaniosis. *Vet Parasitol*. 2005