



HAL
open science

Large palpebral cystadenomatosis in a cat, successfully managed by diode laser vaporization

Matthieu Bott, Sabine Chahory, Jessica Damsten, Louis Humeau, Eddy Nassif, Valentine Muller, Edouard Reyes-Gomez, Noëlle Cochet-Faivre

► To cite this version:

Matthieu Bott, Sabine Chahory, Jessica Damsten, Louis Humeau, Eddy Nassif, et al.. Large palpebral cystadenomatosis in a cat, successfully managed by diode laser vaporization. ECVO Annual Conference, May 2024, Amsterdam, Netherlands. hal-04601326

HAL Id: hal-04601326

<https://hal.science/hal-04601326>

Submitted on 4 Jun 2024

HAL is a multi-disciplinary open access archive for the deposit and dissemination of scientific research documents, whether they are published or not. The documents may come from teaching and research institutions in France or abroad, or from public or private research centers.

L'archive ouverte pluridisciplinaire **HAL**, est destinée au dépôt et à la diffusion de documents scientifiques de niveau recherche, publiés ou non, émanant des établissements d'enseignement et de recherche français ou étrangers, des laboratoires publics ou privés.

Large palpebral cystadenomatosis in a cat, successfully managed by diode laser vaporization

M. Bott¹, S. Chahory¹, J. Damstén¹, L. Humeau², E. Nassif², V. Muller³, E. Reyes Gomez³, N. Cochet-Faivre^{2,4}

¹ Ecole Nationale Vétérinaire d'Alfort, Ophthalmology Unit, Maisons-Alfort, France

² Ecole Nationale Vétérinaire d'Alfort, Dermatology Unit, Maisons-Alfort, France

³ Ecole Nationale Vétérinaire d'Alfort, Histology and Anatomical Pathology Unit, Maisons-Alfort, France

⁴ Ecole Nationale Vétérinaire d'Alfort, ANSES, INRAE, Laboratoire de Santé Animale, BIPAR, Maisons-Alfort, France

Introduction. Palpebral cystadenomatosis is a benign cutaneous tumour of unknown origin. Excision might be necessary when there is discomfort or a potential risk of corneal injury. Surgical management can be challenging in cases with extensive involvement. This case report presents the management and outcomes of a large palpebral cystadenomatosis using a surgical diode laser in a cat.

Case presentation. A 7-year-old domestic shorthair cat was presented with palpebral lesions that had progressed since its adoption, 6 years earlier. It had an history of chronic kidney disease.

Physical examination. Multifocal to coalescent, large, blue-black, cystic nodules were identified, extending across the left cheek and lower eyelid (Fig. 1). Ocular surface integrity remained intact, with no abnormalities noted during the rest of the ophthalmologic and dermatologic examination.

Differential diagnosis. Apocrine cystadenomatosis or adenocarcinoma, pigmented follicular tumour, multiple apocrine cysts or follicular cysts, and melanocytic tumour were suspected.

Complementary examinations. Superficial ultrasonography (22 MHz) confirmed the presence of multiple anechoic cavities. Bacteriological culture of the cyst fluids yielded negative results. Histopathological analysis of incisional biopsies revealed multiple apocrine secretory adenomas and apocrine ductular adenomas, accompanied by significant secondary pyogranulomatous inflammation (Fig. 2), thereby confirming the diagnosis of apocrine cystadenomatosis.

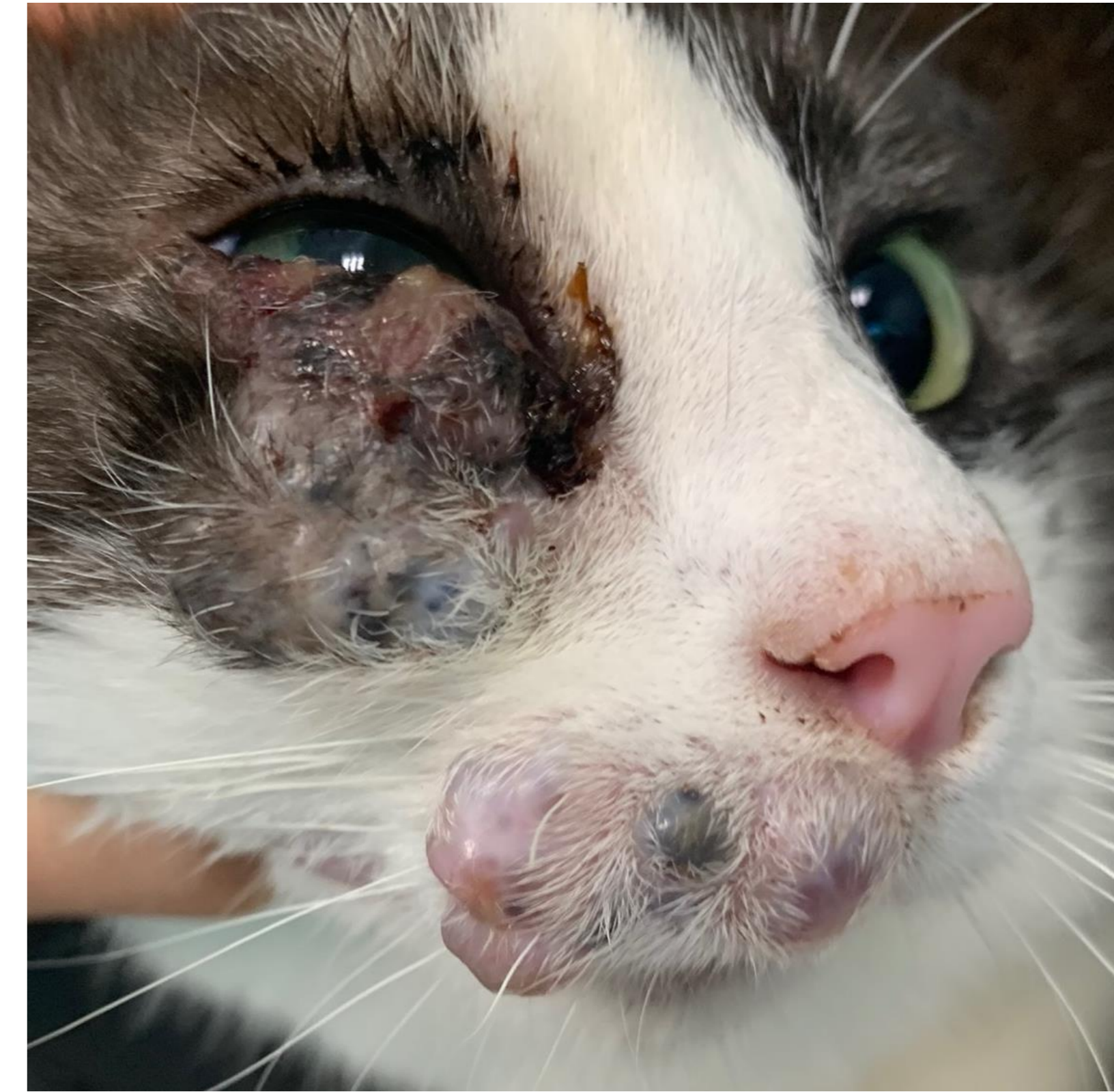

Fig. 1: Initial clinical presentation

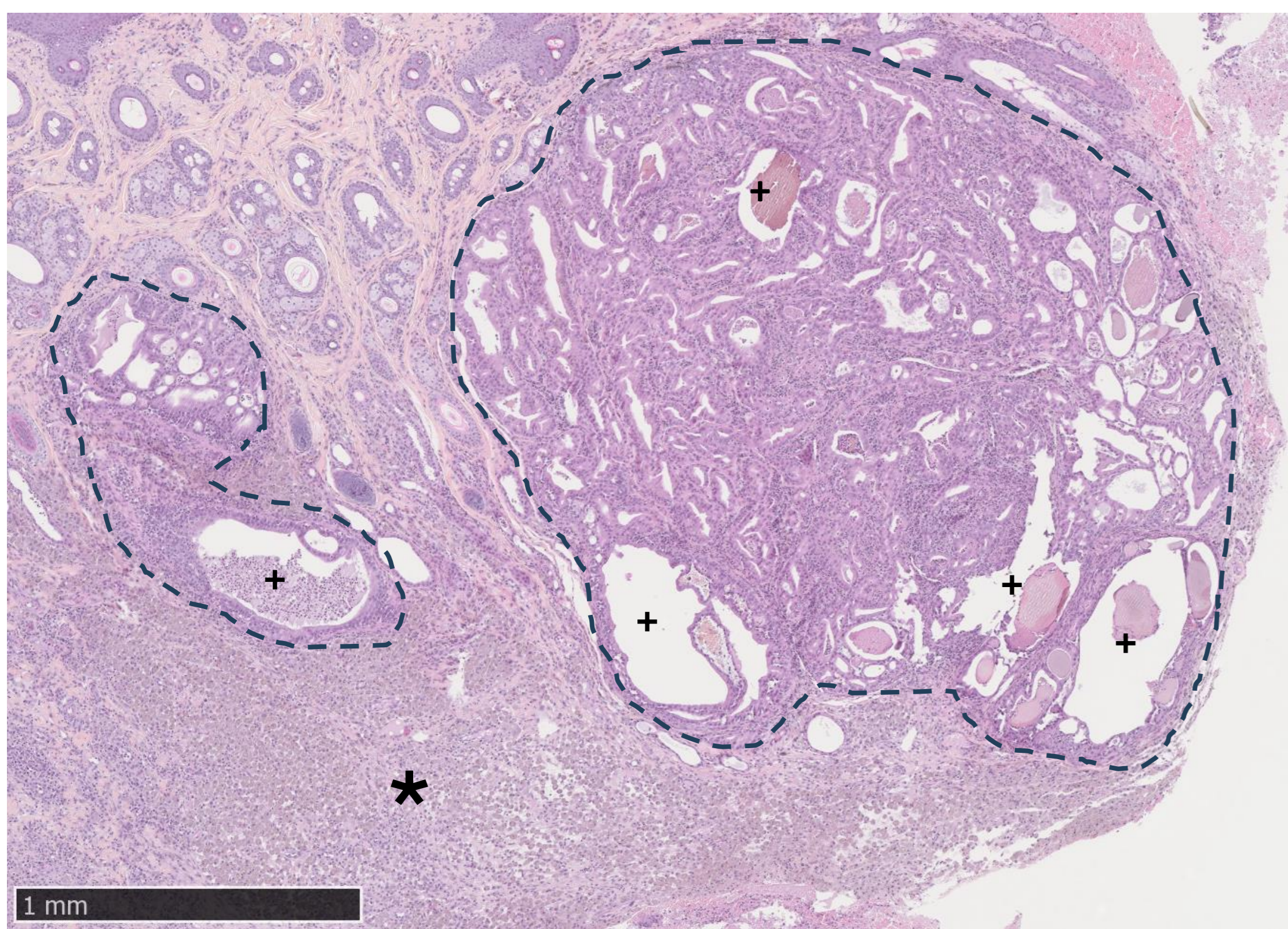


Fig. 2: Histologic features of the palpebral mass, HES. Note the granulomatous inflammation (*) surrounding a simple secretory adenoma (enclosed by a dotted line) with multiple cystic cavities (+) containing a brown secretory product

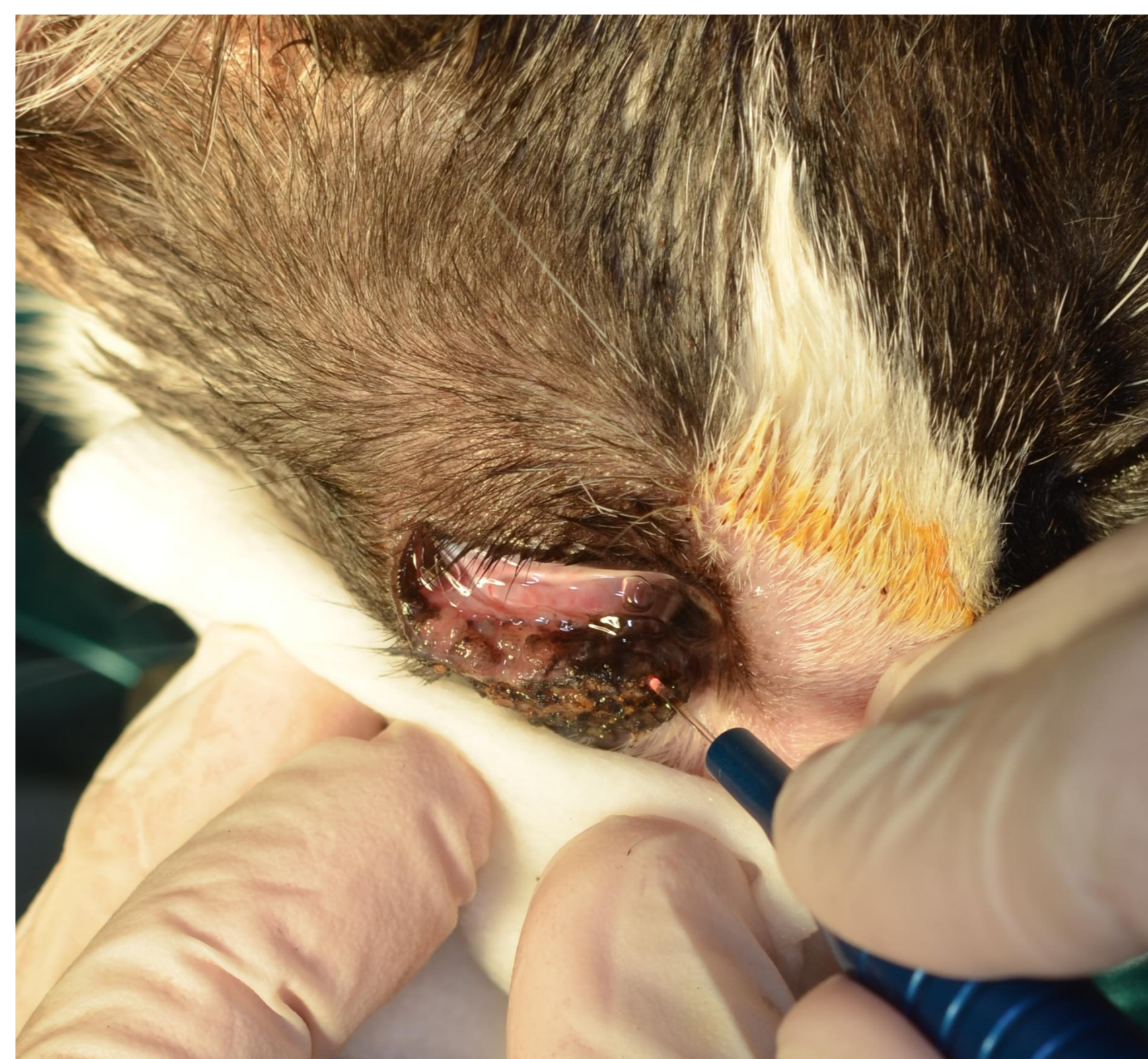

Fig. 3: Diode laser photovaporization

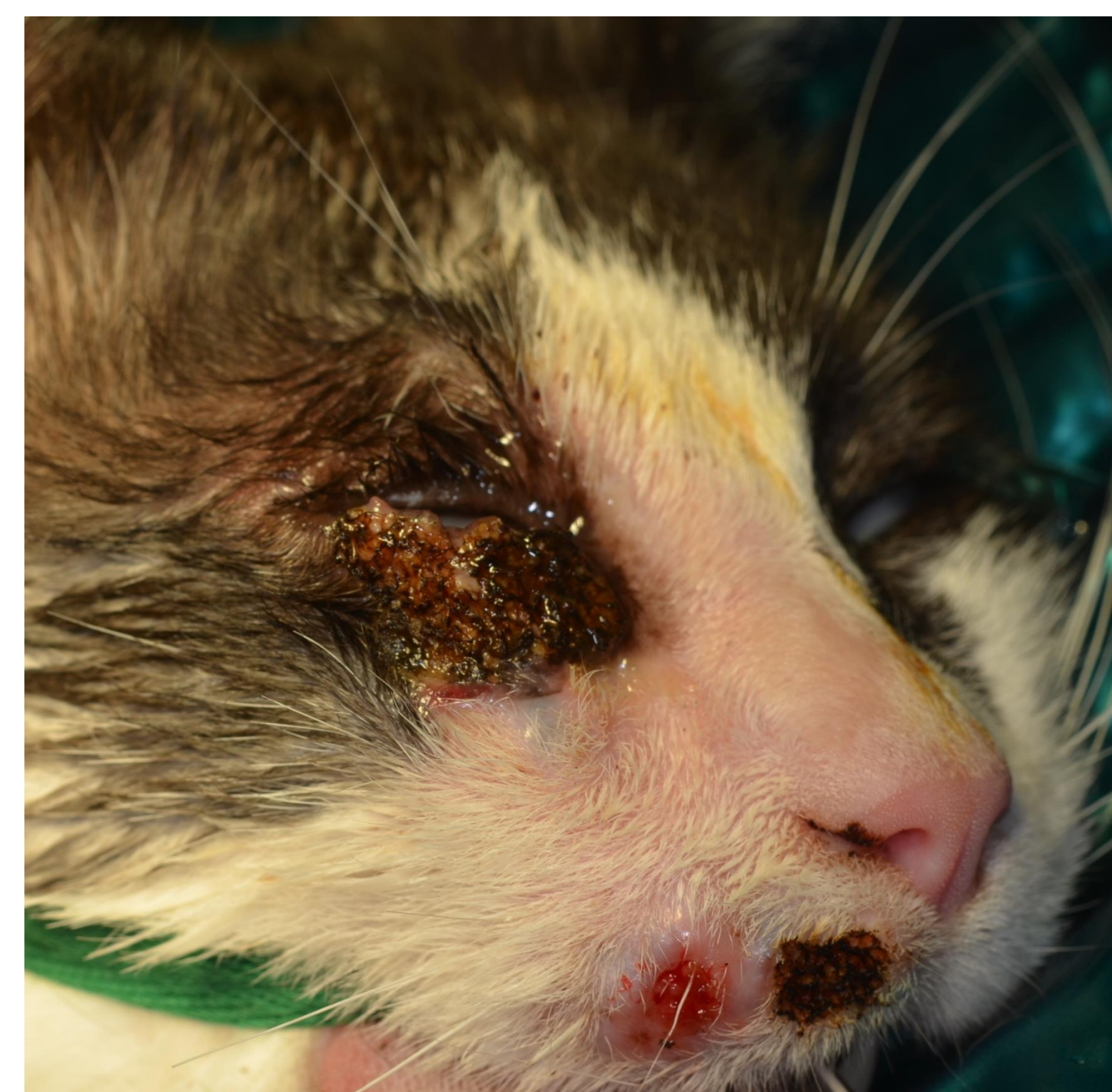

Fig. 4: Immediate post-operative appearance

Management. Due to the extent of the mass, surgical excision was not deemed suitable. Diode laser photovaporisation (600 nm contact fibre, Lumix Surgery Dual, Fisioline) was performed at a fluence of 2,7 J/cm, under general anesthesia (Fig. 3-4). Post-operative care included topical fusidic acid ointment on the lesions and systemic amoxicillin-clavulanic acid for 1 week.

Follow-up. The cat healed uneventfully. By the 3-month follow-up, a significant reduction in the size of the mass was observed, without signs of scarring, ectropion, or alterations in eyelid function (Fig. 5). Unfortunately, the cat succumbed to kidney failure 7 months after surgery. However, there were no indications of recurrence of the apocrine cystadenoma until its passing.

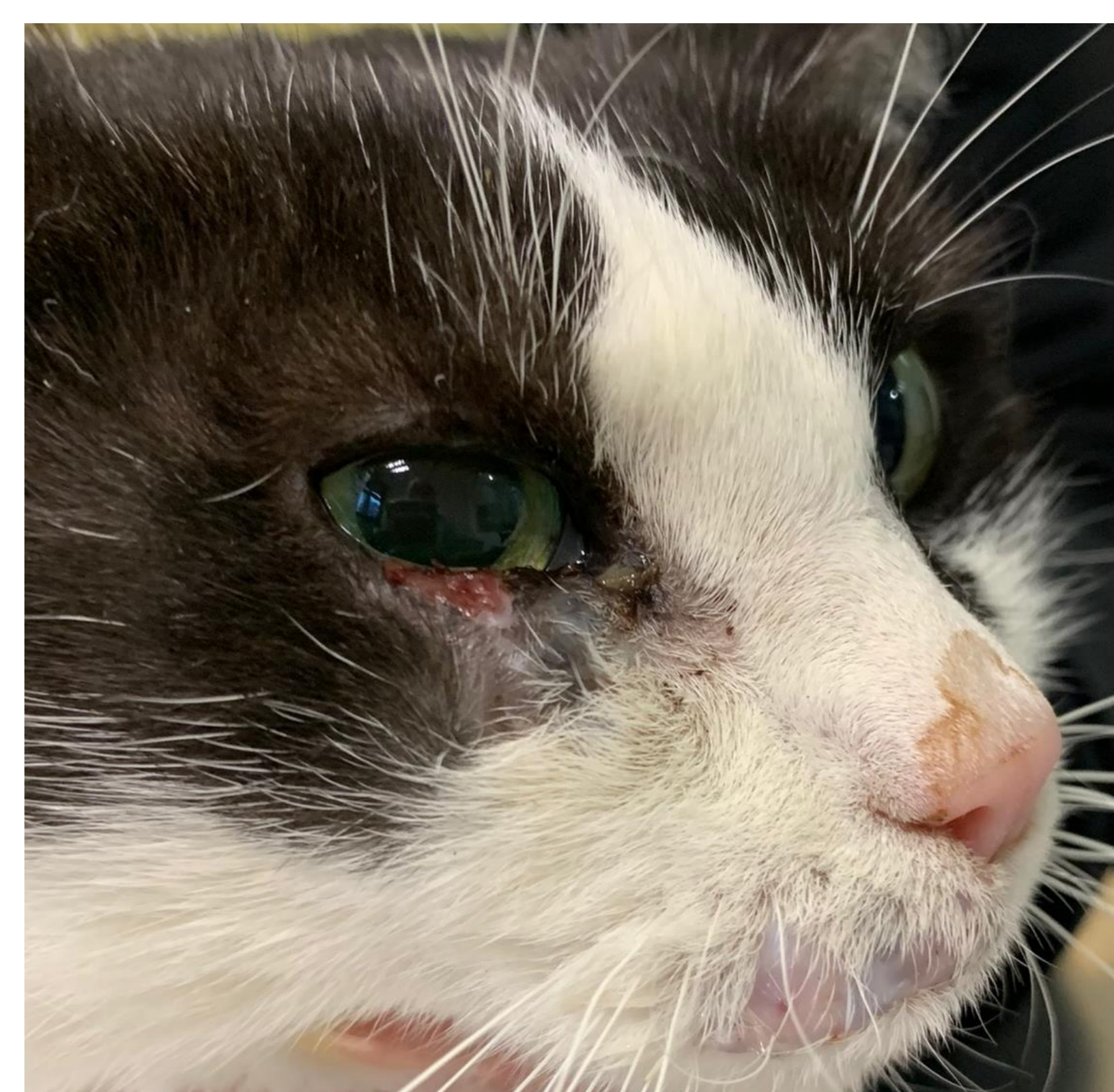


Fig. 5: Appearance at the 3-month follow-up

Discussion. Apocrine cystadenomas originate from modified apocrine glands, including Moll's glands near the eyelid margin. Treatment depends on lesion number, size, and impact on eyelid function. Surgical removal may be indicated but can lead to scarring, collateral tissue damage, or functional loss. Extensive lesions may preclude surgical excision^{1,2}.

Other therapies for feline palpebral cystadenomatosis include trichloroacetic acid (TCA) ablation, cauterization, cryoablation with liquid nitrogen, and CO₂ laser ablation. TCA ablation resulted in remission for up to 2 years in two cats^{3,4}, while CO₂ laser ablation showed excellent outcomes during a 10-month follow-up in another case².

Diode laser photovaporization has not been described for palpebral cystadenomatosis in cats. Its potential benefits, including efficient hemostasis and precise tissue removal, could reduce collateral damage, improve healing, and minimize scarring and functional impairment. This case suggests diode laser photovaporization may be a safe and effective option for large palpebral cystadenomatosis, but further studies are needed to confirm the therapeutic interest of this technology.

References. 1. Glaze MB, Maggs DJ, Plummer CE. Chapter 28: Feline Ophthalmology. In: Gelatt KN, Ben-Shlomo G, Hendrix DVH, et al. (eds) Veterinary ophthalmology: two volume set. Hoboken: John Wiley & Sons, Inc., 2021, pp. 1665-1840. | 2. Loek R, Knollinger A, Laporte C. Successful use of carbon dioxide laser for the treatment of eyelid cystadenomatosis (hidrocystomatosis) in a Persian cat. Vet Rec Case Rep 2023; 11: e617. | 3. Pigatto JAT, Silva AF, Seibel MP, et al. Trichloroacetic Acid Injection for Treatment of Eyelid Apocrine Hidrocystomas in a Cat. Top Companion Anim Med 2022; 46: 100594. | 4. Yang S-H, Liu C-H, Hsu C-D, et al. Use of chemical ablation with trichloroacetic acid to treat eyelid apocrine hidrocystomas in a cat. J Am Vet Med Assoc 2007; 230: 1170-1173.

École nationale vétérinaire d'Alfort

7 Avenue du Général de Gaulle

94 704 Maisons-Alfort Cedex

+33 1 43 96 72 72

vet-alfort.fr

The authors wish to thank the Pr Grégory Jouvion and Ms Typhène Chappron for their contribution, and Dômes Pharma France for their support.