



**HAL**  
open science

# Multimodal treatment of a preauricular and palpebral Feline Bowenoid In Situ Carcinoma (BISC) in a cat : Photodynamic Therapy, caudal auricular cutaneous flap and radiotherapy

Noëlle Cochet-Faivre, Arnaud Guionnet

► **To cite this version:**

Noëlle Cochet-Faivre, Arnaud Guionnet. Multimodal treatment of a preauricular and palpebral Feline Bowenoid In Situ Carcinoma (BISC) in a cat : Photodynamic Therapy, caudal auricular cutaneous flap and radiotherapy. ECVO Annual Conference, May 2024, Amsteram, Netherlands. hal-04601322

**HAL Id: hal-04601322**

**<https://hal.science/hal-04601322>**

Submitted on 4 Jun 2024

**HAL** is a multi-disciplinary open access archive for the deposit and dissemination of scientific research documents, whether they are published or not. The documents may come from teaching and research institutions in France or abroad, or from public or private research centers.

L'archive ouverte pluridisciplinaire **HAL**, est destinée au dépôt et à la diffusion de documents scientifiques de niveau recherche, publiés ou non, émanant des établissements d'enseignement et de recherche français ou étrangers, des laboratoires publics ou privés.

# Multimodal treatment of a preauricular and palpebral Feline Bowenoid In Situ Carcinoma (BISC) in a cat : Photodynamic Therapy, caudal auricular cutaneous flap and radiotherapy



A.GUIONNET<sup>1</sup>, PhD, N.COCHET FAIVRE<sup>1-2-3</sup>, DMV, Dip. ECVD  
Contact : arnaud.guionnet@vet-evolia.fr

1-Veterinary clinic Evolia, small animal ophthalmology department, L'Isle-Adam, France  
2-Ecole Nationale Vétérinaire d'Alfort, Dermatology Unit, Maisons-Alfort, France  
3-Ecole Nationale Vétérinaire d'Alfort, ANSES, INRAE, Laboratoire de Santé Animale, BIPAR,, Maisons-Alfort, France

## INTRODUCTION

**Bowenoid In Situ Carcinoma (BISC)**, also known as squamous cell carcinoma *in situ*, is a type of non-melanocytic **intraepidermal malignancy**. Although uncommon, it is most reported in cats over 10 years of age. FIV positive cats seems to be more affected.

The main triggers are **papillomavirus infection** (FcaPV-2, FcaPV-4)<sup>3</sup> and **solar radiation**.

It is clinically characterized by non pruritic papules, hyperkeratotic, érosive plaques sometimes hyperpigmented. Distribution is often multifocal and involves mainly the face, the neck and the limbs<sup>1,2</sup>.

Histologically, BISC lesions are characterized by hyperkeratosis, irregular epidermal hyperplasia, with broad rete ridges and full thickness epidermal dysplasia<sup>2</sup>.

Evolution is slow, but BISC can progress to locally invasive squamous cell carcinoma.

**Treatment can be challenging** according to multicentric evolution and anatomic locations. Many strategies have been described : cryotherapy, external radiation, surgery and recently PDT.

## METHODS

A twelve-year-old FIV+ cat was referred for unilateral temporal and palpebral progressive squamous-crusty lesions (Figure 1) that had developed over the past year. A previous biopsy performed had revealed BISC (Figure 3). Clinical exam was otherwise normal.

Daylight **photodynamic therapy (PDT)** was implemented as follows:

- Local cleaning of the lesions and withdrawing the crusts.
- Topical application of methyl-aminolevulinat (MAL) (Metvixia 168mg/g Galderma, La Defense, France) as photosensitive agent.
- The animal was kept in a dark room for 30 minutes.
- It was then exposed to daylight in a shaded outdoor area for two hours.

Three sessions were performed one month apart. This led to an almost complete regression of the lesions (Figure 3) and stabilization for 18 months. Clinical relapse and progressive worsening of the lesions led to a new consultation. Eyelids were motionless and a severe keratoconjunctivitis had developed. Cutaneous biopsies and a new session of PDT was performed under general anesthesia. After topical MAL application, exposition to an artificial monochromatic light ( $\lambda=630\text{ nm}$ ) with a Lumix Surgical Dual Veterinary Laser was performed after a latency of 15 minutes. Settings used were as follows: Fluence 37.04 J/cm<sup>2</sup>, Mean Power 0.4 W, total Energy 185.2 J, time 7'43". **Biopsy confirmed the diagnosis of Feline BISC without evolution towards invasiveness**. Despite an observed cutaneous lesional stabilization for four months this procedure failed to improve ocular comfort and keratoconjunctivitis progressed.

**Aggressive surgery** was elected and performed, consisting of enucleation and extensive removal of the affected skin followed by **caudal auricular axial pattern flap reconstruction** (Figures 4,5 and 6). Surgical procedure took place without significant complication. A new histological analysis was performed and pointed out sound but narrow margins (3mm).

Sacha was then referred for **radiotherapy** three weeks after surgery. Adjuvant external beam radiotherapy was performed over a fortnight (42 Gy in fourteen 3 Gy daily sessions).

## RESULTS

The cat recovered completely and **didn't present any lesional relapse to this day** (12 months after the end of radiotherapy) (Figure 7).

## CONCLUSION

Nowadays, "other than surgical" efficient strategies exist to treat feline BISC. They can be especially useful in "difficult" anatomic localizations. These allow to avoid, delay or complete surgery.

**PDT is based on the cytotoxicity of a photosensitive agent** Exposition to light leads to a transformation of this agent into an excited state which then transfers this energy to oxygen or other cells' molecules to form cytotoxic free radicals. Cellular damage and cell death end the process. MAL as a sensitizer (precursor of Protoporphyrin IX) combines efficiency and innocuity. Daylight or monochromatic light can be used to initiate PDT with the same efficiency<sup>4</sup>. Regression of lesions can be expected in 85% to 96% of patients<sup>5</sup>. Subsequent recurrence is frequent (63,6% of cases) and **PDT is not adapted to deep or invasive lesions** due to low penetration of MAL<sup>5</sup>.

**Surgery remains the principal option** in rebellious cases or well localized cases. Large excision is mandatory to expect a complete healing. Lack of skin can be overcome by the use of locoregional flaps. Caudal auricular axial pattern flap is a versatile, efficient and reliable flap<sup>6-7</sup>. Included vascular caudal auricular pedicle improves its perfusion and viability. It allows to obtain a long and large enough flap to reconstruct large cutaneous defects in the orbital area. Complications are frequent (50%) but rarely lead to failure of the technique<sup>7</sup>.

Adjuvant external radiotherapy was used in this case to enhance the likelihood of complete recovery considering the difficulty to correctly assess the lesions' margins.

The proximity of the eye complicated the therapeutic strategy. Owing to definitive lack of mobility of the eyelids and severity of corneal damage, sacrifice of the eye was thought necessary.

The originality of this case lies in its multimodal treatment, which has so far resulted in a survival of more than 900 days after the first consultation. **Daylight phototherapy** has not been described in cats and **reconstruction using the caudal auricular flap technique with adjuvant radiotherapy is uncommonly used**.

## REFERENCES

- 1-Heller WB, Jr, Vossler M, Miller, Scott D.W., Suter M.M. (1992). Multicentric Squamous Cell Carcinomas *In Situ* Resembling Bowen's Disease in Five Cats. *Vet. Dermatol.* Vol 3, 177-1882.
- 2-Wilhelm S., Degorce-Rubiales F., Godson D., Favrot C. (2006). Clinical, histological and immunohistochemical study of feline viral plaques and Bowenoid In Situ Carcinomas. *Journal compilation of the European society of veterinary dermatology.* Vol 17, 424-431.
- 3-Vascellari M., Mazzei M., Zanardello C. et al. (2019). Feline Catus papillomavirus types 1, 2, 3, 4 and 5 in Feline Bowenoid In Situ Carcinoma : an in situ hybridization study. *Veterinary Pathology.* Vol 56 (6), 818-825.
- 4-Kuonen F., Gaide O. (2014). Nouvelle lumière sur la thérapie photodynamique cutanée. *Revue médicale suisse.* Vol 10, 754-759.
- 5-Stell A.J., Dobson J.M., Langmack K. (2001). Photodynamic therapy of feline superficial squamous cell carcinoma using topical 5-aminolevulinic acid. *Journal of Small Animal Practice.* Vol 42, 164-169.
- 6-Guzu M., Rossetti D., Hennet P. (2021). Locoregional flap reconstruction following oro-maxillofacial oncologic surgery in dogs and cats : a review and decisional algorithm. *Frontiers in Veterinary Science* Vol 8, 1-20.
- 7-Proot J.L.J., Jeffery N., Culp W.T.N. et al. (2019). Is the caudal auricular axial pattern flap robust ? A multi-center cohort study of 16 dogs and 12 cats (2005 to 2016). *Journal of Small Animal Practice.* Vol 60, 102-106.

Complete references can be obtained via mail to the author.

## PURPOSE AND CONFLICTS OF INTEREST

To describe a clinical case presenting an uncommon disease : Feline Bowenoid In Situ Carcinoma (BISC) in the periocular area and its multimodal treatment. The author doesn't declare any conflict of interest.

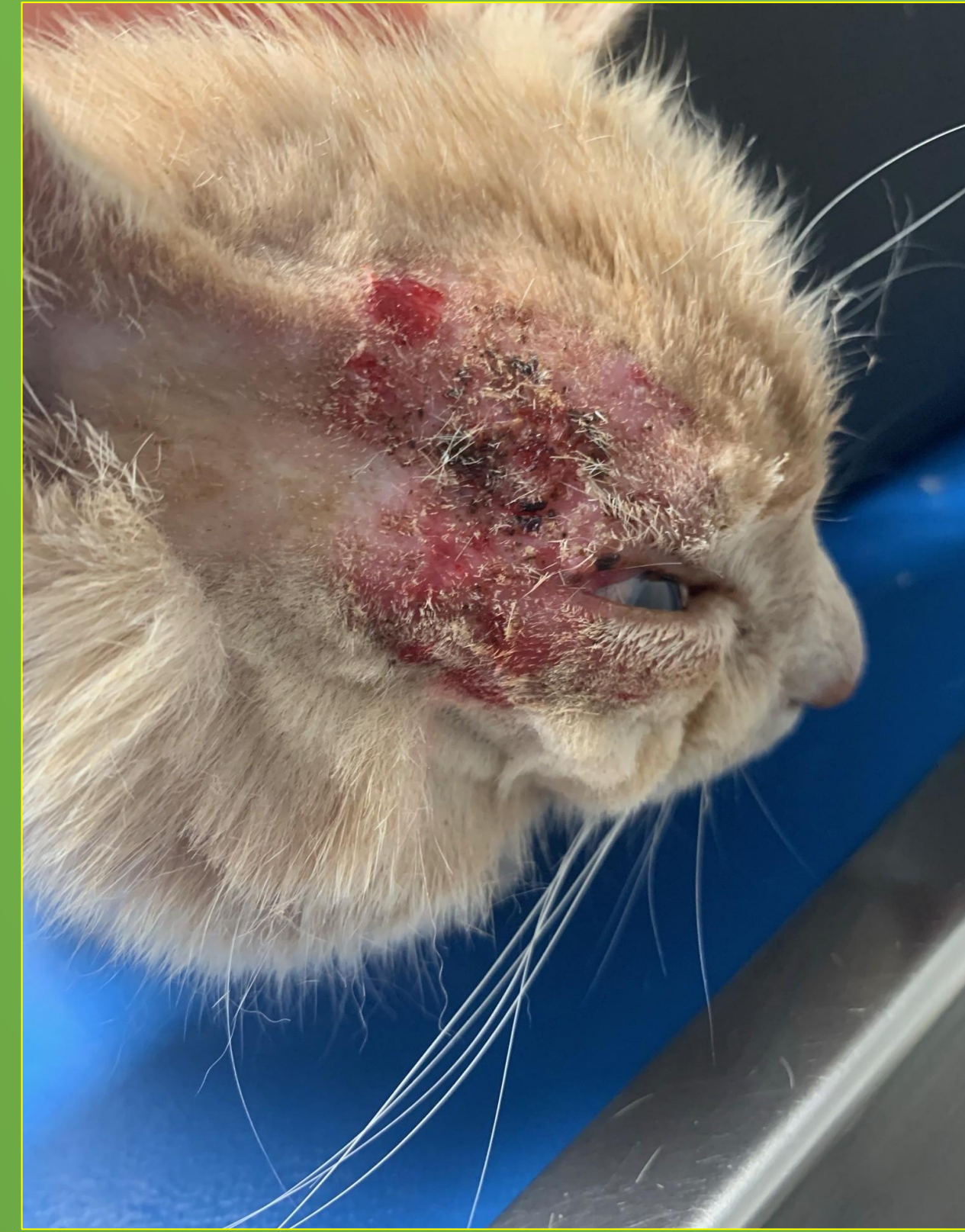

Figure 1 : Aspect at first presentation

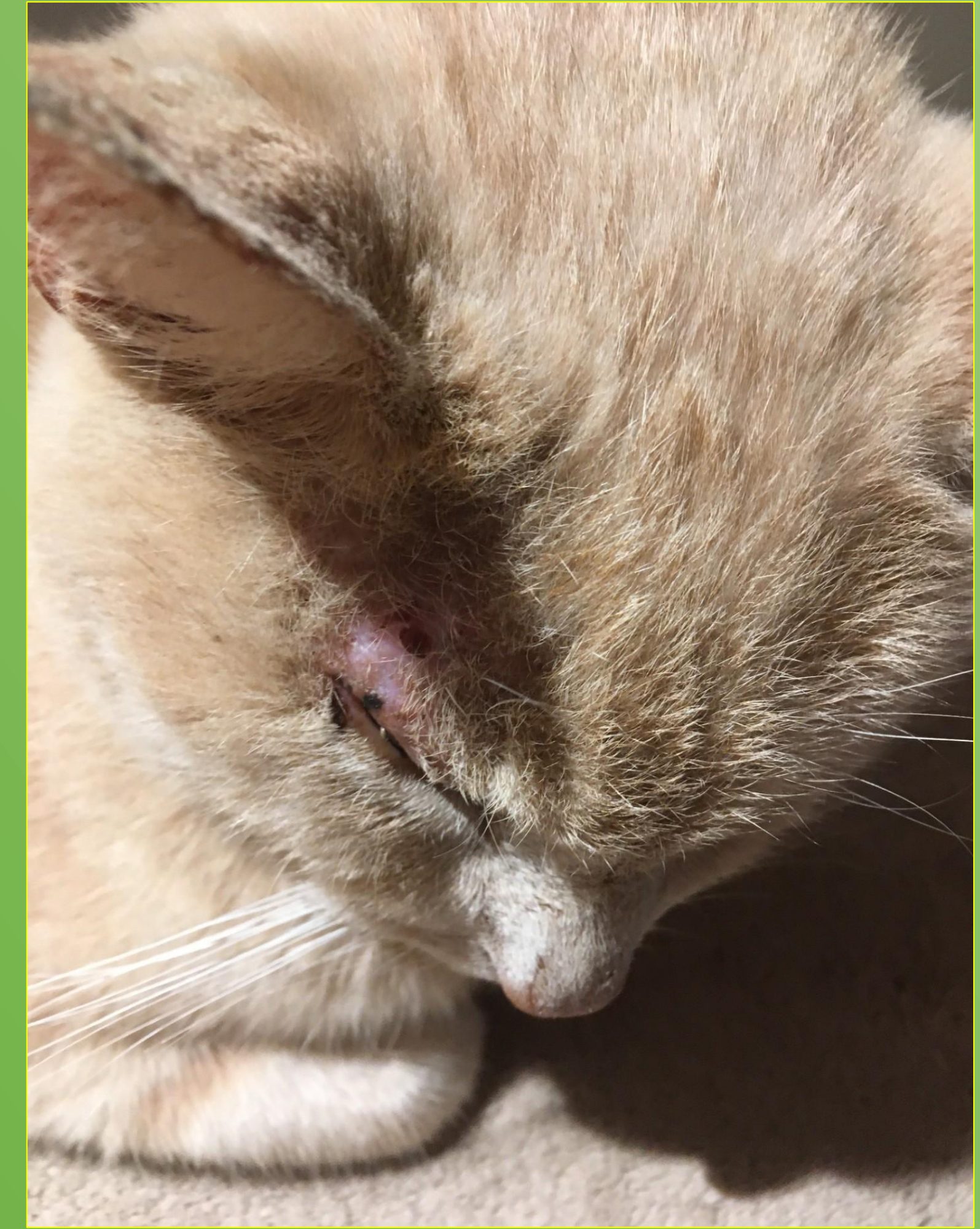

Figure 3 : Aspect after three sessions of daylight PDT

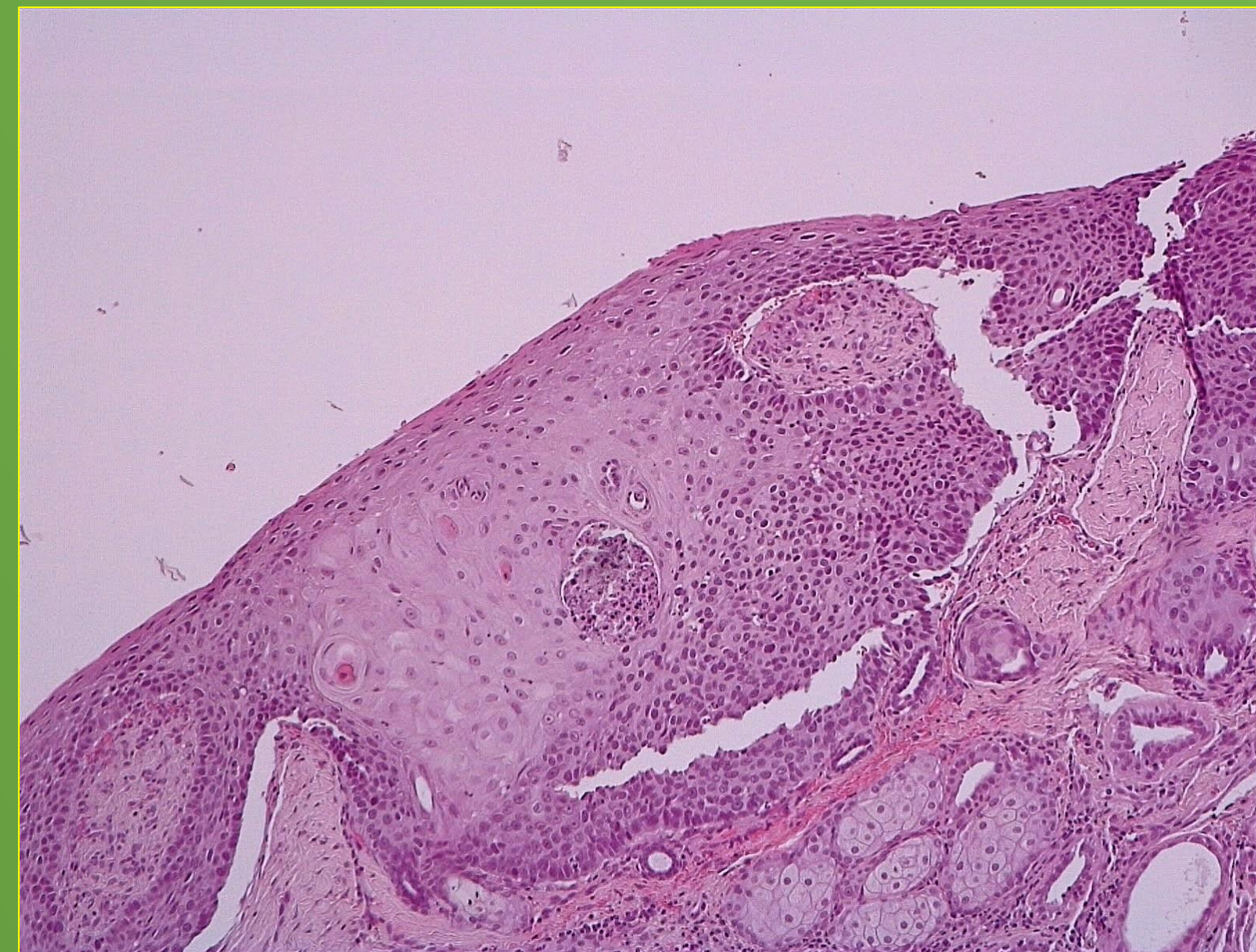

Figure 2 : Anatomopathological aspect of the first biopsy (credits : Frederique DEGORCE LAPVSO-CERBAVET Toulouse)

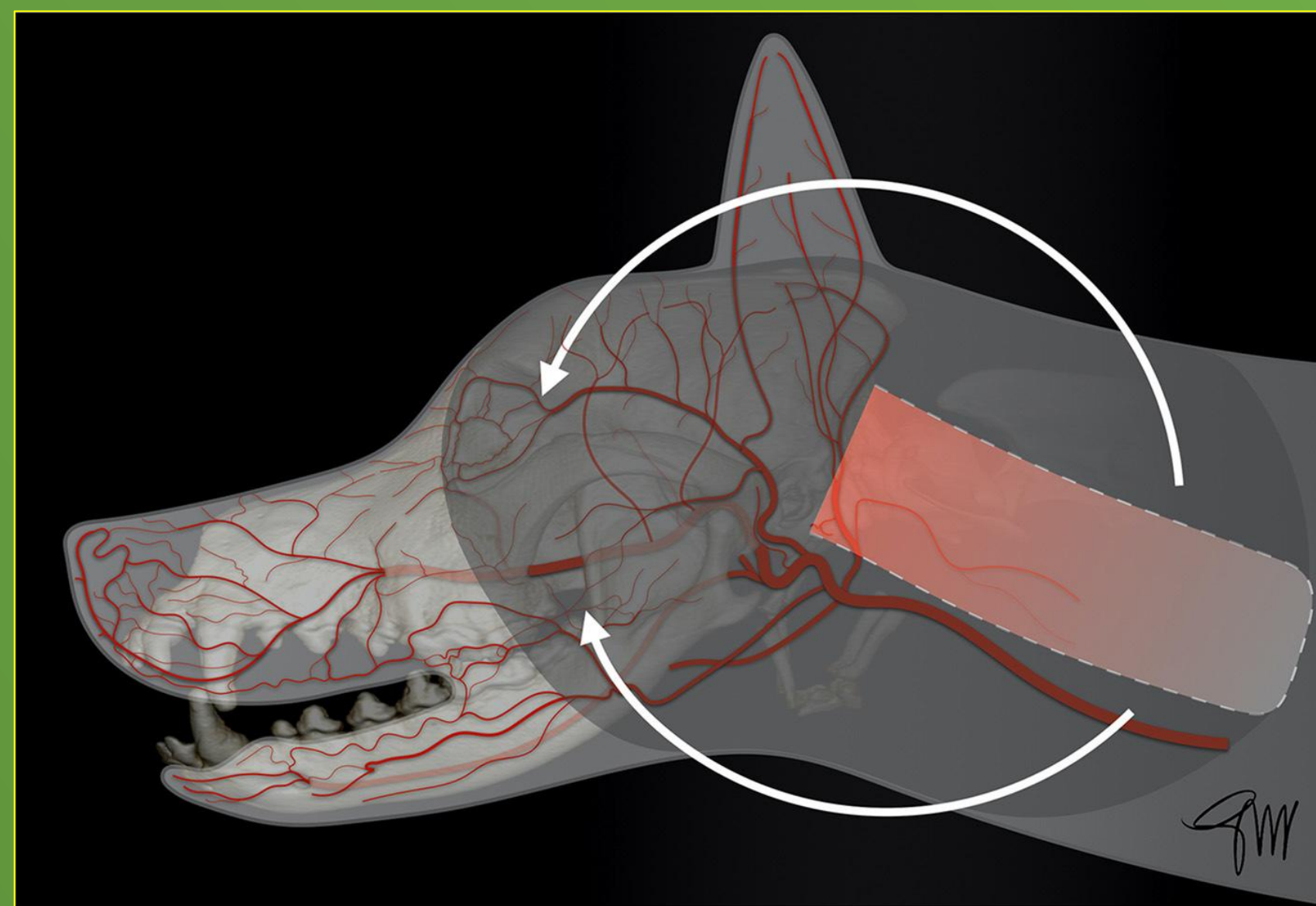


Figure 4 : Caudal auricular flap : anatomical landmarks (extracted from Guzu, Rossetti and Hennet<sup>6</sup>)

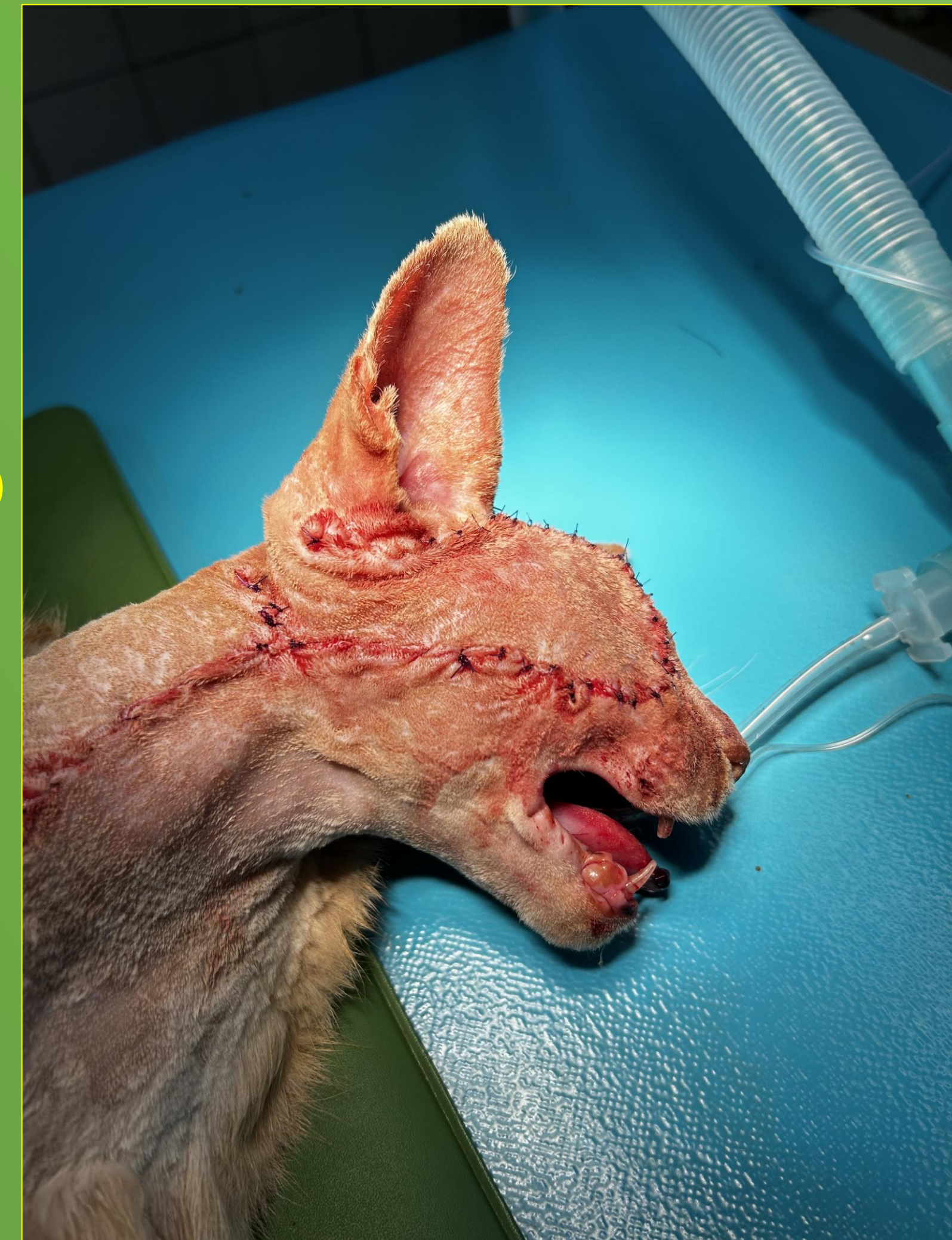

Figure 5 : Immediate post operative aspect

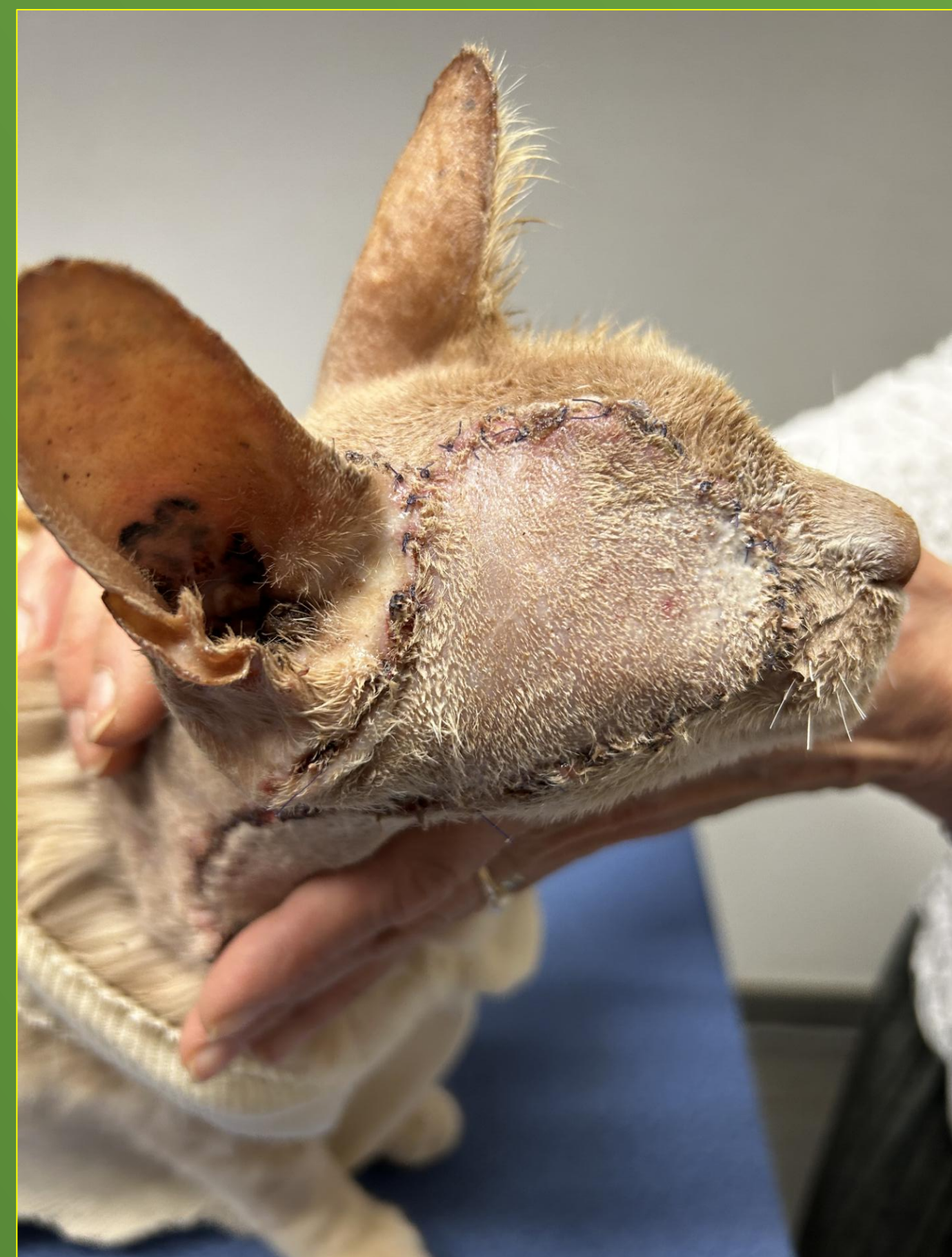

Figure 6 : 15 days post operative aspect



Figure 7 : 11 months post operative aspect