



HAL
open science

Characteristics and management of dental implants displaced into the maxillary sinus: a systematic review

Mathilde Seigneur, Emilie Hascoet, Anne-Gaelle Chaux, Philippe Lesclous,
Alain Hoornaert, Alexandra Cloitre

► To cite this version:

Mathilde Seigneur, Emilie Hascoet, Anne-Gaelle Chaux, Philippe Lesclous, Alain Hoornaert, et al.. Characteristics and management of dental implants displaced into the maxillary sinus: a systematic review. *International Journal of Oral and Maxillofacial Surgery*, 2023, 52 (2), pp.245-254. 10.1016/j.ijom.2022.06.009 . hal-04600658

HAL Id: hal-04600658

<https://hal.science/hal-04600658v1>

Submitted on 4 Jun 2024

HAL is a multi-disciplinary open access archive for the deposit and dissemination of scientific research documents, whether they are published or not. The documents may come from teaching and research institutions in France or abroad, or from public or private research centers.

L'archive ouverte pluridisciplinaire **HAL**, est destinée au dépôt et à la diffusion de documents scientifiques de niveau recherche, publiés ou non, émanant des établissements d'enseignement et de recherche français ou étrangers, des laboratoires publics ou privés.



Distributed under a Creative Commons Attribution 4.0 International License

[ARTICLE TYPE – SYSTEMATIC REVIEW, DENTAL IMPLANTS]

Characteristics and management of dental implants displaced into the maxillary sinus: a systematic review

**Mathilde Seigneur¹, Emilie Hascoët^{1,2}, Anne-Gaëlle Chaux^{1,2}, Philippe
Lesclous^{1,2}, Alain Hoornaert¹, Alexandra Cloitre^{1,2}**

*¹Odontologie Restauratrice et Chirurgicale, UFR Odontologie, Nantes Université,
CHU Nantes, Nantes, France*

*²Regenerative Medicine and Skeleton, RMeS, Nantes Université, Oniris, Université
Angers, CHU Nantes, INSERM, Nantes, France*

Abstract

The displacement of dental implants into the maxillary sinus is increasingly reported and may lead to serious complications. Better knowledge of this condition could help clinicians improve their practice, but it is difficult to draw conclusions from the current literature. Therefore, a systematic review was performed to describe the main characteristics of dental implant displacement, as well as its management and temporal evolution over a 31-year period. This review was conducted according to the PRISMA methodology. The PubMed/Scopus electronic databases were searched to December 2021. Risk of bias was assessed using the Joanna Briggs Institute tools. A

total of 73 articles reporting 321 patients with displaced dental implants were included. Implants located in the upper first molar site were the most frequently involved (23.7%). Displacement occurred mainly during the first 6 months after implant placement (62.6%). The majority became symptomatic (56.2%), most often due to maxillary sinusitis (41.8% [Au?1]). The surgical approaches to remove displaced implants were the lateral approach (38.1%), the Caldwell–Luc approach (27.2%), and endoscopic nasal surgery (23.1%). This review highlights the importance of preventive measures: avoiding implant displacement by careful pre-implantation radiographic analysis, but also preventing infectious complications through early removal of the displaced implant (PROSPERO CRD42021279473).

Keywords: dental implants, maxillary sinus, foreign bodies, human, systematic review

Introduction

The displacement of dental implants into the maxillary sinus is one of the rare but increasingly reported complications in oral implantology^{1,2}. Dental implants are the most frequently described intrasinus foreign bodies in the literature^{3,4}. Such displacement exposes the patient to complications of varying severity, including the development of oroantral fistula and maxillary sinusitis, which may lead to pansinusitis, orbital cellulitis, and intracranial infection in rare cases⁵⁻⁷. Moreover, in some cases the implants may secondarily migrate into the nasal cavity, ethmoidal or sphenoidal sinuses, and even into the cranial fossa^{6,8-10}.

Several therapeutic management approaches are proposed for dental implant displacement, ranging from observation without treatment to surgical removal using different techniques^{11,12}. These techniques have evolved significantly over the past 30 years. While the Caldwell–Luc procedure and the lateral approach are the most widely documented in the literature^{13,14}, endoscopic nasal surgery emerged in the early 2000s¹⁵.

Better knowledge of dental implant displacements into the maxillary sinus could help clinicians improve their practice. However, reports in the literature have mainly included individual cases or small series from which it is difficult to draw conclusions. Only one study labelled as a ‘systematic review’ has been performed, describing 49 displaced implants; however, the authors did not follow current qualitative standards for this type of article¹¹.

Therefore, a systematic review of the literature was conducted, according to the PRISMA methodology, with the following objectives: (1) to describe the main characteristics of dental implant displacement into the maxillary sinus, (2) to investigate the management of this complication, and (3) to determine its temporal evolution over a 31-year period.

Materials and methods

Registration and protocol

This systematic review was registered in the International Prospective Register of Systematic Reviews (PROSPERO; CRD42021279473). It was conducted and

reported according to the PRISMA (Preferred Reporting Items for Systematic Reviews and Meta-analyses) 2020 checklist^{16,17}.

Information sources and search strategy

A literature search was conducted in the MEDLINE PubMed and Scopus online databases, covering articles published from the first report of implant displacement in the maxillary sinus (1990) to December 2021. For the MEDLINE PubMed database, publications were retrieved using the search phrase ((dental implant[MeSH Terms]) OR (dental implants[MeSH Terms])) AND (((((((((((displacement[Text Word]) OR (displacements[Text Word])) OR (displaced[Text Word])) OR (migration[Text Word])) OR (migrations[Text Word])) OR (migrated[Text Word])) OR (removal[Text Word])) OR (retrieval[Text Word])) OR (body, foreign[MeSH Terms])) OR (bodies, foreign[MeSH Terms])) AND (maxillary sinus[MeSH Terms]). For Scopus, the search phrase was KEY (“migration”) AND KEY (“maxillary sinus”) AND KEY (“dental implant”) AND ALL (“research articles”) OR (“case reports”). A manual search of the bibliographic references found in the selected articles was also conducted to complete the main search.

Selection process and eligibility criteria

After the removal of duplicates, two investigators (M.S., A.C.) independently screened the titles and the abstracts of the articles. Articles were selected on the basis of the inclusion and exclusion criteria defined in Table 1. The full-text articles were then assessed by the same investigators to determine publication eligibility. The

selection process is presented in detail in the PRISMA flow diagram in Fig. 1. Any disagreement between the two investigators regarding article inclusion was resolved by a third author.

[Table 1 here]

[Figure 1 here]

Data collection process and data items

Data were collected independently by two authors (M.S., A.C.) and entered into an electronic database (Microsoft Excel 2018; Microsoft Corporation, Redmond, WA, USA). The following data were extracted from each selected article: date of publication, article type, population characteristics (number, sex, age), performance of pre-implant surgery, characteristics of displaced implants (number, initial implant site, timing of displacement), diagnosis (signs and symptoms reported, radiological location in the maxillary sinus), and management (**Supplementary Material Table S1**).

Assessment of the risk of bias and level of evidence

The risk of bias was independently evaluated by two authors (M.S., A.C.) using different methods depending on the study design: the Joanna Briggs Institute (JBI) Critical Appraisal Checklist for Case Reports¹⁸ and the JBI Checklist for Case Series¹⁹. Disagreements between the two investigators regarding the risk of bias in a publication were resolved by a third author. The articles selected were then classified

into three categories: high risk of bias when there was a ‘yes’ score of up to 49%, moderate risk for a score of 50–69%, and low risk for a score of $\geq 70\%$. The level of evidence was graded according to the Oxford Centre for Evidence-Based Medicine.

Synthesis of results and statistical analysis

A meta-analysis was not performed because of the heterogeneity of the publications. Therefore, a descriptive analysis was conducted using Microsoft Excel 365 (Microsoft Corporation). For each data variable, the number and percentage, or mean \pm standard deviation (SD) was calculated. To determine the temporal evolution of the number of cases and their management, data were analysed for three distinct decades: 1990–2000, 2001–2010, and 2011–2021.

Results

Publication selection

The results of the search and selection process are summarized in the flow diagram in Fig. 1. A total of 450 publications were identified through the database search (146 in PubMed and 304 in Scopus). After eliminating two duplicates, the titles and abstracts of the remaining articles were read and 72 of them were selected according to the predefined eligibility criteria (Table 1). After full-text reading, six articles were excluded. A manual search of the reference lists of the selected articles retrieved seven additional records. Ultimately, 73 articles were included in this systematic review^{1,2,4,5,7,8,12–15,20–82}.

Risk of bias and level of evidence

Findings from of the risk of bias assessment of the 59 case reports and the 14 cases series are summarized in Fig. 2. The risk of bias analysis and level of evidence for each article are detailed in **Supplementary Material** Figs. S1 and S2. Half of the case reports had a moderate risk of bias (49.2%), whereas the majority of case series had a low risk of bias (78.6%). The level of evidence was 5 for case reports and 4 for case series.

[Figure 2 here]

Characteristics of dental implants displaced into the maxillary sinus

The characteristics of the 73 included publications reporting 321 patients with implant displacement are listed in **Supplementary Material** Table S1. Of these publications, 72 provided information on the number of implants displaced: 299 implants were displaced in 285 patients.

Age and sex were reported in 303 (94.4%) cases. There were 169 male patients (55.0%) and 138 female patients (45.0%) with implant migration, giving a sex ratio for these reported cases of 1.2:1. The mean age was 51.9 ± 11.1 years (range 19–88 years); mean age was 49.7 years for female patients compared to 54.2 years for male patients.

The occurrence of a pre-implant surgery was only specified in 86 patients, whereas it was noted that such a technique was not performed in 96 patients. The use or not of pre-implant surgery was not mentioned for the remaining 139 patients.

Of a total of 299 displaced implants, 103 (34.4%) replaced upper molars, 31 (10.4%) upper premolars, and for 165 (55.2%) the site was not specified (Table 2). The implant site most frequently involved was the upper first molar (71 cases, 23.7%).

[Table 2 here]

Implant displacement was more than six-fold more common postoperatively than intraoperatively (171 cases vs 25 cases among the 196 cases reporting this timeline; **Supplementary Material** Table S1). The majority of cases of postoperative implant displacement occurred within the first 6 months after placement, particularly during functional loading: 87 cases (62.6%) out of the 139 with a specific date of postoperative displacement.

Most often, the displacement was symptomatic: 164 (56.2%) of the 292 cases specifying associated signs and symptoms. The majority of symptoms were maxillary sinusitis and/or oral–sinus communication, 129 cases (44.2%). Pain was reported in 45 cases (15.4%).

Of the 117 cases reporting the radiological location of the displaced implant, the upper sinus site was the most common: 30 cases (25.6%), including 26 cases (22.2%) at the nasal ostium/floor of the orbit. Other frequently mentioned intrasinus locations were posterior, anterior, low (sinus floor), medial, and central, in 22.2%,

16.2%, 15.4%, 10.3%, and 8.5% of cases, respectively. Rarely, the implant was close to the lateral wall of the maxillary sinus (1.7%).

Management of dental implants displaced into the maxillary sinus

The displaced implant was surgically removed in the vast majority of cases (299 cases, 93.4%). The main surgical approaches used were the lateral approach (122 cases, 38.1%), Caldwell–Luc (87 cases, 27.2%), and endoscopic nasal surgery (74 cases, 23.1%). Rarely, an alveolar approach (10 cases, 3.1%) or a combination of transoral and transnasal approaches (six cases, 1.9%) was performed. Observation without treatment was preferred in 12 cases (3.8%), while one case (0.3%) was lost to follow-up [Au?2]. Spontaneous expulsion of the dental implant into the nasal cavity was reported in eight cases (2.5%), including two cases of ingestion.

Temporal evolution of dental implants displaced into the maxillary sinus over a 31-year period

A steady increase in the number of reported cases of dental implants displaced into the maxillary sinus was observed during the first three decades from 1990 to 2021, including a 3.3-fold increase in the last decade, 2011–2021 (Fig. 3).

[Figure 3 here]

In the first decade, the most common approach to surgically remove an implant displaced into the maxillary sinus was the Caldwell–Luc technique, 1990–

2000 (91.7%), after which it was the lateral approach both in the second decade, 2001–2010 (66.1%), and third decade, 2011–2021 (36.8%) (Fig. 4). The emergence of endoscopic nasal surgery in the early 2000s is worth noting, which accounted for 27.3% of the surgical approaches reported in the past decade.

[Figure 4 here]

Discussion

This PRISMA systematic review, based on 321 reported patient cases, provides a summary of the characteristics and management of dental implants displaced into the maxillary sinus over a 31-year period. It gives an overview of the current evidence regarding the risk factors, diagnosis, complications, and management of displaced dental implants. Such information could help clinicians to improve their practice as well as to prevent and manage these displacements, which can lead to serious complications.

Although rare, the true incidence of implant displacements into the maxillary sinus is unknown and remains questionable. The substantial and steady increase in the number of dental implant displacements reported over the 31-year period in this review may be multifactorial. The main reason for this could be the increase in the number of dental implant placements over time. In the United States, data from the National Health and National Examination Survey showed that the prevalence of dental implants among adults with missing teeth increased by 14% per year between 1999 and 2016⁸³. In addition, this could also be explained by the increase in implant placement performed by surgeons lacking in experience⁷⁴. Another explanatory factor

could be the increase in the number of scientific publications that facilitate the reporting of case reports or case series. In 1990, 410,894 articles were published in the PubMed database, while in 2021, 1,768,951 were indexed, representing a 4.3-fold increase.

A combination of different risk factors may favour implant displacement into the maxillary sinus^{57,60}. No demographic risk factors (age, sex) could be identified in this review. Implants located in the upper first molar site were the most frequently involved, which is consistent with the large case series of Sgaramella et al.². This may be explained mainly by the anatomical proximity of this site to the maxillary sinus, as similar results have been reported for intrasinus tooth displacements⁸⁴. Other unfavourable anatomical characteristics of the implant site have been described: significant bone deficit or pneumatization of the maxillary sinus, and type IV least-dense bone^{44,60,71}. When displacement occurs during implant surgery, a lack of preoperative radiographic analysis and poorly controlled surgery may also be suspected (i.e., excessive drilling of the recipient site, perforation of the sinus membrane)^{2,11,28}. In this review, it was found that displacement was more than six-fold more frequent after implant surgery than intraoperatively. In this case, the main risk factors are a lack of primary stability, failure of osseointegration during the 6 months after implant placement^{24,38}, peri-implantitis^{2,13}, or negative intrasinus pressure^{27,44,45}. The role of inadequate occlusal forces is still debated^{23,47}. It was suggested by some authors that functional loading of the implant was a particularly critical stage for implant displacement^{54,62}. Indeed, implant displacement may occur in two ways: by revealing a lack of osseointegration⁵⁷ or via a deleterious procedure during blind uncovering of a buried posterior implant. A summary of the risk factors

for dental implant displacement into the maxillary sinus reported in the literature is presented in Table 3.

[Table 3 here]

The probability of dental implant displacement into the maxillary sinus may be reduced with preventive measures^{71,85}. First, prior to the implant surgery, a thorough analysis of the clinical and radiographic examinations, including three-dimensional imaging, can determine the anatomy of the implantation site (morphology and bone quality) and the relationship to the adjacent maxillary sinus^{29,86}. Pre-implant surgery may be indicated in cases of severe bone resorption^{1,43,75}, although it does not totally exclude the possibility of implant displacement^{2,33,34}. Indeed, migration can be caused by a lack of graft consolidation^{21,44}. Secondly, implant surgery must be rigorous and performed by an experienced practitioner^{38,86}. If the primary stability of the implant is judged to be insufficient, the practitioner must remove it to prevent intraoperative or delayed implant displacement³. Computer-assisted surgery can optimize the procedure and limit potential complications^{2,35}.

To diagnose a dental implant displaced into the maxillary sinus, a Valsalva test can be performed to demonstrate a secondary oral–sinus communication^{26,45,85}. In all cases, radiographs (retroalveolar or preferably panoramic) may show the location of the displaced implant. Such implants should be removed immediately if they are close to the surgical site. This is a relatively rare event, since only 15.4% of such displaced implants were close to the sinus floor. Otherwise, three-dimensional imaging (wide-field cone beam computed tomography or computed tomography) is better for precise localization of the displaced implant and thus for the best choice of the least invasive

management approach^{4,75,85}. Indeed, a dental implant displaced into the maxillary sinus may have various locations (nasal ostium^{63,66}, paranasal sinuses^{6,9}, or more rarely the orbital floor⁸⁷ and cranial fossa¹⁰). The implant may migrate due to factors such as the movement of ciliary cells of the sinus mucosa^{49,55}, patient position, or intrasinus negative pressure^{45,85}. Radiological examination is urgent because the persistence of an intrasinus implant exposes the patient to the risk of serious infectious complications.

This review showed that the majority of cases of implant displacements into the maxillary sinus became symptomatic, most often because of acute or chronic maxillary sinusitis. These cases are mainly due to bacterial colonization of the sinus by the oral flora that occurs during displacement^{5,11,15}. The presence of a foreign body such as an oral implant can also sometimes provoke an inflammatory reaction, which would favour a sinus infection^{44,59,88}. Although relatively rare (23 cases described), migration towards the nasal ostium exposes the patient to more serious complications such as obstruction of the ostium^{63,88} or expulsion of the implant into the nasal cavity with a risk of ingestion or, even worse, of inhalation^{1,39,49,65}. All of these complications therefore justify early management of the displaced implant^{12,15}.

Surgical management was found to be the first-line treatment in the vast majority of cases (93.4%). The choice of surgical technique differs according to the patient's symptoms and the location of the displaced implant^{22,26,43}. Two oral approaches, Caldwell–Luc and lateral approach, are generally reported as the first-line procedure in cases of intraoperative implant displacement or when healing of the surgical site is incomplete. The Caldwell–Luc technique, which consists of removing the implant through the canine fossa^{13,53}, has remained the gold standard for this type of sinus surgery^{35,45}. The modified version of the Caldwell–Luc technique – the lateral

approach – enables removal of the implant by creating a bone window in the anterolateral part of the maxillary sinus^{14,64}. These techniques from the past decade are still the most widely used. However, the Caldwell–Luc method has disadvantages such as the risk of injury to the infraorbital or superior anterior alveolar nerve^{34,85}. To overcome these drawbacks, endoscopic nasal surgery was developed in the early 2000s^{15,31,40}. The endoscopic nasal surgery approach is increasingly considered to be the preferred technique for the removal of implants displaced into the maxillary sinus^{3,6,9}. This technique is considered reliable and safe with low morbidity^{30,37}. In rare cases, observation without treatment (3.8%) or late treatment was preferred. These options may be proposed in the absence of clinical symptoms or at the patient's request^{35,42}. In addition, they may be indicated when surgical removal of the intrasinus implant is risky due to the proximity to the orbital floor³⁸. Although some publications have described cases of long-term follow-up (>12 months) without irritation of the sinus mucosa^{27,39,42}, this situation remains exceptional, and the patient must be clearly informed of the long-term infectious risk.

A flow diagram of intraoperative and post-implant surgical management based on the results of this literature review is presented in Fig. 5.

[Figure 5 here]

This review has several unavoidable limitations. MEDLINE and Scopus were the only databases investigated, and although a complementary manual search was performed, relevant publications reported in the grey literature may have been missed. The results must be interpreted with caution because they stem from very heterogeneous publications, which did not allow a true meta-analysis. In addition,

these publications had a low level of evidence 4–5 and were mainly case reports, which may be explained by their focus on rare complications. Finally, the publications selected come from all over the world and patient management may differ between countries.

In conclusion, based on publications with a level of evidence of 4–5, this review showed that implant displacement into the maxillary sinus is increasingly reported in the literature. Most often, the displaced implants were located in the upper first molar site and became displaced after implant placement. Surgical removal of an implant from the maxillary sinus should be performed as early as possible to prevent complications such as maxillary sinusitis. Currently, the lateral approach is practiced more frequently than the classic Caldwell–Luc technique, which carries the risk of nerve injury and bleeding complications. Endoscopic nasal surgery appears to be very promising because of its low morbidity and good efficacy. However, further clinical studies with a higher level of evidence are needed to reinforce and validate the results of this systematic review.

Funding

None.

Competing interests

None.

Ethical approval

Not required.

Patient consent

Not required.

References

1. Damlar I. Disappearance of a dental implant after migration into the maxillary sinus: an unusual case. *J Korean Assoc Oral Maxillofac Surg* 2015; 41: 278–280. doi: 10.5125/jkaoms.2015.41.5.278
2. Sgaramella N, Tartaro G, D'Amato S, Santagata M, Colella G. Displacement of dental implants into the maxillary sinus: a retrospective study of twenty-one patients. *Clin Implant Dent Relat Res* 2016; 18: 62–72. doi: 10.1111/cid.12244
3. González-García A, González-García J, Diniz-Freitas M, García-García A, Bullón P. Accidental displacement and migration of endosseous implants into adjacent craniofacial structures: a review and update. *Med Oral Patol Oral Cir Bucal* 2012; 17: e769–e774. doi: 10.4317/medoral.18032
4. Brescia G, Fusetti S, Apolloni F, Marioni G, Saia G. Displaced dental materials in the maxillary sinus: an original series. Analysis and definition of a surgical decision-making process. *Ann Otol Rhinol Laryngol* 2019; 128: 177–183. doi: 10.1177/0003489418812898
5. Quiney RE, Brimble E, Hodge M. Maxillary sinusitis from dental osseointegrated implants. *J Laryngol Otol* 1990; 104: 333–334. doi: 10.1017/s0022215100112630
6. Felisati G, Lozza P, Chiapasco M, Borloni R. Endoscopic removal of an unusual foreign body in the sphenoid sinus: an oral implant. *Clin Oral Implants Res* 2007; 18: 776–780. doi: 10.1111/j.1600-0501.2007.01409.x

7. Kim SM. The removal of an implant beneath the optic canal by modified endoscopic-assisted sinus surgery. *Eur Arch Otorhinolaryngol* 2017; 274: 1167–1171. doi: 10.1007/s00405-016-4416-4
8. Park JH, Kim HY, Kim SJ. From the maxillary sinus to the stomach: a rare case report of a displaced fragment of dental implant. *Eur J Oral Implantol* 2018; 11: 469–473.
9. Haben CM, Balys R, Frenkiel S. Dental implant migration into the ethmoid sinus. *J Otolaryngol* 2003; 32: 342–344. doi: 10.2310/7070.2003.11442
10. Cascone P, Ungari C, Filiaci F, Gabriele G, Ramieri V. A dental implant in the anterior cranial fossae. *Int J Oral Maxillofac Surg* 2010; 39: 92–93. doi: 10.1016/j.ijom.2009.07.017
11. Jeong KI, Kim SG, Oh JS, You JS. Implants displaced into the maxillary sinus: a systematic review. *Implant Dent* 2016; 25: 547–551. doi: 10.1097/ID.0000000000000408
12. Chiapasco M, Felisati G, Maccari A, Borloni R, Gatti F, Di Leo F. The management of complications following displacement of oral implants in the paranasal sinuses: a multicenter clinical report and proposed treatment protocols. *Int J Oral Maxillofac Surg* 2009; 38: 1273–1278. doi: 10.1016/j.ijom.2009.09.001
13. Laureti M, Ferrigno N, Rosella D, Papi P, Mencio F, De Angelis F, Pompa G, Di Carlo S. Unusual case of osseointegrated dental implant migration into maxillary sinus removed 12 years after insertion. *Case Rep Dent* 2017; 2017: 9634672. doi: 10.1155/2017/9634672
14. Bruniera JF, Silva-Sousa YT, Faria PE. Atypical case of three dental implants displaced into the maxillary sinus. *Case Rep Dent* 2015; 2015: 896423. doi: 10.1155/2015/896423

15. Matti E, Emanuelli E, Pusateri A, Muniz CC, Pagella F. Transnasal endoscopic removal of dental implants from the maxillary sinus. *Int J Oral Maxillofac Implants* 2013; 28: 905–910. doi: 10.11607/jomi.2894
16. Page MJ, McKenzie JE, Bossuyt PM, Boutron I, Hoffmann TC, Mulrow CD, Shamseer L, Tetzlaff JM, Akl EA, Brennan SE, Chou R, Glanville J, Grimshaw JM, Hróbjartsson A, Lalu MM, Li T, Loder EW, Mayo-Wilson E, McDonald S, McGuinness LA, Stewart LA, Thomas J, Tricco AC, Welch VA, Whiting P, Moher D. The PRISMA 2020 statement: an updated guideline for reporting systematic reviews. *Int J Surg* 2021; 88: 105906. doi: 10.1016/j.ijisu.2021.105906
17. Muka T, Glisic M, Milic J, Verhoog S, Bohlius J, Bramer W, Chowdhury R, Franco OH. A 24-step guide on how to design, conduct, and successfully publish a systematic review and meta-analysis in medical research. *Eur J Epidemiol* 2020; 35: 49–60. doi: 10.1007/s10654-019-00576-5
18. Ma LL, Wang YY, Yang ZH, Huang D, Weng H, Zeng XT. Methodological quality (risk of bias) assessment tools for primary and secondary medical studies: what are they and which is better? *Mil Med Res* 2020; 7: 1–11. doi: 10.1186/s40779-020-00238-8
19. Munn Z, Barker TH, Moola S, Tufanaru C, Stern C, McArthur A, Stephenson M, Aromataris E. Methodological quality of case series studies: an introduction to the JBI critical appraisal tool. *JBI Evid Synth* 2020; 18: 2127–2133. doi: 10.11124/JBISRIR-D-19-00099
20. Ueda M, Kaneda T. Maxillary sinusitis caused by dental implants: report of two cases. *J Oral Maxillofac Surg* 1992; 50: 285–287. doi: 10.1016/0278-2391(92)90328-w

21. Regev E, Smith RA, Perrott DH, Pogrel MA. Maxillary sinus complications related to endosseous implants. *Int J Oral Maxillofac Implants* 1995; 10: 451–461.
22. Pagella F, Emanuelli E, Castelnovo P. Endoscopic extraction of a metal foreign body from the maxillary sinus. *Laryngoscope* 1999; 109: 339–342. doi: 10.1097/00005537-199902000-00030
23. Iida S, Tanaka N, Kogo M, Matsuya T. Migration of a dental implant into the maxillary sinus. A case report. *Int J Oral Maxillofac Surg* 2000; 29: 358–359.
24. Raghoobar GM, Vissink A. Treatment for an endosseous implant migrated into the maxillary sinus not causing maxillary sinusitis: case report. *Int J Oral Maxillofac Implants* 2003; 18: 745–749.
25. Nakamura N, Mitsuyasu T, Ohishi M. Endoscopic removal of a dental implant displaced into the maxillary sinus: technical note. *Int J Oral Maxillofac Surg* 2004; 33: 195–197. doi: 10.1054/ijom.2003.0470
26. El Charkawi HG, El Askary AS, Ragab A. Endoscopic removal of an implant from the maxillary sinus: a case report. *Implant Dent* 2005; 14: 30–35. doi: 10.1097/01.id.0000156385.50768.cf
27. Galindo P, Sánchez-Fernández E, Avila G, Cutando A, Fernandez JE. Migration of implants into the maxillary sinus: two clinical cases. *Int J Oral Maxillofac Implants* 2005; 20: 291–295.
28. Varol A, Türker N, Göker K, Basa S. Endoscopic retrieval of dental implants from the maxillary sinus. *Int J Oral Maxillofac Implants* 2006; 21: 801–804.
29. Guler N, Delilbasi C. Ectopic dental implants in the maxillary sinus. *Quintessence Int* 2007; 38: e238–e239.

30. Kim JW, Lee CH, Kwon TK, Kim DK. Endoscopic removal of a dental implant through a middle meatal antrostomy. *Br J Oral Maxillofac Surg* 2007; 45: 408–409. doi: 10.1016/j.bjoms.2005.12.003
31. Lubbe DE, Aniruth S, Peck T, Liebenberg S. Endoscopic transnasal removal of migrated dental implants. *Br Dent J* 2008; 204: 435–436. doi: 10.1038/sj.bdj.2008.293
32. Ucer TC. A modified transantral endoscopic technique for the removal of a displaced dental implant from the maxillary sinus followed by simultaneous sinus grafting. *Int J Oral Maxillofac Implants* 2009; 24: 947–951.
33. Chappuis V, Suter VG, Bornstein MM. Displacement of a dental implant into the maxillary sinus: report of an unusual complication when performing staged sinus floor elevation procedures. *Int J Periodontics Restorative Dent* 2009; 29: 81–87.
34. Flanagan D. A method to retrieve a displaced dental implant from the maxillary sinus. *J Oral Implantol* 2009; 35: 70–74. doi: 10.1563/1548-1336-35.2.70
35. Ridaura-Ruiz L, Figueiredo R, Guinot-Moya R, Piñera-Penalva M, Sanchez-Garcés MA, Valmaseda-Castellón E, Gay-Escoda C. Accidental displacement of dental implants into the maxillary sinus: a report of nine cases. *Clin Implant Dent Relat Res* 2009; 11: e38–e45. doi: 10.1111/j.1708-8208.2009.00175.x
36. Chrcanovic BR, Custódio AL. Surgical removal of dental implants displaced into the maxillary sinus. *Serb Dent J* 2009; 56: 139–147. doi: 10.2298/SGS0903139C
37. Kitamura A, Zeredo JL. Migrated maxillary implant removed via semilunar hiatus by transnasal endoscope. *Implant Dent* 2010; 19: 16–20. doi: 10.1097/ID.0b013e3181c419a8

38. Kluppel LE, Santos SE, Olate S, Freire Filho FW, Moreira RW, de Moraes M. Implant migration into maxillary sinus: description of two asymptomatic cases. *Oral Maxillofac Surg* 2010; 14: 63–66. doi: 10.1007/s10006-009-0184-2
39. Borgonovo A, Fabbri A, Boninsegna R, Dolci M, Censi R. Displacement of a dental implant into the maxillary sinus: case series. *Minerva Stomatol* 2010; 59: 45–54.
40. Ramotar H, Jaberoo MC, Koo Ng NK, Pulido MA, Saleh HA. Image-guided, endoscopic removal of migrated titanium dental implants from maxillary sinus: two cases. *J Laryngol Otol* 2010; 124: 433–436. doi: 10.1017/S0022215109990958
41. Sammartino G, Trosino O, di Lauro AE, Amato M, Cioffi A. Use of Piezosurgery device in management of surgical dental implant complication: a case report. *Implant Dent* 2011; 20: e1–e6. doi: 10.1097/ID.0b013e31820fb2da
42. Scarano A, Perrotti V, Carinci F, Shibli JA. Removal of a migrated dental implant from the maxillary sinus after 7 years: a case report. *Oral Maxillofac Surg* 2011; 15: 239–243. doi: 10.1007/s10006-010-0243-8
43. Sohn DS, Jung HS, Kim KH, Song KJ, An HW, Min KH. Removal of displaced foreign body from the maxillary sinus using replaceable bony windows and saline irrigation, followed by suctioning of the foreign body. *Implant Dent* 2011; 20: 112–117. doi: 10.1097/ID.0b013e31820faf53
44. Galindo-Moreno P, Padial-Molina M, Sanchez-Fernandez E, Hernandez-Cortes P, Wang HL, O'Valle F. Dental implant migration in grafted maxillary sinus. *Implant Dent* 2011; 20: 400–405. doi: 10.1097/ID.0b013e31822b9d2d
45. Galindo-Moreno P, Padial-Molina M, Avila G, Rios HF, Hernández-Cortés P, Wang HL. Complications associated with implant migration into the maxillary sinus

cavity. *Clin Oral Implants Res* 2012; 23: 1152–1160. doi: 10.1111/j.1600-0501.2011.02278.x

46. Tilaveridis I, Lazaridou M, Dimitrakopoulos I, Lazaridis N, Charis C. Displacement of three dental implants into the maxillary sinus in two patients. Report of two cases. *Oral Maxillofac Surg* 2012; 16: 311–314. doi: 10.1007/s10006-011-0295-4

47. Tsodoulos S, Karabouta I, Voulgaropoulou M, Georgiou C. Atraumatic removal of an asymptomatic migrated dental implant into the maxillary sinus: a case report. *J Oral Implantol* 2012; 38: 189–193. doi: 10.1563/AAID-JOI-D-10-00053

48. Fusari P, Doto M, Chiapasco M. Removal of a dental implant displaced into the maxillary sinus by means of the bone lid technique. *Case Rep Dent* 2013; 2013: 260707. doi: 10.1155/2013/260707

49. van de Loo S, Kessler P, Lethaus B. Spontaneous transmaxillary-transnasal implant loss: a case report. *Implant Dent* 2013; 22: 117–119. doi: 10.1097/ID.0b013e3182840287

50. Tavares RN, Nogueira AS, da Silva Sampieri MB, Bezerra MF, Gonçalves ES. Late displacement of a dental implant into maxillary sinus. *Braz J Otorhinolaryngol* 2014; 80: 359–361. doi: 10.1016/j.bjorl.2012.11.001

51. Satwalekar P, Reddy BA, Chander KS, Reddy GR, Agarwal T, Chowdary SG. Endoscopic retrieval of dental implant from maxillary sinus. *J Contemp Dent Pract* 2013; 14: 759–761. doi: 10.5005/jp-journals-10024-1398

52. Biglioli F, Chiapasco M. An easy access to retrieve dental implants displaced into the maxillary sinus: the bony window technique. *Clin Oral Implants Res* 2014; 25: 1344–1351. doi: 10.1111/clr.12276

53. Üngör C, Atasoy KT, Çizmeci-Şenel F. Migration of dental implants into maxillary sinus during the healing period due to wrong indication: report of two cases. *J Dent Fac Atatürk Uni* 2014; 24: 93–97.
54. Scarano A, Piattelli A, Lezzi G, Varvara G. Spontaneous bone formation on the maxillary sinus floor in association with surgery to remove a migrated dental implant: a case report. *Minerva Stomatol* 2014; 63: 351–359.
55. Jeong KI, Kim SG, Oh JS, Jeong MA. Displaced implants into maxillary sinus: report of cases. *Implant Dent* 2014; 23: 245–249. doi: 10.1097/ID.0000000000000097
56. Sadda R. Crestal approach for removing a migrated dental implant from the maxillary sinus: a case report. *Gen Dent* 2015; 63: 78–79.
57. Yamashita Y, Iwai T, Hirota M, Omura S, Aoki N, Tohnai I. Removal of migrated dental implants from maxillary sinus 4 years 10 months after implant placement. *Oral Maxillofac Surg* 2015; 19: 315–319. doi: 10.1007/s10006-015-0484-7
58. Furuya Y, Norizuki Y, Yajima Y. A case of simultaneous ectopic tooth extraction and removal of migrated dental implant from maxillary sinus. *Bull Tokyo Dent Coll* 2015; 56: 253–258. doi: 10.2209/tdcpublishation.56.253
59. Eltas A, Dundar S, Eltas SD, Altun O, Yolcu U, Saybak A. Accidental displacement of dental implants into both maxillary sinuses during surgery. *J Oral Implantol* 2015; 41: 601–603. doi: 10.1563/AAID-JOI-D-13-00026
60. Ding X, Wang Q, Guo X, Yu Y. Displacement of a dental implant into the maxillary sinus after internal sinus floor elevation: report of a case and review of literature. *Int J Clin Exp Med* 2015; 8: 4826–4836.

61. Nogami S, Yamauchi K, Tanuma Y, Odashima K, Matsui A, Tanaka K, Takahashi T. Removal of dental implant displaced into maxillary sinus by combination of endoscopically assisted and bone repositioning techniques: a case report. *J Med Case Rep* 2016; 10: 1. doi: 10.1186/s13256-015-0787-1
62. Andreasi Bassi M, Andrisani C, Lico S, Ormanier Z, Arcuri C. Endoscopic retrieval of a dental implant into the maxillary sinus: a case report. *Oral Implantol (Rome)* 2016; 9: 69–75. doi: 10.11138/orl/2016.9.2.069
63. de Jong MA, Rushinek H, Eliashar R. Removal of dental implants displaced into the maxillary sinus: a case series. *Eur J Oral Implantol* 2016; 9: 427–433.
64. Sarmast ND, Wang HH, Ma R, Carrion JA, Iacono VJ. Retrieval of displaced implant attributable to an ill-fitting denture from the maxillary sinus six months after transcrestal sinus floor augmentation and implant placement. *Clin Adv Periodontics* 2016; 6: 175–181. doi: 10.1902/cap.2016.150086
65. Procacci P, De Santis D, Bertossi D, Albanese M, Plotegher C, Zanette G, Pardo A, Nocini PF. Extraordinary sneeze: spontaneous transmaxillary-transnasal discharge of a migrated dental implant. *World J Clin Cases* 2016; 4: 229–232. doi: 10.12998/wjcc.v4.i8.229
66. Lim D, Parumo R, Chai MB, Shanmuganathan J. Transnasal endoscopy removal of dislodged dental implant: a case report. *J Oral Implantol* 2017; 43: 228–231. doi: 10.1563/aaid-joi-D-16-00172
67. Harada T, Isomura ET, Uchihashi T, Kogo M. Aspergillosis associated with migration of a dental implant into the maxillary sinus: a case report. *J Oral Maxillofac Surg Med Pathol* 2017; 29: 448–451. doi: 10.1016/j.ajoms.2017.05.006

68. Dundar S, Karlidag T, Keles E. Endoscopic removal of a dental implant from maxillary sinus. *J Craniofac Surg* 2017; 28: 1003–1004. doi: 10.1097/SCS.0000000000003552
69. Brescia G, Saia G, Apolloni F, Marioni G. A novel nasal endoscopic approach for removing displaced dental implants from the maxillary sinus. *Am J Otolaryngol* 2017; 38: 92–95. doi: 10.1016/j.amjoto.2016.09.005
70. Soylu E, Kilic E, Alkan A. Migration of a dental implant to the maxillary sinus prior to second stage surgery: a case report. *J Odontol* 2018; 2: 1.
71. Manor Y, Anavi Y, Gershonovitch R, Lorean A, Mijiritsky E. Complications and management of implants migrated into the maxillary sinus. *Int J Periodontics Restorative Dent* 2018; 38: e112–e118. doi: 10.11607/prd.3328
72. Conforte JJ, Ponzoni D. Sinusitis due to the presence of a dental implant inside the maxillary sinus. *J Craniofac Surg* 2018; 29: e591. doi: 10.1097/SCS.0000000000004668
73. Yoon SH, Jung S, Kang T, Yang HC. Accidental swallowing of dental implant: complication of transnasal endoscopic removal from maxillary sinus. *J Oral Implantol* 2019; 45: 219–222. doi: 10.1563/aaid-joi-D-18-00231
74. Gnigou M, Goutzani L, Sarivalasis S, Petsinis V. Retrieval of displaced implants inside the maxillary sinus: two case reports and a short review. *Int J Implant Dent* 2019; 5: 24. doi: 10.1186/s40729-019-0173-7
75. Froum SJ, Elghannam M, Lee D, Cho SC. Removal of a dental implant displaced into the maxillary sinus after final restoration. *Compend Contin Educ Dent* 2019; 40: 530–535.
76. Jin T, Wang Y, Li S, Cai Q, Huang Z. Removal of the dental implant displaced into the maxillary sinus through the inferior nasal meatus via transnasal

endoscopy. *J Craniofac Surg* 2019; 30: 1178–1179. doi:

10.1097/SCS.00000000000005263

77. Safadi A, Ungar OJ, Oz I, Koren I, Abergel A, Kleinman S. Endoscopic sinus surgery for dental implant displacement into the maxillary sinus—a retrospective clinical study. *Int J Oral Maxillofac Surg* 2020; 49: 966–972. doi:

10.1016/j.ijom.2020.01.009

78. Chang PH, Chen YW, Huang CC, Fu CH, Huang CC, Lee TJ. Removal of displaced dental implants in the maxillary sinus using endoscopic approaches. *Ear Nose Throat J* 2020; 11: 145561320931304. doi: 10.1177/0145561320931304

79. Núñez-Márquez E, Salgado-Peralvo AO, Peña-Cardelles JF, Kewalramani N, Jiménez-Guerra A, Velasco-Ortega E. Removal of a migrated dental implant from a maxillary sinus through an intraoral approach: a case report. *J Clin Exp Dent* 2021;

13: e733–e736. doi: 10.4317/jced.58350

80. Xia X, Wei ZY, Wei HW. Displacement of the full body of a dental implant into the sinus space without membrane perforation and subsequent osseointegration: a case report. *J Int Med Res* 2021; 49: 3000605211060674. doi:

10.1177/03000605211060674

81. Katagiri W, Hashizume K, Saito N, Funayama A, Kobayashi T. Maxillary sinus aspergillosis associated with migration of a dental implant. A case report. *Advances in Oral and Maxillofacial Surgery* 2021; 4: 100157. doi:

10.1016/j.adoms.2021.100157

10.1016/j.adoms.2021.100157

82. Hamdoon Z, Mahmood N, Talaat W, Sattar AA, Naeim K, Qais A, Kheder W, Jerjes W. Evaluation of different surgical approaches to remove dental implants from the maxillary sinus. *Sci Rep* 2021; 24: 4440. doi: 10.1038/s41598-021-83721-z

83. Elani HW, Starr JR, Da Silva JD, Gallucci GO. Trends in dental implant use in the U.S., 1999–2016, and projections to 2026. *J Dent Res* 2018; 97: 1424–1430. doi: 10.1177/0022034518792567
84. Seigneur M, Cloitre A, Malard O, Lesclous P. Teeth roots displacement in the maxillary sinus: characteristics and management. *J Oral Med Oral Surg* 2020; 26: 34. doi: 10.1051/mbcb/2020029
85. An JH, Park SH, Han JJ, Jung S, Kook MS, Park HJ, Oh HK. Treatment of dental implant displacement into the maxillary sinus. *Maxillofac Plast Reconstr Surg* 2017; 39: 35. doi: 10.1186/s40902-017-0133-1
86. Wanner L, Manegold-Brauer G, Brauer HU. Review of unusual intraoperative and postoperative complications associated with endosseous implant placement. *Quintessence Int* 2013; 44: 773–781. doi: 10.3290/j.qi.a29936
87. Griffa A, Viterbo S, Boffano P. Endoscopic-assisted removal of an intraorbital dislocated dental implant. *Clin Oral Implants Res* 2010; 21: 778–780. doi: 10.1111/j.1600-0501.2009.01894.x
88. Kitamura A. Removal of a migrated dental implant from the maxillary sinus by transnasal endoscopy. *Br J Oral Maxillofac Surg* 2007; 45: 410–411. doi: 10.1016/j.bjoms.2005.12.007

Figure captions

Fig. 1. PRISMA flow diagram of the systematic literature review.

Fig. 2. Risk of bias graphs for the included publications, according to the Joanna Briggs Institute Critical Appraisal Tool for: (A) case reports and (B) case series. The judgement of the review authors about each risk of bias item is presented as the percentage of the total number of included publications.

Fig. 3. Number of cases of dental implants displaced into the maxillary sinus reported from 1990 to 2021.

Fig. 4. Surgical approaches to remove dental implants displaced into the maxillary sinus from 1990 to 2021.

[Figure legend]

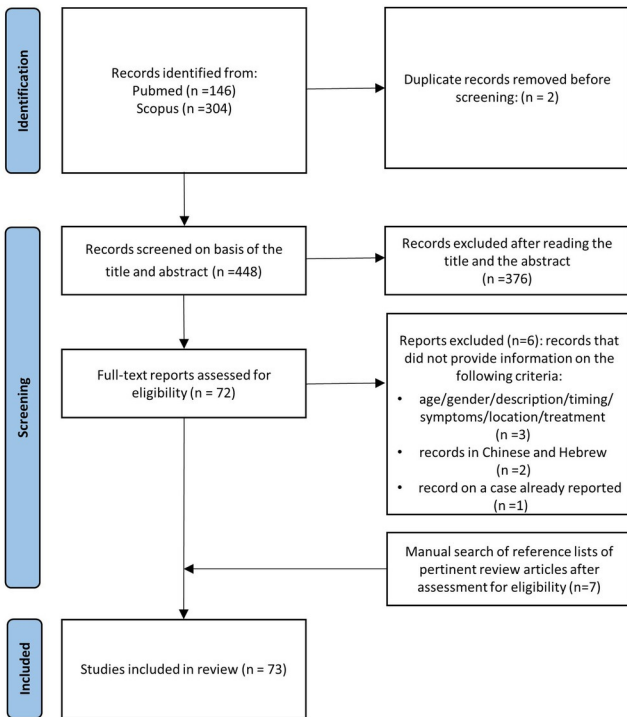
AA: alveolar approach; CL: Caldwell–Luc; LA: lateral approach; ENS: endoscopic nasal surgery; C: combination of transoral and transnasal approaches.

Fig. 5. Algorithm of treatment approaches for removing a dental implant from the maxillary sinus: (A) during implant surgery and (B) after the surgery.

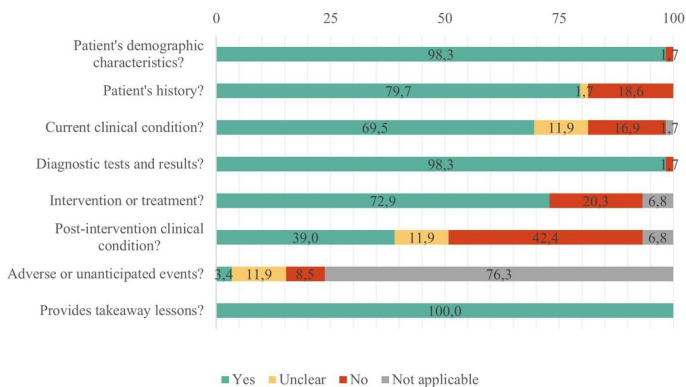
[Figure legend]

AA: alveolar approach; CL: Caldwell–Luc; LA: lateral approach; ENS: endoscopic nasal surgery; OAC: oroantral communication.

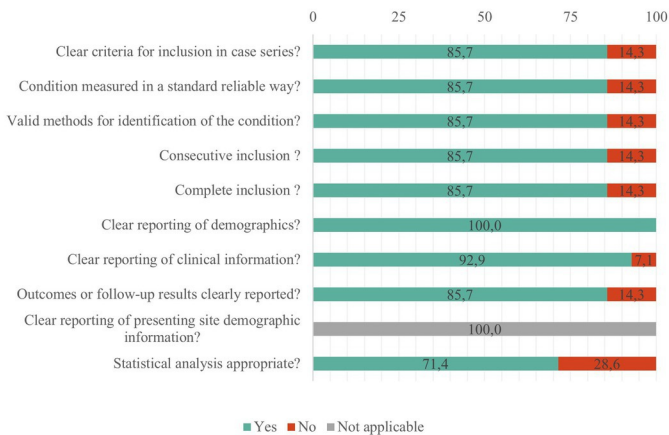
Identification of studies via databases



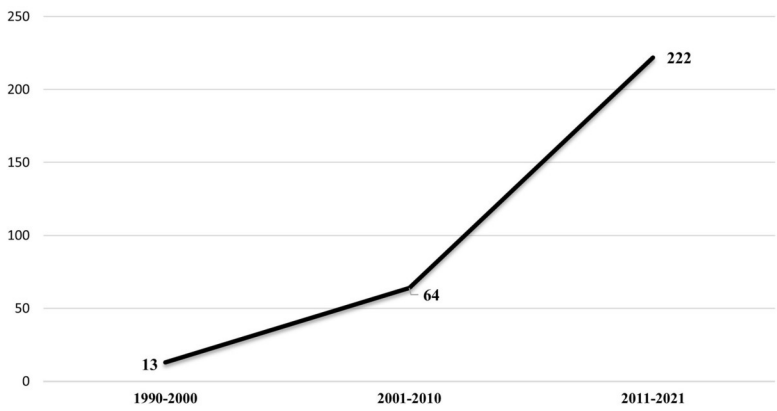
A. Case reports



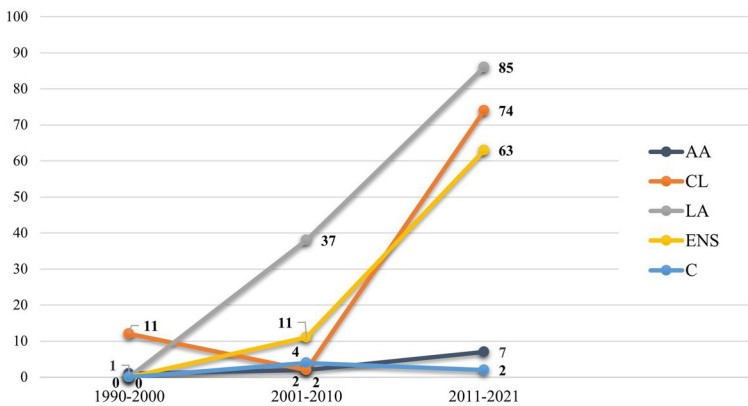
B. Case series



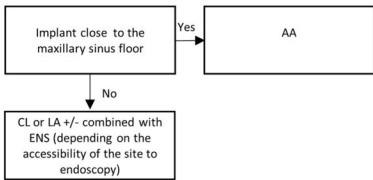
Number of dental implants displaced into the maxillary sinus



Number of cases of dental implants displaced into the maxillary sinus



A.



B.

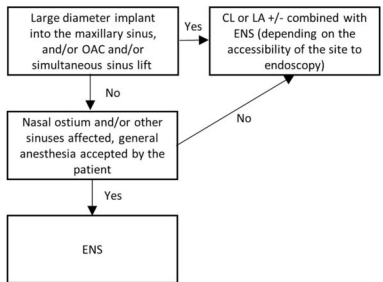


Table 1. Inclusion and exclusion criteria.

Inclusion criteria	Exclusion criteria
<ul style="list-style-type: none"> • Publications involving humans • Publications reporting dental implants displaced into the maxillary sinus, case(s) with sufficient epidemiological, diagnostic, and/or therapeutic data • Publications written in English or French 	<ul style="list-style-type: none"> • Animal studies • Publications on displacement of a foreign body other than a dental implant into the maxillary sinus • Publications of dental implants displaced in areas other than in the maxillary sinus • Publications not involving full dental implant displacement into the maxillary sinus

Table 2. Distribution of dental implants displaced into the maxillary sinus according to the implant site.

Implant site	Number	%
Molar		
M1	71	23.7
M2	30	10.0
M ^a	2	0.7
Total	103	34.4
Premolar		
PM1	6	2.0
PM2	25	8.4
Total	31	10.4
Not reported	165	55.2
Total	299	100

M1, upper first molar; M2, upper second molar; PM1, upper first premolar; PM2, upper second premolar.

^aNot reported whether M1 or M2.

Table 3. Risk factors for dental implant displacement into the maxillary sinus reported in the literature.

Practitioner-related	Patient-related
<ul style="list-style-type: none"> • Poor clinical and radiological analysis of the situation: lack of anticipation of potential complications • Inadequate site rehabilitation: lack of pre-implant surgery • Poor surgical planning: inappropriate choice of implant type • Poorly controlled surgical procedure: lack of primary stability of the implant • Implant buried (implant overlay) • Poorly controlled prosthetic procedure: impaired osseointegration • Absence or limited oral surgery skills 	<ul style="list-style-type: none"> • Proximity of the sinus: upper first molar site • Significant pneumatization of the sinus: related to age, progressive edentulism, and ethnicity (e.g., Asian patients have been reported to have less voluminous sinuses) • Unfavourable anatomical characteristics: insufficient bone volume, poor bone quality (bone height <4 mm) • Poor oral and dental hygiene, smoking: peri-implantitis