



HAL
open science

Insular functional connectivity in migraine with aura

Cédric Gollion, Fleur Lerebours, Federico Nemmi, Germain Arribarat, Fabrice Bonneville, Vincent Larrue, Patrice Péran

► To cite this version:

Cédric Gollion, Fleur Lerebours, Federico Nemmi, Germain Arribarat, Fabrice Bonneville, et al.. Insular functional connectivity in migraine with aura. *Journal of Headache and Pain*, 2022, 23 (1), pp.106. 10.1186/s10194-022-01473-1 . hal-04591904

HAL Id: hal-04591904

<https://hal.science/hal-04591904v1>

Submitted on 15 Oct 2024

HAL is a multi-disciplinary open access archive for the deposit and dissemination of scientific research documents, whether they are published or not. The documents may come from teaching and research institutions in France or abroad, or from public or private research centers.

L'archive ouverte pluridisciplinaire **HAL**, est destinée au dépôt et à la diffusion de documents scientifiques de niveau recherche, publiés ou non, émanant des établissements d'enseignement et de recherche français ou étrangers, des laboratoires publics ou privés.



Distributed under a Creative Commons Attribution 4.0 International License

RESEARCH

Open Access



Insular functional connectivity in migraine with aura

Cédric Gollion^{1,2*}, Fleur Lerebours¹, Federico Nemmi², Germain Arribarat², Fabrice Bonneville^{2,3}, Vincent Larrue^{1†} and Patrice Péran^{2†}

Abstract

Introduction: Insula plays an integrating role in sensory, affective, emotional, cognitive and autonomic functions in migraine, especially in migraine with aura (MA). Insula is functionally divided into 3 subregions, the dorsoanterior, the ventroanterior and the posterior insula respectively related to cognition, emotion, and somatosensory functions. This study aimed at investigating functional connectivity of insula subregions in MA.

Methods: Twenty-one interictal patients with MA were compared to 18 healthy controls (HC) and 12 interictal patients with migraine without aura (MO) and were scanned with functional MRI during the resting state. Functional coupling of the insula was comprehensively tested with 12 seeds located in the right and left, dorsal, middle, ventral, anterior and posterior insula, by using a seed-to-voxel analysis.

Results: Seed-to-voxel analysis revealed, in MA, a strong functional coupling of the right and left antero-dorsal insula with clusters located in the upper cerebellum. The overlap of these cerebellar clusters corresponded to the vermis VI. These functional couplings were not correlated to duration of MA, frequency of MA attacks nor time since last MA attack, and were not found in MO.

Discussion: The anterior insula and superior cerebellum, including vermis VI, are components of the central Autonomic Nervous System (ANS) network. As these regions are involved in the control of cardiovascular parasympathetic tone, we hypothesize that this connectivity may reflect the cardiovascular features of MA.

Conclusion: The anterior dorsal insula is connected with vermis VI in MA patients in the resting state. This connectivity may reflect the cardiovascular features of MA.

Trial registration: NCT02708797.

Keywords: MRI, Functional MRI, Insula, Migraine, Migraine with aura, Cerebellum vermis

Introduction

Migraine is a disabling disorder affecting up to 15% of the global population, and is the second leading cause of years lived with disability [1, 2]. Migraine pain is related

to the involvement of the trigeminovascular system [3], but migraine is not only a pain, as it is also accompanied by several sensory, autonomic, affective and cognitive disorders. These symptoms are posited to result from multiple brain networks involvement within the brainstem, the subcortical and cortical areas, beyond the trigemino-vascular system [4]. In about one third of migraine patients, migraine attacks are accompanied by an aura which is a transient progressive and fully reversible central neurological symptom, most often visual, occurring before the headache. The insula is involved in

[†]Vincent Larrue and Patrice Péran these authors contributed equally to the paper.

*Correspondence: gollion.c@chu-toulouse.fr

¹ Department of Neurology, University Hospital of Toulouse, 31059 cedex 9 Toulouse, France

Full list of author information is available at the end of the article



© The Author(s) 2022. **Open Access** This article is licensed under a Creative Commons Attribution 4.0 International License, which permits use, sharing, adaptation, distribution and reproduction in any medium or format, as long as you give appropriate credit to the original author(s) and the source, provide a link to the Creative Commons licence, and indicate if changes were made. The images or other third party material in this article are included in the article's Creative Commons licence, unless indicated otherwise in a credit line to the material. If material is not included in the article's Creative Commons licence and your intended use is not permitted by statutory regulation or exceeds the permitted use, you will need to obtain permission directly from the copyright holder. To view a copy of this licence, visit <http://creativecommons.org/licenses/by/4.0/>. The Creative Commons Public Domain Dedication waiver (<http://creativecommons.org/publicdomain/zero/1.0/>) applies to the data made available in this article, unless otherwise stated in a credit line to the data.

multiple cerebral functions such as sensorymotor processing, pain, taste, interoception, autonomic control, emotions, attention or salience which refers to the ability to select the most relevant information among multiple internal and external stimuli [5]. Parcellation of insula resulted in two architectonic subdivisions (posterior granular area and anterior dysgranular area) to thirteen multi-modal MRI subdivisions [5, 6]. Nevertheless, data-driven meta-analysis of human functional imaging studies supported a tripartite subdivision of the insula into a ventroanterior area, a dorsoanterior area and a posterior area. The ventroanterior insula is functionally coupled with limbic areas and is associated with emotion, chemosensation and autonomic functions. The dorsoanterior insula is connected to the anterior cingulate cortex and the dorsolateral prefrontal cortex and plays a role in cognitive tasks and executive control. Conversely, the posterior insula is connected to the somatosensory cortex and the supplementary motor area resulting in pain and somatosensory functions involvement [7]. Evidences support the involvement of the insula in several features of migraine pathophysiology from the ictal phase to chronicisation. During the ictal phase of spontaneous migraine attacks, Positron Emission Tomography (PET) studies revealed activation of bilateral insula cortex as well as other cortical areas, brainstem and diencephalic nuclei [8, 9]. In addition, functional MRI studies during the ictal phase showed a stronger activation of the anterior insula in response to olfactory stimulations, but a decreased functional connectivity (FC) of the anterior insula with the medial prefrontal cortex within the Default Mode Network (DMN) inversely proportional to the pain intensity [10, 11]. Another study showed a higher FC between the right thalamus and the left insular cortex during spontaneous migraine attacks [12]. During the interictal phase of migraine without aura (MO), the right posterior insula was identified as a hub of FC more strongly connected to the supplementary motor cortex and the paracentral lobule among other brain areas [13]. In high frequency migraine, defined by 8 to 14 monthly migraine days, compared to low frequency migraine, heat painful stimulations of the hand induced lower contralateral anterior insula and bilateral inferior insula activations, but a higher connectivity of bilateral insula with the left post central gyrus [14]. In chronic migraine, number of years of chronic migraine were correlated to the resting state FC between bilateral anterior insula and the right mediadorsal thalamus, as well as to the FC between the right anterior insula and the periaqueductal grey matter (PAG) [15]. Overall, the insula is posited to play a key role in migraine, acting as a « hub » of integration of autonomic, sensory, affective and cognitive functions [16]. Insula in migraine with aura (MA) is of specific interest as

previous studies have found specific alterations of insular connectivity in MA. The anterior insula had a reduced connectivity with occipital areas in MA compared to MO and Healthy Controls (HC), and the connectivity changes between the left anterior insula and occipital areas were negatively correlated with headache severity in MA only [17]. In a study investigating cognitive functions in migraine and assessing the DMN, patients with MA presented an increased FC between the right insular cortex, the left angular gyrus, the left supramarginal gyrus, the right precentral gyrus and the right postcentral gyrus compared to MO. In patients with complex MA, defined by more than visual symptoms, the right anterior insula was more strongly connected within the sensorimotor network compared to simple visual aura and MO, and this increased FC could discriminate between complex MA and simple visual aura [18]. Moreover, in a PET/MRI brain study, uptake of [11C]PBR28, a glial activation maker, in the right posterior insula was correlated to the number of MA attacks [19]. However, this result was not compared to MO. These observations suggested that the insula exhibited altered connectivity in MA, however these studies have not taken into account the functional division of the insula. In fact, the studies have focused either on the salience network, which includes the anterior insula [17, 20, 21], or on the somato-sensory network, which includes the posterior insula [18] or to a few regions of interest that did not explore the insula in its subdivisions. To our knowledge, the FC of the insula's functional subdivisions has not yet been comprehensively studied in MA. Therefore, in the present study, we aimed at investigating the bilateral insular connectivity in MA using seeds in the anterior, posterior, dorsal, middle and ventral insula.

Methods

Design and population

This study was retrospectively conducted from images acquired in a previous MRI protocol (Trial registration: NCT02708797). Twenty-three patients with MA patients aged 30 to 55 without history of neurological disease were compared to 23 age and sex matched HC. Volunteers were excluded in case of abnormal neurological examination or abnormal MRI. Diagnosis of MA was confirmed by a trained neurologist according to the ICHD-3 criteria [22]. Patients with MA were included during a pain-free period for at least 8 days. Age at migraine onset and aura onset, frequency of migraine attacks in the past twelve months, type of aura (visual, sensory, dysphasic or other), frequency of aura among all migraine attacks, time since last migraine attack, and preventive treatment were recorded. To appraise the specificity of results found in patients with MA, a post-hoc analysis was conducted in

twelve patients with episodic MO from another study previously conducted in our center. This previous study compared the brain FC of patients with chronic migraine to patients with episodic migraine [23]. The fMRI protocol was the same and the patients with MO were scanned during a pain-free period of at least 72 h.

Ethics

The study was approved by the local institutional Ethics Committee (Comité de protection des personnes Sud-Ouest I). All participants gave written informed consent.

Images acquisition

MRI images were acquired on a 3 T MR imager (Philips Achieva dStream 3 T 32-channel coils). All MRI were interpreted by a senior neuroradiologist. All volunteers were evaluated during the resting state, awake and eyes closed. No activation task was performed. For the resting-state functional MRI (rs-fMRI), Blood Oxygen Level Dependent (BOLD) sequence was assessed with the following parameters: 160 volumes, TR = 3000 ms, TE = 30, acquisition matrix 80 × 78, slices = 45, flip angle = 90°, spatial resolution voxel size = 3 × 3 × 3 mm³. A 3D T1-weighted sequence was also acquired with the following parameters: TR = 8.1 ms; TE = 3.7 ms, acquisition matrix 240 × 240, slices = 170, flip angle = 8°, resolution voxel size = 1 × 1 × 1 mm³.

Rs-fMRI analysis

The analysis of the rs-fMRI was processed using Statistical Parametric Mapping (SPM) 12 software (<https://www.fil.ion.ucl.ac.uk/spm/>), running under MATLAB, and conn toolbox. Pre-processing consisted in spatially realignment, normalization in the Montreal Neurological Institute (MNI) space, smoothing using a 8 mm Gaussian kernel. We performed seed-to-voxels analysis of insular connectivity in MA. The seeds corresponded three Region Of Interest (ROI) dorsal, middle and ventral were placed in the left and right anterior and posterior insular cortex accounting for a total of 12 ROI (Fig. 1). MNI coordinates were derived from Cauda et al., *NeuroImage 2011* [24] and are given in Table 1. We thus conducted a seed-to-voxel analysis between each of these insular ROI, considered as seeds, and the voxels in the whole brain. An average time-course was obtained from the seeds. Correlation maps were generated for each subject in a first level analysis, estimating the correlation coefficient between the whole brain voxels and seeds-time series. The connectivity maps were then introduced in a second level analysis comparing the resting-state FC between patients with MA and HC using a two-sample t-test. The statistical maps were thresholded at $p < 0.001$ and only clusters of more than 10 voxels were retained.

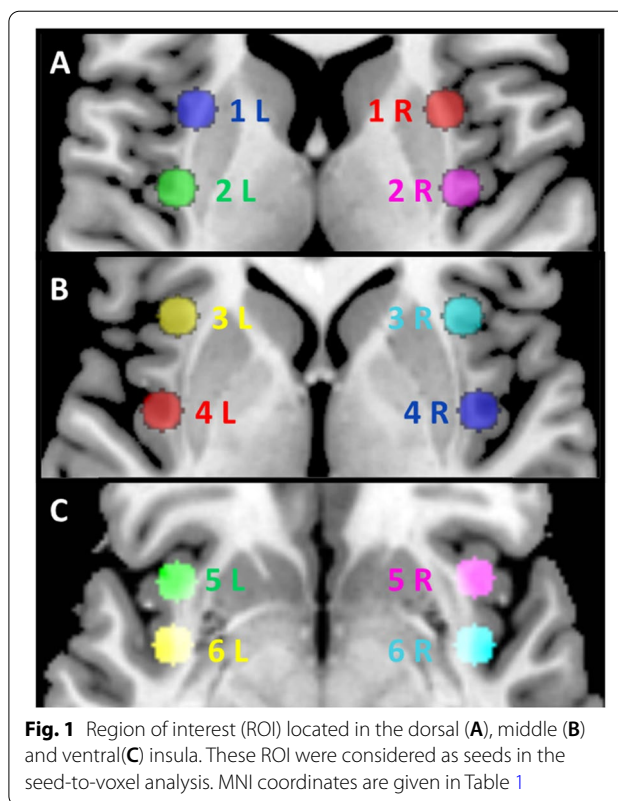


Fig. 1 Region of interest (ROI) located in the dorsal (A), middle (B) and ventral(C) insula. These ROI were considered as seeds in the seed-to-voxel analysis. MNI coordinates are given in Table 1

Table 1 MNI coordinates of the insular ROI (Region of interest)

	Right Number of ROI (x, y, z)	Left Number of ROI (x, y, z)
Antero-dorsal insula	ROI 1 R (31, 12, 8)	ROI 1 L (-31, 12, 8)
Postero-dorsal insula	ROI 2 R (36, -9, 7)	ROI 2 L (-36, -9, 7)
Anterior middle insula	ROI 3 R (36, 19, 1)	ROI 3 L (-36, 19, 1)
Posterior middle insula	ROI 4 R (40, -5, 0)	ROI 4 L (-40, -5, 0)
Antero-ventral insula	ROI 5 R (36, 16, -8)	ROI 5 L (-36, 16, -8)
Postero-ventral insula	ROI 6 R (40, -2, -8)	ROI 6 L (-40, -2, -8)

R right, L Left

Connectivity was assumed significant at $p < 0.05$ corrected for multiple comparisons using the family wise error rate (FWE). A secondary ROI-to-ROI analysis was conducted to precise results of the seed-to-voxels analysis. The average time course was extracted from each ROI and connectivity value was calculated (Fischer Z scores). In ROI-to-ROI analysis, functional coupling was assumed significant at $p < 0.05$. Results were presented with mricron software. Significant results found in MA were afterward compared in patients with MO in order to evaluate the specificity of this result in MA.

Statistics of clinical data

Qualitative and continuous variables were presented as percentages and arithmetic medians with their corresponding interquartile range. Qualitative variables were compared using the Chi-squared test and continuous variable by using the Wilcoxon-Mann-Whitney test. Correlations between clinical data and the strength of FC, figured as a Z score, were evaluated with the Spearman correlation coefficient. Statistical analyses were performed with the statistical R software (v.4.0.0). All tests were considered significant at the 0.05 level.

Data availability

Anonymized data not published within this article will be made available on reasonable request from any qualified investigator.

Results

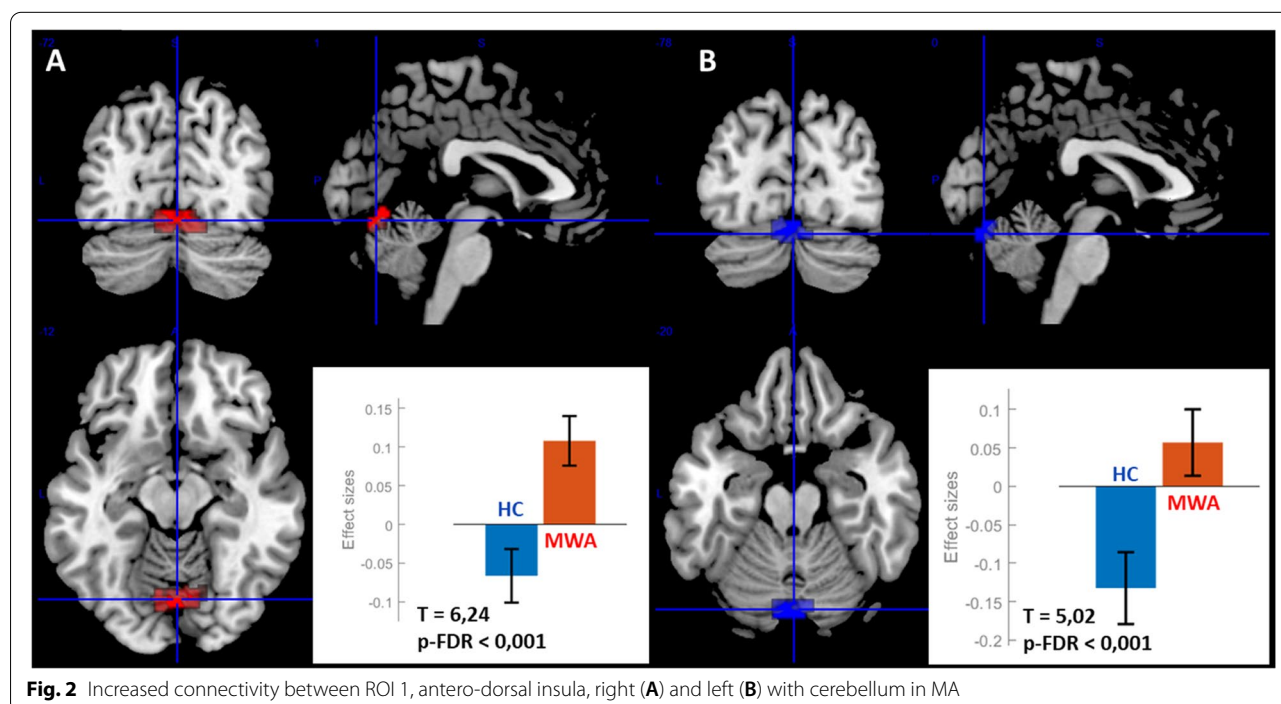
Subjects

Two patients with MA and five HC were excluded because of motion artifacts on BOLD sequence. Functional MR images were thus available in 21 patients with MA, 12 patients with MO and 18 HC. The included volunteers had no significant medical history and were similar in age (MA, median age (IQR): 39.0 (12.0) years; MO: 42 (18.7) years; HC: 39 (9.5) years), $P > 0.05$ and sex (81% women in MA; 75% in MO and 72% in HC), $P > 0.05$. Seven patients with MA were under preventive therapy (2 betablocker, 2 topiramate, 1 valproic acid, 1

valproic acid and aspirin, 1 oxetorone). All patients with MA had visual aura, 8 of them also had sensory aura and seven dysphasic aura. In MA, median (IQR) duration of migraine was 25 [13] years, annual frequency of attacks was 15 [17] attacks/year and time since last migraine attack was 19 [24] days. No patient with MO was under preventive therapy. In MO, median (IQR) duration of migraine was 21 (10.5) years and monthly migraine days was 3.5 (1.25) days.

MA vs HC: seed-to-voxel analysis

ROI 1 R presented an increased FC in MA with a cluster encompassing vermis 6 (31% volume of the cluster), lingual gyrus left (21%), lingual gyrus right (18%), cerebellum 6 right (18%) and cerebellum 6 left (12%). Size of the cluster: 257, size $p\text{-FWE} = 0.015$, peak $p\text{-FWE} = 0.043$, MNI coordinates (x, y, z) = (06, -72, -12), $T = 6,24$, $p\text{-FDR} < 0,001$ (Fig. 2). ROI 1 L presented an increased FC in MA with a cluster encompassing cerebellum crus 1 left (20%), vermis 7 (18%), cerebellum Crus 2 left (17%), vermis 6 (13%), cerebellum 6 left (11%), lingual gyrus left (10%), cerebellum Crus 1 right (5%), cerebellum 6 right (2%). Size of the cluster 218, size $p\text{-FWE} = 0.027$, peak $p\text{-FWE} = 0.806$, MNI coordinates (x, y, z) = (-02, -78, -18), $T = 5,02$, $p\text{-FDR} < 0,001$ (Fig. 2). No significant difference was found between MA and HC for other insular ROI. Then both ROI 1 R and 1 L, corresponding respectively to right and left antero-dorsal insular cortex, presented an increased FC



with a cerebellum area. The anatomical labelling was carried out with SUIIT toolbox [25]. The overlapping of the two cerebellar regions connected with the antero-superior insula corresponded to the vermis VI, MNI coordinates $(x, y, z) = (00, -76, -17)$, size of the cluster 86 (Fig. 3).

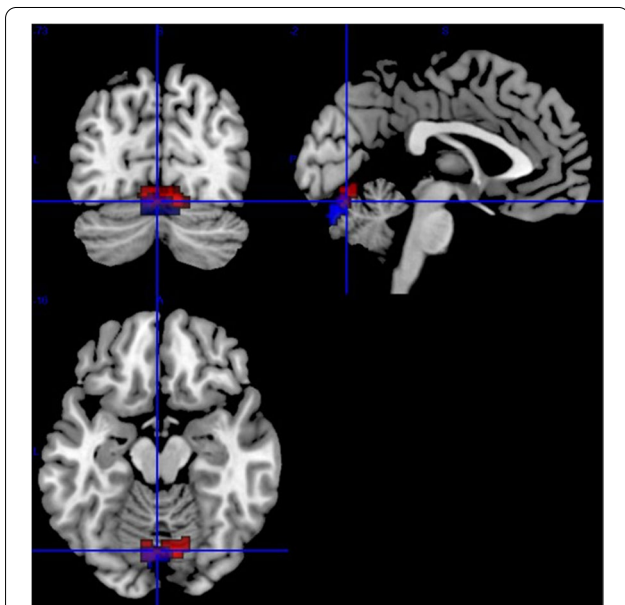


Fig. 3 Overlap (purple) of areas highly connected to the right (red) and left (blue) antero-dorsal insula, corresponding to vermis VI

MA vs HC: ROI-to-ROI analysis

Although the overlap functionally coupled to the antero-dorsal insula corresponded to vermis VI, it is noteworthy that right and left lingual cortices were part of the clusters. As the lingual cortices are involved in MA, we conducted ROI-to-ROI analysis between lingual cortices and insula and between vermis VI and insula. It revealed no FC between the right or the left lingual cortices and ROI 1R or ROI 1L. In contrast, we confirmed the strong FC between the right and left antero-dorsal insula with the vermis VI: $T(48) = 3.27$; $p\text{-FDR} = 0.002$, Fig. 4.

Correlation with clinical data in MA

Neither the FC between ROI 1 R and vermis VI nor the FC between ROI 1 L and vermis VI were correlated to clinical features (duration of migraine, frequency of migraine attacks and time since last migraine attack), Table 2.

Comparison of MA and HC with Mo by using ROI-to-ROI analysis

We compared the FC of vermis VI to ROI 1R and ROI 1L between MO and HC and between MO and MA. No difference of functional coupling was found between MO and HC. When MA was compared to MO, vermis VI was functionally coupled to ROI 1R but not to ROI 1L, $T(48) = 2.96$; $p\text{-FDR} = 0.004$.

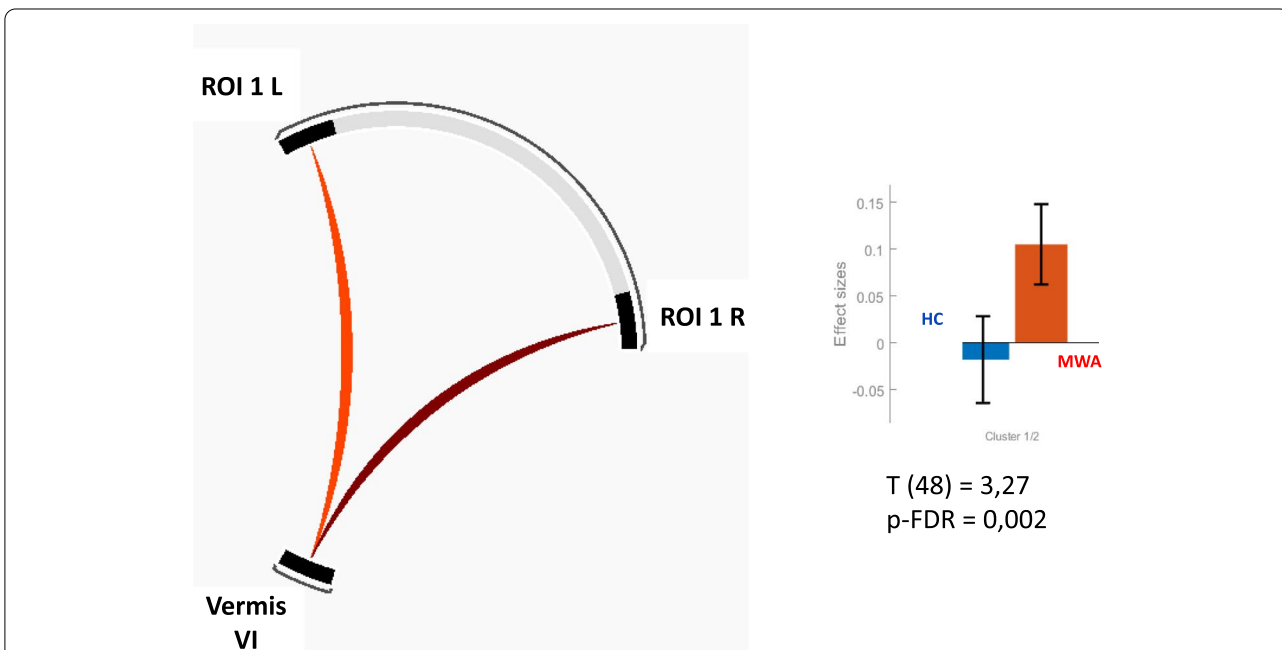


Fig. 4 ROI-to-ROI functional coupling of vermis VI with right (ROI 1 R) and left (ROI 1 L) antero-dorsal insula. HC = healthy controls. MA = migraine with aura

Table 2 Correlation between antero-dorsal insula – vermis VI connectivities and characteristics of migraine (Spearman correlation coefficients)

	Connectivity ROI 1 R – vermis VI (Z score)	Connectivity ROI 1 L – vermis VI (Z score)
Duration of migraine (years)	$\rho=0,21; p=0,36$	$\rho=0,09; p=0,34$
Frequency of migraine attack (/year)	$\rho=-0,40; p=0,08$	$\rho=-0,24; p=0,30$
Time since last migraine attack (days)	$\rho=0,34; p=0,13$	$\rho=0,22; p=0,69$

Discussion

This explorative study aimed at investigating whether insula exhibits differences in FC in patients with MA using a comprehensive seed-to-voxel analysis of right and left insula with six seeds located within the anterior, posterior, dorsal, middle and ventral insula. We found an increase connectivity of both right and left antero-dorsal insula with the cerebellar vermis VI in patients with MA. This increased FC was not found in patients with MO. Previous studies in migraine have shown that insula exhibits alterations of FC with brain structures involved in pain processing such as thalamus [12], PAG [26, 27], somatosensory cortex [18], or cognitive function such as the default mode network [21, 28] or salience network [17, 20, 21]. In MA specifically, insula exhibited altered FC with occipital cortex and somatosensory cortex only in complex MA [17, 18]. However, these findings relied mostly on investigations of other brain areas or partial explorations of insula. To the best of our knowledge, our result is new and its originality could be explained by the methods which consisted of a comprehensive insular FC analysis by distinguishing insula subdivisions from each other. Other methodological differences with previous studies should be considered. Previous studies showing an increased FC of the insula with the thalamus involved MO during spontaneous migraine attacks [12], an increased connectivity of insula with the PAG involved patients with allodynia [26, 27], an increased connectivity of insula with the somatosensory cortex involved patients with complex auras [18]. One study showing a lower correlation with the visual cortex set a less conservative threshold of significance for statistical maps [17]. Our study showing an increased FC of both right and left antero-dorsal insula with the cerebellar vermis VI provides a new perspective on the role of insula in MA. Because our study did not demonstrate a correlation between this FC and clinical features of MA, we acknowledge that the clinical significance of our finding is currently undetermined. However, knowledge on the function of the insula and the vermis VI allowed us to postulate two hypotheses to explain this increased FC: one related to

the central integration of pain, the other to the control of the parasympathetic autonomic nervous system. Animals and humans studies have highlighted the involvement of the cerebellum in pain [29]. Indeed, studies in healthy volunteers, using fMRI showed an activation of cerebellar lobule VI, VIIa, crus I and vermal lobule VIIa evoked by painful stimulation of the left nostril. The cerebellum presented an increased FC with structures involved in pain processing such as rostral pons, PAG, thalamus and cortices regions including insula and face area in the precentral gyrus [30]. Compared to HC, migraine patients presented a higher activation of PAG and left cerebellum crus I in response to nociceptive trigeminal stimulations. Moreover the vermis VI belonged to a cluster that comodulated with migraine-phase [31]. Moreover, functional MR studies revealed cerebellar activation evoked by heat painful stimulations in migraine [32–34]. Although these evidences stressed the role of cerebellum in trigeminal pain processing in migraine, our result did not support clearly a role of vermis-insula FC in pain because this FC was not correlated to migraine feature and was not found in patients with MO. The insula is part of the autonomic nervous system (ANS) network, as well as the anterior cingulate cortex, the pre-frontal cortex and the amygdala [35]. Some studies have suggested that the cerebellum is also involved in the regulation of the cardiovascular ANS. Functional neuroimaging studies in human confirmed that cerebellum is activated during tasks challenging cardiovascular ANS and both anterior insula and vermis cerebellum seem to be involved in the regulation of parasympathetic tone [36–38]. A meta-analysis published in 2013 included studies analysing peripheral signals in response to ANS stimulation by cognitive, affective and somatosensory autonomic nervous system tasks in conjunction with brain imaging in healthy subjects. The ANS response was classified as sympathetic or parasympathetic based on measures of heart rate variability and electrodermal activity. This meta-analysis showed parasympathetic activation of the dorsoanterior insula and vermis VI in addition to other brain structures such as the amygdala or posterior cingulate cortex [38]. The shared role of the cerebellum and insula in the regulation of the cardiovascular ANS is also supported by two activation studies and a connectivity study during ANS stimulation tasks: in a PET study, Critchley et al. have explored the cerebral activation during isometric exercise and mental arithmetic stressor tasks. These tasks induced variation in mean arterial blood pressure (MAP) and heart rate (HR) and were accompanied by an activation of the midline cerebellum, the brainstem in the region of the pontine reticular nuclei and the right dorsal cingulate cortex. In a conjunction analysis, the activation of both the cerebellar vermis and the insular cortex covaried with MAP and HR [39]. Baker et al., in an fMRI study, showed that lower-body negative pressure maneuver (LBNP) induced activation of bilateral insula. The cerebellum and the bilateral insula were

activated during the recovery phase of LBNP [40]. A further analysis revealed that vermis VI was part of a cerebellar connectome functionally coupled with bilateral insula, as well as anterior cingulate cortex, bilateral thalamus and bilateral putamen [41]. These previous observations supported the hypothesis that the increased FC between dorsoanterior insula and vermis VI in MA could be related to the cardiovascular parasympathetic ANS control. However, our study was unable to confirm this hypothesis as no recording of cardiovascular parameters was performed during the MR scan. Nevertheless, this hypothesis is likely given the cardiovascular autonomic disorders observed in MA. It has previously been shown that both MA and MO are at increased risk of syncope and orthostatic intolerance [42]. However, one study found that only MA was associated with increased risk of syncope after adjustment on confounders [43]. A review of studies assessing cardiovascular autonomic balance in migraine showed a trend toward greater autonomic dysfunction in MA than in MO, with sympathetic dysfunction being more common than parasympathetic dysfunction [44]. These previous observations supported the hypothesis of ANS-related alteration of FC between dorsoanterior insula and vermis VI in MA. The strengths of our study were the comprehensive exploration of the insula in a seed-to-voxel analysis. The result remained significant after correction for multiple comparisons and was found bilaterally. A random result seemed thus unlikely. ROI-to-ROI analysis excluded the involvement of the lingual cortex in the vicinity and confirmed the functional coupling of the vermis VI with the antero-dorsal insula. Some limitations should be mentioned. The study involved a small sample of volunteers, which may have underestimated differences in connectivity with other brain areas. Although a previous study suggested gender differences of insular connectivity in pain [45], our study sample did not allow for testing gender differences of insular connectivity in migraine. Patients with MO were included from another study previously conducted at our center but the MRI protocol was the same as in the study including patients with MA and HC. Finally, assessment of the cardiovascular ANS during fMRI was not performed which mitigate the interpretation of our result. Further studies are warranted to determine whether the increased functional coupling of antero-dorsal insula with vermis VI reflected an increased parasympathetic tone as we may hypothesize.

Conclusion

In MA, the bilateral antero-dorsal insula was strongly functionally coupled with the cerebellar vermis IV. Because both regions are involved in the control of the parasympathetic cardiovascular ANS, this functional connectivity could reflect the cardiovascular features of MA. Further research is needed to explore this hypothesis.

Abbreviations

ANS: Autonomic nervous system; BOLD: Blood oxygen level dependent; DMN: Default mode network; FC: Functional connectivity; FEW: Family wise error; fMRI: Functional MRI; HC: Healthy controls; HR: Heart rate; ICHD: International classification of headache disorders; IQR: Interquartile range; LBNP: Lower-body negative pressure maneuver; MAP: Mean arterial blood Pressure; MA: Migraine with Aura; MNI: Montreal neurological institute; MO: Migraine without aura; MRI: Magnetic resonance imaging; PAG: Periaqueductal grey matter; PET: Positron tomography emission; ROI: Region of Interest; SPM: Statistical parametric mapping; Rs-fMRI: Resting functional MRI.

Acknowledgements

We thank the INSERM/UPS UMR1214 Technical Platform for performing the MRI scans.

Author contributions

C.G. and F.L. contributed to the inclusion of participants. C.G., F.N., G.A. and P.P. contributed to MR processing and statistical analysis. F.B. read MR images. C.G. wrote the main manuscript text and prepared tables and figures. V.L. and P.P. contributed to study design and proofread the manuscript. All authors reviewed the manuscript.

Funding

No funding.

Availability of data and materials

Anonymized data and materials not published within this article will be made available on reasonable request from any qualified investigator.

Declarations

Ethical approval and consent to participate

The study was approved by the local institutional Ethics Committee (Comité de protection des personnes Sud-Ouest I). All participants gave written informed consent.

Competing interests

Authors report no disclosure related to this paper.

Author details

¹Department of Neurology, University Hospital of Toulouse, 31059 cedex 9 Toulouse, France. ²Toulouse NeuroImaging Center, ToNIC, University of Toulouse III, Inserm, Toulouse, France. ³Department of Neuroradiology, University Hospital of Toulouse, Toulouse, France.

Received: 12 July 2022 Accepted: 9 August 2022

Published online: 19 August 2022

References

- GBD 2016 Disease and Injury Incidence and Prevalence Collaborators. Global, regional, and national incidence, prevalence, and years lived with disability for 328 diseases and injuries for 195 countries, 1990–2016: a systematic analysis for the Global burden of disease study 2016. *Lancet*. 2017;390(10100):1211–59. [https://doi.org/10.1016/S0140-6736\(17\)32154-2](https://doi.org/10.1016/S0140-6736(17)32154-2).
- Stovner LJ, Hagen K, Linde M, Steiner TJ (2022) The global prevalence of headache: an update, with analysis of the influences of methodological factors on prevalence estimates. *J Headache Pain* 23(1):34
- Ashina M. Migraine. *New England Journal of Medicine* [Internet]. 2020 Nov 4 [cited 2021 Mar 10]; Available from: <https://doi.org/10.1056/NEJMa1915327>
- Burstein R, Nosedà R, Borsook D (2015) Migraine: multiple processes, complex pathophysiology. *J Neurosci* 35(17):6619–6629
- Uddin LQ, Nomi JS, Hébert-Seropian B, Ghaziri J, Boucher O (2017) Structure and function of the human insula. *J Clin Neurophysiol* 34(4):300–306
- Glasser MF, Coalson TS, Robinson EC, Hacker CD, Harwell J, Yacoub E et al (2016) A multi-modal parcellation of human cerebral cortex. *Nat* 536(7615):171–178

7. Chang LJ, Yarkoni T, Khaw MW, Sanfey AG (2013) Decoding the role of the insula in human cognition: functional parcellation and large-scale reverse inference. *Cereb Cortex* 23(3):739–749
8. Afridi SK, Giffin NJ, Kaube H, Friston KJ, Ward NS, Frackowiak RSJ et al (2005) A positron emission tomographic study in spontaneous migraine. *Arch Neurol* 62(8):1270–1275
9. Denuelle M, Fabre N, Payoux P, Chollet F, Geraud G (2007) Hypothalamic activation in spontaneous migraine attacks. *Headache* 47(10):1418–1426
10. Stankewitz A, May A (2011) Increased limbic and brainstem activity during migraine attacks following olfactory stimulation. *Neurology* 77(5):476–482
11. Coppola G, Di Renzo A, Tinelli E, Di Lorenzo C, Scapeccia M, Parisi V et al (2018) Resting state connectivity between default mode network and insula encodes acute migraine headache. *Cephalalgia* 38(5):846–854
12. Amin FM, Hougaard A, Magon S, Sprenger T, Wolfram F, Rostrup E et al (2018) Altered thalamic connectivity during spontaneous attacks of migraine without aura: A resting-state fMRI study. *Cephalalgia* 38(7):1237–1244
13. Ke J, Yu Y, Zhang X, Su Y, Wang X, Hu S, et al. Functional alterations in the posterior insula and cerebellum in migraine without aura: A resting-state MRI study. *frontiers in behavioral neuroscience* [Internet]. 2020 [cited 2022 Jun 7];14. Available from: <https://doi.org/10.3389/fnbeh.2020.567588>.
14. Maleki N, Becerra L, Brawn J, Bigal M, Burstein R, Borsook D (2012) Concurrent functional and structural cortical alterations in migraine. *Cephalalgia* 32(8):607–20. <https://doi.org/10.1177/0333102412445622>
15. Schwedt TJ, Schlaggar BL, Mar S, Nolan T, Coalson RS, Nardos B et al (2013) Atypical resting-state functional connectivity of affective pain regions in chronic migraine. *Headache* 53(5):737–751
16. Borsook D, Veggeberg R, Erpelding N, Borra R, Linnman C, Burstein R et al (2016) The insula: A 'hub of activity' in migraine. *Neuroscientist* 22(6):632–652
17. Niddam DM, Lai KL, Fuh JL, Chuang CYN, Chen WT, Wang SJ (2016) Reduced functional connectivity between salience and visual networks in migraine with aura. *Cephalalgia* 36(1):53–66
18. Silvestro M, Tessitore A, Di Nardo F, Scotto di Clemente F, Trojsi F, Cirillo M et al (2022) Functional connectivity changes in complex migraine aura: beyond the visual network. *Eur J Neurol* 29(1):295–304
19. Albrecht DS, Mainero C, Ichijo E, Ward N, Granziera C, Zürcher NR et al (2019) Imaging of neuroinflammation in migraine with aura: A [11C] PBR28 PET/MRI study. *Neurology* 92(17):e2038–e2050
20. Androulakis XM, Krebs K, Peterlin BL, Zhang T, Maleki N, Sen S et al (2017) Modulation of intrinsic resting-state fMRI networks in women with chronic migraine. *Neurology* 89(2):163–169
21. Yu D, Yuan K, Luo L, Zhai J, Bi Y, Xue T et al (2017) Abnormal functional integration across core brain networks in migraine without aura. *Mol Pain* 13:1744806917737461
22. Headache Classification Committee of the International Headache Society (IHS) The International Classification of Headache Disorders, 3rd edition. *Cephalalgia*. 2018;38(1):1–211.
23. Lerebours F, Boulanouar K, Barège M, Denuelle M, Bonneville F, Payoux P et al (2019) Functional connectivity of hypothalamus in chronic migraine with medication overuse. *Cephalalgia* 39(7):892–899
24. Cauda F, D'Agata F, Sacco K, Duca S, Geminiani G, Vercelli A (2011) Functional connectivity of the insula in the resting brain. *Neuroimage* 55(1):8–23
25. Diedrichsen J, Balsters JH, Flavell J, Cussans E, Ramnani N (2009) A probabilistic MR atlas of the human cerebellum. *Neuroimage* 46(1):39–46
26. Mainero C, Boshyan J, Hadjikhani N (2011) Altered functional magnetic resonance imaging resting-state connectivity in periaqueductal gray networks in migraine. *Ann Neurol* 70(5):838–845
27. Schwedt TJ, Larson-Prior L, Coalson RS, Nolan T, Mar S, Ances BM et al (2014) Allodynia and descending pain modulation in migraine: a resting state functional connectivity analysis. *Pain Med* 15(1):154–165
28. Xue T, Yuan K, Zhao L, Yu D, Zhao L, Dong T et al (2012) Intrinsic brain network abnormalities in migraines without aura revealed in resting-state fMRI. *Plos One* 7(12):e52927
29. Moulton EA, Schmahmann JD, Becerra L, Borsook D (2010) The cerebellum and pain: passive integrator or active participator? *Brain Res Rev* 65(1):14–27
30. Mehnert J, Schulte L, Timmann D, May A (2017) Activity and connectivity of the cerebellum in trigeminal nociception. *Neuroimage* 15(150):112–118
31. Mehnert J, May A (2019) Functional and structural alterations in the migraine cerebellum. *J Cereb Blood Flow Metab* 39(4):730–739
32. Russo A, Tessitore A, Esposito F, Marcuccio L, Giordano A, Conforti R et al (2012) Pain processing in patients with migraine: an event-related fMRI study during trigeminal nociceptive stimulation. *J Neurol* 259(9):1903–1912
33. Moulton EA, Becerra L, Maleki N, Pendse G, Tully S, Hargreaves R et al (2011) Painful heat reveals hyperexcitability of the temporal pole in interictal and ictal migraine States. *Cereb Cortex* 21(2):435–448
34. Schwedt TJ, Chong CD, Chiang CC, Baxter L, Schlaggar BL, Dodick DW (2014) Enhanced pain-induced activity of pain processing Regions in a case-control study of episodic migraine. *Cephalalgia* 34(12):947–958
35. Ruiz Vargas E, Sörös P, Shoemaker JK, Hachinski V (2016) Human cerebral circuitry related to cardiac control: A neuroimaging meta-analysis. *Ann Neurol* 79(5):709–716
36. Kimmerly DS (2017) A review of human neuroimaging investigations involved with central autonomic regulation of baroreflex-mediated cardiovascular control. *Auton Neurosci* 207:10–21
37. Macey PM, Ogren JA, Kumar R, Harper RM (2015) Functional imaging of autonomic regulation: Methods and key findings. *Front Neurosci* 9:513
38. Beissner F, Meissner K, Bär KJ, Napadow V (2013) The autonomic brain: an activation likelihood estimation meta-analysis for central processing of autonomic function. *J Neurosci* 33(25):10503–10511
39. Critchley HD, Corfield DR, Chandler MP, Mathias CJ, Dolan RJ (2000) Cerebral correlates of autonomic cardiovascular arousal: a functional neuroimaging investigation in humans. *J Physiol* 15(523 Pt 1):259–270
40. Baker J, Paturel JR, Kimpinski K (2019) Cerebellar impairment during an orthostatic challenge in patients with neurogenic orthostatic hypotension. *Clin Neurophysiol* 130(1):189–195
41. Baker J, Kimpinski K (2020) Evidence of impaired cerebellar connectivity at rest and during autonomic maneuvers in patients with autonomic failure. *Cerebellum* 19(1):30–39
42. Thijs RD (2006) Syncope in migraine: the population-based camera study. *Neurology* 66:1034–1037
43. Kuan AS, Chen SP, Wang YF, Fuh JL, Cheng CY, Peng KP et al (2019) Risk factors and psychological impact of syncope in migraine patients. *Cephalalgia* 39(14):1838–1846
44. Miglis MG (2018) Migraine and autonomic dysfunction: which is the horse and which is the jockey? *Curr Pain Headache Rep* 22(3):19
45. Dai YJ, Zhang X, Yang Y, Nan HY, Yu Y, Sun Q et al (2018) Gender differences in functional connectivities between insular subdivisions and selective pain-related brain structures. *J Headache Pain* 19(1):24

Publisher's Note

Springer Nature remains neutral with regard to jurisdictional claims in published maps and institutional affiliations.

Ready to submit your research? Choose BMC and benefit from:

- fast, convenient online submission
- thorough peer review by experienced researchers in your field
- rapid publication on acceptance
- support for research data, including large and complex data types
- gold Open Access which fosters wider collaboration and increased citations
- maximum visibility for your research: over 100M website views per year

At BMC, research is always in progress.

Learn more biomedcentral.com/submissions

