



HAL
open science

Application of bilateral condylectomy as an alternative surgical treatment for Class III malocclusion with posterior vertical excess, a technical note

Amaury Derquenne, Jacques Mercier, Sophie Dugast, Pierre Guyonvarc'H, Pierre Corre, Hélios Bertin

► To cite this version:

Amaury Derquenne, Jacques Mercier, Sophie Dugast, Pierre Guyonvarc'H, Pierre Corre, et al.. Application of bilateral condylectomy as an alternative surgical treatment for Class III malocclusion with posterior vertical excess, a technical note. *Journal of Stomatology, Oral and Maxillofacial Surgery*, 2024, 125, pp.3. 10.1016/j.jormas.2024.101797 . hal-04590934

HAL Id: hal-04590934

<https://hal.science/hal-04590934>

Submitted on 28 May 2024

HAL is a multi-disciplinary open access archive for the deposit and dissemination of scientific research documents, whether they are published or not. The documents may come from teaching and research institutions in France or abroad, or from public or private research centers.

L'archive ouverte pluridisciplinaire **HAL**, est destinée au dépôt et à la diffusion de documents scientifiques de niveau recherche, publiés ou non, émanant des établissements d'enseignement et de recherche français ou étrangers, des laboratoires publics ou privés.

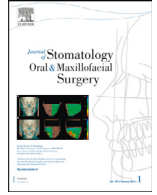


Distributed under a Creative Commons Attribution 4.0 International License



Available online at
ScienceDirect
 www.sciencedirect.com

Elsevier Masson France
EM|consulte
 www.em-consulte.com



Short Communication

Application of bilateral condylectomy as an alternative surgical treatment for Class III malocclusion with posterior vertical excess, a technical note



Amaury Derquenne^a, Jacques Mercier^{a,1}, Sophie Dugast^a, Pierre Guyonvarc'h^a, Pierre Corre^{a,b}, Hélios Bertin^{a,c,*}

^a Service de Chirurgie Maxillo-Faciale et Stomatologie, CHU de Nantes, 1 place Alexis Ricordeau, Nantes 44093, France

^b Regenerative Medicine and Skeleton (RMeS), Faculté de Chirurgie Dentaire, 1 Place Alexis Ricordeau, Nantes 44042, France

^c Laboratoire des Sarcomes Osseux et Remodelage des Tissus Calcifiés (Phy.Os UMR1238), Faculté de Médecine, 1 rue Gaston Veil, Nantes 44000, France

ARTICLE INFO

Article History:

Received 9 February 2024

Accepted 11 February 2024

Available online 12 February 2024

Keywords:

Condylectomy

Orthognathic surgery

Skeletal Class III

Mandibular posterior vertical excess

ABSTRACT

The Posterior vertical excess (PVE) associates a symmetric ramus and condyle elongation to an Angle Class III malocclusion. This dento-skeletal discrepancy can be isolated or associated to a condyle hyperplasia or a transverse overgrowth of the mandible due to macroglossia. We present the technique and the postoperative results of bilateral condylectomy applied for the surgical correction of PVE. Bilateral condylectomy represents an alternative to the bimaxillary surgery and adds to the therapeutic arsenal for the correction of Angle Class III malocclusion.

© 2024 The Author(s). Published by Elsevier Masson SAS. This is an open access article under the CC BY license (<http://creativecommons.org/licenses/by/4.0/>)

1. Introduction

Class III malocclusion is a common dento-skeletal dysmorphism characterized by an anterior crossbite that can be due to an excessive mandibular growth or a retrusive maxilla, or a combination of these two components. Class III manifests as an inversed dental relationship with a first permanent lower molar mesially occluded compared to its normal position. This malocclusion is a less represented phenotype compared to Class II dysmorphism, accounting for 5.92% versus 22.9% in global Caucasian population with a permanent dentition [1]. The dento-skeletal abnormality not only affects the aesthetic harmony of the patients, but also poses functional concerns regarding chewing or the occurrence of temporomandibular disorders [2]. The causes of skeletal Class III malocclusion are complex and can be attributed to a combination of genetic, environmental, and developmental factors. Class III is a polygenic trait with probably an autosomal dominant inheritance with incomplete penetrance and variable expression [3]. Regarding the environmental factors, deleterious oral habits like atypical swallowing, tongue ante-position and mouth breathing during childhood are more likely to this sagittal

discrepancy [4]. Among the developmental causes, individuals born with cleft lip and/or palate (CLP) may be more prone to develop skeletal Class III malocclusion due to the altered maxillary growth [5]. Finally, acromegaly is an acquired abnormality due to an excessive secretion of growth hormone that can lead to a symmetric bilateral prognathism [6].

There are several treatment approaches for Class III malocclusion depending on the severity of the deformity, the patient's age and the team habits; these treatments can be combined over time. Rapid palatal expansion and facemask protraction with tooth anchorage, as proposed by Delaire, have been recommended to correct the maxillary deficiency in prepubertal growth phase [7]. More recently, bone-anchored maxillary protraction (BAMP) methods using mini-plates have been developed to promote the maxillary advancement using facial mask or intermaxillary elastic tractions with a good efficacy [8]. Nevertheless, orthognathic surgery with advancement Le Fort I (LF1) osteotomy associated to a sagittal split osteotomy (SSO) for mandibular setback and angle closure are often needed after completion of growth to achieve a more balanced facial profile and functional bite.

In our Department of Maxillofacial Surgery, we have performed bilateral condylectomy for the treatment of Class III malocclusion with mandibular posterior vertical excess (PVE). To our knowledge, this technique has never been described, although it is part of the therapeutic arsenal in orthognathic surgery. We aim at presenting the surgical technique and indication for bilateral condylectomy in orthognathic surgery.

* Corresponding author at: Service de Chirurgie Maxillo-Faciale et Stomatologie, CHU de Nantes, 1 place Alexis Ricordeau, Nantes 44093, France.

E-mail address: helios.bertin@chu-nantes.fr (H. Bertin).

¹ Author deceased at the time of publication

2. Technical note

2.1. Indication

The bilateral condylectomy is proposed for individuals with posterior vertical excess (PVE) defined clinically by a trans-frontal profile with a closed nasolabial angle and an inversion of the labial relationship with an inferior lip and chin protrusion. Patients often suffers from a rough profile with low and marked mandibular angles (Fig. 1). Radiographically, the mandibular ramus and condyle appear elongated with mandibular angle projecting below the base of the odontoid process of C2. The occlusal plane is often horizontal, sometimes rotated counterclockwise, and mostly below the tangent with the occiput. Cephalometric analysis confirms the posterior mandibular origin of the deformation with a ramus longer than Delaire's F3 line and an angle that projects far below the theoretical gonion point (Fig. 1).

2.2. Surgical technique

The surgical procedure is the same as the proportional condylectomy usually performed to correct unilateral condyle hyperplasia [9], with two refinements:

- The amount of condyle resection is determined preoperatively on the cephalometric analysis; the vertical distance between the real and the theoretical mandibular angles give an estimation of the condylar resection needed to restore the facial architecture.
- The LF1 osteotomy is performed after mandibular surgery to place the maxilla on the mandible in its new position.

Briefly, a pre-auricular approach is performed to expose the submeniscal joint space (Fig. 1). The condylar resection is usually comprised between 8 and 15 mm, fully removing the cartilaginous cap with preservation of the articular disc. Perioperative adjustments in the condylar resection may be needed to improve dental occlusion. Particular attention is paid to verification of the centric occlusion, and to sufficient mandibular withdrawal, which requires further resection to allow the bone section to be in contact with the articular

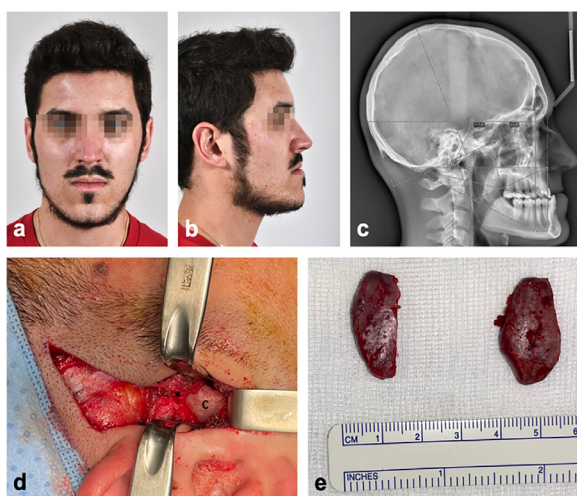


Fig. 1. Clinical and radiographic presentation of the posterior vertical excess. Frontal (a) and lateral (b) photographs showing the inferior vertical excess and the low position of the mandibular angles (case no 6). Lateral cephalograms with Delaire cephalometric analysis confirming the mandibular origin of the deformity with dolichoramy, lowered mandibular angles, and the low position of the pterygoid-occlusal point (Pto) with a horizontal occlusal plane. Surgical pre-auricular approach (d) of the mandibular condyle allowing exposure of the condyle (c) while retaining the articular disc (*). Bilateral symmetrical condyle resection (e).

disc. An early active functional rehabilitation is set up, consisting of lateral diduction and centered propulsion repeated several times a day, associated with intermaxillary fixation with elastics at night.

3. Discussion

The development of the mandibular ramus is mainly determined by the growth of the mandibular condyle. Thus, in condylar hyperplasia, both elongation and hemi-mandibular hyperplasia are observed, and the deformity may be vertical, transverse, or a combination of both according to the Delaire classification [10]. The deformity generally affects only one side of the mandible, but bilateral forms are possible. Mandibular prognathism due to excess of sagittal growth may be secondary to macroglossia, as commonly assessed in patients with Beckwith-Wiedeman or Down syndrome [11,12]. Finally, a combination of both condyle and mandibular sagittal overgrowth can be seen in patients with acromegaly [6]. The term "macro-mandible" has been proposed to characterize volume increase affecting the entire lower jaw in all three dimensions. The posterior vertical dimension is a cephalometric definition that corresponds to the height of the mandibular ramus in a sagittal plane. It directly influences the position, the level and the orientation of the occlusal plane. On Delaire's cephalometric analysis, the height of the mandibular ramus corresponds to the F3 line running from the posterior condylar point to the gonion point. The gonion angle normally projects onto the anteroinferior part of the cervical C2 vertebra. The cranio-vertebral junction then represents the main referential for the evaluation of the posterior mandibular balance as the development of the mandible and the spine are related. Nevertheless, the cervical spine can be the site of abnormalities affecting the interpretation of posterior mandibular height. The basilar impression and the occipitalization of the atlas are occasional deformities of the craniovertebral junction in which the cervical spine is displaced upwards; the mandibular angle appears falsely lower positioned. Thus, it appears important to appreciate the posterior vertical dimension on cephalometry analysis and to correlate it with the cervical spine in order to propose the best therapeutic management.

The bilateral condylectomy has become a technique of choice for the treatment of patients with PVE due to condyle hyperplasia or acromegaly, with good clinical outcomes (Figs. 2 and 3). The procedure has been performed in 13 patients in the past 40 years, which is very few compared with the 200 patients treated for orthognathic surgery at our center every year. In our opinion, the technique takes its advantages in the simple and simultaneous correction of protrusion and mandibular length, as well as the clockwise rotation of the

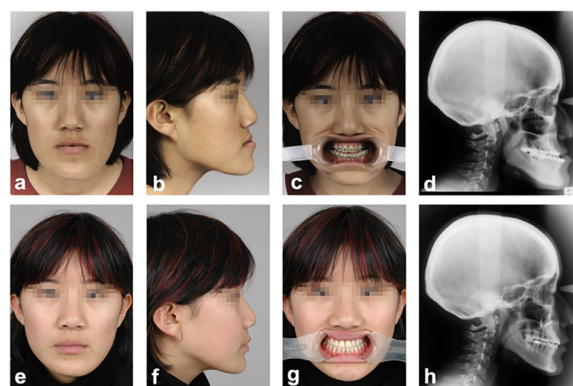


Fig. 2. Patient with non-specific mandibular posterior vertical excess treated with bilateral condylectomy with a concomitant LF1 osteotomy (case no 13). Frontal, lateral, and occlusal views, as well as the lateral cephalogram, in the preoperative period (a–d) and at one year after a bilateral condylectomy with an associated Le Fort I osteotomy (e–h).

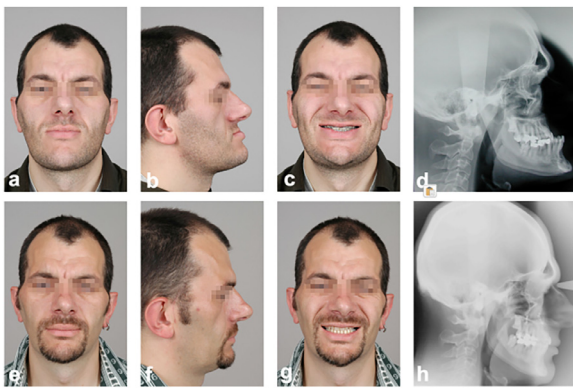

Fig. 3. Patient presenting with an acromegaly that caused PVE of the mandible with mandibular protrusion and Angle Class III malocclusion (case no 14). Frontal, lateral, and smile views, as well as a lateral cephalogram in the preoperative period (a–d) and at two years after a bilateral condylectomy with an associated LF1 osteotomy (e–h).

mandibular occlusal plane, which is often lowered. Nevertheless, condylectomy exposes to potential postoperative complications including facial nerve paresis, usually transient, and temporomandibular disorders [9]. On the other hand, no labiomental hypoesthesia is to be expected with this procedure, given that it can affect 27.8% of patients one year after BSSO [13]. The management of Class III dento-skeletal dysmorphism is a surgical challenge in terms of post-operative stability. Cephalometric studies have shown post-treatment instability and relapse in patients with an isolated mandibular setback surgery, making the 2-jaw surgery preferable for the correction of Class III dysmorphism [14]. According to Proffit et al. one of the key components is the correct positioning of the ramus and mandibular angle during mandibular setback [14]. According to the same author, the further back the ramus is positioned, the more the muscles will pull it back into its initial position, degrading the occlusal result [14]. In bilateral condylectomy, the ramus is shortened and no force pushing it backwards is applied, perhaps resulting in the stable results we observed after a mean 20-month follow-up. The mandibular angle returns to its normal position under the action of the pterygo-masseteric sling. This results in intense condylar remodeling, or even the formation of a neocondyle, as observed in condylectomy performed as part of the treatment of condylar hyperplasia [9]. Bone remodeling also occurs after conventional bimaxillary surgery in skeletal Class III patients, but to a much lesser extent [15]. Finally, a basilar bone resection could be needed for aesthetic purpose in patients with PVE after bimaxillary surgery, while this procedure is rarely useful in patients treated with condylectomy.

4. Conclusion

Bilateral condylectomy adds to the therapeutic arsenal for the surgical correction of Angle Class III malocclusion with vertical posterior excess of the mandible.

Declaration of competing interest

The authors declare that they have no known competing financial interests or personal relationships that could have appeared to

influence the work reported in this paper. The author is an Editorial Board Member/Editor-in-Chief/Associate Editor/Guest Editor for *Journal of Stomatology, oral and maxillofacial surgery* and was not involved in the editorial review or the decision to publish this article.

CRedit authorship contribution statement

Amaury Derquenne: Data curation, Formal analysis, Investigation, Writing – original draft. **Jacques Mercier:** Data curation, Formal analysis, Supervision. **Sophie Dugast:** Data curation, Formal analysis, Writing – original draft. **Pierre Corre:** Supervision, Writing – original draft, Writing – review & editing. **Hélios Bertin:** Data curation, Formal analysis, Supervision, Writing – original draft, Writing – review & editing.

References

- [1] Alhammedi MS, Halboub E, Fayed MS, Labib A, El-Saaidi C. Global distribution of malocclusion traits: a systematic review. *Dent Press J Orthod* 2018;23(6):40.e1–40.e10.
- [2] Bilgiç F, Gelgör İE. Prevalence of temporomandibular dysfunction and its association with malocclusion in children: an epidemiologic study. *J Clin Pediatr Dent* 2017;41(2):161–5.
- [3] Dehesa-Santos A, Iber-Díaz P, Iglesias-Linares A. Genetic factors contributing to skeletal class III malocclusion: a systematic review and meta-analysis. *Clin Oral Investig*. avr 2021;25(4):1587–612.
- [4] Rodríguez-Olivos LHG, Chacón-Uscamaita PR, Quinto-Argote AG, Pumahuallca G, Pérez-Vargas LF. Deleterious oral habits related to vertical, transverse and sagittal dental malocclusion in pediatric patients. *BMC Oral Health* 2022;22(1):88. 23 mars.
- [5] Mafféis J, Odri GA, Mercier JM, Loin J, Perrin JP, Joly A, et al. Stability of Le Fort 1 osteotomy in patients with bilateral cleft lip and palate: a retrospective study of 71 patients. *J Cranio Maxillofac Surg Off Publ Eur Assoc Cranio Maxillofac Surg* 2023;51(7–8):407–15.
- [6] De Stefani A, Dassie F, Wennberg A, Preo G, Muneratto A, Fabris R, et al. Oral manifestations and maxillo-facial features in the acromegalic patient: a literature review. *J Clin Med* 2022;11(4):1092. 18 févr.
- [7] Delaire J. Manufacture of the « orthopedic mask. *Rev Stomatol Chir Maxillofac* 1971;72(5):579–82.
- [8] De Clerck HJ, Cornelis MA, Cevidanes LH, Heymann GC, Tulloch CJF. Orthopedic traction of the maxilla with miniplates: a new perspective for treatment of mid-face deficiency. *J Oral Maxillofac Surg Off J Am Assoc Oral Maxillofac Surg* 2009;67(10):2123–9. oct.
- [9] Mouallem G, Vernex-Boukerma Z, Longis J, Perrin JP, Delaire J, Mercier JM, et al. Efficacy of proportional condylectomy in a treatment protocol for unilateral condylar hyperplasia: a review of 73 cases. *J Cranio Maxillofac Surg Juill* 2017;45(7):1083–93.
- [10] Delaire J, Gaillard A, Tulasne JF. [The place of condylectomy in the treatment of hypercondylosis]. *Rev Stomatol Chir Maxillofac* 1983;84(1):11–8.
- [11] Kawafuji A, Suda N, Ichikawa N, Kakara S, Suzuki T, Baba Y, et al. Systemic and maxillofacial characteristics of patients with Beckwith-Wiedemann syndrome not treated with glossectomy. *Am J Orthod Dentofac Orthop Off Publ Am Assoc Orthod Const Soc Am Board Orthod* 2011;139(4):517–25. avr.
- [12] Doriguëtto PVT, Carrada CF, Scalioni FAR, Abreu LG, Devito KL, Paiva SM, et al. Malocclusion in children and adolescents with down syndrome: a systematic review and meta-analysis. *Int J Paediatr Dent Juill* 2019;29(4):524–41.
- [13] Ow A, Cheung LK. Skeletal stability and complications of bilateral sagittal split osteotomies and mandibular distraction osteogenesis: an evidence-based review. *J Oral Maxillofac Surg Off J Am Assoc Oral Maxillofac Surg* 2009;67(11):2344–53. nov.
- [14] Proffit WR, Phillips C, Turvey TA. Stability after mandibular setback: mandible-only versus 2-jaw surgery. *J Oral Maxillofac Surg Off J Am Assoc Oral Maxillofac Surg Juill* 2012;70(7):e408–14.
- [15] Shi Y, Luo S, Wang H, Yao Q, Shi Y, Cheng J. Three-dimensional bone remodelling of glenoid fossa in patients with skeletal class III malocclusion after bimaxillary orthognathic surgery. *Int J Oral Maxillofac Surg févr* 2024;53(2):133–40.