



HAL
open science

Pathophysiology and management of enteric hyperoxaluria

Jordan Desenclos, Valentine Forté, Cécile Clément, Michel Daudon,
Emmanuel Letavernier

► **To cite this version:**

Jordan Desenclos, Valentine Forté, Cécile Clément, Michel Daudon, Emmanuel Letavernier. Pathophysiology and management of enteric hyperoxaluria. *Clinics and Research in Hepatology and Gastroenterology*, 2024, 48 (5), pp.102322. 10.1016/j.clinre.2024.102322 . hal-04589878

HAL Id: hal-04589878

<https://hal.science/hal-04589878v1>


Submitted on 18 Jun 2024

HAL is a multi-disciplinary open access archive for the deposit and dissemination of scientific research documents, whether they are published or not. The documents may come from teaching and research institutions in France or abroad, or from public or private research centers.

L'archive ouverte pluridisciplinaire **HAL**, est destinée au dépôt et à la diffusion de documents scientifiques de niveau recherche, publiés ou non, émanant des établissements d'enseignement et de recherche français ou étrangers, des laboratoires publics ou privés.



Distributed under a Creative Commons Attribution 4.0 International License



Review

Pathophysiology and management of enteric hyperoxaluria

Jordan Desenclos^a, Valentine Forté^a, Cécile Clément^a, Michel Daudon^{a,b},
Emmanuel Letavernier^{a,b,c,*}

^a Explorations Fonctionnelles Multidisciplinaires, AP-HP, Hôpital Tenon, 4 rue de la Chine, Paris F-75020, France

^b INSERM, UMR S 1155, Paris F-75020, France

^c Sorbonne Université, UMR S 1155, Paris F-75020, France



ARTICLE INFO

Keywords:

Oxalate
Kidney
Gut
Enteric hyperoxaluria
Microbiota
Calcium

ABSTRACT

Enteric hyperoxaluria is a metabolic disorder resulting from conditions associated with fatty acid malabsorption and characterized by an increased urinary output of oxalate. Oxalate is excessively absorbed in the gut and then excreted in urine where it forms calcium oxalate crystals, inducing kidney stones formation and crystalline nephropathies. Enteric hyperoxaluria is probably underdiagnosed and may silently damage kidney function of patients affected by bowel diseases. Moreover, the prevalence of enteric hyperoxaluria has increased because of the development of bariatric surgical procedures. Therapeutic options are based on the treatment of the underlying disease, limitation of oxalate intakes, increase in calcium salts intakes but also increase in urine volume and correction of hypocitraturia. There are few data regarding the natural evolution of kidney stone events and chronic kidney disease in these patients, and there is a need for new treatments limiting kidney injury by calcium oxalate crystallization.

Introduction

Oxalate is a small dicarboxylic acid dianion found in large quantities in various plants, fruits and seeds and is considered as a metabolic end-product in the human body [1–4]. Dietary oxalate is partly absorbed in the intestinal tract but oxalate may also result from liver metabolism. Eventually, oxalate absorbed by intestine and produced by liver is excreted in urine by kidney filtration and secretion.

Oxalate has a high affinity for calcium ions. In the intestinal tract, dietary calcium binds oxalate, limiting its absorption by the intestinal mucosa. In the urine, a mild increase in oxalate concentration may result in the formation of calcium oxalate crystals.

Enteric hyperoxaluria (EH) is a metabolic disorder characterized by an increased output of oxalate in urine, primarily due to an increased absorption of dietary oxalate in the colon. This increased absorption is the consequence of a malabsorption syndrome, that may result from bowel diseases, typically Crohn's disease complicated by ileal resection or short bowel syndrome, but also from pancreatic exocrine insufficiency or bariatric surgery. In these conditions, fatty acid are not reabsorbed by small intestine and bind to massive amounts of dietary calcium in colon. A large part of dietary oxalate is no longer bound to calcium, leading to an increased absorption of oxalate available in the

colon (Fig. 1).

This oxalate excessive load in the systemic circulation is then filtered and secreted by kidneys, resulting in hyperoxaluria. Hyperoxaluria may lead to recurrent kidney stone formation but also acute and chronic kidney injury due to calcium oxalate crystalline nephropathy.

The diagnosis of EH is frequently delayed in the absence of specific symptoms preceding complications, e.g. kidney stones and kidney failure. Laboratory tests including oxalate assays, crystalluria, stone analysis and in some cases kidney biopsies are essential for diagnosis.

The treatment of EH aims to reduce dietary oxalate absorption, in order to prevent kidney stone formation and kidney injury. This strategy includes dietary modifications, such as limiting the intake of oxalate-rich foods and taking oxalate-binders. In addition, increasing urine volume and calcification inhibitors concentration in urine, especially citrate, may decrease calcium oxalate supersaturation and prevent kidney lesions. However, these therapeutic approaches are frequently insufficient to prevent kidney complications.

The purpose of this review is to provide an overview of the pathophysiology and management of EH and to discuss current research in this field.

* Corresponding author.

E-mail address: emmanuel.letavernier@aphp.fr (E. Letavernier).

<https://doi.org/10.1016/j.clinre.2024.102322>

Pathophysiology

Oxalate absorption, synthesis and excretion

Oxalate plays a vital role in the metabolism of many plants, fungi, and bacteria[1]. In humans, oxalate has no identified function and is considered as an end-product.

Oxalate in the human body comes from two main sources: food and endogenous production by liver[2].

Dietary sources rich in oxalate include various vegetables (e.g. spinach, sorrel, chards, beets, rhubarb, star fruit), nuts (almonds, peanuts, sesame seeds), chocolate (cocoa), spices (turmeric).. [3].. Only a part of the dietary oxalate is directly absorbed by the small intestine[4]. A significant amount of oxalate is absorbed in the colon. Actually, in malabsorption conditions, only patients with intact colon have a significant increase in urine oxalate excretion[5]. Experimental murine models evidenced that net intestinal absorption of dietary oxalate results from passive paracellular oxalate absorption, but also from oxalate back secretion mediated by oxalate transporters. Some transporters may also participate in active intestinal absorption of oxalate[6,7].

The liver can produce oxalate from precursors such as, glycolate and glyoxylate in the peroxisomes but also from other precursors, especially hydroxyproline which derives from the breakdown of proteins, including collagen fibers[8,9]. Unlike many other metabolites, oxalate is not eliminated by the liver but exported to the systemic circulation and excreted in urine by the kidney. Primary hyperoxaluria includes a group of rare and severe hereditary metabolic diseases characterized by excessive oxalate production by the liver. These diseases are related to specific genetic mutations altering hepatic glyoxylate metabolism,

increasing oxalate production and threatening renal function but stand beyond the scope of this review[10].

In addition, the breakdown of ascorbic acid results in oxalate formation through non-enzymatic reactions, but its contribution to global oxalate synthesis in the absence of massive vitamin C intakes is probably moderate[11].

Both oxalate absorbed in gut and produced by metabolism are eliminated by kidney filtration but also by tubular secretion, involving anion transporters[12].

Determinants of intestinal oxalate absorption

Role of divalent cations in oxalate absorption

Calcium and magnesium may bind oxalate, limiting its absorption by the gut. Actually, the amount of calcium in food intakes has a dramatic impact on oxalate intestinal absorption[13]. Epidemiological studies have shown a “counterintuitive” negative correlation between calcium dietary intakes and the risk to develop kidney stones[14]. The most likely hypothesis is that dietary calcium chelates oxalate, limiting its absorption, and therefore its excretion in urine, resulting in a decreased risk to form calcium oxalate crystals and stone formation (Fig. 1).

Role of bile acids and fatty acids in oxalate absorption

Bile acids play a crucial role in the emulsification and absorption of dietary cholesterol, triglycerides and fatty acids. Under normal conditions, most of fatty acids and bile salt are absorbed in small intestine, especially ileon. There is therefore a limited amount of fatty acids present in the large intestine while an important proportion of dietary oxalate is present as calcium-oxalate complexes.

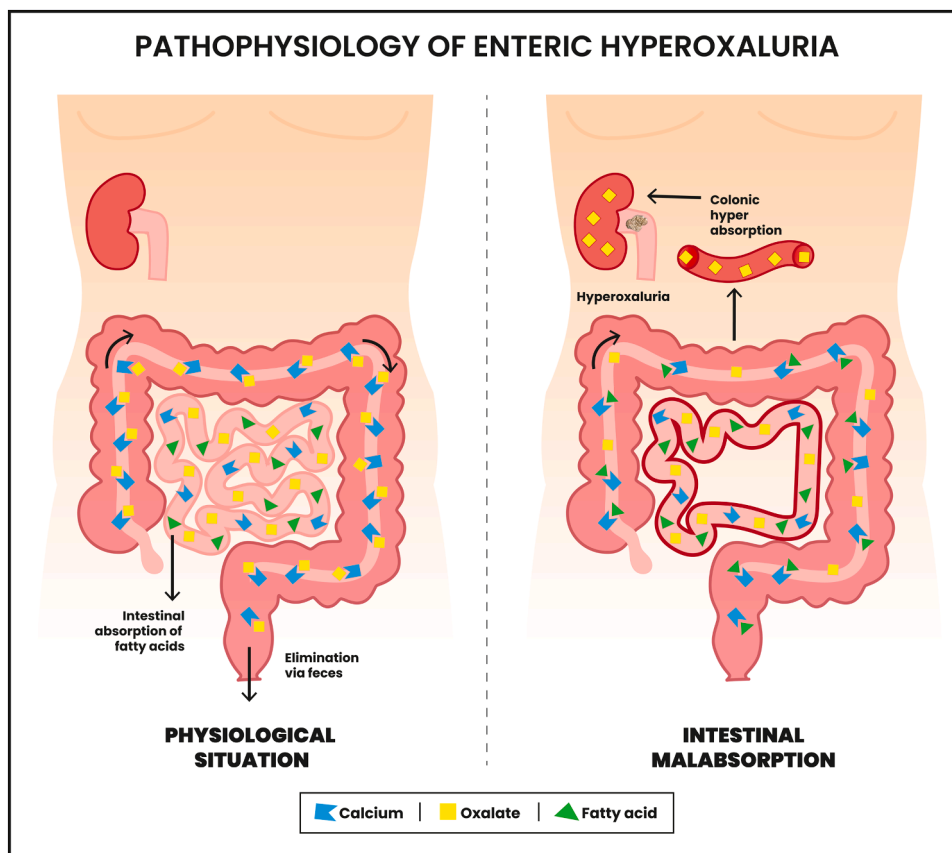


Fig. 1. Main mechanism of EH Under physiological conditions (left panel), oxalate absorption is limited as calcium oxalate complexes are not absorbed in colon. Under malabsorption states, for instance short bowel syndrome or other diseases inducing malabsorption (right panel), the presence of fatty acids in the colon leads to calcium chelation (saponification). Oxalate is no longer bound to calcium and may be absorbed by the colon, resulting in hyperoxaluria.

In malabsorption conditions, this balance is disrupted. The presence of large amounts of fatty acids in the intestinal lumen promotes the formation of calcium salts in colon (saponification). Oxalate is therefore “free” and absorbed through mucosa. Additionally, bile salts and fatty acids can damage the colonic epithelium, promoting inflammation and increasing permeability to oxalate[15].

Role of the gut microbiota

Some commensal bacteria, like *Oxalobacter formigenes*, use oxalate as a carbon source[16]. Many studies focused on the potential of *O. formigenes* to degrade dietary oxalate. Actually, it was shown that intestinal colonization with *O. formigenes* was associated with a reduction in the risk for being a recurrent calcium oxalate stone former[17]. Nowadays, other bacteria including *Lactobacillus* spp. have been shown to degrade oxalate and it seems that multi-species bacterial network ensures healthy oxalate homeostasis[18].

In addition, *O. formigenes* and potentially other bacteria may not only degrade oxalate but also promote its intestinal secretion through transporters, potentially influencing the net amount of oxalate absorbed in the intestine and excreted in the urine[19–21].

It has been suggested that alteration of microbiota by antibiotics would result in a lower intestinal degradation of oxalate by *O. formigenes*, *Lactobacillus* spp or *Bifidobacterium* spp, increasing the risk of kidney stones[22]. However, a recent study suggests that the apparently increased risk of kidney stones after antibiotic therapy may be due to a methodological bias[23].

Role of intestinal oxalate transporters

Several oxalate transporters have been identified in the human intestine, including colon where most of oxalate is absorbed in malabsorption conditions. Most of studies were performed in murine models and their clinical relevance needs to be confirmed in human pathology.

The *SLC26A6* gene encodes a chloride-oxalate exchanger involved in the secretion of dietary oxalate toward the gut lumen[24]. Jiang et al. demonstrated that mice knockout for the *SLC26A6* gene exhibit a defect in intestinal oxalate secretion, resulting in a significant increase in urine oxalate excretion and the development of calcium oxalate nephrolithiasis[25]. Cornière et al. reported recently a family in which a rare heterozygous missense mutation in the *SLC26A6* gene was associated with hyperoxaluria and calcium oxalate urolithiasis[26]. This observation may be the first description of a “genetic” EH in humans and needs to be confirmed by further cases.

Similarly, some mice knockout for the *SLC26A1* gene develop hyperoxalemia and hyperoxaluria, but the role of *SLC26A1* in oxalate homeostasis is very controversial[27–31].

SLC26A3 gene encodes for an anion exchanger of chloride, bicarbonate and oxalate (DRA), implicated in the transcellular absorption of intestinal oxalate. Mice lacking *SLC26A3* show a decrease in oxaluria[32]. Cil et al. discovered that selective inhibitors of DRA were effective in reducing intestinal oxalate absorption, preventing calcium oxalate deposition and renal lesions in animal models of hyperoxaluria[33]. However, a significant role of DRA in intestinal absorption of oxalate in humans has not been shown.

The potential impact of microbiota, bile salts, or fatty acids on these intestinal oxalate transporters is still misunderstood.

Other risk factors for calcium oxalate supersaturation in EH

Low diuresis due to diarrhea

In addition to increased oxalate output, diseases inducing EH are frequently associated with diarrhea and massive water losses limiting diuresis, as typically observed in short bowel syndrome (SBS). This low urine volume increases oxalate and calcium concentration, and therefore calcium oxalate supersaturation[34]. The gastrectomy performed during bariatric surgeries is also a factor limiting water intake and thereby diuresis.

Hypocitraturia and calcification inhibitors deficiency

Citrate is an important inhibitor of calcium oxalate crystallization in urine. Loss of bicarbonate in intestinal diseases may result in metabolic acidosis, limiting citrate excretion in urine and increasing calcium oxalate supersaturation[35]. To a lesser extent, intestinal magnesium loss results in hypomagnesuria, promoting calcium oxalate crystallization.

Diseases causative for EH

EH may result from intestinal or pancreatic diseases causative for fatty acid malabsorption, including Crohn’s disease affecting ileon or complicated by ileal resection, or celiac disease. SBS, especially type II (jejunoileocolic anastomosis with ileal resection and at least partly preserved colon) is associated with severe malabsorption and EH[36]. Patients with SBS type III (jejunoileotransversostomy with jejunal resection and at least 10 cm of terminal ileum and colon retained) have less severe symptoms but are also at risk to form stones.

Chronic pancreatitis and chronic biliary diseases are also classic causes of malabsorption resulting in EH[37]. The diagnosis of EH may be delayed in these conditions if pancreatic exocrine insufficiency has not been identified previously. Of note, the increasing use of GLP1 agonists is associated with an increased risk of pancreatitis and potential exocrine pancreatic deficiency in individuals. Special attention should be paid to diabetic patients who are more at risk to develop chronic kidney disease (CKD)[38]. In the same vein, the use of orlistat has been associated with cases of acute kidney injury possibly due to an increased malabsorption resulting from the inhibition of pancreatic and intestinal lipase by orlistat[39].

Alongside these diseases, a growing cause of EH is the development of surgical procedures for weight loss. The Roux-en-Y gastric bypass (RYGB) and biliopancreatic diversion surgery are associated with hyperoxaluria, increased risk to form kidney stones and calcium oxalate nephropathy, especially after biliopancreatic diversion surgery. By contrast, restrictive surgery (sleeve gastrectomy) does not increase urine oxalate excretion and kidney stones risk or progression of CKD[40].

The massive development of these procedures during the past decades, even if restrictive surgery is more frequently used, exposes a large population to the risk of nephrolithiasis and CKD.

Clinical consequences of EH

Under standard conditions, the amount of oxalate absorbed by intestine is usually moderate and its production by the liver remains limited, resulting in a normal urine oxalate excretion, e.g. <0.45 mmol/day. In patients affected by EH, the massive oxalate load entering the systemic circulation is filtered and secreted by kidneys, increasing urine oxalate excretion, e.g. 0.5–0.8 mmol/day or more[41]. Even a mild increase in urine oxalate output is sufficient to induce calcium oxalate supersaturation and crystals formation in urine. Moreover, the decrease in urine volume due to diarrhea and hypocitraturia also increase calcium oxalate supersaturation. The high oxalate/calcium ratio resulting from EH drives the formation of calcium oxalate monohydrate (COM or whewellite) crystals rather than calcium oxalate dihydrate (COD or weddellite) crystals[42–46].

The repeated crystallization and aggregation of COM in urine may lead to the recurrent formation of calcium oxalate stones, frequently made exclusively of COM and presenting with specific features (see next chapter). In patients undergoing Roux-en-Y bypass or “malabsorptive” surgeries, both surgical procedures were associated with increased risk of stones[40]. Kidney stones may induce a renal colic if they pass in the urinary tract, potentially aggravated by complications: ureteral hydro-nephrosis, rupture of the fornix, hematuria, impairment of renal function, infection.. [47].

Unlike “idiopathic” calcium oxalate stones which generally pose no threat to kidney function, EH is a condition characterized by a frequent onset and progression of CKD. Of note, the most common causes of

oxalate nephropathy are chronic pancreatitis and gastric bypass (48 %) [48]. Few series evaluated renal function in these patients, probably a consequence of the heterogeneous conditions associated with EH. The most complete data come from observations performed after bypass surgical procedures[40]. The risk of CKD increases significantly after malabsorptive procedures.

The precipitation of calcium oxalate crystals in tubules causes acute kidney injury, probably due to intratubular obstruction and tubular cell lesions but also to an afflux of pro-inflammatory cells and the development of granuloma. Actually, crystalline plugs in the distal tubules or collecting ducts induce the activation of inflammasomes, especially NLRP3-related innate immunity pathways and eventually promote interstitial fibrosis and progression of CKD[49–53].

It may be hypothesized that acute episodes of diarrhea and decreased diuresis may lead to repeated acute kidney injury (AKI) and ultimately promote the progression of CKD. Actually, diagnosis of EH in some individuals is performed after the onset of an AKI due to calcium oxalate crystals precipitation.

At last, as recently evidenced, patients affected by EH and advanced CKD may have increased circulating oxalate levels[54]. Further studies are required to assess whether accumulation of oxalate in these patients may have an impact on cardiovascular outcomes or increase the risk of bone fracture.

Diagnosis of EH

The clinical context is often highly suggestive when a patient with kidney stones also presents with a condition affecting intestinal function. The diagnosis may be less evident if undiagnosed malabsorption state exists, for instance exocrine pancreatic insufficiency, or in the absence of renal colic.

Four biological tests are particularly helpful to diagnose EH:

1. Increased urine oxalate excretion
2. The presence of COM crystals in urine, a specific feature of hyperoxaluria
3. Kidney stones made exclusively of COM with a specific morphology (type Ie)
4. The presence of COM crystals in renal tubules if a biopsy is performed

CT-scan may be of help to discriminate uric acid stones (density 400–800 Hounsfield units) from COM stones (density 1200–1700 Hounsfield units)[40]. However, CT-scan will not address the original mechanism of COM stones formation. Moreover, small stones (≤ 6 –8 mm) density may be dramatically underestimated by CT-scans.

Increased urine oxalate output

Consensus Groups recommend to perform oxalate dosage in routine screenings[55]. In patients potentially affected by EH, this test is critical. Actually, patient affected by EH have frequently a high urine oxalate output (frequently ≥ 0.8 mmol/24 h), much higher than urine oxalate excretion observed in idiopathic calcium oxalate stone formers. Urine oxalate excretion >0.3 mmol/L or >0.45 mmol/day is associated with an increased lithogenic risk.

A comprehensive blood and urine analysis should be conducted as a first-line investigation for every patient with kidney stones, starting from the first episode[55]. The objective is to identify lithogenic risk factors and customize management to prevent recurrence. Considering the high risk of CKD and stone formation, an option is to propose the same tests to patients potentially affected by EH, even in the absence of past medical history of kidney stones. These tests include a 24-hr urine collection to assess diuresis, and creatinine excretion is quantified to validate urine collection. A complete collection is indicated by creatinine excretion within the range of 193 ± 41 $\mu\text{mol/kg/day}$ for men and

151 ± 38 $\mu\text{mol/kg/day}$ for women[56,57]. In addition, urine calcium excretion is quantified as well as urine citrate output.

The oxalate assay on a 24-hour urinary collection is pivotal for diagnosis and demands careful attention to pre-analytical conditions. Urine should be stored in a cool place and the use of a preservative is mandatory to assess urine citrate, as bacterial proliferation may decrease citrate in containers. Before analysis, the urine should be homogenized for solution uniformity and acidified with concentrated hydrochloric acid (about 1 % of the total volume to achieve a pH around 2) to dissolve calcium oxalate crystals[58]. The absence of appropriate preanalytical procedure may misdiagnose hyperoxaluria. Oxalate assay should be repeated in optimal conditions if urine oxalate excretion is lower as expected, especially in stone formers or if crystalluria evidences COM crystals.

Ion chromatography is a reference method frequently used for urinary oxalate measurement[59]. Enzyme-based methods employing oxalate oxidase are also used since decades and liquid chromatography coupled with mass spectrometry (LC-MS or LC-MS/MS) is a promising method[60,61].

Crystalluria positive for COM crystals

Crystalluria serves as an early indicator of urine supersaturation, manifesting prior to stone formation. Consequently, it holds significant diagnostic value, particularly when stone analysis is inaccessible[62, 63].

Investigating crystalluria is warranted when EH is under suspicion. The mere presence of COM crystals is pathognomonic for hyperoxaluria [43].

Crucial attention must be given to pre-analytical conditions when examining crystalluria. Ideally, this investigation should be conducted using the first morning urine. Moreover, the specimen should be promptly delivered to the laboratory within 2 to 3 h and maintained at room temperature[64].

The most typical form of COM presents as an oval structure measuring 8 to 12 μm , characterized by a central depression and bulges on the sides, leading to polarization inhomogeneity (Fig. 2A-C). In some cases, COM can also take on an hourglass appearance (Fig. 2D)

When present in a very significant quantity ($> 200/\text{mm}^3$), the presence of COM crystals indicates major hyperoxaluria, suggesting an enteric or genetic origin (Fig. 2E). Conversely, smaller amounts are more suggestive of a dietary origin[65].

In exceptional cases, caoxite crystalluria may be observed, corresponding to calcium oxalate trihydrate (COT). These hexagonal crystals exhibit thick, regular edges, signaling major hyperoxaluria coupled with a macromolecular inhibition issue (Fig. 2F).

Crystalluria is not only valuable for diagnosis but also proves highly effective for patient monitoring. Daudon's research demonstrated that when over 50 % of urine samples exhibit crystal positivity, the risk of recurrent stone formation surpasses 90 % [66].

Morphoconstitutional stone analysis

Many calcium oxalate stones are a mix of COM and COD, and also frequently contain small amounts of calcium phosphates. The exclusive presence of COM in a stone according to physical analyzes (most frequently Fourier Transform Infrared Spectroscopy) suggests that hyperoxaluria is the predominant risk factor of stone formation.

In addition to stone composition, stone morphology provides critical informations. EH is classically characterized by a specific appearance of stones, identified as type Ie according to Daudon's classification (Fig. 3B). This subtype is an intermediate between type Ia (common stones) and type Ic (genetic hyperoxaluria) (Fig. 3A,C)[64].




Fig. 2. Various types of calcium oxalate monohydrate (COM) crystals

- A. Typical COM crystals with a characteristic oval center, depressed edge (black arrows), not to be confused with calcium oxalate dihydrate (COD) crystals which are formed by two flattened pyramids joined together at their bases (black star)
- B. Typical COM crystals with a peanut-like profile view
- C. COM crystals under polarized light, showing polarization inhomogeneity with a darker central zone.
- D. COM crystal with a “hourglass” shape
- E. High number of COM crystals forming aggregates, suggestive for massive hyperoxaluria resulting from enteric or genetic conditions.
- F. Calcium oxalate trihydrate (caoxite) crystal.



Fig. 3. Calcium oxalate monohydrate (COM) stones related with EH

- A. Type Ia stone. This is the most common COM stone type, with a mammillary surface and a section made of concentric and compact layers with a radiating organization. Urine oxalate excretion is usually normal or mildly increased.
- B. Type Ie stones according to Michel Daudon’s classification are exclusively made of COM. These stones are typically observed in EH patients and result from massive hyperoxaluria. They have a granular and budding surface with confluent grains giving it a compact appearance. The color is usually light brown-yellow. The section is disorganized and loose and locally more compact with a radiating section. The aspect is an intermediate between “Ia” common COM stones and “Ic” COM stones due to primary hyperoxaluria.
- C. Type Ic stone. This type of stone is rare and pathognomonic for primary hyperoxaluria. These stones have a budding surface and a light color, cream to pale and sometimes whitish, and a poorly organized and pale section due to a rapid growth in a highly supersaturated milieu.

Calcium oxalate crystalline nephropathy

The onset of AKI or CKD from unknown origin may lead to a kidney biopsy showing calcium oxalate nephropathy (Fig. 4A-C). This crystalline nephropathy is characterized by the presence of strongly birefringent calcium oxalate crystal deposits under polarized light within tubular lumens. This is often accompanied by lesions of tubulointerstitial nephritis[67]. FTIR imaging analysis can confirm that these

crystals are actually made of COM (Fig. 4D)[68].

COM crystalline nephropathy may also be observed after intoxications (e.g. ethylene glycol[69], hair-straightening procedures with products containing glyoxylic acid[70]) or in primary hyperoxaluria.

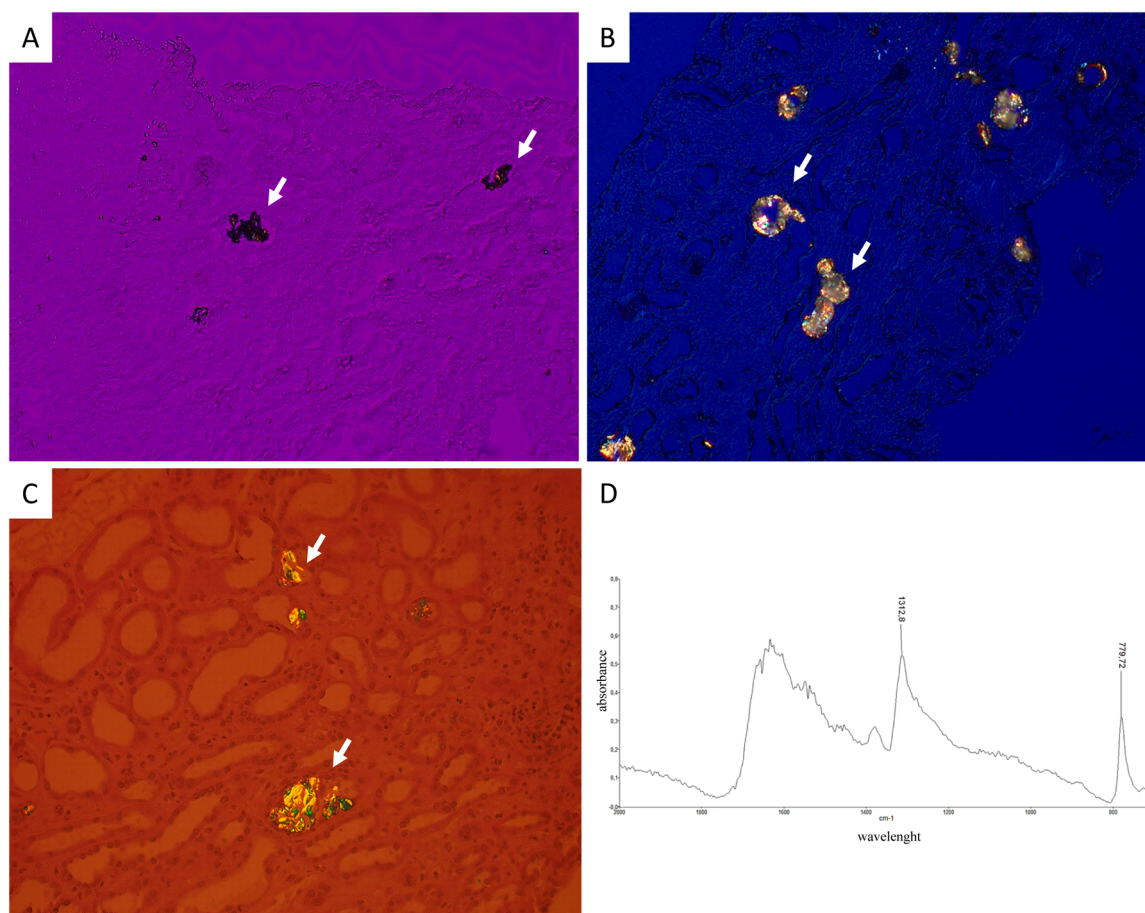


Fig. 4. Calcium oxalate crystalline nephropathy

A. Typical aspect of calcium oxalate monohydrate (COM) crystallites (white arrows) observed in a kidney biopsy, conventional light microscopy
 B,C: Typical aspect of COM crystallites (white arrows) observed in a kidney biopsy, polarized light microscopy
 D. Typical spectrum showing the presence of COM crystals evidenced by FTIR imaging in a kidney biopsy.

Management

Control of the underlying disease

In individuals with calcium oxalate nephropathy following-Roux-en-Y gastric bypass, Agrawal et al. demonstrated that reversing the bypass significantly reduced oxaluria, accompanied by improved renal function [71]. However, this is an extreme measure that cannot be proposed to patients in routine practice. A better risk assessment should be carried out in candidates for a gastric bypass at risk to develop calcium oxalate nephropathy, especially kidney stone formers, and restrictive procedures are probably more appropriate in many cases.

In patients affected by pancreatic exocrine insufficiency, the administration of pancreatic enzyme may decrease malabsorption and should in theory reduce the risk to develop hyperoxaluria but there is few evidence demonstrating this effect [72].

In patients affected by celiac disease, a gluten free diet improves urine oxalate excretion significantly [73].

Dietary measures

Dietary measures are essential for EH management [74]. Initial recommendations include hyperhydration to sustain optimal diuresis (target ≥ 2 liters/day), acknowledging potential limitations imposed by patients' digestive tolerance and the risk of exacerbating diarrhea. Twenty-four urine collections are helpful to assess whether hydration is sufficient. The objective is to reduce oxaluria below 0.3 mmol/L,

representing the crystalline risk threshold. Additionally, a reduction in oxalate intake coupled with increased calcium consumption is advised.

Studies indicate that diminishing dietary oxalate intake correlates with a reduction in urinary oxalate excretion. However, in severe hyperoxaluria cases, the impact on oxaluria may be modest, prompting individuals to restrict intake of otherwise healthy foods [75–78]. Thorough dietary assessment is crucial to identify classic sources of oxalate: nuts, vegetables... In addition, indirect sources are not widely recognized e.g. hydroxyproline-rich gelatinous candies or vitamin C supplements [9,79,80].

Urinary oxalate excretion in EH also correlates directly with the fat content of stool, and limiting fat intake has been shown to reduce urinary oxalate but may lead to malnutrition [59,60]. A low-fat diet also improves steatorrhea, leading to less fecal fluid loss, which further diminishes the risk of stone formation.

Chelating dietary oxalate by incorporating dairy products during meals (or mineralized water) is proposed as a strategy to lower oxaluria [81–83].

Oxalate chelators

In addition to dairy products, calcium medications should be provided during each meal, usually calcium carbonate providing 500 mg-1000 mg of elemental calcium. Monitoring urinary calcium is necessary, though the risk of hypercalciuria in patients with intestinal malabsorption is minimal. Calcium citrate, exhibiting pharmacodynamic superiority over calcium carbonate, would be an alternative,

especially in cases of secondary hyperparathyroidism due to intestinal calcium malabsorption[84]. Calcium citrate may also correct hypocalcemia secondary to acidosis induced by bicarbonate intestinal loss.

Non-calcic chelators have been proposed, such as sevelamer and fosephol, which are classically used as phosphate binders[85,86]. Their efficiency is controversial and these drugs may induce hypophosphatemia, limiting their use in clinical practice in patients affected by malabsorption.

Citrate and alkaline therapies

Considering the low urine citrate excretion observed in patients affected by EH, the administration of oral citrate or bicarbonate seems a reasonable option to reduce urine calcium oxalate supersaturation but the effect of alkali on calcium oxalate supersaturation seems limited[84, 87].

Bile acid sequestrants

Cholestyramine, a bile acid sequestrant, has no significant impact on oxalate intestinal absorption in patients affected by EH[88,89].

Oxalate decarboxylase

Oxalate decarboxylase, catalyzing the conversion of oxalate into carbon dioxide and formate in gut, emerges as a potential intervention for hyperoxaluria. The treatment reloxalase (recombinant oxalate decarboxylase from *Bacillus subtilis*) significantly reduced oxaluria compared to placebo early studies[90]. Quintero et al. observed a 23.87 % reduction in 24-hour oxalate excretion with oxalate decarboxylase (Recombinant oxalate decarboxylase from *Synechococcus elongates*) compared to placebo[91]. A pilot study by Pfau et al. demonstrated that reloxalase administration led to a significant reduction in oxalemia and oxaluria[92].

URIROX-1, a double-blind, placebo-controlled randomized trial, showed a reduction in oxalate excretion after 4 weeks of reloxalase treatment in EH patients[93]. The long-term phase 3 randomized trial URIROX-2 terminated earlier than expected and intermediate results have not been published yet (NCT03847090).

Modification of intestinal microbiota

The intestinal microbiota plays an important role in oxalate metabolism. *O. formigenes*, by degrading dietary oxalate and stimulating intestinal oxalate secretion, leads to a decrease in urinary oxalate output [20,94]. Verhulst et al. showed that administration of *O. formigenes* to ethylene glycol-intoxicated rats reduced oxalemia and the risk of nephrocalcinosis, but had no effect on oxaluria[95]. A phase I/II clinical trial did not evidence an effect of *O. formigenes* administration in primary hyperoxaluria[96]. There is no evidence to date that administration of *O. formigenes* in EH would reduce urine oxalate excretion in humans.

SYNB8802, a modified probiotic derived from *Escherichia coli* Nissle, effectively reduced urinary oxalate excretion in murine and primate models of hyperoxaluria by metabolizing oxalate into formate in the gastrointestinal tract[97].

Conclusion

The pathophysiology of EH encompasses multiple factors, including dietary oxalate intake, hepatic and intestinal metabolism, bile acid interactions, gut microbiota, calcium intakes and the role of specific transporters in the intestine. The natural history of EH is still poorly understood, and requires patient registries and long-term follow-up studies.

The assessment of 24-hr urine oxalate excretion, crystalluria, stone

analysis and in some cases kidney biopsy are essential and cost-effective tools providing a nuanced understanding of the patient's lithogenic risk and aid in tailoring a precise management strategy. The collaboration between experts, especially gastroenterologists, dietitians, nephrologists, and urologists is essential to provide adapted care to EH patients.

Management of EH remains multifaceted, focusing on dietary measures, controlling the underlying disease, and potential interventions targeting oxalate metabolism. The emerging treatments, such as oxalate decarboxylase and modulation of the intestinal microbiota, hold promise for refining therapeutic approaches in the future.

CRedit authorship contribution statement

Jordan Desenclos: Writing – review & editing, Writing – original draft, Methodology, Conceptualization. **Valentine Forté:** Writing – review & editing, Writing – original draft. **Cécile Clément:** Writing – review & editing, Writing – original draft. **Michel Audon:** Writing – review & editing, Writing – original draft. **Emmanuel Letavernier:** Writing – review & editing, Writing – original draft, Supervision, Methodology, Conceptualization.

Declaration of competing interest

The authors declare the following financial interests/personal relationships which may be considered as potential competing interests:

EL and MD filed a patent relative to the use of Stiripentol against primary hyperoxaluria (WO2017140658A1). The authors declare no competing interest regarding this review.

References

- [1] Nakata PA. Advances in our understanding of calcium oxalate crystal formation and function in plants. *Plant Sci* 2003;164(6):901–9.
- [2] Crivelli JJ, Mitchell T, Knight J, Wood KD, Assimos DG, Holmes RP, et al. Contribution of Dietary Oxalate and Oxalate Precursors to Urinary Oxalate Excretion. *Nutrients* 2020;13(1):62.
- [3] Attalla K, De S, Monga M. Oxalate content of food: a tangled web. *Urology* 2014;84(3):555–60.
- [4] Mitchell T, Kumar P, Reddy T, Wood KD, Knight J, Assimos DG, et al. Dietary oxalate and kidney stone formation. *Am J Physiol - Ren Physiol* 2019;316(3):F409–13.
- [5] Modigliani R, Labayle D, Aymes C, Denvil R. Evidence for excessive absorption of oxalate by the colon in enteric hyperoxaluria. *Scand J Gastroenterol* 1978;13(2):187–92.
- [6] Hatch M, Freel RW. The roles and mechanisms of intestinal oxalate transport in oxalate homeostasis. *Semin Nephrol* 2008;28(2):143–51.
- [7] Whittamore JM, Hatch M. Oxalate flux across the intestine: contributions from membrane transporters. *Compr Physiol* 2021;12(1):2835–75.
- [8] Ogawa Y, Miyazato T, Morozumi M, Sugaya K, Hatano T. Urinary oxalate, glycolate, glyoxylate, and citrate after acute intravenous administration of glyoxylate in rats. *Mol Urol* 2000;4(4):341–8.
- [9] Fargue S, Milliner DS, Knight J, Olson JB, Lowther WT, Holmes RP. Hydroxyproline metabolism and oxalate synthesis in primary hyperoxaluria. *J Am Soc Nephrol JASN* 2018;29(6):1615–23.
- [10] Xie X, Zhang X. Primary hyperoxaluria. *N Engl J Med* 2022;386(10):976.
- [11] Knight J, Madduma-Liyanaage K, Mobley JA, Assimos DG, Holmes RP. Ascorbic acid intake and oxalate synthesis. *Urolithiasis* 2016;44(4):289–97.
- [12] Weinman EJ, Frankfurt SJ, Ince A, Sansom S. Renal tubular transport of organic acids. Studies with oxalate and para-aminohippurate in the rat. *J Clin Invest* 1978; 61(3):801–6.
- [13] von Unruh GE, Voss S, Sauerbruch T, Hesse A. Dependence of oxalate absorption on the daily calcium intake. *J Am Soc Nephrol JASN* 2004;15(6):1567–73.
- [14] Taylor EN, Curhan GC. Dietary calcium from dairy and nondairy sources, and risk of symptomatic kidney stones. *J Urol* 2013;190(4):1255–9.
- [15] Dobbins JW, Binder HJ. Effect of bile salts and fatty acids on the colonic absorption of oxalate. *Gastroenterology* 1976;70(6):1096–100.
- [16] Stewart CS, Duncan SH, Cave DR. Oxalobacter formigenes and its role in oxalate metabolism in the human gut. *FEMS Microbiol Lett* 2004;230(1):1–7.
- [17] Kaufman DW, Kelly JP, Curhan GC, Anderson TE, Dretler SP, Preminger GM, et al. Oxalobacter formigenes may reduce the risk of calcium oxalate kidney stones. *J Am Soc Nephrol JASN* 2008;19(6):1197–203.
- [18] Miller AW, Choy D, Penniston KL, Lange D. Inhibition of urinary stone disease by a multi-species bacterial network ensures healthy oxalate homeostasis. *Kidney Int* 2019;96(1):180–8.
- [19] Hoppe B, Pellikka PA, Dehmel B, Banos A, Lindner E, Herberg U. Effects of oxalobacter formigenes in subjects with primary hyperoxaluria Type 1 and end-

- stage renal disease: a phase II study. *Nephrol Dial Transplant Off Publ Eur Dial Transpl Assoc - Eur Ren Assoc* 2021;36(8):1464–73.
- [20] Hatch M, Cornelius J, Allison M, Sidhu H, Peck A, Freel RW. Oxalobacter sp. reduces urinary oxalate excretion by promoting enteric oxalate secretion. *Kidney Int* 2006;69(4):691–8.
- [21] Hatch M. Induction of enteric oxalate secretion by Oxalobacter formigenes in mice does not require the presence of either apical oxalate transport proteins Slc26A3 or Slc26A6. *Urolithiasis* 2020;48(1):1–8.
- [22] Joshi S, Goldfarb DS. The use of antibiotics and risk of kidney stones. *Curr Opin Nephrol Hypertens* 2019;28(4):311–5.
- [23] Thongprayoon C, Vaughan LE, Barreto EF, Mehta RA, Koo K, Schulte PJ, et al. Outpatient antibiotic use is not associated with an increased risk of first-time symptomatic kidney stones. *J Am Soc Nephrol JASN* 2023;34(8):1399–408.
- [24] Waldegger S, Moschen I, Ramirez A, Smith RJ, Ayadi H, Lang F, et al. Cloning and characterization of SLC26A6, a novel member of the solute carrier 26 gene family. *Genomics* 2001;72(1):43–50.
- [25] Jiang Z, Asplin JR, Evan AP, Rajendran VM, Velazquez H, Nottoli TP, et al. Calcium oxalate urolithiasis in mice lacking anion transporter Slc26a6. *Nat Genet* 2006;38(4):474–8.
- [26] Cornière N, Thomson RB, Thauvin S, Villoutreix BO, Karp S, Dynia DW, et al. Dominant negative mutation in oxalate transporter SLC26A6 associated with enteric hyperoxaluria and nephrolithiasis. *J Med Genet* 2022;59(11):1035–43.
- [27] Gee HY, Jun I, Braun DA, Lawson JA, Halbritter J, Shril S, et al. Mutations in SLC26A1 cause nephrolithiasis. *Am J Hum Genet* 2016;98(6):1228–34.
- [28] Dawson PA, Russell CS, Lee S, McLeay SC, van Dongen JM, Cowley DM, et al. Urolithiasis and hepatotoxicity are linked to the anion transporter Sat1 in mice. *J Clin Invest* 2010;120(3):706–12.
- [29] Lee A, Beck L, Markovich D. The mouse sulfate anion transporter gene Sat1 (Slc26a1): cloning, tissue distribution, gene structure, functional characterization, and transcriptional regulation thyroid hormone. *DNA Cell Biol* 2003;22(1):19–31.
- [30] Ko N, Knauf F, Jiang Z, Markovich D, Aronson PS. Sat1 is dispensable for active oxalate secretion in mouse duodenum. *Am J Physiol Cell Physiol* 2012;303(1):C52–7.
- [31] Whittamore JM, Stephens CE, Hatch M. Absence of the sulfate transporter SAT-1 has no impact on oxalate handling by mouse intestine and does not cause hyperoxaluria or hyperoxalemia. *Am J Physiol Gastrointest Liver Physiol* 2019;316(1):G82–94.
- [32] Freel RW, Whittamore JM, Hatch M. Transcellular oxalate and Cl⁻ absorption in mouse intestine is mediated by the DRA anion exchanger Slc26a3, and DRA deletion decreases urinary oxalate. *Am J Physiol Gastrointest Liver Physiol* 2013;305(7):G520–7.
- [33] Cil O, Chu T, Lee S, Haggie PM, Verkman AS. Small-molecule inhibitor of intestinal anion exchanger SLC26A3 for treatment of hyperoxaluria and nephrolithiasis. *JCI Insight* 2022;7(13):e153359.
- [34] Johnson E, Vu L, Matarese LE. Bacteria, bones, and stones: managing complications of short bowel syndrome. *Nutr Clin Pract Off Publ Am Soc Parenter Enter Nutr* 2018;33(4):454–66.
- [35] Maalouf NM, Tondapu P, Guth ES, Livingston EH, Sakhae K. Hypocitraturia and hyperoxaluria after Roux-en-Y gastric bypass surgery. *J Urol* 2010;183(3):1026–30.
- [36] Hylander E, Jarnum S, Jensen HJ, Thale M. Enteric hyperoxaluria: dependence on small intestinal resection, colectomy, and steatorrhea in chronic inflammatory bowel disease. *Scand J Gastroenterol* 1978;13(5):577–88.
- [37] Cartery C, Faguer S, Karras A, Cointault O, Buscaill L, Modesto A, et al. Oxalate nephropathy associated with chronic pancreatitis. *Clin J Am Soc Nephrol CJASN* 2011;6(8):1895–902.
- [38] Sodhi M, Rezaeianzadeh R, Kezouh A, Etmnan M. Risk of gastrointestinal adverse events associated with glucagon-like peptide-1 receptor agonists for weight loss. *JAMA* 2023;330(18):1795–7.
- [39] Weir MA, Beyea MM, Gomes T, Juurlink DN, Mamdani M, Blake PG, et al. Orlistat and acute kidney injury: an analysis of 953 patients. *Arch Intern Med* 2011;171(7):703–4.
- [40] Lieske JC, Mehta RA, Milliner DS, Rule AD, Bergstralh EJ, Sarr MG. Kidney stones are common after bariatric surgery. *Kidney Int* 2015;87(4):839–45.
- [41] Robijn S, Hoppe B, Vervae BA, D'Haese PC, Verhulst A. Hyperoxaluria: a gut-kidney axis? *Kidney Int* 2011;80(11):1146–58.
- [42] Daudon M, Réveillaud RJ. [Whewellite and weddellite: toward a different etiopathogenesis. The significance of morphological typing of calculi]. *Nephrologie* 1984;5(5):195–201.
- [43] Daudon M, Letavernier E, Frochot V, Haymann JP, Bazin D, Jungers P. Respective influence of calcium and oxalate urine concentration on the formation of calcium oxalate monohydrate or dihydrate crystals. *Comptes Rendus Chim* 2016;19(11):1504–13.
- [44] Daudon M. [Crystalluria]. *Nephrol Ther* 2015;11(3):174–90.
- [45] Bazin D, Letavernier E, Haymann JP, Frochot V, Daudon M. [Crystalline pathologies in the human body: first steps of pathogenesis]. *Ann Biol Clin (Paris)* 2020;78(4):349–62.
- [46] De Yoreo JJ, Qiu SR, Hoyer JR. Molecular modulation of calcium oxalate crystallization. *Am J Physiol Renal Physiol* 2006;291(6):F1123–31.
- [47] Patt L, Leslie SW. *Acute renal colic*. StatPearls [Internet]. Treasure Island (FL): StatPearls Publishing; 2023 [cited 2023 Nov 27]. Available from, <http://www.ncbi.nlm.nih.gov/books/NBK431091/>.
- [48] Buyschaert B, Aydin S, Morelle J, Gillion V, Jadoul M, Etiologies Demoulin N. Clinical features, and outcome of oxalate nephropathy. *Kidney Int Rep* 2020;5(9):1503–9.
- [49] Knauf F, Asplin JR, Granja I, Schmidt IM, Moeckel GW, David RJ, et al. NALP3-mediated inflammation is a principal cause of progressive renal failure in oxalate nephropathy. *Kidney Int* 2013;84(5):895–901.
- [50] Ermer T, Eckardt KU, Aronson PS, Knauf F. Oxalate, inflammasome, and progression of kidney disease. *Curr Opin Nephrol Hypertens* 2016;25(4):363–71.
- [51] Mulay SR, Kulkarni OP, Rupanagudi KV, Migliorini A, Darisipudi MN, Vilaysane A, et al. Calcium oxalate crystals induce renal inflammation by NLRP3-mediated IL-1 β secretion. *J Clin Invest* 2013;123(1):236–46.
- [52] Mulay SR, Evan A, Anders HJ. Molecular mechanisms of crystal-related kidney inflammation and injury. Implications for cholesterol embolism, crystalline nephropathies and kidney stone disease. *Nephrol Dial Transplant Off Publ Eur Dial Transpl Assoc - Eur Ren Assoc* 2014;29(3):507–14.
- [53] Mulay SR, Anders HJ. Crystal nephropathies: mechanisms of crystal-induced kidney injury. *Nat Rev Nephrol* 2017;13(4):226–40.
- [54] Grocholski C, Chambrier C, Lauverjat M, Acquaviva C, Abid N, Bergoin C, et al. Circulating oxalate levels in short bowel syndrome as a severity marker of chronic kidney disease. *Kidney Int Rep* [Internet]. 2023 Dec 28 [cited 2024 Jan 15]; Available from, <https://www.sciencedirect.com/science/article/pii/S2468024923016467>.
- [55] Williams JC, Gambaro G, Rodgers A, Asplin J, Bonny O, Costa-Bauzá A, et al. Urine and stone analysis for the investigation of the renal stone former: a consensus conference. *Urolithiasis* 2021;49(1):1–16.
- [56] Edwards OM, Bayliss RI, Millen S. Urinary creatinine excretion as an index of the completeness of 24-hour urine collections. *Lancet Lond Engl* 1969;2(7631):1165–6.
- [57] Forni Ognà V, Ognà A, Vuistiner P, Pruijm M, Ponte B, Ackermann D, et al. New anthropometry-based age- and sex-specific reference values for urinary 24-hour creatinine excretion based on the adult Swiss population. *BMC Med* 2015;13(1):40.
- [58] Karamad D, Khosravi-Darani K, Hosseini H, Tavasoli S. Analytical procedures and methods validation for oxalate content estimation. *Biointerface Res Appl Chem* 2019;9(5):4305–10.
- [59] Robertson WG, Scurr DS, Smith A, Orwell RL. The determination of oxalate in urine and urinary calculi by a new ion-chromatographic technique. *Clin Chim Acta Int J Clin Chem* 1982;126(1):91–9.
- [60] Farrington CJ, Chalmers AH. Gas-chromatographic estimation of urinary oxalate and its comparison with a colorimetric method. *Clin Chem* 1979;25(12):1993–6.
- [61] Marshall DJ, Adaway JE, Keevil BG. A combined liquid chromatography tandem mass spectrometry assay for the quantification of urinary oxalate and citrate in patients with nephrolithiasis. *Ann Clin Biochem* 2018;55(4):461–8.
- [62] Daudon M, Jungers P, Lacour B. [Clinical value of crystalluria study]. *Ann Biol Clin (Paris)* 2004;62(4):379–93.
- [63] Daudon M, Frochot V. Crystalluria. *Clin Chem Lab Med* 2015;53(Suppl 2):s1479–87.
- [64] Letavernier E, Bazin D, Daudon M. Description of stone morphology and crystalluria improve diagnosis and care of kidney stone formers. *Healthcare* 2022; 11(1):2.
- [65] Daudon M, Frochot V, Bazin D, Jungers P. Crystalluria analysis improves significantly etiologic diagnosis and therapeutic monitoring of nephrolithiasis. *Comptes Rendus Chim* 2016;19(11):1514–26.
- [66] Daudon M, Hennequin C, Boujelben G, Lacour B, Jungers P. Serial crystalluria determination and the risk of recurrence in calcium stone formers. *Kidney Int* 2005;67(5):1934–43.
- [67] Demoulin N, Aydin S, Gillion V, Morelle J, Jadoul M. Pathophysiology and management of hyperoxaluria and oxalate nephropathy: a review. *Am J Kidney Dis Off J Natl Kidney Found* 2022;79(5):717–27.
- [68] Bazin D, Letavernier E, Haymann JP, Tielens F, Kellum A, Daudon M. Shedding light on the morphology of calcium oxalate monohydrate crystallites present in kidney biopsies in the case of hyperoxaluria. *Comptes Rendus Chim* 2016;19(11):1548–57.
- [69] Geraghty R, Wood K, Sayer JA. Calcium oxalate crystal deposition in the kidney: identification, causes and consequences. *Urolithiasis* 2020;48(5):377–84.
- [70] Bnaya A, Abu-Amer N, Beckerman P, Volkov A, Cohen-Hagai K, Greenberg M, et al. Acute kidney injury and hair-straightening products: a case series. *Am J Kidney Dis Off J Natl Kidney Found* 2023;82(1):43–52. e1.
- [71] Agrawal V, Wilfong JB, Rich CE, Gibson PC. Reversal of gastric bypass resolves hyperoxaluria and improves oxalate nephropathy secondary to roux-en-Y gastric bypass. *Case Rep Nephrol Dial* 2016;6(3):114–9.
- [72] Domínguez-Muñoz JE. Pancreatic enzyme therapy for pancreatic exocrine insufficiency. *Curr Gastroenterol Rep* 2007;9(2):116–22.
- [73] Ciacci C, Spagnuolo G, Tortora R, Bucci C, Franzese D, Zingone F, et al. Urinary stone disease in adults with celiac disease: prevalence, incidence and urinary determinants. *J Urol* 2008;180(3):974–9.
- [74] Pearle MS, Goldfarb DS, Assimos DG, Curhan G, Denu-Ciocca CJ, Matlaga BR, et al. Medical management of kidney stones: AUA guideline. *J Urol* 2014;192(2):316–24.
- [75] Chadwick VS, Modha K, Dowling RH. Mechanism for hyperoxaluria in patients with ileal dysfunction. *N Engl J Med* 1973;289(4):172–6.
- [76] Schwen ZR, Riley JM, Shilo Y, Averch TD. Dietary management of idiopathic hyperoxaluria and the influence of patient characteristics and compliance. *Urology* 2013;82(6):1220–5.
- [77] Asplin JR. The management of patients with enteric hyperoxaluria. *Urolithiasis* 2016;44(1):33–43.
- [78] Witting C, Langman CB, Assimos D, Baum MA, Kausz A, Milliner D, et al. Pathophysiology and treatment of enteric hyperoxaluria. *Clin J Am Soc Nephrol CJASN* 2021;16(3):487–95.
- [79] Knight J, Jiang J, Assimos DG, Holmes RP. Hydroxyproline ingestion and urinary oxalate and glycolate excretion. *Kidney Int* 2006;70(11):1929–34.

- [80] Fontana F, Cazzato S, Giovannella S, Ballestri M, Leonelli M, Mori G, et al. Oxalate nephropathy caused by excessive vitamin c administration in 2 patients with COVID-19. *Kidney Int Rep* 2020;5(10):1815–22.
- [81] Hylander E, Jarnum S, Nielsen K. Calcium treatment of enteric hyperoxaluria after jejunioleal bypass for morbid obesity. *Scand J Gastroenterol* 1980;15(3):349–52.
- [82] Penniston KL, Nakada SY. Effect of dietary changes on urinary oxalate excretion and calcium oxalate supersaturation in patients with hyperoxaluric stone formation. *Urology* 2009;73(3):484–9.
- [83] Pang R, Linnes MP, O'Connor HM, Li X, Bergstralh E, Lieske JC. Controlled metabolic diet reduces calcium oxalate supersaturation but not oxalate excretion after bariatric surgery. *Urology* 2012;80(2):250–4.
- [84] Tondapu P, Provost D, Adams-Huet B, Sims T, Chang C, Sakhaee K. Comparison of the absorption of calcium carbonate and calcium citrate after Roux-en-Y gastric bypass. *Obes Surg* 2009;19(9):1256–61.
- [85] Lieske JC, Regnier C, Dillon JJ. Use of sevelamer hydrochloride as an oxalate binder. *J Urol* 2008;179(4):1407–10.
- [86] Pozdzik A, David C, Vekeman J, Tielens F, Daudon M. Lanthanum carbonate to control plasma and urinary oxalate level in type 1 primary hyperoxaluria? *IJU Case Rep* 2021;4(4):235–8.
- [87] Bianco J, Chu F, Bergsland K, Coe F, Worcester E, Prochaska M. What treatments reduce kidney stone risk in patients with bowel disease? *Urolithiasis* 2022;50(5):557–65.
- [88] Caspary WF, Tönissen J, Lankisch PG. Enteral hyperoxaluria. Effect of cholestyramine, calcium, neomycin, and bile acids on intestinal oxalate absorption in man. *Acta Hepatogastroenterol (Stuttg)* 1977;24(3):193–200.
- [89] Nordenvall B, Backman L, Larsson L, Tiselius HG. Effects of calcium, aluminium, magnesium and cholestyramine on hyperoxaluria in patients with jejunioleal bypass. *Acta Chir Scand* 1983;149(1):93–8.
- [90] Langman CB, Grujic D, Pease RM, Easter L, Nezzar J, Margolin A, et al. A double-blind, placebo controlled, randomized phase 1 cross-over study with ALLN-177, an orally administered oxalate degrading enzyme. *Am J Nephrol* 2016;44(2):150–8.
- [91] Quintero E, Bird VY, Liu H, Stevens G, Ryan AS, Buzzard S, et al. A prospective, double-blind, randomized, placebo-controlled, crossover study using an orally administered oxalate decarboxylase (OxDC). *Kidney360* 2020;1(11):1284–90.
- [92] Pfau A, Grujic D, Keddis MT, Kausz AT, Lieske JC, Knauf F. Pilot study of reloxaliase in patients with severe enteric hyperoxaluria and hyperoxalemia. *Nephrol Dial Transplant* 2021;36(5):945–8.
- [93] Lieske JC, Lingeman JE, Ferraro PM, Wyatt CM, Tosone C, Kausz AT, et al. Randomized placebo-controlled trial of reloxaliase in enteric hyperoxaluria. *NEJM Evid* 2022;1(7):EVIDoA2100053.
- [94] Arvans D, Jung YC, Antonopoulos D, Koval J, Granja I, Bashir M, et al. Oxalobacter formigenes-derived bioactive factors stimulate oxalate transport by intestinal epithelial cells. *J Am Soc Nephrol JASN* 2017;28(3):876–87.
- [95] Verhulst A, Dehmel B, Lindner E, Akerman ME, D'Haese PC. Oxalobacter formigenes treatment confers protective effects in a rat model of primary hyperoxaluria by preventing renal calcium oxalate deposition. *Urolithiasis* 2022;50(2):119–30.
- [96] Hoppe B, Niaudet P, Salomon R, Harambat J, Hulton SA, Van't Hoff W, et al. A randomised phase I/II trial to evaluate the efficacy and safety of orally administered oxalobacter formigenes to treat primary hyperoxaluria. *Pediatr Nephrol Berl Ger* 2017;32(5):781–90.
- [97] Lubkowitz D, Horvath NG, James MJ, Cantarella P, Renaud L, Bergeron CG, et al. An engineered bacterial therapeutic lowers urinary oxalate in preclinical models and in silico simulations of enteric hyperoxaluria. *Mol Syst Biol* 2022;18(3):e10539.