



HAL
open science

Diagnosis and management in Rubinstein-Taybi syndrome: first international consensus statement

Didier Lacombe, Agnès Bloch-Zupan, Cecilie Bredrup, Edward Cooper, Sofia Douzgou Houge, Sixto García-Miñaúr, Hülya Kayserili, Lidia Larizza, Vanesa Lopez Gonzalez, Leonie Menke, et al.

► **To cite this version:**

Didier Lacombe, Agnès Bloch-Zupan, Cecilie Bredrup, Edward Cooper, Sofia Douzgou Houge, et al..
Diagnosis and management in Rubinstein-Taybi syndrome: first international consensus statement.
Journal of Medical Genetics, 2024, 61 (6), pp.503-519. 10.1136/jmg-2023-109438 . hal-04583123

HAL Id: hal-04583123

<https://hal.science/hal-04583123v1>

Submitted on 11 Dec 2024

HAL is a multi-disciplinary open access archive for the deposit and dissemination of scientific research documents, whether they are published or not. The documents may come from teaching and research institutions in France or abroad, or from public or private research centers.

L'archive ouverte pluridisciplinaire **HAL**, est destinée au dépôt et à la diffusion de documents scientifiques de niveau recherche, publiés ou non, émanant des établissements d'enseignement et de recherche français ou étrangers, des laboratoires publics ou privés.



OPEN ACCESS

Original research

Diagnosis and management in Rubinstein-Taybi syndrome: first international consensus statement

Didier Lacombe ¹, Agnès Bloch-Zupan,² Cecilie Bredrup,³ Edward B Cooper,⁴ Sofia Douzgou Houge,⁵ Sixto García-Miñaur,⁶ Hülya Kayserili ⁷, Lidia Larizza ⁸, Vanesa Lopez Gonzalez,⁹ Leonie A Menke,¹⁰ Donatella Milani,¹¹ Francesco Saettini,¹² Cathy A Stevens,¹³ Lloyd Tooke,¹⁴ Jill A Van der Zee,¹⁵ Maria M Van Genderen,¹⁶ Julien Van-Gils,¹ Jane Waite,¹⁷ Jean-Louis Adrien,¹⁸ Oliver Bartsch,¹⁹ Pierre Bitoun,²⁰ Antonia H M Bouts,²¹ Anna M Cueto-González,²² Elena Dominguez-Garrido,²³ Floor A Duijkers,²⁴ Patricia Fergelot,¹ Elizabeth Halstead,²⁵ Sylvia A Huisman,^{10,26} Camilla Meossi,¹¹ Jo Mullins,²⁷ Sarah M Nikkel,²⁸ Chris Oliver,²⁹ Elisabetta Prada,¹¹ Alessandra Rei,³⁰ Ilka Riddle,³¹ Cristina Rodriguez-Fonseca,³² Rebecca Rodríguez Pena,³³ Janet Russell,³⁰ Alicia Saba,³⁴ Fernando Santos-Simarro,³⁵ Brittany N Simpson,³⁶ David F Smith,³⁷ Markus F Stevens,³⁸ Katalin Szakszon ³⁹, Emmanuelle Taupiac,¹ Nadia Totaro,³⁰ Irene Valenzuela Palafoll ²², Daniëlle C M Van Der Kaay,⁴⁰ Michiel P Van Wijk,⁴¹ Klea Vyshka,⁴² Susan Wiley,³¹ Raoul C Hennekam¹⁰

► Additional supplemental material is published online only. To view, please visit the journal online (<https://doi.org/10.1136/jmg-2023-109438>).

For numbered affiliations see end of article.

Correspondence to

Professor Didier Lacombe, Department of Medical Genetics, University Hospital of Bordeaux, and INSERM U1211, University of Bordeaux, 33076, Bordeaux, France; didier.lacombe@chu-bordeaux.fr

Received 1 June 2023

Accepted 15 February 2024

Published Online First 12 March 2024

ABSTRACT

Rubinstein-Taybi syndrome (RTS) is an archetypical genetic syndrome that is characterised by intellectual disability, well-defined facial features, distal limb anomalies and atypical growth, among numerous other signs and symptoms. It is caused by variants in either of two genes (*CREBBP*, *EP300*) which encode for the proteins CBP and p300, which both have a function in transcription regulation and histone acetylation. As a group of international experts and national support groups dedicated to the syndrome, we realised that marked heterogeneity currently exists in clinical and molecular diagnostic approaches and care practices in various parts of the world. Here, we outline a series of recommendations that document the consensus of a group of international experts on clinical diagnostic criteria for types of RTS (RTS1: *CREBBP*; RTS2: *EP300*), molecular investigations, long-term management of various particular physical and behavioural issues and care planning. The recommendations as presented here will need to be evaluated for improvements to allow for continued optimisation of diagnostics and care.

INTRODUCTION

Rubinstein-Taybi syndrome (RTS) (MIM (Mendelian Inheritance in Man) #180849; #613684; #610543) is a multisystem disorder with physical, cognitive and behavioural characteristics, which can be caused by variants in two genes that regulate transcription via chromatin remodelling. The condition is named after the US paediatrician Jack Rubinstein and Iranian radiologist Hooshang Taybi who described seven affected infants in 1963.¹ There are >800 publications on RTS and related

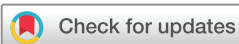topics. Within the framework of the European Reference Network Ithaca a group of international experts recognised the importance of equal practices regarding diagnostic procedures and care for individuals with RTS. To address this issue, an international consensus group was established, which performed a literature review, evaluated data critically, formulated conclusions and held a face-to-face meeting in the presence of patient group representatives. This has led to the present series of guidelines for diagnostics and care for individuals with RTS. For Methods see online supplemental materials.

CLINICAL DIAGNOSTIC CRITERIA

Definition

The goal of defining an entity is that affected individuals and their caregivers who face similar signs, symptoms and health problems, can meet one another, share knowledge, emotions and experiences about the disorder, support one another, and, this way, facilitate care and research. So the essence of a definition is to allow grouping together individuals with the same diagnosis.

Currently, variants in the genes *CREBBP* and *EP300* are known to cause RTS.^{2,3} One may argue that the diagnosis of RTS should be based on these molecular findings and clinical diagnostic criteria are no longer needed. Several issues argue against this: there are individuals with a phenotype classically fitting RTS, but without detectable cytogenetic or molecular anomaly; there are individuals with a genuine variant in *CREBBP* or *EP300* but with a phenotype different from the RTS phenotype,⁴ which can have major consequences in counselling patients and families; there are individuals with



© Author(s) (or their employer(s)) 2024. Re-use permitted under CC BY-NC. No commercial re-use. See rights and permissions. Published by BMJ.

To cite: Lacombe D, Bloch-Zupan A, Bredrup C, et al. *J Med Genet* 2024;**61**:503–519.

Table 1 Main clinical findings in percentages of individuals with molecularly confirmed Rubinstein-Taybi syndrome

	HPO ID*	CREBBP (n=308)	EP300 (n=52)
Growth			
Intrauterine growth retardation	0001511	49	42
Postnatal growth retardation	0004322	75	66
Obesity	0001513	29	39
Microcephaly	0000252	54	87
Craniofacial features			
Highly arched eyebrows	0002253	85	65
Long eyelashes	0000527	89	90
Epicanthal folds	0000286	44	15
Strabismus	0000486	71	39
Myopia	0000545	56	24
Downslanted palpebral fissures	0000494	79	56
Convex nasal ridge	0000444	81	44
Columella below alae nasi	0009765	88	92
Typical smile†	0000273	94	47
Highly arched palate	0002705	77	67
Talon cusps‡	0011087	73	4
Micrognathia	0000347	61	42
Low-set ears	0000369	44	27
Trunk and limbs			
Broad thumbs	0011304	96	69
Angulated thumbs	§	49	2
Broad finger tips	0011300	87	22
Broad halluces	0010055	95	81
Hypertrichosis	0000998	76	51
Keloids	0010562	23	10
Scoliosis	0002650	18	25
Cardiovascular anomalies	0002564	35	26
Constipation	0002019	76	54
Urinary tract anomalies	0000079	28	24
Neuromuscular			
Seizures	0001250	25	10
Cognition and behaviour			
Intellectual disability (any degree)	0001249	99	94
Autism/autism spectrum disorder	0000729	49	25

*HPO ID, Human Phenotype Ontology Identifier.

†Smile characterized by crescent-moon shaped palpebral fissures, deepening of labionasal folds, upturned corners of the mouth, usually mouth almost closed, tight upper vermilion and pouting lower vermilion.

‡Permanent dentition.

§No HPO identifier available; we used as definition: angulation of the distal phalanx of a thumb towards the anterior axis (radial side) of the limb.

either a *CREBBP* or an *EP300* variant of uncertain pathogenicity, and whose phenotype resembles RTS only to a limited extent, leaving it uncertain whether or not the variant is causative for the phenotype; there are many countries worldwide in which the availability of molecular studies is limited, and in which caregivers have to rely on a clinical diagnosis for counselling. For these reasons, we concluded that a clinical definition of the RTS phenotype is still needed and will remain needed.

There is no widely accepted set of clinical diagnostic criteria for RTS. We used the largest published set of data on individuals with RTS and either a *CREBBP* (n=308) or an *EP300* variant (n=52),⁵ to determine the sensitivity of signs and symptoms (table 1).

Table 2 Clinical diagnostic criteria for Rubinstein-Taybi Syndrome

Cardinal	Supportive
1. Face (at least three of six).	a. Maternal pre-eclampsia.
a. Highly arched eyebrows.	b. Keloids.
b. Downslanted palpebral fissures.	c. Hypertrichosis.
c. Convex nasal ridge.	1 point if c is positive, or
d. Columella below alae nasi.	3 points if a and/or b (with or without c) are positive.
e. Highly arched palate.	
f. Typical smile.	
3 points or	
4 points if d and/or f are positive.	
2. Skeletal.	
a. Angulated thumbs and/or halluces.	
b. Broad thumbs.	
c. Broad halluces.	
3 points if b and/or c is positive, or	
4 points if a (with or without b/c) is positive.	
3. Growth.	
a. Microcephaly.	
b. Postnatal growth retardation.	
2 points if a and/or b are positive.	
4. Development.	
Delayed development/intellectual disability	
2 points.	
Cardinal Score is positive only if two of the four groups score positive and also at least either skeletal or craniofacial scores positive	
Definitive clinical diagnosis of Rubinstein-Taybi syndrome: Score ≥12 and positive cardinal score.	
Likely clinical diagnosis of Rubinstein-Taybi syndrome: Score 8–11 and positive cardinal score. This score warrants molecular analyses of <i>CREBBP</i> and <i>EP300</i> .	
Possible clinical diagnosis of Rubinstein-Taybi syndrome: Score 5–7 and negative cardinal score. This score warrants molecular analyses of <i>CREBBP</i> and <i>EP300</i> .	
Unlikely clinical diagnosis of Rubinstein-Taybi syndrome: Score 0–4 and negative cardinal score. Further studies for other aetiologies indicated.	

We used the scored features as available, to avoid a bias. Signs present in at least 75% of either of the two groups were accepted as being sufficiently characteristic of the condition. In addition, we added three features with a lower frequency but which are highly specific for RTS: (1) radially deviated thumbs; (2) keloid formation; and (3) maternal pre-eclampsia. We considered adding talon cusps to these criteria but refrained from doing so as this sign is not yet present in the age group during which typically a diagnostic question arises. When developing the scoring system, it was observed that the presence or absence of the sign ‘long eyelashes’ did not contribute to sensitivity, and given the low intra-observer reliability of this feature it was excluded from the scoring criteria. Furthermore, the features known to be highly specific for RTS (radially deviated thumbs typical smile; columella below alae nasi, maternal pre-eclampsia keloids) were given a higher weighted value in the scoring system to reflect their diagnostic importance. Features were then subdivided into Cardinal Features, which we considered to be essential for RTS, and Suggestive Features, which are present less frequently but should raise suspicion for RTS (table 2; figure 1). Subsequent discussion of these criteria allowed consensus for the clinical diagnostic criteria, based on the presence of both Cardinal and Suggestive Features (online supplemental R1). If an individual

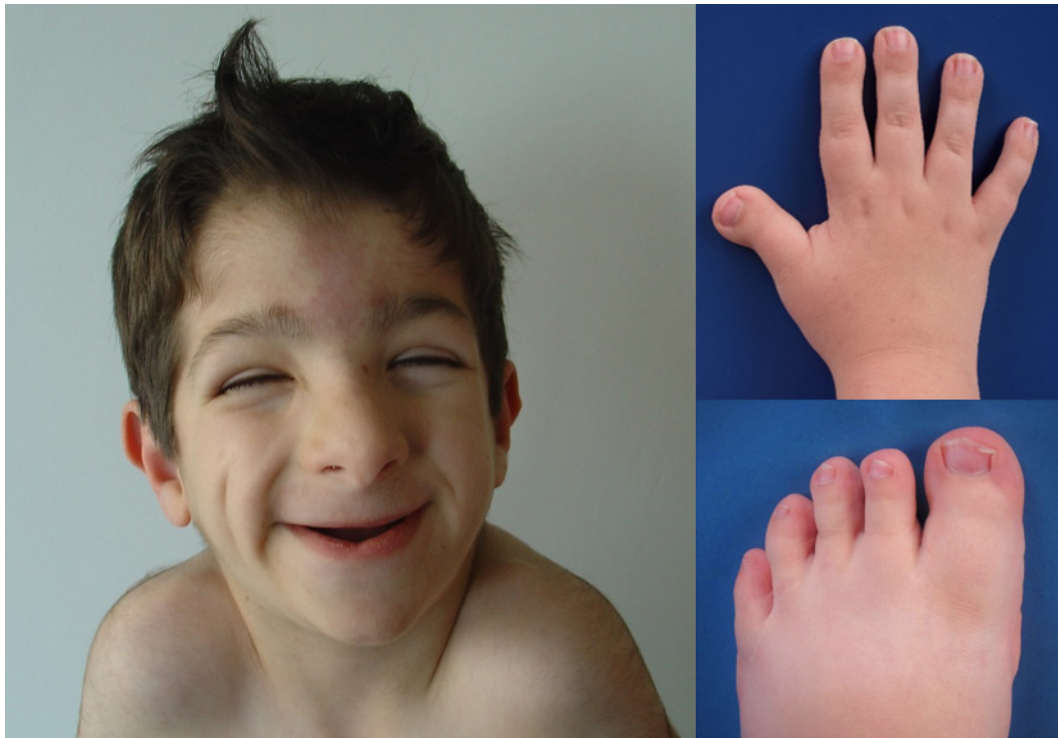

Figure 1 Cardinal features of the clinical diagnostic criteria of face and limbs for Rubinstein-Taybi syndrome (RTS).

scores 12 or higher, including meeting a score for the Cardinal Features, the diagnosis of RTS can be clinically confirmed irrespective of the results of molecular testing. A score of 8–11 including a positive score for the Cardinal Features indicates a likely diagnosis of RTS which requires further confirmation by molecular testing. A score of 5–7, with or without a Cardinal Feature, indicates that the diagnosis of RTS is still possible and molecular studies are indicated. A score of 0–4 indicates that the diagnosis is unlikely, and other explanations of the phenotype should be explored.

We realise that the presence of unusual signs and symptoms is not incorporated in the score as a negative feature. Still, these should always also be taken into account. Especially the presence of an unusual sign or symptom in someone with a score indicating a likely or definitive diagnosis of RTS should lead to considering the presence of a co-existing second (possibly Mendelian) disorder. In addition, in scoring signs, especially low-hanging columella, the ethnic background should be taken into account as in some ethnicities a low-hanging columella is a common variant. If uncertainty remains it is often useful to evaluate both parents and other relatives as well (online supplemental R2). Lastly, in the first months of life delayed development and disturbed postnatal growth may not yet present and a definitive score may be only possible at an age when this can be reliably ascertained.

Subsequently, we evaluated whether the set of diagnostic features allowed establishing the diagnosis reliably in a group of 100 individuals with molecularly confirmed RTS, that had not been part of the group of patients on which the criteria were built (online supplemental table S1). All individuals scored 5 or higher, indicating none would have been missed as having RTS based on clinical criteria (complete sensitivity). Only seven patients scored in the group Possibly RTS, others scored in the group Likely RTS (n=38) or Definitively RTS (n=55). Furthermore, we evaluated whether 45 individuals with a specific group of pathological

CREBBP or *EP300* variants, who have been considered to have a separate entity (Menke-Hennekam syndrome (MKHK); MIM #618332 / #618333),⁴ would be correctly distinguished from RTS (online supplemental table S1). Results showed that none scored as definitive or likely RTS, 9 as possibly RTS and 36 as unlikely RTS, so the entities could correctly be discerned. To determine the specificity, we reasoned that three entities that may resemble RTS and are not uncommon, that is, Floating Harbour syndrome (FHS; MIM #136140) (n=45), Wiedemann-Steiner syndrome (WDSTS; MIM #605130) (n=46) and Cornelia de Lange syndrome (CDLS; MIM #122470) (n=100), should be reliably discerned from RTS based on the set of weighted clinical features (online supplemental table S2). Results showed that none of the individuals with FHS and CDLS fulfilled the criteria for a definitive diagnosis of RTS, but one of the patients with WDSTS had such a score. In addition, one of the patients with WDSTS had a score within the Likely RTS group but was found by the present authors to have a classical RTS facial gestalt. This has to be expected as RTS is a chromatinopathy, and variants in other genes acting in the same pathway are likely to have consequences for the phenotype as well and rarely may even alter the phenotype significantly. Further studies to explain this unusual phenotype are planned. Furthermore, 8 of the 46 WDSTS individuals, and 1 of the 100 CDLS individuals fulfilled the criteria for Likely RTS, indicating that specificity was very high, but not complete. Due to the overlap in function of the genes involved in the four entities, this is to be expected.⁶ The results are in agreement with our joint clinical experience that, infrequently, discrimination between RTS and WDSTS based on clinical criteria can be extremely difficult. This happens less frequently in patients with CDLS and in FHS, but the phenotypic overlap is still marked. Obviously, this has consequences for the molecular analyses in someone with such scores (see *Molecular diagnostic criteria*). We realise that prospective studies will be needed to determine more reliable specificity and sensitivity. In addition,

such studies should include individuals of non-European descent, to evaluate whether the scoring system will be equally valid as in individuals of European descent.

Severity score

A major issue for families, especially at the time of diagnosis, is an indication of the severity of RTS. No severity score for RTS has been published to date. In our opinion a comparison and weighing of the severity and influences that various signs and symptoms have on the quality of life of an affected individual can only be made by the affected individuals and their families, and not just by physicians. We suggest that a group of family members should be facilitated to indicate which set of physical, cognitive and behavioural issues influence the life of individuals with RTS most. Ideally, such criteria should be stratified according to the nature of the molecular genetic cause (online supplemental R3).

MOLECULAR DIAGNOSTIC CRITERIA

RTS has been subdivided into type 1 (RTS1; OMIM #180849) and type 2 (RTS2; OMIM #613684) associated with heterozygous pathogenic variants or re-arrangements in the genes *CREBBP* and *EP300*, respectively, typically leading to haploinsufficiency. Both genes encode paralogous transcriptional co-activators with lysine acetyltransferase activity.^{7,8} The proteins CBP and p300 play a crucial role in transcription initiation by acting as a bridge, linking transcription factors to the transcription machinery, and through acetylation of histones^{9,10} (figure 2).

Mutation spectrum

Variants in *CREBBP* and *EP300* have been identified in 55–75%,^{2,3,11,12} and 8–11%,^{3,5,13,14} of individuals with RTS, respectively, of whom 2–3% have deletions of the complete gene. In 5–20% no molecular anomaly can be detected (online supplemental R4). To date, over 500 *CREBBP* and over 100 *EP300* pathogenic variants are known, distributed along all 31

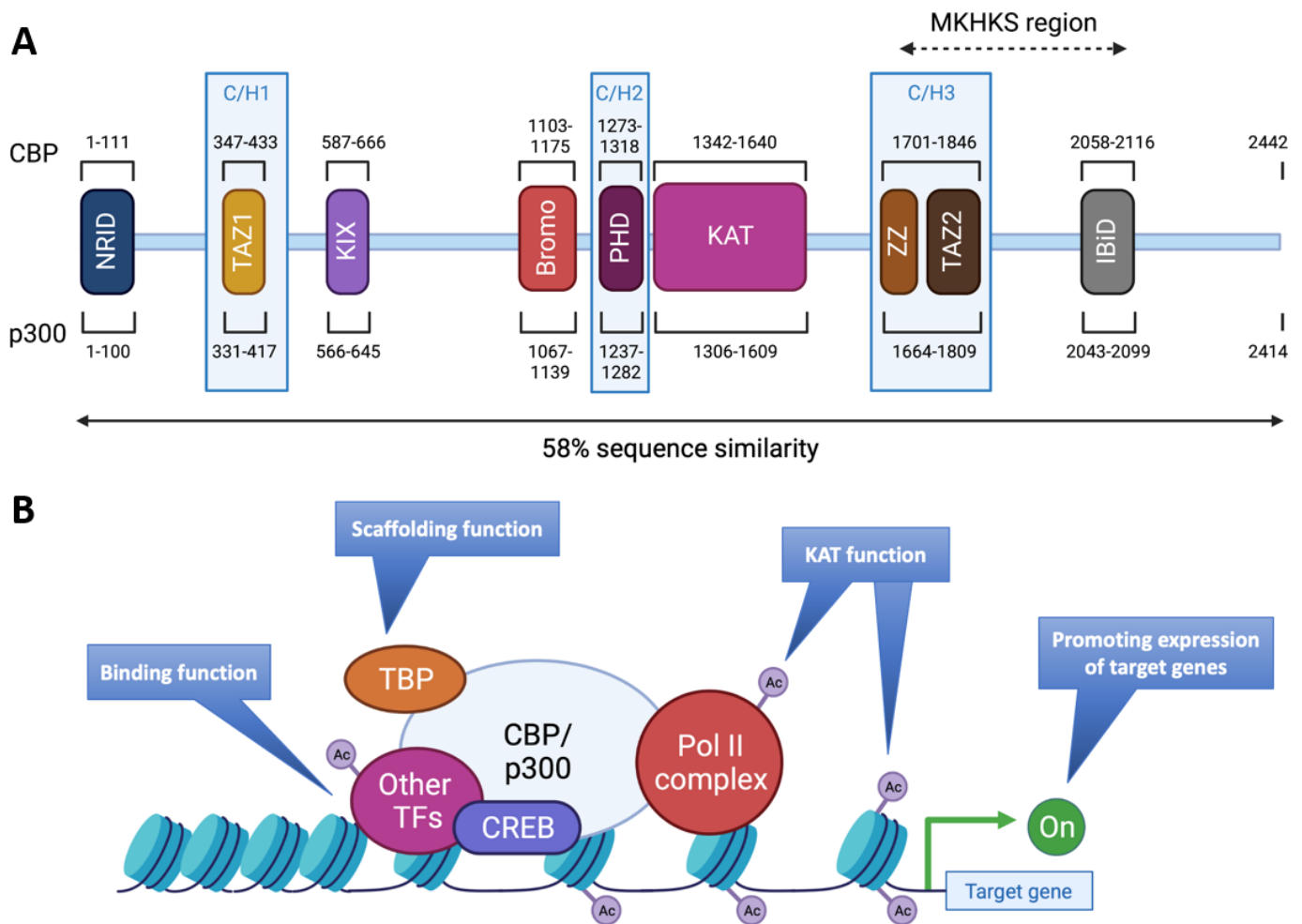


Figure 2 Structures and functions of CBP/p300. (A) The proteins CBP and p300 are composed of 2442 amino acids (AA) and 2414 AA, respectively, with 58% of sequence similarity within their domains. The various domains are represented by their position in the AA sequence: N-terminal nuclear receptor interaction domain (NRID or RID), cysteine-histidine rich region 1 (C/H1) containing the transcriptional adapter zinc finger 1 (TAZ1), kinase-inducible domain (KID) interacting domain (KIX), Bromodomain, C/H2 containing a plant homeodomain (PHD), lysine acetyltransferase domain (KAT), C/H3 containing the zinc finger (ZZ) and TAZ2 domains and interferon-binding transactivation domain (IBiD). The Menke-Hennekam syndrome (MKHKS) region corresponds to the location of the missense variants leading to the MKHKS. (B) CBP and p300 act as transcriptional co-activators of target genes by different mechanisms: (1) Binding function by facilitating the physical and functional interactions of TF; (2) scaffolding function allowing the recruitment of TF and in particular CREB; (3) KAT function by catalysing the transfer of acetyl groups on lysine residues of both histone tails and non-histone proteins such as the RNAPolII complex and TF. Ac, acetyl group; TBP, TATA binding protein; TF, transcription factors. Adapted from a study by Van Gils *et al.*¹⁵

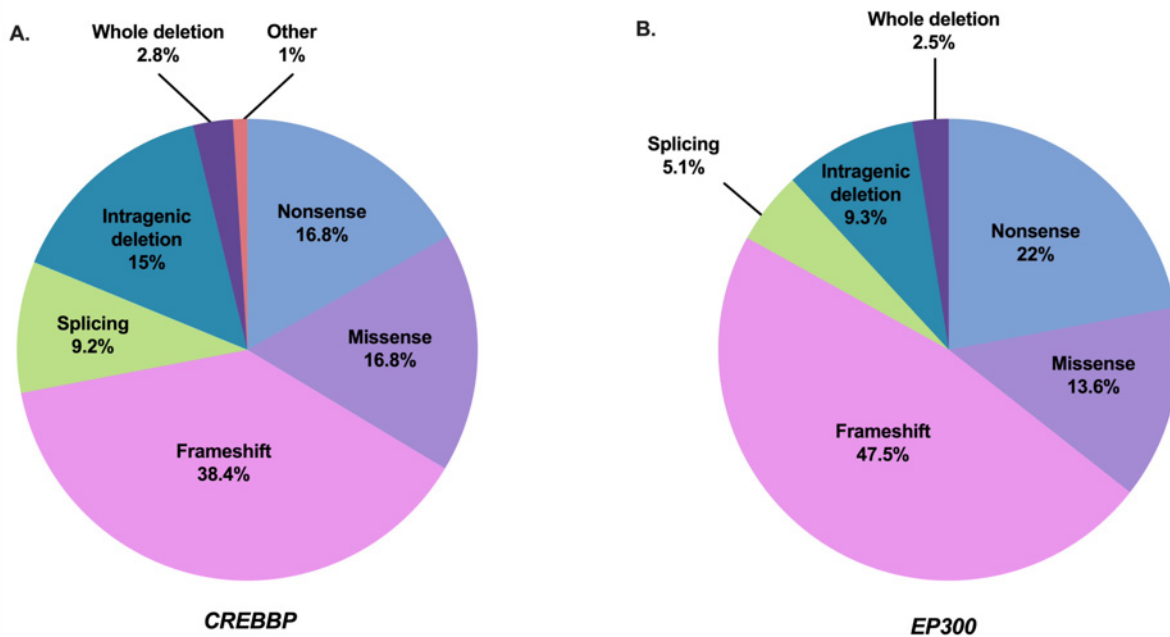


Figure 3 Mutation spectrum of *CREBBP* and *EP300* in individuals with Rubinstein-Taybi syndrome (RTS) (referenced in HGMDPro variant database and/or LOVD). (A) Repartition of 500 pathogenic variants in *CREBBP* referenced as causing RTS1 including 84 non-sense variants, 192 frameshift variants, 46 splicing variants, 84 missense variants, 75 intragenic deletions, 14 deletions including *CREBBP* completely, 2 intragenic duplications and 3 complex rearrangements. (B) Repartition of 118 pathogenic variants in *EP300* referenced as causing RTS2 including 26 non-sense variants, 56 frameshift variants, 3 splicing variants, 16 missense variants, 11 intragenic deletions and 3 deletions encompassing *EP300* completely. Adapted from a study by Van Gils *et al.*¹⁵

exons (figure 3). Several recurrent *CREBBP* variants have been reported, ~50% of missense variants are localised in the KAT domain,¹⁵ and recurrent rearrangements occur between introns 1 and 2 of *CREBBP* due to the high frequency of repeated or palindromic sequences in this region.^{16 17}

Genotype-phenotype correlation

Individuals with RTS1 and RTS2 both may show the classical phenotype but this may also vary. Individuals with RTS2 demonstrate in general less marked typical facial characteristics, no radial deviation of the thumbs, have infrequently keloids and a higher average cognitive level.^{5 13 14} However, maternal pre-eclampsia, intrauterine growth retardation and microcephaly are more common in RTS2 compared with RTS1.⁵

The type and site of variants in *CREBBP* and *EP300* do not associate with a specific phenotype with respect to external morphology, malformations, cognition or behaviour,^{5 11 13 18 19} (online supplemental R5). The exception is formed by missense variants between the end of exon 30 and the beginning of exon 31 of both *CREBBP* and *EP300*, which both lead to a phenotype that differs from RTS (table 1) and has been designated as MKHK (OMIM #618332, #618333).^{4 20} These missense variants hypothesised to affect specifically the binding properties of the ZNF2 (zinc finger, ZZ type) and ZNF3 (zinc finger, TAZ type) domains to different CBP partners by affecting their own folding.^{21 22}

RTS shows broad phenotypic overlap with other Mendelian disorders affecting the structure of chromatin genome-wide called 'chromatinopathies', such as FHS (OMIM #136140), CDLS (OMIM #122470, #300590, #610759, #614701, #300882, #608749), WDSTS (OMIM #605130), Kabuki syndrome (OMIM #147920, #300867), genitopatellar syndrome (OMIM #606170), Biesecker-Young-Simpson

syndrome (OMIM #603736) and Gabriele-de Vries syndrome (OMIM #617557).

Diagnostic approach

There are two main entry points for molecular genetic testing in RTS: clinical suspicion of RTS or no clinical suspicion (figure 4). If clinical presentation suggests RTS, the first-line tests are either targeted analysis of *CREBBP* and *EP300* by Sanger sequencing and Multiplex Ligation-dependent Probe Amplification (MLPA) or by high throughput analysis (array Comparative Genomic Hybridisation (aCGH); whole-exome sequencing (WES) if accessible). If RTS is not suspected in an individual with intellectual disability and/or malformations, the first tier is high throughput analyses (aCGH; WES or whole-genome sequencing). Evaluation of variant should be performed using the ACMG (American College of Medical Genetics and Genomics) classification.²³ Additional RNA studies are needed in case of unknown splicing variants. Suspicion of somatic mosaicism should be confirmed in more than a single tissue (buccal swab; bladder epithelium cells; skin biopsy). The phenotype should be re-evaluated after the identification of a (possibly) pathogenic variant to confirm that the molecular finding fits the clinical phenotype. If targeted analyses yield negative results and high throughput analyses are not available, the diagnosis remains dependent on the clinical phenotype and a definitive diagnosis may not be possible.

If the clinical diagnosis cannot be confirmed molecularly, molecular analyses yield a variant of unknown significance, or the phenotype does not fit the molecular finding, analysis of a genome-wide methylation pattern (epigenetic signature) can be performed as individuals with RTS have a specific pattern.²⁴

If all studies are negative, one should consider other diagnoses. Still, currently, not all molecular mechanisms leading to RTS are known, and if the clinical diagnostic criteria for RTS are met (see

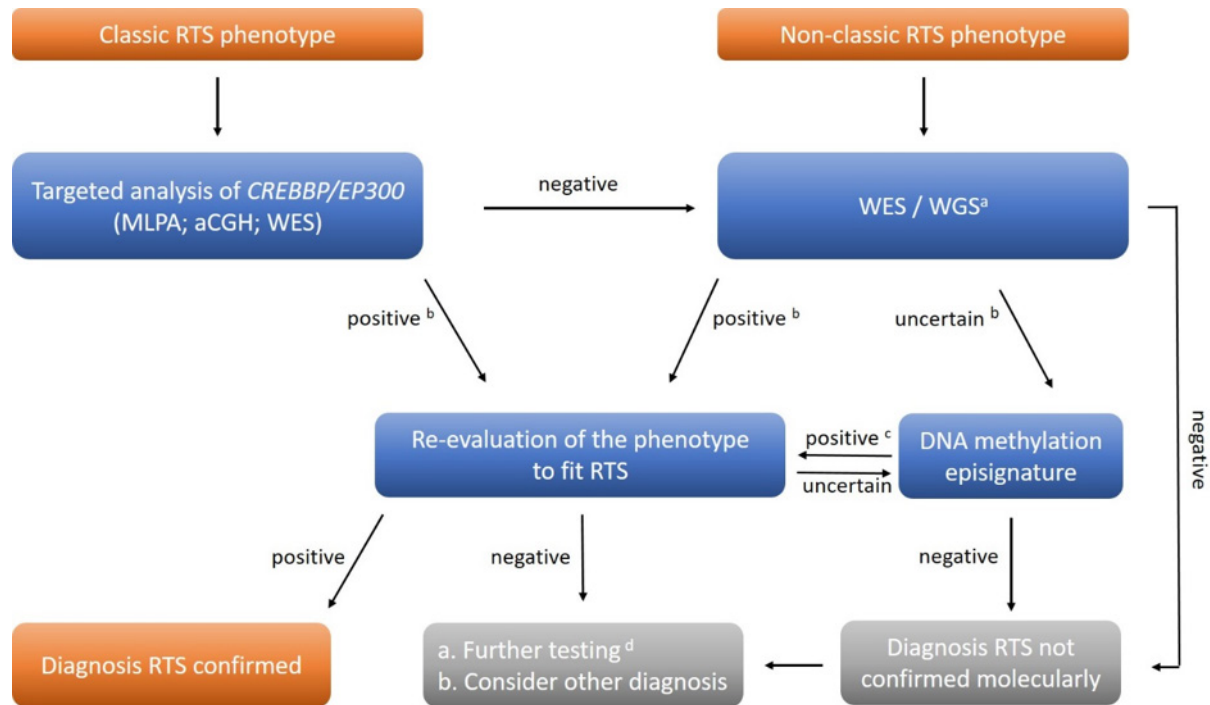


Figure 4 Molecular diagnostic pathways for Rubinstein-Taybi syndrome. In individuals with clinically classic RTS phenotype, the first-line molecular diagnostic approach is targeted analysis of *CREBBP* and *EP300* by Sanger sequencing and MLPA or by high throughput analysis (aCGH; WES). In individuals in whom RTS is not suspected, aCGH and WES or WGS are performed. ^a Including analysis of *CREBBP* / *EP300* and genes causing related entities; ^b evaluation of results using ACMG classification²³; ^c episignature specific for RTS²⁴; ^d RNA studies; searches for mosaicism. aCGH, array Comparative Genomic Hybridisation; ACMG, American College of Medical Genetics and Genomics; MLPA, Multiplex Ligation-dependent Probe Amplification; RTS, Rubinstein-Taybi syndrome; WES, whole-exome sequencing; WGS, whole-genome sequencing

Clinical diagnostic criteria), the diagnosis of RTS remains the standard in guiding management and follow-up of the patient.

Recurrence risk

RTS is inherited as an autosomal dominant trait and occurs de novo in over 99% of patients. However, familial occurrence does occur, either if a parent is relatively mildly affected or due to somatic or germ-line mosaicism.^{25 26} To date, eight instances of somatic or germ-line mosaicism and seven instances of parent-to-child transmission have been described in over 2000 reported affected individuals, indicating the empirical recurrence risk is 0.5–1%.²⁷ The recurrence risk for offspring of an affected individual is 50%, although it may be lower due to a spontaneous miscarriage (online supplemental R6).

Prenatal diagnosis

Without a positive family history, the prenatal diagnosis of RTS is only infrequently made as there are few reliable antenatal signs. Truly detailed three-dimensional ultrasonography may allow suggestive facial characteristics, but the morphology of the extremities, and specifically the radially deviated thumbs, are the main diagnostic handles.^{28 29} Additional findings that may be helpful are intrauterine growth retardation, polyhydramnios, underdevelopment of the cerebellum and gallbladder anomalies.²⁶

The main reason to perform prenatal diagnostics for RTS is the birth of a previous child with RTS in the family. If a causative variant in *CREBBP* or *EP300* has been detected, reliable molecular prenatal diagnostics can be performed in samples obtained by chorionic villus sampling or amniocentesis, or in embryonic cells obtained by in vitro fertilisation (online supplemental R7).

Prenatal testing in families without a previous child with RTS and a known pathogenic variant, by non-invasive cell-free fetal DNA screening, is not advocated, as an interpretation of the pathogenicity of variants detected this way may be extremely difficult. This limits the validity and informative value of the prenatal testing and may cause ethical issues for the families in deciding whether or not a pregnancy should be continued. Any prenatal testing needs to be discussed carefully with the couple before the procedure and should take into account the differences in perspective of couples and national legislation.

NEONATAL CARE

Recognition

86% of children present within the first month of life and 70% of these on the first day of life; prolonged hospital admission after birth was reported in 61%.³⁰ Early recognition of RTS may help identify complications and assist families to cope.³¹ The typical facial features of RTS evolve with time.³² The characteristic appearance in the neonatal period differs somewhat as it is mainly characterised by a prominent forehead with haemangiomas ('stork-bite naevus') in the glabella region, (apparent) hypertelorism, epicanthi and at that age up-slanting palpebral fissures. The nasal bridge tends to be straight, the tip short and upturned, and the nasal septum is not or only slightly extending beyond the alae.³² A small mouth, highly arched palate and small mandible are also present. Additional features can be unusually thick, black hair, a large anterior fontanelle and long eyelashes. Newborns with a variant in *EP300* tend to have a less obvious phenotype.⁵ The distal limb anomalies are the most characteristic of RTS in the neonatal period and are similar to those at

an older age (see *Clinical diagnostic criteria*). Cryptorchidism is common.

Feeding

Neonatal feeding difficulties are common (71–80%), due to swallowing incoordination, poor nipple grasp, hypotonia and gastro-oesophageal reflux.³³ Nutritional supplementation including gastric tube feeding is required in 40% of cases, as are occasionally percutaneous tubes, but most feeding challenges will have resolved within the first year of life.³⁰ Should feeding difficulties persist, additional professionals should be consulted (see *Gastroenterology*). Still, half of the mothers report a sufficient suck and were pleased with their breastfeeding experience.³³ Adequate breastfeeding instructions, proper positioning and ongoing encouragement are indicated (online supplemental R8).

Birth parameters

At birth most infants fall within the normal range for weight, length and head circumference,³⁴ although a higher incidence of microcephaly and growth restriction has been reported in infants with *EP300* variants, possibly related to the frequently occurring pre-eclampsia.⁵ There is no increased risk of preterm birth.³⁵ The use of RTS-specific growth charts is encouraged to monitor growth adequately (online supplemental R9).

Systemic manifestations

The various systemic manifestations of RTS are described elsewhere in the guidelines. The work-up of every newborn with suspected or confirmed RTS should include ophthalmological exams (glaucoma; coloboma); cardiac assessment (malformations); and renal ultrasound (malformations) (online supplemental R10). Obviously, further care such as the baseline newborn hearing screening and vaccinations should be performed as per the general population.

ENDOCRINOLOGY

Hypoglycaemia

Transient hypoglycaemia occurs with a low frequency in newborns with RTS and responds well to usual management schemes (online supplemental R11). Hypoglycaemic hyperinsulinism (HH) is very rare, may occur after birth or in the first years of life, is sometimes associated with concurrent illness, and can be transient or permanent.^{36 37} It has mainly been described in children with *EP300* variants.⁵ Early diagnosis and treatment of HH is crucial to avoid permanent brain damage.³⁸ Treatment is as in the general population: frequent enteral feeding, continuous glucose infusion and diazoxide). Usually, specialist consultation is needed.³⁹

Growth

Postnatal growth retardation is a hallmark of RTS.³⁴ Usually within months after birth, the length, weight and head circumference drop from normal values to ~ -2 SDS. Neither boys nor girls show a pubertal growth spurt, which contributes to a subsequent average adult height of -3 SDS for both men and women.³⁴ The use of growth charts specific for RTS, based on molecularly confirmed patients, facilitates adequate monitoring of growth (online supplemental R9). Growth hormone (GH) deficiency is infrequent but has been reported in few individuals, in whom GH therapy resulted in an increase in height SDS.⁴⁰ Every child in whom growth differs markedly from the growth pattern of the dedicated growth charts needs to be evaluated

for GH deficiency (online supplemental R12). If present, treatment is as in the general population. Prepubertal boys and girls may develop an unusual body shape due to increased fat tissue around the abdomen and hips, which disappears in puberty in boys, but often persists throughout life in girls.⁴¹

Puberty

The timing of puberty and the development of secondary sex characteristics usually falls within normal limits. The mean age of onset of puberty was 12.2 years,³⁵ with a mean age of menarche at 13.6 years.⁴¹ There is no indication that fertility has decreased, although formal studies are lacking. About 25% of adult males and females with RTS are sexually active.⁴² Sexual education should be proposed according to the level of emotional and cognitive functioning,⁴³ and contraceptive options are recommended as in the general population taking the level of developmental functioning into account (online supplemental R13).

GASTROENTEROLOGY

Malformations of the gastrointestinal tract such as a duodenal web and malrotation occur at a low frequency in newborns with RTS, although the frequency of the malrotation may be higher than in the general population.^{44 45} Symptomatology is similar to in newborns without RTS and should be managed as in the general population.^{41 45}

Feeding problems are very frequently present at birth and may remain present for a prolonged period of time.^{41 45 46} Oral feeding is preferred if it is safe and feasible, while tube feeding may be needed and a gastrostomy for long-term use. The involvement of dieticians is often helpful (online supplemental R14). Although feeding problems are in part explained by recurrent respiratory infections and hypotonia, also gastro-oesophageal reflux (GOR) may play a role.⁴⁶ Limited GOR occurs in all healthy infants and children; if causing excessive symptoms it is referred to as GOR disease (GORD).⁴⁷ The symptomatology of GORD may vary widely, from feeding problems, dental enamel erosions and recurrent pneumonias to restlessness and poor sleep. The pathogenesis remains uncertain.⁴⁶ GOR(D) should be differentiated from excessive regurgitation after feeds in otherwise asymptomatic infants, which is usually indicated as infant rumination syndrome.⁴⁸ Extremely rarely, eosinophilic oesophagitis may develop.⁴⁹ Given the lack of evidence for the management of GORD specifically in RTS, management of GORD should be as in the general population,⁴⁷: thickening of food and reassurance of parents as a first step. If symptoms persist, an initial trial with PPI (Proton Pump Inhibitors) treatment can be considered. If problems continue, further evaluation should be considered. If a PPI trial improves symptomatology, this does not conclusively prove acid-related GORD. Long-term use of PPI may cause side-effects,⁵⁰ thus in successful PPI trials individuals should undergo weaning trials regularly (eg, after 6 months and yearly thereafter) to evaluate the utility of continuing PPI treatment, while mitigating rebound effects by dose tapering. If symptoms persist or recur, additional testing, such as pH-impedance testing and/or endoscopy can be considered (online supplemental R15). Fundoplication and other surgical interventions are not recommended in an early phase of management, as these have a relatively high failure rate, commonly cause complications and can induce dysphagia and subsequent feeding problems; it should be reserved for patients with proven GORD unresponsive to optimal nutritional and medical therapy.⁵¹ Fortunately, complications of long-term GORD such as Barrett's oesophagus are rare in RTS,⁵² and oesophageal cancer has not been reported.

Constipation is extremely prevalent in RTS across all age groups throughout the lifespan.^{41,45} The cause remains unknown, Hirschsprung disease or other identifiable aetiologies do not occur more frequently than in the general population. Additional investigations are only indicated if symptomatology suggests an underlying disease. Long-term treatment with increased dietary fibres and fluid intake, and oral osmotic laxatives remain the cornerstone of treatment⁵³ (online supplemental R16). In severe cases, stimulant laxatives may be added, and further management schemes are as in the general population.

CARDIOLOGY AND PULMONOLOGY

Cardiovascular system

Congenital heart defects (CHDs) occur in 30% of cases, without a genotype–phenotype correlation.^{18 54–56} The reported differences in incidence according to ethnicity can be explained by ascertainment bias and differences in methodology.⁵⁷ The typical CHDs are patent ductus arteriosus, persistent foramen ovale and atrial and ventricular septal defect.^{5 13 19 55 58–60} Individuals with a CHD do not have a higher rate of other malformations or are associated with impaired cognitive function.

The cardiovascular system should be evaluated at diagnosis, including cardiac sonography (online supplemental R17). Treatment is as in the general population, including endocarditis prophylaxis as indicated. Surgery is needed in 15–22% of patients.^{42 61} CHDs do not cause unexpected complications in adults.⁴²

Cardiovascular problems typical for the general adult population occur in adults with RTS at a lower frequency. Hypertension is reported in 10% of adults,⁴² and surveillance and treatment are as in the general population (online supplemental R18).

Pulmonary system

Mild respiratory distress in the first hours of life is common in RTS neonates. Treatment is only needed if other risk factors such as prematurity are present. Upper respiratory infections are common (see *Immunology*). Infections of the lower respiratory system are uncommon,⁴² and are explained by feeding problems, microaspirations and gastro-oesophageal reflux. Exceptionally, immunodeficiency may play a role; the reported higher frequency of lower respiratory infections was caused by a study bias.⁶² In case of recurrent pneumonia with wheezing, hoarseness or stridor, the patient should first be evaluated for microaspirations and gastro-oesophageal reflux⁴⁹ (online supplemental R19). If negative, a search for immunodeficiency is indicated. Bronchiectasis has been described only in individuals with severe immunological malfunctioning.⁶³

Interstitial lung disease that becomes evident either in childhood,⁶⁴ or adulthood,⁶⁵ is uncommon but potentially severe. The diagnosis is made through the radiological characteristics of CT and can be confirmed by biopsy.⁶⁴ Management is as in the general population and is problematic.

Pulmonary functioning can also be compromised secondary to restrictive pulmonary diseases related to scoliosis,⁶⁶ and pulmonary hypertension caused by chronic sleep apnoea (obstructive sleep apnoea (OSA))⁶⁷ (see *Otolaryngology and Anaesthesiology*).

OPHTHALMOLOGY

Ocular abnormalities and/or reduced vision are reported in 20–80% of individuals with RTS.^{55 57 61 68–72} An overview of ocular anomalies is presented in online supplemental table S3 (online supplemental materials). Every child with RTS needs to

be referred for ophthalmological evaluation once the diagnosis is suspected (online supplemental R20).

Eye abnormalities were reported to be more common in individuals from Asia and Latin America than those from Africa and the Middle East, but this may be biased.⁵⁷ Both individuals with *CREBBP* and *EP300* variants present ocular anomalies, but due to small numbers of data on individuals with *EP300* variants differences in occurrence remain uncertain.

Anatomical anomalies

Congenital nasolacrimal duct obstruction by a persistent membranous obstruction at the entrance of the duct into the nose causes a watery eye from birth. It is mostly unilateral, with the incidence between 11% and 47%.^{55 57 59 71–74} Treatment follows international guidelines (Nasolacrimal Duct Obstruction in Children - American Academy of Ophthalmology aao.org) but the surgeon should be aware of the thicker bones and brittle lacrimal sacs in children with RTS.⁷⁵

The reported frequency of congenital glaucoma varies from 4% to 11%.^{55 57 61 72 75} The glaucoma can be unilateral or bilateral and be associated with anterior segment anomalies such as iris coloboma or lens luxation. Symptoms include tearing, blepharospasm and photophobia, and enlargement of the eye, manifesting as megalocornea and rapidly increasing myopia. Treatment should be as soon as possible after birth as it can lead to a marked loss of vision (www.eugs.org. Congenital Glaucoma - Europe - American Academy of Ophthalmology aao.org).

Cataracts has been reported in 6–25% of individuals with RTS,^{19 57 61 72 75} and is usually congenital.⁷² Reliable incidence figures are lacking. Early diagnosis and treatment in the first 2 months of life are mandatory to avoid visual deprivation, treatment is as in the general population (Pediatric Cataracts: Overview - American Academy of Ophthalmology aao.org). Frequent follow-up is needed for appropriate refractive correction and monitoring of secondary complications. Cataracts may also develop later in life⁷¹ (online supplemental R21).

Coloboma is reported in 10% of individuals.^{19 57 59 71–73} The coloboma can affect the iris, choroid, retina and/or optic nerve. Symptoms depend on location and size and may include visual field loss, reduced vision and photophobia. There is no curative therapy, but sometimes glare can be reduced by wearing sunglasses.

Retinal abnormalities occur frequently,⁷² but are often subtle, so may go unnoticed, without severe loss of vision, except for macular degeneration secondary to high myopia (online supplemental R21). Evidence may be present in the abnormal distribution of pigment in the macula and a subnormal electroretinogram. In some patients, the abnormal aspect of the macula is caused by foveal hypoplasia (Van Genderen, unpublished).

Functional anomalies

Visual impairment (best corrected binocular visual acuity <6/18) occurs in 20% of individuals,⁷² and typically is caused by anatomical abnormalities. Bilateral severe anomalies may lead to infantile nystagmus because of decreased sensory input from birth. Refractive errors and strabismus are very common, both occurring in 50–75% of individuals, and may change rapidly with age indicating the need for frequent controls, especially under 5 years of age.^{13 55 57 61 71 72} (online supplemental R21). In young children, high refractive errors need correction to prevent amblyopia. Children may however refuse to wear glasses if improvement of vision is not immediately evident. Gradual introduction in situations in which the child benefits most from

glasses may allow the child to get accustomed to wearing spectacles (online supplemental R22).

Treatment of strabismus to prevent amblyopia is as in the general population, provided the affected eye has no congenital anomaly that inhibits amelioration of vision.

Photophobia is common due to cataracts, glaucoma or trichiasis.⁷² Treatment is by treating the cause. Photophobia secondary to coloboma or retinal dysfunction can be ameliorated by shielding the eyes from direct (sun) light or wearing sunglasses.

OTOLARYNGOLOGY AND ANAESTHESIOLOGY

Hearing

The typical facial characteristics in individuals with RTS include a small chin and small oral cavity which can result in airway difficulties and, together with gastro-oesophageal reflux, can result in complications such as recurrent middle ear infections.⁷⁶ Conductive, sensorineural and mixed hearing loss may result.^{77–79} Regular auditory evaluation is therefore recommended (online supplemental R23).

Sleep

Abnormal facial anatomy and increased collapsibility of the laryngeal walls predispose individuals with RTS to higher rates of sleep-disordered breathing and OSA.^{80 81} Sleep disorders are frequent in children, and occur in 62% of adults.^{42 61} OSA is typically characterised by snoring and excessive daytime sleepiness and affects 25% of adults with RTS.^{42 61} If present in children the facial anatomy is often markedly abnormal and accompanied by obesity, hypotonia and adenotonsillar hypertrophy.⁸¹ As with the general population, management should take into account the various causal factors as well as potential difficulties in treating both children and adults with RTS⁶⁷ (online supplemental R24). Assessment of the sleep patterns using a validated questionnaire, such as the Sleep Disturbance Scale for Children,⁸² may offer information on both sleep patterns and response to therapy (online supplemental R25). Prior to a major surgical intervention, polysomnography should be considered.⁸³ Management of sleep disorders is aimed at implementing healthy sleep practices, particularly position during sleep, behavioural strategies and the use of and education on pharmacological interventions. Melatonin should be used appropriately in individuals with specific types of insomnias and sleep rhythm disturbances.

Anaesthesiology

Approximately 48% of adults with RTS require surgery at least once, with half of those requiring two or more surgeries during their lifetime.⁴² Children with RTS are no exception as they receive a higher fraction of anaesthetics relative to their age-matched cohorts.³⁵ As a result of the multisystemic manifestations of RTS, anaesthesiologists should be prepared to provide a tailored anaesthetic for this population (online supplemental R26).

Premedication and behavioural therapy support may prove beneficial in the preoperative setting. A single case series described complications such as cardiac arrhythmias associated with intraoperative administration of atropine and succinylcholine, but other studies have shown the safe and efficacious use in RTS,^{84 85} and this is also our joint personal experience. The altered facial anatomy may make mask ventilation, laryngoscopy and intubation challenging, and coupled with positioning limitations that may be present due to scoliosis, kyphosis, hypermobility and obesity, may warrant the use of video-laryngoscopy or fiberoptic intubation.^{35 86} Rarely, transnasal placement of a

nasopharyngeal airway or nasogastric tube is inhibited due to narrow or atretic choanae.

Intraoperative management of ventilation and postextubation care can be complicated by the presence of laryngotracheomalacia and augmented airway reactivity. In the immediate postoperative period, opioid use, while not contraindicated, should be used judiciously to prevent exacerbation of obstructive symptoms and hasten potential apnoeas. The perioperative use of analgesic and anxiolytic adjuncts such as non-steroidal anti-inflammatory drugs, acetaminophen and dexmedetomidine are encouraged, if not contraindicated secondary to other comorbidities or surgical considerations. Initiation of transient, non-invasive positive airway pressure may be helpful. Secondary to the elevated risk of complications with anaesthesia and airway manipulation, particular efforts should be made to bundle non-emergent procedures into a single anaesthetic to mitigate potential morbidity (online supplemental R27).

DERMATOLOGY

The main skin problem in RTS is the propensity to develop keloid. Keloids are non-malignant fibrous growths resulting from an abnormal response to skin injuries or inflammation that extend beyond the borders of the original wound. The pathogenesis of keloids is thought to involve multiple patient-specific factors (genetics, age, hormones, ethnicity), and environmental factors (trauma, surgery, inflammation) which collectively stimulate wound healing and persistent inflammation.⁸⁷ Spontaneous keloids occur only in genetic syndromes,⁸⁸ raising the question whether they are truly spontaneous, or whether unrecognised triggering environmental factors occur.

RTS is the syndrome considered to have the highest risk of keloid development.⁸⁹ The frequency of Dutch and UK RTS individuals developing keloids was 24%.⁸⁹ While keloids are most frequently occurring in association with *CREBBP* variants, around 10% of individuals with *EP300*-related disease develop such changes.^{5 13 56} Compared with the general population keloids develop earlier in life in individuals with RTS,^{57 89} and increase with age: up to 60% was reported in a cohort of adults.⁴² Up to 100 keloids have been recorded in the same individual.⁹⁰ In RTS keloids are most frequently seen on the shoulders and chest.⁸⁹ Development of keloids is not associated with other traits of the phenotype within RTS.⁸⁹

Apart from aesthetic issues, keloids cause pain, itching and reduced mobility of the involved region, thus seriously affecting the quality of patients' lives⁸⁹ (online supplemental R28). Prevention is difficult and keloids may be unavoidable as minimal trauma such as rubbing of clothes may be sufficient to induce keloid formation. There are no standardised treatment protocols for keloids in individuals with RTS. Therapy options include repeated intra-lesion steroid injections, laser therapy, compression, local radiation, cryotherapy and surgery, either individually or in combination, but no treatment is fully satisfactory, and the recurrence rate remains high.⁹¹ There is no detectable association between keloids and cancer risk, suggesting different aetiologies or pathogenesises.⁹²

Another skin problem in RTS occurring in 17% of a series of molecularly proven Dutch cases,⁹³ are multiple pilomatricomas: benign skin tumours derived from hair matrix, often harbouring activating mutations of beta-catenin.⁹⁴ These skin-coloured, red or white lesions typically occur on the head and neck in children and adolescents, but do occur elsewhere and may arise at older ages as well. Pilomatricomas typically calcify, causing them to feel like hard lumps. They may coexist with keloids.^{19 95} Similar

to keloids there are often multiple pilomatricomas, and puberty may act as a triggering factor. Complete surgical excision has been recommended,⁹⁶ but others suggested surgical removal only in case of discomfort⁸⁹ (online supplemental R29).

Ingrowing nails occur regularly in both fingers and toes, especially in the partially duplicated thumbs and halluces,³⁵ and may cause pain and skin infections. Adequate instructions regarding nail care and avoiding narrow shoes may prevent ingrowing nails (online supplemental R30). Treatment is as in the general population. Further skin findings in RTS are congenital generalised hypertrichosis, both in individuals with *CREBBP* and *EP300* variants,⁹⁷ apparently more frequent in individuals from Latin America and the Middle East and less frequently in those from Africa.⁵⁷ Usually, it becomes less marked with age. Other changes are angiomas, melanocytic naevi, white papulae on the trunk and limbs, supernumerary nipples and sometimes lentiginos and café-au-lait spots.

UROGENITAL SYSTEM

Urinary tract

Urinary tract anomalies occur in 23% of individuals with RTS,^{5 13 19 35 55 57} and include horseshoe kidney, renal duplication, renal agenesis, renal dysplasia, hydronephrosis, nephrolithiasis and vesicoureteral reflux. Symptomatology and treatment follow the general population management. Individuals with *CREBBP* and *EP300* variants are equally affected and there is no known genotype–phenotype correlation.

The high prevalence of renal anomalies warrants at least one renal ultrasound and blood pressure measurement when the diagnosis of RTS has been made (online supplemental R31). If renal anomalies or elevated blood pressure are detected, consultation with a specialist (paediatric nephrologist and urologist) is recommended (online supplemental R32). Hypertension in children with RTS is rare but can occur, and is then caused by renal artery stenosis (Hennekam, unpublished observations).

Genitalia

The most common genital anomaly is unilateral or bilateral cryptorchidism, which occurs in 59% of men.^{13 17 19 35 55 57} All men should be checked by careful physical examination after diagnosis (online supplemental R33). Treatment is as in the general population following international guidelines.⁹⁸ Other external anomalies occurring in less than 10% of individuals are hypospadias in both men and women, and fusion of labia minora,^{19 35} which can be treated as in the general population. Shawl scrotum formation is common in RTS and needs no treatment.

Uterine malformations have been reported rarely.⁹⁹ Women may have hypermenorrhagia or metrorrhagia. A questionnaire survey among 76 women (online supplemental materials Menses Survey) yielded that 10 of them did not yet or did no longer menstruate, 21 of the remaining 66 (32%) used medication (typically contraceptives) because of menses problems, 19 of the 45 (42%) without this medication has metrorrhagia and 10 of 45 (22%) has menorrhagia. Contraceptives were invariably successfully treating the menses problems (online supplemental R34).

MUSCULOSKELETAL SYSTEM

Musculoskeletal anomalies in RTS vary widely. They are somewhat more frequent in individuals with *CREBBP* variants than in those with *EP300* variants.⁵ Using the data from several large series of patients,^{5 11 13 17–19 100–103} major limb anomalies (*CREBBP* variants vs *EP300* variants) are broad thumbs (343/360; 95% vs 51/81; 63%), radially-deviated thumbs (183/343; 53% vs 5/71;

7%) and broad halluces (278/290; 96% vs 55/81; 68%). The broadness of the thumbs hardly ever causes problems, but the broadness of the halluces may cause problems in walking or wearing shoes, especially if the halluces are medially deviated. In a minority of patients, surgical correction is needed. Several methods for surgical correction have been reported.^{104–107} However, often the deviated thumbs have good function and recurrence of the deviation after surgery is common. In our experience, a decision regarding surgery is best postponed until the function of the hands in the patient can be accurately evaluated, which typically can be done around 3–4 years of age. If surgery is indicated, it should be performed by a surgeon familiar with the procedure in RTS (online supplemental R35).

Other findings include limitation of mobility between the proximal and distal phalanx of the thumbs, broadness of distal phalanges of fingers, limited syndactylies, and rarely camptodactyly, but these do not require treatment.

Hypermobility in the hip, elbow, fingers and thumbs, knee and patella is common.^{35 80 108 109} In combination with other not well-known factors (muscular, bony, neurological), this may cause stiffness and the typical waddling gait in some adolescents and adults. A detailed evaluation of motor skills is indicated¹¹⁰ (online supplemental R36). Further studies describing gait problems in RTS are lacking.

Regular evaluation of the gait is indicated since patella dislocation and Perthes-like hip problems may need therapy (online supplemental R36). In particular, patella problems can cause major mobility challenges and, if untreated, can cause problems like genua valga and knee contractures. These issues may ultimately necessitate wheelchair use. Recurrent patella dislocation may require physical therapy, orthotics or surgical correction,^{111 112} although procedures are not always successful.

An emerging gait disturbance in older children and adolescents may be caused by an aseptic hip joint inflammation resembling Perthes disease, which occurs in 3% of patients, is often marked, and may take 2 or 3 years to resolve spontaneously.⁸⁰ It may be difficult to distinguish this from slipped capital femoral epiphyses.¹¹³ Management is symptomatic.

Other uncommon limb problems such as congenital hip dislocation, tight heel cords and increased risk for fractures, should be treated as in the general population.

Scoliosis is reported in 34/184 (18%) of individuals with *CREBBP* variants and 15/78 (19%) of those with *EP300* variants,⁵ and develops in late childhood and puberty. Treatment is as in the general population (online supplemental R37). Significant thoracic kyphosis and lumbar lordosis can occur and typically do not need treatment.^{41 45} Radiologically the spine may show changes resembling an early ankylosing spondylitis (M Bechterew) but progression into a true ankylosing spondylitis has not been reported.³⁵ Other infrequent spine anomalies include instability of C1–C2, underdevelopment of the dens and cervical vertebral fusions, which should be managed as in the general population.¹¹⁴ Occult spina bifida is detected regularly but does not cause clinical manifestations and may be left untreated.

Children and adults have an increased fracture risk, and 8% of adults have osteoporosis indicating a potentially disturbed ossification in RTS,⁴² (Simpson *et al* unpublished observations) (online supplemental R38). Clues for this abnormal ossification in radiographies of the upper spine have been reported.³⁵

INTRAORAL CHARACTERISTICS

The main non-dental oral characteristic of RTS is the narrow, highly arched palate, which may rarely show clefting of either

the complete palate (sometimes submucous), the soft palate or only the uvula, which may or may not be accompanied by a cleft lip.⁵ A careful evaluation of the palate is indicated in every newborn or child with RTS (online supplemental R39). The treatment of clefting is as in the general population. Other, less frequent characteristics are a relatively large tongue, the bifid tip of the tongue, a short frenulum, and wide alveolar ridges.³⁵

Dental characteristics are almost universally present and may exist as abnormalities in tooth number (15–30%; hyperdontia, hypodontia, mesiodens), structure (23–29%; enamel hypoplasia, discolouration), eruption (5%; neonatal teeth, persistence of primary teeth, delayed eruption), position (62–64%; malocclusion, malalignment, crowded teeth, crossbite) and abnormal tooth shape including talon cusps, a diagnostic hallmark for RTS.^{61 115 116} Talon cusps are accessory cusps on the lingual side of incisors. *CREBBP* and *EP300* are strongly expressed in both incisors and molars¹¹⁷ and influence the formation of the secondary and (to a lesser extent) primary enamel knots, allowing, if mutated, for talon cusp formation in 27% of primary incisors and 70–92% of permanent (upper) incisors.^{115 116} Sealing the fissures around the talon cusps may prevent caries. Treatment is only needed if it interferes with mouth closure and occlusion or leads to marked caries (online supplemental R40).

Dental anomalies may also be secondary, that is, difficulties in maintaining adequate oral health leading to caries and periodontal disease, and also to enamel demineralisation due to gastro-oesophageal reflux.^{115 116} Children and adults with RTS often demonstrate also anxieties when facing dental assessments and treatments, stressing the need for early intervention.¹¹⁸ Informing parents and other caregivers of the importance of early adequate oral hygiene, and subsequent advice, is paramount. Regular dental evaluation and treatment, preferably by a dentist with experience in caring for individuals with special needs, can prevent further problems, and treatment may be aided with sedation or general anaesthesia,¹¹⁹ (online supplemental R41). Orthodontic assessments and treatments are as in the general population. However, some procedures may not be well tolerated and should be considered in close collaboration with the individual and family.

IMMUNOLOGY

Infections

Recurrent infections of organs or organ systems do not typically occur in RTS, except for respiratory infections (70% of children, <20% of adults), including otitis media.^{35 42 61} Explanations include microaspiration and gastro-oesophageal reflux, but dysfunction of the immune response may also contribute. B cell defects have been reported.⁶² If a child with RTS has recurrent unexplained infections, a baseline immune workup including complete blood count with differential, immunoglobulin (Ig) levels (IgG, IgA and IgM), vaccine titres and lymphocyte subsets with B-cell phenotyping should be performed (online supplemental R42). In lower airway infections microaspiration or gastro-oesophageal reflux should be considered (online supplemental R19). If the immune workup yields abnormal results, consultation with an immunologist is indicated (online supplemental R42). Although a reduction of T cell or specific T-cell subtypes has been found in some cases, combined immune defects such as viral or opportunistic infections, have not been reported and specific antiviral or antifungal prophylaxis is not indicated.⁶² Vaccination can be performed as in the general population, causing the typical level of protection (online supplemental R43).

Oncology

CREBBP and *EP300* are involved in several basic cellular activities, such as DNA repair, growth, differentiation, apoptosis and tumour suppression. Early surveys suggested an increased frequency of malignancies in case reports on individuals with RTS.¹²⁰ However, a more recent population-based study found no evidence of an increased risk for malignancies in individuals below 40 years of age.⁹³ Data for older individuals are too limited to allow conclusions. Benign tumours, however, were more common: meningiomas and pilomatricomas were present in 8% and 17% of molecularly-proven patients, respectively.⁹³ Surveillance for malignancies below 40 years of age is not recommended; the value of additional surveillance at an older age remains uncertain, and these individuals should follow surveillance schemes according to national standards (online supplemental R44).

NEUROLOGY

Central nervous system anomalies

The most common intracranial malformations (74%) in individuals with RTS are corpus callosum-related malformations. Periventricular posterior white matter abnormalities (63%), cerebellar vermis malformations (58%) and small or absent olfactory bulb (32%) are also regularly observed.^{28 54 121–124} Infrequent findings are Arnold-Chiari malformation, underdeveloped pituitary gland and Dandy-Walker malformation.^{28 35 40 41 54 55 125 126} None of these findings has direct consequences for regular medical care and routine cerebral brain MRI is not recommended and indications for brain MRI studies should follow the standard of care for the general population (online supplemental R45), with the exception of microcephaly without other neurological manifestations. Spinal cord malformations such as tethered cord, syringomyelia, lipomas and spina bifida have also been observed.^{13 35 121 124 127} Spinal MRI is indicated if neurological signs or symptoms are present. Studies for genotype—brain phenotype association have suggested an association of microcephaly and low-positioning of the conus with an altered *KAT* function,¹²¹ and no other association.

Epilepsy

Non-specific electroencephalogram (EEG) abnormalities are observed in around 58–76% of individuals with RTS2 but clinical epileptic manifestations are infrequent, ranging from 9% to 33%.^{5 13 57 121 128–130} In individuals with RTS type 2, epilepsy is reported in 0–10%.^{5 13} Specific EEG findings also in individuals without a history of seizures have been suggested,^{121 122} but have no consequences for medical care. Routine EEGs are therefore not recommended, and EEGs should remain limited to individuals with RTS with epileptic seizures. Treatment and surveillance should follow national standards of care (online supplemental R46).

NEURODEVELOPMENT

The early symptoms of delayed development are the delay in achieving basic motor skills (table 3).^{35 131} First words are typically spoken at 2 years of age, sentences of two words or three words at 4 years of age or later on, with a wide variability across individuals. IQ ranges from 25 to 79, non-verbal performance IQ generally being higher than verbal IQ.^{41 121 132 133} Individuals with a *CREBBP* variant typically have a moderate-to-severe intellectual disability (ID), while individuals with *EP300* variants have mainly a mild ID and only rarely severe ID.⁵ There is no

Table 3 Developmental milestones of children with Rubinstein-Taybi syndrome compared with typically developing children

Milestone	Rubinstein-Taybi syndrome		General population (Dowman 2012)	
	Mean age (months)	Range	Mean age (months)	Range
Laughing	2.5	2–6	2	2–6
Rolling over	10	4–18	6	5–9
Sitting	16	9–24	7	6–12
Crawling	19	12–36	9	8–12
Standing	29	11–80	9	8–18
Walking	35	18–54	14	12–18
First words	24	6–84	12	8–18

correlation between the type and site of variants and cognitive abilities.^{5 11}

Intellectual disability involves related impairments of cognitive function, learning attainment, expressive language, symbolic play and adaptive behaviour. The role of reduced neuronal histone acetylation in the aetiology of ID has been pointed out by mouse models of RTS showing deficits in long-term memory, but not in short-term memory on a variety of learning and memory tasks.^{134 135} Weaker memory impairments were found in *Ep300* mutant mice¹³⁶ in keeping with the milder ID of *EP300*- compared with *CREBBP*-mutated individuals. Consolidation of learnt information into long-term memories through stimuli-driven transcription is mainly imputed to CBP given its interaction with CREB, a key transcription factor involved in memory formation which diminished levels impair spatial memory,¹³⁷ as observed in RTS children. Mice with *Cbp* mutation(s) disrupting CBP-CREB interaction, besides memory deficits, exhibit impaired motor skill learning,¹³⁸ similar to the difficulties in planning and executing motor acts experienced by *CREBBP*-mutated patients.

Early assessment of cognitive abilities will benefit each child to access care earlier and for optimal stimulation of development (online supplemental R47). Non-verbal children may benefit from non-symbolic communication, such as non-speech vocalisation and gestures, which help them in their social interactions, and augmentative communication should be prioritised from early on, also in the preverbal stage (online supplemental R48). Early physiotherapy may enhance rehabilitation as well, focusing on the most weakened skills, which have been identified as those requiring a high level of visuomotor coordination.¹¹⁰ Early implementation and maintenance of communication strategies to catalyse preverbal and verbal language development and socialisation skills. Follow-up should include also repeated neuropsychological testing to ensure continuous optimal stimulation, especially at sensitive life phases (school entry, puberty, traumatic events, adulthood and ageing)⁴² (online supplemental R49).

BEHAVIOUR

Recommendations for clinical practice

Interventions for behaviours, cognition and emotion specifically for individuals with RTS are lacking. Applying strategies and intervention approaches designed for individuals with intellectual disability in general, as well as interventions for individuals with a diagnosis of autism, may be helpful (online supplemental table S4 summarises key recommendations).

Self-injurious and aggressive behaviour

The prevalences of self-injurious and aggressive behaviour vary markedly in children and adults with RTS (between 7–48% and 10–16%, respectively).^{18 139} These figures are similar to the prevalences in individuals with intellectual disability and autism in general.¹⁴⁰ Aggressive behaviours may increase in older individuals.^{132 141} Our joint experience indicates that the self-injurious behaviour and aggression do not show specific characteristics. However, formal studies assessing individuals over time and describing specific topographies of behaviour using standardised measures, are lacking.

Emotions

Emotional outbursts, often severe and weekly, were noted in 7/31 children.¹³⁹ However, a questionnaire study measuring ‘temper tantrums or hot temper’ found no differences between children with RTS and typically developing children.¹⁴² Emotional outbursts were reported in 5/13 adults with RTS,¹³⁹ seemingly indicating an increase with age, as reported by others.¹³²

On the Child Behaviour Checklist, 64.5% of individuals above 13 years of age and 27.5% of younger individuals were reported to be very anxious.¹⁴¹ The anxiety is not correlated with genotypes.⁵⁹ For some anxiety subtypes, scores did not differ from children diagnosed with an anxiety disorder.¹⁴³ Screening for anxieties using a questionnaire validated for individuals with intellectual disability will benefit many individuals with RTS (online supplemental R50). Subsequent interventions should follow best practice guidance for individuals with intellectual disability.

Repetitive behaviours

Repetitive behaviours in individuals with RTS include body, hand and object stereotypy, adherence to routines, repetitive phrases and repetitive questioning.^{66 142 144} Repetitive behaviour, in particular, repetitive questioning, has been associated with inhibitory control and working memory difficulties,^{145 146} which has led to the hypothesis that individuals may have difficulties suppressing questioning behaviour, and retaining information in their working memory.^{145 146} Co-occurrence of adherence to routines and temper outbursts in older individuals has led to the suggestion that executive function difficulties may contribute to these characteristics.^{142 146}

Autism spectrum characteristics

Prevalence rates of autism range from 37–44% on standardised screening assessments.^{139 142} The estimates for individuals with a *CREBBP* variant have been higher (49%) compared with those with an *EP300* variant (25%).⁵ Studies using direct assessments of children with a *CREBBP* variant and a severe intellectual disability, demonstrate areas of cognitive and socio-emotional differences similar to those in children with a diagnosis of autism matched for degree of disability.¹³³ Therefore, families can make use of strategies designed for autism populations, specifically with respect to strategies for language delays, imitation and symbolic activities⁴² (online supplemental R51).

Caregivers need to be aware that most screening questionnaires use both repetitive behaviour and social behaviour in their scoring, and individuals with RTS may reach the cut-off for autism only because of their repetitive behaviour.

Social characteristics

Social behaviour is typically characterised by motivation to interact with others, and enhanced social skills,¹⁴² and ‘over-friendliness’

have been reported in >70% of individuals,^{132 139} while other studies using observational measures have suggested social motivation is aligned with typical development.¹⁴³

Parents have reported that their children are vulnerable to social exploitation, particularly as they age and gain independence.¹⁴⁷ While social motivation is likely to be heightened or preserved, social understanding (eg, the ability to think about what another may be thinking) is a relative weakness.¹⁴⁷ Individuals with RTS may benefit from learning appropriate skills to manage complex social situations, understand others' intentions, and reduce impulsivity (online supplemental R52).

Self-regulation, impulsivity and overactivity

Distractibility, impulsivity and overactivity have been noted from early descriptions of RTS.^{135 41} A short attention span was found in 76–90%,^{35 41} irrespective of the cognitive level.¹⁴² Studies yielded varying results regarding hyperactivity, and sometimes underactivity was noticed.^{135 61 147}

Increased pain threshold

Our joint experience indicates that many parents report their child has not shown evidence of pain or discomfort following a fall or an accident, even for gallstones, fractures, burns or other significant injuries and illnesses. Consequently, it is important not to underestimate subtle changes in behaviour. Medical professionals should be receptive to parent reports, and investigate proactively, even if the presence of a major health problem seems unlikely.

ADULT CARE

Over 90% of individuals with RTS reportedly survive to adulthood,⁷¹ and progress in diagnostics, knowledge and management abilities allows improved care for older individuals.⁶¹ Adults with RTS enjoy both social and occupational activities and show a varied experience of everyday life. A recently reported cohort of adults underscored the importance of continued management and follow-up.⁴² Half of all individuals required multispecialist follow-up and surgery during adulthood, usually more than once. Fortunately, significant morbidity in adulthood is not frequent. The adult natural history of RTS is defined by behavioural/psychiatric problems (83%), gastrointestinal problems (73%), skin and adnexa problems (65%), sleep problems (62%) and further concerns of high pain threshold, decreased mobility, hypersensitivity to noise and crowded places and vision difficulties or loss (approximately 50%).

The behavioural pattern remains broad but includes frequently rigid, repetitive and inflexible behaviours and emotional dysregulation (anxiety, aggression, frustration and/or a mood disorder) with reported age-dependent progression.^{141 144} Sleep problems show a consistent pattern of sleep apnoea, difficulty staying asleep and an increased need for sleep.⁴²

Clinical concerns include gastrointestinal problems with the highest frequency of constipation and in much lower frequency, other problems including eosinophilic oesophagitis. Retinal dysplasia increases with age,⁷² but does not cause severe loss of vision. Skin problems are variable but typically progressive, such as keloid formation, ingrowing fingernails and/or toenails (with infections) and poor wound healing.⁴² Hypertension, overweight, diabetes mellitus and cardiovascular problems do occur in adults but in a lower frequency compared with the general population.⁴² Treatment is as in the general population (online supplemental R53).

Data on fertility are limited but likely fertility is not impacted. Adults with RTS may be sexually active (25%).⁴² The risk to offspring is 50% with each pregnancy and familial recurrence has been reported. Thus, developmentally appropriate sexual education throughout the lifespan and especially at transition to adulthood is indicated^{43 61} (online supplemental R54). Contraceptive options should be discussed with the individual and family.

Reliable data on other adult problems such as dementia are not available.

CLINICAL TRIALS

CBP and p300 have multiple actions and functions, and clinical trials are aimed at decreasing or correcting abnormal functioning. Prenatally, variants in *CREBBP/EP300* can cause malformations unamenable to postnatal change (online supplemental R55). Variants can also cause dysplasias, and these may still be influenced postnatally. CBP/p300 are the 'master co-activators' of transcription in humans,¹⁴⁸ due to their involvement in many important pathways related to development and differentiation, and postnatal functions such as calcium signalling, nutrient metabolism, hypoxia and stress response.^{149–151} The latter may be influenced postnatally, thus obvious candidate dysfunctions are memory problems, behaviour, keloids and gastrointestinal problems (online supplemental R56).

Cognition

CREBBP/EP300 mutations cause epigenetic modifications that impact brain development and postnatal brain function of *cbp+/cbp-* mice.¹⁵⁰ Histone deacetylases inhibitors (HDACi) lead to an increase in the acetylation in mice. The HDACi suberoylanilide hydroxamic acid and trichostatin A have been shown to influence neurological functioning and long-term memory in mice.¹³⁵

Inhibitors of phosphodiesterase 4 (PDE4) prevent the hydrolysis of cAMP-enhancing PKA-dependent signalling upstream of *CREBBP*. The PDE4 inhibitor rolipram abolishes the long-term memory defects of *cbp+/cbp-* mice.¹⁵² Rolipram is currently tested in Fragile X syndrome and Alzheimer's disease (ClinicalTrials.gov Identifier: NCT03817684) that may be associated with reduced histone acetylation.¹⁵³ If successful it is a candidate to be used in individuals with RTS as well.

The HDAC inhibitor sodium valproate can pass the blood-brain barrier. A monocentric, double-blind, randomised, phase 2 trial, primary endpoint long-term memory, investigated the efficiency of sodium valproate after 1 year of treatment (30 mg/kg/d) in 41 children with RTS (ClinicalTrials.gov NCT01619644). Results using subtests of a neuropsychological test battery specifically designed for memory evaluation did not demonstrate a significant difference between the verum and placebo groups. As a side effect, a slight amelioration of some motor functions was found, and a trial with sodium valproate using motor skills as a primary outcome should be considered.

Keloids

Keloids develop most likely following an inciting stimulus (environmental factor) in genetically predisposed individuals. The unremitting accumulation of thick fibres of collagen I and III in the extracellular matrix of connective tissue places keloids among fibrotic disorders. Keloids are unique to humans, there are no adequate animal models, and a high interlesional and intralesional heterogeneity impairs the comparison of in vitro models.⁸⁷

The principal cell type responsible for keloids is the myofibroblast derived from resident skin fibroblasts through transdifferentiation or pluripotent stem cells,¹⁵⁴ but also keratinocytes play a distinct role based on their stemness signature.¹⁵⁵ Fibroblasts from keloids overexpress transforming growth factor (TGF)- β 1/2 and their receptors that interact with intracellular SMADs (Signaling Mothers Against Decapentaplegic), stimulate transcription of genes intervening in wound healing and cause persistent inflammation through continuous cell division, growth of extracellular matrix beyond the wound boundary, and abnormal vascularisation. Inhibition of the TGF- β 1/2 signalling pathway is, therefore, the main target of keloids therapeutics. Indeed, the TGF- β receptor inhibitor LY2109761 has been shown to suppress the secretion of keloid matrix components and to slow down the proliferation of derived fibroblasts.¹⁵⁶

Within keloids, several pathways are dysregulated epigenetic modifications including DNA methylation, histone modification and non-coding RNAs.^{157 158} Reverting these epigenetic anomalies to those of normal skin may also lead to successful treatment. Mutated CBP/p300 causes abnormal histone acetylation which may cause the epigenetic signature of keloids in individuals with RTS to be different from that of keloids from individuals with other disorders. Much of the work on histone modifications on keloids has been focused on the use of the HDAC inhibitor trichostatin A.¹⁵⁹ An increase in keloids of HDAC2 (and not of other HDACs),¹⁶⁰ suggests the topical application of an HDAC2 inhibitor to be a potential treatment.¹⁵⁷ CUDC-907 is an inhibitor of HDAC and also of the PI3K/AKT/mTOR pathway, and has been proposed as a candidate systemic drug.¹⁶¹

Another approach is using upregulation of the mitochondrial oxidative stress response and protein processing in the endoplasmic reticulum (ER).¹⁶² Treatment with an inhibitor of ER stress tauroursodeoxycholic acid (TUDCA) reduced scar formation in the rabbit ear.¹⁶² The potential use in men is favoured by the clinical approval of TUDCA in cholestasis, and its effective inhibition of ER stress in fibropulmonary disease in mice.¹⁶³ Single-cell RNA sequencing of keloid tissue has shown significant expansion of fibroblast and vascular endothelial cell subpopulations, responsible for the aberrant keloid fibrogenesis and angiogenesis. In fibroblasts *TWIST1* and *SMAD3* are top-upregulated genes and *TWIST1* inhibition has been proposed as a therapeutic target (Liu 2021). Tumour-related pathways are activated in fibroblast and endothelial cell subpopulations, accounting for the excessive proliferation and resistance to apoptosis of keloids,¹⁶⁴ and indicating the transferability and efficiency of medical therapies applied in tumours for the clinical treatment of keloids.

Author affiliations

¹Department of Medical Genetics, University Hospital of Bordeaux, and INSERM U1211, University of Bordeaux, 33076 Bordeaux, France

²Faculté de Chirurgie Dentaire, Université de Strasbourg, and Centre de référence des maladies rares orales et dentaires, Hôpitaux Universitaires de Strasbourg, Strasbourg, and Institut de Génétique et de Biologie Moléculaire et Cellulaire, INSERM U1258, Illkirch, France

³Department of Clinical Medicine, University of Bergen, 5020 Bergen, Norway

⁴Department of Anesthesiology, Cincinnati Children's Hospital, University of Cincinnati College of Medicine, Cincinnati, Ohio, USA

⁵Department of Medical Genetics, Haukeland University Hospital, Bergen, Norway and Division of Evolution, Infection and Genomics, School of Biological Sciences, Faculty of Biology, Medicine and Health, University of Manchester, Manchester, UK

⁶Instituto de Genética Médica y Molecular (INGEMM), Hospital Universitario La Paz, Madrid, Spain

⁷Department of Medical Genetics, Koc University School of Medicine (KUSOM), 34010 Istanbul, Turkey

⁸Laboratorio di Ricerca in Citogenetica medica e Genetica Molecolare, Centro di Ricerche e Tecnologie Biomediche IRCCS-Istituto Auxologico Italiano, Milano, Italy

⁹Department of Pediatrics, Medical Genetics Section, Virgen de la Arrixaca University Hospital, IMIB, CIBERER, Murcia, Spain

¹⁰Department of Pediatrics, Emma Children's Hospital, Amsterdam UMC, University of Amsterdam, Amsterdam, Netherlands

¹¹Fondazione IRCCS, Ca'Granda Ospedale Maggiore, 20122 Milan, Italy

¹²Fondazione Matilde Tettamanti Menotti De Marchi Onlus, Fondazione Monza e Brianza per il Bambino e la sua Mamma, Monza, Italy

¹³Department of Pediatrics, University of Tennessee College of Medicine, Chattanooga, Tennessee, USA

¹⁴Department of Pediatrics, Groote Schuur Hospital, University of Cape Town, Cape Town, South Africa

¹⁵Department of Pediatric Urology, Emma Children's Hospital, Amsterdam UMC, University of Amsterdam, Amsterdam, Netherlands

¹⁶Bartiméus Diagnostic Center for complex visual disorders, Zeist and Department of Ophthalmology, University Medical Center Utrecht, Utrecht, Netherlands

¹⁷School of Psychology, College of Health and Life Sciences, Aston University, Birmingham, UK

¹⁸Université de Paris, Laboratoire de Psychopathologie et Processus de Santé, Boulogne Billancourt, France

¹⁹MVZ - Humangenetik, University Medical Center, Johannes Gutenberg University Mainz, 55131 Mainz, Germany

²⁰Département de Génétique, SIDVA 91, Juvisy-sur-Orge, France

²¹Department of Pediatric Nephrology, Emma Children's Hospital, Amsterdam UMC, University of Amsterdam, Amsterdam, The Netherlands

²²Department of Clinical and Molecular Genetics, University Vall d'Hebron Barcelona Hospital Campus, Barcelona, Spain

²³Molecular Diagnostics Laboratory, Fundacion Rioja Salud, La Rioja, Spain

²⁴Department of Human Genetics, Amsterdam UMC, University of Amsterdam, Amsterdam, Netherlands

²⁵Psychology and Human Development Department, University College London, London, UK

²⁶Zodiak, Prinsenstichting, Purmerend, Netherlands

²⁷Rubinstein-Taybi Syndrome Support Group, Registered Charity, Rickmansworth, UK

²⁸Department of Medical Genetics, University of British Columbia, Vancouver, British Columbia, Canada

²⁹School of Psychology, University of Birmingham, Edgbaston, UK

³⁰Associazione Rubinstein-Taybi Syndrome-Una Vita Speciale, Organizzazione di Volontariato (ODV), Gornate Olona, Varese, Italy

³¹Division of Developmental and Behavioral Pediatrics, Cincinnati Children's Hospital Medical Center, and Department of Pediatrics, College of Medicine, University of Cincinnati, Cincinnati, Ohio, USA

³²Asociación Española para el Síndrome de Rubinstein-Taybi (AESRT), Madrid, Spain

³³Immunology, Hospital Universitario La Paz, IdiPaz, Madrid, Spain

³⁴French RTS Support Group, Paris, France

³⁵Unit of Molecular Diagnostics and Clinical Genetics, Hospital Universitari Son Espases, Health Research Institute of the Balearic Islands (IdISBa), Palma, Spain

³⁶Division of Human Genetics, Cincinnati Children's Hospital Medical Center, and Department of Pediatrics, Cincinnati School of Medicine, Cincinnati, Ohio, USA

³⁷Department of Pediatric Otolaryngology, Cincinnati Children's Hospital Medical Center, and Department of Otolaryngology – Head and Neck Surgery, University of Cincinnati College of Medicine, Cincinnati, Ohio, USA

³⁸Department of Anesthesiology, Amsterdam UMC, University of Amsterdam, Amsterdam, The Netherlands

³⁹Institution of Pediatrics, University of Debrecen Clinical Centre, Debrecen, Hungary

⁴⁰Division of Paediatric Endocrinology, Department of Paediatrics, Erasmus University Medical Centre, Sophia Children's Hospital, Rotterdam, The Netherlands

⁴¹Department of Pediatric Gastroenterology, Emma Children's Hospital, Amsterdam UMC, University Amsterdam, Amsterdam, Netherlands

⁴²European Reference Network on Rare Congenital Malformations and Rare Intellectual Disability (ERN-ITHACA), Robert Debré University Hospital, Paris, France

Correction notice The article has been corrected since it was published online. An author's name and affiliation have been amended.

Acknowledgements We are indebted and thank the ERN-ITHACA and all the Rubinstein-Taybi syndrome support groups and families.

Contributors DL, AB-Z, CB, EBC, SDH, SG-M, HK, LL, VLG, LAM, DM, FS, CAS, LT, JAVdZ, MMVG, JV-G, JW and RH researched data for the article. DL, AB-Z, CB, EBC, SDH, SG-M, HK, LL, VLG, LAM, DM, FS, CAS, LT, JAVdZ, MMVG, JV-G, JW, J-LA, OB, PB, AHMB, AMC-G, ED-G, FAD, PF, CR-F, EH, SAH, CM, JM, SMM, CO, EP, AR, IR, RRP, JR, AS, FS-S, BNS, DFS, MFS, KS, ET, NT, IVP, DCMVDK, MPVW, KV, SW and RH contributed to discussion of the content. DL, AB-Z, CB, EBC, SDH, SG-M, HK, LL, VLG, LAM, DM, FS, CAS, LT, JAVdZ, MMVG, JV-G, JW and RH wrote the article. DL and RH reviewed and/or edited the article. AB-Z, CB, EBC, SDH, SG-M, HK, LL, VLG, LAM, DM, FS, CAS, LT, JAVdZ, MMVG, JV-G, JW are the second authors.

Funding This publication has been supported by the European Reference Network on Rare Congenital Malformations and Rare Intellectual Disability (ERN-ITHACA). ERN-ITHACA is partly co-funded by the Health Program of the European Union.

Competing interests None declared.

Patient consent for publication Consent obtained from parent(s)/guardian(s).

Ethics approval The authors affirm that human research participants provided informed consent, for publication of the images in Figure 1.

Provenance and peer review Not commissioned; externally peer reviewed.

Author note The recommendations are included as online supplemental file 2. They have been part of the peer-reviewed manuscript files accepted for publication, and constitute an integral part of the article.

Supplemental material This content has been supplied by the author(s). It has not been vetted by BMJ Publishing Group Limited (BMJ) and may not have been peer-reviewed. Any opinions or recommendations discussed are solely those of the author(s) and are not endorsed by BMJ. BMJ disclaims all liability and responsibility arising from any reliance placed on the content. Where the content includes any translated material, BMJ does not warrant the accuracy and reliability of the translations (including but not limited to local regulations, clinical guidelines, terminology, drug names and drug dosages), and is not responsible for any error and/or omissions arising from translation and adaptation or otherwise.

Open access This is an open access article distributed in accordance with the Creative Commons Attribution Non Commercial (CC BY-NC 4.0) license, which permits others to distribute, remix, adapt, build upon this work non-commercially, and license their derivative works on different terms, provided the original work is properly cited, appropriate credit is given, any changes made indicated, and the use is non-commercial. See: <http://creativecommons.org/licenses/by-nc/4.0/>.

ORCID iDs

Didier Lacombe <http://orcid.org/0000-0002-8956-2207>

Hülya Kayserili <http://orcid.org/0000-0003-0376-499X>

Lidia Larizza <http://orcid.org/0000-0002-1367-7227>

Katalin Szakszon <http://orcid.org/0000-0002-2659-7488>

Irene Valenzuela Palafoll <http://orcid.org/0000-0003-2350-6058>

REFERENCES

- Rubinstein JH, Taybi H. Broad thumbs and toes and facial abnormalities. A possible mental retardation syndrome. *Am J Dis Child* 1963;105:588–608.
- Petrij F, Giles RH, Dauwerse HG, et al. Rubinstein-Taybi syndrome caused by mutations in the transcriptional co-activator CBP. *Nature* 1995;376:348–51.
- Roelfsema JH, White SJ, Ariyürek Y, et al. Genetic heterogeneity in Rubinstein-Taybi syndrome: mutations in both the CBP and Ep300 genes cause disease. *Am J Hum Genet* 2005;76:572–80.
- Menke LA, Gardeitchik T, Hammond P, et al. Further delineation of an entity caused by CREBBP and Ep300 mutations but not resembling Rubinstein-Taybi syndrome. *Am J Med Genet A* 2018;176:862–76.
- Fergelot P, Van Belzen M, Van Gils J, et al. Phenotype and genotype in 52 patients with Rubinstein-Taybi syndrome caused by Ep300 mutations. *Am J Med Genet A* 2016;170:3069–82. 10.1002/ajmg.a.37940 Available: <https://onlinelibrary.wiley.com/doi/10.1002/ajmg.a.37940>
- Larizza L, Finelli P. Developmental disorders with intellectual disability driven by chromatin dysregulation: clinical overlaps and molecular mechanisms. *Clin Genet* 2019;95:231–40.
- Chrivia JC, Kwok RP, Lamb N, et al. Phosphorylated CREB binds specifically to the nuclear protein CBP. *Nature* 1993;365:855–9.
- Allis CD, Berger SL, Cote J, et al. New nomenclature for chromatin-modifying enzymes. *Cell* 2007;131:633–6.
- Bedford DC, Kasper LH, Fukuyama T, et al. Target gene context influences the transcriptional requirement for the Kat3 family of CBP and P300 Histone Acetyltransferases. *Epigenetics* 2010;5:9–15.
- Wang L, Tang Y, Cole PA, et al. Structure and chemistry of the P300/CBP and Rtt109 histone acetyltransferases: implications for histone acetyltransferase evolution and function. *Curr Opin Struct Biol* 2008;18:741–7.
- Pérez-Grijalva V, García-Oguiza A, López M, et al. New insights into genetic variant spectrum and genotype-phenotype correlations of Rubinstein-Taybi syndrome in 39 CREBBP-positive patients. *Mol Genet Genomic Med* 2019;7:e972.
- Cross E, Duncan-Flavell PJ, Howarth RJ, et al. Screening of a large Rubinstein-Taybi cohort identified many novel variants and emphasizes the importance of the CREBBP histone acetyltransferase domain. *Am J Med Genet A* 2020;182:2508–20.
- Cohen JL, Schrier Vergano SA, Mazzola S, et al. Ep300-related Rubinstein-Taybi syndrome: highlighted rare phenotypic findings and a genotype-phenotype meta-analysis of 74 patients. *Am J Med Genet A* 2020;182:2926–38.
- Negri G, Magini P, Milani D, et al. From whole gene deletion to point mutations of Ep300-positive Rubinstein-Taybi patients: new insights into the mutational spectrum and peculiar clinical hallmarks. *Hum Mutat* 2016;37:175–83.
- Van Gils J, Magdinier F, Fergelot P, et al. Rubinstein-Taybi syndrome: a model of epigenetic disorder. *Genes (Basel)* 2021;12:968.
- Coupry I, Monnet L, Attia AAEM, et al. Analysis of CBP (CREBBP) gene deletions in Rubinstein-Taybi syndrome patients using real-time quantitative PCR. *Hum Mutat* 2004;23:278–84.
- Rusconi D, Negri G, Colapietro P, et al. Characterization of 14 novel deletions underlying Rubinstein-Taybi syndrome: an update of the CREBBP deletion repertoire. *Hum Genet* 2015;134:613–26.
- Schorry EK, Keddache M, Lanphear N, et al. Genotype-phenotype correlations in Rubinstein-Taybi syndrome. *Am J Med Genet A* 2008;146A:2512–9. 10.1002/ajmg.a.32424 Available: <https://onlinelibrary.wiley.com/doi/10.1002/ajmg.a.32424>
- Spena S, Milani D, Rusconi D, et al. Insights into genotype-phenotype correlations from CREBBP point Mutation screening in a cohort of 46 Rubinstein-Taybi syndrome patients. *Clin Genet* 2015;88:431–40.
- Banka S, Sayer R, Breen C, et al. Genotype-phenotype specificity in Menke-Hennekam syndrome caused by missense variants in exon 30 or 31 of CREBBP. *Am J Med Genet A* 2019;179:1058–62.
- De Guzman RN, Liu HY, Martinez-Yamout M, et al. Solution structure of the Taz2 (Ch3) domain of the transcriptional adaptor protein Cbp1. *J Mol Biol* 2000;303:243–53.
- Ponting CP, Blake DJ, Davies KE, et al. ZZ and TAZ: new putative zinc fingers in dystrophin and other proteins. *Trends Biochem Sci* 1996;21:11–3.
- Richards S, Aziz N, Bale S, et al. Standards and guidelines for the interpretation of sequence variants: a joint consensus recommendation of the American college of medical genetics and genomics and the Association for molecular pathology. *Genet Med* 2015;17:405–24.
- Aref-Eshghi E, Kerkhof J, Pedro VP, et al. Evaluation of DNA methylation epigenatures for diagnosis and phenotype correlations in 42 mendelian neurodevelopmental disorders. *Am J Hum Genet* 2020;106:356–70.
- Gervasini C, Castronovo P, Bentivegna A, et al. High frequency of mosaic CREBBP deletions in Rubinstein-Taybi syndrome patients and mapping of somatic and germ-line Breakpoints. *Genomics* 2007;90:567–73.
- Chiang P-W, Lee N-C, Chien N, et al. Somatic and germ-line mosaicism in Rubinstein-Taybi syndrome. *Am J Med Genet A* 2009;149A:1463–7.
- Bartsch O, Kress W, Kempf O, et al. Inheritance and variable expression in Rubinstein-Taybi syndrome. *Am J Med Genet A* 2010;152A:2254–61. 10.1002/ajmg.a.33598 Available: <https://onlinelibrary.wiley.com/doi/10.1002/ajmg.a.33598>
- Van-Gils J, Naudion S, Toutain J, et al. Fetal phenotype of Rubinstein-Taybi syndrome caused by CREBBP mutations. *Clin Genet* 2019;95:420–6.
- Cardalliac C, Vincent M, Joubert M, et al. Rubinstein-Taybi syndrome in a fetus: contribution of 2- and 3-dimensional ultrasonography. *J Ultrasound Med* 2018;37:531–4.
- Levetan C, Van Gils J, Saba A, et al. Rubinstein-Taybi syndrome: presentation in the first month of life. *J Pediatr* 2022;249:106–10.
- Lewis C, Skirton H, Jones R. Living without a diagnosis: the parental experience. *Genet Test Mol Biomarkers* 2010;14:807–15.
- Allanson JE, Hennekam RC. Rubinstein-Taybi syndrome: objective evaluation of craniofacial structure. *Am J Med Genet* 1997;71:414–9.
- Moe JK, Holland MD, Johnson RK. Breastfeeding practices of infants with Rubinstein-Taybi syndrome. *J Hum Lact* 1998;14:311–5.
- Beets L, Rodriguez-Fonseca C, Hennekam RC. Growth charts for individuals with Rubinstein-Taybi syndrome. *Am J Med Genet A* 2014;164A:2300–9.
- Hennekam RC, Van Den Boogaard MJ, Sibbles BJ, et al. Rubinstein-Taybi syndrome in the Netherlands. *Am J Med Genet Suppl* 1990;6:17–29. 10.1002/ajmg.1320370604 Available: <http://doi.wiley.com/10.1002/ajmg.1320370604>
- Wild KT, Nomakuchi TT, Sheppard SE, et al. Hyperinsulinism in an individual with an Ep300 variant of Rubinstein-Taybi syndrome. *Am J Med Genet A* 2021;185:1251–5.
- Welters A, El-Khairi R, Dastamani A, et al. Persistent hyperinsulinaemic hypoglycaemia in children with Rubinstein-Taybi syndrome. *Eur J Endocrinol* 2019;181:121–8.
- Muukkonen L, Männistö J, Jääskeläinen J, et al. The effect of hypoglycaemia on neurocognitive outcome in children and adolescents with transient or persistent congenital hyperinsulinism. *Dev Med Child Neurol* 2019;61:451–7.
- Thornton PS, Stanley CA, De Leon DD, et al. Recommendations from the pediatric endocrine society for evaluation and management of persistent hypoglycemia in neonates, infants, and children. *J Pediatr* 2015;167:238–45.
- Marzuillo P, Grandone A, Coppola R, et al. Novel cAMP binding protein-BP (CREBBP) mutation in a girl with Rubinstein-Taybi syndrome, GH deficiency, Arnold Chiari malformation and pituitary hypoplasia. *BMC Med Genet* 2013;14:28.
- Stevens CA, Carey JC, Blackburn BL. Rubinstein-Taybi syndrome: a natural history study. *Am J Med Genet Suppl* 1990;6:30–7. 10.1002/ajmg.1320370605 Available: <http://doi.wiley.com/10.1002/ajmg.1320370605>
- Douzgou S, Dell'Oro J, Fonseca CR, et al. The natural history of adults with Rubinstein-Taybi syndrome: a families-reported experience. *Eur J Hum Genet* 2022;30:841–7.
- Quint EH. Menstrual and reproductive issues in adolescents with physical and developmental disabilities. *Obstet Gynecol* 2014;124:367–75.

- 44 Stevens CA. Intestinal malrotation in Rubinstein–Taybi syndrome. *Am J Med Genet A* 2015;167A:2399–401. 10.1002/ajmg.a.37167 Available: <https://onlinelibrary.wiley.com/doi/10.1002/ajmg.a.37167>
- 45 Rubinstein JH. Broad thumb-hallux (Rubinstein-Taybi) syndrome 1957-1988. *Am J Med Genet* 1990;37:3–16. 10.1002/ajmg.1320370603 Available: <http://doi.wiley.com/10.1002/ajmg.v37%3A6%2B>
- 46 Grunow JE. Gastroesophageal reflux in Rubinstein–Taybi syndrome. *J Pediatr Gastroenterol Nutr* 1982;1:273–4.
- 47 Rosen R, Vandenplas Y, Singendonk M, et al. Pediatric gastroesophageal reflux clinical practice guidelines: joint recommendations of the North American society for pediatric gastroenterology, hepatology, and nutrition and the European society for pediatric gastroenterology, hepatology, and nutrition. *J Pediatr Gastroenterol Nutr* 2018;66:516–54.
- 48 Nikaki K, Rybak A, Nakagawa K, et al. Rumination syndrome in children presenting with refractory gastroesophageal reflux symptoms. *J Pediatr Gastroenterol Nutr* 2020;70:330–5.
- 49 Noble A, Drouin E, Faure C. Eosinophilic esophagitis and gastritis in Rubinstein-Taybi syndrome. *J Pediatr Gastroenterol Nutr* 2007;44:498–500.
- 50 Vaezi MF, Yang Y-X, Howden CW. Complications of proton pump inhibitor therapy. *Gastroenterology* 2017;153:35–48.
- 51 Hassall E. Decisions in diagnosing and managing chronic gastroesophageal reflux disease in children. *J Pediatr* 2005;146(3 Suppl):S3–12.
- 52 Kumar P, Thota PN. Barrett's esophagus in Rubinstein-Taybi syndrome. *Cureus* 2020;12:e11709.
- 53 Tabbers MM, DiLorenzo C, Berger MY, et al. Evaluation and treatment of functional constipation in infants and children: evidence-based recommendations from ESPGHAN and NASPGHAN. *J Pediatr Gastroenterol Nutr* 2014;58:258–74.
- 54 Lee JS, Byun CK, Kim H, et al. Clinical and mutational spectrum in Korean patients with Rubinstein–Taybi syndrome: the spectrum of brain MRI abnormalities. *Brain Dev* 2015;37:402–8.
- 55 Yu S, Wu B, Qian Y, et al. Clinical exome sequencing identifies novel CREBBP variants in 18 Chinese Rubinstein-Taybi syndrome kids with high frequency of polydactyly. *Mol Genet Genomic Med* 2019;7:e1009.
- 56 Choi N, Kim HY, Lim BC, et al. Genetic and clinical heterogeneity in Korean patients with Rubinstein-Taybi syndrome. *Mol Genet Genomic Med* 2021;9:e1791.
- 57 Tekendo-Ngongang C, Owosola B, Fleischer N, et al. Rubinstein-Taybi syndrome in diverse populations. *Am J Med Genet A* 2020;182:2939–50.
- 58 Hanauer D, Argilla M, Wallerstein R. Rubinstein-Taybi syndrome and hypoplastic left heart. *Am J Med Genet* 2002;112:109–11.
- 59 Negri G, Milani D, Colapietro P, et al. Clinical and molecular characterization of Rubinstein-Taybi syndrome patients carrying distinct novel mutations of the Ep300 gene. *Clin Genet* 2015;87:148–54.
- 60 Bentivegna A, Milani D, Gervasini C, et al. Rubinstein-Taybi syndrome: spectrum of crebbp mutations in Italian patients. *BMC Med Genet* 2006;7:77.
- 61 Stevens CA, Pouncey J, Knowles D. Adults with Rubinstein–Taybi syndrome. *Am J Med Genet A* 2011;155A:1680–4. 10.1002/ajmg.a.34058 Available: <https://onlinelibrary.wiley.com/doi/10.1002/ajmg.a.34058>
- 62 Saettini F, Herriot R, Prada E, et al. Prevalence of immunological defects in a cohort of 97 Rubinstein-Taybi syndrome patients. *J Clin Immunol* 2020;40:851–60.
- 63 Lougaris V, Facchini E, Baronio M, et al. Progressive severe B cell deficiency in pediatric Rubinstein-Taybi syndrome. *Clin Immunol* 2016;173:181–3.
- 64 Bradford L, Ross MK, Minso J, et al. Interstitial lung disease in children with Rubinstein-Taybi syndrome. *Pediatr Pulmonol* 2022;57:264–72.
- 65 Kosaki R, Kikuchi S, Koinuma G, et al. Two patients with Rubinstein-Taybi syndrome and severe pulmonary interstitial involvement. *Am J Med Genet A* 2010;152A:1844–6. 10.1002/ajmg.a.33382 Available: <https://onlinelibrary.wiley.com/doi/10.1002/ajmg.a.33382>
- 66 Bounakis N, Karampalis C, Sharp H, et al. Surgical treatment of scoliosis in Rubinstein-Taybi syndrome type 2: a case report. *J Med Case Rep* 2015;9:10.
- 67 Choi HS, Yu JJ, Kim Y-H, et al. Pulmonary hypertension due to obstructive sleep apnea in a child with Rubinstein-Taybi syndrome. *Korean J Pediatr* 2012;55:212–4.
- 68 Candan S, Ornek C, Candan F. Ocular anomalies in Rubinstein–Taybi syndrome: a further case report and review of the literature. *Clin Dysmorphol* 2014;23:138–42.
- 69 DaCosta J, Brookes J. Infantile glaucoma in Rubinstein–Taybi syndrome. *Eye (Lond)* 2012;26:1270–1.
- 70 Huang F-R, Zhang A-M, Xu J, et al. A clinical characteristics and genetic analysis of a case of Rubinstein-Taybi syndrome with glaucoma. *Eur Rev Med Pharmacol Sci* 2021;25:1447–54.
- 71 Milani D, Manzoni FMP, Pezzani L, et al. Rubinstein-Taybi syndrome: clinical features, genetic basis, diagnosis, and management. *Ital J Pediatr* 2015;41:4.
- 72 van Genderen MM, Kinds GF, Riemsdijk FC, et al. Ocular features in Rubinstein-Taybi syndrome: investigation of 24 patients and review of the literature. *Br J Ophthalmol* 2000;84:1177–84.
- 73 Enomoto Y, Yokoi T, Tsurusaki Y, et al. Divergent variant patterns among 19 patients with Rubinstein-Taybi syndrome uncovered by comprehensive genetic analysis including whole genome sequencing. *Clin Genet* 2022;101:335–45.
- 74 Naik JM, Naik MN, Ali MJ. Lacrimal drainage anomalies in Rubinstein-Taybi syndrome: case report and review of literature. *Orbit* 2019;38:335–7.
- 75 Yu PT, Luk H-M, Lo IFM. Rubinstein-Taybi syndrome in Chinese population with four novel mutations. *Am J Med Genet A* 2021;185:267–73.
- 76 Stocks RMS, Egerman R, Thompson JW, et al. Airway management of the severely retrognathic child: use of the laryngeal mask airway. *Ear Nose Throat J* 2002;81:223–6.
- 77 Peñaranda A, Cerón M. Rubinstein-Taybi syndrome and mixed bilateral hypacusia case report. *Otol Neurotol* 2007;28:501–3.
- 78 Naimi DR, Munoz J, Rubinstein J, et al. Rubinstein–Taybi syndrome: an immune deficiency as a cause for recurrent infections. *Allergy Asthma Proc* 2006;27:281–4.
- 79 Torres LC, Sugayama SMM, Arslanian C, et al. Evaluation of the immune humoral response of Brazilian patients with Rubinstein-Taybi syndrome. *Braz J Med Biol Res* 2010;43:1215–24.
- 80 Hennekam RCM. Rubinstein–Taybi syndrome. *Eur J Hum Genet* 2006;14:981–5.
- 81 Zucconi M, Ferini-Strambi L, Erminio C, et al. Obstructive sleep apnea in the Rubinstein-Taybi syndrome. *Respiration* 1993;60:127–32.
- 82 Bruni O, Ottaviano S, Guidetti V, et al. The sleep disturbance scale for children (SDSC): construction and validation of an instrument to evaluate sleep disturbances in childhood and adolescence. *J Sleep Res* 1996;5:251–61.
- 83 Roland PS, Rosenfeld RM, Brooks LJ, et al. Clinical practice guideline: polysomnography for sleep-disordered breathing prior to tonsillectomy in children. *Otolaryngol Head Neck Surg* 2011;145(1 Suppl):S1–15.
- 84 Stirt JA. Succinylcholine in Rubinstein-Taybi syndrome. *Anesthesiology* 1982;57:429.
- 85 Darlong V, Pandey R, Garg R, et al. Perioperative management of a patient of Rubinstein-Taybi syndrome with ovarian cyst for laparotomy. *J Anaesthesiol Clin Pharmacol* 2014;30:422:422–4..
- 86 Gathuya Z, Bosenberg A. Anaesthesia and Rubinstein-Taybi syndrome. *South Afr J Anaesth Analg* 2005;11:135–7.
- 87 Limandjaja GC, Niessen FB, Scheper RJ, et al. The Keloid disorder: heterogeneity, Histopathology, mechanisms and models. *Front Cell Dev Biol* 2020;8:360.
- 88 Jfri A, Rajeh N, Karkashan E. A case of multiple spontaneous keloid scars. *Case Rep Dermatol* 2015;7:156–60.
- 89 van de Kar AL, Houge G, Shaw AC, et al. Keloids in Rubinstein-Taybi syndrome: a clinical study. *Br J Dermatol* 2014;171:615–21. 10.1111/bjd.13124 Available: <https://onlinelibrary.wiley.com/doi/10.1111/bjd.13124>
- 90 Bienias W, Pastuszka M, Gutfreund K. Letter to the editor. *Arch Med Sci* 2015;11:232–4.
- 91 Betarbet U, Blalock TW. Keloids: a review of etiology, prevention, and treatment. *J Clin Aesthet Dermatol* 2020;13:33–43.
- 92 Siraganian PA, Rubinstein JH, Miller RW. Keloids and neoplasms in the Rubinstein-Taybi syndrome. *Med Pediatr Oncol* 1989;17:485–91.
- 93 Boot MV, van Belzen MJ, Overbeek LI, et al. Benign and malignant tumors in Rubinstein-Taybi syndrome. *Am J Med Genet A* 2018;176:597–608.
- 94 Rokunohe D, Nakano H, Akasaka E, et al. Rubinstein-Taybi syndrome with multiple pilomatricomas: the first case diagnosed by CREBBP mutation analysis. *J Dermatol Sci* 2016;83:240–2.
- 95 Yagi Y, Kuwatsuka Y, Asai M, et al. Coexistence of keloids and pilomatricoma in a patient with Rubinstein-Taybi syndrome. *Dermatol Online J* 2018;24:13030/qt4rq2k5fr.
- 96 Jones CD, Ho W, Robertson BF, et al. Pilomatricoma: a comprehensive review of the literature. *Am J Dermatopathol* 2018;40:631–41.
- 97 Pavone P, Praticò AD, Falsaperla R, et al. Congenital generalized hypertrichosis: the skin as a clue to complex malformation syndromes. *Ital J Pediatr* 2015;41:55.
- 98 Uroweb - European Association of Urology. EAU guidelines on paediatric urology - INTRODUCTION - Uroweb. Available: [https://uroweb.org/guidelines/paediatric-urology/Accessed 11 Oct 2023](https://uroweb.org/guidelines/paediatric-urology/Accessed%2011%20Oct%202023).
- 99 de Castro Coelho F, Câmara S, Alves I, et al. Septate uterus in a girl with Rubinstein–Taybi syndrome. *Case Rep Pediatr* 2018;2018:7878156. 10.1155/2018/7878156 Available: <https://doi.org/10.1155/2018/7878156>
- 100 Hamilton MJ, Newbury-Ecob R, Holder-Espinasse M, et al. Rubinstein-Taybi syndrome type 2: report of nine new cases that extend the phenotypic and genotypic spectrum. *Clin Dysmorphol* 2016;25:135–45.
- 101 López M, García-Oguiza A, Armstrong J, et al. Rubinstein-Taybi 2 associated to novel Ep300 mutations: deepening the clinical and genetic spectrum. *BMC Med Genet* 2018;19:36.
- 102 Sharma N, Mali AM, Bapat SA. Spectrum of crebbp mutations in Indian patients with Rubinstein-Taybi syndrome. *J Biosci* 2010;35:187–202.
- 103 Wincent J, Luthman A, van Belzen M, et al. Crebbp and Ep300 mutational spectrum and clinical presentations in a cohort of Swedish patients with Rubinstein-Taybi syndrome. *Mol Genet Genomic Med* 2016;4:39–45.
- 104 Wood VE, Rubinstein JH. Surgical treatment of the thumb in the Rubinstein-Taybi syndrome. *J Hand Surg Br* 1987;12:166–72.
- 105 Cerqueiro-Mosquera J, Fleming AN. The bilobed flap: a new application in the reconstruction of congenital thumb deviation. *J Hand Surg Br* 2000;25:262–5.
- 106 Jain A, Rehman S, Smith G. Long-term results following osteotomy of the thumb delta phalanx in Rubinstein-Taybi syndrome. *J Hand Surg Eur Vol* 2010;35:296–301.
- 107 Le Mapihan M, Badina A, Pannier S, et al. Non-vascularized toe phalanx transfer for correction of severe clinodactyly of the thumb in Rubinstein-Taybi syndrome. *J Hand Surg Eur Vol* 2020;45:715–21.

- 108 Mehlman CT, Rubinstein JH, Roy DR. Instability of the patellofemoral joint in Rubinstein-Taybi syndrome. *J Pediatr Orthop* 1998;18:508–11.
- 109 Lázaro JS, Herráez SS, Gállego LD, *et al.* Spontaneous patella dislocation in Rubinstein-Taybi syndrome. *Knee* 2007;14:68–70.
- 110 Cazalets JR, Bestaven E, Doat E, *et al.* Evaluation of motor skills in children with Rubinstein-Taybi syndrome. *J Autism Dev Disord* 2017;47:3321–32.
- 111 Stevens CA. Patellar dislocation in Rubenstein-Taybi syndrome. *Am J Med Genet* 1997;72:188–90.
- 112 Mirzatołooei F. Patellofemoral ligament reconstruction in a patient with Rubinstein-Taybi syndrome. *Acta Med Iran* 2014;52:228–30.
- 113 Shah H, Singh G, Vijayan S, *et al.* Second report of slipped capital femoral epiphysis in Rubinstein-Taybi syndrome. *Clin Dysmorphol* 2011;20:55–7.
- 114 Yamamoto T, Kurosawa K, Masuno M, *et al.* Congenital anomaly of cervical vertebrae is a major complication of Rubinstein-Taybi syndrome. *Am J Med Genet A* 2005;135:130–3.
- 115 Hennekam RCM, Van Doorne JM. Oral aspects of Rubinstein-Taybi syndrome. *Am J Med Genet* 1990;37:42–7. Available <http://doi.wiley.com/10.1002/ajmg.v37%3A6%2B>
- 116 Bloch-Zupan A, Stachtou J, Emmanouil D, *et al.* Oro-dental features as useful diagnostic tool in Rubinstein-Taybi syndrome. *Am J Med Genet A* 2007;143A:570–3.
- 117 Laugel-Haushalter V, Paschaki M, Thibault-Carpentier C, *et al.* Molars and incisors: show your Microarray IDS. *BMC Res Notes* 2013;6:113.
- 118 Clinical Affairs Committee-behavior management subcommittee, American Academy of pediatric dentistry. Guideline on behavior guidance for the pediatric dental patient. *Pediatr Dent* 2015;37:57–70.
- 119 Ashley P, Anand P, Andersson K. Best clinical practice guidance for conscious sedation of children undergoing dental treatment: an EAPD policy document. *Eur Arch Paediatr Dent* 2021;22:989–1002.
- 120 Miller RW, Rubinstein JH. Tumors in Rubinstein-Taybi syndrome. *Am J Med Genet* 1995;56:112–5. Available <https://onlinelibrary.wiley.com/toc/10968628/56/1>
- 121 Ajmone PF, Avignone S, Gervasini C, *et al.* Rubinstein-Taybi syndrome: new neuroradiological and neuropsychiatric insights from a multidisciplinary approach. *Am J Med Genet B Neuropsychiatr Genet* 2018;177:406–15.
- 122 Giacobbe A, Ajmone PF, Milani D, *et al.* Electroclinical phenotype in Rubinstein-Taybi syndrome. *Brain Dev* 2016;38:563–70.
- 123 Mishra S, Agarwalla SK, Potpalle DR, *et al.* Rubinstein-Taybi syndrome with agenesis of corpus callosum. *J Pediatr Neurosci* 2015;10:175–7.
- 124 Hadziev K, Gyorsok Z, Till A, *et al.* Rubinstein-Taybi syndrome 2 with cerebellar abnormality and neural tube defect. *Clin Dysmorphol* 2019;28:137–41.
- 125 Guion-Almeida ML, Richieri-Costa A. Callosal agenesis, Iris coloboma, and megacolon in a Brazilian boy with Rubinstein-Taybi syndrome. *Am J Med Genet* 1992;43:929–31. 10.1002/ajmg.1320430604 Available: <https://onlinelibrary.wiley.com/toc/10968628/43/6>
- 126 Tsai AC-H, Dossset CJ, Walton CS, *et al.* Exon deletions of the Ep300 and CREBBP genes in two children with Rubinstein-Taybi syndrome detected by aCGH. *Eur J Hum Genet* 2011;19:43–9.
- 127 Tanaka T, Ling BC, Rubinstein JH, *et al.* Rubinstein-Taybi syndrome in children with tethered spinal cord. *J Neurosurg* 2006;105(4 Suppl):261–4.
- 128 Cantani A, Gagliesi D. Rubinstein-Taybi syndrome. Review of 732 cases and analysis of the typical traits. *Eur Rev Med Pharmacol Sci* 1998;2:81–7.
- 129 Hou J-W. Rubinstein-Taybi syndrome: clinical and molecular cytogenetic studies. *Acta Paediatr Taiwan* 2005;46:143–8.
- 130 Kumar S, Suthar R, Panigrahi I, *et al.* Rubinstein-Taybi syndrome: clinical profile of 11 patients and review of literature. *Indian J Hum Genet* 2012;18:161–6.
- 131 Dosman CF, Andrews D, Goulden KJ. Evidence-based milestone ages as a framework for developmental surveillance. *Paediatr Child Health* 2012;17:561–8.
- 132 Hennekam RC, Baselier AC, Beyaert E, *et al.* Psychological and speech studies in Rubinstein-Taybi syndrome. *Am J Ment Retard* 1992;96:645–60.
- 133 Taupiac E, Lacombe D, Thiébaud E, *et al.* Psychomotor, cognitive, and socio-emotional developmental profiles of children with Rubinstein-Taybi syndrome and a severe intellectual disability. *J Intellect Dev Disabil* 2021;46:80–9.
- 134 Alarcón JM, Malleret G, Touzani K, *et al.* Chromatin acetylation, memory, and LTP are impaired in CBP+/- mice: a model for the cognitive deficit in Rubinstein-Taybi syndrome and its amelioration. *Neuron* 2004;42:947–59.
- 135 Korzus E, Rosenfeld MG, Mayford M. CBP histone acetyltransferase activity is a critical component of memory consolidation. *Neuron* 2004;42:961–72.
- 136 Viosca J, Lopez-Atalaya JP, Olivares R, *et al.* Syndromic features and mild cognitive impairment in mice with genetic reduction on P300 activity: differential contribution of P300 and CBP to Rubinstein-Taybi syndrome etiology. *Neurobiol Dis* 2010;37:186–94.
- 137 Benito E, Barco A. CREB's control of intrinsic and synaptic plasticity: implications for CREB-dependent memory models. *Trends Neurosci* 2010;33:230–40.
- 138 Oliveira AMM, Abel T, Brindle PK, *et al.* Differential role for CBP and P300 CREB-binding domain in motor skill learning. *Behav Neurosci* 2006;120:724–9.
- 139 Boer H, Langton J, Clarke D. Development and behaviour in genetic syndromes: Rubinstein-Taybi syndrome. *Res Intellect Disabil* 1999;12:302–7. 10.1111/j.1468-3148.1999.tb00086.x Available: <https://onlinelibrary.wiley.com/toc/14683148/12/4>
- 140 Arron K, Oliver C, Moss J, *et al.* The prevalence and phenomenology of self-injurious and aggressive behaviour in genetic syndromes. *J Intellect Disabil Res* 2011;55:109–20.
- 141 Yagihashi T, Kosaki K, Okamoto N, *et al.* Age-dependent change in behavioral feature in Rubinstein-Taybi syndrome. *Congenit Anom (Kyoto)* 2012;52:82–6.
- 142 Galéra C, Taupiac E, Fraitse S, *et al.* Socio-behavioral characteristics of children with Rubinstein-Taybi syndrome. *J Autism Dev Disord* 2009;39:1252–60.
- 143 Crawford H, Waite J, Oliver C. Diverse profiles of anxiety related disorders in fragile X, Cornelia de Lange and Rubinstein-Taybi syndromes. *J Autism Dev Disord* 2017;47:3728–40.
- 144 Waite J, Moss J, Beck SR, *et al.* Repetitive behavior in Rubinstein-Taybi syndrome: parallels with autism spectrum Phenomenology. *J Autism Dev Disord* 2015;45:1238–53.
- 145 Perry V, Ellis K, Moss J, *et al.* Executive function, repetitive behaviour and restricted interests in neurodevelopmental disorders. *Res Dev Disabil* 2022;122:104166.
- 146 Waite J, Beck SR, Powis L, *et al.* The executive function account of repetitive behavior: evidence from Rubinstein-Taybi syndrome. *Am J Intellect Dev Disabil* 2023;128:49–65.
- 147 Ellis K, Moss J, Stefanidou C, *et al.* The development of early social cognitive skills in neurogenetic syndromes associated with autism: Cornelia de Lange, fragile X and Rubinstein-Taybi syndromes. *Orphanet J Rare Dis* 2021;16:488.
- 148 Breen ME, Mapp AK. Modulating the masters: chemical tools to dissect CBP and P300 function. *Curr Opin Chem Biol* 2018;45:195–203.
- 149 Dancy BM, Cole PA. Protein lysine acetylation by P300/CBP. *Chem Rev* 2015;115:2419–52.
- 150 Valor LM, Pulopulos MM, Jimenez-Minchan M, *et al.* Ablation of CBP in forebrain principal neurons causes modest memory and transcriptional defects and a dramatic reduction of histone acetylation but does not affect cell viability. *J Neurosci* 2011;31:1652–63.
- 151 Wang F, Marshall CB, Ikura M. Transcriptional/epigenetic regulator CBP/P300 in tumorigenesis: structural and functional versatility in target recognition. *Cell Mol Life Sci* 2013;70:3989–4008.
- 152 Bourtchouladze R, Lidge R, Catapano R, *et al.* A mouse model of Rubinstein-Taybi syndrome: defective long-term memory is ameliorated by inhibitors of phosphodiesterase 4. *Proc Natl Acad Sci U S A* 2003;100:10518–22.
- 153 Schueller E, Paiva I, Blanc F, *et al.* Dysregulation of histone acetylation pathways in hippocampus and frontal cortex of Alzheimer's disease patients. *Eur Neuropsychopharmacol* 2020;33:101–16.
- 154 Macarak EJ, Wermuth PJ, Rosenbloom J, *et al.* Keloid disorder: fibroblast differentiation and gene expression profile in fibrotic skin diseases. *Exp Dermatol* 2021;30:132–45. 10.1111/exd.14243 Available: <https://onlinelibrary.wiley.com/toc/16000625/30/1>
- 155 Yan L, Cao R, Liu Y, *et al.* Mir-21-5p links epithelial-mesenchymal transition phenotype with stem-like cell signatures via AKT signaling in keloid keratinocytes. *Sci Rep* 2016;6:28281.
- 156 Wang X, Gu C, Shang F, *et al.* Inhibitory effect of the Ly2109761 on the development of human keloid fibroblasts. *Anal Cell Pathol (Amst)* 2021;2021:e8883427.
- 157 Stevenson AW, Deng Z, Allahham A, *et al.* The epigenetics of keloids. *Exp Dermatol* 2021;30:1099–114.
- 158 Lv W, Ren Y, Hou K, *et al.* Epigenetic modification mechanisms involved in keloid: current status and prospect. *Clin Epigenetics* 2020;12:183.
- 159 Diao J-S, Xia W-S, Yi C-G, *et al.* Histone deacetylase inhibitor reduces hypertrophic scarring in a rabbit ear model. *Plast Reconstr Surg* 2013;132:61e–9e.
- 160 Fitzgerald O'Connor EJ, Badshah II, Addae LY, *et al.* Histone deacetylase 2 is upregulated in normal and keloid scars. *J Invest Dermatol* 2012;132:1293–6.
- 161 Tu T, Huang J, Lin M, *et al.* CUDC-907 reverses pathological phenotype of keloid fibroblasts in vitro and in vivo via dual inhibition of Pi3K/AKT/mTOR signaling and Hdac2. *Int J Mol Med* 2019;44:1789–800.
- 162 Kim S, Lee SE, Yi S, *et al.* Tauroursodeoxycholic acid decreases keloid formation by reducing endoplasmic reticulum stress as implicated in the pathogenesis of keloid. *Int J Mol Sci* 2021;22:10765.
- 163 Tanaka Y, Ishitsuka Y, Hayasaka M, *et al.* The exacerbating roles of CCAAT/enhancer-binding protein homologous protein (CHOP) in the development of bleomycin-induced pulmonary fibrosis and the preventive effects of tauroursodeoxycholic acid (TUDCA) against pulmonary fibrosis in mice. *Pharmacol Res* 2015;99:52–62.
- 164 Liu X, Chen W, Zeng Q, *et al.* Single-cell RNA-sequencing reveals lineage-specific regulatory changes of fibroblasts and vascular endothelial cells in keloids. *J Invest Dermatol* 2022;142:124–35.