



HAL
open science

Conception and validation of A 3d printed learning model of supra condylar fracture of children

Alexis Lubet, Mariette Renaux-Petel, Laurent Delbreilh, Agnès Liard-Zmuda, Annabelle Auble, Mathilde Payen

► **To cite this version:**

Alexis Lubet, Mariette Renaux-Petel, Laurent Delbreilh, Agnès Liard-Zmuda, Annabelle Auble, et al.. Conception and validation of A 3d printed learning model of supra condylar fracture of children. Heliyon, 2024, 10 (10), pp.e30741. 10.1016/j.heliyon.2024.e30741 . hal-04573395

HAL Id: hal-04573395

<https://hal.science/hal-04573395v1>

Submitted on 8 Nov 2024

HAL is a multi-disciplinary open access archive for the deposit and dissemination of scientific research documents, whether they are published or not. The documents may come from teaching and research institutions in France or abroad, or from public or private research centers.

L'archive ouverte pluridisciplinaire **HAL**, est destinée au dépôt et à la diffusion de documents scientifiques de niveau recherche, publiés ou non, émanant des établissements d'enseignement et de recherche français ou étrangers, des laboratoires publics ou privés.



Distributed under a Creative Commons Attribution - NonCommercial 4.0 International License



Research article

Conception and validation of A 3d printed learning model of supra condylar fracture of children



Alexis Lubet^{a,b,c}, Mariette Renaux-Petel^{a,c}, Laurent Delbreilh^b,
Agnès Liard-Zmuda^{a,c}, Annabelle Auble^{a,c}, Mathilde Payen^{a,c,*}

^a Clinique chirurgicale infantile, CHU Charles Nicolle, 1 rue de Ger mont – 76031 Rouen cedex, France

^b Groupe de Physique des Matériaux UMR 6634, Université Rouen Normandie, INSA Rouen Normandie, CNRS, 76000 Rouen, France

^c Université de Rouen Normandie, 1 rue Thomas Becket, 76821 Mont-Saint-Aignan cedex, France

ARTICLE INFO

Keywords:

3D printing
Supra condylar fracture
Learning model
Surgical education

ABSTRACT

The supracondylar fracture of the child is a common fracture. Its physiology, physiopathology and treatment use periosteum. As far as we know, there is no 3D printed model of this typical fracture in children with periosteum. **The purposes** of the research are to present the concept of an educational 3D printed supra condylar model with periosteum of the child and its expert validation.

Materials and methods: The basis for the paediatric elbow model was a 3D scan of a four-year-old girl. Once the data had been extracted, the models were constructed using 3D Slicer®, Autodesk fusion 360® and Ultimaker Cura® software's. The Creality 3D Ender 6 SE Printer® used PLA filaments to print bone and TPU for periosteum. Printing took place at the University Hospital and the steps were modelled by hand. 3D printed bones and 3D printed periosteum were manually assembled.

Participants: Expert validation with twelve paediatric orthopaedic surgeons took place in three University hospitals of the North of France.

Results: Four Lagrange and Rigault 3D printed models of supracondylar fractures with periosteum were obtained with 200 h of design, printing and manual assembly based on a four-year-old elbow. According to the paediatric orthopaedic surgery experts, the size of the model is very good, but the model itself is of little interest compared to the information provided by the reconstruction of a 3D scanner. In total, with 9 out of 12 questions scoring higher than 8/10, the model was considered to be a good model for informing parents and teaching students.

Conclusions: This study details the design of the first 3D-printed supra condylar fracture model in children with a full-size physéal and periosteum. The model has been validated by paediatric orthopaedic surgery experts.

Alexis Lubet: Funding Source Declaration: this work was supported by the research scholarship of Société Française de Chirurgie Pédiatrique.

Mariette Renaux-Petel: none.

Laurent Delbreilh: none.

* Corresponding author. Clinique chirurgicale infantile, CHU Charles Nicolle, 1 rue de Germont – 76031 Rouen cedex, France.

E-mail address: mathilde-payen@hotmail.fr (M. Payen).

<https://doi.org/10.1016/j.heliyon.2024.e30741>

Received 26 November 2023; Received in revised form 2 May 2024; Accepted 3 May 2024

Available online 4 May 2024

2405-8440/© 2024 The Authors. Published by Elsevier Ltd. This is an open access article under the CC BY-NC license (<http://creativecommons.org/licenses/by-nc/4.0/>).

Agnes Liard-Zmuda: none.

Annabelle Auble: none;

Mathilde Payen: none.

Accreditation Council for Graduate Medical Education (ACGME) competencies: this study aims to bring **Medical Knowledge** through the creation of a 3D learning model of paediatric fracture.

1. Introduction

Supracondylar fractures in children account for 60 % of all elbow fractures in growing children. It's defined as a metaphyseal fracture involving the distal end of the humerus. This specific paediatric fracture is explained by the physiological joint laxity of the child [1]. The periosteal membrane is a solid growth membrane that helps to reduce and stabilise this fracture. Supracondylar fractures in children can be divided into four stages as described by Lagrange and Rigault [2]. The severity of the fracture increases from stage I to stage IV. Treatment is based on orthopaedic therapy for stages I and II. Stages III and IV are treated surgically in most teams [3]. Supracondylar fractures are common in routine practice and need to be taught to students and residents. In paediatric orthopaedic surgery, the current educational model is mainly oral with visual support (<https://collegechirurgiepediatrique.fr/>). Treatment is based on the periosteal hinge [1]. This concept is specific to paediatric fractures. The Saw Bone® model (www.sawbones.com) is the gold standard of educational bone models to date [4]. However, it is based on an adult model and doesn't represent growth plates or periosteum. To the best of our knowledge, there is no 3D printed model of a paediatric supracondylar elbow fracture with physis and periosteum. The lack of models for paediatric fractures, and in particular for the supra condylar fracture, has a real impact. Students do not visualize the different anatomical elements of the child's elbow. Residents and students alike are unable to grasp the pathophysiological importance of the periosteum in paediatric traumatology.

The aim of this work was to produce an expert-validated educational 3D printed model of supra-condylar fracture (SCF) in children with representation of the physis and periosteum in order to improve parents' understanding, as well as students' knowledge and management of patients.

2. Materials and Methods

2.1. A. imaging

A CT scan with 3D reconstruction of the elbow of a 4-year-old patient was performed in an emergency situation after complete devascularisation of the forearm following a stage 4 supracondylar fracture despite osteosynthesis. The CT scan with contrast was realised on a GE Medical Systems Revolution EVO, DFOV 42,4 x 18,0 cm. the total dose length product was 72,85 mGy cm/-: kV = 80.0 mAs = 76.0 Target Region = Chest/-: kV = 80.0 mAs = 50.0 TargetRegion = Chest/-: kV = 100.0 mAs = 360.9. The 3D reconstruction was automatically done with the PACS software (Pacs Carestream.Ink). This clinical CT scan model allowed visualisation of the growth plate and osteo-cartilaginous model of the elbow. The 3D CT reconstruction showed the reduced stage 4 SCF with 3 Kirschner wires (Fig. 1). The 3D model represented the actual size of the elbow. All modelling was completely anonymous and the PACS Carestream software downloaded the data in DICOM format.

2.2. b. modelling with 3D Slicer®, Autodesk fusion 360®, Meshmixer® and Ultimaker Cura®

3D Slicer® software was used to model DICOM formats. 3D Slicer® was used to modify the 3D reconstruction of the elbow by removing the Kirschner wires (Fig. 2). A proximal radioulnar synostosis was added to ensure stability of both forearm bones in the

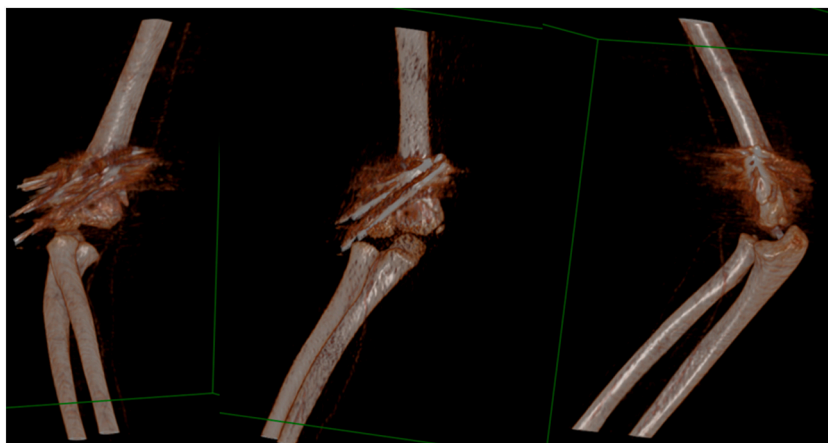


Fig. 1. Elbow CT-scan with three-dimensional reconstruction. The three K-wire are present.

model. The humeral shaft was missing from the 3D reconstruction, although it was required for periosteal fixation. The humerus was augmented by cutting proximally with Meshmixer® software. For Lagrange and Rigault stages I and II, the elbow was modelled without fracture lines [2]. For Lagrange and Rigault stages III and IV, the elbow was modelled with fracture lines (Fig. 2) [2]. Autodesk fusion 360® software was used to draw the periosteum. The ratio between the measurements of the 3D model of the humerus and those of the two bones of the forearm on the scanner was taken into account to calculate the ideal size of the periosteum model: it measured 21 cm long by 7 cm wide and 0.4 cm thick. The edges were blunted for greater harmony.

2.3. c. printing and assembly

Ultimaker Cura® software was used to create the support zones for the different parts of the bone model. It was also used to transmit the models created on 3D Slicer® and Autodesk fusion 360® in a specific language to the 3D printer used.

The 3D printing machine was the Creality 3D Ender SE 3D Printer® with a printing area of $220 \times 220 \times 250$ mm, buse of 0.4 mm and a Bowden extruder. The filament used was bio sourced polylactic acid (PLA). Thirty-five grams of PLA Eryone®, silk white 1,75 mm diameter, 24€/kg, for the bone. The filament used was transparent thermoplastic polyurethane (TPU). Ten grams of TPU shore 95A, Eryone®, 1,75 mm diameter, 48€/kg transparent was used for the periosteum [5]. Before use, a drying time of 12 h was required inside EIBOS 3D Filament Dryer Series X: Easdry® using a bowden-type extruder, before printing at 50 °C. It took 8 h to print a periosteum and 14 h to print a bone model. In all, 88 h were needed to produce the four FSC models associated with their periosteum.

Manual modification was required to model FSC stage I. A hand saw was used to remove a solid triangle opposite the anterior cortex. Stage II modelling required the use of an electric engraver to dig the fracture deeper without weakening the model too much. Neoprene 400 Orapi® contact adhesive was used to bond the bone models to the periosteal model. This flexible, moisture-resistant, multi-purpose adhesive is applied by double gluing (150 ml/m^2 per side). A drying time of 15 min is required before assembly. Bonding was performed manually, positioning the ends of the periosteal model proximally on the humeral shaft and distally on the ulnar shaft. After assembly, each part of the bone model was independent of the other, connected by the 3D-printed periosteum (Fig. 3).

2.4. D. expert validation

To face the validity of the 3D printed model (Fig. 3), multi centre validation of paediatric orthopaedic surgeons were asked to answer a survey (Annexes) based on the work of ESUT research group [6]. All experts have medical thesis and diplomas in orthopaedic paediatric surgery. The working experience of each expert as a senior, ranging from 1 to 40 years, is detailed in Table 1. The questionnaire consisted of 10 questions ranging from 0 to 10, plus a section for free comments. The questionnaire sought the experts' opinions on the usefulness of a supracondylar model for better informing parents in the preoperative period (questions 1 to 4) and on the quality of the 3D-printed model presented to them (questions 5 and 6). Finally, the experts gave their opinion on the usefulness of the model presented, both for explanations to families and for teaching purposes, for medical students as well as orthopaedic interns (questions 7 to 10).

For each question, a score between 0 and 3 corresponded to a poor result (red), a score between 4 and 6 to an average result (orange), a score between 7 and 8 to a good result (yellow) and a score between 9 and 10 to a very good result (green) (Fig. 5).

2.5. e. statistical analysis

The results of the questionnaires completed by the experts were analysed and presented in the form of the mean (standard deviation) for each question, according to Student's method with confidence intervals of 95 % (Table 2). The data were analysed using Excel software.

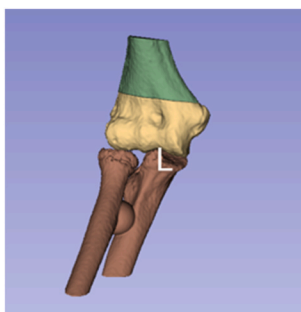


Fig. 2. Modelization of the fracture line on 3D Slicer [5].

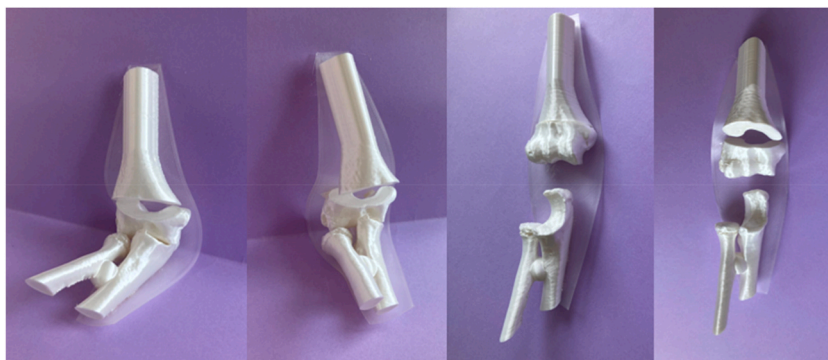


Fig. 3. Placement of 3D printed bones into the periosteum.

Table 1

Baseline characteristics of regional experts in paediatric orthopaedic surgery.

id	Fonction	Sex	Career start date
002 exp	DJ	M	2022
007 exp	DJ	M	2022
004 exp	CCA	M	2021
012 exp	DJ	M	2021
008 exp	PH	M	2020
011 exp	PH	M	2018
003 exp	PH	F	2017
009 exp	MCU PH	F	2012
001 exp	PH	M	2009
010 exp	PUPH	M	2003
006 exp	PH	F	1993
005 exp	PUPH	M	1985

DJ: Junior Doctor, CCA: Clinical and Research Fellow, PH: Hospital Practitioner, MCU PH: Assistant Professor and Hospital Practitioner, PUPH: University Professor and Hospital Practitioner (MDPhD)..

Table 2

Results of experts presented with means and 95 % confidence intervals (95 % CI) according to Student's method.

	Mean	Lower limit (IC95 %)	Upper limit (IC95 %)
Question 1	8,33	7,65	9,02
Question 2	8,42	7,42	9,41
Question 3	5,83	4,19	7,48
Question 4	8,08	6,32	9,85
Question 5a	8,25	7,39	9,11
Question 5b	7,58	6,71	8,46
Question 5c	9,17	8,64	9,7
Question 6	7,17	6,12	8,21
Question 7	8,5	7,66	9,34
Question 8a	8,92	8,34	9,49
Question 8b	8,75	7,98	9,52
Question 9	7,33	5,66	9,01
Question 10	8,08	6,89	9,28

3. Results

3.1. A. 3D printed model

Two surgeons worked together to create the models. Computer modelling was used to obtain four distal humeri, four proximal radio ulnar ends and four periosteums (Fig. 4). These different elements were then assembled to reconstruct the elbow joint, allowing the supra condylar fracture and its potential for reduction to be visualised thanks to the presence of the periosteum.

The average fitting time for a supracondylar model was 15 min, plus 5 min for modification of the humeral part for Lagrange and Rigault stages 1 and 2.

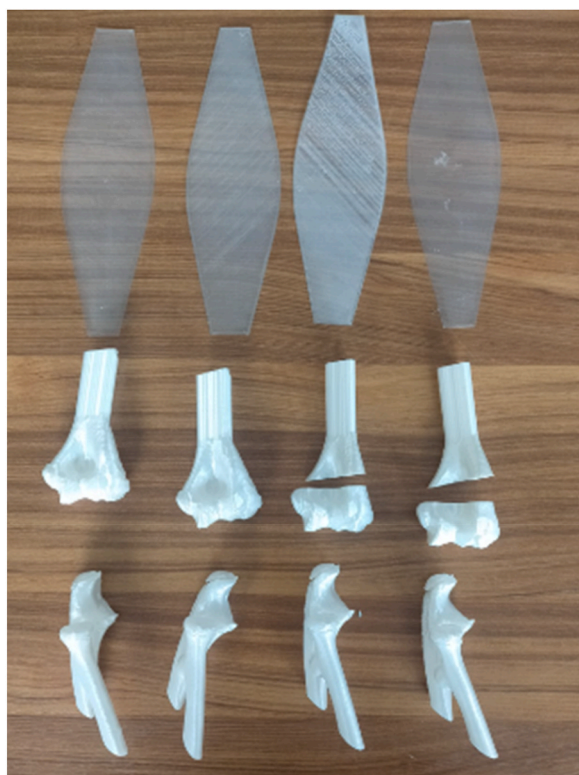

Fig. 4. Four 3D printed bones and periosteum.

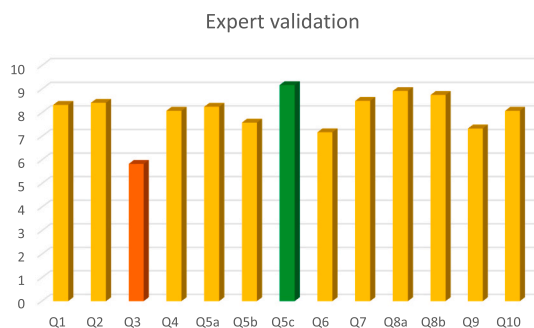

Fig. 5. Histograms showing the average responses of the 12 experts to the 10 questions questionnaire. Questions 1 to 4: utility of a 3D model, Questions 5 and 6: quality of the presented model, Questions 7 to 10: usefulness of the presented model. The color-coded bars correspond to poor (red), average (orange), good (yellow) and very good results (green). (For interpretation of the references to color in this figure legend, the reader is referred to the Web version of this article.)

3.2. b. expert validations

Twelve experts from three different centres responded to the survey. The characteristics of the expert population are presented in Table 1. The average score for each question is shown in Fig. 5 (Fig. 5.).

There are no "poor results". According to the experts, the size of the 3D model is very good (Question 5c), but the model itself is of little interest compared to the information provided by the reconstruction of a 3D scanner (Question 3). Three experts thought that stage II could be improved by adding mobility to the model. Most of the experts would have liked to see greater congruence between the bones and a periosteum that more closely followed the shape of the bones and joint (free comments).

The average scores obtained for each question (Table 2) ranged from 5.83 (Question 3) to 9.17 (Question 5c). Nine out of 12 questions have an average score above 8, with an overall average for all questions of 8.03. The 3D-printed supracondylar model therefore appears to be considered a 'good' model by the experts, which means that it can be used for teaching and patient information

purposes (Table 2).

4. Discussion

In this study, we report on the development and validation of a novel 3D-printed model of a supra-condylar fracture in children. This model consists of 4 parts representing the 4 stages of the Lagrange and Rigault classification, 3D printed from a CT scan of the elbow of a 4-year-old child. Once printed and assembled (Fig. 3), these models were evaluated by 12 paediatric orthopaedic experts, who provided highly favourable ratings in a satisfaction questionnaire. According to these experts, the models are perfectly suited for supporting the pre-operative information for parents and for educational purposes.

The impetus behind creating this supra-condylar fracture model stemmed a particular need: the complexity of explaining the role of the humeral periosteum in the pathophysiology and management of supra-condylar of such fractures to parents and students. To our knowledge, no elbow model representing the periosteum exists in France [7,8]. For instance, the model presented by Saw bone® is fixed at 90° and the periosteum is represented very minimally (Fig. 6). By incorporating a flexible membrane intended to represent the periosteum onto the 3D-printed bones, we addressed this challenge, with experts noting the satisfactory representation of the periosteum. The size of the model, made to a scale of 1:1 in relation to the elbow of a 4-year-old child (Fig. 1.), was judged to be perfectly suited to the educational objective.

While our 3D-printed model received favourable feedback from experts, it is important to note their observation that the model did not offer significant advantages over a 3D scanner reconstruction. Although a 3D scanner reconstruction could potentially provide a highly detailed representation of the fracture, it is not the standard imaging modality for supracondylar fractures, which may limit its practical utility for parents. Additionally, the use of CT scans for educational purposes would involve unnecessary radiation exposure for children, making it less feasible in clinical practice.

The choice of printer in this study holds significant importance. We opted for a low-cost printer (200€), ensuring affordability and widespread availability for users. The total cost of producing the 3D printed model was 1€32. In detail, the cost of 35g PLA (24€/kg) for all bony parts of the model was 84 euro cents. The cost of 10g TPU (48€/kg) for the periosteum was 48 euro cents per model. The minimal cost of 1€32 is a real asset over the gold standard model on the market, such as those from Sawbones® (Fig. 6).

The decision to use a Bowden extruder instead of a direct drive was made possible by the high Shore hardness of the TPU material we employed [5]. While using a direct drive extruder would have allowed for the use of a more flexible TPU. The results achieved with our configuration were already highly satisfactory. We also adjusted the material's flexibility by varying the model's thickness, which contributed to achieving our objectives. Furthermore, using a multi-material printer would have provided the capability to directly print the TPU periosteum onto the model, opening up new avenues for our research.

Our study admittedly has its limitations, since its sole aim is to publish our model and to study the satisfaction of a few experts with regard to the pedagogical objective. The small sample size in our study is largely attributable to the limited number of specialists in our medical field.

However, the 12 experts to whom the model was presented were unanimous about its value, both in explaining the supra-condylar fracture to parents and in teaching it to students. This result should be confirmed by other studies, this time involving parents or students, to test the superiority of this 3D model compared with verbal explanations, a 2D drawing or a scanner reconstruction where possible.

The experts highlighted several areas in which the model could be improved. Specifically, experts suggested a more flexible, more mobile model, with a periosteum that was more adherent to the bone, would undoubtedly be even more explicit. Indeed, TPU is not an elastic thermoplastic, and printing elastomers remains a challenging task in 3D printing. One of our upcoming improvements will involve adding elastic components to the lateral sections of the model to address this realism deficiency. In our study, we opted for the use of PLA due to its high compatibility, ease of printing, low cost, and widespread availability. While we implemented manual modifications, it is conceivable that we could have directly incorporated fracture features into the model, albeit at the expense of support structures in the case of larger models. However, this approach might have led to a deterioration in the model's surface quality. The model allows us to represent bone anatomy, periosteal physiology, different fracture stages and ligamentotaxis reduction options. The choice of bio-sourced PLA filament for modelling the bone reflects our commitment to environmentally-friendly materials [9]. The performed modelling is based on a biological model. It provides a 100 % faithful representation of bone relief. This biological model is difficult to remodel, requiring considerable computational power. This difficulty can be seen on the "biological" distal humerus and the diaphysis modelled by adding a computer cut (Fig. 4).

Regarding the periosteum, experts noted its lack of realism, particularly in terms of transparency and flexibility. As far as the periosteum is concerned, the choice was made for a flexible, transparent material that allows great mobility (Fig. 3 And 4). The transparency is far from anatomical reality, but allows the bone parts to be visualised while remaining closer to the physiology of the periosteum. 3D-printed periosteum is not elastic and has difficulty in fitting perfectly to the bones of the joint, which is a real limitation for the realism of the model. Several tests were carried out to improve the flexibility of the periosteum, which depends on the thickness chosen: at 0.2 mm the periosteum was too fragile, at 0.6 mm it was too thick and not very malleable, so a thickness of 0.4 mm was chosen.

Additionally, the homemade aspect of the model, requiring assembly and gluing before use, represents a limitation. Although assembly time was relatively short, around 15 min, this aspect may impact user experience and practicality. Ongoing research is underway to evaluate the model among students and parents, assessing its effectiveness and impact in educational settings. This study aims to shed light on the potential benefits of the model while identifying areas for technological improvement.

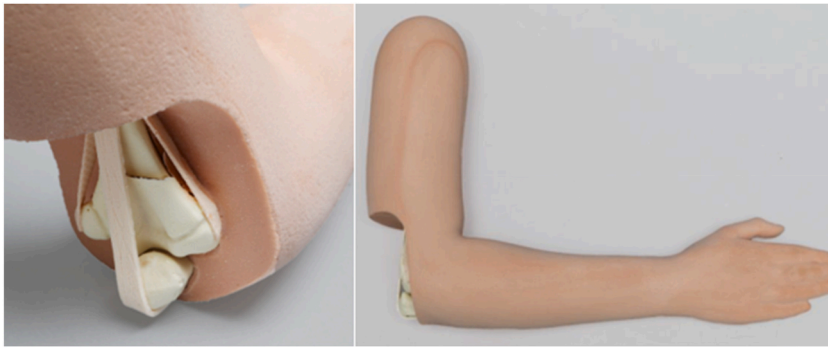


Fig. 6. Saw bone® training model for osteosynthesis of supra condylar fracture.

5. Conclusion

The model of the supracondylar fracture in children presented in this work has received positive feedback from paediatric orthopaedic surgery experts, highlighting its value for parent education and student learning. While a few points for improvement have been identified, this model represents a promising advancement in paediatric orthopaedic education, with potential benefits for understanding, communication, and patient care.

Ethics statement

Informed consent was not required for this study because it does not concern patients or medical data.

Date availability statement

No data associated with your study has been deposited into a publicly available repository. A INPI procedure is ongoing.

CRediT authorship contribution statement

Alexis Lubet: Resources, Conceptualization. **Mariette Renaux-Petel:** Writing – review & editing, Validation. **Laurent Delbreilh:** Supervision. **Agnès Liard-Zmuda:** Supervision. **Annabelle Auble:** Methodology, Formal analysis. **Mathilde Payen:** Writing – original draft, Investigation, Data curation.

Declaration of competing interest

The authors declare the following financial interests/personal relationships which may be considered as potential competing interests:

Dr Alexis Lubet reports financial support was provided by Société de chirurgie pédiatrique. If there are other authors, they declare that they have no known competing financial interests or personal relationships that could have appeared to influence the work reported in this paper.

Acknowledgements

Special thanks to Dr Delbreilh, Associate Professor in the University of Rouen and his Groupe de Physique des Matériaux UMR 6634, Université Rouen Normandie, INSA Rouen Normandie, CNRS, 76000 Rouen, France for this participation to this study.

Special thanks to Dr Hassani, head of radiologic paediatric department, for producing and analysing the CT scan that enabled this study to be carried out.

Special thanks to Dr André Gillibert, biostatistician, who conducted the statistical analysis.

Appendix A. Supplementary data

Supplementary data to this article can be found online at <https://doi.org/10.1016/j.heliyon.2024.e30741>.

References

- [1] H. De Boeck, T. Van Isacker, Fractures de l'extrémité inférieure de l'humérus chez l'enfant, *EMC - Appar Locomoteur* 2 (2007) 1–10, [https://doi.org/10.1016/S0246-0521\(06\)43671-8](https://doi.org/10.1016/S0246-0521(06)43671-8).
- [2] J. Lagrange, P. Rigault, [Treatment of supra-condylar fractures of the humerus in children], *Presse Med.* 78 (1970) 2382.
- [3] C.V.A. Kinkpé, A.V. Dansokho, M.M. Niane, E. Chau, J. Sales De Gauzy, J.L. Clement, et al., Children distal humerus supracondylar fractures: the Blount Method experience, *Orthop Traumatol Surg Res* 96 (2010) 276–282, <https://doi.org/10.1016/j.otsr.2009.12.010>.
- [4] A. Pradhan, W. Hennrikus, G. Pace, A. Armstrong, G. Lewis, Increased pin diameter improves torsional stability in supracondylar humerus fractures: an experimental study, *J Child Orthop* 10 (2016) 163–167, <https://doi.org/10.1007/s11832-016-0722-z>.
- [5] E. Brancewicz-Steinmetz, J. Sawicki, P. Byczkowska, The influence of 3D printing Parameters on adhesion between polylactic acid (PLA) and thermoplastic polyurethane (TPU), *Mater Basel Switz* 14 (2021) 6464, <https://doi.org/10.3390/ma14216464>.
- [6] F. Porpiglia, R. Bertolo, E. Checucci, D. Amparore, R. Autorino, P. Dasgupta, et al., Development and validation of 3D printed virtual models for robot-assisted radical prostatectomy and partial nephrectomy: urologists' and patients' perception, *World J. Urol.* 36 (2018) 201–207, <https://doi.org/10.1007/s00345-017-2126-1>.
- [7] J.-C. Bernhard, S. Isotani, T. Matsugasumi, V. Duddalwar, A.J. Hung, E. Suer, et al., Personalized 3D printed model of kidney and tumor anatomy: a useful tool for patient education, *World J. Urol.* 34 (2016) 337–345, <https://doi.org/10.1007/s00345-015-1632-2>.
- [8] C. Michiels, A. Boulenger de Hauteclouque, J. Sarrazin, F. Cornelis, S. Ricard, M. Faessel, et al., Utilisation de l'impression 3D avant néphrectomie partielle pour tumeur du rein, *Prog. Urol.* 30 (2020) 970–975, <https://doi.org/10.1016/j.purol.2020.09.007>.
- [9] M. Murariu, P. Dubois, PLA composites: from production to properties, *Adv. Drug Deliv. Rev.* 107 (2016) 17–46, <https://doi.org/10.1016/j.addr.2016.04.003>.