



HAL
open science

Evaluation of the “release and perfuse technique” for aortic arch surgery

Antonio Piperata, Nicolas d’Ostrevy, Olivier Busuttil, Martina Avesani,
Thomas Modine, Giulia Lorenzoni, Danila Azzolina, Louis Labrousse,
Mathieu Pernot

► **To cite this version:**

Antonio Piperata, Nicolas d’Ostrevy, Olivier Busuttil, Martina Avesani, Thomas Modine, et al.. Evaluation of the “release and perfuse technique” for aortic arch surgery. *Journal of Cardiac Surgery*, 2022, 37 (9), pp.2633-2639. 10.1111/jocs.16640 . hal-04568829

HAL Id: hal-04568829

<https://hal.science/hal-04568829>

Submitted on 5 May 2024


HAL is a multi-disciplinary open access archive for the deposit and dissemination of scientific research documents, whether they are published or not. The documents may come from teaching and research institutions in France or abroad, or from public or private research centers.

L’archive ouverte pluridisciplinaire **HAL**, est destinée au dépôt et à la diffusion de documents scientifiques de niveau recherche, publiés ou non, émanant des établissements d’enseignement et de recherche français ou étrangers, des laboratoires publics ou privés.



Distributed under a Creative Commons Attribution 4.0 International License

Evaluation of the “release and perfuse technique” for aortic arch surgery

Antonio Piperata MD¹  | Nicolas d'Ostrevy MD¹ | Olivier Busuttil MD¹ |
Martina Avesani MD¹ | Thomas Modine MD, PhD¹ | Giulia Lorenzoni PhD²
Danila Azzolina PhD² | Louis Labrousse MD, PhD¹ | Mathieu Pernot MD¹

1 Department of Cardiology and CardioVascular Surgery, Hôpital Cardiologique de Haut-Lévêque, Bordeaux University Hospital, Pessac, France

2 Department of Cardiac, Thoracic, Vascular Sciences and Public Health, Unit of Biostatistics, Epidemiology and Public Health, University of Padova, Padova, Italy

Abstract

Objectives: The hypothermic circulatory arrest is a major limitation of the frozen elephant trunk (FET) technique, associated with a high incidence of postoperative morbidity and mortality. The aim of this study was to evaluate the surgical outcomes of patients suffering from different aortic arch diseases treated with the release and perfuse technique (RPT).

Methods: We retrospectively reviewed the records of patients who had undergone aortic arch repair with the RPT at our Institution between October 2019 and September 2021. Preoperative, intra-operative, and postoperative data were collected.

Results: A total of 18 patients undergoing aortic arch surgery with the use of RPT were analyzed. Twelve of them (67%) were males, and the median age of the entire cohort was 67 (56–73) years. The primary indications for surgery included acute type A aortic dissection (50%), chronic type B aortic dissection (33%), and chronic aneurysms (17%). The median cardiopulmonary bypass-, aortic cross-clamp- and circulatory arrest times were 163 (147–213) min, 69 (51–120) min, and 10 (8–13) min, respectively. The median intensive care unit and hospital stay were 4 (2–7) and 12 (11–16) days, respectively. One patient (6%) died during the first 30 days after surgery.

Conclusions: Considering the anatomical limitations related to the use of this technique, the RPT can be safely performed and could represent a promising strategy to reduce the circulatory arrest time during aortic arch surgery. Nevertheless, further studies are required to demonstrate its efficacy.

Introduction

The modern evolution of the classic elephant trunk (ET) technique is the frozen elephant trunk (FET), which is the result of technical and device modifications over decades with the main purpose of reducing complications.^{1,2} Although FET allows to perform a complete singlestage treatment in extended thoracic aortic disease, early outcome is still suboptimal due to the complex surgical technique, patients' anatomy, and different pathological settings.^{2,3} In this context, the problem of circulatory arrest time is still unsolved, and the standard FET, although safe, does not ensure satisfactory abdominal protection.⁴ Thus, to reduce the circulatory arrest time, many modifications of the technique have been proposed. These include the proximalization of the distal anastomosis from Zone 3 to Zone 2, endovascular techniques, or the use of new devices.^{5–11}

Our group recently described the modified FET called “release and perfuse technique” (RPT) using the Thoraflex Hybrid prosthesis (Vascutek Terumo) as a possible surgical alternative to minimize the circulatory arrest time.¹² This technique does not require additional surgical skills or devices, but it simply consists of performing the lower body reperfusion before starting the distal anastomosis. In the following manuscript, we present the results of patients treated with this technique in our center. This single center experience has the main objective to evaluate the feasibility of RPT as a new possible strategy in the armamentarium of aortic arch surgery in reducing the circulatory arrest time.

Materials and methods

Study population

We started to use the Thoraflex Hybrid prosthesis for FET procedures at our Institution in January 2018. Up to September 2021, a total of 44 patients were successfully treated with this prosthesis, and 18 of them were treated with the use of the RPT, introduced in October 2019.

Baseline and preoperative characteristics of the overall population are shown in Table 1.

The primary indications for surgery included acute type A aortic dissection (ATAAD), chronic type B aortic dissection (TBAD), and chronic aneurysms. Cerebral protection was ensured through the antegrade selective cerebral perfusion with mild-to-moderate hypothermia. The analysis of surgical outcomes was performed by reviewing electronic health records, and the results are presented according to the different aortic diseases

The descriptive statistics have been reported summarizing the continuous data as I quartile, median, and III quartiles; categorical data are instead reported as percentages and absolute frequencies.

Operative technique

The RPT

The surgical protocol applied in Bordeaux University Hospital has been previously detailed.^{12,14} Here, we give a short explanation of the procedure. All operations were performed by senior surgeons with extensive experience in aortic arch surgery under standard general anesthesia. The cardiopulmonary bypass (CPB) was established by the right axillary artery and central venous cannulation as previously described.¹⁴ During the patient's cooling, the arterial cannula (20 Fr, EOPA, Medtronic) was inserted into the fourth branch of the Thoraflex Hybrid and then securitized. At the target temperature, CPB flow was reduced, the supra-aortic vessels clamped, and standard CPB was switched to unilateral brain perfusion. The arch was then completely opened and inspected. The prosthesis was then introduced in an antegrade fashion in the descending aorta and released (Figure 1). Two 4-0 polypropylene Ustitches with pledgets were used to fix the sewing collar of Thoraflex with the aortic wall.

At this point, a second arterial line is connected to the cannula previously placed into the fourth branch of Thoraflex. The antegrade blood flow is slowly restored to fill the abdominal and descending aorta. Once the prosthesis is completely full of blood, de-airing is done, and the proximal part of the prosthesis and its branches are clamped (Figure 1). The full arterial flow is now slowly restarted to perfuse the lower body, and the patient progressively rewarmed. The distal anastomosis is performed between the incorporating sewing collar of the Thoraflex and the aorta, starting from the previously prepared 2 U-stitches

(Figure 1).

The supra-aortic vessels are anastomosed to the branches of the graft, and the operation is completed with an aortic root procedure if necessary.

Indication and choice of the strategy

During the study period, the choice of the surgical strategy was made based on the anatomical characteristics of each patient. The first step was the evaluation of the feasibility of the RPT. For each patient, the decision to perform RPT was collegially discussed after an accurate and meticulous investigation of the descending aortic landing zone size, as assessed by a computer tomography (CT) scan. This step was mandatory before choosing the stent graft's size in case of RPT.

If the size of the aorta at the level of the landing zone could not guarantee a perfect sealing with a correct oversizing, the RPT was considered infeasible and the strategy switched to classic FET.

Figure 2 reports the criteria used to choose the stent-graft size. The aim is to perform an over-sizing of about 15% in case of degenerative aortic aneurysms, and about 5%–10% derived from the maximal diameter of the true lumen in case of aortic dissection, to avoid any aortic injury caused by the radial force of the stent on the aortic wall.

Results

Baseline and preoperative characteristics of the overall population are shown in Table 1. A total of 18 patients (12 males and 6 females), with a median age of 67 years 56–73 underwent a FET procedure with the use of RPT. Indications for surgery were ATAAD in nine (50%) patients, TBAD in six (33%) patients, and chronic aortic aneurism in three (17%) patients. Preoperative intubation and organ malperfusion were reported in 1 and 2 patients, respectively. Table 2 shows the intra-operative details. Concomitant procedures were performed in five patients, including valve sparing (four patients), and Bentall procedure (one patient). The median cardio-pulmonary bypass, cross-clamp, and circulatory arrest times were 163 (147–213), 69 (51–120), and 10 min, 8–12, 14 respectively. The median lowest core temperature was 29 (28–31)°C, while the intraoperative mortality was 0%.

Data regarding the postoperative results are shown in Table 3.

The median number of packed blood units during the operative time and the first 24 h were: red blood cells 1 (0–1.3), fresh frozen plasma 1 0-1, platelets 0 (0–0.5), and fibrinogen 2 (1–2.3) g. The median reported lactates peak during the first 24 h postintervention was 2.8 (2.2–3) mmol/L. Overall, the median ICU and hospital stay were 42–7 days and 1211, 12, 14–17 days, respectively. One patient affected by ATAAD died of multiorgan failure on Day 14. In this case, the aortic dissection started from the ascending aorta and involved the arch, the left carotid artery, and the descending aorta. The preoperative neurological status was normal but due to rapid worsening of his clinical condition, he was preoperatively intubated. We decided to perform aortic arch surgery with the RPT with the main objective to reduce the circulatory arrest time. However, the patient developed fatal postoperative multiorgan failure with permanent neurological deficit.

Excluding the above-mentioned patient, no case of postoperative multiorgan failure, digestive ischemia, or death was reported.

Conclusion

Since its introduction in clinical practice, the FET technique with modern hybrid prostheses has represented an important milestone in the treatment of complex lesions of the thoracic aorta.¹ However, one of the limitations of this technique is the duration of circulatory arrest time, which includes prosthesis' deployment and the time required to perform the distal anastomosis.^{2,3}

The most important finding of our work is that the use of RPT is both feasible and beneficial in patients undergoing aortic arch surgery. The circulatory arrest times reported in our series are undoubtedly shorter than those reported in the literature with the use of standard FET, in which the distal anastomosis precedes the lower body reperfusion.⁴

This finding could support and explain a few more favorable consequences.

Firstly, the RPT reduces the circulatory arrest time and therefore the visceral ischemic time, with consequently lower postoperative RPT is the possibility of performing the procedure at mild hypothermia. In fact, the significantly shorter circulatory arrest time allows to expose patients to hypothermia for shorter periods, reducing all the risks related to low temperatures.^{15–17} The effects are undoubtedly translated into reduced blood transfusions and an easier hemostasis phase. Lastly, minimizing all these criticisms could play a key role in reducing postoperative complications and the length of hospitalization.

Regarding the technical aspect of the RPT, we want to highlight that, despite our limited experience, we have not reported any case of aortic injury or endoleaks at the level of the landing zone. Moreover, after deploying the Thoraflex prosthesis, full blood flow through the side branch was achieved in all patients in the absence of backflow at the level of the sewing collar. However, in hypothetic case of occurrence, we suggest reducing the pump output until a bloodless surgical field is obtained to perform the distal anastomosis.

In addition, the RPT can be easily performed even in complicated settings, such as type A aortic dissection, TBAD, and chronic aneurysm, without requiring specific surgical's skills or other devices. Up to now several surgical groups have proposed various modifications of the classic FET procedure with the common goal of reducing the circulatory arrest time. These include the proximalization of the distal anastomosis from Zone 3 to Zone 2, and 1 or the use of new prostheses.^{5–11} Di Eusanio and colleagues¹⁸ have recently published a hybrid technique involving the use of balloon endoclamping and femoral cannulation. This seems promising, and it represents the last effort of the surgical community to resolve the problem of circulatory arrest time during aortic arch surgery.^{13,19}

Similar to the RPT, Senage et al.²⁰ have recently described a modified FET technique in which the lower body reperfusion precedes the distal anastomosis. Despite some technical differences (i.e., the proximalization of the distal anastomosis and the use of two tourniquets to avoid backflow on the operative field) this approach appears to be feasible in specific anatomic settings.

The technique presented from our group represents another “fish in the sea,” and despite the limitations related to the seal of the landing zone, it appears to be safe and effective in reducing the circulatory arrest time. Moreover, there is an undisputed need to simplify the complex aortic procedures and endovascular techniques are playing a key role in evolving in this direction.¹⁹ We believe that our technique could give an important contribution and impetus in pursuing this goal, having the advantage to reduce the circulatory arrest time.

Limitations

The main limitation of the study is its retrospective rather than randomized nature. In addition, we are aware that this limited and heterogeneous sample cannot give a solid scientific value to this study. Moreover, the results are influenced by surgeons' skills and periprocedural context. Also, due to the cohort size, no specific statistical analyses were performed.

For all these reasons, further studies with larger samples are needed to demonstrate its safety and efficacy.

Author contribution

Antonio Piperata: Conceptualization, data collection, writing. Nicolas d'Ostrevy: Data collection. Olivier Busuttill: Data collection. Martina Avesani: Editing and revision. Thomas Modine: Review and editing, supervision. Giulia Lorenzoni: Statistical analysis. Danila Azzolina: Statistical analysis. Louis Labrousse: Supervisor. Mathieu Pernot: Project administration, critical revision of article, approval of article, supervisor.

References

1. Shrestha M, Bachet J, Bavaria J, et al. Current status and recommendations for use of the frozen elephant trunk technique: a position paper by the Vascular Domain of EACTS. *Eur J Cardiothorac Surg.* 2015;47(5):759-769.
2. Tian DH, Wan B, Di Eusanio M, Black D, Yan TD. A systematic review and meta-analysis on the safety and efficacy of the frozen elephant trunk technique in aortic arch surgery. *Ann Cardiothorac Surg.* 2013;2(5):581-591.
3. Czerny M, Rylski B, Kari FA, et al. Technical details making aortic arch replacement a safe procedure using the Thoraflex™ Hybrid prosthesis. *Eur J Cardiothorac Surg.* 2017;51:i15-i19.
4. Tian DH, Ha H, Joshi Y, Yan TD. Long-term outcomes of the frozen elephant trunk procedure: a systematic review. *Ann Cardiothorac Surg.* 2020;9(3):144-151.
5. Tsagakis K, Jakob H. Which frozen elephant trunk offers the optimal solution? Reflections from Essen group. *Semin Thorac Cardiovasc Surg.* 2019;31:679-685.
6. Gottardi R, Voetsch A, Krombholz-Reindl P, et al. Comparison of the conventional frozen elephant trunk implantation technique with a modified implantation technique in zone 1. *Eur J Cardiothorac Surg.* 2020;57:669-675.
7. Leone A, Di Marco L, Coppola G, et al. Open distal anastomosis in the frozen elephant trunk technique: initial experiences and preliminary results of arch zone 2 versus arch zone 3†. *Eur J Cardiothorac Surg.* 2019;56:564-571.
8. Detter C, Demal TJ, Bax L, et al. Simplified frozen elephant trunk technique for combined open and endovascular treatment of extensive aortic diseases. *Eur J Cardiothorac Surg.* 2019;56:738-745.
9. Matt P, Banerjee P, Grapow M, et al. Modified frozen elephant trunk for acute type A aortic dissection: a comparative study with standard repair technique. *Eur J Cardiothorac Surg.* 2017;51(4):754-760.
10. Grabenwöger M, Mach M, Mächler H, et al. Taking the frozen elephant trunk technique to the next level by a stented side branch for a left subclavian artery connection: a feasibility study. *Eur J Cardiothorac Surg.* 2021;59:1247-1254.
11. Roselli EE, Idrees JJ, Bakaeen FG, et al. Evolution of simplified frozen elephant trunk repair for acute DeBakey type I dissection: midterm outcomes. *Ann Thorac Surg.* 2018;105:749-755.

12. Piperata A, d'Ostrevy N, Busuttill O, Pernot M. How to minimize the circulatory arrest time by using the Thoraflex Hybrid prosthesis: the 'release and perfuse' technique. *Eur J Cardiothorac Surg.* 2021;61:235-237.
13. Sun X, Guo H, Liu Y, Li Y. The aortic balloon occlusion technique in total arch replacement with frozen elephant trunk. *Eur J Cardiothorac Surg.* 2019;55(6):1219-1221.
14. Piperata A, Watanabe M, Pernot M, et al. Unilateral versus bilateral cerebral perfusion during aortic surgery for acute type A aortic dissection: a multicentre study. *Eur J Cardiothorac Surg.* 2021:ezab341.
15. Etz CD, Luehr M, Kari FA, et al. Selective cerebral perfusion at 28 degrees C—is the spinal cord safe? *Eur J Cardiothorac Surg.* 2009;36:946-955.
16. Cooper WA, Duarte IG, Thourani VH, et al. Hypothermic circulatory arrest causes multisystem vascular endothelial dysfunction and apoptosis. *Ann Thorac Surg.* 2000;69(3):696-702.
17. Strauch JT, Lauten A, Spielvogel D, et al. Mild hypothermia protects the spinal cord from ischemic injury in a chronic porcine model. *Eur J Cardiothorac Surg.* 2004;25:708-715.
18. Di Eusanio M, Gatta E. Frozen elephant trunk without circulatory arrest in acute aortic dissection. *Ann Thorac Surg.* 2021;112(2):e143-e145.
19. Detter C, Brickwedel J. The goal of simplifying complex aortic arch surgery. *Eur J Cardiothorac Surg.* 2021;59:1254-1255.
20. SénageT, BonnetN, Guimbretière G, David CH, Roussel JC, Braunberger E. A simplified delivery frozen elephant trunk technique to reduce circulatory arrest time in hybrid aortic arch surgery. *J Card Surg.* 2021;36(9):3371-3373.

Figures

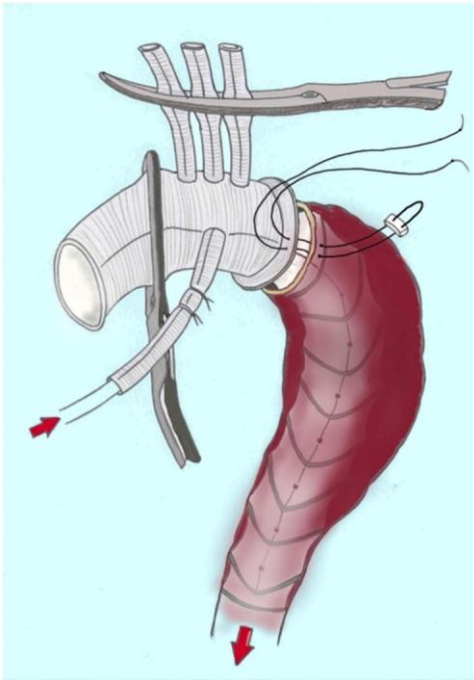
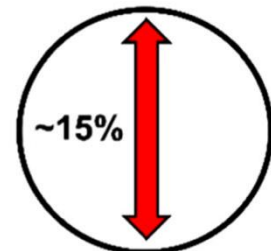

Figure 1 : The release and perfuse technique.

Size of aortic landing zone (mm)	Size of the Thoraflex stent graft (mm)	
	Chronic aneurysm	Acute aortic dissection
36	40	40
35	40	38
34	40	36
33	38	36
32	38	34
31	36	34
30	36	32
29	34	32
28	34	30
27	32	30
26	30	28
25	28	28

CHRONIC ANEURYSM OVERSIZING



AORTIC DISSECTION OVERSIZING

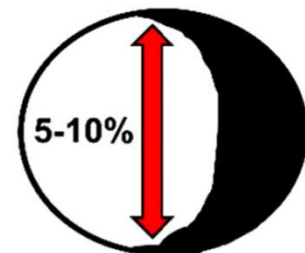


Figure 2 : Criteria for choosing the size of the prosthesis.

Tables

Variable	ATAAD ⁹	TBAD ⁶	Chronic aneurysms ³	Overall ¹³
Age (years)	69 (53–73)	62 (55–70)	73 (67–74)	67 (56–73)
Gender (males)	7 (78%)	4 (67%)	1 (33%)	12 (67%)
Previous cardiac surgery (n°)	1 (11%)	0	0	1 (6%)
Blood hypertension (n°)	9 (100%)	6 (100%)	1 (33%)	13 (89%)
COPD (n°)	2 (22%)	1 (17%)	1 (33%)	4 (22%)
Dyslipidaemia (n°)	5 (56%)	2 (33%)	1 (33%)	8 (44%)
Diabetes (n°)	2 (22%)	0	0	2 (11%)
Genetic aortic syndrome (n°)	0	0	0	0
LVEF (%)	60 (57–64)	63 (60–66)	60 (55–64)	60 (60–65)
Preoperative Neurological dysfunction (n°)	0	0	0	0
Preoperative intubation (n°)	1 (11%)	0	0	1 (6%)
Preoperative malperfusion				
Brain	0	0	0	0
Cardiac	1 (11%)	0	0	1 (6%)
Kidney	1 (11%)	0	0	1 (6%)
Mesenterix	0	0	0	0
Peripheral	0	0	0	0

Table 1 : Demographic and preoperative characteristics of patients treated with the use of release and perfuse technique.

Note: Continuous data are reported as median (I, III quartiles); categorical data are reported as a percentage and absolute frequencies.

Abbreviations: ATAAD, acute type A aortic dissection; COPD, chronic obstructive pulmonary disease; LVEF, left ventricle ejection fraction; TBAD, type B aortic dissection.

Variable	ATAAD ⁹	TBAD ⁶	Chronic aneurysms ³	Overall ¹³
Cardiopulmonary bypass time (min)	170 (152–233)	137 (112–173)	175 (156–255)	163 (147–213)
Cross-clamp time (min)	92 (61–121)	66 (51–113)	51 (51–139)	69 (51–120)
Circulatory arrest (min)	11 (8–14)	11 (7–13)	9 (8–9)	10 (8–13)
Core body temperature (°C)	29 (26–30)	30 (28–31)	32 (28–34)	29 (28–31)
Aortic valve replacement (n°)	0	0	0	0
Valve sparing (n°)	2 (22%)	1 (17%)	1 (33%)	4 (22%)
Coronary artery bypass (n°)	0	0	0	0
Bentall (n°)	2 (22%)	0	0	1 (11%)
Intraoperative death (n°)	0	0	0	0

Table 2 : Operative details of patients treated with the use of release and perfuse technique.

Continuous data are reported as median (I, III quartiles); categorical data are reported as a percentage and absolute frequencies.

Variable	ATAAD ⁹	TBAD ⁵	Chronic aneurysms ³	Overall ¹³
30-day mortality (n°)	1 (11%)	0	0	1 (6%)
ICU stay (days)	5 (3–8)	5 (3–15)	2 (2–3)	4 (2–7)
Hospital stays (days)	13 (11–15)	16 (12–24)	11 (10–12)	12 (11–16)
Permanent neurologic deficit (n°) ^a	1 (11%)	0	0	1 (6%)
Transient neurologic dysfunction (n°) ^b	0	0	1 (33%)	1 (6%)
Reoperation for bleeding (n°)	0	1 (17%)	0	1 (6%)
Multiorgan failure (n°)	1 (11%)	0	0	1 (6%)
Acute kidney failure (n°)	1 (11%)	0	0	1 (6%)
Pulmonary infection (n°)	1 (11%)	0	0	1 (6%)
Limb ischemia (n°)	0	0	0	0
Mediastinitis (n°)	0	0	0	0
Digestive ischemia (n°)	0	0	0	0
Digestive hemorrhage (n°)	0	0	0	0
Lactates peak in the first 24 h (mmol/L)	2.8 (2.2–3.3)	2.5 (2–3.3)	1.8 (2.8–2.9)	2.8 (2.2–3)
Packed red blood cells (n°)	1 (0–1.5)	1 (0–1.3)	0 (1–3)	1 (0–1.3)
Fresh frozen plasma (n°)	1 (0–3)	0 (0–1)	1 (0–1)	1 (0–1)
Platelet concentrate (n°)	0 (0–1.5)	0 (0–0)	0 (0–0)	0 (0–0.5)
Fibrinogen (g)	2 (1–3)	2 (2–3)	1 (0–2)	2 (1–2.3)

Table 3 Postoperative characteristics.

Note: Continuous data are reported as median (I, III quartiles); categorical data are reported as a percentage and absolute frequencies.

Abbreviations: ATAAD, acute type A aortic dissection; CT, computed tomography; ICU, intensive care unit; TBAD, type B aortic dissection.

aPermanent neurologic deficit was defined as the presence of stroke, motor deficit (confirmed at CT/MRI control) or coma.

bTransient neurologic dysfunction was defined as the presence of reversible postoperative deficit before discharge, including confusion, delirium, and motor deficits with no signs of stroke at CT scan.