



HAL
open science

Assessment of malalignment at early stage in adolescent idiopathic scoliosis: a longitudinal cohort study

Tristan Langlais, Claudio Vergari, Grégoire Rougereau, Mathilde Gaume, Laurent Gajny, Kariman Abelin-Genevois, Jean-Claude Bernard, Zongshan Hu, Jack Chun Yiu Cheng, Winnie Chiu Wing Chu, et al.

► To cite this version:

Tristan Langlais, Claudio Vergari, Grégoire Rougereau, Mathilde Gaume, Laurent Gajny, et al.. Assessment of malalignment at early stage in adolescent idiopathic scoliosis: a longitudinal cohort study. *European Spine Journal*, 2024, 33 (4), pp.1665-1674. <10.1007/s00586-024-08178-w>. <hal-04564428>

HAL Id: hal-04564428

<https://hal.science/hal-04564428v1>

Submitted on 30 Apr 2024


HAL is a multi-disciplinary open access archive for the deposit and dissemination of scientific research documents, whether they are published or not. The documents may come from teaching and research institutions in France or abroad, or from public or private research centers.

L'archive ouverte pluridisciplinaire HAL, est destinée au dépôt et à la diffusion de documents scientifiques de niveau recherche, publiés ou non, émanant des établissements d'enseignement et de recherche français ou étrangers, des laboratoires publics ou privés.



HAL Authorization

Assessment of malalignment at early stage in adolescent idiopathic scoliosis: a longitudinal cohort study

Tristan Langlais^{1,2}  · Claudio Vergari¹ · Gregoire Rougereau³ · Mathilde Gaume⁴ · Laurent Gajny¹ · Kariman Abelin-Genevois⁵ · Jean Claude Bernard⁵ · Zongshan Hu⁶ · Jack Chun Yiu Cheng⁶ · Winnie Chiu Wing Chu⁷ · Ayman Assi^{1,8} · Mohamad Karam⁸ · Ismat Ghanem^{8,9} · Tito Bassani¹⁰ · Fabio Galbusera¹¹ · Luca Maria Sconfienza^{10,12} · Marco Brayda-Bruno¹⁰ · Isabelle Courtois¹³ · Eric Ebermeyer¹³ · Raphael Vialle¹⁴ · Jean Dubousset¹ · Wafa Skalli¹

Abstract

Introduction Our objective was to assess abnormalities of the odontoid-hip axis (OD-HA) angle in a mild scoliotic population to determine whether screening for malalignment would help predict the distinction between progressive and stable adolescent idiopathic scoliosis (AIS) at early stage.

Materials and methods All patients (non-scoliotic and AIS) underwent a biplanar X-ray between 2013 and 2020. In AIS, inclusion criteria were Cobb angle between 10° and 25°; Risser sign lower than 3; age higher than 10 years; and no previous treatment. A 3D spine reconstruction was performed, and the OD-HA was computed automatically. A reference corridor for OD-HA values in non-scoliotic subjects was calculated as the range [5th–95th percentiles]. A severity index, helping to distinguish stable and progressive AIS, was calculated and weighted according to the OD-HA value.

Results Eighty-three non-scoliotic and 205 AIS were included. The mean coronal and sagittal OD-HA angles in the non-scoliotic group were 0.2° and −2.5°, whereas in AIS values were 0.3° and −0.8°, respectively. For coronal and sagittal OD-HA, 27.5% and 26.8% of AIS were outside the reference corridor compared with 10.8% in non-scoliotic (OR = 3.1 and 3). Adding to the severity index a weighting factor based on coronal OD-HA, for thoracic scoliosis, improved the positive predictive value by 9% and the specificity by 13%.

Conclusion Analysis of OD-HA suggests that AIS patients are almost three times more likely to have malalignment compared with a non-scoliotic population. Furthermore, analysis of coronal OD-HA is promising to help the clinician distinguish between stable and progressive thoracic scoliosis.

Keywords Scoliosis · Adolescent · Biplanar X-ray · Early diagnosis

Abbreviations

3D	Three-dimensional
OD-HA	The odontoid-hip axis angle
AIS	Adolescent idiopathic scoliosis

Introduction

Idiopathic scoliosis is a three-dimensional (3D) spinal deformity of uncertain aetiology, which can be defined in the coronal plane by a Cobb angle of at least 10° and axial vertebral rotation [1]. Its aetiopathogeny is multifactorial and the causal factors poorly understood [2], but several

preliminary studies focus on a possible sensory imbalance at early stage [3, 4].

Recently, a validated predictive model based on 3D biplanar reconstruction (i.e. the severity index described by Skalli et al.[5]) was developed to distinguish between progressive and stable scoliosis at the first visit. However, this predictive model still needs to be improved and is based solely on the 3D reconstruction of the spine and not on the overall head-spine-pelvis alignment. Dubousset introduced the concept of the “cone of economy” to describe the ideal position of the body’s centre of gravity [6]. In a static or dynamic balanced posture, the human head is located above the pelvis in all three planes. When the centre of gravity is outside of the stability area, several musculoskeletal compensation mechanisms are activated to bring it back in. In the literature, several studies used the centre of the body of C7 as a

reference point in relation to the posterosuperior edge of the sacral plateau to assess the global balance of a subject in a static position [7].

Recently, Amabile et al. described a new quasi-invariant parameter (the odontoid-hip axis [OD-HA] angle parameter), describing the position of the head (or, more precisely, of the odontoid process of C2) relative to the pelvis, which is a proxy for the global alignment of the subject [8].

Our previous work showed that some severe scoliosis patients could present an imbalance, as quantified by an abnormal OD-HA [9]. However, it is not yet clear whether early malalignment can be detected in adolescent idiopathic scoliosis (AIS) using this new parameter from the 3D reconstruction of low-dose biplanar radiography.

Our objective was to assess abnormalities of OD-HA angle in a mild scoliotic population, relative to a control cohort, in order to determine whether screening for spine malalignment would help predict the distinction between progressive and stable scoliosis at an early stage. Furthermore, the effect of including OD-HA parameter extracted from 3D reconstruction to the severity index was studied.

Materials and methods

Subjects

This study was approved by the ethics committee (C.P.P. Ile de France VI 6001 and local hospitals' ethical committees). Parents, children, and adults were informed about the protocol and consented to participate before inclusion.

Data were collected prospectively, between 2013 and 2020, and divided into 2 groups: non-scoliotic and AIS. Data from non-scoliotic subjects were collected at a single centre, matched with the age of AIS patients and within a research protocol. These subjects underwent a radiographic examination for unrelated reasons (participation in other studies, trauma, etc.), and absence of scoliosis was checked radiologically. All non-scoliotic adolescents had no history of spinal disease, and a physical examination was performed by a physician to rule out any spinal disorder.

Data from AIS patients were obtained from 6 centres in 4 countries (with a minimal of 10% inclusions per centre) within a follow-up clinical survey. This cohort of scoliotic patients has been previously reported in studies using a severity index to predict scoliosis progression (i.e. the severity index and its six parameters) [5, 10, 11], which did not include assessment of 3D malalignment (i.e. OD-HA assessment). In the AIS group, inclusion criteria were: (1) confirmed diagnosis of AIS; (2) Cobb angle between 10° and 25°; (3) European Risser sign lower than 3 [12]; (4) age higher than 10 years; and (5) no previous treatment (such as brace or spine surgery). Patients with non-idiopathic

scoliosis, transitional anomalies or supernumerary vertebrae were excluded from this study.

Protocol

All subjects underwent a low-dose biplanar X-ray (EOS system, EOS Imaging), in the free-standing position [13], at the onset of inclusion. Patients were classified by location of the main curve [14–16], i.e. according to the location of the apex: thoracic (apex between the T2 vertebra and the T11-T12 intervertebral disc), thoracolumbar (apex between the T12 and L1 vertebrae) and lumbar (apex between the L1-L2 intervertebral disc and the L4 vertebra).

Patients were then followed until one of these two events occurred: (1) the patient reached skeletal maturity of the trunk (with a Risser sign greater than or equal to 3), without progression of the curvature (i.e. a Cobb angle of the main curvature less than 25°) and without treatment. These patients were classified as “stable”; (2) a corrective brace was prescribed, in which case patients were classified as “progressive”. Quantitative and objective criteria were used to decide on brace treatment according to the International Society on Scoliosis Orthopaedic and Rehabilitation Treatment guidelines, i.e. a Cobb angle of the main curvature greater than 25° and a Risser sign less than or equal to 2, or an increase of 5° in Cobb angle or vertebral axial rotation within 6 months [17], as well as an assessment of the clinical profile.

Imaging data and 3D reconstruction processing

A quasi-automatic 3D spine reconstruction was performed, from the biplanar radiography acquired at inclusion, using a previously validated method [11, 18]. The specific anatomical landmarks were OD, the most superior point of dentiform apophyse of C2, as an estimate of the head centre of mass, and HA was the midpoint of pelvic acetabula [8] (Fig. 1). The 3D OD-HA angle was computed automatically and then projected on the coronal and sagittal patient's planes [8]. A positive sagittal OD-HA corresponds to a frontal lean, while a positive coronal OD-HA corresponded to a lean towards the right side. The end vertebrae of the scoliotic curve were manually selected by an experienced operator, and the Cobb angle was computed automatically from the 3D reconstruction.

For each patient, the calculation of the severity index (ranging from 0 to 1) was automatic [5, 11] and considered the stage of the European Risser sign, as previously described [10]. The index was weighted according to the OD-HA value. When the OD-HA was greater than two standard deviations from the reference cohort value, a multiplication factor of 1.5 was applied. In cases where the OD-HA was less than one standard deviation from

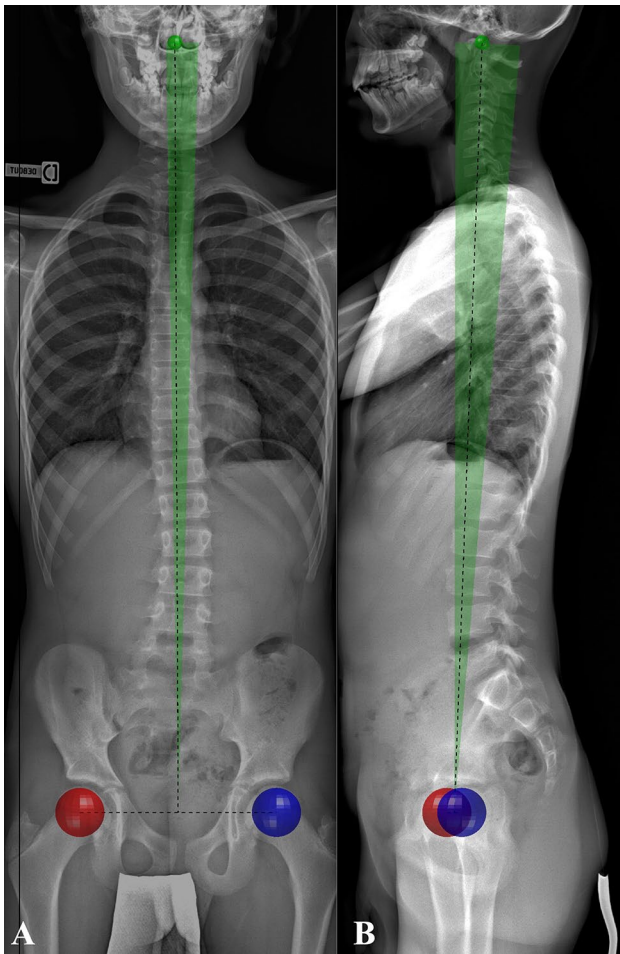


Fig. 1 Characterization of the OD-HA measurement and its reference corridor. The centre of the femoral heads is represented by the red circle on the right side and the blue circle on the left (HA). The most superior point of dentiform apophyse of C2 is represented by the green circle (OD). The black dotted line represents the measurement of the OD-HA on the frontal (a) and lateral (b) radiographs. The green zone delimits the reference corridor between the 5th and 95th percentiles of non-scoliotic patients

the normal cohort value, the multiplication factor 0.8 was applied, thus lowering the severity index. An index lower than 0.4 is indicative for a stable curve, while an index higher than 0.6 is indicative for a progressive one. No prediction was issued for values in-between, and patient was unclassified.

Statistics

Descriptive results were presented according to their mean, one standard deviation (SD) and range. After checking that values did not follow a normal distribution (Lilliefors normality test), the Mann–Whitney test was applied. Significance was set a 0.05. A reference corridor for OD-HA values in non-scoliotic subjects was calculated as the

range [5th–95th percentiles]. The number of AIS having their OD-HA values higher than the corridor’s limits was reported, and their values were defined as abnormal. Odds ratios were calculated to evaluate the relationship between abnormal OD-HA and risk of progression. Its confidence interval [5–95%] was calculated according to the Wolff method, and an interval including the value one was considered non-significant. To analyse the weighting of the severity index with the OD-HA, we reported the sensitivity, specificity, positive and negative predictive value of the test according to the locations of the curvature. Sensitivity is calculated as the ratio of the number of true positives (i.e. severity index greater than 0.6 and progression observed during follow-up) over the sum of true positives and false negatives (i.e. severity index less than 0.4 and progression observed during follow-up). Specificity is calculated as the ratio of the number of true negatives (i.e. severity index less than 0.4 and stable scoliosis during follow-up) over the sum of true negatives and false positives (i.e. severity index greater than 0.6 and stable scoliosis during follow-up). The positive predictive value is calculated as the ratio of the number of true positives to the sum of true positives and false positives, while the negative predictive value is calculated as the ratio of the number of true negatives to the sum of true negatives and false negatives.

Results

Description of population

Eighty-three non-scoliotic subjects (50 females; 33 males; 12 years old, $SD=2$) and 205 scoliosis (12 years old, $SD=1.5$; 171 females and 34 males; 88 thoracic, 52 thoracolumbar and 65 lumbar) were included. These two cohorts were not statistically different for the age criterion ($p>0.8$). Mean Cobb angle of scoliotic patients was (16.1° , $SD=3.7^\circ$; range from 10° to 24.8°). After the clinical and biplanar radiographic follow-up, 109 AIS (53%) was classified as stable and 96 (47%) as progressive. In the stable patients, the European Risser sign was evenly distributed (0 in 42/109, 1 in 32/109, 2 in 35/109 patients). In the progressive group, a European Risser sign was 0 in 78/96 patients, while it was only 1 and 2 in 18/96 patients. The demographic characteristics are resumed in Table 1.

OD-HA parameters

In the non-scoliotic group, coronal OD-HA was 0.2° , $SD=1^\circ$ with a range between 5 and 95th percentile range from -1° to 2° , while sagittal OD-HA was -2.5° , $SD=2.4^\circ$ with a range from -6° to 1° (illustrated in Fig. 1). In AIS, mean coronal OD-HA was 0.3° , $SD=1.4^\circ$; range from -4.6°

Table 1 Demographics characteristics of population

	Non-scoliotic (<i>n</i> = 83)	AIS population		
		Total (<i>n</i> = 205)	Stable (<i>n</i> = 109)	Progressive (<i>n</i> = 96)
Age: yo, SD (range)	12, 4 (7–18)	12, 1 (10–15)	12, 1 (10–15)	11, 1 (10–14.5)
Gender: <i>n</i> (%)				
Girls	58 (70%)	171 (83%)	90 (83%)	81 (84%)
Boys	25 (30%)	34 (17%)	19 (17%)	15 (16%)
Curve topography: <i>n</i> (%)				
Thoracic		88 (43%)	46 (42%)	42 (44%)
Thoraco-lumbar		52 (25%)	27 (25%)	25 (26%)
Lumbar		65 (32%)	36 (33%)	29 (30%)
Cobb angle (°): mean, SD (range)		16.1, 4.4 (8.8–24.8)	14.7, 4.6 (8.8–22.8)	17.4, 3.8 (10.3–24.8)

n is the number of patients included

Table 2 Number of AIS with OD-HA position values outside the reference corridor based on the topography of the main curvature

	Thoracic (<i>n</i> = 88)	Thoraco-lumbar (<i>n</i> = 52)	Lumbar (<i>n</i> = 65)
Coronal OD-HA: <i>n</i> (%)	25 (28%)	16 (31%)	15 (23%)
Sagittal OD-HA: <i>n</i> (%)	19 (21%)	14 (27%)	22 (34%)
3D OD-HA: <i>n</i> (%)	14 (16%)	9 (17%)	13 (20%)

n is the number of patients included

to 4.3° and the mean sagittal OD-HA was −0.8°, SD = 2.5°; range from −9° to 5.6°. Nine non-scoliotic subjects (*N* = 83, 10.8%) and 56 AIS (*N* = 205, 27.5%) were outside the reference corridor for coronal OD-HA (OR = 3.1; CI = 1.4–6.6). For sagittal OD-HA, nine non-scoliotic subjects (*N* = 83, 10.8%) and 55 AIS (*N* = 205, 26.8%) were outside the reference corridor (OR = 3; CI = 1.4–6.4). The 3D position of OD relative to the inter-hip axis suggests that AIS patients are almost two times more likely to have an abnormal OD-HA value (OR = 2.3; CI = 1.1–4.9). The number of AIS with abnormal OD-HA position values did not differ by curvature location (*p* = 0.2) (Table 2).

OD-HA analysis by patient outcome

The mean coronal and sagittal OD-HAs were 0.3° (SD = 1.2°; range −4.6° to 4°) and −0.8° (SD = 2.5°; range −9.1° to 5.3°) in stable scoliosis, while the means were, respectively, 0.4° (SD = 1.5°; range −3.6° to 4.5°) and −0.8° (SD = 2.6°; range −7° to 5.6°) in progressive scoliosis. For coronal OD-HA, 20 stable scoliosis (*N* = 109) and 36 progressive patients (*N* = 96) were outside the reference corridor (OR = 2.7; CI = 1.4–5). For sagittal OD-HA, 25 stable AIS (*N* = 109) and 30 progressive patients (*N* = 96) were outside

the reference corridor (OR = 1.5; CI = 0.8–2.8). For the 3D OD-HA (i.e. position of OD relative to the inter-hip axis), the odds ratio was of 2.2 (CI = 1–4.5). Focussing on the topography of the curvature, the odds ratios were not significant (i.e. the confident interval includes the value of one).

OD-HA and the severity index

Following the previous results, only the odds ratio of coronal OD-HA between stable and progressive scoliosis was significant. Therefore, the weighting of the S-index was performed only with the coronal OD-HA values. All results are summarized in Table 3. Adding to the s-index a weighting factor based on coronal OD-HA improved the positive predictive value by 6% (from 78% to 84%) and the specificity by 7% (from 78% to 85%). For thoracic scoliosis, the specificity increases by 13% (from 73% to 86%) and the positive predictive value by 9% (from 77% to 86%).

Discussion

In this study, the measurement of the OD-HA position could be determined in a healthy adolescent population and in AIS. This 3D measurement is based on a quasi-automatic reconstruction method [18] which can be compatible with daily clinical practice since it takes less than 5 min.

Previously, several angles and distances have been described to assess the overall balance of the spine. For instance, the sagittal T9 plumbline described by Beauval-Beaupère who considered T9 to approximate the trunk's centre of gravity. The coronal and sagittal C7 plumblines are commonly used to assess the balance of the thoracic and lumbar spine [19]. The disadvantage of these parameters is that it does not consider the alignment of the superior cervical spine-hip axis. As an example, Kim et al. showed the clinical relevance of OD-HA angle assessment in 199

Table 3 Classification, performance of index with coronal OD-HA weighting according to curve location

	Total cohort		Thoracic scoliosis		Thoraco-lumbar scoliosis		Lumbar scoliosis	
	S-index	S-index*	S-index	S-index*	S-index	S-index*	S-index	S-index*
Sample size: <i>n</i>	205		88		52		65	
Stable scoliosis: <i>n</i>	108		46		28		34	
Progressive scoliosis: <i>n</i>	97		42		24		31	
Correctly classified: <i>n</i> (%)	154 (75%)	149 (73%)	66 (75%)	63 (72%)	39 (75%)	38 (73%)	49 (75%)	48 (74%)
Misclassified: <i>n</i> (%)	35 (17%)	25 (12%)	15 (17%)	8 (9%)	9 (17%)	7 (13%)	11 (17%)	10 (15%)
Unclassified: <i>n</i> (%)	16 (8%)	31 (15%)	7 (8%)	17 (19%)	4 (8%)	7 (13%)	5 (8%)	7 (11%)
Sensitivity (%)	87%	87%	90%	91%	73%	76%	89%	89%
Specificity (%)	78%	85%	73%	86%	88%	92%	75%	77%
Positive predictive value (%)	78%	84%	77%	86%	84%	89%	76%	77%
Negative predictive value (%)	85%	88%	88%	91%	79%	81%	89%	89%

n is the number of patients; S-index * corresponds at the S-index with OD-HA weighting. Values in italics and bold are values for which the weighting of the S-index increased the performance of the test by 5%

adults undergoing spinal deformity surgery. As a result, the OD-HA angle measurement was correlated with the quality-of-life score and mechanical complications, while the T1-pelvis angle was associated with the spino-pelvic parameter [20]. Gangnet et al. [21] described the 3D position of the line connecting the middle of the external acoustic meatus to the middle of the bi-coxo-femoral axis. The measurement of the OD-HA position is a natural extension of this, since it approximates the position of the head's centre of mass, like the centre of the acoustic meatus, but it is more clearly visible in radiographs. The OD-HA parameter can therefore complement other 3D radiographic analyses of alignment, including the upper and lower cervical spine, the pelvic vertebrae and the lower limb. Previous studies have shown that OD-HA can be reliable. According to Amabile et al. [8], OD was marked in 12 non-scoliotic patients with 48 repetitions by two operators. The 95% confidence interval was 2.0 mm for X, anteroposterior direction; 1.2 mm for Y, mediolateral direction; and 2.2 mm for Z, superior direction, respectively. Langlais et al. [22] found that OD-HA measurement in pre- and postoperative AIS patients had a measurement uncertainty of around 0.2° or less. In our study, we found values for coronal and sagittal OD-HA in the non-scoliotic group around 0.2° (SD=1°) and -2.5° (SD=2.4°). In a population of 516 subjects of Chinese origin and non-scoliotic, Hu et al. found values around 0.2° (SD=1.1°) for the coronal and -0.2° (SD=2.5°) for the sagittal angle. The same authors also showed that there was a positive (or negative) correlation between the sagittal (or coronal) OD-HA value and age [23]. In other words, the OD-HA values varied with age (and more precisely between from 20 and 80 s) by 2.45° for the sagittal measure and by 1.06° for the coronal angle [23]. These small physiological variations are consistent with the fact that the OD-HA angle is quasi-invariant [8] and that the head tends to remain above the pelvis in a small cone of stability.

The main finding of this work suggests that AIS patients can show almost three times the odds to have a coronal and sagittal OD-HA malalignment and this at an early stage. Different strategies can be deployed to maintain postural alignment and a constant position of the OD-HA, which has been demonstrated to be invariant even during breathing [24]. These strategies can involve the whole body from head to toe, and they depend on the functional capacities of each subject. For example, elderly people prefer to recruit compensation mechanisms in the pelvis, cervical spine and ultimately lower limbs [8, 25, 26]. For example, Ferrero et al. [27] (2021) found extreme OD-HA values in significantly elderly patients with significant functional impairment. These subjects with sagittal malalignment and loss of lumbar lordosis recruited compensatory mechanisms such as pelvic retroversion, cervical hyper-lordosis to maintain the head above the pelvis. On the other hand, young subjects can

adjust their spinal-pelvic alignment by adjusting the curvature of their spine and the orientation of their pelvis, or even the shape of their pelvis by a modification of the incidence [28–30]. Indeed, with an approximate head weight of 4 to 5 kg [31, 32], it appears that a strict alignment of the head upon the pelvis is a requirement for an economic posture. Failing to maintain the head upon the pelvis could indicate abnormal balance, but the mechanism is still to investigate.

The other interesting finding is that progressive scoliosis is almost three times more likely to have coronal OD-HA malalignment than stable thoracic scoliosis without difference between topography of curvature. It is still difficult to understand the origin of this global malalignment of the scoliotic patient, especially in progressive scoliosis. Numerous studies have shown that global alignment is closely linked to neurological sensory inputs [33] such as oculomotor [34], vestibular [35] or proprioceptive [36] systems. The position of the OD-HA is a quasi-invariant factor, and the results of this study show that it could be a biomarker of progression in thoracic scoliosis. However, it is probably not the only marker involved in the progression of the biomechanical cascade. Disturbances in the mechanical properties of the intervertebral discs probably play a role in the progression of curvature and torsion of the axial plane [37], especially at the junctional levels [38]. These biomechanical mechanisms seem to be interrelated.

Finally, we assessed the influence of the coronal OD-HA measurement on the previously published severity index [5]. For thoracic scoliosis, the specificity and predictive positive value are improved by 13% and 9%, respectively, and thus increase the probability of being a stable scoliosis when the index is less than 0.4 and of being a progressive scoliosis when the index is greater than 0.6. In clinical practice, this means that we decrease the number of false positives, so we treat less stable scoliosis, but we do not significantly decrease the risk of mistaking progressive scoliosis as stable scoliosis. Indeed, this weighting decreases the number of misclassified patients by 8% and therefore the risk of over- or under-treatment. However, it also decreases the number of correctly classified patients by 3%. This apparently contradictory result is explained by the increased number of unclassified patients by 11% and therefore challenges the clinician to insist on close monitoring of this scoliosis whose index is between 0.4 and 0.6 (as illustrated in Fig. 2). A factorial discriminant analysis could in the future allow the addition of coronal OD-HA to the severity index, under the defined conditions. Meanwhile, the coronal OD-HA is a factor that the clinician could consider at the first visit, particularly for the thoracic curves (as illustrated in Fig. 3).

The main limitation of this work is that this study focuses on a static approach and therefore focuses on alignment. However, it has been established that the dynamic proprioceptive system is affected in patients with

Fig. 2 Illustration of sagittal and coronal OD-HA measurement on the biplanar inclusion radiograph of a thoracic scoliosis. The S-index was 0.70 and classified the scoliosis as “progressive”, whereas the radiograph 3 years later (illustrated by the image on the right) shows that the scoliosis is stable. Weighting by coronal OD-HA brings the S-index down to 0.56 (<0.6) and thus into the unclassified group

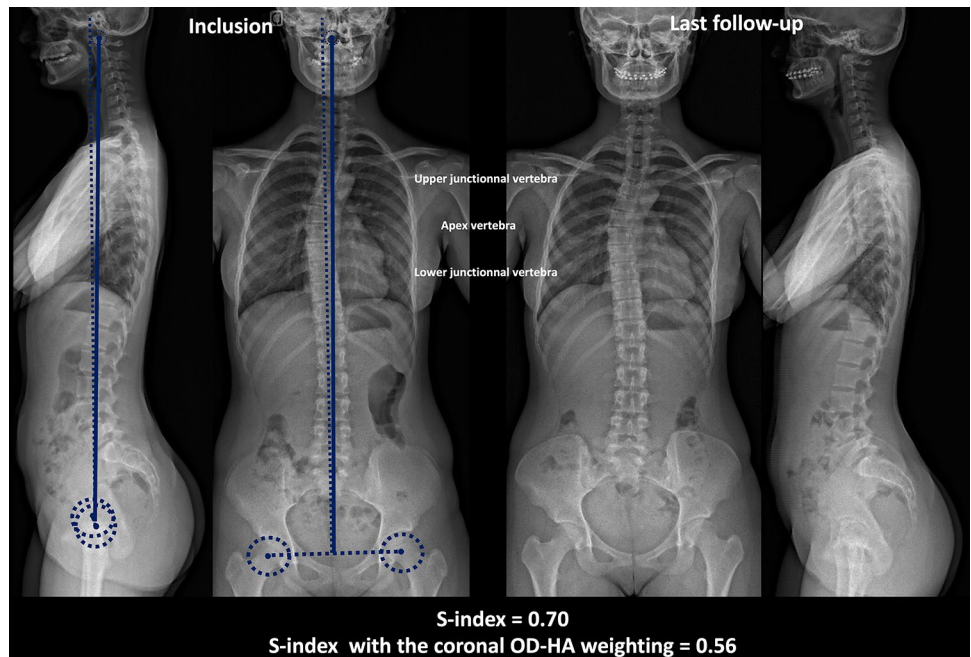
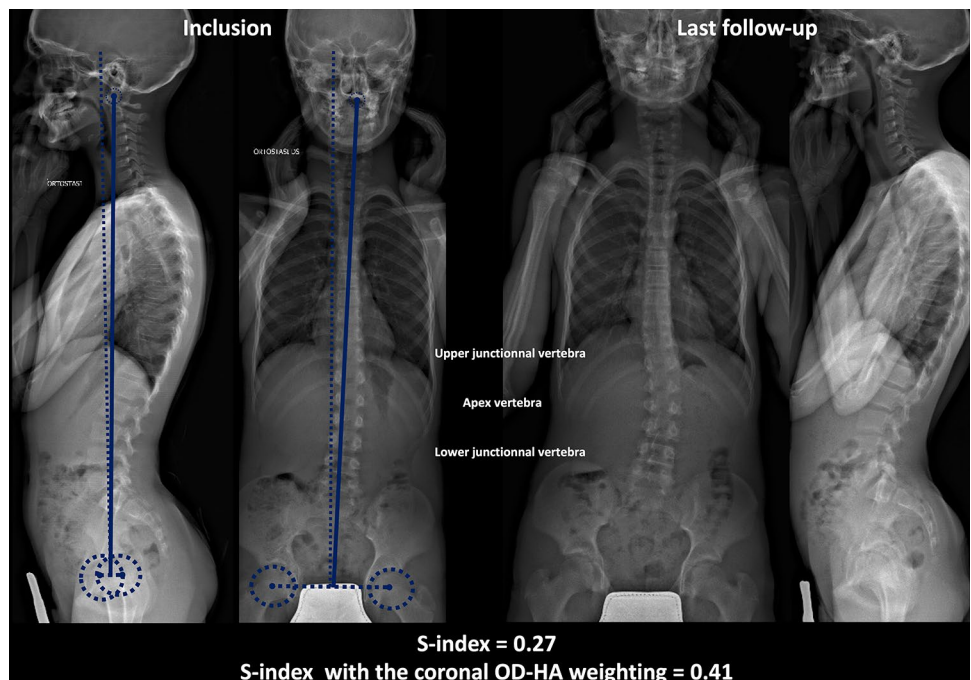


Fig. 3 Illustration of sagittal and coronal OD-HA measurement on the biplanar inclusion radiograph of a lumbar scoliosis. The S-index was 0.27 and classified the scoliosis as “stable”, whereas the radiograph 2 years later (illustrated by the image on the right) shows that the scoliosis is progressive. Weighting by coronal OD-HA brings the S-index down to 0.41 (<0.4) and thus into the unclassified group



idiopathic scoliosis [3]. Rebeyrat et al. [39] investigated changes in dynamic OD-HA on adult spinal deformities and found that dynamically unbalanced spinal patients had postural malalignments that persisted during walking, associated with kinematic alterations of the trunk, pelvis and lower limbs, making them more prone to falls. For thoracic AIS with abnormal radiological OD-HA, further investigations could concern how dynamic OD-HA is

affected, providing a better understanding of the relationship between malalignment and imbalance.

The second limitation is that the Cobb angle of the main curvature of progressive scoliosis was larger than that of stable scoliosis. This difference could indirectly increase the ratio of patients with abnormal and normal 3D OH-HA position. Finally, although high odds ratios have been estimated in this study, the confidence intervals

suggest that their significance could be low (confidence interval close to one). A study on a larger cohort could give a more robust answer to the question of malalignment in early scoliosis.

Conclusion

Analysis of OD-HA (coronal and sagittal) malalignment, using biplanar radiographs, suggests that AIS patients are almost three times more likely to have malalignment and at an early stage compared with a non-scoliotic population. Furthermore, analysis of coronal OD-HA malalignment is promising to help the clinician distinguish between stable and progressive thoracic scoliosis at an early stage, and increases the specificity of the severity index by 13%.

Acknowledgements The authors are grateful to the BiomecAM chair programme on subject-specific musculoskeletal modelling (with the support of ParisTech and Yves Cotrel Foundations, Société Générale, Covea and Proteor).

Funding This study has received funding from the BiomecAM chair programme on subject-specific musculoskeletal modelling (with the support of ParisTech and Yves Cotrel Foundations, Société Générale, Covea and Proteor).

Declarations

Competing interest Wafa Skalli has a patent related to biplanar X-rays and associated 3D reconstruction methods, with no personal financial benefit (royalties rewarded for research and education) licenced to EOS imaging. Raphael Vialle reports personal fees and grants (unrelated to this study) from Stryker. The other authors of this manuscript declare no relationships with any companies, whose products or services may be related to the subject matter of the article.

Ethical approval and informed consent Institutional review board approval was obtained. Written informed consent was obtained from all subjects (patients) in this study.

Data availability statements The datasets generated during and/or analysed during the current study are available from the corresponding author on reasonable request.

Study subjects or cohorts overlap Some study subjects or cohorts have been previously reported in:

(*N* = 138) Vergari et al. 2022: Spine slenderness is not an early sign of progression in adolescent idiopathic scoliosis. *Medical Engineering and Physics*

(*N* = 205) Vergari et al., 2021: Effect of curve location on the severity index for adolescent idiopathic scoliosis: a longitudinal cohort study. *European Radiology*

(*N* = 55) Vergari et al., 2019: Quasi-automatic early detection of progressive idiopathic scoliosis from biplanar radiography a preliminary validation. *European Spine Journal*


(*N* = 65) Skalli et al., 2017: Early detection of progressive adolescent idiopathic scoliosis a severity index. *Spine*

References

1. RW Coonrad GA Murrell G Motley 1998 A logical coronal pattern classification of 2,000 consecutive idiopathic scoliosis cases based on the scoliosis research society-defined apical vertebra *Spine (Phila Pa 1976)* 23 1380 1391 <https://doi.org/10.1097/00007632-199806150-00016>
2. J-WM Kouwenhoven RM Castelein 2008 The pathogenesis of adolescent idiopathic scoliosis: review of the literature *Spine (Phila Pa 1976)* 33 2898 2908 <https://doi.org/10.1097/BRS.0b013e3181891751>
3. C Assaiante S Mallau J-L Jouve 2012 Do Adolescent Idiopathic Scoliosis (AIS) neglect proprioceptive information in sensory integration of postural control? *PLoS ONE* 7 e40646 <https://doi.org/10.1371/journal.pone.0040646>
4. X Guo WW Chau CWY Hui-Chan 2006 Balance control in adolescents with idiopathic scoliosis and disturbed somatosensory function *Spine* 31 E437 E440 <https://doi.org/10.1097/01.brs.0000222048.47010.bf>
5. W Skalli C Vergari E Ebermeyer 2017 Early detection of progressive adolescent idiopathic scoliosis: a severity index *Spine* 42 823 830 <https://doi.org/10.1097/BRS.0000000000001961>
6. Hasegawa K, Duboussset JF (2022) Cone of economy with the chain of balance-historical perspective and proof of concept. *Spine Surg Relat Res* 6:337–349. <https://doi.org/10.22603/ssrr.2022-0038>
7. E Berthonnaud J Dimnet P Roussouly H Labelle 2005 Analysis of the sagittal balance of the spine and pelvis using shape and orientation parameters *J Spinal Disord Tech* 18 40 47 <https://doi.org/10.1097/01.bsd.0000117542.88865.77>
8. C Amabile H Pillet V Lafage 2016 A new quasi-invariant parameter characterizing the postural alignment of young asymptomatic adults *Eur Spine J* 25 3666 3674 <https://doi.org/10.1007/s00586-016-4552-y>
9. M Karam I Ghanem C Vergari 2022 Global malalignment in adolescent idiopathic scoliosis: the axial deformity is the main driver *Eur Spine J* 31 2326 2338 <https://doi.org/10.1007/s00586-021-07101-x>
10. C Vergari W Skalli K Abelin-Genevois 2021 Effect of curve location on the severity index for adolescent idiopathic scoliosis: a longitudinal cohort study *Eur Radiol* 31 8488 8497 <https://doi.org/10.1007/s00330-021-07944-4>
11. C Vergari L Gajny I Courtois 2019 Quasi-automatic early detection of progressive idiopathic scoliosis from biplanar radiography: a preliminary validation *Eur Spine J* 28 1970 1976 <https://doi.org/10.1007/s00586-019-05998-z>
12. Bitan FD, Veliskakis KP, Campbell BC (2005) Differences in the Risser grading systems in the United States and France. *Clin Orthop Relat Res* 190–195. <https://doi.org/10.1097/01.blo.0000160819.10767.88>
13. FD Faro MC Marks J Pawelek PO Newton 2004 Evaluation of a functional position for lateral radiograph acquisition in adolescent idiopathic scoliosis *Spine (Phila Pa 1976)* 29 2284 2289 <https://doi.org/10.1097/01.brs.0000142224.46796.a7>
14. P Stagnara P Queneau 1953 Developmental scolioses during the period of growth; clinical and radiological aspects and therapeutic considerations *Rev Chir Orthop Reparatrice Appar Mot* 39 378 452
15. Perdriolle R (1979) La scoliose: son étude tridimensionnelle
16. Lenke LG, Betz RR, Clements D, et al (2002) Curve prevalence of a new classification of operative adolescent idiopathic scoliosis: does classification correlate with treatment? *Spine (Phila Pa 1976)* 27:604–611. <https://doi.org/10.1097/00007632-200203150-00008>
17. Negrini S, Donzelli S, Wynes J, Zaina F (2018) 2016 SOSORT guidelines: orthopaedic and rehabilitation treatment of idiopathic

- scoliosis during growth - PubMed. <https://pubmed.ncbi.nlm.nih.gov/29435499/>. Accessed 8 Oct 2022
18. L Gajny S Ebrahimi C Vergari 2019 Quasi-automatic 3D reconstruction of the full spine from low-dose biplanar X-rays based on statistical inferences and image analysis *Eur Spine J* 28 658 664 <https://doi.org/10.1007/s00586-018-5807-6>
 19. RC Clement J Anari CE Bartley 2020 What are normal radiographic spine and shoulder balance parameters among adolescent patients? *Spine Deform* 8 621 627 <https://doi.org/10.1007/s43390-020-00074-9>
 20. Kim K-R, Le Huec J-C, Jang H-J, et al (2021) Which is more predictive value for mechanical complications: fixed thoracolumbar alignment (T1 pelvic angle) versus dynamic global balance parameter (odontoid-hip axis angle). *Neurospine* 18:597–607. <https://doi.org/10.14245/ns.2142452.226>
 21. N Gangnet V Pomero R Dumas 2003 Variability of the spine and pelvis location with respect to the gravity line: a three-dimensional stereoradiographic study using a force platform *Surg Radiol Anat* 25 424 433 <https://doi.org/10.1007/s00276-003-0154-6>
 22. T Langlais C Vergari G Rougureau 2021 Balance, barycentremetry and external shape analysis in idiopathic scoliosis: What can the physician expect from it? *Med Eng Phys* 94 33 40 <https://doi.org/10.1016/j.medengphy.2021.06.004>
 23. Hu Z, Vergari C, Gajny L, et al (2022) An analysis on the determinants of head to pelvic balance in a Chinese adult population. *Quant Imaging Med Surg* 12:2311–2320. <https://doi.org/10.21037/qjms-21-718>
 24. L Clavel V Attali I Rivals 2020 Decreased respiratory-related postural perturbations at the cervical level under cognitive load *Eur J Appl Physiol* 120 1063 1074 <https://doi.org/10.1007/s00421-020-04345-1>
 25. C Barrey S Champain S Campana 2012 Sagittal alignment and kinematics at instrumented and adjacent levels after total disc replacement in the cervical spine *Eur Spine J* 21 1648 1659 <https://doi.org/10.1007/s00586-012-2180-8>
 26. BG Diebo JJ Varghese R Lafage 2015 Sagittal alignment of the spine: What do you need to know? *Clin Neurol Neurosurg* 139 295 301 <https://doi.org/10.1016/j.clineuro.2015.10.024>
 27. E Ferrero P Guigui M Khalifé 2021 Global alignment taking into account the cervical spine with odontoid hip axis angle (OD-HA) *Eur Spine J* 30 3647 3655 <https://doi.org/10.1007/s00586-021-06991-1>
 28. F Schwab V Lafage R Boyce 2006 Gravity line analysis in adult volunteers: age-related correlation with spinal parameters, pelvic parameters, and foot position *Spine (Phila Pa 1976)* 31 E959 E967 <https://doi.org/10.1097/01.brs.0000248126.96737.0f>
 29. C Vidal K Mazda B Ilharreborde 2016 Sagittal spino-pelvic adjustment in severe Lenke 1 hypokyphotic adolescent idiopathic scoliosis patients *Eur Spine J* 25 3162 3169 <https://doi.org/10.1007/s00586-016-4681-3>
 30. A Alzakri C Vergari M Abbeele Van den 2019 Global sagittal alignment and proximal junctional kyphosis in adolescent idiopathic scoliosis *Spine Deform* 7 236 244 <https://doi.org/10.1016/j.jspd.2018.06.014>
 31. JM Vital J Senegas 1986 Anatomical bases of the study of the constraints to which the cervical spine is subject in the sagittal plane. A study of the center of gravity of the head *Surg Radiol Anat* 8 169 173 <https://doi.org/10.1007/BF02427845>
 32. B Sandoz S Laporte W Skalli D Mitton 2010 Subject-specific body segment parameters' estimation using biplanar X-rays: a feasibility study *Comput Methods Biomech Biomed Eng* 13 649 654 <https://doi.org/10.1080/10255841003717608>
 33. DC Gómez Crisanchó G Jovel Trujillo IF Manrique 2023 Neurological mechanisms involved in idiopathic scoliosis. Systematic review of the literature *Neurocirugia (Astur : Engl Ed)* 34 1 11 <https://doi.org/10.1016/j.neucie.2022.02.009>
 34. A Lion T Haumont GC Gauchard 2013 Visuo-oculomotor deficiency at early-stage idiopathic scoliosis in adolescent girls *Spine (Phila Pa 1976)* 38 238 244 <https://doi.org/10.1097/BRS.0b013e31826a3b05>
 35. J-P Pialasse M Descarreaux P Mercier 2015 The vestibular-evoked postural response of adolescents with idiopathic scoliosis is altered *PLoS ONE* 10 e0143124 <https://doi.org/10.1371/journal.pone.0143124>
 36. J-P Pialasse P Mercier M Descarreaux M Simoneau 2017 A procedure to detect abnormal sensorimotor control in adolescents with idiopathic scoliosis *Gait Posture* 57 124 129 <https://doi.org/10.1016/j.gaitpost.2017.05.032>
 37. M Karam C Vergari W Skalli 2022 Assessment of the axial plane deformity in subjects with adolescent idiopathic scoliosis and its relationship to the frontal and sagittal planes *Spine Deform* 10 509 514 <https://doi.org/10.1007/s43390-021-00443-y>
 38. T Langlais C Vergari R Pietton 2018 Shear-wave elastography can evaluate annulus fibrosus alteration in adolescent scoliosis *Eur Radiol* 28 2830 2837 <https://doi.org/10.1007/s00330-018-5309-2>
 39. G Rebeyrat W Skalli R Rachkidi 2022 Assessment of dynamic balance during walking in patients with adult spinal deformity *Eur Spine J* 31 1736 1744 <https://doi.org/10.1007/s00586-022-07199-7>

Authors and Affiliations

Tristan Langlais^{1,2}  · Claudio Vergari¹ · Gregoire Rougureau³ · Mathilde Gaume⁴ · Laurent Gajny¹ · Kariman Abelin-Genevois⁵ · Jean Claude Bernard⁵ · Zongshan Hu⁶ · Jack Chun Yiu Cheng⁶ · Winnie Chiu Wing Chu⁷ · Ayman Assi^{1,8} · Mohamad Karam⁸ · Ismat Ghanem^{8,9} · Tito Bassani¹⁰ · Fabio Galbusera¹¹ · Luca Maria Sconfienza^{10,12} · Marco Brayda-Bruno¹⁰ · Isabelle Courtois¹³ · Eric Ebermeyer¹³ · Raphael Vialle¹⁴ · Jean Dubouset¹ · Wafa Skalli¹

✉ Tristan Langlais
tristanlanglais@yahoo.fr

¹ Institut de Biomécanique Humaine Georges Charpak, Arts et Métiers, HESAM Université, Paris, France

² Service Orthopédie et Traumatologie, Hôpital des Enfants, Purpan, Toulouse Université, Toulouse, France

³ Service Orthopédie et Traumatologie, Hôpital Pitié-Salpêtrière, Sorbonne Université, APHP, Paris, France

- 4 Service Orthopédie et Traumatologie, Hôpital Necker Enfants Malades, Paris cité Université, APHP, Paris, France
- 5 Department of Orthopaedic Surgery and Children Conservative Treatment, Croix-Rouge Française. Centre Médico-Chirurgical Et de Réadaptation Des Massues, Lyon, France
- 6 SH Ho Scoliosis Research Laboratory, Department of Orthopaedics and Traumatology, Faculty of Medicine, The Prince of Wales Hospital, The Chinese University of Hong Kong, Shatin, Hong Kong SAR, China
- 7 Department of Imaging and Interventional Radiology, Faculty of Medicine, The Prince of Wales Hospital, The Chinese University of Hong Kong, Shatin, Hong Kong SAR, China
- 8 Laboratory of Biomechanics and Medical Imaging, Faculty of Medicine, Joseph University of Beirut, SaintBeirut, Lebanon
- 9 Department of Orthopedic Surgery, Hotel-Dieu de France Hospital, Saint Joseph University, Beirut, Lebanon
- 10 IRCCS Istituto Ortopedico Galeazzi, Milan, Italy
- 11 Spine Center, Schulthess Clinic, Zurich, Switzerland
- 12 Dipartimento di Scienze Biomediche per la Salute, Università Degli Studi di Milano, Milan, Italy
- 13 Unite Rachis, CHU - Hopital Bellevue, Saint-Etienne, France
- 14 Sorbonne Université, Service Orthopédie et Traumatologie, Hôpital A. Trousseau, APHP, Paris, France