



HAL
open science

Interactions between avian viruses and skin in farm birds

Laurent Souci, Caroline Denesvre

► **To cite this version:**

Laurent Souci, Caroline Denesvre. Interactions between avian viruses and skin in farm birds. Veterinary Research, 2024, 55 (1), pp.54. 10.1186/s13567-024-01310-0 . hal-04562218

HAL Id: hal-04562218

<https://hal.science/hal-04562218>

Submitted on 29 Apr 2024

HAL is a multi-disciplinary open access archive for the deposit and dissemination of scientific research documents, whether they are published or not. The documents may come from teaching and research institutions in France or abroad, or from public or private research centers.

L'archive ouverte pluridisciplinaire **HAL**, est destinée au dépôt et à la diffusion de documents scientifiques de niveau recherche, publiés ou non, émanant des établissements d'enseignement et de recherche français ou étrangers, des laboratoires publics ou privés.



Distributed under a Creative Commons Attribution 4.0 International License

REVIEW

Open Access



Interactions between avian viruses and skin in farm birds

Laurent Souci¹ and Caroline Denesvre^{1*}

Abstract

This article reviews the avian viruses that infect the skin of domestic farm birds of primary economic importance: chicken, duck, turkey, and goose. Many avian viruses (e.g., poxviruses, herpesviruses, Influenza viruses, retroviruses) leading to pathologies infect the skin and the appendages of these birds. Some of these viruses (e.g., Marek's disease virus, avian influenza viruses) have had and/or still have a devastating impact on the poultry economy. The skin tropism of these viruses is key to the pathology and virus life cycle, in particular for virus entry, shedding, and/or transmission. In addition, for some emergent arboviruses, such as flaviviruses, the skin is often the entry gate of the virus after mosquito bites, whether or not the host develops symptoms (e.g., West Nile virus). Various avian skin models, from primary cells to three-dimensional models, are currently available to better understand virus-skin interactions (such as replication, pathogenesis, cell response, and co-infection). These models may be key to finding solutions to prevent or halt viral infection in poultry.

Keywords Avian viruses, skin tropism, feathers, keratinocytes, in vitro skin models, chicken, duck

Table of Contents

1 Introduction to avian skin and integuments

- 1.1 Organization of the chicken skin
- 1.2 Hard and soft skin appendages in chicken
- 1.3 Immune component of the skin

2 Viruses infecting avian skin and/or skin appendages

- 2.1 Poxviruses
- 2.2 Herpesviruses
 - 2.2.1 Marek's disease virus
 - 2.2.2 Herpesvirus of turkey and Gallid Herpesvirus type 3
 - 2.2.3 Infectious laryngo-tracheitis virus
- 2.3 Circoviruses and groviruses

2.3.1 Goose circovirus

2.3.2 Duck circovirus

2.3.3 Psittacine beak and feather disease virus

2.3.4 The chicken anemia virus

2.4 Retroviruses

2.4.1 Avian leukosis virus

2.4.2 Reticuloendotheliosis virus

2.5 Influenza viruses type A

2.6 Flavivirus

2.6.1 West Nile virus

2.6.2 Usutu virus

2.6.3 Duck Tembusu

2.7 Polyomaviridae and Papillomaviridae

2.8 Parvoviruses

3 In vitro avian skin models to study avian virus-skin interactions

3.1 Primary cells keratinocytes

3.2 Keratinocyte cell lines

Handling editor: Marie Galloux

*Correspondence:

Caroline Denesvre
caroline.denesvre@inrae.fr

¹ Laboratoire de Biologie des Virus Aviaires, UMR1282 ISP, INRAE Centre Val-de-Loire, 37380 Nouzilly, France



© The Author(s) 2024. **Open Access** This article is licensed under a Creative Commons Attribution 4.0 International License, which permits use, sharing, adaptation, distribution and reproduction in any medium or format, as long as you give appropriate credit to the original author(s) and the source, provide a link to the Creative Commons licence, and indicate if changes were made. The images or other third party material in this article are included in the article's Creative Commons licence, unless indicated otherwise in a credit line to the material. If material is not included in the article's Creative Commons licence and your intended use is not permitted by statutory regulation or exceeds the permitted use, you will need to obtain permission directly from the copyright holder. To view a copy of this licence, visit <http://creativecommons.org/licenses/by/4.0/>. The Creative Commons Public Domain Dedication waiver (<http://creativecommons.org/publicdomain/zero/1.0/>) applies to the data made available in this article, unless otherwise stated in a credit line to the data.

- 3.3 Skin explants cultivation in vitro
- 3.4 Feather follicle cultivation
- 3.5 Reconstituted skin equivalent
- 3.6 Potential of skin models for studying the skin immune response

4 Conclusion

References

1 Introduction to avian skin and integuments

Since the chicken is the most studied bird in terms of pathology and anatomy, as well as the third animal model in biomedical research [1], chicken skin will be used as a reference herein. Important differences between chicken and duck, goose, or turkey skins will be mentioned at the end of this section.

The chicken skin or tegument consists of the skin itself, invaginated glands, and protruded appendages, such as feathers and scales. It ensures diverse roles: (i) physical protection against external aggressors including pathogens, (ii) regulation of thermal, hygrometric, and chemical parameters, (iii) waterproofing, providing a permeability barrier to prevent water loss, (iv) matting and locomotion [2].

1.1 Organization of the chicken skin

Like in mammals, chicken skin consists of a dermis covered by an epidermis, both separated by a basement membrane [3] (Figure 1). The dermis is composed of different cell types (fibroblasts, endothelial cells, and immune cells) and is rich in dense irregular connective tissue. The epidermis is a stratified squamous epithelium, containing mostly keratinocytes. The epidermis of chicken is composed of three layers, from the deepest to the most superficial: (i) the basal layer, (ii) the intermediate layer, and (iii) the cornified layer. Keratinocytes proliferate in the basal layer and then differentiate and stratify gradually into suprabasal layers through a process called terminal differentiation [4]. This is accompanied with cornification, a programmed cell death (as reviewed by Eckhart [5]). This results in flat dead keratinocytes (called corneocytes) which cover the surface of the epidermis in contact with the air or water [5]. In unfeathered skin, the maintenance of the epidermal homeostasis is secured by a constant shedding of corneocytes balanced by a cell replacement with differentiating keratinocytes. The new keratinocytes arise from a pool of epidermal stem cells located in the basal layer [5, 6]. Chicken skin presents several major differences with mammal skin. The chicken

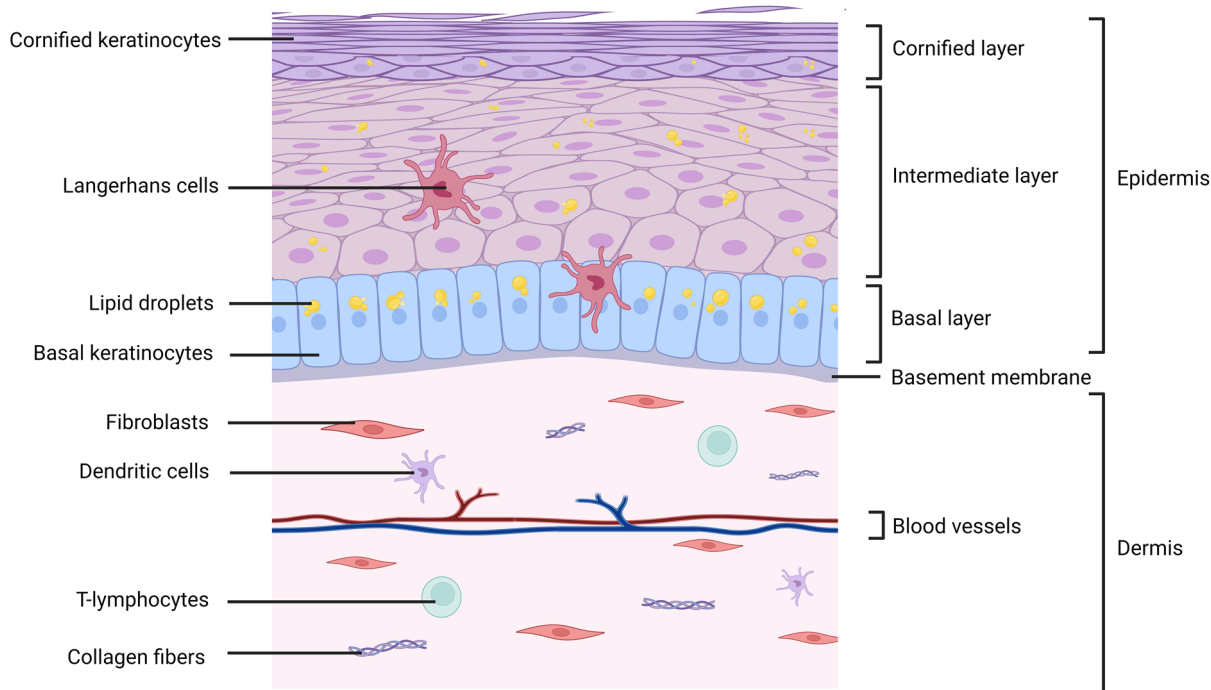


Figure 1 Structure of the avian skin. Skin is constituted by an epidermis and a dermis separated by the basement membrane. Three layers constitute bird's epidermis: the basal layer made of undifferentiated basal keratinocytes, the intermediate layer and the cornified layer made of cornified keratinocytes that are fully differentiated. Keratinocytes are rich in lipids and/or lipid droplets. The dermis is a fibrous vascularized structure mainly composed of fibroblasts and of matrix components such as collagen fibers. By analogy to mammals, it is probable that dendritic cells and T-lymphocytes also reside in the dermis. Langerhans cells are present in basal but also intermediate layers of the epidermis. This figure was illustrated by using BioRender.com (Agreement number: XJ26EG35BS).

epidermis is thinner, given the absence of the granular layer [7]. Chicken keratinocytes accumulate intracellular lipid droplets [8, 9], a feature that protects against dehydration in absence of sebaceous glands. Lastly, avian epidermis exhibits feathers, instead of hair in mammals.

1.2 Hard and soft skin appendages in chicken

About a century ago (1883), Jeffries stated that “the epidermis of birds possesses a much greater variety of appendages than that of any other vertebrate group” [3]. Birds possess several hard skin appendages (feathers, scales, claws, and beak) composed mainly of alpha-keratins (as in all vertebrates), but also of corneous beta-proteins (also referred in the past as beta-keratins) unique to birds and reptiles [10–12]. Corneocytes from hard skin appendages are characterized by a heavily cross-linked cytoskeleton, a rigid and chemically resistant envelope, and very tight cell-to-cell connections that impede cells desquamation [3, 5]. Feathers are the most abundant cutaneous appendages, covering the major surface of the body [13]. Each feather arises from a feather follicle (FF), a self-renewing mini-organ invaginated into the skin, through a series of complex

events [14]. Scales are highly keratinized extensions of the cornified layer and ensure both physical protection and water loss prevention [15]. Three types of scales exist in chicken: (i) reticulate scales from footpads (ii) scutate scales from the dorsal part of the toe, and (iii) scutella scales that are smaller and positioned lateral to scutate scales [15, 16] (Figure 2). Differences occur between avian species: land birds (e.g. chicken, turkey) have hard cornified feet skin scales (podotheca), while water birds (e.g. duck) have softer ones [17, 18]. Beak and claw structures consist of a hard cornified epidermis (forming a sheath) that cover the bones of the jaw and feet, respectively [11, 19].

Several integumentary outgrowths also named soft skin appendages are present on the head and upper neck of chicken [3, 17] including the maxillary rictus, the comb, the earlobes, and the wattles, all localized in the glabrous region [2] (Figure 2). Such structures are composed of soft epidermis [11, 20]. Eyelids are also considered as soft skin appendages. They ensure cornea protection and are constituted by an upper and a lower lid made of a loose fold of skin (unfeathered or with delicate feathers, depending on the bird species) covering eyes globes [21].

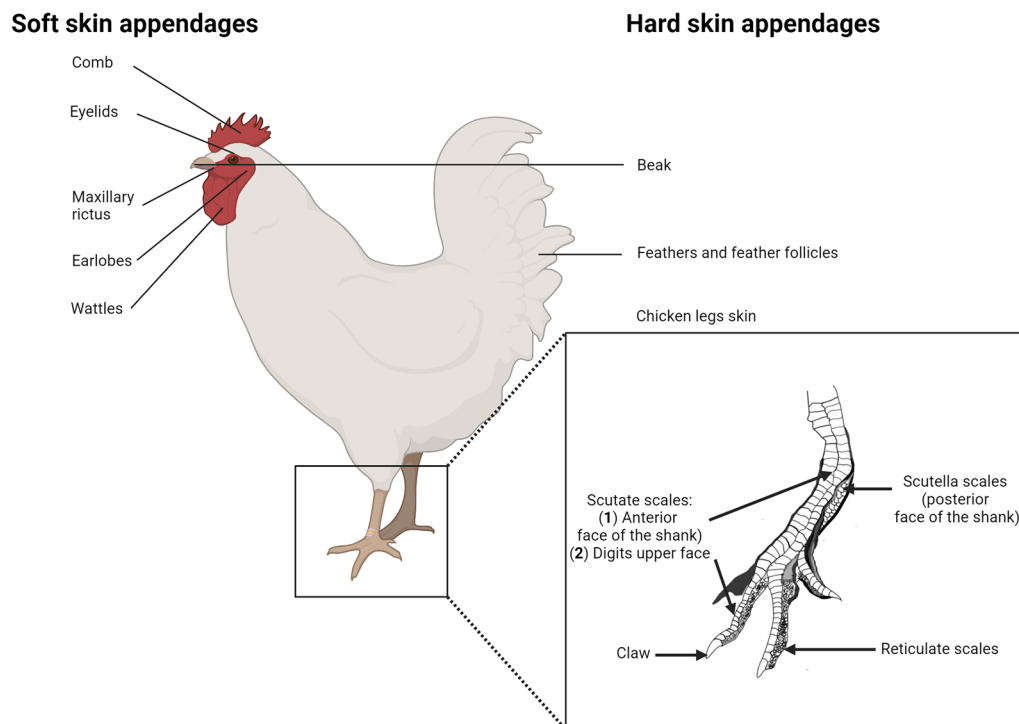


Figure 2 Hard and soft skin appendages in birds/chicken. On the left panel, soft skin appendages including comb, eyelids, maxillary rictus, earlobes and wattles are shown. On the right panel, hard skin appendages including beak, feathers, feather follicles and chicken legs skin are shown with a special focus onto legs scales. Legs possess different hard cornified elements: claw, scutate scales (large and distally overlapping scales) onto digits and anterior face of the shank, scutella scales (smaller and proximally overlapping scales) on the posterior face of the shank and finally reticulate scales (smaller) that recover the remainder of foot surface and are non-overlapping. This figure was illustrated by using BioRender.com (Agreement number: GC26L9TWNH) and Inkscape software.

A third eyelid, the nictitating membrane, is a protective fold of skin [17].

1.3 Immune component of the skin

The immune component of the skin and appendages of birds was poorly studied yet, including in chicken. It is likely that dendritic cells (Langerhans cells and dermal dendritic cells), macrophages, and T lymphocytes are present, as shown in healthy human and mouse skin (for review see [22, 23]). In chicken skin, the Langerhans cell is the best characterized immune cell. Langerhans cells are present in chicken epidermis of featherless skin, and its number has been estimated at 2000 per mm² in an 8-week-old chick [24–26]. In contrast to mammals, the presence of intraepithelial lymphocytes was not demonstrated yet. In addition, a role for avian keratinocytes in the immune response is probable, as shown in mammals for example by sensing virus components [22], but this has never been reported for birds. Concerning chicken skin appendages, some immune cell populations were quantified from the pulp of growing feathers and wattles by flow cytometry and immunohistochemistry [27]. In feather pulp *sensu stricto*, Erf et al. estimated by immunohistochemistry less than 1% CD4-positive cells, less than 2% CD8-positive cells and about 7% MHCII-positive cells. Using transgenic 8 day-old-chicks (“MacRed” chickens) in which monocytes and tissue macrophages expressed a red fluorescent reporter protein, Balic et al. reported numerous macrophagic cells in feather pulp [26].

2 Viruses infecting avian skin and/or skin appendages

This section will focus on viruses infecting farm birds of primary importance: chicken, duck, turkey, and goose. A few pet or wild bird viruses will be also mentioned when important. A large number of avian viruses show a tropism for the skin and its related appendages. These viruses belong to families well known for their tropism for the skin in mammals (e.g. *Poxviridae*, *Herpesviridae*, and *Papillomaviridae*), to families containing arboviruses (arthropod-borne disease) entering the host through arthropod bites (e.g. *Flaviviruses*), and to families that do not usually replicate in the skin of mammals (e.g. *Retroviridae*, *Influenza viruses*) (Table 1). In the sections below, viruses will be referred to by their common name, but the taxonomic name will also be mentioned. All virus infections reviewed in this chapter are more extensively covered in Swayne’s *Disease of Poultry* book [28].

2.1 Poxviruses

Poxviruses infecting birds belong to the *Avipoxvirus* genus in the *Poxviridae* family and cause fowlpox disease, a common disease with economic consequences

in poultry (reviewed in [29–31]). They are large double-stranded DNA viruses, with an unconventional envelope. In farms, avipoxviruses (APV) are more prevalent in tropical and subtropical countries than in northern countries [32]. Three APV species can be involved: fowlpox virus, turkeypox virus, and goosepox virus [33]. All of them have a strong tropism for skin and are known to induce cutaneous lesions. Transmission generally occurs directly by stitching and scratching or most commonly following insect bites. Indirect transmission between birds may also occur by aerosol inhalation or by ingesting infected scabs/dust [31].

The fowlpox virus being the most important APV in poultry, it will be taken as an example in this section. The fowlpox virus infects chicken and turkey [34], causing fowlpox disease, for which two clinical forms are described: a cutaneous form (the most common) and a diphtheritic form. The cutaneous form or “dry fowlpox” is a slow-spreading skin disease with low mortality. It is characterized by hyperplasia of the epidermis (acanthosis), ballooning of keratinocytes, and the formation of large eosinophilic intracytoplasmic inclusions containing virion particles [35]. The nodular or crusty lesions are mainly observed in unfeathered areas of skin, but also in the comb, wattles, and eyelids of chicken [36] and turkey [34]. Hard skin appendages such as beaks, claws, and feet skin may eventually present lesions. Feather lesions are atypical, but occasionally described [37, 38]. The recovery rate for dry fowlpox is high.

The diphtheritic form usually occurs after ingestion or inhalation of the virus and is more severe, with up to 15% of mortality [32]. This form is characterized by lesions located in diverse mucosa (mouth, esophagus, larynx, or trachea) [35, 36]. Vaccines are available for fowlpox prevention. Chicken and turkey are vaccinated with a live attenuated strain of fowlpox or pigeonpox virus [39]. The spread of infection being slow, vaccination within the flock can be performed during the early phases of the outbreak [31].

Until now, permissive culture systems used to replicate APV are mostly primary chicken embryonic fibroblasts (CEFs) [36], DF-1 cell line [32], and embryonated chicken eggs inoculated onto their chorioallantoic membranes [36]. Therefore, cell interaction and cell response to infection have been studied mostly in these systems rather than in cell types naturally infected *in vivo*, such as keratinocytes.

2.2 Herpesviruses

Four avian herpesviruses in the *Herpesviridae* family show a tropism for skin. They all belong to the *Alphaherpesvirus* subfamily, with three from the *Mardivirus* genus (Marek’s disease Virus, Herpesvirus of turkey,

Table 1 Avian viruses with skin-tropism

Virus family	Virus genus	Virus species including common names	Host species	Disease
DNA				
<i>Polyomaviridae</i>	<i>Polyomavirus</i>	Goose hemorrhagic polyomavirus (GHPV)	Goose	Haemorrhagic nephritis enteritis
	<i>Polyomavirus</i>	Avian polyomavirus (APV)/Budgerigar fledgling disease virus (BFDV)	Parrot	Budgerigar fledgling disease also called Avian polyomavirus infection, non budgerigar polyoma infection
<i>Papillomaviridae</i>	<i>Papillomavirus</i>	Fringilla Coelebs papillomavirus 1 (FcPV1), <i>Pygoscelis adeliae</i> Papillomavirus 1, PaPV-1, psittacus erithacus, papillomavirus 1 (PePV-1) ...	Parrot, wild birds	Cutaneous lesions, tumors
<i>Parvoviridae</i>	<i>Dependoparvovirus</i>	Anseriform dependoparvovirus 1	Muscovy duck, mule, Peking duck and goose	Derzsy's disease
	<i>Parvovirus</i>	Goose Parvovirus (GPV)	Goose, duck (muscovy)	Derzsy's disease
<i>Poxviridae</i>	<i>Avipoxvirus</i>	Fowlpox (FPV)	Chicken	Dry pox or wet pox
		Turkeypox virus (TPV)	Turkey	
		Goosepox (HGP)	Goose	
<i>Herpesviridae</i>	<i>Mardivirus</i>	Gallid herpesvirus type 2 (GaHV2)/Marek disease virus (MDV)	Chicken	Marek Disease (MD)
		Mealagrid herpesvirus (MeHV1)/Turkey herpesvirus (HVT)	Chicken, turkey	Not pathogenic
		Gallid herpesvirus type 3 (GaHV3)	Chicken	Not pathogenic
	<i>Iltovirus</i>	Gallid herpesvirus type 1 (GaHV1)/Infectious laryngotracheitis virus (ILT1)	Chicken	Infectious laryngotracheitis
<i>Circoviridae and Anelloviridae</i>	<i>Circovirus</i>	Goose circovirus (GoCV)	Goose	Immunosuppression, feathers disorders
		Duck circovirus (DuCV)	Duck	Immunosuppression, feathers disorders
		Psittacine beak and feather disease virus (BFDV)	Parrot, Psittacine birds	Psittacine Beak and Feather Disease
		<i>Gyrovirus</i>	Chicken anemia virus (CAV)	Chicken
RNA				
<i>Retroviridae</i>	<i>Alpharetrovirus</i>	Avian leukosis virus (ALV)	chicken	Immunosuppression, leukaemia-like proliferative diseases
	<i>Gammaretrovirus</i>	Reticuloendotheliosis virus (REV)	chicken, turkey, duck, goose and quail	Immunosuppression, cell lymphomas, feathers disorders, "Nakanuke" disease
<i>Orthomyxoviridae</i>	<i>Alphainfluenzavirus</i>	Avian Influenza type A virus Highly pathogenic viruses (HPAIV) (H5N8, H5N1...) Low pathogenic viruses (LPAIV) (of all H and N subtypes)	Duck (domestic, waterfowl), goose, chicken, turkey	Avian Flu
<i>Flaviviridae</i>	<i>Flavivirus</i>	West Nile Virus (WNV)	Birds	Encephalitis and other neurological disorders
		Usutu virus (USUV)	Birds	Severe neurological disorders
		Duck Tembusu virus (DTMUV)	Duck	Egg drop syndrome, neurological disorders

Gallid herpesvirus type 3) and one from the *Iltovirus* genus (Infectious laryngo-tracheitis virus). Herpesviruses are large enveloped viruses, with a linear double-stranded DNA genome.

2.2.1 Marek's disease virus

Marek's disease virus (MDV or Gallid herpesvirus type 2, GaHV2), the prototype of the *Mardivirus* genus, is mostly known for inducing lethal T-cell lymphoma

in chicken. This virus was disastrous before vaccines availability in the 1970s. Today, this virus is still found worldwide and economically important for the poultry industry. The infection occurs by inhalation of contaminated dander present in poultry dust. In the first week of infection, the virus infects lymphocytes and the feather follicle epithelium (FFE) [40–43]. Whereas T-lymphocyte infection leads mostly to a latent cycle, FFE infection leads to a lytic cycle and virion production. In 2022, by imaging the whole body of experimentally-infected chickens, we discovered that MDV also infects the skin of the legs covered with scales, the beak, and the base of the claws [43]. Therefore, MDV is capable of infecting and replicating in all hard skin appendages of the chicken but not in soft skin appendages. Infection was detected in small areas of each skin appendage. In the epidermis, MDV replication was limited to the intermediate layer and never observed in the basal layer [43–45]. By electron microscopy, mature virion particles were observed in quantity only in the cytoplasm of keratinocytes from the FFE [46], whereas very few mature particles were present in other cell types *in vivo* (reviewed in [47, 48]).

MDV replicates persistently in the FFE of non-vaccinated chicks until death [49], but also in the FFE of vaccinated chicks [50]. Therefore, viral replication in the FFE appears not to be controlled by the immune response. Feathers debris (especially of the feather outer sheath) and dander contained in farm dust are considered as the major source of MDV [51, 52] and horizontal transmission between individual chickens [42]. Surprisingly, farm dust remains infectious for months into the environment [53, 54], which is unusual for a herpesvirus. This suggests that the mature enveloped virions are not “free” but are physically protected from degradation by a material that remains to be identified. In addition of being the site of virus shedding the skin can also be the site of small tumors, often diagnosed due to swollen FF with lymphoid aggregates [42].

Until now, MDV is cultivated mostly in primary chicken or duck embryo fibroblasts. There is currently no cell culture system that enables the production of mature virions as seen in FFE *in vivo* [47, 55]. Even if chicken keratinocytes derived from embryonic stem cells developed in our laboratory [56] or chicken skin explants prepared from unfeathered skin of 18–20-day-old embryos [57] have been able to sustain MDV infection, they did not produce mature virions efficiently. It remains unknown why complete particles maturation is restricted to differentiated keratinocytes of the FFE.

2.2.2 *Herpesvirus of turkey and Gallid Herpesvirus type 3*

The herpesvirus of turkey (HVT or Meagrid herpesvirus type 1, MeHV1), naturally infects turkeys [58]. As

HVT is not pathogenic for the chicken and highly related antigenically to MDV, this virus was initially used to vaccinate chickens against Marek’s disease [59, 60]. Since the 2000s, this virus is widely used as a vaccine for numerous poultry pathogens (reviewed in [61]). After inoculation to chicks, HVT reaches the FFE [62] and persists for months (and up to the chicken lifetime) in this tissue [63]. Although HVT genome is present in dander [64], HVT spreads very poorly between chickens [65].

Like HVT, the Gallid herpesvirus type 3 (GaHV3) is non-pathogenic for the chicken and used to vaccinate against Marek’s disease [60]. GaHV3 also replicates into the FFE [62] and is shed in dander [64]. In contrast to HVT, GaHV3 efficiently spreads between chickens and is probably circulating “silently” among farms. Indeed, we reported the presence of GaHV3 genome on the skin surface of healthy chickens, sampled from a French experimental farm [66], in which GaHV3 vaccine had never been used. The presence of this virus was also suspected in UK flocks, after detection of GaHV3 sequence by qPCR from feather tip material (S. Baigent, personal communication).

HVT and GaHV3 are cultivated on the same cell systems than MDV. Infection of HVT was also reported on chicken skin explants prepared from unfeathered skin of 18- to 20-day-old embryos, although no mature virions were observed by electron microscopy [57].

2.2.3 *Infectious laryngo-tracheitis virus*

The infectious laryngo-tracheitis virus (ILT or Gallid herpesvirus type 1, GaHV1) causes a respiratory disease in chicken, with various degrees of severity. ILTV replicates predominantly in the epithelial cells of the trachea and conjunctiva of infected chickens, inducing lesions of the mucosa [28]. Clinical symptoms include a dry or crusty ocular discharge around the eyes and the eyelids. Although ILTV does not display a true skin tropism, the ILTV genome was detected in feather material from infected or vaccinated chickens [67, 68]. Even if the ILTV genome can be found in feathers and dust [68, 69], it is unclear if these materials may be source of ILTV transmission.

2.3 *Circoviruses and gyroviruses*

Circoviruses and Gyroviruses are small icosahedral non-enveloped, circular single-stranded DNA viruses that belong to the family of *Circoviridae* and of *Anelloviridae*, respectively. Circovirus DNA is ambisense, whereas Gyrovirus DNA is negative sense [28]. More than 60 bird species can be infected by such viruses, with immunosuppression as a consequence in most cases. Clinical symptoms related to skin appendages are described below.

2.3.1 *Goose circovirus*

The goose circovirus (GoCV) has been described in farm and wild geese in Europe and Asia [70]. GoCV infection causes immunosuppression with nonspecific clinical symptoms and promotes secondary infection by other pathogens (e.g., goose parvovirus). GoCV can also cause feather disorders, with atrophy or insufficient development of feather follicles [71]. A study conducted with goslings from about 40 Taiwanese farms, showed that infected animals had feather loss at 21–35 days of age and/or broken feathers at 42–60 days of age [72]. In GoCV-positive geese, FFs presented necrosis with inclusion bodies [72].

2.3.2 *Duck circovirus*

Similar to GoCV, the duck circovirus (DuCV) causes immunosuppression and favors secondary infection [73, 74]. All ducks infected with DuCV exhibit feathering disorder, feather loss, and growth retardation [73, 75, 76]. Feather dystrophy with haemorrhagic shafts was observed along the dorsum of ducks [77]. DuCV was detected in farm ducks (Muscovy, Pekin or mule ducks) but also in wild ducks [75, 78]. These data come mainly from naturally occurring or experimental bird infections, given that no cell culture system is currently available for propagation of DuCV [76]. Synergistic effects between DuCV and other viruses are observed: for example, coinfection by DuCV and Goose parvovirus potentiates replication and pathogenicity [79].

2.3.3 *Psittacine beak and feather disease virus*

Although not affecting farm birds, the Psittacine beak and feather disease virus (PBFDV) nicely illustrates the tropism of this virus family for the skin and its appendages. This virus, discovered in 1984, affects most (if not all) Psittaciformes, endangering some species [80]. In its chronic form, the psittacine beak and feather disease is characterized by feather loss and deformed beak and claws [80]. These lesions are caused by epidermal hyperplasia, necrosis of epidermal cells, and hyperkeratosis with an excessive amount of scales. Normal feathers are progressively replaced by dystrophic ones after their molting [81, 82]. Intracytoplasmic inclusion bodies can be observed in feather epithelial cells and macrophages [81]. The virus can be transmitted horizontally from bird to bird through feces, contaminated feather dust, and crop secretions [83], but also vertically from mother to embryos. It appears to persist in the environment, allowing indirect transmission.

2.3.4 *The chicken anemia virus*

The chicken anemia virus (CAV), first isolated from chicken in 1979 in Japan is the agent responsible for

the chicken infectious anemia disease, an economically important immunosuppressive poultry disease [84]. CAV is the unique member recognized among *gyrovirus*, a genus that has been reclassified from *Circoviridae* to the new *Anelloviridae* family [85]. Briefly, CAV causes aplastic anemia, immunosuppression, reduced growth, and lymphoid tissue atrophy in young chicken [86]. In chickens older than 3–4 weeks, CAV causes mild sub-clinical infection due to the transient immunosuppression that can result in secondary infections. In the skin, only occasional/marginal symptoms can be observed such as (i) subcutaneous haemorrhages localised to the wings that may turn blue and break (Blue-wing disease) (mainly in co-infection context) [87], and (ii) skin lesions subsequent to secondary bacterial infection. Feathers constitute one potential source of infection [88]. CAV can be transmitted vertically and horizontally mainly by the faecal-oral route, but sometimes through infected FFE. When newly hatched chickens were experimentally inoculated at oral or ocular mucosal surfaces with CAV extracted from feathers, the virus was detected 7–14 days post-infection [86, 88]. In the same study, infectious CAV was found in the feathers' shaft, surface, and pulp and was shed from feathers [88].

2.4 *Retroviruses*

In the *Retroviridae* family, in the *Orthoretrovirinae* sub-family, two avian virus groups have been shown to interact with the skin and feathers: the avian leukosis virus (ALV) from the *Alpharetrovirus* genus (reviewed in [89]) and the reticuloendotheliosis virus (REV) from the *Gammaretrovirus* genus (reviewed in [90]). Retroviruses are enveloped RNA viruses encoding a reverse transcriptase, which generates a DNA provirus that integrates into the host genome.

2.4.1 *Avian leukosis virus*

Avian leukosis viruses (ALV) are often classified in subgroups (currently 11) based on their envelope glycoprotein (e.g. subgroups A, B, C, D, J, and E). The E subgroup contains only endogenous viruses, whereas the subgroups A, B, C, D and J contain exogenous viruses. Natural infection with exogenous ALV occurs in chickens. The virus is shed by the hen into the albumen, contributing to vertical transmission. This mode of transmission is exclusive, except for ALV-J, which is also transmissible horizontally. For all ALV, the progeny of an infected hen is tolerant to the virus and lacks neutralizing antibodies. This tolerance leads to viral persistence and tumorigenesis, resulting in either lymphoid leukosis or myelocytomatosis [89].

ALV can be isolated from many samples of infected chickens [89], including the feather pulp by group specific

antigen testing and visualized by transmission electron microscopy (TEM) [91]. In TEM, retroviral particles are visible in the intercellular space of the epidermis of the FF, but also budding from epidermal cell membranes [92].

For ALV-J, retroviral particles have been observed by TEM in various regions of the feather epithelium (epidermal collar, intermediate layer of the feather epidermis), in accordance with the detection of the p27 viral antigen by immunochemistry [93]. The virus has been detected in the feather pulp of infected chickens, usually at higher titers than in plasma or cloacal swabs [94], making the feather a sample of choice for diagnostic. For this reason, the feather pulp is preferentially used to detect ALV-J, notably by PCR [94–96]. Therefore, it has been suspected (but not yet proven) that feathers could be the source of ALV-J in horizontal transmission. Broilers (young chickens) infected in ovo by ALV-J show feather abnormalities in remiges [93] (thinness, increase transparency of the calamus, sparseness of the vane), indicating that virus replication alters feather development.

Endogenous ALV (ev) infection has been detected in feather pulp cells through group-specific antigen detection [97]. Interestingly, in White Leghorn chicken, a dominant sex-linked late-feathering allele (K) was characterized by a slow growth of wings and tail feathers. This mutation was found associated to the integration of ev21 (an ALV-E), suggesting a relationship between ev21 and feather development [98].

2.4.2 *Reticuloendotheliosis virus*

REV natural infection occurs in chickens, turkeys, ducks, geese, and quails. REV is transmitted horizontally by contact or possibly by blood-sucking insect bites, and vertically in chickens and turkeys. Infections with replicative strains induce three types of pathology, which are relatively rare in flocks [90]: runting syndrome, immunosuppression, and cell lymphomas. The runting syndrome may be associated with abnormal development of the feathers [90], named Nakanuke disease, which consists of feathers with barbs adhering to a small portion of the shaft [99, 100], as well as feathers with increased transparency and thinness of the calamus and rachis and loss of proximal barbs [101]. These feather abnormalities were initially reported after injection of one-day-old chicks with a REV isolated as contaminant of HVT-infected cells [99]. They were observed in various contour feathers, but mostly in the flight feathers of the wings [101]. These lesions appear to be due to REV-induced necrosis of feather-forming epithelial cells of the developing barb ridges [101]. Viral particles can be observed by TEM in feathers and occasionally in FFs. In feathers, virions are restricted to the epidermal collar, ramogenic zone,

and barb ridges, especially in cells of the intermediate layer [101]. Virions are mostly present in interepithelial spaces. No particles were detected in the dermal papilla and the feather pulp [101]. This indicates that REV has a tropism for and a high replication rate in the epithelial cells of the feathers. REV attenuated for its oncogenic properties by passage on cells retains its ability to induce feather abnormalities [102]. Feather abnormalities were also observed when REV was accidentally transmitted to chicks through contaminated vaccines (HVT or fowlpox virus) [100, 103]. Of note, REV sequences were also found inserted in field isolates of fowlpox virus [104], suggesting that the two viruses can co-infect the same cell type, possibly keratinocytes. Experimentally, REV can be transmitted by close contact with infected birds, but not when chickens are separated by wire mesh [90]. This indicates that REV is rapidly inactivated in the environment.

2.5 *Influenza viruses type A*

Avian influenza type A virus (AIV) are members of the *Orthomyxoviridae* family. They are enveloped viruses, with a segmented negative-sense single-strand RNA genome. The virus classification relies on the two major glycoproteins, the hemagglutinin (H) and the neuraminidase (N) (for example H5N1 or H7N7). AIV are naturally widespread in wild aquatic birds, which are considered as the major reservoir [105], and can naturally infect most farm birds [106]. AIV infections are either asymptomatic in poultry, or can cause avian influenza, a systemic and highly lethal disease. The symptom severity of the disease depends on various parameters such as the virus pathotype, the host (bird species, age, host immunity), co-infection occurrence with other pathogens, and environmental factors (reviewed in [107]).

Highly pathogenic avian influenza viruses (HPAIV) (only of H5 and H7 subtypes) induce severe disease with high mortality and morbidity in chickens and other Galliformes, but variable clinical signs and mortality in ducks [108]. HPAIV can cause outbreaks with considerable economic losses, due either to virus morbidity and mortality in infected flocks, high transmissibility, or strict measures taken to limit virus spread in a geographical area (reviewed in [107]). HPAI viruses spread systemically, when most low pathogenic avian influenza (LPAI) viruses remain confined to mucosa. If most LPAIV (of all H and N subtypes) induce no or mild clinical symptoms, mostly respiratory, some can induce severe respiratory signs. In addition, LPAIV with H5 or H7 represent a real threat for poultry as they may mutate into HPAIV.

In Galliformes, in acute cases induced by HPAIV, hemorrhages can be observed in many tissues, especially in unfeathered skin and soft appendages [109].

In 2007, for the first time, Yamamoto et al. reported necrotic lesions of the feather epithelium in domestic call ducks experimentally infected by intravenous inoculation with an H5N1 HPAIV strain [110]. In 2-week-old ducks, lesions were observed 3 to 7 days post-infection (dpi), especially in growing feathers, and were distributed from the epidermal collar to the pulp cap of the feather [110]. Focal necrosis was also observed in the epithelium of the beak and of the scaled skin of the legs, suggesting a tropism for most hard skin appendages [110]. Abundant expression of viral antigens was detected in necrotic lesions [110] and infectious virus was isolated from 1 to 7 dpi in skin harboring numerous small feathers, with titers above 10^3 (determined by the 50% egg infectious dose/g) [110]. Virions were observed in the feather epithelium of infected ducks by TEM [111].

The presence of H5N1 HPAIV in feathers was also reported from naturally infected ducks (Pekin and Muscovy) initially by reverse transcription quantitative PCR, in Vietnamese farms [112]. Abundant antigens were detected by immunochemistry in nearly all feathers of ducks infected by a Vietnamese H5N1 HPAIV, and in all skin tracts [113]. Viral antigens were located in the epidermis of feathers and follicles, with higher amount in feathers [113]. The proportion of feathers positive for viral antigens was lower in the feathers of ducks infected with two other H5N1 of Indonesian clades, suggesting different degree in feathers tropism and/or replication among H5N1 HPAIV. Importantly, H5N1 was detected and isolated from duck feathers with and without clinical signs [111].

Experimentally, nasal inoculation of call ducks with H5N1 confirmed that a natural infection route leads to feather infection [114]. In addition, oral inoculation of call ducks with feathers from a H5N1 infected duck leads to infection, indicating that feathers contain infectious material and are a possible source of horizontal transmission between birds and possibly mammals [114].

The feather tropism is a property shared by HPAIV, H5N1, but also H7N1 [115] and H5N8 [116]. Indeed, viral RNA was detected in growing feathers of naturally infected ducks during the recent outbreaks of clade 2.3.4.4b H5N8 and H5N1 in France. Moreover, in domestic ducks experimentally infected with H5N8, Gaide et al. showed (by examining viral antigen location in growing feathers by immunochemistry at 3 and 5 dpi) that the virus diffuses into the feather from the dermal pulp and the marginal plate of the epithelium to barbs and barbules [117]. This suggests that the virus follows the path of keratinocyte growth and differentiation. By micro-dissecting the infected growing primary feathers, the authors found a moderate viral infectivity in all parts of the feather, but statistically greater infectivity in newly

formed barbs/barbules (around 10^5 – 10^6 focus forming unit/mL) compared to the outer sheath (10^2 – 10^3 plaques forming unit/mL) and dermal pulp [117].

The presence of LPAIV in feathers was not reported. This is not surprising because these viruses usually remain in the respiratory and digestive mucosa and do not lead to a systemic infection. For the few LPAIV shown to spread hematogenous, it would be interesting to search for the presence of the virus in feathers. The replication of HPAIV in the feather epithelium is not restricted to ducks and was also reported after natural or experimental infections in other farm birds: chicken [112, 115, 117–119], goose [111, 116], turkey [117], and quail [117]. In chickens infected with H5N1 HPAIV, lesions and viral antigens are mostly found in the dermis of feathers and follicles, in contrast to ducks where they are mostly detected in the feather epithelium [113]. A tropism for the dermis was also observed in H5N8-infected chickens [117]. Therefore, depending on the bird species, the same virus shows a preferential tropism for the dermis or epidermis.

AIV infectivity in feathers persists for a long time. In feathers detached from infected domestic ducks, H5N1 infectivity lasts for 15 days at 20 °C and 160 days at 4 °C [120], and can persist up to 240 days in chicken feathers at 4 °C. Preen oil secreted by the uropygial gland plays a role in H5N1 stability on duck feathers [121].

Due to the persistence of AIV infectivity in feathers and to the higher amount of virus in feather samples than in oropharyngeal and cloacal swab samples at almost all time points post-infection, feathers could be used as reference samples for AIV surveillance and diagnosis [112, 115, 116, 118, 122, 123].

Finally, the presence of AIV in feathers raises the crucial question of the presence of infectious HPAIV in dust and fomites, and the possibility of HPAIV spread through airborne particles on relatively long distances. Recently, histological analysis of dust collected from HPAIV-positive farms revealed a co-staining for viral antigen with a corneous- β -protein, a feather marker [117] indicating that feather dust contains viral material. Recently, James et al. reported the presence of infectious H5N1 in dust samples collected outside poultry houses during an epizooty in the UK [124]. These data suggest that poultry dust and possibly feathers may play a role in HPAIV transmission. This is an important question that will need to be addressed in the future.

2.6 Flavivirus

Flaviviruses are enveloped, positive single-stranded RNA viruses. Here, we will focus on three arboviruses from the *Flavivirus* genus in the *Flaviviridae* family, for which birds plays an important role in the virus life cycle:

West Nile virus (WNV), Usutu virus (USUV), and Tembusu virus (TMUV). For other avian flaviviruses, refer to Davidson's review [125].

2.6.1 West Nile virus

WNV is a zoonotic arbovirus, nowadays spread on every continent (except Antarctica). The WNV is mostly transmitted by *Culex* mosquitoes as they take a blood meal. Birds are the principal vertebrate hosts of this virus [126], although WNV infection and disease occur occasionally in humans and mammals (principally horses). WNV was detected in more than 300 bird species [127], with different susceptibility to infection and disease [128]. Passeriformes (incl. *Corvus* genus) and Charadriiformes are the most susceptible birds, developing the most severe (possibly fatal) disease. Interestingly, in Corvidae, WNV was detected in the feather pulp of 77% of the dead birds, almost twice more than in spleen and kidney [129]. In house sparrows, WNV was found to persist at least a month in the skin [130]. Due to their high viremia, these birds play a major role of reservoir by amplifying the virus and being a source of infection for competent mosquitoes [127, 128].

Among farm birds, domestic geese are the most susceptible, showing the highest viremia and possibly developing disease with severe neurological signs [131–135]. High mortality rate (25–40%) was reported in natural infections of goslings in Israel and Canada [133, 136]. Infection of geese by subcutaneous inoculation revealed that among the eight organs tested, the feather pulp was the most positive for WNV genome at 3 dpi [135], indicating that this tissue could be an interesting tissue to sample for diagnostic in birds. WNV RNA was also detected from waterfowl ducks' samples (organs and swabs) that died in a US commercial farm during an outbreak [137]. In contrast, in experimentally infected ducks, low viremia was observed, with no shedding or symptoms [128, 134]. Such difference may be due to the duck species infected but also to breeding conditions. Although infectable, chickens and turkeys are less susceptible than geese and ducks [134, 138]. Experimentally infected chickens show low and transient viremia (below 10^4 pfu/mL for 1 to 3 days during the first week of infection) and no symptoms except seroconversion [134, 139]. In consequence, farm birds are not considered as a reservoir/amplifier, their viremia being insufficient to infect mosquitoes, but can serve as sentinels to detect the presence of WNV in mosquitoes through their antibody response [134, 139]. They were often used as such in various geographic areas (for e.g. [140, 141]).

Experimental infections of farm birds are usually performed by subcutaneous needle inoculation or mosquito bite (for examples see [128, 134, 139, 142]). In

chickens, viremia is higher after a mosquito bite than needle inoculation [142]. An experimental infection of four chicks showed that *Culex* mosquitoes inject WNV predominantly extravascularly at the site of feeding (the toe) and little directly into the blood [143]. Phipps reported the presence of viral RNA in skin tissues harvested from chickens inoculated subcutaneously, but not intravenously. Moreover, viral RNA was still detectable in the skin at 3 dpi [144]. Although not investigated yet, it is probable that WNV infects and replicates in skin cells of birds, like it has been demonstrated for mammals. Indeed, WNV was shown to infect keratinocytes at 5 dpi after subcutaneous inoculation in the rear footpads of mice [145]. In human skin explants, WNV infects keratinocytes and dendritic cells, principally in the dermis, but not Langerhans cells [146]. Several questions remain unsolved regarding the difference in birds' susceptibility, notably the role of the skin in amplifying the virus and of the innate immune response to control the virus at the early stages of infection.

2.6.2 Usutu virus

Initially restricted to Africa, USUV emerged in Europe in 1996, and rapidly spread across the continent (reviewed in [147]). *Culex* mosquitoes are responsible for transmission, similarly to WNV (reviewed in [147]). USUV is highly related to WNV with 76% amino acid identity, complicating serological distinction between the two viruses [126]. USUV infection was recorded in more than 50 bird species of 13 orders, and does not usually induce mortality (reviewed in [148]). However, high mortality was recorded in a few wild bird species, predominantly in Eurasian blackbirds of Passeriformes and also grey owls of Strigiformes [149]. USUV is a zoonotic virus and considered as an emerging threat for humans in Europe [126].

Farm birds are infectable by USUV, but poorly susceptible. Like for WNV, chickens are used as sentinels (e.g., in Italy [150] and in the UK [140]). The low susceptibility of chicken was demonstrated by IV inoculation of USUV in 2-week-old chickens. USUV genome was detected in blood during the first week of infection in all 6 chickens but no clinical signs were observed. More recently, the susceptibility of chickens to four strains of African or European origin was compared after subcutaneous injection of 2-day-old chicks [151]. Microscopic inflammatory lesions were observed in the heart at 5 dpi. Morbidity as well as virus titration from blood, oral swabs, and five organs showed that a chicken line developing low antibody titers is more susceptible than one developing high titers [151]. Feather pulp was not tested in that study. However, in another study, USUV RNA was detected in immature feathers of three inoculated

canaries, suggesting that the virus replicates in this tissue [152]. Although not demonstrated, it is probable that USUV infects and is amplified in bird skin, as seen in human and mouse. In human skin explants, USUV infects keratinocytes and Langerhans cells, but not resident dermal dendritic cells [146, 153]. After subcutaneous injection of mice, the viral genome was detected in the skin at the inoculation site, 2 and 5 dpi, but not at distant cutaneous sites [153].

In vitro, USUV replicates in the DF-1 fibroblastic chicken line [151, 154], in a chicken chorioallantoic membrane-derived cell line, and in goose embryonic fibroblasts [155]. Only the last two cell systems show cytopathic effects [152, 156]. Infection of chicken embryonated eggs with high doses of 4 USUV strains of distinct lineages causes embryo death [155]. In that model, USUV is detected in a large number of tissues (including FFs) by immunocytochemistry, although the presence of infected keratinocytes remains unclear [155].

2.6.3 Duck Tembusu

TMUV, identified in 1955, is an emerging flavivirus infecting ducks and chickens (reviewed in [157]). This virus is of economic importance for poultry in Asia, where it induces neurological disease outbreaks. Transmission occurs via *Culex* mosquitoes [157]. Due to its mode of transmission, it is plausible that, like other *Culex*-borne flaviviruses, TMUV infects skin cells, although this is currently unknown.

2.7 Polyomaviridae and Papillomaviridae

In mammals, notably in humans, Polyomaviruses and Papillomaviruses have a well-known tropism for the skin. In birds, ten virus species have been identified as polyomavirus (reviewed in [158]), all non-oncogenic, with only one naturally infecting domestic farm birds: the goose hemorrhagic polyomavirus [159, 160], which does not induce skin disorders. In contrast, the budgerigar fledgling disease virus (BFDV) causes an acute disease in budgies, resulting in high mortality. In chronically infected adult parrots, BFDV causes mostly integument symptoms, with feather loss and feather abnormalities, especially at re-growth [161]. Interestingly, BFDV does not have a strict host specificity as it can infect chicken and duck cultured cells [161, 162]. The Adelie penguin polyomavirus infection also induces feather loss, the only clinical symptoms [163].

In the last ten years, with the power of next-generation sequencing (metagenomic studies), about 20 new avian papillomaviruses were identified in wild birds, among which duck papillomaviruses [164–168]. Avian papillomaviruses, like mammalian viruses, have a cutaneous or mucosa tropism. Indeed, avian papillomaviruses

have been isolated from cutaneous lesions (*Fringilla coelebs* papillomavirus 1 and parrot *Psittacus erithacus* papillomavirus 1), healthy skin (for instance Francolinus leucoscepus papillomavirus 1 [169]), and from cloacal swabs/fecal matter (for instance *Pygoscelis adeliae* Papillomavirus 1) [170]. Different types of cutaneous lesions have been reported with these viruses: (i) squamous (cauliflower) papilloma lesions on the foot and lower leg of chaffinches infected by the *Fringilla coelebs* papillomavirus 1 [171], (ii) verrucous proliferative lesions on the eyelids and around the beak of African grey parrots infected by the *Psittacus erithacus* papillomavirus 1 [172], and (iii) mesenchymal dermal tumor on the foot of Mallard ducks infected by the *Anas platyrhynchos* papillomavirus 2 [168]. In all cutaneous lesions, virions were detected by TEM [168, 171].

To date, no papillomavirus have been found in chicken and no avian papillomavirus infections have been reported in farms. To this end, several years ago, we explored the skin virome of healthy chickens using cutaneous swabs and could not detect any DNA from papillomaviruses or polyomaviruses [66], like in humans [173–175].

2.8 Parvoviruses

Very little is known on avian parvoviruses and skin interactions although integument disorders have been reported for parvovirus infections, such as the “short beak and dwarfism” syndrome reported in different duck species in several countries [176, 177]. The disease is caused by a goose parvovirus variant and the deformity of the beak appears in the first week of age [176, 178, 179]. Goslings infected at late age show feather loss on the back, neck and wings. The lesions observed in ducks and geese suggest infection of beak epithelial and of feather follicles, but this remains to be demonstrated.

3 In vitro avian skin models to study avian virus-skin interactions

Most of the above-mentioned in vitro studies with avian viruses have been performed on monolayer cell culture with non-cutaneous epithelial cells or on chicken embryonic eggs. In particular, several viruses are able to replicate in chicken and duck primary embryo fibroblasts (e.g. fowlpox virus, avian retroviruses, MDV). The advantage of using such cell systems is the ease of preparation and culture. However, some viruses such as MDV present incomplete virion morphogenesis in fibroblasts. In addition, the “behavior” of the cells upon viral infection in vitro varies according to cell types and therefore these models cannot be extrapolated to skin cells. Below we review the skin cell models currently available and briefly discuss how each model could be useful to study the

avian viruses-skin interactions. The host response to viral infection in these models is also discussed. Although current models were developed using chickens, some could be easily translated to other bird species.

3.1 Primary cells keratinocytes

Human primary epidermal keratinocytes have been cultivated efficiently since 1975 following procedures innovated by Rheinwald and Green [180]. It is only 30 years later that the serial cultivation of chicken primary keratinocytes (CPKs) was first reported [9]. Basal CPKs are isolated from the body skin of 1-day-old chicks after down removal, and cultivated onto a supporting mouse fibroblast feeder layer (mitomycin-treated 3T3-J2F) with chicken serum. Although it was initially thought that chicken keratinocytes are dependent on the feeder for growth, a recent study reported that CPKs isolated from leg skin can be cultivated without a feeder layer with keratinocyte growth medium [4].

CPKs display a major advantage, which is the potential of differentiation into corneocytes. However, CPKs present also drawbacks such as: (i) a complex and time-consuming protocol to isolate and cultivate them, (ii) a high donor variability, (iii) a short lifetime and a limited potential of serial passaging. In addition, culturing CPKs requires caution to preserve their stem cell properties in order to maintain their proliferative capacity [9]. As of today, only newly hatched chicks and not embryos are utilized to isolate CPKs, although chicken embryos appear to be an easier source of cells and of better societal acceptability. To our knowledge, no serial cultivation of primary keratinocytes has been reported for duck or turkey.

3.2 Keratinocyte cell lines

Obtaining differentiated cell lines remains a challenge in avian biology. Until quite recently (2015), no keratinocyte cell lines were available for avian species. Such model was developed for the first time in our laboratory by differentiating chicken embryonic stem cells (cES) towards a chicken keratinocyte lineage [181]. The differentiation of cES was achieved following induction with BMP4 and ascorbic acid [181]. Three homogeneous populations of cells were obtained: K-cES-K1, -KP2, and -K8 cells. Having keratinocyte cell lines at our disposal to study avian viruses may prove useful considering the limitations encountered with primary CPKs, notably using animals as a source of cells and related ethical issues. We have shown that these keratinocyte cell lines are permissive to the replication of non-pathogenic and pathogenic MDV and lead to the production of cell-associated viral progeny [181]. Nevertheless, despite the presence of all types of virions in cells, no extracellular mature virions

have been obtained, suggesting the need of even more sophisticated *in vitro* models in such context. In addition, these cell lines are most likely models for chicken integument skin and not for hard skin appendages. Although no keratinocyte cell lines have been developed from ducks yet, this appears feasible from duck embryonic stem cells reported in 2010 [182].

Monolayers of keratinocytes, either CPKs or cell lines, are very useful cell systems to compare the replication of various viral strains or recombinant mutants (such as viruses with knocked-out or overexpressed genes). Keratinocytes will also be particularly helpful to identify viral or molecular determinants involved in viral replication and cell-to-cell spread in an appropriate target cell.

3.3 Skin explants cultivation *in vitro*

Skin explants cultivation *in vitro* was developed in the early 1960s from chicken embryos, mostly by chicken embryologists (see [183–185]). This system involves maintaining the embryonic chicken skin explants at air-liquid interface on a grid, an insert, or a semi-solid agar support [184, 186]. Another method involves grafting embryonic explants on a chorioallantoic membrane [184]. When embryonic chicken skin explants are cultivated, feather buds can develop [184, 187]. One drawback is the limited time (about 5 days) the skin explant structure and integrity can be maintained in culture. Culture of fowlpox virus [183] and replication of HVT or MDV [57] has been studied in embryonic explants, showing the permissivity of keratinocytes to fowlpox virus and MDV. Skin explants have been harvested mostly from embryos, but they can be theoretically harvested from hatched animals. Such a model has the advantage of having all cells, including immune cells. Moreover, cultivation of the epidermis alone may also be considered to study avian viruses with specific tropism for this layer.

In our opinion, this model has been underused in virology and deserves to be revisited with the new molecular tools of virology (e.g., recombinant viruses), basic knowledge in immunology and cell biology, as well as the new advances in imaging.

3.4 Feather follicle cultivation

Inspired from *in vitro* hair follicle's cultivation models [188], we developed in 2022 the first chicken FF *in vitro* model. After dissecting FFs individually, FFs were immersed in appropriate medium. Such system allows viability of the FFs for 7 days, although the development of feathers is partially impaired [189]. No viral infection with such model has been depicted yet, but this model may help decipher the dynamic steps of feather infection, especially from feather pulp with cell-free viruses, such as influenza virus or retroviruses. The infection could be

achieved by injecting the virus directly into the pulp of growing feathers, as Erf and colleagues previously did with antigens *in vivo* [27]. This model presents the advantage to include all the cells naturally present in feathers and FFs, such as melanocytes, macrophages and possibly Langerhans cells.

3.5 Reconstituted skin equivalent

Very recently, the first avian skin equivalent was reconstructed by using a three-dimensional model [4]. It was obtained by seeding CPKs from chicken leg skin onto a fibroblast-populated collagen matrix before lifting it at an air–liquid interface. Similar systems were developed in mammals since the 1980s (reviewed in [185]). In infectious diseases, they were used in particular to study interactions between the human epidermis and several viruses, such as human herpesvirus type 1 [190, 191], Orf virus, a zoonotic epitheliotropic parapoxvirus [192], or Merkel cell polyomavirus [193].

This model could be interesting to study the interplay between chicken epidermis and several viruses, like Marek's disease virus or fowlpox virus. This model is particularly interesting to follow a relationship between virus replication and keratinocyte differentiation. This system may also help to decipher the response of keratinocytes to infection or to evaluate the efficiency of antiviral molecules as described for humans [190], even if it is mainly for the purpose of comparative biology and not of bird treatments.

3.6 Potential of skin models for studying the skin immune response

Skin represents the first line of defense against external threats by mechanical/physical (e.g., cornified keratinocytes from stratum corneum tightly joined), chemical (secretion by the epidermis of acids or lipids hostile to pathogens), or cellular/immune (innate or adaptive immune response) barriers. In mammals, keratinocytes participate in the immune defense against pathogens, including viruses, notably through the early innate immune response promoting cutaneous inflammation [194]. Only a few studies have depicted the innate immune response in avian skin in response to skin viral infection. A better characterization of the expression of toll-like receptors and/or mediators of signaling pathways (nucleic acid sensors) in avian skin will help understand the role of skin in viral entry or exit. In addition, as previously mentioned, keratinocytes are naturally rich in lipid droplets. Because lipid droplets were recently shown to play a role in early innate immune response to viral infection in mammalian cells [195], studying the role of these cellular elements in avian keratinocytes in response to viral infection would be of particular interest.

All *in vitro* or *ex vivo* systems presented above provide a great opportunity to better understand the interplay between skin, viruses, and the immune response.

4 Conclusion

The skin and skin appendages, in particular feathers, are a gateway or an excretion site for numerous avian viruses. It is therefore a strategic site to limit infection as well as transmission and/or environment contamination. In addition, feathers, which are easy to collect, are now considered to be a reliable sample for the diagnostic of several avian viral infections (such as Marek's disease, avian influenza viruses, REV and ALV-). In the past 10 years, four new skin models were developed in the chicken and could be easily adapted to other avian species. These models open opportunities to study avian virus interactions with natural target cells. They also are particularly important to reduce animal experimentation.

Abbreviations

ALV	avian leukosis virus
APV	avipoxviruses
BFDV	budgerigar fledgling disease virus
CAV	chicken anemia virus
cES	chicken embryonic stem cells
dpi	days post-infection
DuCV	duck circovirus
ev	endogenous ALV
FF	feather follicle
FFE	feather follicle epithelium
GaHV3	Gallid herpesvirus type 3
HVT	herpesvirus of turkey
GoCV	goose circovirus
ILT	infectious laryngo-tracheitis virus
MDV	Marek's disease virus
PBFDV	psittacine beak and feather disease virus
REV	reticuloendotheliosis virus
TEM	transmission electron microscopy
TMUV	Tembusu virus
USUV	Usutu virus
WNV	West Nile virus

Authors' contributions

LS and CD wrote the manuscript. Both authors read and approved the final manuscript.

Declarations

Competing interests

The authors declare that they have no competing interests.

Received: 30 January 2024 Accepted: 24 March 2024

Published online: 26 April 2024

References

1. Flores-Santin J, Burggren WW (2021) Beyond the chicken: alternative avian models for developmental physiological research. *Front Physiol* 12:712633. <https://doi.org/10.3389/fphys.2021.712633>

2. Gopinathan KM, Menon J (2000) Avian epidermal lipids: functional considerations and relationship to feathering. *Am Zool* 40:540–552. <https://doi.org/10.1093/icb/40.4.540>
3. Lucas AM, Stettenheim PR (1972) Avian anatomy integument. US Dept. of Agriculture, Washington
4. Lachner J, Ehrlich F, Wielscher M, Farlik M, Hermann M, Tschachler E, Eckhart L (2022) Single-cell transcriptomics defines keratinocyte differentiation in avian scutate scales. *Sci Rep* 12:126. <https://doi.org/10.1038/s41598-021-04082-1>
5. Eckhart L, Lippens S, Tschachler E, Declercq W (2013) Cell death by cornification. *Biochim Biophys Acta* 1833:3471–3480. <https://doi.org/10.1016/j.bbamcr.2013.06.010>
6. Potten CS (1981) Cell replacement in epidermis (keratopoiesis) via discrete units of proliferation. *Int Rev Cytol* 69:271–318. [https://doi.org/10.1016/s0074-7696\(08\)62326-8](https://doi.org/10.1016/s0074-7696(08)62326-8)
7. Mlitz V, Strasser B, Jaeger K, Hermann M, Ghannadan M, Buchberger M, Alibardi L, Tschachler E, Eckhart L (2014) Trichohyalin-like proteins have evolutionarily conserved roles in the morphogenesis of skin appendages. *J Invest Dermatol* 134:2685–2692. <https://doi.org/10.1038/jid.2014.204>
8. Matoltsy AG (1969) Keratinization of the avian epidermis: an ultrastructural study of the newborn chick skin. *J Ultrastruct Res* 29:438–458. [https://doi.org/10.1016/s0022-5320\(69\)90065-3](https://doi.org/10.1016/s0022-5320(69)90065-3)
9. Vanhoutteghem A, Londero T, Djian P, Ghinea N (2004) Serial cultivation of chicken keratinocytes, a composite cell type that accumulates lipids and synthesizes a novel beta-keratin. *Differentiation* 72:123–137. <https://doi.org/10.1111/j.1432-0436.2004.07204002.x>
10. Holthaus K, Lachner J, Ebner B, Tschachler E, Eckhart L (2021) Gene duplications and gene loss in the epidermal differentiation complex during the evolutionary land-to-water transition of cetaceans. *Sci Rep* 11:12334. <https://doi.org/10.1038/s41598-021-91863-3>
11. Alibardi L (2023) General aspects on skin development in vertebrates with emphasis on sauropsids epidermis. *Dev Biol* 501:60–73. <https://doi.org/10.1016/j.ydbio.2023.05.007>
12. Sachslehner AP, Surbek M, Golabi B, Geiselhofer M, Jäger K, Hess C, Kuchler U, Gruber R, Eckhart L (2023) Transglutaminase activity is conserved in stratified epithelia and skin appendages of mammals and birds. *Int J Mol Sci* 24:2193. <https://doi.org/10.3390/ijms24032193>
13. Dhouailly D (2009) A new scenario for the evolutionary origin of hair, feather, and avian scales. *J Anat* 214:587–606. <https://doi.org/10.1111/j.1469-7580.2008.01041.x>
14. Yu M, Yue Z, Wu P, Wu DY, Mayer JA, Medina M, Widelitz RB, Jiang TX, Chuong CM (2004) The biology of feather follicles. *Int J Dev Biol* 48:181–191. <https://doi.org/10.1387/ijdb.031776my>
15. Chuong C, Chodankar R, Widelitz R, Jiang T (2000) Evo-devo of feathers and scales: building complex epithelial appendages. *Curr Opin Genet Dev* 10:449–456. [https://doi.org/10.1016/S0959-437X\(00\)00111-8](https://doi.org/10.1016/S0959-437X(00)00111-8)
16. Wu P, Lai Y-C, Widelitz R, Chuong C-M (2018) Comprehensive molecular and cellular studies suggest avian scutate scales are secondarily derived from feathers, and more distant from reptilian scales. *Sci Rep* 8:16766. <https://doi.org/10.1038/s41598-018-35176-y>
17. Stettenheim PR (2000) The integumentary morphology of modern birds—an overview. *Am Zool* 40:461–477. <https://doi.org/10.1093/icb/40.4.461>
18. Akat E, Yenmiş M, Pombal MA, Molist P, Megias M, Arman S, Veselý M, Anderson R, Ayaz D (2022) Comparison of vertebrate skin structure at class level: a review. *Anat Rec* 305:3543–3608. <https://doi.org/10.1002/ar.24908>
19. Dhouailly D (2023) Evo devo of the vertebrates integument. *J Dev Biol* 11:25. <https://doi.org/10.3390/jdb11020025>
20. Alibardi L (2016) Sauropsids cornification is based on corneous beta-proteins, a special type of keratin-associated corneous proteins of the epidermis. *J Exp Zool B Mol Dev Evol* 326:338–351. <https://doi.org/10.1002/jez.b.22689>
21. Klećkowska-Nawrot JE, Goździewska-Harłajczuk K, Łupicki D, Marycz K, Nawara T, Barszcz K, Kowalczyk A, Rosenberger J, Łukaszewicz E (2018) The differences in the eyelids microstructure and the conjunctiva-associated lymphoid tissue between selected ornamental and wild birds as a result of adaptation to their habitat. *Acta Zool* 99:367–394. <https://doi.org/10.1111/azo.12223>
22. Nestle FO, Di Meglio P, Qin JZ, Nickoloff BJ (2009) Skin immune sentinels in health and disease. *Nat Rev Immunol* 9:679–691. <https://doi.org/10.1038/nri2622>
23. Nguyen AV, Soulika AM (2019) The dynamics of the skin's immune system. *Int J Mol Sci* 20:1811. <https://doi.org/10.3390/ijms20081811>
24. Perez Torres A, Millan Aldaco DA (1994) Ia antigens are expressed on ATPase-positive dendritic cells in chicken epidermis. *J Anat* 184:591–596
25. Igyarto BZ, Lacko E, Olah I, Magyar A (2006) Characterization of chicken epidermal dendritic cells. *Immunology* 119:278–288. <https://doi.org/10.1111/j.1365-2567.2006.02432.x>
26. Balic A, Garcia-Morales C, Vervelde L, Gilhooly H, Sherman A, Garceau V, Gutowska MW, Burt DW, Kaiser P, Hume DA, Sang HM (2014) Visualisation of chicken macrophages using transgenic reporter genes: insights into the development of the avian macrophage lineage. *Development* 141:3255–3265. <https://doi.org/10.1242/dev.105593>
27. Erf GF, Ramachandran IR (2016) The growing feather as a dermal test site: comparison of leukocyte profiles during the response to *Mycobacterium butyricum* in growing feathers, wattles, and wing webs. *Poult Sci* 95:2011–2022. <https://doi.org/10.3382/ps/pew122>
28. Swayne D (2018) Diseases of Poultry. Wiley-Blackwell, Hoboken. <https://doi.org/10.1002/9781119371199>
29. Bolte AL, Meurer J, Kaleta EF (1999) Avian host spectrum of avipoxviruses. *Avian Pathol* 28:415–432. <https://doi.org/10.1080/03079459994434>
30. Bányai K, Palya V, Dénes B, Glávits R, Ivanics É, Horváth B, Farkas SL, Marton S, Bálint Á, Gyuranecz M, Erdélyi K, Dán Á (2015) Unique genomic organization of a novel Avipoxvirus detected in Turkey (*Meleagris gallopavo*). *Infect Genet Evol* 35:221–229. <https://doi.org/10.1016/j.meegid.2015.08.001>
31. Tripathy DN, Reed WM (2018) Pox. In: Swayne DE, Boulianne M et al. (eds) Diseases of poultry, 14th edn. Hoboken, Wiley-Blackwell, pp 364–381. <https://doi.org/10.1002/9781119371199.ch10>
32. Giotis ES, Skinner MA (2019) Spotlight on avian pathology: fowlpox virus. *Avian Pathol* 48:87–90. <https://doi.org/10.1080/03079457.2018.1554893>
33. Weli SC, Tryland M (2011) Avipoxviruses: infection biology and their use as vaccine vectors. *Virology* 418:49–59. <https://doi.org/10.1016/j.virus.2011.11.011>
34. Hess C, Maegdefrau-Pollan B, Bilic I, Liebhart D, Richter S, Mitsch P, Hess M (2011) Outbreak of cutaneous form of poxvirus on a commercial turkey farm caused by the species fowlpox. *Avian Dis* 55:714–718. <https://doi.org/10.1637/9771-050511-Case.1>
35. Raidal SR (1995) Viral skin diseases of birds. *Semin Avian Exotic Pet Med* 4:72–82. [https://doi.org/10.1016/S1055-937X\(05\)80042-8](https://doi.org/10.1016/S1055-937X(05)80042-8)
36. Gilhare VR, Hirpurkar SD, Kumar A, Naik SK, Sahu T (2015) Pock forming ability of fowl pox virus isolated from layer chicken and its adaptation in chicken embryo fibroblast cell culture. *Vet World* 8:245–250. <https://doi.org/10.14202/vetworld.2015.245-250>
37. Nakamura K, Waseda K, Yamamoto Y, Yamada M, Nakazawa M, Hata E, Terazaki T, Enya A, Imada T, Imai K (2006) Pathology of cutaneous fowlpox with amyloidosis in layer hens inoculated with fowlpox vaccine. *Avian Dis* 50:152–156. <https://doi.org/10.1637/7408-071305R.1>
38. Mirzazadeh A, Matos M, Emadi-Jamali S, Liebhart D, Hess M (2021) Atypical manifestation of cutaneous fowlpox in broiler chickens associated with high condemnation at a processing plant. *Avian Dis* 65:340–345. <https://doi.org/10.1637/aviandiseases-D-21-00025>
39. Kim HR, Jang I, Song HS, Kim SH, Kim HS, Kwon YK (2022) Genetic diversity of fowlpox virus and putative genes involved in its pathogenicity. *Microbiol Spectr* 10:e0141522. <https://doi.org/10.1128/spectrum.01415-22>
40. Calnek BW (2001) Pathogenesis of Marek's disease virus infection. *Curr Top Microbiol Immunol* 255:25–55. https://doi.org/10.1007/978-3-642-56863-3_2
41. Jarosinski KW (2012) Marek's disease virus late protein expression in feather follicle epithelial cells as early as 8 days postinfection. *Avian Dis* 56:725–731. <https://doi.org/10.1637/10252-052212-reg.1>
42. Nair V, Gimeno IM, Dunn JR (2018) Marek's disease. In: Swayne DE, Boulianne M et al. (eds) Diseases of poultry, 14th edn. Wiley-Blackwell, Hoboken, pp 550–586. <https://doi.org/10.1002/9781119371199.ch15>
43. Lantier I, Mallet C, Souci L, Larcher T, Conradie AM, Courvoisier K, Trapp S, Pasdeloup D, Kaufner BB, Denesvre C (2022) In vivo imaging reveals

- novel replication sites of a highly oncogenic avian herpesvirus in chickens. *PLoS Pathog* 18:e1010745. <https://doi.org/10.1371/journal.ppat.1010745>
44. Lapen RF, Piper RC, Kenzy SG (1970) Cutaneous changes associated with Marek's disease of chickens. *J Natl Cancer Inst* 45:941–950. <https://doi.org/10.1093/jnci/45.5.941>
 45. Couteaudier M, Denesvre C (2014) Marek's disease virus and skin interactions. *Vet Res* 45:36. <https://doi.org/10.1186/1297-9716-45-36>
 46. Johnson EA, Burke CN, Fredrickson TN, DiCapua RA (1975) Morphogenesis of Marek's disease virus in feather follicle epithelium. *J Natl Cancer Inst* 55:89–99. <https://doi.org/10.1093/jnci/55.1.89>
 47. Denesvre C (2013) Marek's disease virus morphogenesis. *Avian Dis* 57:340–350. <https://doi.org/10.1637/10375-091612-review.1>
 48. Denesvre C, Rémy S, Fragnet L, Smith LP, Georgeault S, Vautherot J-F, Nair V (2016) Marek's disease virus undergoes complete morphogenesis after reactivation in T-lymphoblastoid cell line transformed by recombinant fluorescent marker virus. *J Gen Virol* 97:480–486. <https://doi.org/10.1099/jgv.0.000354>
 49. Rémy S, Blondeau C, Le Vern Y, Lemesle M, Vautherot J-F, Denesvre C (2013) Fluorescent tagging of VP22 in N-terminus reveals that VP22 favors Marek's disease virus virulence in chickens and allows morphogenesis study in MD tumor cells. *Vet Res* 44:125. <https://doi.org/10.1186/1297-9716-44-125>
 50. Read AF, Baigent SJ, Powers C, Kgosana LB, Blackwell L, Smith LP, Kennedy DA, Walkden-Brown SW, Nair VK (2015) Imperfect vaccination can enhance the transmission of highly virulent pathogens. *PLoS Biol* 13:e1002198. <https://doi.org/10.1371/journal.pbio.1002198>
 51. Beasley JN, Patterson LT, McWade DH (1970) Transmission of Marek's disease by poultry house dust and chicken dander. *Am J Vet Res* 31:339–344
 52. Jurajda V, Klimes B (1970) Presence and survival of Marek's disease agent in dust. *Avian Dis* 14:188–190
 53. Witter RL, Burgoyne GH, Burmester BR (1968) Survival of Marek's disease agent in litter and droppings. *Avian Dis* 12:522–530. <https://doi.org/10.2307/1588168>
 54. Carozza JH, Fredrickson TN, Prince RP, Liginbuhl RE (1973) Role of desquamated epithelial cells in transmission of Marek's disease. *Avian Dis* 17:767–781. <https://doi.org/10.2307/1589045>
 55. Denesvre C, Blondeau C, Lemesle M, Le Vern Y, Vautherot D, Roingear P, Vautherot JF (2007) Morphogenesis of a highly replicative EGF-PVP22 recombinant Marek's disease virus (MDV) in cell culture. *J Virol* 81:12348–12359. <https://doi.org/10.1128/jvi.01177-07>
 56. Couteaudier M, Courvoisier K, Trapp-Fragnet L, Denesvre C, Vautherot J-F (2016) Keratinocytes derived from chicken embryonic stem cells support Marek's disease virus infection: a highly differentiated cell model to study viral replication and morphogenesis. *Virol J* 13:7. <https://doi.org/10.1186/s12985-015-0458-2>
 57. Prasad LB (1979) Replication of turkey herpesvirus and Marek's disease virus in chick embryo skin organ culture. *Res Vet Sci* 27:82–88. [https://doi.org/10.1016/S0034-5288\(18\)32863-7](https://doi.org/10.1016/S0034-5288(18)32863-7)
 58. Witter RL, Solomon JJ (1971) Epidemiology of a herpesvirus of turkeys: possible sources and spread of infection in turkey flocks. *Infect Immun* 4:356–361. <https://doi.org/10.1128/iai.4.4.356-361.1971>
 59. Purchase HG, Okazaki W, Burmester BR (1971) Field trials with the herpes virus of turkeys (HVT) strain FC126 as a vaccine against Marek's disease. *Poult Sci* 50:775–783. <https://doi.org/10.3382/ps.0500775>
 60. Schat KA (2016) History of the first-generation Marek's disease vaccines: the science and little-known facts. *Avian Dis* 60:715–724. <https://doi.org/10.1637/11429-050216-Hist>
 61. Hein R, Koopman R, Garcia M, Armour N, Dunn JR, Barbosa T, Martinez A (2021) Review of poultry recombinant vector vaccines. *Avian Dis* 65:438–452. <https://doi.org/10.1637/0005-2086-65.3.438>
 62. Cortes AL, Montiel ER, Lemiere S, Gimeno IM (2011) Comparison of blood and feather pulp samples for the diagnosis of Marek's disease and for monitoring Marek's disease vaccination by real time-PCR. *Avian Dis* 55:302–310. <https://doi.org/10.1637/9578-101510-resnote.1>
 63. Rémy S, Le Pape G, Gourichon D, Gardin Y, Denesvre C (2020) Chickens can durably clear herpesvirus vaccine infection in feathers while still carrying vaccine-induced antibodies. *Vet Res* 51:24. <https://doi.org/10.1186/s13567-020-00749-1>
 64. Islam A, Walkden-Brown SW (2007) Quantitative profiling of the shedding rate of the three Marek's disease virus (MDV) serotypes reveals that challenge with virulent MDV markedly increases shedding of vaccinal viruses. *J Gen Virol* 88:2121–2128. <https://doi.org/10.1099/vir.0.82969-0>
 65. Cho BR, Kenzy SG (1975) Horizontal transmission of turkey herpesvirus to chickens. 3. Transmission in three different lines of chickens. *Poult Sci* 54:109–115. <https://doi.org/10.3382/ps.0540109>
 66. Denesvre C, Dumarest M, Rémy S, Gourichon D, Eloit M (2015) Chicken skin virome analyzed by high-throughput sequencing shows a composition highly different from human skin. *Virus Genes* 5:209–216. <https://doi.org/10.1007/s11262-015-1231-8>
 67. Davidson I, Raibstein I, Altiori A, Elkin N (2016) Infectious laryngotracheitis virus (ILT) vaccine intake evaluation by detection of virus amplification in feather pulps of vaccinated chickens. *Vaccine* 34:1630–1633. <https://doi.org/10.1016/j.vaccine.2016.01.006>
 68. Davidson I, Nagar S, Raibstein I, Shkoda I, Perk S, Garcia M (2009) Detection of wild- and vaccine-type avian infectious laryngotracheitis virus in clinical samples and feather shafts of commercial chickens. *Avian Dis* 53:618–623. <https://doi.org/10.1637/8668-022709-ResNote.1>
 69. Roy P, Fakhru Islam AFM, Burgess SK, Hunt PW, McNally J, Walkden-Brown SW (2015) Real-time PCR quantification of infectious laryngotracheitis virus in chicken tissues, faeces, isolator-dust and bedding material over 28 days following infection reveals high levels in faeces and dust. *J Gen Virol* 96:3338–3347. <https://doi.org/10.1099/jgv.0.000268>
 70. Stenzel T, Farkas K, Varsani A (2015) Genome sequence of a diverse goose circovirus recovered from greylag goose. *Genome Announc* 3:e00767. <https://doi.org/10.1128/genomeA.00767-15>
 71. Guo J, Tian X, Tan X, Yu H, Ding S, Sun H, Yu X (2011) Pathological observations of an experimental infection of geese with goose circovirus. *Avian Pathol* 40:55–61. <https://doi.org/10.1080/03079457.2010.538371>
 72. Ting C-H, Lin C-Y, Huang Y-C, Liu S-S, Peng S-Y, Wang C-W, Wu H-Y (2021) Correlation between goose circovirus and goose parvovirus with gosling feather loss disease and goose broke feather disease in southern Taiwan. *J Vet Sci* 22:e1. <https://doi.org/10.4142/jvs.2021.22.e1>
 73. Hattermann K, Schmitt C, Soike D, Mankertz A (2003) Cloning and sequencing of Duck circovirus (DuCV). *Arch Virol* 148:2471–2480. <https://doi.org/10.1007/s00705-003-0181-y>
 74. Soike D, Albrecht K, Hattermann K, Schmitt C, Mankertz A (2004) Novel circovirus in mulard ducks with developmental and feathering disorders. *Vet Rec* 154:792–793. <https://doi.org/10.1136/vr.154.25.792>
 75. Zhang Z, Jia R, Lu Y, Wang M, Zhu D, Chen S, Yin Z, Chen X, Cheng A (2013) Identification, genotyping, and molecular evolution analysis of duck circovirus. *Gene* 529:288–295. <https://doi.org/10.1016/j.gene.2013.07.028>
 76. Hong YT, Kang M, Jang HK (2018) Pathogenesis of duck circovirus genotype 1 in experimentally infected Pekin ducks. *Poult Sci* 97:3050–3057. <https://doi.org/10.3382/ps/pey177>
 77. Franco G, Segalés J (2021) Circoviruses (Circoviridae). In: Bamford DH, Zuckerman M (eds) *Encyclopedia of virology*, 4th edn. Academic Press, Oxford, pp 182–192. <https://doi.org/10.1016/B978-0-12-814515-9.00041-2>
 78. Niu X, Liu L, Han C, Li J, Zeng X (2018) First findings of duck circovirus in migrating wild ducks in China. *Vet Microbiol* 216:67–71. <https://doi.org/10.1016/j.vetmic.2018.02.007>
 79. Liu J, Yang X, Hao X, Feng Y, Zhang Y, Cheng Z (2020) Effect of goose parvovirus and duck circovirus coinfection in ducks. *J Vet Res* 64:355–361. <https://doi.org/10.2478/jvetres-2020-0048>
 80. Pass DA, Perry RA (1984) The pathology of psittacine beak and feather disease. *Aust Vet J* 61:69–74. <https://doi.org/10.1111/j.1751-0813.1984.tb15520.x>
 81. Katoh H, Ogawa H, Ohya K, Fukushi H (2010) A review of DNA viral infections in psittacine birds. *J Vet Med Sci* 72:1099–1106. <https://doi.org/10.1292/jvms.10-0022>
 82. Raidal SR, Sarker S, Peters A (2015) Review of psittacine beak and feather disease and its effect on Australian endangered species. *Aust Vet J* 93:466–470. <https://doi.org/10.1111/avj.12388>
 83. Ritchie BW, Niagro FD, Latimer KS, Steffens WL, Pesti D, Ancona J, Lukert PD (1991) Routes and prevalence of shedding of psittacine beak and feather disease virus. *Am J Vet Res* 52:1804–1809
 84. Schat KA (2019) Chicken infectious anaemia virus. In: Samal S.K. (ed) *Avian Virology: Current Research and Future Trends*. Caister Academic

- Press, Virginia-Maryland College of Veterinary Medicine, University of Maryland, USA, pp. 249–282. <https://doi.org/10.21775/9781912530106.09>
85. Rosario K, Breitbart M, Harrach B, Segalés J, Delwart E, Biagini P, Varsani A (2017) Revisiting the taxonomy of the family Circoviridae: establishment of the genus Cyclovirus and removal of the genus Gyrovirus. *Arch Virol* 162:1447–1463. <https://doi.org/10.1007/s00705-017-3247-y>
 86. Schat KA (2009) Chicken anemia virus. *Curr Top Microbiol Immunol* 331:151–183. https://doi.org/10.1007/978-3-540-70972-5_10
 87. Engström BE (1999) Prevalence of antibody to chicken anaemia virus (CAV) in Swedish chicken breeding flocks correlated to outbreaks of blue wing disease (BWD) in their progeny. *Acta Vet Scand* 40:97–107. <https://doi.org/10.1186/bf03547027>
 88. Davidson I, Artzi N, Shkoda I, Lublin A, Loeb E, Schat KA (2008) The contribution of feathers in the spread of chicken anemia virus. *Virus Res* 132:152–159. <https://doi.org/10.1016/j.virusres.2007.11.012>
 89. Nair V (2018) Leukosis sarcoma group. In: Swayne DE, Boulianne M et al. (eds) *Diseases of Poultry*, 14th edn. Wiley-Blackwell, Hoboken, pp 587–625. <https://doi.org/10.1002/9781119371199.ch15>
 90. Zavala G, Nair V (2018) Reticuloendotheliosis. In: Swayne DE, Boulianne M et al. (eds) *Diseases of Poultry*, 14th edn. Wiley-Blackwell, Hoboken, pp 625–637. <https://doi.org/10.1002/9781119371199.ch15>
 91. Spencer JL, Gilka F, Gavora JS (1983) Detection of lymphoid leukosis virus infected chickens by testing for group-specific antigen or virus in feather pulp. *Avian Pathol* 12:85–99. <https://doi.org/10.1080/0307945879458308436151>
 92. Spencer JL, Gavora JS, Gilka F (1987) Feather pulp organ cultures for assessing host resistance to infection with avian leukosis-sarcoma viruses. *Avian Pathol* 16:425–438. <https://doi.org/10.1080/03079458708436393>
 93. Landman WJ, Wilgen JL, Koch G, Dwars RM, Ultee A, Gruys E (2001) Avian leukosis virus subtype J in ovo-infected specific pathogen free broilers harbour the virus in their feathers and show feather abnormalities. *Avian Pathol* 30:675–684. <https://doi.org/10.1080/03079450120092170>
 94. Sung HW, Reddy SM, Fadly AM (2002) High virus titer in feather pulp of chickens infected with subgroup J avian leukosis virus. *Avian Dis* 46:281–286. [https://doi.org/10.1637/0005-2086\(2002\)046\[0281:HVTIFF\]2.0.CO;2](https://doi.org/10.1637/0005-2086(2002)046[0281:HVTIFF]2.0.CO;2)
 95. Zavala G, Jackwood MW, Hilt DA (2002) Polymerase chain reaction for detection of avian leukosis virus subgroup J in feather pulp. *Avian Dis* 46:971–978. [https://doi.org/10.1637/0005-2086\(2002\)046\[0971:pcrfd0\]2.0.co;2](https://doi.org/10.1637/0005-2086(2002)046[0971:pcrfd0]2.0.co;2)
 96. Davidson I, Borenshtain R (2002) The feather tips of commercial chickens are a favorable source of DNA for the amplification of Marek's disease virus and avian leukosis virus, subgroup J. *J Avian Pathol* 31:237–240. <https://doi.org/10.1080/03079450220136549>
 97. Robinson HL, Lamoreux WF (1976) Expression of endogenous ALV antigens and susceptibility to subgroup E ALV in three strains of chickens (endogenous avian C-type virus). *Virology* 69:50–62. [https://doi.org/10.1016/0042-6822\(76\)90193-8](https://doi.org/10.1016/0042-6822(76)90193-8)
 98. Bacon LD, Smith E, Crittenden LB, Havenstein GB (1988) Association of the slow feathering (K) and an endogenous viral (ev21) gene on the Z chromosome of chickens. *Poult Sci* 67:191–197. <https://doi.org/10.3382/ps.0670191>
 99. Koyama H, Suzuki Y, Ohwada Y, Saito Y (1976) Reticuloendotheliosis group virus pathogenic to chicken isolated from material infected with turkey herpesvirus (HVT). *Avian Dis* 20:429–434. <https://doi.org/10.2307/1589286>
 100. Jackson CA, Dunn SE, Smith DI, Gilchrist PT, Macqueen PA (1977) Proventriculitis, "nakanuke" and reticuloendotheliosis in chickens following vaccination with herpesvirus of turkeys (HVT). *Aust Vet J* 53:457–459. <https://doi.org/10.1111/j.1751-0813.1977.tb05509.x>
 101. Tajima M, Nunoya T, Otaki Y (1977) Pathogenesis of abnormal feathers in chickens inoculated with reticuloendotheliosis virus. *Avian Dis* 21:77–89
 102. Koyama H, Sasaki T, Ohwada Y, Saito Y (1980) The relationship between feathering abnormalities ("nakanuke") and tumour production in chickens inoculated with reticuloendotheliosis virus. *Avian Pathol* 9:331–340. <https://doi.org/10.1080/03079458008418417>
 103. Fadly AM, Witter RL, Smith EJ, Silva RF, Reed WM, Hoerr FJ, Putnam MR (1996) An outbreak of lymphomas in commercial broiler breeder chickens vaccinated with a fowlpox vaccine contaminated with reticuloendotheliosis virus. *Avian Pathol* 25:35–47. <https://doi.org/10.1080/03079459608419118>
 104. Diallo IS, Mackenzie MA, Spradbrow PB, Robinson WF (1998) Field isolates of fowlpox virus contaminated with reticuloendotheliosis virus. *Avian Pathol* 27:60–66. <https://doi.org/10.1080/03079459808419275>
 105. Webster RG, Bean WJ, Gorman OT, Chambers TM, Kawaoka Y (1992) Evolution and ecology of influenza A viruses. *Microbiol Rev* 56:152–179. <https://doi.org/10.1128/mr.56.1.152-179.1992>
 106. Alexander DJ (2000) A review of avian influenza in different bird species. *Vet Microbiol* 74:3–13. [https://doi.org/10.1016/s0378-1135\(00\)00160-7](https://doi.org/10.1016/s0378-1135(00)00160-7)
 107. Swayne DE, Suarez DL, Sims LD (2018) Influenza. In: Swayne DE, Boulianne M et al. (eds) *Diseases of poultry*, 14th edn. Wiley-Blackwell, Hoboken, pp 210–256. <https://doi.org/10.1193/119371199.ch6>
 108. Sturm-Ramirez KM, Hulse-Post DJ, Govorkova EA, Humberd J, Seiler P, Puthavathana P, Buranathai C, Nguyen TD, Chaisingh A, Long HT, Naipospos TS, Chen H, Ellis TM, Guan Y, Peiris JS, Webster RG (2005) Are ducks contributing to the endemicity of highly pathogenic H5N1 influenza virus in Asia? *J Virol* 79:11269–11279. <https://doi.org/10.1128/JVI.79.17.11269-11279.2005>
 109. Pantin-Jackwood MJ, Swayne DE (2009) Pathogenesis and pathobiology of avian influenza virus infection in birds. *Rev Sci Tech* 28:113–136. <https://doi.org/10.20506/rst.28.1.1869>
 110. Yamamoto Y, Nakamura K, Kitagawa K, Ikenaga N, Yamada M, Mase M, Narita M (2007) Severe nonpurulent encephalitis with mortality and feather lesions in call ducks (*Anas platyrhynchos* var. domestica) inoculated intravenously with H5N1 highly pathogenic avian influenza virus. *Avian Dis* 51:52–57. [https://doi.org/10.1637/0005-2086\(2007\)051\[0052:SNEWMA\]2.0.CO;2](https://doi.org/10.1637/0005-2086(2007)051[0052:SNEWMA]2.0.CO;2)
 111. Yamamoto Y, Nakamura K, Okamatsu M, Yamada M, Mase M (2008) Avian influenza virus (H5N1) replication in feathers of domestic waterfowl. *Emerg Infect Dis* 14:149–151. <https://doi.org/10.3201/eid1401.071036>
 112. Slomka MJ, To TL, Tong HH, Coward VJ, Hanna A, Shell W, Pavlidis T, Densham AL, Kargiolakis G, Arnold ME, Banks J, Brown IH (2012) Challenges for accurate and prompt molecular diagnosis of clades of highly pathogenic avian influenza H5N1 viruses emerging in Vietnam. *Avian Pathol* 41:177–193. <https://doi.org/10.1080/03079457.2012.656578>
 113. Nuradji H, Bingham J, Payne J, Harper J, Lowther S, Wibawa H, Long NT, Meers J (2017) Highly pathogenic avian influenza (H5N1) virus in feathers. *Vet Pathol* 54:226–233. <https://doi.org/10.1177/0300985816666608>
 114. Yamamoto Y, Nakamura K, Kitagawa K, Ikenaga N, Yamada M, Mase M, Narita M (2007) Pathogenesis in call ducks inoculated intranasally with H5N1 highly pathogenic avian influenza virus and transmission by oral inoculation of infective feathers from an infected call duck. *Avian Dis* 51:744–749. [https://doi.org/10.1637/0005-2086\(2007\)51\[744:PICDII\]2.0.CO;2](https://doi.org/10.1637/0005-2086(2007)51[744:PICDII]2.0.CO;2)
 115. Busquets N, Abad FX, Alba A, Dolz R, Allepuz A, Rivas R, Ramis A, Darji A, Majo N (2010) Persistence of highly pathogenic avian influenza virus (H7N1) in infected chickens: feather as a suitable sample for diagnosis. *J Gen Virol* 91:2307–2313. <https://doi.org/10.1099/vir.0.021592-0>
 116. Gaide N, Foret-Lucas C, Figueroa T, Vergne T, Lucas MN, Robertet L, Souvestre M, Croville G, Le Loc'h G, Delverdier M, Guerin JL (2021) Viral tropism and detection of clade 2.3.4.4b H5N8 highly pathogenic avian influenza viruses in feathers of ducks and geese. *Sci Rep* 11:5928. <https://doi.org/10.1038/s41598-021-85109-5>
 117. Gaide N, Filaire F, Bertran K, Crispo M, Dirat M, Secula A, Foret-Lucas C, Payre B, Perlas A, Cantero G, Majo N, Soubies S, Guerin JL (2023) The feather epithelium contributes to the dissemination and ecology of clade 2.3.4.4b H5 high pathogenicity avian influenza viruses in ducks. *Emerg Microbes Infect* 12:2272644. <https://doi.org/10.1080/22221751.2023.2272644>
 118. Nuradji H, Bingham J, Lowther S, Wibawa H, Colling A, Long NT, Meers J (2015) A comparative evaluation of feathers, oropharyngeal swabs, and cloacal swabs for the detection of H5N1 highly pathogenic avian influenza virus infection in experimentally infected chickens and ducks. *J Vet Diagn Invest* 27:704–715. <https://doi.org/10.1177/1040638715611443>

119. Yamamoto Y, Nakamura K, Mase M (2017) Survival of highly pathogenic avian influenza H5N1 virus in tissues derived from experimentally infected chickens. *Appl Environ Microbiol* 83:e00604-17. <https://doi.org/10.1128/AEM.00604-17>
120. Yamamoto Y, Nakamura K, Yamada M, Mase M (2010) Persistence of avian influenza virus (H5N1) in feathers detached from bodies of infected domestic ducks. *Appl Environ Microbiol* 76:5496–5499. <https://doi.org/10.1128/AEM.00563-10>
121. Karunakaran AC, Murugkar HV, Kumar M, Nagarajan S, Tosh C, Pathak A, Mekhemadhom Rajendrakumar A, Agarwal RK (2019) Survivability of highly pathogenic avian influenza virus (H5N1) in naturally preened duck feathers at different temperatures. *Transbound Emerg Dis* 66:1306–1313. <https://doi.org/10.1111/tbed.13148>
122. Yamamoto Y, Nakamura K, Okamatsu M, Miyazaki A, Yamada M, Mase M (2008) Detecting avian influenza virus (H5N1) in domestic duck feathers. *Emerg Infect Dis* 14:1671–1672. <https://doi.org/10.3201/eid1410.080415>
123. Slomka MJ, To TL, Tong HH, Coward VJ, Mawhinney IC, Banks J, Brown IH (2012) Evaluation of lateral flow devices for identification of infected poultry by testing swab and feather specimens during H5N1 highly pathogenic avian influenza outbreaks in Vietnam. *Influenza Other Respir Viruses* 6:318–327. <https://doi.org/10.1111/j.1750-2659.2011.00317.x>
124. James J, Warren CJ, De Silva D, Lewis T, Grace K, Reid SM, Falchieri M, Brown IH, Banyard AC (2023) The role of airborne particles in the epidemiology of clade 2.3.4.4b H5N1 high pathogenicity avian influenza virus in commercial poultry production units. *Viruses* 15:1002. <https://doi.org/10.3390/v15041002>
125. Davidson I (2015) A new look at avian flaviviruses. *Isr J Vet Med* 70:3–8
126. Pierson TC, Diamond MS (2020) The continued threat of emerging flaviviruses. *Nat Microbiol* 5:796–812. <https://doi.org/10.1038/s41564-020-0714-0>
127. Petersen LR, Brault AC, Nasci RS (2013) West Nile virus: review of the literature. *JAMA* 310:308–315. <https://doi.org/10.1001/jama.2013.8042>
128. Komar N, Langevin S, Hinten S, Nemeth N, Edwards E, Hettler D, Davis B, Bowen R, Bunning M (2003) Experimental infection of North American birds with the New York 1999 strain of West Nile virus. *Emerg Infect Dis* 9:311–322. <https://doi.org/10.3201/eid0903.020628>
129. Docherty DE, Long RR, Griffin KM, Saito EK (2004) Corvidae feather pulp and West Nile virus detection. *Emerg Infect Dis* 10:907–909. <https://doi.org/10.3201/eid1005.030825>
130. Nemeth N, Young G, Ndaluka C, Bielefeldt-Ohmann H, Komar N, Bowen R (2009) Persistent West Nile virus infection in the house sparrow (*Passer domesticus*). *Arch Virol* 154:783–789. <https://doi.org/10.1007/s00705-009-0369-x>
131. Swayne DE, Beck JR, Smith CS, Shieh WJ, Zaki SR (2001) Fatal encephalitis and myocarditis in young domestic geese (*Anser anser domesticus*) caused by West Nile virus. *Emerg Infect Dis* 7:751–753. <https://doi.org/10.3201/eid0704.010429>
132. Banet-Noach C, Simanov L, Malkinson M (2003) Direct (non-vector) transmission of West Nile virus in geese. *Avian Pathol* 32:489–494. <https://doi.org/10.1080/0307945031000154080>
133. Austin RJ, Whiting TL, Anderson RA, Drebot MA (2004) An outbreak of West Nile virus-associated disease in domestic geese (*Anser anser domesticus*) upon initial introduction to a geographic region, with evidence of bird to bird transmission. *Can Vet J* 45:117–123
134. Holicki CM, Michel F, Vasic A, Fast C, Eiden M, Raileanu C, Kampen H, Werner D, Groschup MH, Ziegler U (2020) Pathogenicity of West Nile virus lineage 1 to German poultry. *Vaccines* 8:507. <https://doi.org/10.3390/vaccines8030507>
135. Reemtsma H, Holicki CM, Fast C, Bergmann F, Eiden M, Groschup MH, Ziegler U (2022) Pathogenesis of West Nile virus lineage 2 in domestic geese after experimental infection. *Viruses* 14:1319. <https://doi.org/10.3390/v14061319>
136. Bin H, Grossman Z, Pokamunski S, Malkinson M, Weiss L, Duvdevani P, Banet C, Weisman Y, Annis E, Gandaku D, Yahalom V, Hindiyeh M, Shulman L, Mendelson E (2001) West Nile fever in Israel 1999–2000: from geese to humans. *Ann N Y Acad Sci* 951:127–142. <https://doi.org/10.1111/j.1749-6632.2001.tb02691.x>
137. Meece JK, Kronenwetter-Koepel TA, Vandermause MF, Reed KD (2006) West Nile virus infection in commercial waterfowl operation, Wisconsin. *Emerg Infect Dis* 12:1451–1453. <https://doi.org/10.3201/eid1209.051648>
138. Swayne DE, Beck JR, Zaki S (2000) Pathogenicity of West Nile virus for turkeys. *Avian Dis* 44:932–937. <https://doi.org/10.2307/1593067>
139. Langevin SA, Bunning M, Davis B, Komar N (2001) Experimental infection of chickens as candidate sentinels for West Nile virus. *Emerg Infect Dis* 7:726–729. <https://doi.org/10.3201/eid0704.010422>
140. Buckley A, Dawson A, Gould EA (2006) Detection of seroconversion to West Nile virus, *Usutu virus* and *Sindbis virus* in UK sentinel chickens. *Virology* 3:71. <https://doi.org/10.1186/1743-422X-3-71>
141. Maquart M, Boyer S, Rakotoharinome VM, Ravaomanana J, Tantely ML, Heraud JM, Cardinale E (2016) High prevalence of West Nile virus in domestic birds and detection in 2 new mosquito species in Madagascar. *PLoS One* 11:e0147589. <https://doi.org/10.1371/journal.pone.0147589>
142. Styer LM, Bernard KA, Kramer LD (2006) Enhanced early West Nile virus infection in young chickens infected by mosquito bite: effect of viral dose. *Am J Trop Med Hyg* 75:337–345. <https://doi.org/10.4269/ajtmh.2006.75.337>
143. Styer LM, Kent KA, Albright RG, Bennett CJ, Kramer LD, Bernard KA (2007) Mosquitoes inoculate high doses of West Nile virus as they probe and feed on live hosts. *PLoS Pathog* 3:1262–1270. <https://doi.org/10.1371/journal.ppat.0030132>
144. Phipps LP, Gough RE, Ceeraz V, Cox WJ, Brown IH (2007) Detection of West Nile virus in the tissues of specific pathogen free chickens and serological response to laboratory infection: a comparative study. *Avian Pathol* 36:301–305. <https://doi.org/10.1080/03079450701460492>
145. Lim PY, Behr MJ, Chadwick CM, Shi PY, Bernard KA (2011) Keratinocytes are cell targets of West Nile virus in vivo. *J Virol* 85:5197–5201. <https://doi.org/10.1128/JVI.02692-10>
146. Martin MF, Maarifi G, Abiven H, Seffals M, Mouchet N, Beck C, Bodet C, Leveque N, Arhel NJ, Blanchet FP, Simonin Y, Nisole S (2022) Usutu virus escapes langerin-induced restriction to productively infect human Langerhans cells, unlike West Nile virus. *Emerg Microbes Infect* 11:761–774. <https://doi.org/10.1080/22221751.2022.2045875>
147. Roesch F, Fajardo A, Moratorio G, Vignuzzi M (2019) Usutu virus: an arbovirus on the rise. *Viruses* 11:640. <https://doi.org/10.3390/v11070640>
148. Saiz J-C, Blazquez A-B (2017) Usutu virus: current knowledge and future perspectives. *Virus Adapt Treat* 9:27–40. <https://doi.org/10.2147/VAAT.S123619>
149. Becker N, Jost H, Ziegler U, Eiden M, Hoper D, Emmerich P, Fichet-Calvet E, Ehichioya DU, Czajka C, Gabriel M, Hoffmann B, Beer M, Tenner-Racz K, Racz P, Gunther S, Wink M, Bosch S, Konrad A, Pfeffer M, Groschup MH, Schmidt-Chanasit J (2012) Epizootic emergence of Usutu virus in wild and captive birds in Germany. *PLoS One* 7:e32604. <https://doi.org/10.1371/journal.pone.0032604>
150. Lelli R, Savini G, Teodori L, Filippini G, Di Gennaro A, Leone A, Di Gialleonardo L, Venturi L, Caporale V (2008) Serological evidence of USUTU virus occurrence in north-eastern Italy. *Zoonoses Public Health* 55:361–367. <https://doi.org/10.1111/j.1863-2378.2008.01146.x>
151. Kuchinsky SC, Frere F, Heitzman-Breen N, Golden J, Vazquez A, Honaker CF, Siegel PB, Ciupe SM, LeRoith T, Duggal NK (2021) Pathogenesis and shedding of Usutu virus in juvenile chickens. *Emerg Microbes Infect* 10:725–738. <https://doi.org/10.1080/22221751.2021.1908850>
152. Benzarti E, Rivas J, Sarlet M, Franssen M, Desmecht D, Schmidt-Chanasit J, Savini G, Lorusso A, Van Laere AS, Garigliany MM (2020) Experimental Usutu virus infection in domestic canaries *Serinus canaria*. *Viruses* 12:164. <https://doi.org/10.3390/v12020164>
153. Vouillon A, Barthelemy J, Lebeau L, Nisole S, Savini G, Leveque N, Simonin Y, Garcia M, Bodet C (2023) Skin tropism during Usutu virus and West Nile virus infection: an amplifying and immunological role. *J Virol* 98:e0183023. <https://doi.org/10.1128/jvi.01830-23>
154. Barr KL, Anderson BD, Prakoso D, Long MT (2016) Working with Zika and Usutu viruses in vitro. *PLoS Negl Trop Dis* 10:e0004931. <https://doi.org/10.1371/journal.pntd.0004931>
155. Benzarti E, Rivas J, Sarlet M, Franssen M, Moula N, Savini G, Lorusso A, Desmecht D, Garigliany MM (2020) Usutu virus infection of embryonated chicken eggs and a chicken embryo-derived primary cell line. *Viruses* 12:531. <https://doi.org/10.3390/v12050531>

156. Bakonyi T, Lussy H, Weissenböck H, Hornyak A, Nowotny N (2005) In vitro host-cell susceptibility to Usutu virus. *Emerg Infect Dis* 11:298–301. <https://doi.org/10.3201/eid1102.041016>
157. Hamel R, Phanitchat T, Wichit S, Morales Vargas RE, Jaroenpool J, Diagne CT, Pompon J, Misse D (2021) New insights into the biology of the emerging Tembusu virus. *Pathogens* 10:1010. <https://doi.org/10.3390/pathogens10081010>
158. Wang CW, Chen YL, Mao SJT, Lin TC, Wu CW, Thongchan D, Wang CY, Wu HY (2022) Pathogenicity of avian polyomaviruses and prospect of vaccine development. *Viruses* 14:2079. <https://doi.org/10.3390/v14092079>
159. Guerin JL, Gelfi J, Dubois L, Vuillaume A, Boucraut-Baralon C, Pingret JL (2000) A novel polyomavirus (goose hemorrhagic polyomavirus) is the agent of hemorrhagic nephritis enteritis of geese. *J Virol* 74:4523–4529. <https://doi.org/10.1128/jvi.74.10.4523-4529.2000>
160. Garmyin A, Verlinden M, Bosseler L, Adriaensen C, Martel A (2017) Persistent goose hemorrhagic polyomavirus infection on a Belgian goose farm. *Avian Dis* 61:536–538. <https://doi.org/10.1637/11604-020317-Case.1>
161. Krautwald ME, Müller H, Kaleta EF (1989) Polyomavirus infection in budgerigars (*Melopsittacus undulatus*): clinical and aetiological studies. *Zentralbl Veterinarmed B* 36:459–467. <https://doi.org/10.1111/j.1439-0450.1989.tb00628.x>
162. Stoll R, Luo D, Kouwenhoven B, Hobom G, Müller H (1993) Molecular and biological characteristics of avian polyomaviruses: isolates from different species of birds indicate that avian polyomaviruses form a distinct subgenus within the polyomavirus genus. *J Gen Virol* 74:229–237. <https://doi.org/10.1099/0022-1317-74-2-229>
163. Varsani A, Porzig EL, Jennings S, Kraberger S, Farkas K, Julian L, Massaro M, Ballard G, Ainley DG (2015) Identification of an avian polyomavirus associated with Adelie penguins (*Pygoscelis adeliae*). *J Gen Virol* 96:851–857. <https://doi.org/10.1099/vir.0.000038>
164. Fawaz M, Vijayakumar P, Mishra A, Gandhale PN, Dutta R, Kamble NM, Sudhakar SB, Roychoudhary P, Kumar H, Kulkarni DD, Raut AA (2016) Duck gut viral metagenome analysis captures snapshot of viral diversity. *Gut Pathog* 8:30. <https://doi.org/10.1186/s13099-016-0113-5>
165. Williams RAJ, Tolf C, Waldenstrom J (2018) Molecular identification of papillomavirus in ducks. *Sci Rep* 8:9096. <https://doi.org/10.1038/s41598-018-27373-6>
166. Truchado DA, Williams RAJ, Benitez L (2018) Natural history of avian papillomaviruses. *Virus Res* 252:58–67. <https://doi.org/10.1016/j.virusres.2018.05.014>
167. Canuti M, Munro HJ, Robertson GJ, Kroyer ANK, Roul S, Ojkic D, Whitney HG, Lang AS (2019) New insight into avian papillomavirus ecology and evolution from characterization of novel wild bird papillomaviruses. *Front Microbiol* 10:701. <https://doi.org/10.3389/fmicb.2019.00701>
168. Rosenbaum CS, Wunschmann A, Armien AG, Schott R, Singh VK, Mor SK (2022) Novel papillomavirus in a mallard duck with mesenchymal chondroid dermal tumors. *J Vet Diagn Invest* 34:231–236. <https://doi.org/10.1177/10406387221075607>
169. Van Doorslaer K, Sidi AO, Zanier K, Rybin V, Deryckere F, Rector A, Burk RD, Lienau EK, van Ranst M, Trave G (2009) Identification of unusual E6 and E7 proteins within avian papillomaviruses: cellular localization, biophysical characterization, and phylogenetic analysis. *J Virol* 83:8759–8770. <https://doi.org/10.1128/JVI.01777-08>
170. Varsani A, Kraberger S, Jennings S, Porzig EL, Julian L, Massaro M, Pollard A, Ballard G, Ainley DG (2014) A novel papillomavirus in Adelie penguin (*Pygoscelis adeliae*) faeces sampled at the Cape Crozier colony, Antarctica. *J Gen Virol* 95:1352–1365. <https://doi.org/10.1099/vir.0.064436-0>
171. Lina PH, van Noord MJ, de Groot FG (1973) Detection of virus in squamous papillomas of the wild bird species *Fringilla coelebs*. *J Natl Cancer Inst* 50:567–571. <https://doi.org/10.1093/jnci/50.2.567>
172. Jacobson ER, Mladinich CR, Clubb S, Sundberg JP, Lancaster WD (1983) Papilloma-like virus infection in an African gray parrot. *J Am Vet Med Assoc* 183:1307–1308
173. Wieland U, Mauch C, Kreuter A, Krieg T, Pfister H (2009) Merkel cell polyomavirus DNA in persons without merkel cell carcinoma. *Emerg Infect Dis* 15:1496–1498. <https://doi.org/10.3201/eid1509.081575>
174. Schowalter RM, Pastrana DV, Pumphrey KA, Moyer AL, Buck CB (2010) Merkel cell polyomavirus and two previously unknown polyomaviruses are chronically shed from human skin. *Cell Host Microbe* 7:509–515. <https://doi.org/10.1016/j.chom.2010.05.006>
175. Foulongne V, Sauvage V, Hebert C, Dereure O, Cheval J, Gouilh MA, Pariente K, Segondy M, Burguiere A, Manuguerra JC, Caro V, Eloit M (2012) Human skin microbiota: high diversity of DNA viruses identified on the human skin by high throughput sequencing. *PLoS One* 7:e38499. <https://doi.org/10.1371/journal.pone.0038499>
176. Palya V, Zolnai A, Benyeda Z, Kovács E, Kardi V, Mató T (2009) Short beak and dwarfism syndrome of mule duck is caused by a distinct lineage of goose parvovirus. *Avian Pathol* 38:175–180. <https://doi.org/10.1080/03079450902737839>
177. Ning K, Wang M, Qu S, Lv J, Yang L, Zhang D (2017) Pathogenicity of Pekin duck- and goose-origin parvoviruses in Pekin ducklings. *Vet Microbiol* 210:17–23. <https://doi.org/10.1016/j.vetmic.2017.08.020>
178. Yu K, Ma X, Sheng Z, Qi L, Liu C, Wang D, Huang B, Li F, Song M (2016) Identification of goose-origin parvovirus as a cause of newly emerging beak atrophy and dwarfism syndrome in ducklings. *J Clin Microbiol* 54:1999–2007. <https://doi.org/10.1128/jcm.03244-15>
179. Ning K, Liang T, Wang M, Dong Y, Qu S, Zhang D (2018) Pathogenicity of a variant goose parvovirus, from short beak and dwarfism syndrome of Pekin ducks, in goose embryos and goslings. *Avian Pathol* 47:391–399. <https://doi.org/10.1080/03079457.2018.1459040>
180. Rheinwald JG, Green H (1975) Serial cultivation of strains of human epidermal keratinocytes: the formation of keratinizing colonies from single cells. *Cell* 6:331–343. [https://doi.org/10.1016/s0092-8674\(75\)80001-8](https://doi.org/10.1016/s0092-8674(75)80001-8)
181. Couteaudier M, Trapp-Fragnet L, Auger N, Courvoisier K, Pain B, Denesvre C, Vautherot JF (2015) Derivation of keratinocytes from chicken embryonic stem cells: establishment and characterization of differentiated proliferative cell populations. *Stem Cell Res* 14:224–237. <https://doi.org/10.1016/j.scr.2015.01.002>
182. Olivier S, Jacoby M, Brillon C, Bouletreau S, Mollet T, Nerriere O, Angel A, Danet S, Souttou B, Guehenneux F, Gauthier L, Berthome M, Vie H, Beltraminelli N, Mehtali M (2010) EB66 cell line, a duck embryonic stem cell-derived substrate for the industrial production of therapeutic monoclonal antibodies with enhanced ADCC activity. *MAbs* 2:405–415. <https://doi.org/10.4161/mabs.12350>
183. Wolff ET, Laforest P (1960) On the specific histopathological lesions induced by the fowl-pox virus in explants of chick embryo skin in organ culture in vitro. *Ann Inst Pasteur* 98:325–334
184. Dhouailly D (1973) Dermo-epidermal interactions between birds and mammals: differentiation of cutaneous appendages. *J Embryol Exp Morphol* 30:587–603. <https://doi.org/10.1242/dev.30.3.587>
185. Souci L, Denesvre C (2021) 3D skin models in domestic animals. *Vet Res* 52:21. <https://doi.org/10.1186/s13567-020-00888-5>
186. Chuong CM (2000) Skin morphogenesis. Embryonic chicken skin explant cultures. *Methods Mol Biol* 136:101–106. <https://doi.org/10.1385/1-59259-065-9:101>
187. Chuong C-M, Ting SA, Widelitz RB, Lee Y-S (1992) Mechanism of skin morphogenesis. II. Retinoic acid modulates axis orientation and phenotypes of skin appendages. *Development* 115:839–852. <https://doi.org/10.1242/dev.115.3.839>
188. Philpott MP (2013) Hair follicle culture—a historical perspective. *Int Soc Hair Restor Surg* 23:130–133. <https://doi.org/10.33589/23.2.0130>
189. Mallet C, Souci L, Ledevin M, Georgeault S, Larcher T, Denesvre C (2022) Establishment of a culture model for the prolonged maintenance of chicken feather follicles structure in vitro. *PLoS One* 17:e0271448. <https://doi.org/10.1371/journal.pone.0271448>
190. Andrei G, Duraffour S, Van den Oord J, Snoeck R (2010) Epithelial raft cultures for investigations of virus growth, pathogenesis and efficacy of antiviral agents. *Antiviral Res* 85:431–449. <https://doi.org/10.1016/j.antiviral.2009.10.019>
191. De La Cruz NC, Mockel M, Niehues H, Rubsam M, Malter W, Zinser M, Krummenacher C, Knebel-Morsdorf D (2023) Ex vivo infection of human skin models with herpes simplex virus 1: accessibility of the receptor nectin-1 during formation or impairment of epidermal barriers is restricted by tight junctions. *J Virol* 97:e0026223. <https://doi.org/10.1128/jvi.00262-23>
192. Muhsen M, Protschka M, Schneider LE, Müller U, Kohler G, Magin TM, Buttner M, Alber G, Siegemund S (2019) Orf virus (ORFV) infection in a three-dimensional human skin model: characteristic cellular

- alterations and interference with keratinocyte differentiation. *PLoS One* 14:e0210504. <https://doi.org/10.1371/journal.pone.0210504>
193. Loke ASW, Longley BJ, Lambert PF, Spurgeon ME (2021) A novel in vitro culture model system to study merkel cell polyomavirus-associated MCC using three-dimensional organotypic raft equivalents of human skin. *Viruses* 13:138. <https://doi.org/10.3390/v13010138>
194. Jiang Y, Tsoi LC, Billi AC, Ward NL, Harms PW, Zeng C, Maverakis E, Kahlenberg JM, Gudjonsson JE (2020) Cytokinocytes: the diverse contribution of keratinocytes to immune responses in skin. *JCI Insight* 5:e142067. <https://doi.org/10.1172/jci.insight.142067>
195. Monson EA, Trenerry AM, Laws JL, Mackenzie JM, Helbig KJ (2021) Lipid droplets and lipid mediators in viral infection and immunity. *FEMS Microbiol Rev* 45:fuaa066. <https://doi.org/10.1093/femsre/fuaa066>

Publisher's Note

Springer Nature remains neutral with regard to jurisdictional claims in published maps and institutional affiliations.