



HAL
open science

Spinal axial torque assessment after surgical correction in adolescent idiopathic scoliosis: a new approach to 3D barycentremetry and mass distribution based on biplanar radiographs

Tristan Langlais, Wafa Skalli, Xavier Du Cluzel, Nicolas Mainard, Samuel George, Laurent Gajny, Raphaël Vialle, Jean Dubousset, Claudio Vergari

► To cite this version:

Tristan Langlais, Wafa Skalli, Xavier Du Cluzel, Nicolas Mainard, Samuel George, et al.. Spinal axial torque assessment after surgical correction in adolescent idiopathic scoliosis: a new approach to 3D barycentremetry and mass distribution based on biplanar radiographs. *Spine Deformity*, 2024, 10.1007/s43390-023-00816-5 . hal-04559634

HAL Id: hal-04559634


<https://hal.science/hal-04559634v1>

Submitted on 25 Apr 2024

HAL is a multi-disciplinary open access archive for the deposit and dissemination of scientific research documents, whether they are published or not. The documents may come from teaching and research institutions in France or abroad, or from public or private research centers.

L'archive ouverte pluridisciplinaire **HAL**, est destinée au dépôt et à la diffusion de documents scientifiques de niveau recherche, publiés ou non, émanant des établissements d'enseignement et de recherche français ou étrangers, des laboratoires publics ou privés.

Spinal axial torque assessment after surgical correction in adolescent idiopathic scoliosis: a new approach to 3D barycentremetry and mass distribution based on biplanar radiographs

Tristan Langlais^{1,2}  · Wafa Skalli¹ · Xavier du Cluzel³ · Nicolas Mainard⁴ · Samuel George³ · Laurent Gajny¹ · Raphael Vialle⁴ · Jean Dubousset¹ · Claudio Vergari¹

Received: 2 October 2023 / Accepted: 23 December 2023
© The Author(s), under exclusive licence to Scoliosis Research Society 2024

Abstract

Purpose Barycentremetry in adolescent idiopathic scoliosis (AIS) allows the distribution of masses and their loading of the spine to be studied. In particular, the axial torque on the spine has been studied in AIS, but not after surgical correction. Spinal axial torque was studied in AIS before and after surgery.

Methods All AIS (Lenke 1 and 3) who underwent posterior spinal fusion surgery at our center in 2019 were included retrospectively. AIS underwent frontal and sagittal biplanar radiographs in the free-standing position before surgery, 4 months after surgery, and at the last follow-up. Their spine and external envelope were reconstructed with validated methods. Spinal axial torque at the apex and the upper and lower end vertebra was calculated. Finally, the preoperative and postoperative values were compared to a previously published reference corridor for asymptomatic subjects.

Results Twenty-nine patients were included ($54 \pm 11^\circ$ Cobb angle, 15 ± 2 years old at surgery). The surgical procedure decreased the Cobb angle by $36^\circ \pm 11^\circ$ and decreased the spinal axial torque at the upper end vertebra by 2.5 N/m (95% CI = [1.9; 3]; $p < 0.001$), at the apex by 0.6 N/m (95% CI = [0.4; 1]; $p = 0.004$), at the lower end vertebra by 2 N/m (95% CI = [1.5; 2.8]; $p < 0.001$). Compared to 95th percentile of torque, which was previously evaluated in asymptomatic subjects, more than 90% of patients had higher values at the upper and lower end vertebrae before surgery. Postoperatively, 62% of patients still had higher torque at the upper end vertebra than asymptomatic subjects, while only 38% patients showed abnormal values at the lower junction.

Conclusion Results of this study confirm that AIS patients show abnormally high spinal axial torque, especially at the end vertebrae, and that this parameter is normalized postoperatively for only a small number of patients.

Keywords Scoliosis · Idiopathic · Adolescent · Barycentremetry · Axial torque · Biplanar radiographs

Introduction

Idiopathic scoliosis is a three-dimensional (3D) spinal deformity in which the goal of surgical treatment is to achieve a successful arthrodesis in a patient-satisfactory 3D balance position. Given the multiplicity of implants and industrial processes, an objective, reproducible, and operator-independent therapeutic evaluation has become necessary. The objective of the evaluation is to assess the axial correction (i.e., the reduction of the rib hump), the frontal correction (i.e., a satisfactory balance of the shoulders and the height), and the sagittal balance (i.e., a thoracic kyphosis in adequacy with the lumbar lordosis and the pelvic parameters). The 3D reconstruction of the spine from low-dose biplanar radiographs allows quantification of the

✉ Tristan Langlais
langlais.t@chu-toulouse.fr

¹ Institut de Biomécanique Humaine Georges Charpak, Arts et Métiers, HESAM Université, Paris, France

² Service Orthopédie et Traumatologie, Hôpital des Enfants, CHU Purpan, Toulouse Université, Toulouse, France

³ Service Orthopédie et Traumatologie, CHU Necker Enfants Malades, Paris Cité Université, APHP, Paris, France

⁴ Service Orthopédie et Traumatologie, CHU Armand Trousseau, APHP, Sorbonne Université, Paris, France

bone correction in the standing position using geometrical parameters (e.g., intervertebral axial rotation, torsion index) [1]. However, this 3D analysis method only focuses on the alignment, and it does not inform us on balance related to the forces acting on the spine, and in particular on the asymmetrical displacement of mass and gravity center.

Recently, the barycentremetry analysis made possible by the 3D reconstruction of the external envelope from biplanar X-rays has allowed the analysis of new biomechanical markers such as the spinal axial torque [2, 3]. These studies showed that there were alterations of load and mass distribution in scoliosis patients compared to a cohort of subjects without spinal pathology. However, it remained unclear if surgical correction of severe cases could restore these parameters to values similar to asymptomatic patients.

To this end, parameters from 3D reconstruction of the external envelope were studied in a cohort of patients who were undergoing surgery for idiopathic scoliosis.

Materials and methods

Subjects

This study was approved by the ethics local committee and registered in the National Commission on Informatics and Freedoms (CNIL) database register (No 2231354). Parents, children, and adults were informed about the protocol and consented to participate. All adolescents with idiopathic scoliosis (Lenke 1 and 5) [4] who underwent posterior spinal fusion surgery at our center between January 2019 and December 2019 were included retrospectively. Spinal surgery was proposed if the frontal Cobb angle was greater than 40°, Risser's sign greater than 1, and at least one of clinical trunk malalignment and/or lower thoracic hypokyphosis of 20°. Exclusion criteria were transitional anomaly, previous spinal surgery, halo traction before fusion, and incomplete follow-up (under 24 months). A single spine surgeon performed the surgical interventions, using an all-screw fixation (except a transverse hook at the top of construct) in all patients under somatosensory and motor evoked potentials monitoring. Correction was done by a posteromedial translation method [5].

Imaging data assessment

All patients underwent frontal and sagittal biplanar radiographs (EOS™ system, EOS imaging, Paris, France) [6] in the free-standing position [7] before surgery, 4 months after surgery, and at the last follow-up. Incorrect positioning on biplanar radiographs was an exclusion criterion. Quasi-automatic 3D reconstructions of the spine were performed using a previously validated technique [8]. The upper and lower

boundary vertebra of the main curve were defined to obtain the maximization of the Cobb angle. An automatic algorithm provided an initial 3D reconstruction solution, upon which the operator could perform rapid manual adjustment of the vertebrae to improve accuracy. The reconstruction took about 5 min on average. The 3D reconstruction allowed the automatic calculation of spinopelvic geometric parameters: Cobb angle of the main curve (°), kyphosis T4–T12 (°), L1–S1 lordosis (°), pelvic tilt (°), pelvic incidence (°), the OD-HA angle coronal and sagittal (°) (where OD was the position of the C2 odontoid, as an estimate of the center of mass of the head, and HA was the midpoint of the pelvic acetabular) [9], the index torsion [10], the hypokyphosis index [11], the intervertebral axial rotation at the upper and lower end vertebra, the vertebra axial rotation at the apex and the spinal length T1–T12 and T1–S1 [12]. The index torsion was computed as the mean of the sum of intervertebral axial rotations from lower junction to apex and from apex to upper junction [10] (Fig. 1). The hypokyphosis index [11] was defined as the difference between the patient's local kyphosis (or lordosis) at the apex of the thoracic curvature and mean value at the equivalent level for persons without scoliosis (Fig. 1).

3D barycentremetry assessment

Preoperative, postoperative, and last follow-up external shape was reconstructed (3 reconstructions per patient = 3 × 29 patient = 87 reconstructions), retrospectively, using a validated technique [8] (Fig. 2). The reconstruction takes about 15 min, and it allows automatic estimation of body segments masses, according to a recent estimation of segmental mass density [13], calculation of the apex and the upper and lower end vertebra spinal axial torque [2]. The spinal axial torque applied to each vertebra (apical, upper, and lower boundary) resulted from its lateral displacement and inclination in the sagittal plane, due to the mass of the body above the vertebra and the position of this segment's center of mass (Figs. 3 and 4). The preoperative, postoperative, and last follow-up values were analyzed, as well as their correlation with the spinal parameters. Finally, the preoperative and postoperative values were compared to a previously published reference corridor for asymptomatic subjects [3]. The percentage of scoliotic patients outside this reference corridor (i.e., outside the values between the 5th and 95th percentiles) for the preoperative and postoperative values was calculated.

Statistical analysis

Results are presented by mean (SD; range). The normality of data was verified with the Shapiro–Wilk test. The difference between preoperative/postoperative and postoperative/last

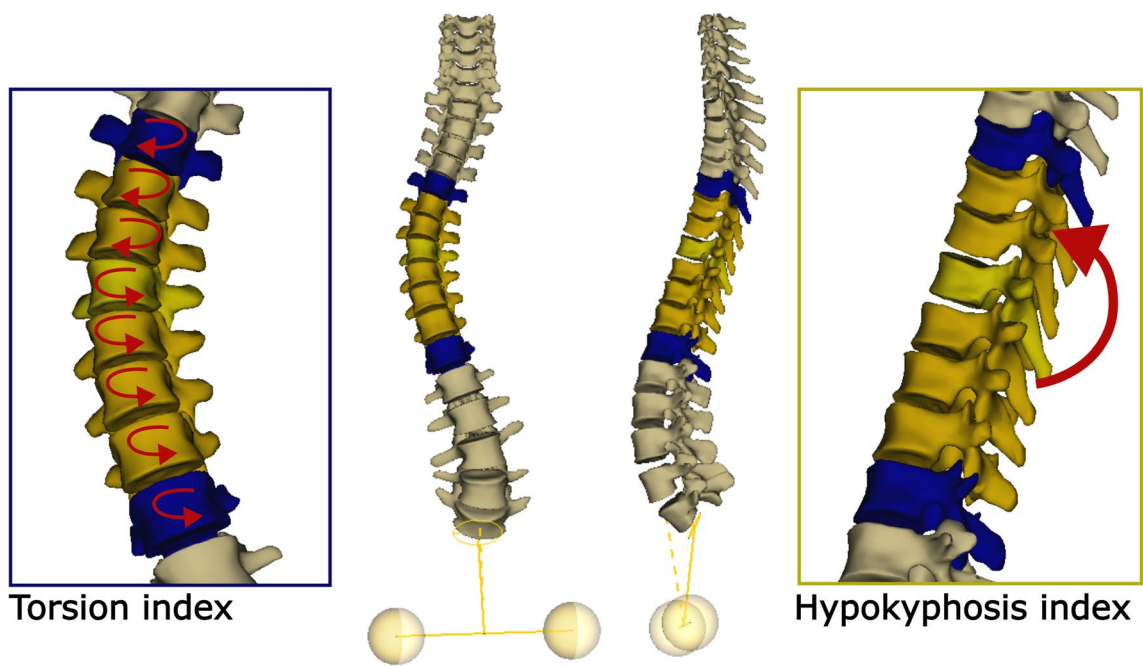


Fig. 1 Illustration about the measure of torsion and hypokyphosis index

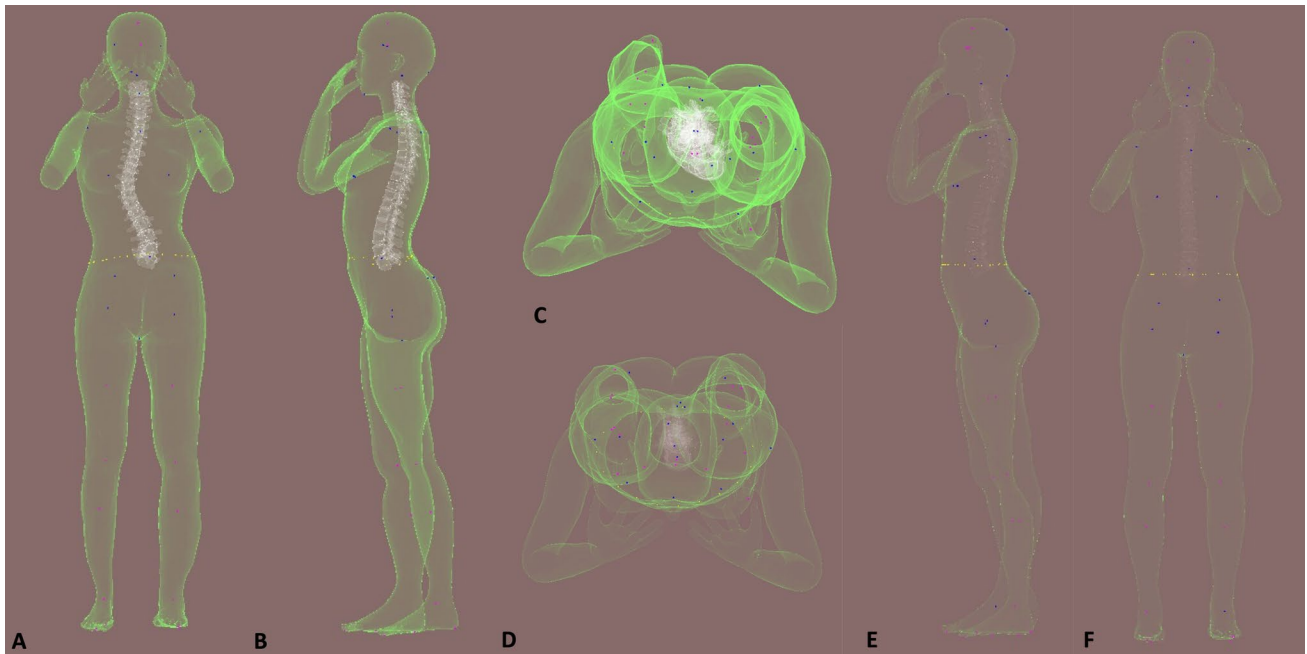


Fig. 2 Example of the preoperative (A: frontal, B: sagittal, C: top of view) external envelope reconstruction and the postoperative (D, E, F)

follow-up was assessed with the Student's paired t test or the Wilcoxon signed-rank test, depending on the normality condition. For correlation assessment between spinal and 3D barycentremetry parameters, the Spearman's or Pearson's coefficient was used, depending on the normality condition.

Correlation was considered very strong from 1 to 0.9, strong from 0.9 to 0.7, moderate from 0.7 to 0.5, low from 0.5 to 0.3, and poor from 0.3 to 0. For the comparative analysis of preoperative and postoperative values outside the reference corridor, a Fisher exact test was used. Alpha risk was

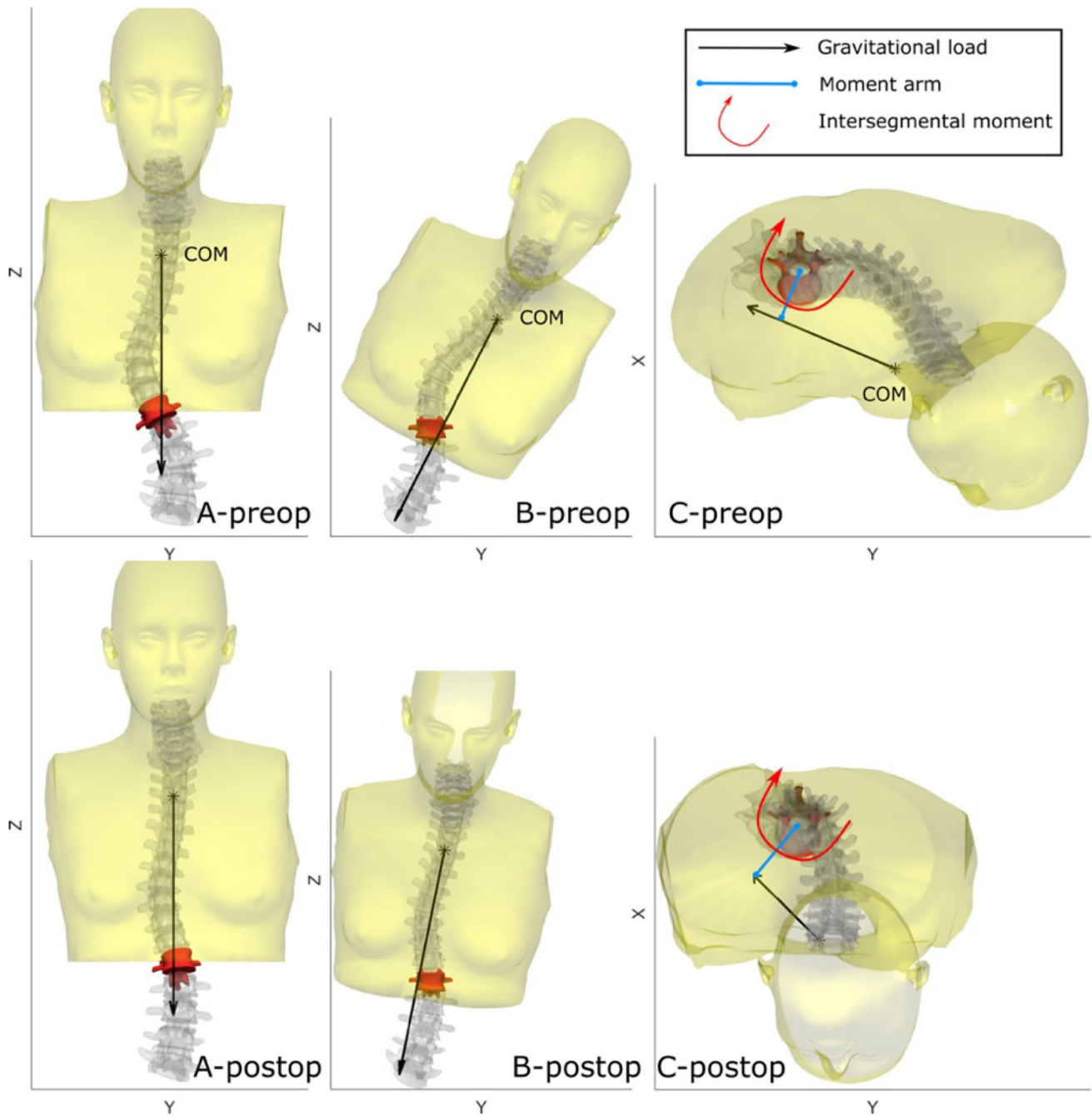


Fig.3 Visual representation of the intersegmental axial torque at the lower junctional vertebra in a patient, preop and postop. Panel A shows the 3D reconstruction of the spine, with the junctional vertebra highlighted in red, as well as the portion of the trunk above this vertebra and its center of mass (COM). The gravitational load is shown by the arrow. Panel B shows the same 3D reconstruction, but the patient (and gravitational load) was virtually rotated so that the lower end vertebra is now perfectly horizontal. Panel C shows the same configuration as B from a top view, so now the end vertebra is hori-

zontal and viewed from above. It can be noticed that the lever arm in preop and postop is similar, and the load is identical (as it depends on the weight of the trunk above the vertebra); however, in C-postop, the load arrow appears much shorter than in C-preop. This is due to the different orientation of the vertebra in the two cases, which affects the component of the load vector in the XY plane. Hence, even if the load and the lever arm are similar preop ad postop, the postop intersegmental torque is lower because the axial component of the load vector is much smaller

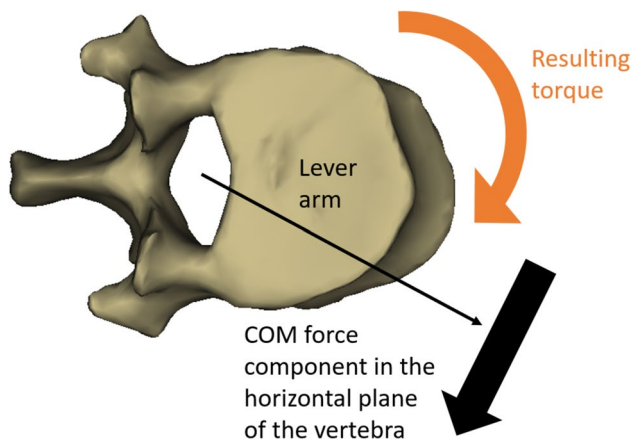


Fig. 4 Visual representation of the intersegmental axial torque for one vertebrae. The intersegmental axial torque results of the center of mass force (component in the horizontal plane of the vertebrae) and the lever arm

set to 5% ($\alpha=0.05$). Statistical analysis was performed with EasyMedStat (version 3.20.2; Neuilly-sur-Seine, France).

Results

Cohort description

Twenty-nine patients were included (twenty-three with type 1 and six with Lenke type 5 curves or twenty-three thoracic, three thoracolumbar, and three lumbar scoliosis) after removal of one patient because his external envelope was outside the frame of the frontal X-ray acquisition. The mean age at surgery was 14.8 years (SD=1.6; range 11–17) and the mean body mass index was 19 kg.m^{-2} (SD=3.3; range 7.8–27). The mean Risser's sign was 3 (SD=1; range 2–5). The mean follow-up was 29 months (range from 24 to 48 months).

Spinal radiographic assessment

The preoperative, postoperative, and last follow-up spinal parameters are reported in Table 1. The surgical procedure decreased the Cobb angle by 35.8° (95% CI = [32.6;

Table 1 Preoperative, postoperative, and last follow-up spine radiographic parameters

	Preoperative	Postoperative	Last follow-up	p value ¹	p value ²
Cobb angle (°)	53 (10) [40;77]	17 (8) [1;32]	17 (9) [1;37]	<0.001*	0.4
T4–T12 kyphosis (°)	23 (14) [− 3;46]	30 (9) [13;45]	28 (9) [5;42]	0.005*	0.2
L1–S1 lordosis (°)	56 (12) [35;74]	53 (10) [34;70]	52 (10) [30;73]	0.2	0.9
Pelvis tilt (°)	6 (9.3) [− 12;31]	8 (10) [− 13;31.8]	8 (7) [− 12;31]	0.08*	0.2
Pelvic incidence (°)	47 (15) [23;75]	48 (13) [27;75]	47 (11) [28;74]	0.2	0.7
OD-HA sagittal (°)	3 (3) [− 5;8]	2 (4) [− 7;8]	3 (3) [− 2;9]	0.2	0.2
OD-HA coronal (°)	-1 ± 2.7 [− 7;4]	-0.5 ± 2.1 [− 6;5]	-1.2 ± 1.5 [− 5;2]	0.6	0.1
Torsion index (°)	11 (5) [3.;20]	3 (2) [0.6;9]	3 (3) [0.3;12]	<0.001*	0.8
Hypokyphosis index (°)	-2 (5) [− 16;14]	1 (3) [− 6;7]	1 (3) [− 6;10]	0.003*	0.7
Intervertebral axial rotation at the upper end vertebra (°)	3 (1) [0.6;6]	2 (2) [0.1;5]	2 (2) [0.7;9]	0.07	0.8
Intervertebral axial rotation at the lower end vertebra (°)	5 (3) [0.6;12]	2 (1) [0.6;6]	2 (1) [0.8;4]	<0.001*	0.5
Vertebral axial rotation at the apex (°)	16 (8) [0.5;30]	5 (4) [0.01;11]	5 (3) [0.09;16]	<0.001*	0.8
Spinal length T1–T12 (mm)	237 (13) [212;271]	244 (15) [214;285]	245 (16) [218;286]	<0.001*	0.7
Spinal length T1–L5 (mm)	398 (21) [361;454]	406 (22) [366;468]	406 (25) [369;470]	<0.001*	0.7

Results are presented by mean (SD) [range]. p value¹ refers to the analysis of preoperative and postoperative data while p value² refers to postoperative and final follow-up data. Significant p values are shown by an asterisk*

39]; $p < 0.001$), the torsion index by 7.3° (95% CI = [5.8; 8.9]; $p < 0.001$), the hypokyphosis index by 2.9° (95% CI = [0.9; 4.5]; $p = 0.003$), the intervertebral axial rotation at the lower end vertebra by 3.6° (95% CI = [2.5; 4.4]; $p < 0.001$), and the vertebral axial rotation at the apex by 10.7° (95% CI = [9.4; 15]; $p < 0.001$); increase the T4–T12 kyphosis by 6.9° (95% CI = [2.3; 11.5]; $p = 0.005$); and achieved a mean gain in T1–T12 length of 6.4 mm (95% CI = [4.1; 8.7]; $p < 0.001$ and T1–L5 of 7.8 mm (95% CI = [5.5; 10.1]; $p < 0.001$).

3D barycentremetry assessment

The surgical procedure decreased the spinal axial torque at the upper end vertebra by 2.5 N/m (95% CI = [1.9; 3]; $p < 0.001$), at the apex by 0.6 N/m (95% CI = [0.4; 1]; $p = 0.004$), at the lower end vertebra by 2 N/m (95% CI = [1.5; 2.8]; $p < 0.001$). There was no statistical difference for spinal and barycentremetry parameters between the postoperative radiographic and the last follow-up ($p > 0.05$) (Table 2).

Correlation between spinal and 3D barycentremetry parameters

A correlation was found between the correction of spinal axial torque at the upper end vertebra and the correction of Cobb angle ($\rho = 0.4$; $p = 0.03$), the variation of kyphosis T4–T12 ($\rho = 0.6$; $p < 0.001$), the correction of hypokyphosis index ($\rho = 0.5$; $p = 0.04$), and the correction of the

vertebra axial rotation at the apex ($\rho = 0.5$; $p = 0.006$). Another correlation was found between the correction of spinal axial torque at the lower end vertebra and the variation of kyphosis T4–T12 ($\rho = 0.4$; $p = 0.03$), the decrease in the torsion index ($\rho = 0.5$; $p = 0.003$) and the intervertebral axial rotation in the lower end vertebra ($\rho = 0.4$; $p = 0.03$).

Postoperative barycentremetry parameters in scoliotics compared to a reference corridor

The percentage of patients outside the reference corridor preoperative and postoperative is shown in Table 3. The percentage of patients whose preoperative values were outside the reference corridor and then inside after the surgical procedure was 38% for spinal axial torque at the upper end vertebra (OR = 0.06; $p < 0.001$) and 52% at the lower extremity vertebra (OR = 0.07; $p < 0.00001$).

Discussion

The advent of 3D reconstruction has made it possible to focus on the correction obtained in the axial planes with the analysis of parameters such as the intervertebral rotation or axial rotation of the vertebra. These are the parameters derived from direct 3D reconstruction of the bone column. But what about the distribution of the body masses? How does the vertebra, the trunk, the waist behave in relation to the center of gravity following a bone correction? Recently, J. Dubousset reported that the objective of a scoliotic deformity surgery was to obtain a harmony, from head to

Table 2 Preoperative, postoperative, and last follow-up for spine spinal axial torque values.

	Preoperative	Postoperative	Last follow-up	p value ¹	p value ²
Upper end vertebra (N/m)	4 (2) [1;9]	2 (1) [0.1;4]	2 (1) [0.3;3]	<0.001*	0.2
Apex (N/m)	1 (1) [0.1;6]	1 (1) [0.03;4]	1 ± 1 [0.02;4]	0.004*	0.6
Lower end vertebra (N/m)	3 (1) [0.3;7]	1 (1) [0.01;2]	1 (1) [0.04;2]	<0.001*	0.1

Results are presented by means (SD) [range]. p value¹ refers to the analysis of preoperative and postoperative data while p value² refers to postoperative and final follow-up data. Significant p values are shown by an asterisk*

Table 3 Percentage of patient outside the reference corridor for the spinal axial torque parameters

	Preoperative (%)	Postoperative (%)	Odds ratio [CI 95%]	p value
Upper end vertebra (N/m)	100	62	0.06 [0.001; 0.5]	<0.001*
Apex (N/m)	45	24	0.4 [0.1; 1.4]	0.2
Lower end vertebra (N/m)	90	38	0.07 [0.01; 0.3]	<0.00001*

Significant p values are shown by an asterisk*

toe, of both the external envelope and the 3D bone balance [14]. Balance describes an equilibrium in each plane; it is called sagittal balance when considering thoracic kyphosis, cervical and lumbar lordosis, and pelvic parameters; it is called coronal balance when assessing the balance of the shoulders, the waist, the Cobb angle of a curve. In the axial plane, rotation of the vertebrae is usually considered relative to the pelvic. However, harmony includes the analysis of balance but also of the distribution of masses, in other words the center of gravity and the 3D external shape of the whole body. A preliminary study evaluated parameters derived from the external shape reconstruction, which has been previously validated in a population of healthy subjects and scoliotic patients [3]. These markers reflect the displacement and distribution of body masses and constitute an original and modern approach to 3D spinal deformation. In turn, these masses represent the static loads which are applied to the spine in load-bearing position. Previous studies [15, 16] have focused on external torso asymmetry using a surface topography device. Gardner et al. [16] concluded that surgical correction of the spine did not systematically lead to a symmetric torso. According to the authors, there were yet undefined factors that would lead to greater postoperative torso symmetry. Barycentremetry was initially proposed by Duval Beaupère et al. [17] with a gamma rays scanner. However, it was in lying position. More recently, Skalli and her team proposed barycentremetry from the biplanar radiographs taking advantage of external shape 3D reconstruction [8] and density models [13]. To our knowledge, there are no studies on the postoperative evaluation of external shape analysis and barycentremetry from low-dose biplanar radiographs used in daily clinical practice.

The first important finding is that spinal axial torque, at all three levels studied, were significantly improved by the surgical correction (Figs. 2 and 3). The uncertainty of these measurements had been measured in a previous study [3] and did not exceed 0.5 N/m. Taking this uncertainty into account, the markers were still modified after surgery. The posteromedial multisegmented translation induced a displacement of the apical vertebra and of the upper and lower boundary, which in turn helped decrease spinal axial torque. The question remains as to which component (sagittal tilt, lateral displacement) and to what extent the translational technique allowed this change. In addition, this procedure also brought the center of mass closer to the apical and the lower boundary to the line of HA vertical axis [2].

The second outcome is the correlation between the spinal axial torque at the upper and lower boundary with spinal parameters from 3D bone reconstruction. This confirms that the decrease, following surgery, of the axial torque at the upper level is related to a correction of the anomalies of the frontal plane (translated by a decrease of the Cobb angle), sagittal plane (translated by an increase of the T4–T12

kyphosis, an improvement of the hypokyphosis index) but also of the axial plane (translated by a decrease of the vertebra axial rotation at the apical). As far as the lower levels are concerned, the decrease in the axial torque is linked to an improvement in the thoracic kyphosis but also to a decrease in the torsion index and the intervertebral rotation at the lower boundary. The fact that the axial rotation of the apical vertebra correlates with the decrease of the axial torque at the superior level and that the decrease of the torsion index improves the axial torque at the inferior level reflects the importance of considering the correction of the axial plane of curvature in its entirety and not at a single level. These different correlations between the displacements in the three planes reinforce the idea, demonstrated by some authors [18, 19], that the analysis of the axial plane should be included in the initial and final evaluation of a treatment.

The third important point is that the surgical procedure allowed for several patients (outside the reference corridor in preoperative) to achieve postoperative values within this corridor and statistically significant for the axial torque at the upper (38% of patients) and lower (52% of patients) boundary. It should be noted that the reference corridor was calculated in a population of subjects with an average age of 21 years (from 10 to 31 years) without a history of spinal pathology [3]. The basal state of barycentremetry in scoliotic patients is not known and probably each patient has his own characteristics. The aim in future studies would be to find a body harmony of the mass displacement resulting from the 3D surgical correction rather than trying to bring the values of these parameters into a reference corridor. Finally, one of the clinical applications of this barycentric assessment is to understand possible mechanical complications (such as proximal junctional kyphosis or adding-on phenomena below the instrumented lower level) and long-term outcome. Considering these parameters, the distribution of the different forces and moments applied above and below the arthrodesis can be assessed; in particular, this study focused on the axial torque applied to the vertebra, but the vertebra is subjected to six forces and moments in three main directions, which could be relevant to study mechanical complications. Recently, Kim et al. reported in a population of 199 adults operated on for spinal deformity that postoperative assessment of odontoid-hip alignment (by measuring the OD-HA) was predictive of mechanical complications [20].

This study has some limitations. It is a barycentremetry assessment in static positions, and the effect of the dynamic proprioceptive system on the compressive forces or the center of gravity was not investigated, although it has been established that the dynamic proprioceptive system is affected in patients with idiopathic scoliosis [21]. The second limitation is the small number of patients included with no difference between the different curvature locations. Another limitation is our data measurement.

By convention, we measure the thoracic kyphosis between the upper T4 and the lower T12 plates on the profile radiograph. The T4 vertebra is easily identifiable on the biplanar radiograph, while the vertebrae above are harder to distinguish by overlapping the arms. However, in Lenke's classification, the measurement of thoracic kyphosis corresponds to the angle T5–T12. Finally, this study did not evaluate quality of life scores and especially self-evaluation of postoperative physical appearance. It would be important to carry out this study to verify whether the assessment of the external envelope correction by this analytical method brings satisfaction to the patients. In other words, to know if patients whose postoperative values are outside the reference corridor have a worse clinical evolution. Since postoperative improvement of quality of life is related to the correction of kyphosis and axial rotation [22], and the postoperative correction of these parameters is related to spinal torque, we hypothesize that the latter should also be related to changes in quality of life.

Conclusion

The 3D assessment of the barycenter after surgery to correct adolescent idiopathic scoliosis is promising. This is achieved by 3D reconstruction of the external envelope from low-dose biplanar radiographs. Results of this study confirm that AIS patients show abnormally high spinal axial torque, especially at the end vertebrae, and that this parameter is normalized postoperatively for only a small number of patients. Further studies should focus on the relationship between this parameter and the development of postoperative mechanical complications.

Author contributions TL, WS, JD, CV: conception or design. TL, XdC, NM, SG: acquisition, analysis or interpretation of data. TL, CV: statistical analysis. TL, WS, XdC, NM, SG, LG, RV, JD, CV: draft or revised the work. TL, WS, XdC, NM, SG, LG, RV, JD, CV: approved final version.

Funding This study has received funding from the BiomecAM chair program on subject-specific musculoskeletal modeling (with the support of ParisTech and Yves Cotrel Foundations, Société Générale, Covea, and Proteor).

Data availability The datasets generated and analyzed during the current study are available from the corresponding author on reasonable request.

Declarations

Conflict of interest The authors did not receive support from any organization for the submitted work. Wafa Skalli has a patent related to biplanar X-rays and associated 3D reconstruction methods, with no personal financial benefit (royalties rewarded for research and educa-

tion) licensed to EOS Imaging. Raphael Vialle reports personal fees and grants (unrelated to this study) from Stryker. The other authors of this manuscript declare no relationships with any companies, whose products or services may be related to the subject matter of the article.

Ethical approval Institutional Review Board approval was obtained.

Informed consent This was a retrospective study. Parents and children were informed about the protocol and consented to participate.

References

1. Courvoisier A, Drevelle X, Dubouset J, Skalli W (2013) Transverse plane 3D analysis of mild scoliosis. *Eur Spine J* 22:2427–2432. <https://doi.org/10.1007/s00586-013-2862-x>
2. Thenard T, Vergari C, Hernandez T et al (2019) Analysis of center of mass and gravity-induced vertebral axial torque on the scoliotic spine by barycentrometry. *Spine Deform* 7:525–532. <https://doi.org/10.1016/j.jspd.2018.11.007>
3. Langlais T, Vergari C, Rougereau G et al (2021) Balance, barycentrometry and external shape analysis in idiopathic scoliosis: What can the physician expect from it? *Med Eng Phys* 94:33–40. <https://doi.org/10.1016/j.medengphy.2021.06.004>
4. Lenke LG, Betz RR, Clements D et al (2002) Curve prevalence of a new classification of operative adolescent idiopathic scoliosis: does classification correlate with treatment? *Spine* 27:604–611. <https://doi.org/10.1097/00007632-200203150-00008>
5. Lamerain M, Bachy M, Dubory A et al (2017) All-pedicle screw fixation with 6-mm-diameter cobalt-chromium rods provides optimized sagittal correction of adolescent idiopathic scoliosis. *Clin Spine Surg* 30:E857–E863. <https://doi.org/10.1097/BSD.0000000000000413>
6. Dubouset J, Charpak G, Dorion I et al (2005) A new 2D and 3D imaging approach to musculoskeletal physiology and pathology with low-dose radiation and the standing position: the EOS system. *Bull Acad Natl Med* 189:287–297 (**discussion 297–300**)
7. Faro FD, Marks MC, Pawelek J, Newton PO (2004) Evaluation of a functional position for lateral radiograph acquisition in adolescent idiopathic scoliosis. *Spine* 29:2284–2289. <https://doi.org/10.1097/01.brs.0000142224.46796.a7>
8. Gajny L, Ebrahimi S, Vergari C et al (2019) Quasi-automatic 3D reconstruction of the full spine from low-dose biplanar X-rays based on statistical inferences and image analysis. *Eur Spine J* 28:658–664. <https://doi.org/10.1007/s00586-018-5807-6>
9. Amabile C, Pillet H, Lafage V et al (2016) A new quasi-invariant parameter characterizing the postural alignment of young asymptomatic adults. *Eur Spine J* 25:3666–3674. <https://doi.org/10.1007/s00586-016-4552-y>
10. Steib J-P, Dumas R, Mitton D, Skalli W (2004) Surgical correction of scoliosis by in situ contouring: a detorsion analysis. *Spine* 29:193–199. <https://doi.org/10.1097/01.BRS.0000107233.99835.A4>
11. Skalli W, Vergari C, Ebermeyer E et al (2017) Early detection of progressive adolescent idiopathic scoliosis: a severity index. *Spine* 42:823–830. <https://doi.org/10.1097/BRS.0000000000001961>
12. Langlais T, Vergari C, Xavier F et al (2022) 3D quasi-automatic spine length assessment using low dose biplanar radiography after surgical correction in thoracic idiopathic scoliosis. *Med Eng Phys* 99:103735. <https://doi.org/10.1016/j.medengphy.2021.103735>
13. Amabile C, Choïne J, Nérot A et al (2016) Determination of a new uniform thorax density representative of the living

- population from 3D external body shape modeling. *J Biomech* 49:1162–1169. <https://doi.org/10.1016/j.jbiomech.2016.03.006>
14. Dubousset J (2020) Past, present, and future in pediatric spinal surgery. *Ann Transl Med* 8:36. <https://doi.org/10.21037/atm.2019.08.13>
 15. Gorton GE, Young ML, Masso PD (2012) Accuracy, reliability, and validity of a 3-dimensional scanner for assessing torso shape in idiopathic scoliosis. *Spine* 37:957–965. <https://doi.org/10.1097/BRS.0b013e31823a012e>
 16. Gardner A, Berryman F, Pynsent P (2021) The use of statistical modelling to identify important parameters for the shape of the torso following surgery for adolescent idiopathic scoliosis. *J Anat* 239:602–610. <https://doi.org/10.1111/joa.13454>
 17. Duval-Beaupère G, Robain G (1987) Visualization on full spine radiographs of the anatomical connections of the centres of the segmental body mass supported by each vertebra and measured in vivo. *Int Orthop* 11:261–269. <https://doi.org/10.1007/BF00271459>
 18. Schlösser TPC, van Stralen M, Brink RC et al (2014) Three-dimensional characterization of torsion and asymmetry of the intervertebral discs versus vertebral bodies in adolescent idiopathic scoliosis. *Spine* 39:E1159–1166. <https://doi.org/10.1097/BRS.0000000000000467>
 19. Illés TS, Lavaste F, Dubousset JF (2019) The third dimension of scoliosis: the forgotten axial plane. *Orthop Traumatol Surg Res* 105:351–359. <https://doi.org/10.1016/j.otsr.2018.10.021>
 20. Kim KR, Le Huec JC, Jang HJ et al (2021) Which is more predictive value for mechanical complications: fixed thoracolumbar alignment (T1 pelvic angle) versus dynamic global balance parameter (odontoid-hip axis angle). *Neurospine* 18:597–607. <https://doi.org/10.14245/ns.2142452.226>
 21. Assaiante C, Mallau S, Jouve J-L et al (2012) Do adolescent idiopathic scoliosis (ais) neglect proprioceptive information in sensory integration of postural control? *PLoS One* 7:e40646. <https://doi.org/10.1371/journal.pone.0040646>
 22. Ohashi M, Bastrom TP, Bartley CE et al (2020) Associations between three-dimensional measurements of the spinal deformity and preoperative SRS-22 scores in patients undergoing surgery for major thoracic adolescent idiopathic scoliosis. *Spine Deform* 8:1253–1260. <https://doi.org/10.1007/s43390-020-00150-0>

Publisher's Note Springer Nature remains neutral with regard to jurisdictional claims in published maps and institutional affiliations.

Springer Nature or its licensor (e.g. a society or other partner) holds exclusive rights to this article under a publishing agreement with the author(s) or other rightsholder(s); author self-archiving of the accepted manuscript version of this article is solely governed by the terms of such publishing agreement and applicable law.