



**HAL**  
open science

# The Usefulness of Postoperative Tranexamic Acid in Primary Breast Augmentation with Implants

Mathilde ML Lehelley, Y G Youssef Gam, Thomas Colson

► **To cite this version:**

Mathilde ML Lehelley, Y G Youssef Gam, Thomas Colson. The Usefulness of Postoperative Tranexamic Acid in Primary Breast Augmentation with Implants. *Asian Journal of Research in Surgery*, 2024, 7, pp.72-83. hal-04557011

**HAL Id: hal-04557011**

**<https://hal.science/hal-04557011>**

Submitted on 23 Apr 2024

**HAL** is a multi-disciplinary open access archive for the deposit and dissemination of scientific research documents, whether they are published or not. The documents may come from teaching and research institutions in France or abroad, or from public or private research centers.

L'archive ouverte pluridisciplinaire **HAL**, est destinée au dépôt et à la diffusion de documents scientifiques de niveau recherche, publiés ou non, émanant des établissements d'enseignement et de recherche français ou étrangers, des laboratoires publics ou privés.



Distributed under a Creative Commons Attribution - NonCommercial 4.0 International License



# The Usefulness of Postoperative Tranexamic Acid in Primary Breast Augmentation with Implants

M.L. Mathilde Lehelley <sup>a</sup>, Y.G. Youssef Gam <sup>a</sup>  
and T.C. Thomas Colson <sup>a\*</sup>

<sup>a</sup> *Department: Hospital NOVO, 6-avenue de l'île de France, 95300 Pontoise, France.*

## **Authors' contributions**

*This work was carried out in collaboration among all authors. Author ML designed the study, performed the statistical analysis, wrote the protocol, and first draft of the manuscript. Author YG managed the analyses of the study. Author TC managed the literature searches. All authors read and approved the final manuscript.*

## **Article Information**

### **Open Peer Review History:**

This journal follows the Advanced Open Peer Review policy. Identity of the Reviewers, Editor(s) and additional Reviewers, peer review comments, different versions of the manuscript, comments of the editors, etc are available here: <https://www.sdiarticle5.com/review-history/115128>

**Original Research Article**

**Received: 09/02/2024**  
**Accepted: 13/04/2024**  
**Published: 18/04/2024**

## **ABSTRACT**

**Aims:** Tranexamic acid, an anti-fibrinolytic agent, is being widely used surgery because of its effect on blood loss decrease. However, few articles have analyzed its use in plastic surgery.

The aim of this study was to investigate the impact of oral administration of tranexamic acid on postoperative drainage volumes following primary breast augmentation.

**Methodology:** A total of 60 patients were included in this case-control study over a period of 17 months. Patients were divided into two equal groups. The case group received 2 g of oral tranexamic acid per day while the control group received no treatment. A record of the main data (study population characteristics, location and type of implant, duration of surgery, mean arterial pressure at surgery, volume in the drains, length of hospital stay and complications) was made.

\*Corresponding author: E-mail: [rabie.93@hotmail.fr](mailto:rabie.93@hotmail.fr);

**Results:** Oral administration of tranexamic acid significantly reduced drain volumes by 20% at day 1 (40 mL in the control group versus 30 mL in the case group/ $p < 0.0001$ ) and increased the number of patients discharged at day 1 by 44% (43% in the control group versus 87% in the case group). There were no treatment-related side effects. The two groups were comparable in terms of age, implant placement and perioperative blood pressure. At the last follow up, there was no significant difference in terms of periprosthetic capsular contracture.

**Conclusion:** Oral administration of TXA is a major contribution to therapies to reduce post-operative bleeding and probably the length of hospital stay.

*Keywords: Tranexamic acid; breast augmentation; implant.*

## 1. INTRODUCTION

Prosthesis breast augmentation is one of the most common operations performed in plastic surgery. Intra- and postoperative bleeding can lead to complications such as haematomas, implant's infection, and delayed exposure of the implant, leading to repeat visits to the operating theatre. These complications lead to additional risk for the patient and additional costs, with new hospital admissions and repeat administrations of general anaesthesia [1, 2]. In addition, breast augmentation surgery is not particularly incapacitating, but the drainage impairs the patient's movements and delays their discharge. It is therefore of interest to seek to minimise the volumes of the latter to allow rapid removal of the suction drain and thereby the patient's discharge from hospital [3, 4].

Tranexamic acid is an antifibrinolytic. It blocks the lysine receptor on plasminogen, which prevents the activation of plasminogen into plasmin [5]. Tranexamic acid has been primarily used in cardiac, orthopaedic, and trauma surgery. Its usage has remarkably increased including oral surgery, gynaecology and gastroenterology [6].

However, relatively few articles have focused on the interest of using it in plastic surgery.

The aim of this study was to investigate whether oral administration of tranexamic acid reduced drainage volumes after primary breast augmentation with implants.

A secondary, delayed complication of implants is the formation of a peri-prosthetic capsular contracture. This peri-prosthetic contracture can result in breast deformity and pain [7-10]. The result then becomes unsightly. Implant replacement with capsulectomy is the standard treatment. Spear et al. [11] established Baker's classification to define the different stages of this capsular retraction. Handel et al. [12] have shown a link between early postoperative peri-

prosthetic haematoma and the development of peri-prosthetic contractile capsules. We therefore contacted the patients' months to years later to see if the patients who had had tranexamic acid had fewer cases of capsular contracture than the control patients.

## 2. MATERIALS AND METHODS

We performed a retrospective study starting from November 2014 to April 2016.

We included patients aged from 18 to 50 years old, who presented to our department for primary bilateral breast augmentation using prostheses. We excluded from the study patients with a history of venous thromboembolism, those taking anticoagulants or platelet aggregation inhibitors, those with severe co-morbidities (ASA III-IV), those with contraindications to the administration of tranexamic acid, those for whom the implants were placed above the pectoralis muscles, and those for whom we also performed a mastopexy. For each patient, we recorded their gender, age, type of implant inserted (anatomical or round shape), the texture of the implant (smooth or textured), the size of the implant, the surgical incision (sub-mammary or peri-areolar), the operating time (in minutes), the average blood pressure during surgery (in mmHg), the drainage volumes (in millilitres) per side and per day without recording the colour or consistency and the length of hospital stay (in days). Complications were also noted (haematoma, infection, early exposure of the implant, pulmonary embolism, phlebitis, anaphylactic reaction). All early (less than seven days) and delayed (less than thirty days) postoperative complications were also recorded. All side effects associated with treatment with Spotof® have also been listed.

A total of 60 patients were included in this retrospective cohort study. Participants were divided into two equal groups. The use of

tranexamic acid is not yet standardised in breast augmentation. We therefore followed the recommendations of one gram twice a day, starting immediately after the end of the surgery, to avoid any adverse effects. The treated patients therefore received 2 grams of Spotof® (C.C.D laboratory, Portugal) oral solution per day for the first three days postoperatively, while the other patients received no equivalent treatment.

Four surgeons participated in this study. The operations were all carried out at the same hospital. Two operators performed the surgeries. Each surgeon operated on one side of the patient. At the end of the surgery, a suction drain was placed in the retropectoral space of each breast, and a compressive garment was applied to the surgical site before discharge from the operating room. The surgical dressing was removed the day after the operation. The patients all received oral analgesics according to the hospital's protocols, and did not receive thromboprophylaxis according to the recommendations of the French Society of Anaesthesia and Intensive Care Medicine (SFAR). During their stay in the hospital, patients received a visit from a nurse every four hours after leaving the recovery room. Drainage volumes were recorded every 24 hours in the morning. The drain was removed if the volume was less than 40cc per 24 hours, in accordance with the department protocol. Patients were free to leave after both drainage tubes were removed. All patients were seen in consultation at seven days and at two months after surgery, in accordance with the department protocol. Patients were given a telephone number, which could be called at any time of the day, to deal with any complications promptly.

Patients were contacted again between March and April 2022. We attempted to contact all patients by email or phone. If our first attempt was not successful, we made two further attempts to contact them. Patients then answered our questions in-person or by phone. We looked for the presence of a capsular contracture, a breast asymmetry and a surgical second-look since primary breast augmentation. We also took pictures of the patients who came in person to the follow-up consultation.

Quantitative variables are presented with their median (interquartile range) [minimum-

maximum]; they were compared between groups with the Wilcoxon test. Qualitative variables are presented with numbers (percentages); they were compared between groups with Fischer's exact test. The proportion of 40mL drainage volume  $\leq$  at D1 postoperatively was estimated per breast and per patient (40mL  $\leq$  volume, i.e. removal of suction drain for both breasts). Similarly, the volume of drainage at D1 and D1-2 (for patients with a suction drain at D2) was estimated per breast and per patient.

The proportion of 40mL drainage volume  $\leq$  at D1 and the drainage volumes per breast were compared as a function of TXA treatment using generalised linear mixed models with random effects on patient and surgeon (4 surgeons participated in the study). The proportion of patients whose 2 drainage tubes were removed on Day 1 (2 drainage volumes of  $\leq$  40 mL on Day 1) and drainage volumes per patient (bilateral volume) were compared according to treatment with TXA using Wilcoxon tests. A linear regression model was then used to look for predictors of bleeding. This linear regression model made it possible to explore the factors associated with response after a bivariate scan. This scan selected as a possible factor those with a significant response at  $p=0.25$ . A search for the best model was then carried out using a top-down step-by-step approach evaluated by the Akaike information criterion. All tests were two-tailed, and a significance level below 5% was considered to indicate a significant association.

The statistical analysis was carried out using the software R [13] & various packages, in particular, tidyverse [14], FactoMineR [15] & baseph [16].

This study was authorised and registered with the FDA, ClinicalTrials.gov Identifier: NCT03364569.

### 3. RESULTS

The study included 60 patients; 30 of them received tranexamic acid (TXA) and 30 did not. The study population was homogeneous in age, implant type, surgical approach, surgeon, blood pressure during surgery and operative time (Table 1). Drainage volumes between the two groups were compared. (Table 2). Drainage volumes were lower in the treated patients compared to the untreated patients on D1 and on D1-2.

**Table 1. Characteristics of the study population**

Variable	Total	No TXA	TXA	P
Total	60	30(50)	30(50)	
Age (years)	30 (25 to 37) [19 to 54]	30 (27 to 36) [19 to 52]	32 (23 to 38) [20 to 54]	0.78
Shape of implants				1
Round	55 (92)	27 (90)	28 (93)	
Anatomic	5 (8)	3 (10)	2 (7)	
<b>Texture of implants</b>				0,75
Smooth	12 (20)	5 (17)	7 (23)	
Textured	48 (80)	25 (83)	23 (77)	
<b>Surgical Pocket</b>				
Retro-pectoral	60 (100)	30 (100)	30 (100)	
<b>Surgeons</b>				1
1	16 (27)	8 (27)	8 (27)	
2	13 (22)	6 (20)	7 (23)	
3	16 (27)	8 (27)	8 (27)	
4	15 (25)	8 (27)	7 (23)	
<b>Surgical Approach</b>				1
Periareolar incision	31 (52)	16 (53)	15 (50)	
Inframammary incision	29 (48)	14 (47)	15 (50)	
Surgical time (min)	142 (131 to 170) [91 to 260]	140 (131 to 174) [91 to 258]	145 (134 to 160) [110 to 260]	0,67
Mean blood Pressure (mmHg)	67 (63 to 71) [52 to 90]	68 (61 to 72) [52 to 79]	66 (64 to 71) [61 to 90]	0,99
<b>Hospital Stays (Days)</b>				0,003
1	36 (60)	13 (43)	23 (77)	
2	13 (22)	7 (23)	6 (20)	
3	10 (17)	9 (30)	1 (3)	
6	1 (2)	1 (3)	0 (0)	
Hospital Stay > 1 day	24 (40)	17 (57)	7 (23)	0,017

**Table 2. Description of the drainage volumes**

Variables	Total	No TXA	TXA	P
Per breast				
Breast N=120	120	60	60	
Volume D1≤ 40mL	87(72)	32(53)	55(92)	0,003
Volume D1 (mL)	30 (20 to 46) [0 to 175]	40 (28 to 60) [10 to 175]	30 (20 to 30) [0 to 140]	< 0,0001
Volume D2 (mL)	100 (70 to 125) [55 to 200]	100 (74 to 125) [55 to 200]	70 (60 to 135) [60 to 180]	0,22
Per patient				
Patients N= 60	60	30	30	
Volume D1≤ 40mL bilateral	39 (65)	13(43)	26(87)	0,0009
Volume D1 (mL)	60 (44 to 91) [10 to 255]	75 (52 to 110) [30 to 255]	52 (32 to 65) [10 to 180]	0,001
Volume D2 (mL)	135 (100 to 210) [60 to 325]	145 (100 to 230) [70 to 325]	132 (112 to 146) [60 to 180]	0,47

Statistically significantly, the number of suction drains with a volume of less than 40mL at D1 was higher in the TXA group: 92% (P<0.05). There was therefore more redon drain removal at D1 in this group (Fig. 1). Consequently, the number of patients discharged at D1 was 26 or 87% in the TXA group, whereas it was only 13 or 43% in the noTXA group. The two redon drains were therefore removed earlier in the treated patients. This difference was also statistically significant (P<0.00009) (Fig. 2).

Finally, the plot (Fig. 3) shows the cumulative drain volumes in patients according to TXA treatment. As seen previously, drainage volumes were significantly lower in TXA patients.

The question could have been raised as to whether there was an intercurrent factor explaining the difference in drainage volume and therefore bleeding. We carried out a monovariate analysis with its various factors. The results are

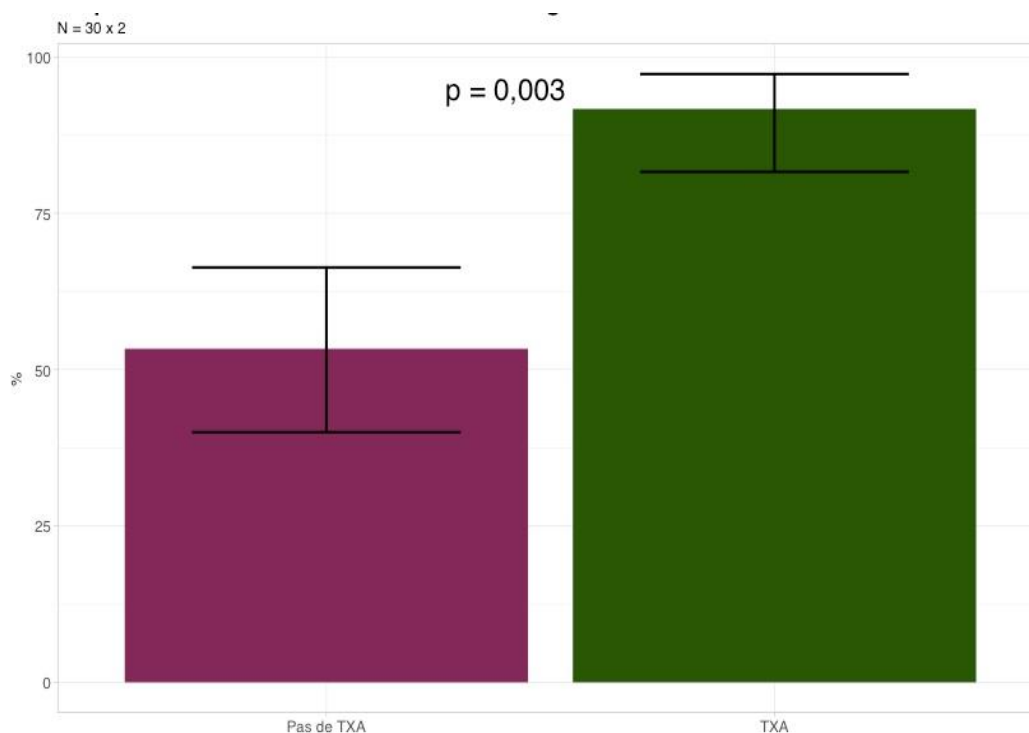
presented in table 3. Only the duration of the operation seemed to influence the volume of drainage in the suction drains. Indeed, the longer the operating time, the greater the drainage volumes (Fig. 4).

Finally, 27 patients were successfully re-contacted in the second phase of our study.

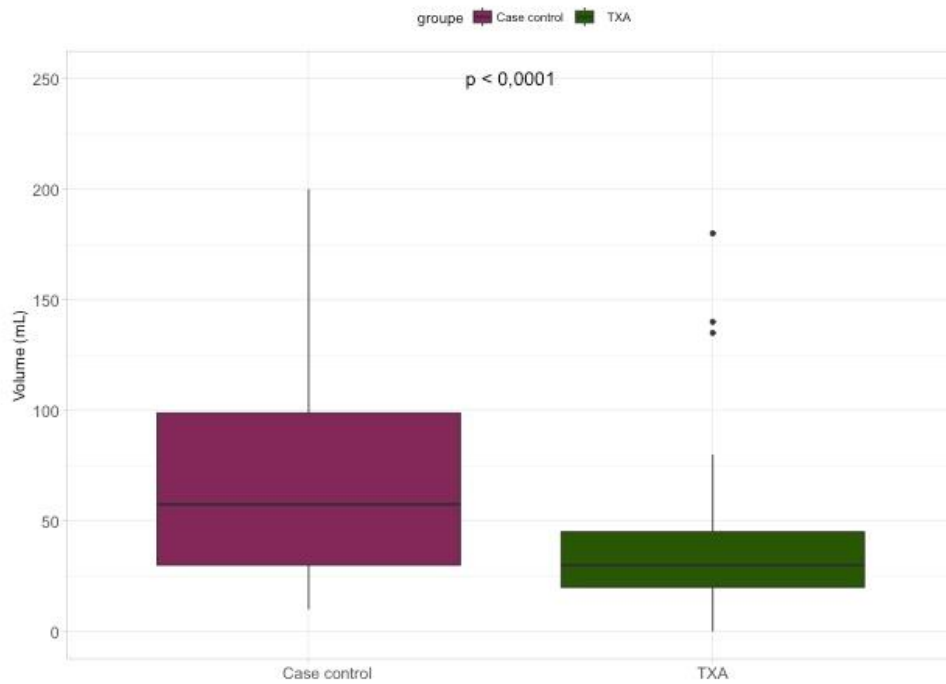
One patient was unable to answer questions about capsular contracture and asymmetry correctly over the phone.

In total, we found no significant difference between the two groups for the number of periprosthetic retractile capsule, surgical second-look or implant replacement and breast asymmetry. The prosthesis changes were caused by a capsular contracture and an implant malposition. Fig. 5 and 6 show pre and post operative photos of two patients.

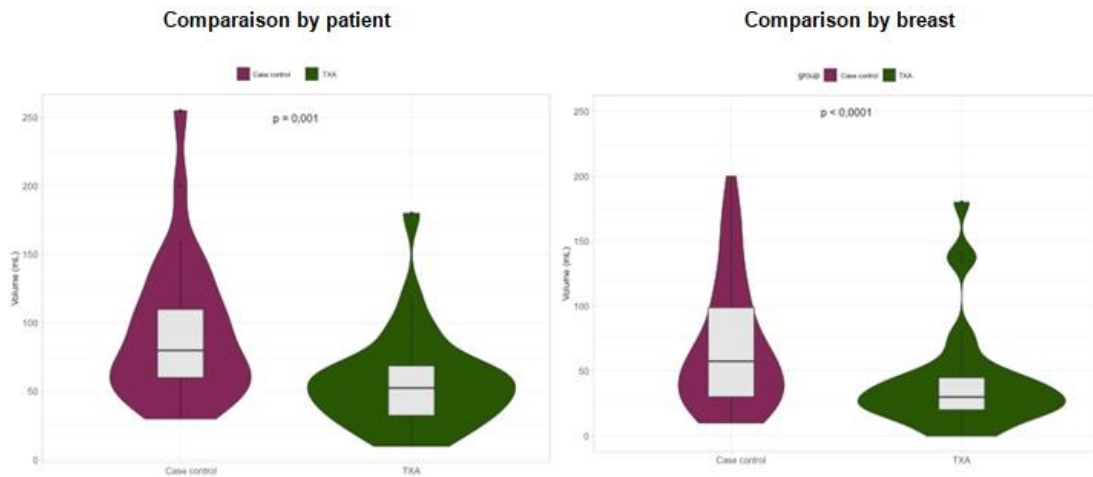
During our study, there were no complications in the entire study population.



**Fig. 1. Proportion of breasts with a drainage volume ≤ 40mL at D1 post-op (N=60\*2)**



**Fig. 2. Proportion of patients with both drainage volumes (left and right breasts)  $\leq$  40mL at D1 post-op (N=30\*2)**



**Fig. 3. Comparison of drainage volumes according to TXA treatment, at D1 postoperatively, per breast and per patient**

**Table 3. Bleeding factor – Monovariate Analysis**

	p-value
Groupe	0.023
Age (years)	0.35
Implant volume Right (cc)	0.224
Implant volume Left (cc)	0.152
Implant Shape	0.602
Implant Texture	0.587
Surgical Time	0.017
Mean Operative Blood Pressure (mmHg)	0.165

Note: factorial variables: t.test; numerical variables: correlation test

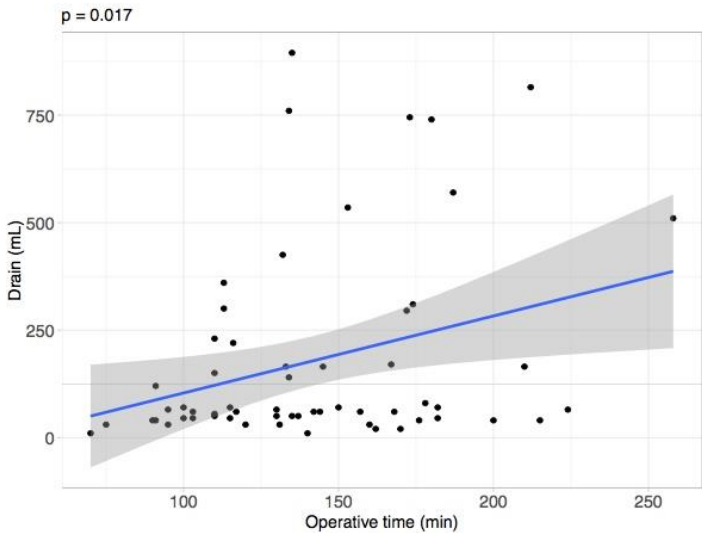
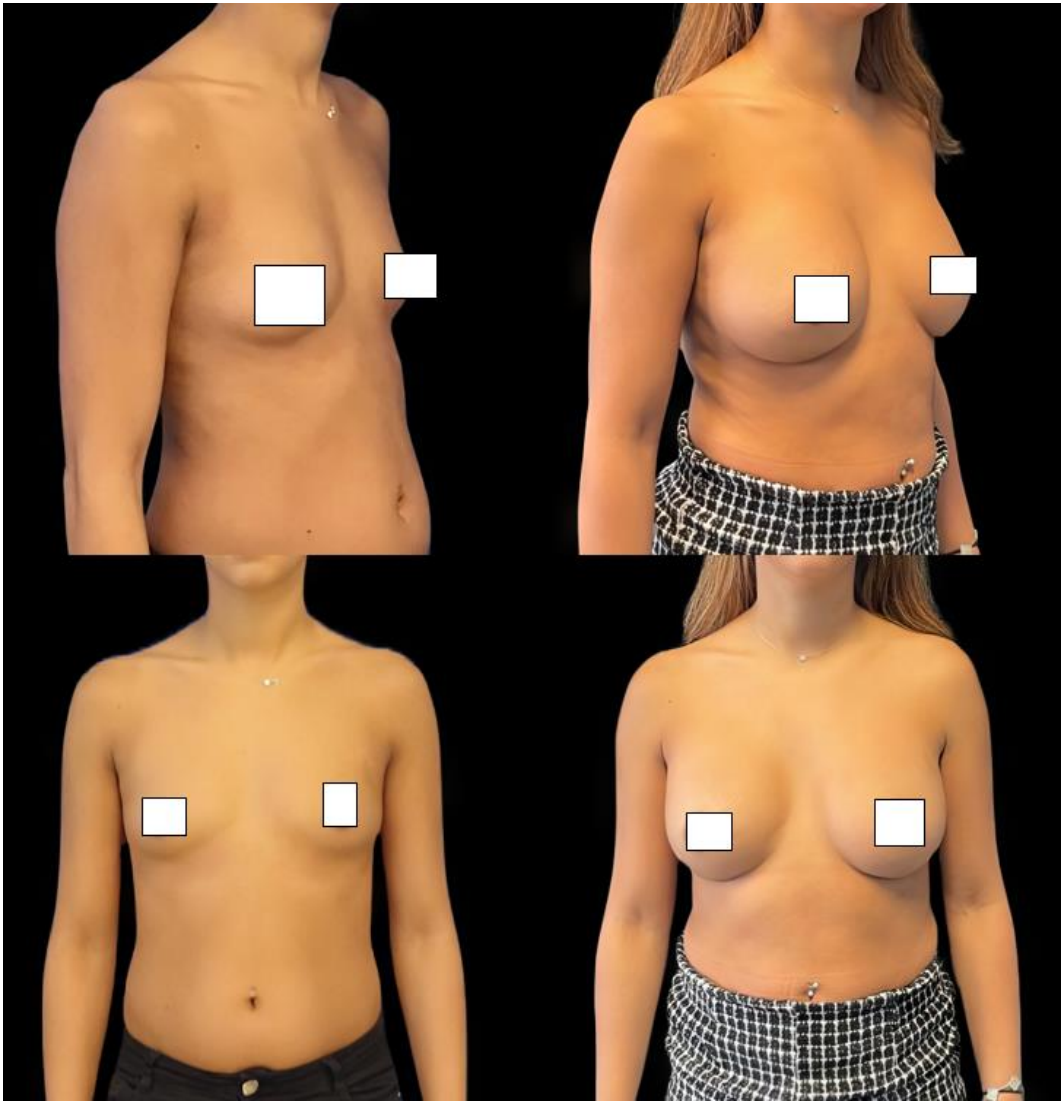
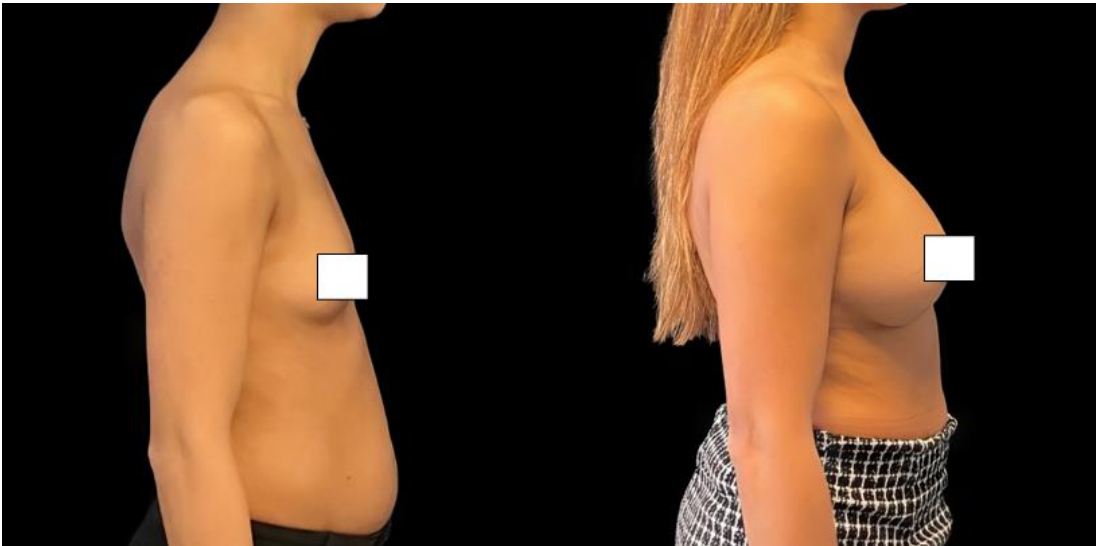


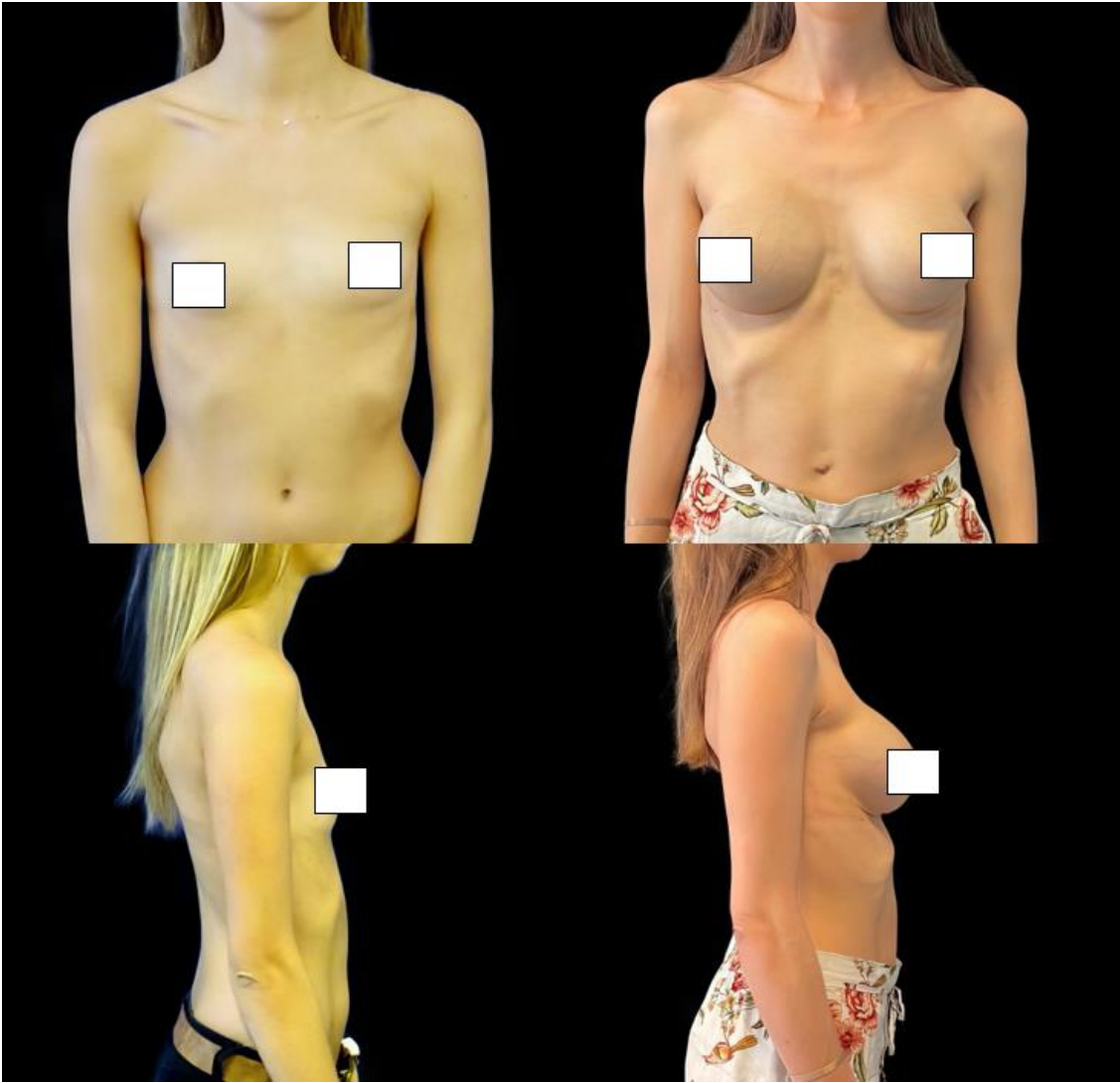
Fig. 4. Operating time and drainage volume

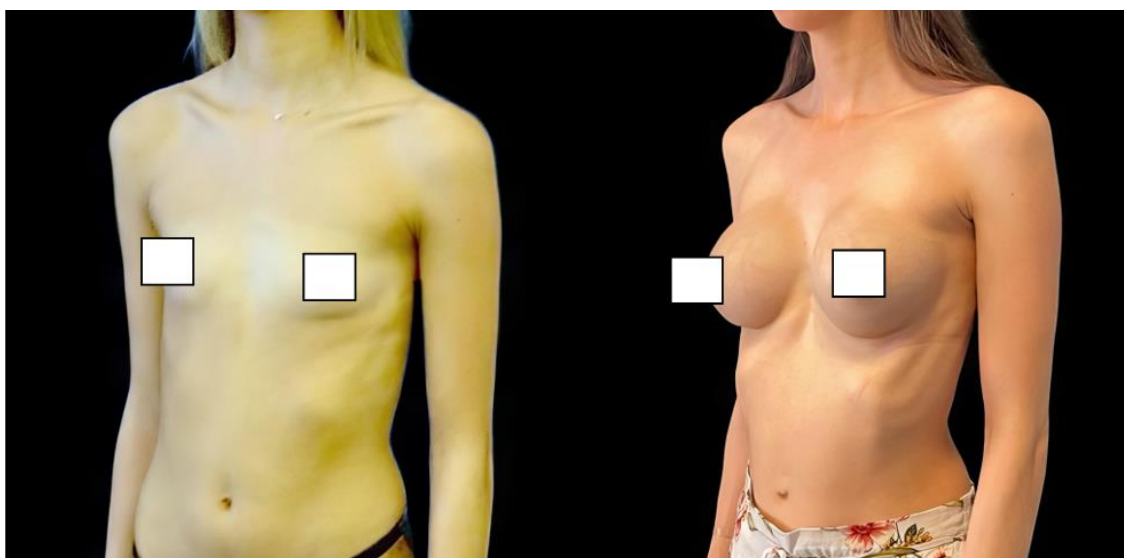






**Fig. 5. Pre et post operative photos of patient treated with tranexamic acid, post operative photo were tacken at 7 years old**





**Fig. 6. Pre et post operative photos of patient treated without tranexamic acid, post operative photo were taken at 7 years old**

#### 4. DISCUSSION

Tranexamic acid in surgery was mainly used for patients treated with anticoagulants [17]. Subsequently, it found many indications in the management of post-traumatic haemorrhages [18], and cardiac and orthopaedic surgery [19]. These applications are expanding, as there is considerable research into its usefulness in the perioperative management of blood loss. For example, it has been shown that its use in perioperative settings reduces blood loss by 34% [20], with small differences depending on the type of surgery and the way the drug is administered. A systematic review of the literature also found that TXA decreased the likelihood of patients requiring transfusion by 38% [21].

Tranexamic acid is increasingly being used in cosmetic and functional surgery. In rhinoplasty, its indication has been proven by two meta-analyses [22,23]. They showed a reduction in perioperative bleeding, postoperative oedema and ecchymosis. In breast surgery, Ausen [24] used TXA-soaked compresses on perioperative breast reduction surgery. There was a 39% decrease in blood loss in the suction drains at 24 hours post-surgery. The clear benefit of tranexamic acid has recently been summarised in an article in Rohrich [25].

In our study, we showed a 20% decrease in drainage volumes at D1, as well as an increase in discharge at D1 in patients on TXA. Therefore,

it can be asserted that tranexamic acid reduces postoperative bleeding, and therefore reduces postoperative complications (haematomas, infections, etc.). Nevertheless, it is noted that there is no significant difference concerning the cumulative drainage volumes on D1–2. This can be explained by a lack of data. Indeed, in the TXA group, only 4 patients and 5 suction drains remained, compared to 17 patients and 28 drainage devices in the control group. If we look at the length of hospital stay of the patients, we can see that the maximum length of hospital stay for TXA patients is 3 days, whereas, in the other group, 10 patients were discharged between D3 and D6. Therefore, it can be accepted that drainage volumes remain greater than 40 mL for a longer period of time in untreated patients. However, the current trend is to maximise outpatient surgery. It could therefore be hypothesised that patients could be discharged with their drainage tubes and a prescription to remove the tubes if the volume is  $\leq 40$  mL. The problem remains unresolved as we are aware of the discomfort generated by the presence of drainage tubes in patients. In addition, the presence of a suction drain device at home often generates stress and discomfort for patients. Their early removal should therefore be considered an important goal prior to the hospital discharge.

One of the main limits of our study is the non-randomisation of the patients. Treatment should have been randomly defined to avoid selection bias. Indeed, nurses and surgeons, who collect

data of drainage volumes, were also the ones who delivered the treatment. Measurement bias cannot be excluded. Furthermore, a group with placebo treatment should have been included. However, our study focuses only on the placement of primary breast augmentations. There are no additional procedures such as capsulectomy or placement of an acellular dermal matrix (ADM). As known, these procedures can promote the production of seromas. It can therefore be concluded that the drainage volumes recorded are a good reflection of the postoperative blood located in the implant pockets.

We have chosen to carry out oral and postoperative administrations of tranexamic acid. It is interesting to note that the majority of study protocols on this molecule favour intravenous perioperative administrations. It is questionable whether intraoperative administration of tranexamic acid, more or less in combination with postoperative administration, would not have the same effects or even improve its effectiveness.

The incidence rate of peri-prosthetic contracture varies according to the studies between 2.8% and 20.4%, with a follow-up of between 10 and 15 years [26]. The link between capsular retraction and postoperative haematoma has been demonstrated by numerous studies. [27–29]. In these studies, the authors highlight the link between haematoma, inflammation, infection and contracture. There is an important role for TGF- $\beta$  inflammation factor in periprosthetic capsule thickening. Studies thus show an interest in limiting proinflammatory factors. Thus, there seems to be an interest in the use of a mechanical insertion device to limit infections. In our study, we had one case of capsular formation in the tranexamic acid group.

We chose to administer tranexamic acid orally. Various studies have shown favourable results on intravenous administration of tranexamic acid in reducing intraoperative and postoperative bleeding. [30–31] We could therefore question the interest of a combined intraoperative and postoperative intravenous administration for our primary breast augmentations.

Finally, the strength of our study is in the use of tranexamic acid in breast surgery since 2014. It would be interesting to try to contact patients again, 10 years after their first surgery.

## 5. CONCLUSION

Tranexamic acid is increasingly being used in surgery to limit intraoperative and postoperative bleeding. We have shown in this study that its administration in the immediate postoperative period significantly decreased the drainage volumes after breast augmentation with implants. There is therefore a benefit to its administration in reducing postoperative bleeding and related complications such as haematomas. In addition, there were no adverse reactions associated with the administration of tranexamic acid, corroborating its safety in this indication.

## CONSENT

All authors declare that 'written informed consent was obtained from the patient for publication of this case report and accompanying images

## ETHICAL APPROVAL

As per international standards or university standards written ethical approval has been collected and preserved by the author(s).

## COMPETING INTERESTS

Authors have declared that no competing interests exist.

## REFERENCES

1. Handel N, Jensen JA, Black Q, James R, Waisman, Silverstein MJ. The Fate of Breast Implants: A Critical Analysis of Complications and Outcomes. *Plastic and Reconstructive Surgery*. Dec 1995;96(7):1521-33.
2. Ajdic D, Zoghbi Y, Gerth D, Panthaki ZJ, Thaller S. The Relationship of Bacterial Biofilms and Capsular Contracture in Breast Implants. *Aesthet Surg J*. March 2016;36(3):297-309.
3. Ozdemir M, Leach GA, Kanapathy M, Mosahebi A, Reid CM. Keller Funnel Efficacy in "No Touch" Breast Augmentation and Reconstruction: A Systematic Review. *Plast Reconstr Surg Glob Open*. 2022;10(11):e4676.
4. Oliver JD, DeLoughery EP, Gupta N, Boczar D, Sisti A, Huayllani MT, et al. Local Pro- and Anti-Coagulation Therapy

- in the Plastic Surgical Patient: A Literature Review of the Evidence and Clinical Applications. *Medicina*.2019;55(5):208.
5. Dunn CJ, Goa KL. Tranexamic acid: A review of its use in surgery and other indications. *Drugs*. 1999;57:1005–1032.
  6. Dunn CJ, Goa KL. Tranexamic acid: a review of its use in surgery and other indications. *Drugs*. 1999;57(6):1005-32. DOI:10.2165/00003495-199957060-00017. PMID: 10400410.
  7. Dunn CJ, Goa KL. Tranexamic acid: A review of its use in surgery and other indications. *Drugs*. 1999;57(6):1005-32.
  8. Tang YMJ, Chapman TWL, Brooks P. Use of tranexamic acid to reduce bleeding in burns surgery. *J Plast Reconstr Aesthet Surg*. 2012;65(5):684-6.
  9. Cansancao AL, Condé-Green A, David JA, Cansancao B, Vidigal RA. Use of Tranexamic Acid to Reduce Blood Loss in Liposuction. *Plastic and Reconstructive Surgery*. 2018;141(5):1132-5.
  10. What is the evidence for tranexamic acid in Burns? - ScienceDirect [Internet]. [cited 8 Feb 2022]. Available: <https://www.sciencedirect.com/science/article/abs/pii/S0305417914001569?via%3Dihub>
  11. Spear SL, Baker JL. Classification of Capsular Contracture after Prosthetic Breast Reconstruction. *Plastic and Reconstructive Surgery*. 1995;6(5):1119-23; discussion 1124.
  12. Handel N, Jensen JA, Black Q, Waisman JR, Silverstein MJ. The fate of breast implants: a critical analysis of complications and outcomes. *Plast Reconstr Surg*. 1995; 96(0032-1052 (Print): 1521–33.
  13. R CORE TEAM. *R: A Language and Environment for Statistical Computing*. R Foundation for Statistical Computing. Vienna, Austria; 2022. Available: <https://www.R-project.org/>
  14. Hadley WICKHAM et al. "Welcome to the tidyverse". In: *Journal of Open Source Software*. 2019;4(43);1686. DOI: 10.21105/joss.01686.
  15. Sébastien LÊ, Julie JOSSE and François HUSSON. "FactoMineR: A Package for Multivariate Analysis". In: *Journal of Statistical Software*. 2008;25.(1):1–18. DOI: 10.18637/jss.v0 25.i01.
  16. Philippe MICHEL. *Baseph : un package pour les études cliniques simples (Baseph: a package for simple clinical studies)*. Pontoise, France, 2022. Available: <https://github.com/philippemichel/baseph>.
  17. Keiani Motlagh K, Loeb I, Legrand W, Daelemans P, Van Reck J. Prévention des saignements postopératoires chez des patients sous anticoagulants oraux. Effets de l'acide tranexamique [Prevention of postoperative bleeding in patients taking oral anticoagulants. Effects of tranexamic acid]. *Rev Stomatol Chir Maxillofac*. 2003;104(2):77-9. French. PMID: 12750624.
  18. Ramirez RJ, Spinella PC, Bochicchio GV. Tranexamic Acid Update in Trauma. *Crit Care Clin*. 2017;33(1):85-99. DOI: 10.1016/j.ccc.2016.08.004 PMID: 27894501.
  19. Wang Q, Liu J, Fan R, Chen Y, Yu H, Bi Y, Hua Z, Piao M, Guo M, Ren W, Xiang L. Tranexamic acid reduces postoperative blood loss of degenerative lumbar instability with stenosis in posterior approach lumbar surgery: a randomized controlled trial. *Eur Spine J*. 2013;22(9):2035-8. DOI: 10.1007/s00586-013-2836-z Epub 2013 29 May. PMID: 23715891; PMCID: PMC3777047
  20. Ker K, Prieto-Merino D, Roberts I. Systematic review, meta-analysis and meta-regression of the effect of tranexamic acid on surgical blood loss. *Br J Surg*. 2013;100(10):1271-9. DOI: 10.1002/bjs.9193. Epub 2013 9 Jul PMID: 23839785
  21. Ker K, Edwards P, Perel P, Shakur H, Roberts I. Effect of tranexamic acid on surgical bleedings: systematic review and cumulative meta-analysis. *BMJ*. 2012; 344:e3054.
  22. de Vasconcellos SJA, do Nascimento-Júnior EM, de Aguiar Menezes MV, Tavares Mendes ML, de Souza Dantas R, Martins-Filho PRS. Preoperative Tranexamic Acid for Treatment of Bleeding, Edema, and Ecchymosis in Patients Undergoing Rhinoplasty: A Systematic Review and Meta-analysis. *JAMA Otolaryngol Head Neck Surg*. 2018 1;144(9):816-823. DOI:10.1001/jamaoto.2018.1381

- PMID: 30098161; PMCID: PMC6233636
23. McGuire C, Nurmsoo S, Samargandi OA, Bezuhly M. Role of Tranexamic Acid in Reducing Intraoperative Blood Loss and Postoperative Edema and Ecchymosis in Primary Elective Rhinoplasty: A Systematic Review and Meta-analysis. *Jama Facial Plast Surg.* 2019;21(3):191-198.  
DOI: 10.1001/jamafacial.2018.1737.  
PMID: 30605219; PMCID: PMC6537831
24. Ausen K, Fossmark R, Spigset O, Pleym H. Randomized clinical trial of topical tranexamic acid after reduction mammoplasty. *Br J Surg.* 2015;102(11):1348-1353.  
DOI:10.1002/bjs.9878
25. Rohrich RJ, Cho MJ. The role of tranexamic acid in plastic surgery: review and technical considerations. *Plast Reconstr Surg.* 2018;141(2):507-515.  
DOI:10.1097/00006534-200108000-00035
26. Headon H, Kasem A, Mokbel K. Capsular Contracture after Breast Augmentation: An Update for Clinical Practice. *Arch Plast Surg.* 2015;42(5):532-43.
27. Codner MA, Mejia JD, Locke MB, et al. A 15-year experience with primary breast augmentation. *Plast Reconstr Surg.* 2011;127(3):1300–10.
28. Handel N, Jensen JA, Black Q, Waisman JR, Silverstein MJ. The fate of breast implants: a critical analysis of complications and outcomes. *Plast Reconstr Surg.* 1995;96(0032-1052 (Print)):1521–33
29. Bachour Y, Bargon CA, de Blok CJM, Ket JCF, Ritt MJPF, Niessen FB. Risk factors for developing capsular contracture in women after breast implant surgery: A systematic review of the literature. *Journal of Plastic, Reconstructive & Aesthetic Surgery.* 2018 1;71(9):e29-48.
30. Balogh ZJ, King KL. Perspectives on tranexamic acid in surgery. *ANZ Journal of Surgery.* 2020;90(4):409-409.
31. Abboud NM, Kapila AK, Abboud S, Yaacoub E, Abboud MH. The Combined Effect of Intravenous and Topical Tranexamic Acid in Liposuction: A Randomized Double-Blinded Controlled Trial. *Aesthet Surg J Open Forum.* Jan 2021;3(1):ojab002.

© Copyright (2024): Author(s). The licensee is the journal publisher. This is an Open Access article distributed under the terms of the Creative Commons Attribution License (<http://creativecommons.org/licenses/by/4.0>), which permits unrestricted use, distribution, and reproduction in any medium, provided the original work is properly cited.

*Peer-review history:*

*The peer review history for this paper can be accessed here:*  
<https://www.sdiarticle5.com/review-history/115128>