



HAL
open science

Palliative surgery for thumb involvement in ulnar paralysis

A. Cambon-Binder, M. Chammas, Bertrand Coulet, C. Lazerges

► **To cite this version:**

A. Cambon-Binder, M. Chammas, Bertrand Coulet, C. Lazerges. Palliative surgery for thumb involvement in ulnar paralysis. *Hand Surgery and Rehabilitation*, 2022, 41, pp.S112-S117. <10.1016/j.hansur.2020.10.021>. <hal-04556575>

HAL Id: hal-04556575

<https://hal.science/hal-04556575v1>

Submitted on 22 Jul 2024

HAL is a multi-disciplinary open access archive for the deposit and dissemination of scientific research documents, whether they are published or not. The documents may come from teaching and research institutions in France or abroad, or from public or private research centers.

L'archive ouverte pluridisciplinaire **HAL**, est destinée au dépôt et à la diffusion de documents scientifiques de niveau recherche, publiés ou non, émanant des établissements d'enseignement et de recherche français ou étrangers, des laboratoires publics ou privés.



Copyright - All rights reserved

Palliative surgery for thumb involvement in ulnar paralysis

Chirurgie palliative pour l'atteinte du pouce dans la paralysie ulnaire

A. Cambon-Binder¹, Michel Chammas², Bertrand Coulet², Cyril Lazerges²

1 : Service d'orthopédie et de chirurgie du membre supérieur, Hôpital Saint-Antoine, 184 Rue du Faubourg Saint-Antoine, 75012 Paris, France

2 : Service de chirurgie de la main et du membre supérieur, chirurgie des nerfs périphériques Hôpital Lapeyronie, CHU Montpellier, CHU Montpellier, Avenue du doyen Gaston Giraud, 34295 Montpellier cedex 5, France

Correspondance :

Pr Michel Chammas

Service de chirurgie de la main et du membre supérieur, chirurgie des nerfs périphériques Hôpital Lapeyronie, CHU Montpellier, Avenue du doyen Gaston Giraud, 34295 Montpellier cedex 5, France

tél : 0467338538

fax : 0467337966

email : m-chammas@chu-montpellier.fr

Autres auteurs :

Adeline Cambon-Binder

Bertrand Coulet

Cyril Lazerges

Conflits d'intérêts :

Les auteurs déclarent ne pas avoir de liens d'intérêts en relation avec cet article.

1

2 **Abstract**

3 Ulnar paralysis has multiple clinical presentations, which are due to partial recovery or to
4 anatomical variations between the ulnar and median nerves. The main sequelae of ulnar
5 nerve paralysis are the loss of hand strength with impairment of all intrinsic functions of the
6 fingers and some of the thumb's functions. Weakness of the adductor pollicis and flexor
7 pollicis brevis muscles may manifest as weak key pinch with automatic flexion of the thumb
8 interphalangeal joint when gripping. Indications for palliative surgery have decreased due to
9 advances in peripheral nerve surgery. However, palliative surgery still has a significant role
10 to play when nerve repair techniques are not indicated or do not provide satisfactory results.
11 The principle is to reinforce metacarpophalangeal flexion while stabilizing the thumb's
12 interphalangeal joint, thus supplementing the action of the flexor pollicis brevis. This is
13 generally done by transferring the flexor digitorum superficialis tendon of the fourth finger to
14 the distal insertion of the superficial thenar muscles and the extensor pollicis longus.
15 Restoration of the first dorsal interosseous is more rarely indicated.

16

17 **Résumé**

18 Les tableaux cliniques des paralysies ulnaires sont multiples en raison soit d'une
19 récupération partielle, soit de variations anatomiques entre nerf ulnaire et nerf médian. La
20 principale des séquelles des paralysies du nerf ulnaire est la perte de force de la main avec
21 atteinte de toutes les fonctions intrinsèques des doigts longs et d'une partie de celles du
22 pouce. La faiblesse des muscles adductor pollicis et flexor pollicis brevis peuvent se
23 manifester par une faiblesse de la pince latérale avec une flexion automatique de
24 l'interphalangienne du pouce lors des prises. Les indications de chirurgie palliative ont
25 diminué en raison des progrès de la chirurgie nerveuse périphérique. Toutefois, la chirurgie
26 palliative garde une place non négligeable en cas de résultat incomplet des techniques de
27 réparation nerveuse ou lorsqu'elles ne sont pas indiquées. Le principe est de renforcer la
28 flexion métacarpo-phalangienne tout en stabilisant l'interphalangienne du pouce, donc de

29 suppléer à l'action des muscles intrinsèques du pouce, au moyen généralement du transfert
30 du tendon FDS du quatrième doigt sur l'insertion distale des muscles thénariens superficiels
31 et l'extensor pollicis longus. La réanimation du premier interosseux dorsal est plus rarement
32 indiquée.

33

34 *Keywords:* Ulnar nerve paralysis; Tendon transfers; Palliative surgery; Flexor pollicis brevis

35

36 *Mots-clés :* Paralysie du nerf ulnaire ; Transferts tendineux ; Chirurgie palliative ; Flexor
37 pollicis brevis

38

39

40 **1. Introduction**

41 In most cases, ulnar nerve palsy is the result of injuries to the wrist or forearm. Although
42 isolated ulnar nerve injury is possible, it is usually associated with finger and thumb flexor
43 tendon lacerations. It is essential to consider these when assessing the sequelae and
44 surgical repair needed to treat the nerve palsy. Variations in the innervation to the forearm
45 and hand provided by the median and ulnar nerves are very common. These differences and
46 partial recovery, especially after nerve surgery, explain the discrepancies found in clinical
47 and functional outcomes from one patient to the next. An in-depth analysis of the injury is
48 required to determine whether palliative surgery is indicated. It is essential for the patient to
49 begin rehabilitation therapy as soon as palsy starts to set in, to avoid joint stiffness, soft
50 tissue contracture, compensation patterns, and maintain hand function within overall body
51 dynamics.

52 The impact of ulnar nerve palsy on the fingers and sensory impairment in the hand
53 will not be discussed, as they do not affect the thumb. Indications for surgery, the leading
54 tendon transfer techniques, as well as their benefits and drawbacks are presented.

55

56 **2. Contribution of the ulnar nerve to grip strength (Fig. 1)**

57 Typically, the ulnar nerve supplies the deep thenar muscle group of the hand: the deep head
58 of the flexor pollicis brevis (FPB) muscle and the adductor pollicis muscle. The adductor
59 pollicis muscle has two heads: oblique and transverse. The oblique head originates from the
60 capitate and the trapezoid bones, the base of the second and third metacarpals, and the
61 tendinous sheath of the flexor carpi radialis. The transverse head, triangular in shape, stems
62 from the distal two-thirds of the anterior aspect of the third metacarpal.

63 The distal insertion of the adductor holds the medial sesamoid bone and ends on the
64 ulnar aspect of the base of the proximal phalanx and onto the oblique pulley of the thumb. It
65 sends an expansion to the extensor pollicis longus (EPL), forming the dorsal hood with the
66 corresponding expansion from the abductor pollicis brevis (APB). Another expansion passes

67 under the flexor pollicis longus (FPL) to merge with the fibers of the deep head of the FPB
68 and those of the abductor pollicis.

69 The adductor pollicis has many functions: thumb adduction (thus contributing to
70 retropulsion of the thumb column), metacarpophalangeal (MCP) joint flexion, and
71 interphalangeal (IP) joint extension with the APB and the FPB.

72 The FPB muscle has two parts: the superficial head and the deep head. The
73 superficial head originates from the tubercle of the trapezium bone and the inferior aspect of
74 the flexor retinaculum. Its course is in front and superficial to the FPL. The deep head arises
75 from the anterior aspect of the trapezoid and capitate bones. It passes deep to the FPL and
76 merges with the tendon of the superficial head. The FPB inserts on the lateral sesamoid
77 bone of the MCP joint and the lateral tubercle at the base of the proximal phalanx. It also has
78 an expansion to the EPL with the APB [1]. The superficial head acts in adduction and slight
79 antepulsion. The deep head plays a role in thumb adduction. The two heads contribute to
80 MCP joint flexion. Finally, the muscle participates in IP joint extension through its dorsal
81 expansion.

82 The adductor pollicis muscle and the deep head of the FPB are innervated by the
83 deep branch of the ulnar nerve. However, nerve supply to the muscles powering the thumb
84 can vary; being aware of these anatomic variations is essential to accurately assess each
85 patient [2]. The best-known are the Martin-Gruber and Riché-Cannieu communicating
86 branches [3].

87 The Martin-Gruber communicating branch, found in 15% of patients [3], consists in a
88 median to ulnar nerve fiber anastomosis in the forearm, starting either from the trunk of the
89 median nerve or from the anterior interosseous nerve. This anastomosis can be found at any
90 level in the forearm, supplying intrinsic muscles normally innervated by the ulnar nerve: the
91 first dorsal interosseous, the adductor pollicis, the abductor digiti minimi, and, less frequently,
92 the second and third dorsal interossei. It should be noted that this anastomosis can also work
93 in the opposite direction and carry nerve fibers from the ulnar to the median nerve. A Martin-
94 Gruber communicating branch can explain the impairment of intrinsic muscles normally

95 innervated by the ulnar nerve after high median nerve injury, or high ulnar nerve injury
96 without intrinsic muscle impairment but with paralysis of the flexor carpi ulnaris (FCU) and of
97 the flexor digitorum profundus (FDP) of the fifth digit.

98 The Riché-Cannieu communicating branch [3] is an anastomosis between the ramus
99 of the thenar branch supplying the superficial head of the FPB and the deep branch of the
100 ulnar nerve supplying the deep head of the FPB. This anastomosis circles deep under the
101 FPL tendon. Harness and Sekeles [4] found it in 77% of dissections in preserved specimens
102 and in virtually all fresh specimens. Several variations have been described, some passing
103 through the first lumbrical, and some between the deep branch of the ulnar nerve and one of
104 the palmar digital nerves of the thumb or index finger. Therefore, the FPB can be exclusively
105 innervated by one or the other of the two nerves. This affects either thumb opposition or
106 Froment's sign, depending on whether the injury is to the ulnar or median nerve. A Riché-
107 Cannieu communicating branch may be the reason for continued thumb opposition when the
108 median nerve has been completely transected (the superficial head of the FPB is then
109 innervated by the ulnar nerve) and may also explain the absence of Froment's sign (see
110 below) when the ulnar nerve has been completely severed (the deep head of the FPB is then
111 innervated by the median nerve).

112 Dual innervation is also frequent when it comes to the thenar muscles. Zancolli and
113 Cozzi [5] found it in 30% of cases for the superficial head of the FPB, in 79% of cases for its
114 deep head, and in 35% of cases for the oblique head of the adductor pollicis. However, the
115 transverse head of the adductor pollicis is innervated exclusively by the ulnar nerve in 96% of
116 cases. From a clinical standpoint, these variations in nerve supply mean that the thenar
117 muscles are solely innervated by the ulnar nerve in 2% of cases and by the median nerve in
118 2% of cases [6]. The FPB remains functional in 58% of cases when the ulnar nerve is
119 completely severed and 73% of cases when the median nerve is completely severed [6].
120 Consequently, Jensen [7] considers tendon transfers to restore thumb opposition necessary
121 in only 14% of total isolated median nerve palsies.

122

123

124 **3. Clinical presentation of isolated ulnar nerve palsy [2]**

125 The first consequence of ulnar nerve damage, whether high or low, is a loss of adduction of
126 the first metacarpal joint during opposition, caused by FPB injury. Antepulsion is possible, but
127 the thumb cannot reach the base of the ulnar digits [8]. Furthermore, paralysis of the
128 adductor pollicis and the first dorsal interosseous muscle result in much weaker pinch grips.

129 Froment's sign manifests to compensate for paralysis of the adductor pollicis and the
130 FPB, resulting in thumb IP joint flexion through the FPL during key pinch grips (Fig. 2). It is
131 more severe when the FPB is innervated exclusively by the ulnar nerve. The EPL, aided by
132 the APB and the superficial head of the FPB contributing to the extensor hood, is not strong
133 enough to counter the FPL. Assessment requires the patient to pinch a sheet of paper
134 between the pad of the thumb and the lateral surface of the index finger.

135 Jeanne's sign reveals MCP joint instability as it becomes extended or hyperextended
136 during pinch grips, due to FPB and adductor pollicis paralysis.

137 Ulnar palsy causes an important loss in pinch strength (75% to 80%) [9]. Thenar
138 muscle motor deficit will have varying clinical presentations, depending on how the
139 median/ulnar nerve supply is divided if there is a communicating Riché-Cannieu branch, or,
140 in case of high ulnar injury, a communicating Martin-Gruber branch.

141

142 **4. Preoperative assessment**

143 A palliative surgical procedure may be considered as the first-line treatment when ulnar
144 nerve palsy is not the result of a previous nerve repair, when the time between the trauma
145 and surgery is excessively long, or when the patient presents poor prognostic factors (age,
146 active smokers, etc.). As a second-line treatment, a palliative procedure can be
147 recommended in case of failed primary nerve repair, in the absence of recovery after a
148 reasonable delay (varies depending on the severity of injury), the type of injury, patient age,
149 the quality of initial nerve repair. In practice, it is best to differentiate which nerve injuries are
150 more likely to have a good prognosis for nerve regeneration from those with a poor prognosis

151 (grade II injuries, long time to surgery, older patient, proximal injury). In this last case,
152 complete palliative surgery may be offered early on, to avoid waiting unnecessarily for a
153 recovery that will never happen.

154 A comprehensive assessment is necessary before recommending surgery and
155 choosing the appropriate technique for the patient. The overall elements to consider are the
156 way the hand is used despite paralysis, the patient's understanding of the goals, possibilities
157 and limits of surgery, as well as a capacity to integrate the transfer and adhere to the
158 rehabilitation program. An assessment of the affected limb is also needed: tissues have
159 healed and the scar is stable (bone union is complete, absence of inflammation or infection,
160 adequate scarring of the areas that may be used during transfer), hand and wrist range of
161 motion, presence of trophic disorders and cold intolerance, testing muscles that could be
162 transferred. Furthermore, pain which might impact hand function is also investigated. In case
163 of complete median-ulnar nerve palsy with numbness, tendon transfer is not necessarily
164 indicated in the presence of trophic disorders and pain.

165 Thereafter, we can distinguish between palsies without complications involving only
166 intrinsic muscles or extending to extrinsic muscles, from palsies with complications involving
167 limited passive mobility because of soft tissue contracture and/or joint stiffness, important
168 sensory nerve damage combining pain, anesthesia and severe trophic disorders.

169

170 **5. Surgical management**

171 There are two types of ulnar nerve palsies: low nerve palsy, involving an ulnar nerve injury to
172 the distal part of the forearm or wrist (these do not impact the FDP of the ulnar digits and the
173 FCU) and high nerve palsy caused by more proximal injuries. We will focus on complete
174 isolated ulnar nerve palsies.

175 Functional deficits vary depending on the extent of paralysis and the patient's needs.
176 The goal of palliative surgery will be to strengthen the pinch grip on both sides of the thumb
177 and index finger. To this end, the thumb's MCP and IP joints need to be stabilized as well as
178 the index finger's MCP joint. Several surgical options have been described to achieve this

179 outcome. We will not list them all but rather present a simplified, tiered outlook. The two main
180 goals are restoring thumb adduction and strengthening MCP joint flexion. Like Revol and
181 Servant [8] we prefer strengthening MCP joint flexion using the method described by Zancolli
182 [10]. Restoring thumb adduction can result in first web space contracture and an increased
183 risk of adhesions because of the course taken by the transfer and its pulley.

184

185 5.1. Transfer of fourth digit flexor digitorum superficialis (FDS) tendon to restore FPB,
186 according to Zancolli [2,8,10] (Fig. 3)

187 This transfer helps MCP joint flexion, contributes to IP joint extension and has an adduction
188 effect through its axis which starts downstream from the pisiform bone. Because the path of
189 the motor tendon is parallel to the first metacarpal and on its palmar aspect, it effectively
190 corrects Froment's sign, regardless of the metacarpal's position during opposition [8].

191 The FDS of the fourth digit is used as the motor tendon. It is harvested upstream from
192 the Chiasma tendinum, between the A1 and A2 pulleys as recommended by North and Littler
193 [11], to keep the vincula intact and minimize the functional impact at the level of the proximal
194 interphalangeal (PIP) joint. The tendon is then retrieved upstream from the carpal tunnel,
195 passed underneath it and recovered on the distal aspect of the carpal tunnel through an
196 oblique incision going towards the base of the thumb. The tubercle of the trapezium acts as
197 the pulley, on the radial and distal side of the carpal tunnel. The tendon courses under the
198 FPL, between the two heads of the FPB, and then shifts to the radial side of the thumb,
199 passing under the pedicles. The fixation point is the APB tendon and its expansion into the
200 dorsal aspect of the extensor and the EPL. This final fixation was proposed by Riordan [12]
201 to counteract IP joint flexion during pinch. The tension is set with the wrist straight, the thumb
202 in average anteposition and the MCP and IP joints straight.

203 However, there are some contraindications to using the fourth digit's FDS tendon. In
204 case of sequelae due to a transection of the flexor tendons or FDP palsy of the same finger
205 because of a high ulnar nerve injury, there is a risk of decreased grip strength and of swan
206 neck deformity, especially in patients with lax joints. In the absence of a usable FDS, the

207 extensor indicis proprius (EIP) can be used along a transmembrane course or circumular
208 course under the FCU and the ulnar bundle before passing deep at the level of the carpal
209 tunnel [13].

210

211 5.2. Tendon transfer to restore thumb adduction [2,8,10] (Fig. 4)

212 According to Thompson [14], the most popular tendon for transfer is the ring finger's FDS,
213 with the ulnar aspect of the superficial palmar aponeurosis and the distal side of the flexor
214 retinaculum acting as a pulley. Typically, the adductor pollicis is the fixation point. Bourrel
215 [15] and Chaise [16] use two bands for fixation, passing on the radial side of the MCP joint,
216 one on the EPL and the other on the insertion of the adductor pollicis or the medial surface of
217 the first metacarpal neck. This transfer acts in adduction and repropulsion because of its
218 course. Its drawbacks are the risk of limited abduction, its long course which hinders the
219 stabilizing effect on the MCP joint during pinch, and a marked angle at the pulley level with a
220 potential for adhesion formation. The EIP has also been transferred, with the second
221 intermetacarpal space acting as a pulley [17].

222

223 5.3. Bone and joint options [2]

224 In the event that there are no motor tendons available, the treatment for instability of the
225 thumb MCP joint is arthrodesis [18,19] or capsulodesis with sesamoid-
226 metacarpal stabilization [10]. The extensor pollicis brevis (EPB) can then be used to restore
227 the first dorsal interosseous.

228 In case of irreducible flexion contracture of the IP joint or when tendon transfer to
229 stabilize the MCP joint is impossible, a simple thumb IP joint arthrodesis [20] can improve
230 function and increase strength. However, some patients find the loss of mobility
231 uncomfortable [21], which is why it is only used in severe flexion contracture cases. This IP
232 joint arthrodesis may also provide an opportunity to reroute the FPL behind the proximal
233 phalanx, according to Oberlin's modification of the Makin technique (which included

234 osteotomy of the proximal phalanx). This procedure was initially described to restore
235 opposition, but it also has a relevant stabilizing effect on the thumb MCP joint [22].

236

237 5.4. Index finger MCP joint stabilization

238 Restoring the first dorsal interosseous can be recommended to patients whose index finger
239 always comes into adduction during key pinch, which greatly decreases pinch strength. In
240 practice, most patients make up for first dorsal interosseous muscle paralysis with their other
241 fingers, compensating for the index finger's ulnar drift. When appropriate, we believe that
242 EPB transfer [23] is the preferred solution, much better than direct EIP transfer [24] whose
243 line of pull is nearly nil. This transfer is even more indicated when arthrodesis of the thumb
244 MCP joint is performed. Finally, we recently described an alternative technique, consisting in
245 EIP tendon transfer rerouted to the first compartment, giving it a line of pull similar to that of
246 the first dorsal interosseous [25].

247

248 **6. Conclusion**

249 Paralysis of the thumb's intrinsic muscles following ulnar nerve injury can cause important
250 functional limitations. An in-depth assessment of the patient's condition is essential prior to
251 any indication for surgery. Today, palliative surgery is not as common because of advances
252 in peripheral nerve repair. Nonetheless, surgery can sometimes greatly improve the patient's
253 function and should be offered as a treatment option as soon as neurological recovery is
254 deemed unsatisfactory.

255

256 **Conflict of interest statement:**

257 The authors report no conflict of interest in relation with this work.

258

259 **References**

260

- 261 1. Gupta S, Michelsen-Jost H. Anatomy and function of the thenar muscles. *Hand Clin*
262 2012;28:1-7.
- 263 2. Chammas M, Coulet B, Lumens D, Belin C, Lazerges C, Thauray MN. Chirurgie
264 palliative dans les lésions du nerf médian et du nerf ulnaire. In: Alnot JY and Chammas M
265 (eds.) *Lésions traumatiques des nerfs périphériques*. Paris, Elsevier; 2007: 180-205.
- 266 3. Doyle JR, Botte MJ (eds.) *Surgical anatomy of the hand and upper extremity*.
267 Philadelphia: Lippincott Williams & Wilkins; 2003.
- 268 4. Harness D, Sekeles E. The double anastomotic innervation of thenar muscles. *J Anat*
269 1971;109:461-6.
- 270 5. Zancolli EA, Cozzi EP. *Atlas of surgical anatomy of the hand*. New York: Churchill
271 Livingstone; 1992.
- 272 6. Rowntree T. Anomalous innervation of the hand muscles. *J Bone Joint Surg Br*
273 1949;31:505-10.
- 274 7. Jensen EG. Restoration of opposition of the thumb. *Hand* 1978;10:161-7.
- 275 8. Revol M, Servant JM. *Paralysies de la main et du membre supérieur*. Paris: Medsi;
276 1987.
- 277 9. Mannerfelt L. Studies on the hand in ulnar nerve paralysis: A clinical-experimental
278 investigation in normal and anomalous innervation. *Acta Orthop Scand* 1966;Suppl 87:89-97.
- 279 10. Zancolli EA (ed.) *Structural and dynamic basis of hand surgery*, 2nd ed. Philadelphia:
280 Lippincott; 1979.
- 281 11. North ER, Littler JW. Transferring the flexor superficialis tendon: Technical
282 considerations in the prevention of proximal interphalangeal joint disability. *J Hand Surg Am*
283 1980;5:498-501.
- 284 12. Riordan DC. Tendon transfers in hand surgery. *J Hand Surg Am* 1983;8:748-53.
- 285 13. Caplan S, Chouhy Aguirre S. Sobre secuelas de lesión alta e irreparable de nervios
286 mediano y cubital y su tratamiento. *Prensa Med Argent* 1956;43:2341-6.
- 287 14. Thompson TC. A modified operation for opponens paralysis. *J Bone Joint Surg Am*
288 1942;24: 632-40.

- 289 15. Bourrel P. Chirurgie de la lèpre chez l'africain. Expérience personnelle de 580
290 interventions. Med Trop 1969;29:1-33.
- 291 16. Chaise F. Stratégie thérapeutique dans les paralysies des muscles intrinsèques du
292 pouce. Chir Main 2007;26:1-12.
- 293 17. Alnot JY, Masquelet AC. Restauration de la pince pouce-index par double transfert
294 tendineux dans les séquelles de paralysie cubitale. Ann Chir Main 1983;2:202-10.
- 295 18. Omer GE Jr. Reconstructive procedures for extremities with peripheral nerve defects.
296 Clin Orthop Relat Res 1982;163:80-91.
- 297 19. Brand PW. Tendon transfers for median and ulnar nerve paralysis. Orthop Clin North
298 Am 1970;1:447-54.
- 299 20. Tubiana R. Paralysies des muscles du pouce. In: Tubiana T (éd.) Traité de chirurgie
300 de la main. Paris, Masson; 1991: 211-260.
- 301 21. Hastings H 2nd, Davidson S. Tendon transfers for ulnar nerve palsy. Evaluation of
302 results and practical treatment considerations. Hand Clin 1988;4:167-78.
- 303 22. Makin M. Translocation of the flexor pollicis longus tendon to restore opposition. J
304 Bone Joint Surg Br 1967;49:458-61.
- 305 23. Bruner JM. Tendon transfer to restore abduction of the index finger using the
306 extensor pollicis brevis. Plast Reconstr Surg 1948;3:197-201.
- 307 24. Brown PW. Reconstruction for pinch in ulnar intrinsic palsy. Orthop Clin North Am
308 1974;5:323-42.
- 309 25. Kaiser D, Masquelet AC, Sautet A, Cambon-Binder A. Reconstruction of lateral pinch
310 in an isolated paralysis of the first dorsal interosseous muscle - A new surgical technique.
311 Orthop Traumatol Surg Res 2020;106:353-6.

312

313

314 **Figure legends**

315 Fig. 1. Mechanism of action of the extrinsic and intrinsic muscles on the trapeziometacarpal
316 joint. *APL*: abductor pollicis longus; *APB*: abductor pollicis brevis; *FPB*: flexor pollicis brevis;
317 *FPL*: flexor pollicis longus; *AP*: adductor pollicis; *EPL*: extensor pollicis longus; *EPB*:
318 extensor pollicis brevis; *OP*: opponens pollicis (from Chammas M et al. [2]).

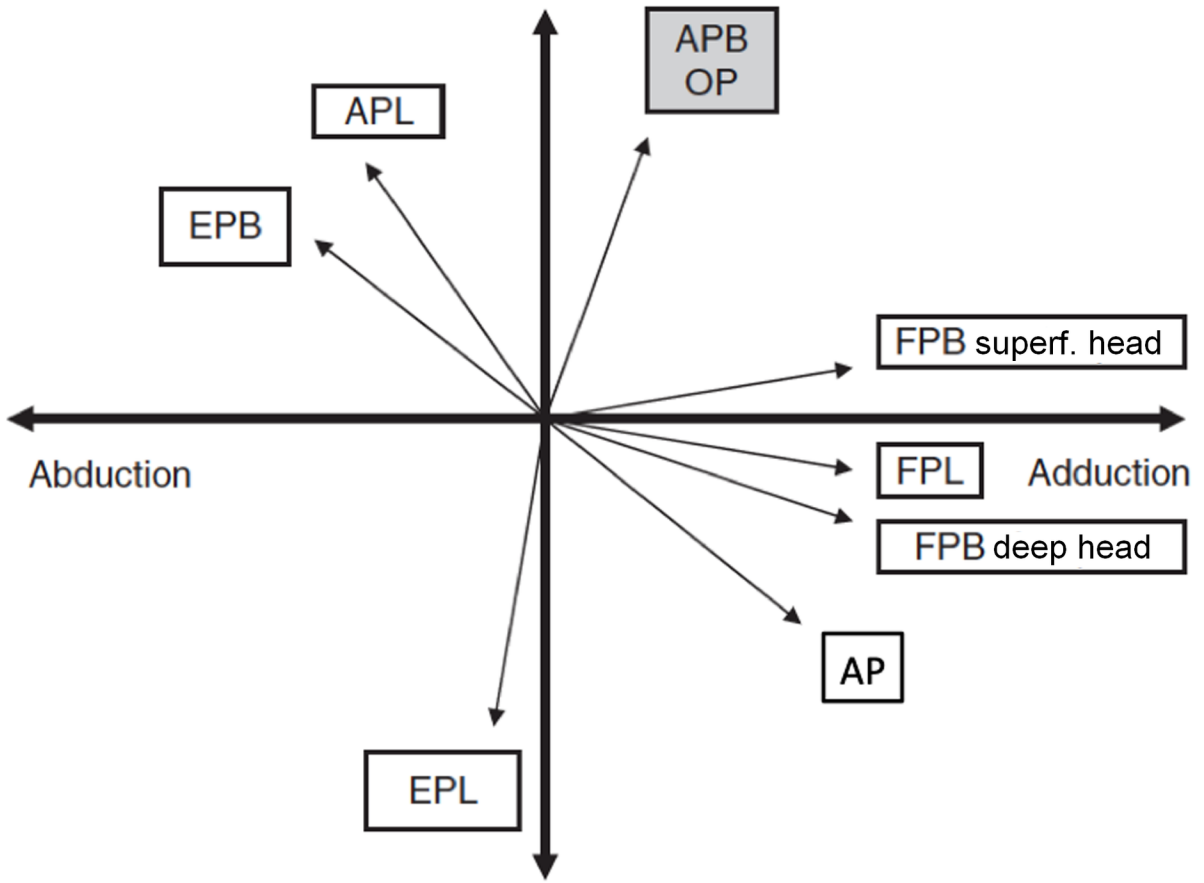
319 Fig. 2. Sequelae following ulnar nerve injury on the left side (a). Froment's sign (b). Tendon
320 transfer to stabilize the thumb metacarpophalangeal joint with Riordan's technique, using the
321 FDS from the 4th digit with fixation to the abductor pollicis brevis and the extensor pollicis
322 longus (c, d, e). An extensor digiti minimi transfer, rerouted into the 4th extensor
323 compartment, was performed at the same time to correct Wartenberg's sign (see chapter on
324 surgical correction for Wartenberg's sign). Clinical outcomes (f, g, h, i, j).

325 Fig. 3. Transfer of the fourth digit's FDS tendon to the abductor pollicis brevis and the
326 extensor pollicis longus (from Chammas M et al. [2]).

327 Fig. 4. Restoration of thumb opposition by transferring the fourth digit's FDS tendon to the
328 adductor pollicis and extensor pollicis longus according to Thompson [14].

329

Antepulsion



EPB

APL

APB
OP

FPB superf. head

Abduction

FPL

Adduction

FPB deep head

AP

EPL

Retropulsion

