



HAL
open science

Renal Histopathological Lesions Associated with SARS-CoV-2 Infection in Patients with no History of Kidney Disease: A Systematic Review

Thais Morgana Mendes Santos, Andressa Duarte De Souza, Ariel de Castro Mendes Sá, Jonathan Lopes Moreira, Lucas Cardoso Batista, Marcela Costa Amorim, Matheus Ribeiro Moreira, Michelly Siman Glória, Kinulpe Honorato Sampaio

► To cite this version:

Thais Morgana Mendes Santos, Andressa Duarte De Souza, Ariel de Castro Mendes Sá, Jonathan Lopes Moreira, Lucas Cardoso Batista, et al.. Renal Histopathological Lesions Associated with SARS-CoV-2 Infection in Patients with no History of Kidney Disease: A Systematic Review. *Journal of Advances in Medicine and Medical Research*, 2024, 36 (5), pp.224-244. 10.9734/jammr/2024/v36i55432 . hal-04552055

HAL Id: hal-04552055

<https://hal.science/hal-04552055>

Submitted on 19 Apr 2024

HAL is a multi-disciplinary open access archive for the deposit and dissemination of scientific research documents, whether they are published or not. The documents may come from teaching and research institutions in France or abroad, or from public or private research centers.

L'archive ouverte pluridisciplinaire **HAL**, est destinée au dépôt et à la diffusion de documents scientifiques de niveau recherche, publiés ou non, émanant des établissements d'enseignement et de recherche français ou étrangers, des laboratoires publics ou privés.

Copyright



Renal Histopathological Lesions Associated with SARS-CoV-2 Infection in Patients with no History of Kidney Disease: A Systematic Review

Thais Morgana Mendes Santos ^a,
Andressa Duarte de Souza ^a, Ariel de Castro Mendes Sá ^a,
Jonathan Lopes Moreira ^{a,b}, Lucas Cardoso Batista ^a,
Marcela Costa Amorim ^a, Matheus Ribeiro Moreira ^a,
Michelly Siman Glória ^a and Kinulpe Honorato Sampaio ^{a,b*}

^a Faculdade de Medicina, Universidade Federal dos Vales do Jequitinhonha e Mucuri, Diamantina, Minas Gerais, Brazil.

^b Programa de Pós-graduação em Ciências da Saúde, Universidade Federal dos Vales do Jequitinhonha e Mucuri, Diamantina, Minas Gerais, Brazil.

Authors' contributions

This work was carried out in collaboration among all authors. All authors read and approved the final manuscript.

Article Information

DOI: 10.9734/JAMMR/2024/v36i55432

Open Peer Review History:

This journal follows the Advanced Open Peer Review policy. Identity of the Reviewers, Editor(s) and additional Reviewers, peer review comments, different versions of the manuscript, comments of the editors, etc are available here: <https://www.sdiarticle5.com/review-history/115330>

Systematic Review Article

Received: 08/02/2024

Accepted: 12/04/2024

Published: 17/04/2024

ABSTRACT

Background and Aims: Structural and functional lung damage is the most documented impairment in SARS-CoV-2. Nevertheless, the virus's impact extends beyond pulmonary manifestations, affecting various organs and tissues, including the kidneys, known for their expression of ACE2, the

*Corresponding author: E-mail: kinulpe@ufvjm.edu.br;

virus's cell entry receptor. The objective of this review is to provide a comprehensive summary of studies investigating kidney injuries in individuals lacking prior renal conditions following SARS-CoV-2 infection.

Methodology: A literature search encompassed studies published between December 2019 and September 2022, adhering to the PRISMA protocol. Electronic search strategies were developed to identify relevant studies across several bibliographic databases, including Pubmed, Scopus, Web of Knowledge, Embase, Scielo, Lilacs, Bireme, and Cochrane databases. A comprehensive analysis was undertaken, encompassing 43 studies involving 128 patients selected based on stringent inclusion criteria: a confirmed diagnosis of SARS-CoV-2 infection, observable renal alterations through microscopy, and/or viral presence detected in the kidneys.

Results: The included patients, primarily male (60.1%) with an average age of 53, exhibited prevalent comorbidities such as hypertension, diabetes, and obesity. The predominant outcome was death (43.7%), and various renal lesions were identified, with sclerosis, hyalinosis, tubular necrosis, and vascular injuries being the most common. Tubular lesions combined with glomerular lesions were frequently observed, regardless of comorbidity status. A greater predominance of renal involvement in patients with associated comorbidities, mainly arterial hypertension. The limited detection of the virus in renal tissue suggests a multifactorial origin of renal lesions, not solely attributed to the virus itself. The risk of bias assessment revealed mostly high-quality studies, with 24 assessed as low risk, 15 as moderate, and four as high risk.

Conclusion: Ours results provides a comprehensive analysis of kidney injuries in COVID-19 patients, emphasizing the significant role of comorbidities such as hypertension, diabetes, and obesity in contributing to the severity and occurrence of renal complications. Notably, hypertension emerges as a prominent risk factor. The findings suggest a multifaceted manifestation of kidney injury induced by SARS-CoV-2, involving both direct viral impact on kidney tissue and a systemic response to the infection. The study underscores the importance of understanding the renal implications of COVID-19 for guiding targeted interventions and future research in this critical area.

Keywords: COVID-19; SARS-CoV-2; acute kidney injury; kidney disease; renal pathology.

1. INTRODUCTION

In December 2019, a novel disease surfaced in Wuhan, China, later identified as a result of infection with a newly discovered acute virus, severe acute respiratory syndrome coronavirus 2 (SARS-CoV-2) [1,2]. This virus swiftly propagated, culminating in a global respiratory outbreak named coronavirus disease 2019 (COVID-19), officially declared a pandemic by the World Health Organization on March 11, 2020 [2], resulting in a total count of over 6 million deaths [2,3].

SARS-CoV-2 harbors structural proteins, including nucleocapsid protein (N) and membrane glycoprotein (M), integral to stabilizing viral genetic material and facilitating the viral replication cycle [4, 5]. Another critical component is the spike (S) glycoprotein, responsible for initiating host cell entry by binding to the angiotensin-converting enzyme 2 (ACE2) receptor [4,5].

The spectrum of SARS-CoV-2 infection ranges from asymptomatic cases to critical conditions [6]. Asymptomatic individuals exhibit no

symptoms or may experience respiratory symptoms common to other viral infections [1,6]. Severe cases of COVID-19 often entail multiple organ dysfunction, necessitating hospitalization [1,6]. Well-documented symptoms include runny nose, dry cough, fever, fatigue, shortness of breath, myalgia, diarrhea, headache, and weakness [4].

While structural and functional lung damage is extensively documented [2,4,6], other organs and tissues, such as blood, nervous tissue, heart, gastrointestinal tract, liver, and kidneys, can also be affected [2,4,6]. Among the myriad complications observed, acute respiratory distress syndrome, pneumonia, prothrombotic coagulopathy, acute cerebrovascular disease, and renal failure stand out [2]. The kidneys, in particular, are susceptible, emerging as frequent and severe complications of COVID-19 [2,6].

Research indicates an upregulation of ACE2 expression in renal cells [3,5,7]. Pathological mechanisms, both direct (viral tropism in the kidney) and indirect (inflammatory system activation, hypercoagulability, microangiopathy, and hypovolemia), contribute to the diverse and

multifactorial pathophysiology of kidney injury in COVID-19 [1,2,7]. These mechanisms result in tubular and glomerular damage, leading to acute kidney injury (AKI) [7]. Initial reports unveiled an incidence of AKI ranging from 5% to 29% in COVID-19 patients [8]. The development of AKI, especially in SARS-CoV-2-infected individuals, emerges as a grim prognostic factor linked to increased risks of death, ICU admission, and prolonged hospital stays [7,9]. Incidence rates may correlate with various risk factors, including age, obesity, hypertension, diabetes, lung disease, chronic kidney disease, and smoking [1–4,7].

Studies investigating the relationship between SARS-CoV-2 infection and AKI development acknowledge limitations such as a small number of patients [3,7,6,7], unreported pre-existing conditions [7], interpatient differences [7], limited laboratory investigations [8], and monocentric designs [9]. The diverse clinical features of COVID-19, especially in AKI [8], necessitate further clarification on how SARS-CoV-2 affects the kidneys and renal cells, especially in conditions without prior kidney disease, deepening our understanding of the disease's pathogenesis. So, this systematic review aims to analyze renal anatomopathological changes in SARS-CoV-2-infected patients without pre-existing renal disease. Additionally, it seeks to discuss the potential etiology and pathogenesis of renal injury in COVID-19.

2. METHODOLOGY

2.1 Search Strategy

We conducted a systematic review of original articles in accordance with PRISMA guidelines [10]. The protocol was registered in PROSPERO (CRD42021290467). A systematic search of electronic databases including Pubmed, Scopus, Web of Knowledge, Embase, Scielo, Lilacs, Cochrane, with studies published between December 2019 and September 2022. To search for articles in the databases, descriptors in health sciences (Decs) and Medical subject Headings (Mesh) were previously defined and divided into two groups: terms associated with exposure to Sars-Cov-2 and terms related to acute kidney injury as an outcome. The terms were combined with each other using Boolean operators and adjusted according to the database used (Supplementary Table 1).

2.2 Selection of Studies

Two independent investigators (MRM, JLM) assessed titles and abstracts of all studies found with electronic searches, and relevant articles were selected for full-text review. Studies identified by the initial search were evaluated according to the following inclusion criteria: 1) language (English, Spanish, Portuguese); 2) type of study (case-control, cohort, cross-sectional studies, case reports, case series, clinical trials); 3) description of renal histopathological and/or ultrastructural alterations. The studies selected at this stage were transferred to the Mendeley software to remove duplicates. After removing duplicates, the articles were analyzed in full-text by another two independent investigators (ADS, MCA). Studies were excluded if they reported patients with previous kidney disease, patients without a confirmed diagnosis for COVID-19 by exams, and without histopathological description of kidney injury. Those that did not meet the inclusion and exclusion criteria were excluded. Discrepancies about the eligibility were resolved by the senior reviewer (KHS). At the end of the full-text analysis stage, the selected articles underwent extraction of the data of interest.

2.3 Data Extraction

For data extraction, an electronic spreadsheet was created by two reviewers (MRM, JLM). The selected articles were divided between pairs of reviewers (TMMS, LCB, and MSG, ACMS) for data extraction. The information was collected in 3 axes: General information of the article, clinical-laboratory and demographic information of the patients of the analyzed study and anatomopathological alterations. In general data, the following information was extracted: Authors, title, DOI, publication date, type of study, language. The clinical-laboratory and demographic data obtained were: age, sex, comorbidities, number of patients, clinical presentation, outcome (death, for example), laboratory tests, imaging tests (ultrasound, computed tomography, for example) and therapeutic approach adopted. (dialysis, kidney transplantation, for example). The anatomopathological alterations described in the studies were divided into 3 parts, according to the method used for their detection: anatomopathological alterations present in optical microscopy, immunofluorescence and electron microscopy.

2.4 Assessment of Methodological Quality

To assess the methodological quality and risk of bias of the selected studies, we used the Newcastle Ottawa Scale (NOS) [11] and the critical assessment tools for systematic reviews proposed by the Joanna Briggs Institute (JBI) [12]. The NOS scale was used to evaluate the cohort studies included in the review, analyzing them through 3 parameters: selection, comparability and outcome. The tools proposed by the JBI were used to assess the quality of the case reports and case series present in the review. They assess the quality of studies using a dichotomous (yes or no) response questionnaire. Studies with more than 70% of a "yes" answer show a low risk of bias; between 50 to 69% of "yes" answers have a moderate risk of bias; and "yes" answers below 49% indicate a high risk of bias.

2.5 Statistical Analysis

To assess whether there was a difference in the frequency of renal lesions according to the renal compartment (glomerular, tubular, vascular) among individuals with and without comorbidities, and between genders, data were analyzed using the Chi-square test. Statistical analyses were performed using the Graph Pad Prism (version 8.00) software (Irvine, CA, USA). Statistical significance was set at $p < 0.05$.

3. RESULTS

The search strategy identified a total of 9991 studies across all databases. Out of these, 97% ($n=9639$) were excluded based on title and abstract readings and selection criteria. Subsequently, 298 articles underwent evaluation, and 85.5% ($n=255$) were excluded based on selection criteria. Ultimately, 43 articles were subjected to analysis. The study selection flowchart is presented in Fig. 1. Among the analyzed articles, 40% ($n=17$) were from 2020, 37% from 2021, and 23% from 2022. The language of all articles was English. The distribution based on study type included 65% ($n=28$) case reports, 28% ($n=12$) case series, and 7% ($n=3$) cohort studies. Regarding microscopy techniques used, 98% ($n=42$) utilized light microscopy, 56% ($n=24$) electron microscopy, and 51% ($n=22$) fluorescence microscopy. The studies originated from various countries, with 37% ($n=16$) conducted in the United States, 9% ($n=4$) in Iran, Italy, and Spain

each, 7% ($n=3$) in France, and smaller percentages in other countries.

3.1 Characteristic of the Selected Patients

A total of 296 patients were assessed across 43 studies, and 128 patients met the inclusion criteria, which specified a confirmed diagnosis of SARS-COV-2 infection, observable kidney changes through microscopy, and/or viral presence in the kidneys. Exclusion criteria were applied to patients with prior kidney disease. The characteristics of the selected patients are detailed in Table 1. Among the selected patients, 61% ($n=78$) were male, while 39% ($n=50$) were female, with a mean age of 53 years for both groups. The most prevalent comorbidities included hypertension, diabetes, and obesity. Half of the patients had hypertension, a quarter had diabetes, and approximately 17.2% were affected by obesity. Cardiovascular disease was present in 13.3% of cases, while 24.2% ($n=31$) had no associated comorbidities.

Regarding outcomes, death was the most prevalent at 43.7% ($n=56$). Additionally, 18.7% ($n=24$) of patients experienced a worsening of renal conditions, while 28.9% ($n=37$) showed improvement in laboratory test values, renal symptoms, and kidney recovery. Outcomes were not reported for 11.7% ($n=15$) of patients. Fever was the predominant clinical presentation, affecting 36.7% ($n=47$) of patients (Table 2), with a higher frequency in males, constituting 63.8% ($n=30$) of fever cases. Dyspnea was observed in 28.9% ($n=37$) of patients, with no significant difference between sexes, consistent with COVID-19 symptoms. Urinary disorders, including oliguria and hematuria, were observed in 16.4% ($n=21$) of cases, predominantly in males. Additionally, 13.3% ($n=17$) of patients remained asymptomatic.

3.2 Histopathological Characteristics of Kidney Injury in COVID-19 Patients

In this study, the findings of kidney anatomopathological changes were divided into three categories of lesions according to renal compartment: 1) Glomerular: hypercellularity; glomerular basement membrane changes; sclerosis and hyalinosis; podocytopathies; deposition of immune complexes and antibodies; 2) Tubular: tubular necrosis; tubulointerstitial nephritis; cylinders and epithelium 3) Vascular:

thrombotic microangiopathy; fibrin trombi; frequencies between patients with and without thromboses; thickening arterial; comorbidities according to each renal arterionephrosclerosis (Table 3). When comparing the distribution of renal lesion compartment, no significant differences were observed (χ^2 , $p=0.1169$).

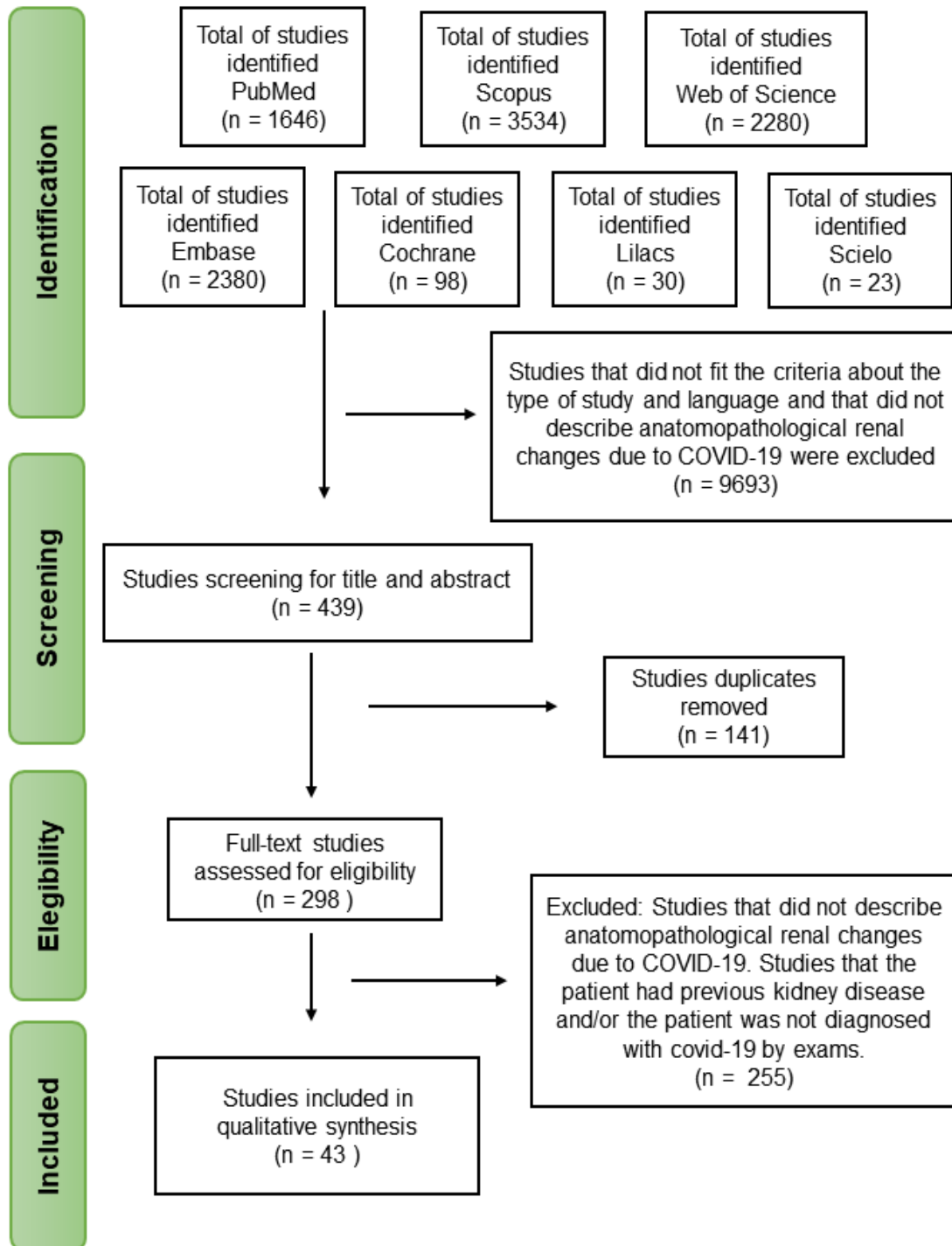


Fig. 1. The study selection flowchart

Table 1. Selected patients characteristics

Authors	Type of study	Number of patients	Mean age (range)	Male:Female	Mean Comorbidity	Clinical Presentation	Outcome	Main renal alterations
Akilesh et al. (2020) [13]	Case Series	14	55 (34-77)	6:8	HTN; DM; Obesity; Dyslipidemia	Fever; Weakness; Dyspnea; Abdominal pain	Kidney deterioration; Improvement in renal symptoms	Glomerular, Vascular and Tubular
Alawad et al. (2022) [14]	Case Report	1	27	1:0	Absent	HBP; Periorbital edema; Limb edema	Improvement in lab tests	Tubular and Glomerular lesions
Azukaitis et al. (2022) [15]	Case Report	1	12	1:0	Absent	-	Kidney recovery	Tubular and Glomerular lesions
Basiratnia et al. (2021) [16]	Case Report	2	16; 17	2:0	Absent	Fever; Periorbital edema; Oliguria; Nausea and vomit; HBP	Kidney deterioration; Kidney recovery; Death	Glomerular, Vascular and Tubular
Bradley et al. (2020) [17]	Case Series	6	65 (42-76)	2:4	HTN; HF; DM; Obesity; Dyslipidemia	Fever; Dyspnea	Death	Glomerular, Vascular and Tubular
Buyansky et al. (2021) [18]	Case Report	1	62	0:1	-	Fever; Dyspnea	Kidney recovery;	Tubular and Glomerular lesions
Couturier et al. (2022) [19]	Case Report	2	53	2:0	HTN	Fever; Weakness	Kidney recovery	Tubular and Glomerular lesions
Dargelos et al. (2020) [20]	Case Report	3	67 (63-72)	3:0	HTN; DM	Fever; Dyspnea	Kidney deterioration; Death	Tubular and Glomerular lesions
Diao et al. (2021) [21]	Coorte	6	69 (51-86)	2:2	HTN	-	Death	Tubular and Glomerular lesions

Authors	Type of study	Number of patients	Mean age (range)	Male:Female	Mean Comorbidity	Clinical Presentation	Outcome	Main renal alterations
Fabritiis et al. (2021) [22]	Case Report	1	35	1:0	Absent	Foamy urine	Improvement in renal symptoms and in lab tests	Tubular and Glomerular lesions
Farkash et al. (2020) [23]	Case Report	1	53	1:0	Dyslipidemia; Obesity	-	Death	No changes
Gambella et al. (2022) [24]	Case Series	8	54 (15-80)	4:4	HTN; DM; Obesity; RA	Fever; Limb edema; Weakness	-	Glomerular, Vascular and Tubular
Gandhi et al. (2021) [25]	Case Report	1	27	1:0	HTN	HBP; Abdominal pain	Kidney deterioration	Tubular and Vascular lesions
Golmai et al. (2020) [26]	Case Series	11	69 (49-92)	9:2	HTN; DM	-	Death	Glomerular, Vascular and Tubular
González et al. (2020) [27]	Case Report	2	78	2:0	HTN; DM; Dyslipidemia	-	Death	Tubular and Vascular lesions
Gupta et al. (2020) [28]	Case Report	2	54;71	2:0	HTN; DM	Fever; Limb edema; Oliguria; Frequent urination; Nausea and vomit	Kidney deterioration; Improvement in renal symptoms	Glomerular, Vascular and Tubular
Hanley et al. (2020) [29]	Case Series	8	64 (22-97)	6:2	HTN; DM; CAD	Fever; Abdominal pain; Diarrhea; Dyspnea	Death	Tubular and Vascular lesions
Jalalzadeh et al. (2021) [30]	Case Report	1	46	0:1	DM	HBP; Limb edema; Abdominal pain; Nausea and vomit; Diarrhea	-	Tubular and Glomerular lesions
Korotchaeva et al. (2021) [31]	Case Report	1	49	0:1	Absent	Fever; Oliguria; Abdominal pain; Nausea and vomit; Diarrhea;	Improvement in lab tests	Tubular and Vascular lesions

Authors	Type of study	Number of patients	Mean age (range)	Male:Female	Mean Comorbidity	Clinical Presentation	Outcome	Main renal alterations
Laboux et al. (2021) [32]	Case Report	1	57	1:0	HTN	Tachypnea Fever; Oliguria; Diarrhea	Kidney recovery	Tubular and Glomerular lesions
León-Román et al. (2022) [33]	Coorte	1	64	1:0	Absent	Fever; Dyspnea	Kidney recovery	Tubular and Glomerular lesions
Li et al. (2021) [34]	Case Report	1	30	1:0	-	Fever; Abdominal pain; Nausea and vomit	Improvement in renal symptoms	Tubular and Glomerular lesions
Magoon et al. (2020) [35]	Case Report	1	28	0:1	-	Fever; Weakness; Dyspnea	Kidney recovery	Tubular and Glomerular lesions
Maritati et al. (2021) [36]	Case Report	1	64	0:1	HTN	Dyspnea	Improvement in renal symptoms	Tubular and Glomerular lesions
Moeinzadeh et al. (2020) [37]	Case Report	1	25	1:0	Absent	Weakness	Improvement in renal symptoms	Only glomerular lesions
N et al. (2022) [38]	Case Report	2	13;16	2:0	Absent	Anasarca; Oliguria; Nausea and vomit; Diarrhea	Death	Tubular and Glomerular lesions
Nomura et al. (2022) [39]	Case Series	5	10 (5-18)	3:2	Absent; DM (n=1)	Fever; Hematuria; Nausea and vomit; Diarrhea; Dyspnea;	Kidney deterioration; Improvement in lab tests	Glomerular and Vascular lesions
Nowak et al. (2021) [40]	Case Report	1	34	1:0	HTN	Fever; Backache; Abdominal pain; Diarrhea; Dyspnea	Kidney recovery	Tubular and Glomerular lesions
Peleg et al.(2020) [41]	Case Report	1	46	1:0	Obesity	Limb edema; Oliguria; Abdominal pain; Nausea and	-	Glomerular, Vascular and Tubular

Authors	Type of study	Number of patients	Mean age (range)	Male:Female	Mean Comorbidity	Clinical Presentation	Outcome	Main renal alterations
Pérez et al. (2021) [42]	Case Report	1	88	1:0	HTN; Dyslipidemia	vomit Limb edema; Dyspnea	Kidney deterioration	Tubular and Glomerular lesions
Pinte et al. (2022) [43]	Case Report	1	23	1:0	HTN	HBP	Kidney deterioration	Only glomerular lesions
Rapkiewicz et al. (2020) [44]	Case Series	6	56 (44-64)	2:4	HTN; DM; Dyslipidemia; Obesity	Fever; Dyspnea	Death	Tubular and Vascular lesions
Sebastian et al. (2021) [45]	Case Series	4	35 (18-53)	2:2	Absent	Fever; Hematuria; Nausea and vomit	Improvement in renal symptoms	Glomerular, Vascular and Tubular
Serafineli et al. (2021) [46]	Case Series	2	10;12	0:2	Absent	Weakness; Hematuria	Kidney recovery	Glomerular, Vascular and/ Tubular
Sharma P. et al. (2020) [47]	Case Series	8	68 (60-77)	4:4	HTN; DM; Dyslipidemia	Weakness; Dyspnea; Fever	Kidney recovery; Death	Glomerular, Vascular and Tubular
Sharma Y. et al. (2020) [48]	Case Report	2	49;67	2:0	HTN; DM; Dyslipidemia	HBP; Fever; Abdominal pain; Nausea and vomit; Diarrhea; Dyspnea	Kidney deterioration	Glomerular, Vascular and Tubular
Shetty et al. (2020) [49]	Case Series	3	61 (54-64)	2:1	HTN; DM	Fever; Diarrhea; Anuria; Limb edema	Kidney recovery; Kidney deterioration	Tubular and Glomerular lesions
Suso et al. (2020) [50]	Case Report	1	78	1:0	HTN; Dyslipidemia	HBP; Limb edema; Hematuria	Improvement in renal symptoms and in lab tests	Oly glomerular lesions
Szajek et al. (2021) [51]	Case Report	1	62	1:0	Dyslipidemia	Fever; Oliguria; Hematuria; Others	Kidney deterioration	Glomerular, Vascular and

Authors	Type of study	Number of patients	Mean age (range)	Male:Female	Mean Comorbidity	Clinical Presentation	Outcome	Main renal alterations
Tancredi et al. (2020) [52]	Case Report	1	38	0:1	DM; Obesity; Others	Nausea and vomit; Diarrhea; Dyspnea; Others	Improvement in renal symptoms and in lab tests	Tubular Oly glomerular lesions
Volbeda et al. (2021) [53]	Coorte	6	65 (49-78)	4:2	HTN; DM; Obesity.	Asymptomatic	Death	Glomerular, Vascular and Tubular
Yaghamaii et al. (2022) [54]	Case Report	1	10	1:0	Absent	HBP; Fever; Oliguria; Weakness	Improvement in renal symptoms and in lab tests	Tubular and Glomerular lesions
Zerehpooosh et al. (2021) [55]	Case Series	4	68 (47-78)	1:3	HTN; DM; Dyslipidemia	Fever; Dyspnea	Death	Tubular and Glomerular lesions

HTN: Hypertension; DM: Diabetes Mellitus

Table 2. Clinical presentation of the patients

Clinical presentation (symptomatology)	Total (= 128)	%
Not mentioned	20	15.6
Fever	47	36.7
Dyspnea	37	28.9
Urinary disorders (oliguria and hematuria)	21	16.4
High blood pressure	12	9.4
Lower back pain	12	9.4
Abdominal pain	12	9.4
Asymptomatic	11	8.6
Nausea and vomiting	11	8.6
Limb edema	10	7.8
Diarrhea	8	6.3
Weakness	8	6.3
Periorbital edema	3	2.3
Anasarca	1	0.8

Table 3. Lesions according to renal compartment

Compartment	Anatomopathological changes	With comorbidity		Without comorbidity	
		N	Total	N	Total
Glomerular	Hypercellularity	13	63	32	27
	Basement membrane changes	11		3	
	Sclerosis and hyalinosis	50		10	
	Podocytopathies	33		7	
	Deposition of immune complexes and antibodies	17		12	
Tubular	Tubular necrosis	70	84	8	20
	Tubulointerstitial nephritis	42		18	
	Cylinders and epithelium	15		3	
Vascular	Vascular injuries	44	39	9	8

Sclerosis and hyalinosis, tubular necrosis, tubulointerstitial nephritis and vascular lesions were the most common lesions, with a frequency greater than 40%. Overall, there was no common lesion for all patients. Regarding glomerular lesions, hypercellularity was observed in 35.4% (n=45) of patients, with 41.9% (n=32) in those without comorbidities and 33.3% (n=13) in those with comorbidities. Basement membrane changes were detected in 11% (n=14) of patients, with 9.6% (n=3) in those without comorbidities and 11.4% (n=11) in those with comorbidities. Sclerosis and hyalinosis were present in 47.2% (n=60) of patients, with 32.2% (n=10) in those without comorbidities and 52% (n=50) in those with comorbidities. Podocytopathies were identified in 31.5% (n=40) of patients, with 22.5% (n=7) in those without comorbidities and 34.3% (n=33) in those with comorbidities. Deposition of immune complexes and antibodies was found in 22.8% (n=29) of patients, with 38.7% (n=12) in those without comorbidities and 17.7% (n=17) in those with

comorbidities. Regarding tubular and interstitial lesions, tubular necrosis was present in 61.4% (n=78) of patients, predominantly in those with comorbidities (72.9%; n=70) compared to those without comorbidities (25.8%; n=8). Tubulointerstitial nephritis was observed in 47.2% (n=60) of patients, with 58% (n=18) in those without comorbidities and 43.7% (n=42) in those with comorbidities. Cylinders and epithelium were detected in 14.1% (n=18) of patients, with 9.6% (n=3) in those without comorbidities and 15.6% (n=15) in those with comorbidities. Additionally, vascular injuries were found in 41.7% (n=53) of patients, with 29% (n=9) in those without comorbidities and 45.8% (n=44) in those with comorbidities.

To identify the most common categories of injuries among patients, they were classified into seven groups (Table 4): (1) only Glomerular lesions 10.7% (n=13); (2) only Tubular lesions 8.2% (n=10); (3) only Vascular lesions 1.6% (n=2); (4) Tubular and Glomerular lesions 42.1%

(n=51); (5) Tubular and Vascular lesions 15.7% (n=19); (6) Glomerular and Vascular lesions 1.6% (n=2); (7) All three categories – Glomerular, Vascular, and Tubular – 19.8% (n=24). As shown in Table 2, the group with the highest frequency consisted of patients presenting tubular lesions together with glomerular lesions, accounting for 42.1% (n=51). This pattern was consistent in both patients with and without comorbidities. Notably, patients without comorbidities exhibited a predominance of glomerular lesions, with the group comprising glomerular lesions together with tubular lesions representing 15.1% (n=14) and the group with only glomerular lesions representing 25.8% (n=8). Conversely, patients with comorbidities displayed a higher prevalence of tubular lesions, with the group comprising glomerular lesions together with tubular lesions representing 41.1% (n=37), followed by the group with all three lesions representing 23.3% (n=21), and the group of tubular and vascular lesions representing 19.9% (n=17).

In this seven-group analysis, seven patients were not included. The anatomopathological description of the microscopic findings of the patients by Volbeda et al. (2021) was performed collectively, without a detailed description of each patient [53], thus precluding their classification into the seven groups of kidney injuries. Additionally, Farkash et al. (2020) presented a patient without kidney injury, but with visualized viral particles in renal tissues [23], leading to inclusion in the study without being part of the renal lesion analysis. Moreover, during the analysis of renal changes by sex, two patients by Diao et al. (2021) were excluded from the total number of patients due to lack of information on their sex [21]. Regarding microscopic findings by sex, no significant percentage differences were observed between groups (X^2 , $p=0.9671$). However, the predominant finding remained the group of patients with tubular lesions together with glomerular lesions, with 40.4% (n=19) in females and 41.6% (n=30) in males.

Table 4. Frequency of kidney injury categories found on microscopy

<u>Injury</u>	<u>Patients with comorbidity n (%)</u>	<u>Patients without comorbidities n (%)</u>	<u>Male n (%)</u>	<u>Female n (%)</u>	<u>Total patients n (%)</u>
Glomerular	5 (5,6)	8 (25,8)	7 (9,7)	6 (12,7)	13 (10,7)
Tubular	9 (10)	1 (3,2)	7 (9,7)	3 (6,3)	10 (8,2)
Vascular	1 (1,1)	1 (3,2)	1 (1,4)	1 (2,1)	2 (1,6)
Tubular/Glomerular	37 (41,1)	14 (45,1)	30 (41,6)	19 (40,4)	51 (42,1)
Tubular/Vascular	17 (18,9)	2 (6,4)	10 (13,8)	9 (19,1)	19 (15,7)
Glomerular/Vascular	0 (0)	2 (6,4)	1 (1,4)	1 (2,1)	2 (1,6)
Glomerular/Tubular/Vascular	21 (23,3)	3 (9,6)	16 (22,2)	8 (17)	24 (19,8)

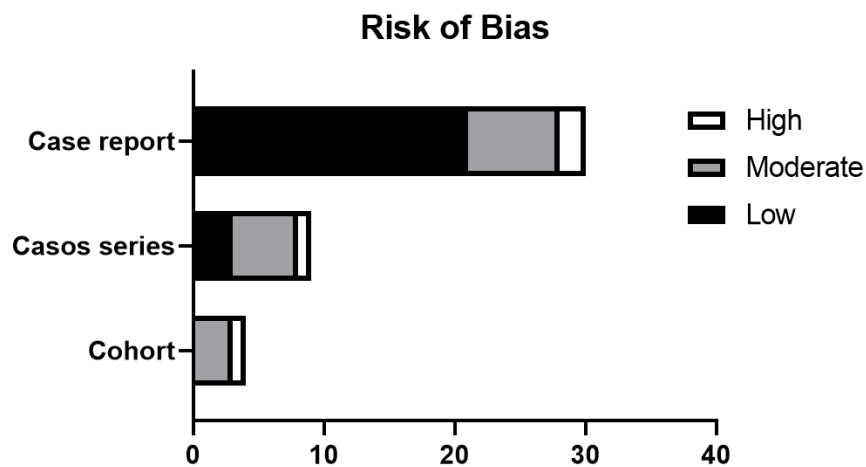


Fig. 2. Risk of Bias

Table 5. Comorbidities and the occurrence of kidney injuries

	HTN	DM	Obesity	HTN/ DM	HTN/ Obesity	DM/ Obesity	HTN/DM/O besity	Total
GL	2	-	-	1	-	1	1	5
TU	1	1	1	4	-	-	-	7
VAS	-	1	-	-	-	-	-	1
TU/GL	19	2	1	4	3	-	1	30
TU/VAS	3	-	1	3	1	-	4	12
GL/TU/VAS	9	2	4	5	1	-	2	23
Total	34	6	7	17	5	1	8	78

HTN: Hypertension; DM: Diabetes Mellitus; GL: Glomerular; TU: Tubular; VAS: Vascular

Furthermore, an analysis was conducted on patients with three comorbidities: hypertension, diabetes, and obesity, either isolated or combined. This analysis aimed to determine the most prevalent type of kidney injury in each comorbidity group (Table 5). Patients with hypertension most frequently exhibited lesions in the tubulo/glomerular compartment (n=19) and in the tubulo/glomerular/vascular compartment (n=9). In comparison, those with diabetes mellitus as their only comorbidity exhibited fewer lesions in the tubulo/glomerular compartment (n=2). However, hypertensive and diabetic patients showed a higher incidence of tubular (n=4), tubuloglomerular (n=4), and tubulo/glomerular/vascular (n=5) changes. Patients with obesity as the sole comorbidity most commonly displayed damage in the tubulo/glomerular/vascular compartment (n=4). Finally, individuals with all three comorbidities exhibited a greater number of lesions in the tubular/vascular compartments (n=4). In summary, systemic arterial hypertension emerged as the primary comorbidity predisposing patients to kidney damage.

3.3 Risk of Bias Assessment

The comprehensive evaluation of study quality revealed predominantly favorable outcomes. Among the total studies, 24 demonstrated low risk, 15 exhibited moderate risk, and only four were deemed high risk. Fig. 2 visually encapsulates the risk of bias assessment for the included studies.

4. DISCUSSION

This systematic review provides valuable insights about COVID-19-induced kidney injury in patients without a prior history of kidney disease. The findings reveal the multifaceted nature of renal pathology associated with SARSCoV-2 infection. Glomerular lesions, particularly those

resembling Focal and Segmental Glomerulosclerosis, have been frequently observed, along with tubular alterations, including tubular necrosis, tubulointerstitial nephritis, and the presence of casts and epithelium in the tubular tissue. Our findings suggest that the renal complications of COVID-19 are not solely due to direct viral activity but also involve a complex interplay of immune responses and inflammation. Furthermore, the presence of comorbidities in numerous patients may indicate the existence of previously unidentified renal injury, particularly given that these comorbidities, such as hypertension, diabetes, and obesity, progressively affect renal function over time.

4.1 Main renal alterations

Glomerular lesions are one of the main renal alterations found in the patients of the present study. Among the alterations found, Segmental and Focal Glomerulosclerosis (FSGS) stands out, present in 21 patients and its variant Segmental and Focal Collapsing Glomerulosclerosis, evidenced in 20 patients. Other glomerular alterations, such as Minimal Change Disease and Rapidly Progressive Glomerulonephritis were also found. Wu et al. [56] and Laboux et al. [32] studies indicate an increased prevalence of collapsing FSGS in patients who have high-risk APOL1 genotypes, more common in individuals of African descent. The presence of this gene, together with the release of cytokines promoted by SARS-Cov-2 infection, can cause glomerular lesions characteristic of collapsing FSGS [32,56,57].

Tubular alterations were identified in approximately 75 of patients with comorbidities, either associated with glomerular lesions or associated with vascular lesions. Among patients without comorbidities, 17 cases were reported. The tubular alterations that are described by the

analyzed authors refer to tubular necrosis, tubulointerstitial nephritis and the presence of casts and epithelium in the tubular tissue. In a study with 18 patients without previous kidney disease, Fukao et al. (2021) [64] analyzed data from urinary biomarkers with inflammatory indicators and identified high levels of IL-6 in patients with positive PCR as a marker of tubular injury, suggesting a severe systemic inflammatory state involved in the pathogenesis of this structure.

Regarding vascular lesions, the infection by SARS-CoV-2 may be associated with thrombotic microangiopathy present in renal infarction. Vasquez et al. [59], reported the case of a 21-year-old, healthy woman, using an oral contraceptive pill (OCP) and with a positive diagnosis for SARS-CoV-2 by PCR, presented multiple areas compatible with renal infarction in computed tomography. Excluding other precedents, COVID-19 infection and the use of OCP were accepted for this case as risk factors for the development of endothelial damage and microvascular thrombi as a cause of renal infarction [59]. A post-mortem histopathological analysis of 26 positive cases for COVID-19 corroborates our findings by observing severe endothelial injury in 3 cases and edema of endothelial cells with foamy degeneration in 5 cases with comorbidities. However, the authors suggest that endothelial injury is induced by direct infection of SARS-CoV-2 to the renal parenchyma [62].

4.2 Mechanisms of Renal Injury

The pathogenesis of glomerular lesions resulting from infection by Sars-Cov-2 is still unclear. There may be a direct viral effect on the kidneys due to ACE2 expression in podocytes and mesangial cells, allowing the virus to enter these cells [1,58]. Another hypothesis is the massive release of pro-inflammatory cytokines triggered by the immune response to the virus, which may cause glomerular lesions [1,58]. Regarding vascular lesions, activation the immune system, local and/or systemic inflammation can occur with consequent endothelial dysfunction and a hypercoagulable state. Thus, a SARS-CoV-2 infection may be associated with thrombotic microangiopathy present in renal infarction. Balbi et al. [60], analyzed serum samples from 83 patients and observed a 2.7-fold increase in circulating microparticles and extracellular vesicles (EV) in SARS-CoV-2 positive patients compared to SARS-CoV-2 negative patients and

healthy controls. Studies suggest that EV causes microthrombi in patients with COVID-19 by increasing specific markers such as CD9, CD63, CD81 and CD142 by inducing immune responses and initiating the coagulation cascade [60, 61].

The pathophysiological mechanisms related to tubular injury were identified in studies by several authors. Among them, tubular damage was correlated with the presence and cellular activity of Sars-Cov-2, since podocytes and tubular cells have high expression of receptors for ACE2. In this way, the cells of this tissue function as the main gateway for infection [63]. So, these findings suggest that the renal complications of COVID-19 are not solely due to direct viral activity but also involve a complex interplay of immune responses and inflammation.

4.3 Detection of Coronaviruses in Renal Tissues

Studies have reported that some patients with COVID-19 showed an elevated level of proteinuria, which suggests SARS-CoV-2 infection can cause acute kidney injury (AKI). ACE2 is widely expressed not only in the lungs, but also in other vital organs such as the kidney, and it interacts with viral spike protein [21]. However, it is still being questioned whether the kidney damage is directly mediated by presence of the virus or by a secondary to immune response [40]. Diao et al. [21] showed that SARS-CoV-2 nucleocapsid protein and spike antigens were found binding the ACE2 protein in the kidney tubules. Hypoxic damage-associated molecules, as DP2 and prostaglandin D synthase were also co-expressed, suggesting SARS-CoV-2 virus may be able to establish hypoxia and consequently lead to kidney injury [21].

On the other hand, another kidney injury mechanism is proposed, different from direct viral activity. Nowak et.al. [40] demonstrate that an unproportional immune response to the virus antigens may lead to cytokine storm, interferon release and mononuclear cells activation resulting in kidney inflammatory injury.

Among the articles analyzed, some cases were selected because they described the presence of viral particles in the kidney tissue, with a total of 11 patients (n=11) [15,17,21,23,42,46]. Of these patients, 8 had comorbidities and 3 did not. Azukaitis et al. (2022) identified few virus-like

particles intracellularly and confirmed their existence by electron microscopy analysis with immunohistochemical staining [15]. On the other hand, Farkash et al. (2020) visualized viral particles with nuclei of intermediate density, surrounded by an envelope with electro-dense tips in the form of a crown, but analysis by electron microscopy did not detect the virus [23].

Pérez et al. (2021) located viral particles with a double contour membrane and a characteristic crown in the podocyte cytoplasm [42], and Serafinelli et al. (2021) found in one of their patients virus-like particles in the tubular epithelium [46]. Both studies were positive in the immunohistochemical analysis, but had a negative Sars-Cov-2 RT-PCR. Finally, one last situation was described by Bradley et al. (2020) in which the renal tubular epithelium was positive for SARS-CoV-2 spike protein by immunohistochemistry in one of the patients [17]. The same situation of viral protein identification in the renal tubules was also observed in all six patients with biopsies analyzed by Diao et al. (2021) [21].

Among the renal lesions found in these patients, some similarities were presented. In both cases in which the viral particle was found and the immunohistochemical analysis was positive [42,46], endocapillary proliferation was observed in the renal tissue, presence of mesangial IgA and subendothelial and mesangial electro-dense deposits. Azukaitis et al. [15], similar to the cases reported by Pérez [42], reported that their patients had leukocyte infiltration and interstitial inflammation in the renal tissue. The patient described by Farkash (2020) did not show any kidney damage on biopsy [23]. No other similarities were found. On the other hand, a correlation can be made between the affected renal compartments, and the majority (72,7%; n=8) of all lesions presented refer to changes in glomerular diseases and tubulars. In addition, 9% (n=1) of the lesions presented refer to glomerular and vascular diseases and 9% (n=1) are due to glomerular, tubular and vascular injury. The study carried out by Azukaitis et al. (2022) was the one that most documented tubular and interstitial lesions [15], and the study by Pérez et al. [42] identified many glomerular lesions.

It is important to emphasize the presence or absence of comorbidities among patients in whom viral particles were detected in renal tissue. The individuals reported by Azukaitis et

al. [15] and Serafinelli et al. [46] did not present any comorbidity, whereas the patients described by Farkash et al. [23], Bradley et al. [17] and Pérez et al. (2021) [42] had dyslipidemia and other unrelated diseases, in addition to hypertension [42] and other cardiovascular diseases [23]. Among the 6 patients reported by Diao et al. [21], two of them had no comorbidity, while the other four had hypertension, and one of them still had other cardiovascular diseases.

4.4 Relation to Comorbidities and Systemic Disorders

In our analysis between comorbidities and the occurrence of kidney injuries, hypertension alone was notoriously the comorbidity most associated with the occurrence of kidney injuries. According to Ejaz et al. [65], uncontrolled hypertension was associated with an increased risk for infection by SARS-VOC-2 as well as a high rate of morbidity and mortality [65]. Wang et al. (2020) reported that the prevalence of hypertension was higher among those patients who required intensive care compared to those who did not [61]. The increased propensity for infection by SARS-COV-2 in hypertensive patients seems to be related to the imbalance in the renin-angiotensin-aldosterone system, the main pathway involved in blood pressure control. According to Ejaz et al. (2020), a decrease in angiotensin II converting enzyme (ACE II) and angiotensin 1-7 levels, in addition to an increase in ACE and angiotensin II concentrations were associated with an increased risk of developing COVID-19 in its severe form [65]. In a study published by Schiffrin et al. (2020), ACE II appears to have an anti-inflammatory role, protecting against lung and kidney damage, which are common complications of COVID-19 in its most severe spectrum [66]. Therefore, the reduction of this enzyme in hypertensive patients is probably related to the greater amount of kidney damage that we observed in the hypertensive patients in our study.

Diabetes was another comorbidity evaluated in our study. Diabetic patients developed fewer kidney lesions compared to hypertensive patients, but it was still a comorbidity associated with a negative renal outcome. Ejaz et. al. (2020) revealed that diabetic people are more likely to contract infections by sars-cov-2 due to impaired function of phagocytic cells, as well as an increased level of receptors for ACE II, key receptor for the interaction between virus-host [65].

Finally, obesity was another comorbidity associated with the occurrence of kidney damage in patients with COVID-19. Fresan et al. (2020), in a cohort of 433,995 patients, showed that patients had an increased risk of hospitalization and of developing severe forms of the disease [67]. The prevalence of severe forms of the disease in obese patients, according to a study published by Gao et al. (2021), seems to be related to restrictive ventilatory effects caused by excessive abdominal fat, as well as a prothrombotic state, impaired immune function, chronic inflammation in low grade, and increases in ACE II receptor expression in adipose and cardiovascular tissue [68].

The most frequent renal alterations found in this review were tubular lesions associated with glomerular lesions, both in patients with comorbidity and in those without comorbidity, with glomerular lesions being the main alterations. The number of patients with detection of the virus in the renal tissue was small, corroborating the hypothesis that the renal lesion can be multifactorial, not only directly caused by the virus. In addition, studies point to a greater predominance of renal involvement in patients with associated comorbidities, mainly arterial hypertension, which suggests a greater risk factor, although it also occurs in smaller numbers in patients without comorbidities.

5. CONCLUSION

In summary, our analysis underscores the pivotal role of comorbidities, particularly hypertension, diabetes, and obesity, in both the frequency and intensity of kidney injuries among COVID-19 patients. Notably, hypertension emerges as a substantial risk factor in this context. While the direct detection of viral particles in renal tissues remains limited, the findings presented in this review illuminate the intricate nature of kidney injury induced by SARS-CoV-2. This multifaceted manifestation can stem either directly from the virus's impact on kidney tissue or as a consequence of the systemic response to the viral infection. The comprehensive insights gleaned from this study contribute to a nuanced understanding of the renal implications associated with COVID-19, paving the way for targeted interventions and further research in this critical area.

6. LIMITATIONS

This review has limitations, as it was developed mostly from case reports or case series. Many

articles that addressed the theme had to be excluded, as they had not performed a renal biopsy. Some articles had no description of electron microscopy to confirm the presence or absence of Sars-Cov-2 viral particles, others articles did not perform immunohistochemistry for Spike protein. Despite these limitations, our study provides a selective analysis of COVID-19 kidney damage in patients who did not have a prior kidney disease. In addition, the presence of previous comorbidities was also observed in these patients and their relationship with the development of kidney damage associated with infection by Sars-Cov-2.

CONSENT AND ETHICAL APPROVAL

It is not applicable.

FUNDING

KHS is part of the "Minas Gerais Artificial Intelligence Network in Human Reproduction" supported by FAPEMIG (RED-00135-22), and he is a recipient of CNPq (303206/2022-5), which had no role in the conduct of the research or preparation of this manuscript.

ACKNOWLEDGEMENTS

The authors thank National Council for Scientific and Technological Development (CNPq), Coordination for the Improvement of Higher Education Personnel (CAPES) and Fundação de Amparo à Pesquisa do Estado de Minas Gerais (FAPEMIG).

COMPETING INTERESTS

Authors have declared that no competing interests exist.

REFERENCES

1. Hilton J, Boyer N, Nadim MK, et al. COVID-19 and Acute Kidney Injury. *Crit Care Clin.* 2022;38:473–489. Available:<https://doi.org/10.1016/j.ccc.2022.01.002>
2. Cai X, Wu G, Zhang J, Yang L. Risk factors for acute kidney injury in adult patients with COVID-19: A systematic review and meta-analysis. *Front Med.* 2021;8:719472. Available:<https://doi.org/10.3389/fmed.2021.719472>

3. Rostami Z, Mastrangelo G, Einollahi B, et al. A prospective study on risk factors for acute kidney injury and all-cause mortality in hospitalized COVID-19 patients from Tehran (Iran). *Front Immunol.* 2022;13:874426. Available:<https://doi.org/10.3389/fimmu.2022.874426>
4. Chávez-Valencia V, Orizaga-de-la-Cruz C, Lagunas-Rangel FA. Acute kidney injury in COVID-19 patients: Pathogenesis, clinical characteristics, therapy, and mortality. *Diseases.* 2022;10:53. Available:<https://doi.org/10.3390/diseases10030053>
5. Musiał K. Update on innate immunity in acute kidney injury—lessons taken from COVID-19. *Int J Mol Sci.* 2022;23:12514. Available:<https://doi.org/10.3390/ijms232012514>
6. Medeiros T, Guimarães GMC, Carvalho FR, et al. Acute kidney injury associated to COVID-19 leads to a strong unbalance of circulant immune mediators. *Cytokine.* 2022;157:155974. Available:<https://doi.org/10.1016/j.cyto.2022.155974>
7. Sabaghian T, Kharazmi AB, Ansari A, et al. COVID-19 and Acute Kidney Injury: A Systematic Review. *Front Med.* 2022;9:705908. Available:<https://doi.org/10.3389/fmed.2022.705908>
8. Kolhe NV, Fluck RJ, Selby NM, Taal MW. Acute kidney injury associated with COVID-19: A retrospective cohort study. *Plos Med.* 2020;17:e1003406. Available:<https://doi.org/10.1371/journal.pmed.1003406>
9. Esposito P, Russo E, Picciotto D, et al. Changes of acute kidney injury epidemiology during the COVID-19 pandemic: A retrospective cohort study. *J Clin Med.* 2022;11:3349. Available:<https://doi.org/10.3390/jcm11123349>
10. Moher D, Liberati A, Tetzlaff J, et al. Preferred reporting items for systematic reviews and meta-analyses: The PRISMA Statement. *Plos Med.* 2009;6:E1000097. Available:<https://doi.org/10.1371/journal.pmed.1000097>
11. Wells, GA, Shea, B, O'Connell, D, et al. The Newcastle-Ottawa Scale (NOS) for assessing the quality of nonrandomised studies in meta-analyses; 2011.
12. Aromataris E, Fernandez R, Godfrey CM, et al. Summarizing systematic reviews: Methodological development, conduct and reporting of an umbrella review approach. *Int J Evid Based Healthc.* 2015;13:132–140. Available:<https://doi.org/10.1097/XEB.000000000000055>
13. Akilesh S, Nast CC, Yamashita M, et al. Multicenter clinicopathologic correlation of kidney biopsies performed in COVID-19 patients presenting with acute kidney injury or proteinuria. *Am J Kidney Dis.* 2021;77:82-93.e1. Available:<https://doi.org/10.1053/j.ajkd.2020.10.001>
14. Alawad MJ, Subahi EA, Al-Ani HA, et al. A case of crescentic glomerulonephritis in a patient with COVID-19 infection: A case report and literature review. *Medicine (Baltimore).* 2022;101:e28754. Available:<https://doi.org/10.1097/MD.00000000000028754>
15. Azukaitis K, Besusparis J, Laurinavicius A, Jankauskiene A. Case Report: SARS-CoV-2 Associated Acute Interstitial Nephritis in an Adolescent. *Front Pediatr.* 2022;10:861539. Available:<https://doi.org/10.3389/fped.2022.861539>
16. Basiratnia M, Derakhshan D, Yeganeh BS, Derakhshan A. Acute necrotizing glomerulonephritis associated with COVID-19 infection: Report of two pediatric cases. *Pediatr Nephrol.* 2021;36:1019–1023. Available:<https://doi.org/10.1007/s00467-021-04944-w>
17. Bradley BT, Maioli H, Johnston R, et al. Histopathology and ultrastructural findings of fatal COVID-19 infections in Washington State: A case series. *The Lancet.* 2020;396:320–332. Available:[https://doi.org/10.1016/S0140-6736\(20\)31305-2](https://doi.org/10.1016/S0140-6736(20)31305-2)
18. Buyansky D, Fallaha C, Gougeon F, et al. Acute tubulointerstitial nephritis in a patient on anti-programmed death-Ligand 1 Triggered by COVID-19: A Case Report. *Can J Kidney Health Dis.* 2022;8:205435812110147. Available:<https://doi.org/10.1177/20543581211014745>
19. Couturier A, Ferlicot S, Chevalier K, et al. Indirect effects of severe acute respiratory syndrome coronavirus 2 on the kidney in coronavirus disease patients. *Clin Kidney J.* 2020;13:347–353.

- Available:<https://doi.org/10.1093/ckj/sfaa088>
20. Dargelos M, Couturier A, Ferlicot S, et al. Severe acute respiratory syndrome coronavirus 2 indirectly damages kidney structures. *Clin Kidney J.* 2020;13:1101–1104. Available:<https://doi.org/10.1093/ckj/sfaa209>
 21. Diao B, Wang C, Wang R, et al. Human kidney is a target for novel severe acute respiratory syndrome coronavirus 2 infection. *Nat Commun.* 2021;12:2506. Available:<https://doi.org/10.1038/s41467-021-22781-1>
 22. De Fabritiis M, Angelini ML, Fabbriozio B, et al. Renal thrombotic microangiopathy in concurrent covid-19 vaccination and infection. *Pathogens.* 2021;10:1045. Available:<https://doi.org/10.3390/pathogens10081045>
 23. Farkash EA, Wilson AM, Jentzen JM. Ultrastructural evidence for direct renal infection with SARS-CoV-2. *J Am Soc Nephrol.* 2020;31:1683–1687. Available:<https://doi.org/10.1681/ASN.2020040432>
 24. Gambella A, Barreca A, Biancone L, et al. Spectrum of kidney injury following COVID-19 Disease: Renal biopsy findings in a single Italian pathology service. *Biomolecules.* 2022;12:298. Available:<https://doi.org/10.3390/biom12020298>
 25. Gandhi B, Jebakumar D, Nickell M, Narayanan M. Thrombotic microangiopathy with multiorgan involvement following COVID-19. *Bayl Univ Med Cent Proc.* 2022;35:204–206. Available:<https://doi.org/10.1080/08998280.2021.1997054>
 26. Golmai P, Larsen CP, DeVita MV, et al. Histopathologic and ultrastructural findings in postmortem kidney biopsy material in 12 Patients with AKI and COVID-19. *J Am Soc Nephrol.* 2020;31:1944–1947. Available:<https://doi.org/10.1681/ASN.2020050683>
 27. González Pessolani T, Muñoz Fernández De Legaria M, Elices Apellániz M, et al. Multi-organ pathological findings associated with COVID-19 in postmortem needle core biopsies in four patients and a review of the current literature. *Rev Esp Patol.* 2021;54:275–280. Available:<https://doi.org/10.1016/j.patol.2020.09.003>
 28. Gupta RK, Bhargava R, Shaikat A-A, et al. Spectrum of podocytopathies in new-onset nephrotic syndrome following COVID-19 disease: A report of 2 cases. *BMC Nephrol.* 2020;21:326. Available:<https://doi.org/10.1186/s12882-020-01970-y>
 29. Hanley B, Naresh KN, Roufousse C, et al. Histopathological findings and viral tropism in UK patients with severe fatal COVID-19: A post-mortem study. *Lancet Microbe.* 2020;1:e245–e253. Available:[https://doi.org/10.1016/S2666-5247\(20\)30115-4](https://doi.org/10.1016/S2666-5247(20)30115-4)
 30. Jalalzadeh M, Valencia-Manrique JC, Boma N, et al. Antineutrophil Cytoplasmic Antibody-Associated Glomerulonephritis in a Case of Scleroderma After Recent Diagnosis With COVID-19. *Cureus;* 2021. Available:<https://doi.org/10.7759/cureus.12485>
 31. Korotchayeva J, Chebotareva N, Andreeva E, et al. Thrombotic microangiopathy triggered by COVID-19: Case Reports. *Nephron.* 2022;146:197–202. Available:<https://doi.org/10.1159/000520144>
 32. Laboux T, Gibier J-B, Pottier N, et al. COVID-19-related collapsing glomerulopathy revealing a rare risk variant of APOL1: lessons for the clinical nephrologist. *J Nephrol.* 2021;34:373–378. Available:<https://doi.org/10.1007/s40620-020-00935-6>
 33. León-Román J, Agraz I, Vergara A, et al. COVID-19 infection and renal injury: Where is the place for acute interstitial nephritis disease? *Clin Kidney J.* 2022;15:1698–1704. Available:<https://doi.org/10.1093/ckj/sfac079>
 34. Li NL, Papini AB, Shao T, Girard L. Immunoglobulin-a vasculitis with renal involvement in a patient with covid-19: a case report and review of acute kidney injury related to SARS-CoV-2. *Can J Kidney Health Dis.* 2021;8:205435812199168. Available:<https://doi.org/10.1177/2054358121991684>
 35. Magoon S, Bichu P, Malhotra V, et al. COVID-19–Related Glomerulopathy: A Report of 2 Cases of Collapsing Focal Segmental Glomerulosclerosis. *Kidney Med.* 2020;2:488–492. Available:<https://doi.org/10.1016/j.xkme.2020.05.004>

36. Maritati F, Moretti MI, Nastasi V, et al. ANCA-Associated glomerulonephritis and anti-phospholipid syndrome in a patient with SARS-CoV-2 infection: Just a coincidence? *Case Rep Nephrol Dial.* 2021;11:214–220. Available:<https://doi.org/10.1159/000517513>
37. Moeinzadeh, Firouzeh, Dezfouli, Majid, Naimi, Azar, et al. Newly diagnosed glomerulonephritis during covid-19 infection undergoing immunosuppression therapy, A case report. *Iran. J. Kidney Dis.* 2020;239-242.
38. NV, Singh RKN, Kumari N, et al. A Novel Association between Coronavirus Disease 2019 and Normocomplementemic Rapidly Progressive Glomerulonephritis-Crescentic Immunoglobulin A Nephropathy: A Report of Two Pediatric Cases. *Cureus*; 2022. Available:<https://doi.org/10.7759/cureus.22077>
39. Nomura E, Finn LS, Bauer A, et al. Pathology findings in pediatric patients with COVID-19 and kidney dysfunction. *Pediatr Nephrol*; 2022;37: 2375–2381. Available:<https://doi.org/10.1007/s00467-022-05457-w>
40. Nowak PJ, Forycka J, Cegielska N, et al. Glucocorticoids induce partial remission of focal segmental glomerulosclerosis but not interstitial nephritis in COVID-19 Acute Kidney Injury in an APOL1 Low-Risk Genotype White Patient. *Am J Case Rep* 22; 2021. Available:<https://doi.org/10.12659/AJCR.933462>
41. Peleg Y, Kudose S, D'Agati V, et al. Acute kidney injury due to collapsing glomerulopathy following COVID-19 Infection. *Kidney Int Rep.* 2020;5:940–945. Available:<https://doi.org/10.1016/j.ekir.2020.04.017>
42. Pérez A, Torregrosa I, D'Marco L, et al. IgA-dominant infection-associated glomerulonephritis following SARS-CoV-2 Infection. *Viruses.* 2021;13:587. Available:<https://doi.org/10.3390/v13040587>
43. Pinte L, Sorohan BM, Prohászka Z, et al. COVID-19: A trigger for severe thrombotic microangiopathy in a patient with complement gene variant. *Rom J Intern Med.* 2022;60:138–142. Available:<https://doi.org/10.2478/rjim-2021-0040>
44. Rapkiewicz AV, Mai X, Carsons SE, et al. Megakaryocytes and platelet-fibrin thrombi characterize multi-organ thrombosis at autopsy in COVID-19: A case series. *Eclinicalmedicine.* 2020;24:100434. Available:<https://doi.org/10.1016/j.eclinm.2020.100434>
45. Sebastian R, Arunachalam J, Rajendran M. Temporal clustering of antiglomerular basement membrane disease in COVID-19 Pandemic: A Case Series. *Int J Nephrol Renov Dis.* 2021;14:393–398. Available:<https://doi.org/10.2147/IJNRD.S333894>
46. Serafinelli J, Mastrangelo A, Morello W, et al. Kidney involvement and histological findings in two pediatric COVID-19 patients. *Pediatr Nephrol.* 2021;36:3789–3793. Available:<https://doi.org/10.1007/s00467-021-05212-7>
47. Sharma P, Uppal NN, Wanchoo R, et al. COVID-19–Associated Kidney Injury: A Case Series of Kidney Biopsy Findings. *J Am Soc Nephrol.* 2020;31:1948–1958. Available:<https://doi.org/10.1681/ASN.2020050699>
48. Sharma Y, Nasr SH, Larsen CP, et al. COVID-19–Associated collapsing focal segmental glomerulosclerosis: A report of 2 cases. *Kidney Med.* 2020;2:493–497. Available:<https://doi.org/10.1016/j.xkme.2020.05.005>
49. Shetty AA, Tawhari I, Safar-Boueri L, et al. COVID-19–associated glomerular disease. *J Am Soc Nephrol.* 2021;32:33–40. Available:<https://doi.org/10.1681/ASN.2020060804>
50. Suso AS, Mon C, Oñate Alonso I, et al. IgA Vasculitis with Nephritis (Henoch–Schönlein Purpura) in a COVID-19 Patient. *Kidney Int Rep.* 2020;5:2074–2078. Available:<https://doi.org/10.1016/j.ekir.2020.08.016>
51. Szajek K, Kajdi M-E, Luyckx VA, et al. Granulomatous interstitial nephritis in a patient with SARS-CoV-2 infection. *BMC Nephrol.* 2021;22:19. Available:<https://doi.org/10.1186/s12882-020-02213-w>
52. Tancredi T, DeWaters A, McGillen KL. Renal ultrasound findings secondary to COVID-19 related collapsing focal segmental glomerulosclerosis – A case report. *Clin Imaging.* 2021;71:34–38. Available:<https://doi.org/10.1016/j.clinimag.2020.11.011>

53. Volbeda M, Jou-Valencia D, Van Den Heuvel MC, et al. Comparison of renal histopathology and gene expression profiles between severe COVID-19 and bacterial sepsis in critically ill patients. *Crit Care*. 2021;25:202. Available:<https://doi.org/10.1186/s13054-021-03631-4>
54. Najafi Z Renal Involvement in a Child with COVID-19 Infection and its Management with CRRT. *Int J Prev Med*. 2022;13:19:1–4.
55. Bidari Zerehpooosh F, Sabeti S, Bahrami-Motlagh H, et al. Post-mortem histopathologic findings of vital organs in critically ill patients with COVID-19. *Arch Iran Med*. 2021;24:144–151. Available:<https://doi.org/10.34172/aim.2021.23>
56. Wu H, Larsen CP, Hernandez-Arroyo CF, et al. AKI and Collapsing glomerulopathy associated with COVID-19 and APOL 1 High-Risk Genotype. *J Am Soc Nephrol*. 2020;31:1688–1695. Available:<https://doi.org/10.1681/ASN.2020050558>
57. Muehlig AK, Gies S, Huber TB, Braun F. Collapsing focal segmental glomerulosclerosis in viral infections. *Front Immunol*. 2022;12:800074. Available:<https://doi.org/10.3389/fimmu.2021.800074>
58. Hassler L, Reyes F, Sparks MA, et al. Evidence for and against direct kidney infection by sars-COV-2 in patients with COVID-19. *Clin J Am Soc Nephrol*. 2021;16:1755–1765. Available:<https://doi.org/10.2215/CJN.04560421>
59. Vasquez Espinosa WA, Santos Argueta A, Hurtado Tandazo VA, Vasquez Espinosa CF. A Case Report of a Young Female With Renal Infarction Secondary to Breakthrough COVID Infection. *Cureus*; 2022. Available:<https://doi.org/10.7759/cureus.25527>
60. Balbi C, Burrello J, Bolis S, et al. Circulating extracellular vesicles are endowed with enhanced procoagulant activity in SARS-CoV-2 infection. *EBioMedicine*. 2021;67:103369. Available:<https://doi.org/10.1016/j.ebiom.2021.103369>
61. Wang C, Yu C, Novakovic VA, et al. Circulating microparticles in the pathogenesis and early anticoagulation of thrombosis in Covid-19 with kidney injury. *Front Cell Dev Biol*. 2022;9:784505. Available:<https://doi.org/10.3389/fcell.2021.784505>
62. Su H, Yang M, Wan C, et al. Renal histopathological analysis of 26 postmortem findings of patients with COVID-19 in China. *Kidney Int*. 2020;98:219–227. Available:<https://doi.org/10.1016/j.kint.2020.04.003>
63. Aroca-Martínez G, Avendaño-Echavez L, Garcia C, et al. 10.1002/oby.23029. *Ir J Med Sci*. 2023;1971 - 192:923–927. Available:<https://doi.org/10.1007/s11845-022-02993-0>
64. Fukao Y, Nagasawa H, Nihei Y, et al. COVID-19-induced acute renal tubular injury associated with elevation of serum inflammatory cytokine. *Clin Exp Nephrol*. 2021;25:1240–1246. Available:<https://doi.org/10.1007/s10157-021-02101-z>
65. Ejaz H, Alsrhani A, Zafar A, et al. COVID-19 and comorbidities: Deleterious impact on infected patients. *J Infect Public Health*. 2020;13:1833–1839. Available:<https://doi.org/10.1016/j.jiph.2020.07.014>
66. Schiffrin EL, Flack JM, Ito S, et al. Hypertension and COVID-19. *Am J Hypertens*. 2020;33:373–374. Available:<https://doi.org/10.1093/ajh/hpaa057>
67. Fresán U, Guevara M, Elía F, et al. Independent role of severe obesity as a risk factor for COVID-19 hospitalization: A Spanish population-based cohort study. *Obesity*. 2021;29:29–37. Available:<https://doi.org/10.1002/oby.23029>
68. Gao Y, Ding M, Dong X, et al. Risk factors for severe and critically ill COVID-19 patients: A review. *Allergy*. 2021;76:428–455.
69. Available:<https://doi.org/10.1111/all.14657>

SUPPLEMENTARY

Table 1. Search strategy in the databases

<p style="text-align: center;">• English:</p> <p>(“Acute Kidney Injury” OR “Acute Kidney Injuries” OR “Acute Renal Injury” OR “Acute Renal Injuries” OR “Acute Renal Insufficiency” OR “Acute Kidney Insufficiencies” OR “Acute Renal Failure” OR “Acute Renal Failures” OR “Acute Kidney Failure” OR “Acute Kidney Failures” OR “Kidney Disease” OR “Kidney Diseases”) AND (COVID-19 OR “Coronavirus Infections” OR “SARS CoV 2 Infection” OR “SARS-CoV-2 Virus” OR “Severe Acute Respiratory Syndrome Coronavirus 2”)</p>
<p style="text-align: center;">• English/Portuguese/Spanish:</p> <p>(“Acute Kidney Injury” OR “Acute Kidney Injuries” OR “Acute Renal Injury” OR “Acute Renal Injuries” OR “Acute Renal Insufficiency” OR “Acute Kidney Insufficiencies” OR “Acute Renal Failure” OR “Acute Renal Failures” OR “Acute Kidney Failure” OR “Acute Kidney Failures” OR “Kidney Disease” OR “Kidney Diseases” OR “Lesão Renal Aguda” OR “Injúria Renal aguda” OR “Doença renal” OR “Doenças renais” OR “Nefropatia” OR “Nefropatias” OR “Lesión Renal Aguda” OR “Enfermedades renales”) AND (“COVID-19” OR “COVID19” OR “covid-19” OR “Coronavirus Infections” OR “SARS CoV 2 Infection” OR “SARS-CoV-2 Virus” OR “Severe Acute Respiratory Syndrome Coronavirus 2” OR “Doença Viral COVID-19” OR “Infecção pelo SARS-CoV-2” OR “Infecção por SARS-CoV-2” OR “Infecções por SARS-CoV-2” OR “Pandemia por COVID-19” OR “Infección por el SARS-CoV-2”)</p>
<p style="text-align: center;">• Portuguese/Spanish:</p> <p>(“Lesão Renal Aguda” OR “Injúria Renal aguda” OR “Doença renal” OR “Doenças renais” OR “Nefropatia” OR “Nefropatias” OR “Lesión Renal Aguda” OR “Enfermedades renales”) AND (“COVID-19” OR “COVID19” OR “covid-19” OR “Doença Viral COVID-19” OR “Infecção pelo SARS-CoV-2” OR “Infecção por SARS-CoV-2” OR “Infecções por SARS-CoV-2” OR “Pandemia por COVID-19” OR “Infección por el SARS-CoV-2”)</p>
<p style="text-align: center;">• Portuguese:</p> <p>(“Lesão Renal Aguda” OR “Injúria Renal aguda” OR “Doença renal” OR “Doenças renais” OR “Nefropatia” OR “Nefropatias”) AND (“COVID-19” OR “COVID19” OR “covid-19” OR “Doença Viral COVID-19” OR “Infecção pelo SARS-CoV-2” OR “Infecção por SARS-CoV-2” OR “Infecções por SARS-CoV-2” OR “Pandemia por COVID-19”)</p>
<p style="text-align: center;">• Spanish:</p> <p>(“Lesión Renal Aguda” OR “Enfermedades renales”) AND (“Infección por el SARS-CoV-2”)</p>

© Copyright (2024): Author(s). The licensee is the journal publisher. This is an Open Access article distributed under the terms of the Creative Commons Attribution License (<http://creativecommons.org/licenses/by/4.0>), which permits unrestricted use, distribution, and reproduction in any medium, provided the original work is properly cited.

Peer-review history:

The peer review history for this paper can be accessed here:

<https://www.sdiarticle5.com/review-history/115330>