



HAL
open science

Expiratory obstruction in patients with Duchenne muscular dystrophy under non-invasive ventilation: A step-by-step analysis of a new obstructive pattern

Antoine Léotard, Mathieu Delorme, Vincent Delord, Myriam Niel-Duriez, David Orlikowski, Djillali Annane, Hélène Prigent, Frédéric Lofaso

► To cite this version:

Antoine Léotard, Mathieu Delorme, Vincent Delord, Myriam Niel-Duriez, David Orlikowski, et al.. Expiratory obstruction in patients with Duchenne muscular dystrophy under non-invasive ventilation: A step-by-step analysis of a new obstructive pattern. *Chronic Respiratory Disease*, 2022, 18, pp.147997312110369. 10.1177/14799731211036901 . hal-04550960

HAL Id: hal-04550960

<https://hal.science/hal-04550960>

Submitted on 18 Apr 2024


HAL is a multi-disciplinary open access archive for the deposit and dissemination of scientific research documents, whether they are published or not. The documents may come from teaching and research institutions in France or abroad, or from public or private research centers.

L'archive ouverte pluridisciplinaire **HAL**, est destinée au dépôt et à la diffusion de documents scientifiques de niveau recherche, publiés ou non, émanant des établissements d'enseignement et de recherche français ou étrangers, des laboratoires publics ou privés.



Distributed under a Creative Commons Attribution - NonCommercial 4.0 International License

Expiratory obstruction in patients with Duchenne muscular dystrophy under non-invasive ventilation: A step-by-step analysis of a new obstructive pattern

Chronic Respiratory Disease
Volume 18: 1–5
© The Author(s) 2021
Article reuse guidelines:
sagepub.com/journals-permissions
DOI: 10.1177/14799731211036901
journals.sagepub.com/home/crd


Antoine Léotard^{1,2} , Mathieu Delorme³, Vincent Delord^{1,4}, Myriam Niel-Duriez⁵, David Orlikowski^{2,5,6}, Djillali Annane⁵, Hélène Prigent^{1,2} and Frédéric Lofaso^{1,2} 

Abstract

Purpose: Non-invasive ventilation (NIV) is the reference standard for managing chronic hypoventilation in patients with Duchenne muscular dystrophy (DMD). In these patients, upper airway obstruction under NIV may compromise efficacy and adherence. We aim to describe a novel pattern of expiratory obstructive events occurring during nocturnal barometric NIV. **Methods:** We retrospectively included all patients with DMD who underwent full-night polygraphy during NIV as part of their usual follow-up between May 2018 and July 2019. **Results:** We provide a step-by-step description of this previously undescribed pattern of obstruction. Expiratory obstructions lead to end-inspiratory breath-holding and impossibility to take another inspiratory breath with a barometric mode until expiration occurs. These events were observed in 4 (36%) of 11 DMD patients under barometric NIV. **Conclusion:** Expiratory obstructions may be common in DMD patients receiving NIV and should be sought out routinely. This previously undescribed variant of obstructive event must be identified.

Keywords

Duchenne muscular dystrophy, patient–ventilator asynchrony, neuromuscular diseases, sleep apnea, non-invasive ventilation

Date received: 13 February 2021; accepted: 13 July 2021

Background

Patients with Duchenne muscular dystrophy (DMD) may experience multimodal sleep-disordered breathing with early obstructive sleep apneas (OSAs) and, later during the disease, diaphragmatic failure and/or central apneas. The underlying pathophysiological mechanisms cover a wide range of causes that include macroglossia, respiratory muscle weakness, and cardiomyopathy.¹ Nocturnal non-invasive ventilation (NIV) has been shown to reduce the occurrence of sleep-related breathing events and to improve quality of life, sleep, and survival in patients with slowly progressive neuromuscular diseases (NMDs).^{1,2} However, obstructive or central apneas/hypopneas (AHs) may persist during NIV, compromising treatment efficacy and/or

¹Département de Physiologie, Explorations Fonctionnelles, Unité des Pathologies du Sommeil, AP-HP, Hôpital Raymond Poincaré, Garches, France

²Université Versailles–Saint-Quentin-en-Yvelines, END:ICAP U1179 Inserm, UFR des Sciences de la Santé–Simone-Veil, Versailles, France

³UVSQ, ERPHAN, Université Paris-Saclay, Versailles, France

⁴SOS Oxygène, Nice, France

⁵Service de Médecine Intensive Réanimation - Unité Fonctionnelle de Ventilation à Domicile, AP-HP, Hôpital Raymond Poincaré, Garches, France

⁶Centre d'Investigation Clinique I429, AP-HP, Hôpital Raymond Poincaré, Garches, France

Corresponding author:

Antoine Léotard, Département de Physiologie, Explorations Fonctionnelles, Unité des Pathologies du Sommeil, AP-HP, Hôpital Raymond Poincaré, 104 Boulevard Raymond Poincaré, Garches 92380, France.

Email: antoine.leotard@aphp.fr



Creative Commons Non Commercial CC BY-NC: This article is distributed under the terms of the Creative Commons Attribution-NonCommercial 4.0 License (<https://creativecommons.org/licenses/by-nc/4.0/>) which permits non-commercial use, reproduction and distribution of the work without further permission provided the original work is attributed as specified on the SAGE and Open Access pages (<https://us.sagepub.com/en-us/nam/open-access-at-sage>).

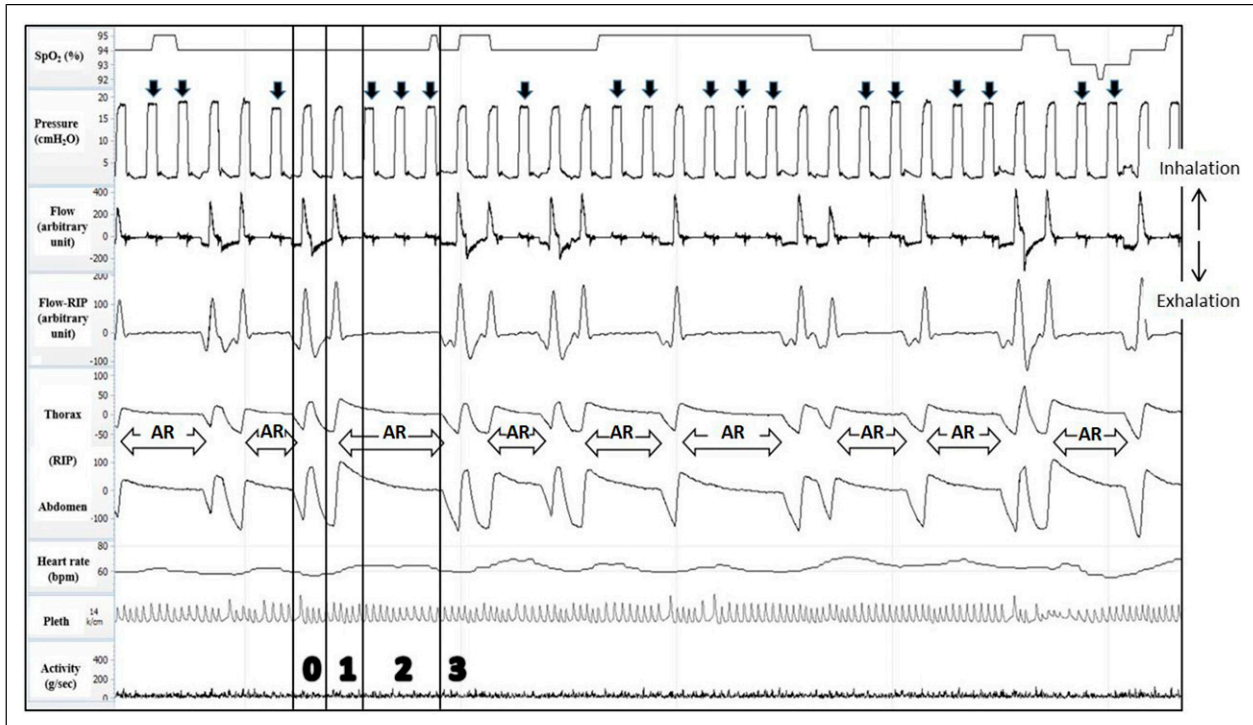


Figure 1. Successive complete obstructions beginning at exhalation with ineffective insufflations and air stacking (without leaks). Legend: The tracings are presented in the following order, from top to bottom: oxygen saturation (SpO_2), pressure, flow, respiratory inductive plethysmography (RIP) flow, thoracic movements, abdominal movements, heart rate, finger plethysmography (Pleth), and activity. Pressure and flow were measured with an external pressure sensor and with an external pneumotachograph. AR means air retention; the vertical black arrows point to ineffective insufflations and the vertical white arrows point to partially effective insufflations; the horizontal white arrows indicate expiratory obstructions. [0] appropriate patient–ventilator interaction: pressure increase is associated with adapted flow wave and synchronous thoraco-abdominal movements at both inhalation and exhalation; [1] expiratory obstruction: at the end of an effective insufflation, expiratory obstruction occurs (no significant exhalation observed before the next cycle on the flow, RIP flow, or thoraco-abdominal belts); [2] air stacking: complete (both inspiratory and expiratory) upper airway obstruction with three subsequent ineffective insufflations while the patient remained above the relaxed volume. We must underline that independently of the presence or not of upper airway obstruction, with a pressure mode, additional lung insufflation above the previous insufflation is not possible when reproducing the same inspiratory pressure according to the pressure–volume relationship; [3] apnea resolution: obstruction release begins with a tidal expiration characterized by a return to the relaxed volume as observed on the respiratory inductive plethysmography and flow signals.

patient's comfort.^{3,4} Upper airway obstruction during sleep is common in DMD and other NMDs and may persist under NIV due to inappropriate ventilator settings. Residual respiratory events may also be triggered by NIV, as the ventilator-induced decrease in ventilatory drive may induce central AHs with or without glottic closure.⁴ Furthermore, excessive tightening of the naso–buccal interface may result in obstructive events.⁵

The SomnoNIV group (a group of French experts on nocturnal ventilation during NIV) has published a systematic description of nocturnal respiratory events seen during NIV.^{3,6} Residual obstructive events under NIV occurred at different levels of the upper airway (glottis and/or pharynx), with or without an alteration in respiratory drive. The group has stated that the first step during NIV initiation is to prevent these events as they promote the occurrence of patient–ventilator asynchronies.⁶ The semiology of patient–ventilator interactions is now better understood, thanks to

the development by the SomnoNIV group of algorithms for analyzing polygraphs recorded during NIV.^{3,6}

Here, we provide a step-by-step analysis of a previously undescribed pattern of obstructive events during NIV. The occurrence of these events at exhalation with subsequent air retention has never been described to our knowledge.

Methods

At the first place, we identify an unusual pattern of obstruction when a 26-year-old man under barometric NIV with DMD was referred to our chronic ventilation unit with increased fatigue and morning headaches. We thus performed a full night polygraphy under NIV to seek for residual obstructive events or patient–ventilator asynchronies. This sleep recording highlights an important increase in residual apnea hypopnea index (25.5 events per hour) but

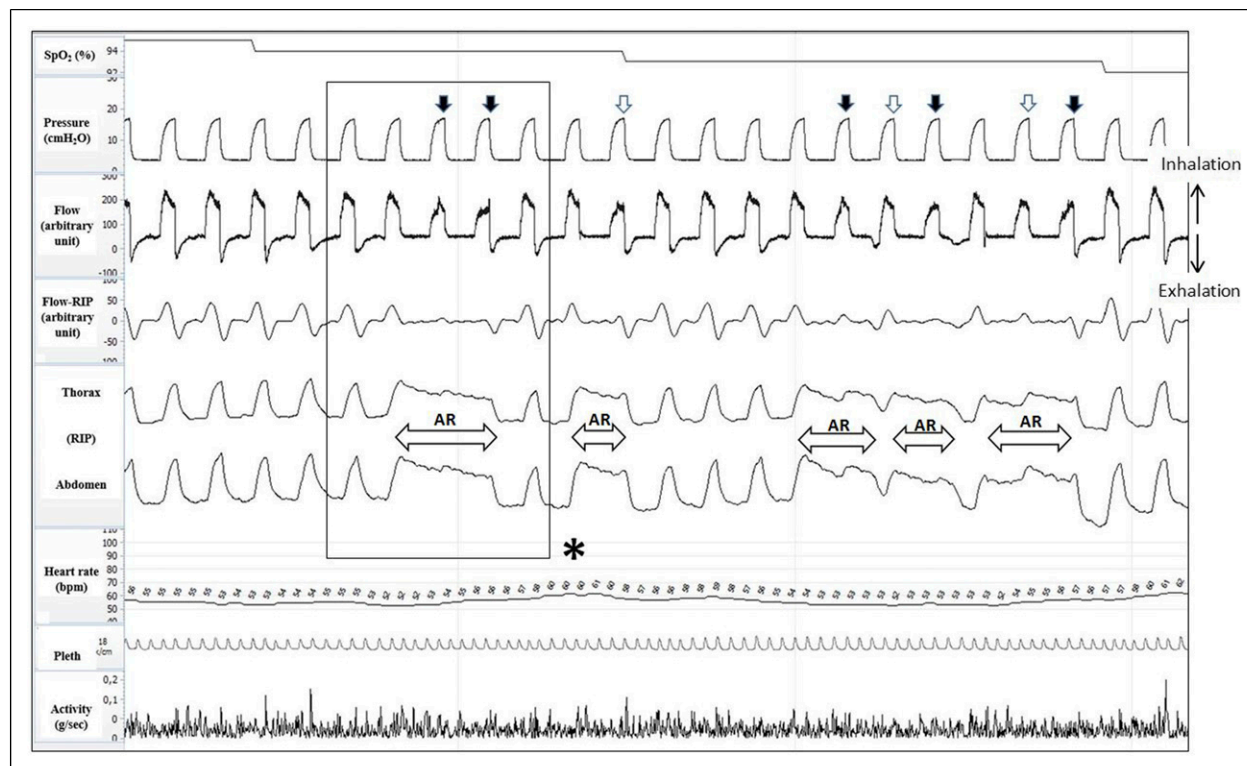


Figure 2. Brief and prolonged expiratory obstructions leading to ineffective and partially effective insufflations and leaks. Legend: The tracings are presented in the following order, from top to bottom: oxygen saturation (SpO_2), pressure, flow, respiratory inductive plethysmography (RIP) flow, thoracic movements, abdominal movements, heart rate, finger plethysmography (Pleth), and activity. Pressure and flow were measured with an external pressure sensor and with an external pneumotachograph. AR means air retention; the vertical black arrows point to ineffective insufflations and the vertical white arrows point to partially effective insufflations; the horizontal white arrows indicate expiratory obstructions. The presence of inspiratory flow during AR periods suggests occurrence of leaks due to the remaining inflation observed on the thoracic and abdominal belts (see Figure 3). * Detailed analysis provided in Figure 3.

with an uncommon obstructive pattern beginning at exhalation (Figure 1).

Based on this case, we retrospectively screened all sleep recordings performed between May 2018 and July 2019 at our tertiary care hospital, which is part of a national reference center for the management of NMDs. We included all patients with DMD who underwent full-night polygraphy during barometric NIV as part of their usual follow-up (Supplemental e-Figure 1) seeking for similar pattern of expiratory obstructions. All recordings were interpreted by the same investigator (F.L.). The main patient features are provided in the online supplement (Supplemental e-Tables 1 and 2).

Results

Description of the novel expiratory obstruction pattern

Expiratory obstructions (EOs) consisted in upper airway obstruction at the end of an effective insufflation, resulting in the absence of exhalation before the next cycle. No significant expiration was observed on the nasal flow signal

as well as thoracic and abdominal respiratory inductive plethysmography (RIP) signals eliminating presence of mouth expiration. Consequently, air retention occurred, with persistent inflation of the lungs. The next insufflations, with the same target pressure, remained ineffective until the occurrence of a tidal expiration characterized by a return to the relaxed volume and pressure (see RIP signals; Figure 1). Figures 2 and 3 provide a detailed step-by-step analysis of the phenomenon.

Results of the retrospective analysis

Among 21 DMD patients who underwent full-night polygraphy, 11 were ventilated with a barometric mode. Expiratory obstructions (EOs) occurred during NIV in 4 (36%) of these patients (e-Table 1 reports the patient characteristics).

The only significant difference in patient characteristics between patients with versus without EOs (e-Table 2) was slightly lower mean nocturnal oxygen saturation (SpO_2) in patients with EOs. EOs seemed to have moderate consequences on SpO_2 , which seemed mainly dependent on apnea duration.

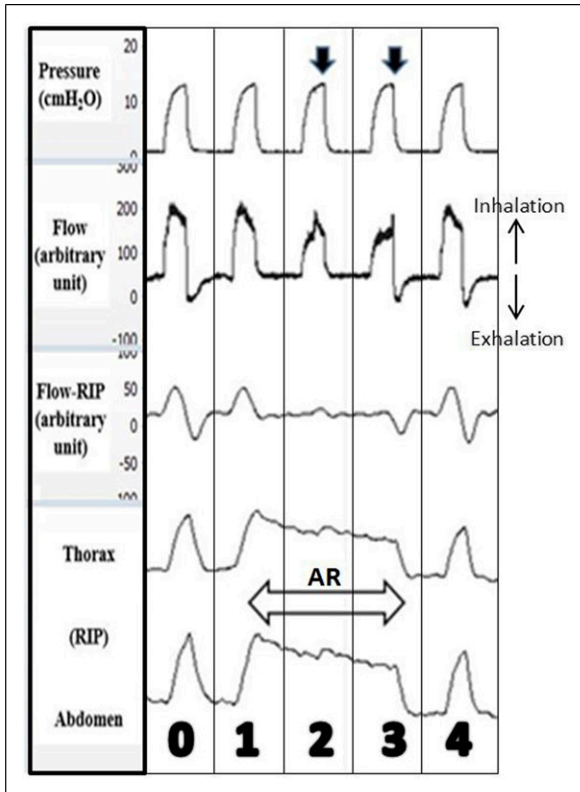


Figure 3. Step-by-step analysis of expiratory obstruction under non-invasive ventilation. AR means air retention; the vertical black arrows point to ineffective insufflations; the horizontal white arrows indicate expiratory obstructions. [0] appropriate patient–ventilator interaction: pressure increase is associated with adapted flow wave and synchronous thoraco-abdominal movements at both inhalation and exhalation; [1] expiratory obstruction: at the end of an effective insufflation, expiratory obstruction occurred (no significant exhalation observed before the next cycle on the flow, RIP flow, or thoraco-abdominal belts); [2] ineffective insufflation with leaks: pressure delivery did not allow additional inflation above the previous inflation (see the RIP signals), independently of the presence or not of upper airway obstruction, according to the pressure–volume relationship; [3] apnea resolution: obstruction release begin with a tidal expiration characterized by a return to the relaxed volume; [4] return to appropriate patient–ventilator interaction. RIP: respiratory inductive plethysmography.

Discussion

To our knowledge, EOs during nocturnal NIV have not been previously reported. We found this expiratory upper airway collapse phenomenon under NIV in a third of our DMD patients ventilated with a pressure mode.

In OSA, it has been shown that upper airway obstruction may occur not only during inspiration but also during expiration.^{7,8} Since muscle tone and upper airway pressure differ during inspiration and expiration, the mechanisms and

sites of upper airway occlusion are believed to differ also between these two phases. During sleep, the loss of expiratory muscle tone increases the supraglottic/retroglottal airway obstruction.⁸ Mechanisms promoting EOs during NIV may include dynamic pulmonary hyperinflation, afferent mechanoreceptor inhibition of upper airway reflexes, macroglossia (which is common in patients with DMD), and increased collapsibility due to loss of positive intraluminal pressures. Increased positive expiratory pressure has been observed prior to apneic events, suggesting that expiratory flow limitation with increased airway instability may precede apneas and that expiratory obstruction may play a critical role in the pathogenesis of upper airway obstruction during sleep.

In DMD, expiratory obstruction might be promoted by multiple mechanisms including impaired upper airway muscle activity and macroglossia. The *mdx* mouse, a widely used animal model of human DMD, shows evidence of impaired pharyngeal dilator muscle function, which may have implications for the control of airway patency in DMD.⁹

Lofaso et al.¹⁰ showed that expiratory abdominal muscle activity might be an indirect marker of expiratory upper airway obstruction, which may be related to an insufficient CPAP setting rather than to excessive settings in OSA patients. These data and the pathophysiological considerations stated above may justify the use of higher EPAP values in DMD patients to prevent expiratory obstruction.

To better pick-up these events, we propose a three step definition of expiratory obstruction in DMD patients undergoing barometric ventilation: (1) no significant exhalation observed before the next cycle on the flow, and thoraco-abdominal belts; (2) subsequent ineffective insufflations while the patient remained above the relaxed volume; and (3) obstruction release begin with a tidal expiration.

The retrospective single-center design of our study and the small sample size precludes definitive conclusions about the frequency of EOs under NIV in DMD or about risk factors. Yet, the expiratory pattern of these events (with subsequent air retention) represents a novel finding which should complete the panel of asynchronies occurring with NIV.

Further studies with larger samples and polysomnographic measurements may shed light on the clinical relevance of our findings.

Conclusion

EOs may be common in DMD patients receiving NIV and should be sought routinely.

Author contributions

Conceptualization: F.L and A.L.; data curation: A.L.; formal analysis: A.L, M.D, V.D; M.N-D, D.O, D.A, H.P, and F.L; methodology: A.L, F.L, and M.D; validation: all co-authors;

writing—original draft: A.L, M.D, H.P, and F.L; and writing—review and editing: all co-authors.

Declaration of conflicting interests

The author(s) declared no potential conflicts of interest with respect to the research, authorship, and/or publication of this article.

Funding

The author(s) received no financial support for the research, authorship, and/or publication of this article.

Ethical approval

All procedures performed in studies involving human participants were in accordance with the ethical standards of the institutional and/or national research committee and with the 1964 Helsinki Declaration and its later amendments or comparable ethical standards.

Informed consent

Patients were informed about the study and they could oppose the use of their data.

ORCID iDs

Antoine Leotard  <https://orcid.org/0000-0001-9120-9050>

Frédéric Lofaso  <https://orcid.org/0000-0001-5030-8175>

Supplementary material

Supplemental material for this article is available online.

References

1. Aboussouan LS and Mireles-Cabodevila E. Sleep-disordered breathing in neuromuscular disease. *Chest* 2017; 152(4): 880–892.
2. Annane D, Orlikowski D and Chevret S. Nocturnal mechanical ventilation for chronic hypoventilation in patients with neuromuscular and chest wall disorders. *Cochrane Database Syst Rev* 2014; 2014(12):CD001941.
3. Gonzalez-Bermejo J, Perrin C, Janssens JP, et al. Proposal for a systematic analysis of polygraphy or polysomnography for identifying and scoring abnormal events occurring during non-invasive ventilation. *Thorax* 2012; 67(6): 546–552.
4. Aarrestad S, Qvarfort M, Kleiven AL, et al. Sleep related respiratory events during non-invasive ventilation of patients with chronic hypoventilation. *Respir Med* 2017; 132: 210–216.
5. Schellhas V, Glatz C, Beecken I, et al. Upper airway obstruction induced by non-invasive ventilation using an oronasal interface. *Sleep Breath* 2018; 22(3): 781–788.
6. Gonzalez-Bermejo J, Janssens J-P, Rabec C, et al. Framework for patient-ventilator asynchrony during long-term non-invasive ventilation. *Thorax* 2019; 74(7): 715–717.
7. Stănescu D, Kostianev S, Sanna A, et al. Expiratory flow limitation during sleep in heavy snorers and obstructive sleep apnoea patients. *Eur Respir J* 1996;9(10): 2116–2121.
8. Woodson BT. Expiratory pharyngeal airway obstruction during sleep: a multiple element model. *The Laryngoscope* 2003; 113(9): 1450–1459.
9. Burns DP, O'Halloran KD. Evidence of hypoxic tolerance in weak upper airway muscle from young mdx mice. *Respir Physiol Neurobiol.* 2016; 226: 68–75.
10. Lofaso F, d'Ortho MP, Fodil R, et al. Abdominal muscle activity in sleep apnea during continuous positive airway pressure titration. *Chest* 2001; 120(2): 390–396.