



HAL
open science

Renal artery thrombosis induced by COVID-19

Carole Philipponnet, Julien Aniort, Pascal Chabrot, Bertrand Souweine,
Anne-Elisabeth Heng

► **To cite this version:**

Carole Philipponnet, Julien Aniort, Pascal Chabrot, Bertrand Souweine, Anne-Elisabeth Heng. Renal artery thrombosis induced by COVID-19. *Clinical Kidney Journal*, 2020, 13 (4), pp.713-713. 10.1093/ckj/sfaa141 . hal-04548249

HAL Id: hal-04548249

<https://hal.science/hal-04548249>

Submitted on 22 Apr 2024


HAL is a multi-disciplinary open access archive for the deposit and dissemination of scientific research documents, whether they are published or not. The documents may come from teaching and research institutions in France or abroad, or from public or private research centers.

L'archive ouverte pluridisciplinaire **HAL**, est destinée au dépôt et à la diffusion de documents scientifiques de niveau recherche, publiés ou non, émanant des établissements d'enseignement et de recherche français ou étrangers, des laboratoires publics ou privés.



Distributed under a Creative Commons Attribution 4.0 International License

LETTER TO THE EDITOR

Renal artery thrombosis induced by COVID-19Carole Philipponnet ¹, Julien Aniort¹, Pascal Chabrot², Bertrand Souweine³ and Anne-Elisabeth Heng¹¹Nephrology, Dialysis and Transplantation Department, University Hospital, Clermont Ferrand, France,²Department of Vascular Radiology, University Hospital, Clermont Ferrand, France and ³Intensive Medicine and Reanimation, University Hospital, Clermont Ferrand, France

Correspondence to: Carole Philipponnet; E-mail: cphilipponnet@chu-clermontferrand.fr

A 52-year-old man was admitted to the medical intensive care unit for abdominal pain. His medical history included right nephrectomy for renal neoplasia and stenting in the aorta and left renal artery after aortic dissection. He presented with asthenia over recent weeks. Clinical examination revealed normal blood pressure, afebrile, distended abdomen and oligo-anuria. His initial laboratory test were as follows: serum creatinine 486 $\mu\text{mol/L}$, haemoglobin 15.9 g/dL, platelets 400 G/L, lactate dehydrogenase 1795 U/L (normal <246), protein C reactive 82, D-dimer 16 354 ng/mL and fibrinogen 7.2 g/L. A thoraco-abdominopelvic computed tomography scan was performed and showed intra-stent thrombosis of the left renal artery with extensive ischaemic lesions of the renal parenchyma as well as images suggestive of severe acute respiratory syndrome coronavirus 2 (SARS-CoV-2) pneumonia (bilateral, subpleural ground-glass opacities) (Figure 1). An angioplasty failed to restore revascularization of the left renal artery. A tunnelled dialysis catheter was placed for the initiation of chronic haemodialysis. SARS-CoV-2 RNA was detectable in nasopharyngeal swabs. A diagnosis of renal artery thrombosis induced by coronavirus disease 2019 (COVID-19) was made. The outcome was favourable without specific treatment and pursuit of chronic haemodialysis.

It is now known that COVID-19 may predispose patients to thrombotic disease, both in the venous and arterial circulations, due to excessive inflammation, platelet activation, endothelial dysfunction and stasis. The initial coagulopathy of COVID-19 presents with prominent elevation of fibrin/fibrinogen and degradation products, while abnormalities in prothrombin time, partial thromboplastin time and platelet counts are relatively uncommon in initial presentations.

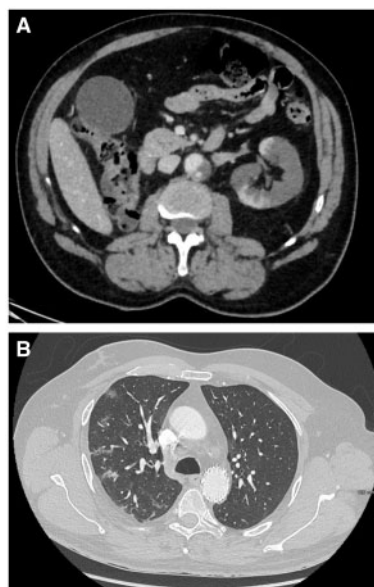


FIGURE 1: CT scan. (A) Intrastent thrombosis of the left renal artery with extensive ischaemic lesions of the renal parenchyma. (B) Bilateral, subpleural ground-glass opacities suggestive of SARS-CoV-2 pneumonia.

CONFLICT OF INTEREST STATEMENT

None declared.

Received: 1.6.2020; Editorial decision: 7.6.2020

© The Author(s) 2020. Published by Oxford University Press on behalf of ERA-EDTA.

This is an Open Access article distributed under the terms of the Creative Commons Attribution Non-Commercial License (<http://creativecommons.org/licenses/by-nc/4.0/>), which permits non-commercial re-use, distribution, and reproduction in any medium, provided the original work is properly cited. For commercial re-use, please contact journals.permissions@oup.com