



**HAL**  
open science

## **Strong Procedure for Superior Mesenteric Artery Syndrome in Children: A Case Report**

Saad Annattah, Younes Hajjaji, Abdelkrim Haita, Saad Andaloussi, Aziz El  
Madi

► **To cite this version:**

Saad Annattah, Younes Hajjaji, Abdelkrim Haita, Saad Andaloussi, Aziz El Madi. Strong Procedure for Superior Mesenteric Artery Syndrome in Children: A Case Report. *Scholars Journal of Medical Case Reports*, 2024, 12 (03), pp.316 - 321. 10.36347/sjmcr.2024.v12i03.020 . hal-04545989

**HAL Id: hal-04545989**

**<https://hal.science/hal-04545989>**

Submitted on 14 Apr 2024

**HAL** is a multi-disciplinary open access archive for the deposit and dissemination of scientific research documents, whether they are published or not. The documents may come from teaching and research institutions in France or abroad, or from public or private research centers.

L'archive ouverte pluridisciplinaire **HAL**, est destinée au dépôt et à la diffusion de documents scientifiques de niveau recherche, publiés ou non, émanant des établissements d'enseignement et de recherche français ou étrangers, des laboratoires publics ou privés.

Public Domain

## Strong Procedure for Superior Mesenteric Artery Syndrome in Children: A Case Report

Saad Annattah<sup>1\*</sup>, Younes Hajjaji<sup>1</sup>, Abdelkrim Haita<sup>1</sup>, Saad Andaloussi<sup>1</sup>, Aziz El Madi<sup>1</sup><sup>1</sup>Department of Pediatric Urology and Visceral, Mohammed VI University Hospital, Abdelmalek Essaadi University Faculty of Medicine and Pharmacy, Tangier 40000, MoroccoDOI: [10.36347/sjmcr.2024.v12i03.020](https://doi.org/10.36347/sjmcr.2024.v12i03.020)

| Received: 25.08.2023 | Accepted: 03.10.2023 | Published: 22.03.2024

**\*Corresponding author:** Saad Annattah

Department of Pediatric Urology and Visceral, Mohammed VI University Hospital, Abdelmalek Essaadi University Faculty of Medicine and Pharmacy, Tangier 40000, Morocco

### Abstract

### Case Report

Superior mesenteric artery syndrome (SMAS) or Wilkie syndrome is a rare anomaly resulting from extrinsic compression of the third duodenal segment by the superior mesenteric artery (SMA) anteriorly and the abdominal aorta posteriorly. Clinically, SMAS is characterized by acute or chronic upper obstruction associated with intermittent abdominal pain. Abdominal computed tomography is the key examination for establishing the diagnosis. Although initial management is medical, surgery is required if this fails. We report the case of a 12-year-old girl admitted for acute occlusive syndrome associated with abdominal pain, in whom the diagnosis of SMAS was retained. Treatment consisted of Strong's surgical technique after failure of medical treatment with good evolution. Our case reports that in cases of SMAS where medical treatment is ineffective, less invasive surgical options such as Strong's technique may be considered to facilitate rapid recovery while minimizing the risk of complications associated with more complex procedures involving bowel resection and anastomosis.

**Keywords:** Strong procedure, occlusion, case report, infant.

**Copyright © 2024 The Author(s):** This is an open-access article distributed under the terms of the Creative Commons Attribution **4.0 International License (CC BY-NC 4.0)** which permits unrestricted use, distribution, and reproduction in any medium for non-commercial use provided the original author and source are credited.

## INTRODUCTION

An anatomical clamp consisting of the superior mesenteric artery and the aorta compresses the third portion of the duodenum, leading to superior mesenteric artery syndrome (SMAS) [1]. With an estimated incidence of 0.1-0.3% [2]. It may cause symptoms such as abdominal pain, nausea, vomiting, early satiety and weight loss, or even lead to intestinal obstruction. [1]. Treatment is primarily medical, consisting of gastro-duodenal decompression and nutritional support, but surgical management by gastrojejunostomy, duodenojejunostomy or Strong's procedure, which involves the release of the ligament of Treitz and duodenal derotation, may be necessary if conservative treatment fails [3].

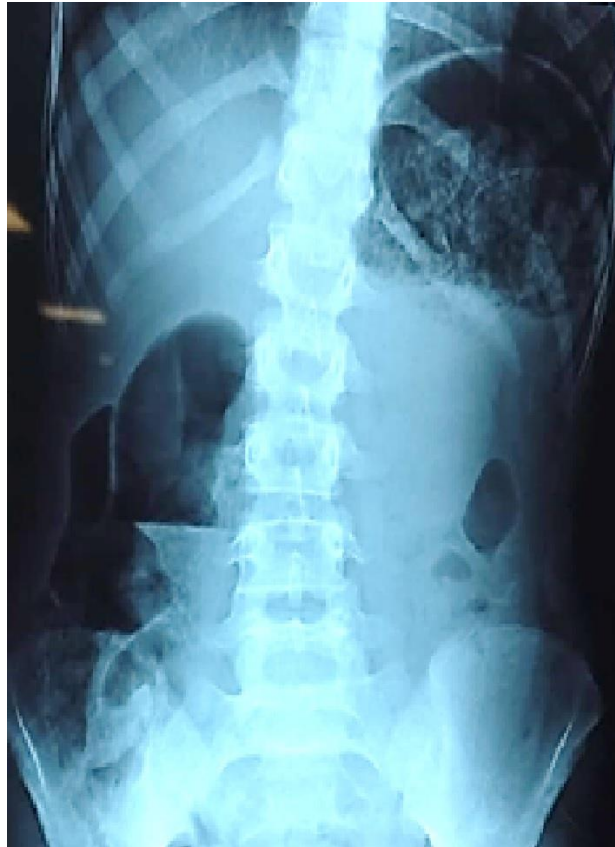
## CASE PRESENTATION

**Patient information:** A 12-year-old girl, with no significant medical history, was admitted to our

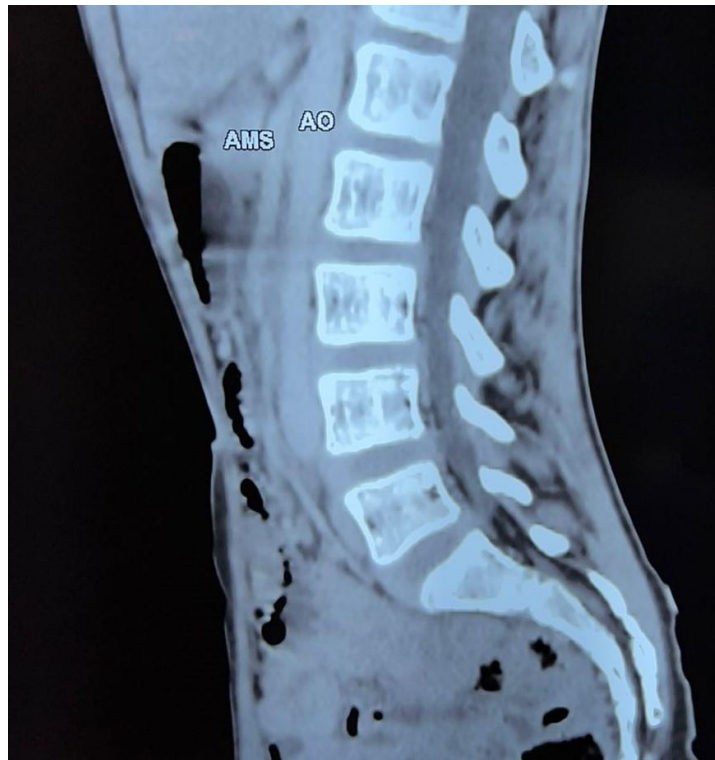department due to an acute occlusive syndrome with abdominal pain.

**Clinical Findings:** examination revealed a cachectic, malnourished girl weighing 25 kg (- 2 DS) with no clinical signs of dehydration; her abdomen was tender to palpation with no palpable mass or visible peristaltic undulations.

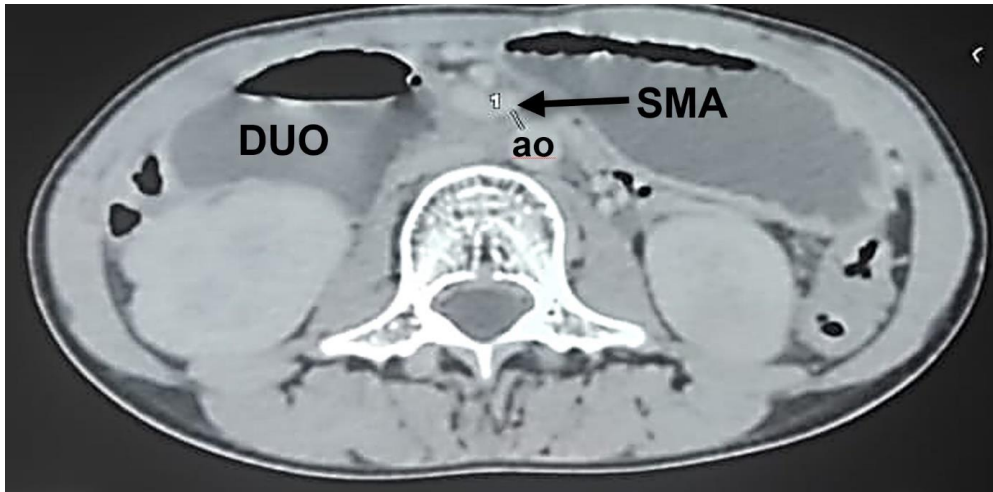
**Diagnostic Assessment:** Biological tests revealed acute renal insufficiency (urea: 1.96g/l and creatinine: 6mg/L), hyponatremia (131 mmol/l) and hypochloremia (89 mmol/l). An unprepared abdominal X-ray (UPX) revealed two hydroaeric levels, one large in the epigastria projection and the other on the right flank (Figure 1). Abdominal angioscan confirmed extrinsic compression of the 3rd duodenum under the aortomesenteric angle measured at 15° and the aorta-arterial distance at 4 mm (Figure 2 and Figure 3).



**Figure 1: Standard radiograph of the abdomen without preparation: the superposition of the two hydro-air levels, double-bubble appearance**



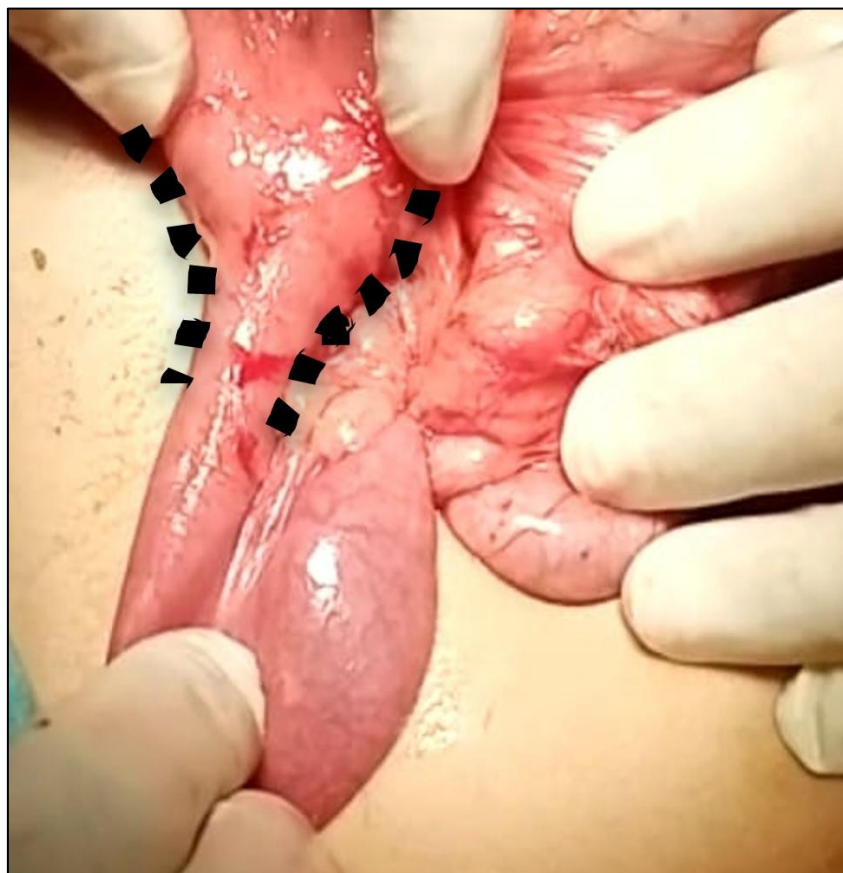**Figure 2: Abdominal angioscan: the acute angle between the aorta and superior mesenteric artery, measured at 15°**



**Figure 3: CT cross-section: evident compression of the third portion of the duodenum (duo) caused by the superior mesenteric artery (SMA) against the aorta (ao), with a distance measured at approximately 4.2 mm**

**Therapeutic intervention:** After unsuccessful medical treatment, including discontinuation of oral feeding, aspiration, electrolyte rebalancing and correction of renal function, the child was treated surgically by decreasing

the duodeno-jejunal angle by positioning the jejunum to the right of the AMS after sectioning Treitz's muscle using Strong's technique (Figure 4), which removed the vascular obstacle.

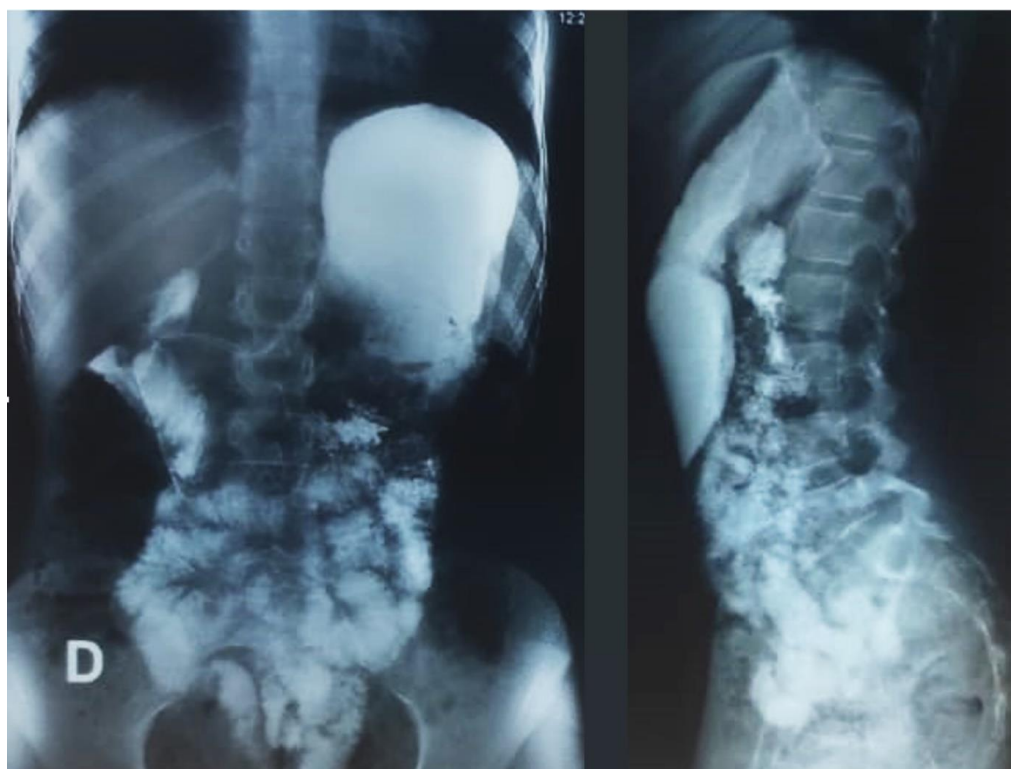

**Figure 4: Operative view showing the disparity in caliber at D3; after the duodeno-jejunal angle had been decreased in relation to the clamp**

**Follow-up and outcomes:** The patient experienced bilious vomiting for 3 days, which gradually improved. On the 6th postoperative day, the patient was released to

go home. Control TOGD (Figure 5) at 3 months post-op showed good intestinal permeability. Vomiting disappeared with a weight gain of 8 kg over 2 years.





**Figure 5: Control Oeso-gastro-duodenal transit, X-ray: good intestinal permeability**

## DISCUSSION

In 1861, Carl Von Rokitansky [4], first reported SMAS after performing an autopsy on a group of young, asthenic women who experienced abdominal discomfort and intermittent vomiting after eating. Rokitansky determined that the cause of their symptoms was due to the compression of the duodenum between the aorta and the SMA. Then In 1927, Wilkie [5] studied the pathophysiology and treatment of this syndrome in detail in a series of 75 patients. It is a rare condition [6], which occurs preferentially in young women between the ages of 17 and 39. Its physiopathology is related to a reduction in the aorto-mesenteric artery distance to less than 8 mm at the third part of duodenum, accompanied an aorto-mesenteric angle inferior to  $22^\circ$  [7]. The duodenum is normally safeguarded by perivascular adipose tissue. However, the occurrence of superior mesenteric artery syndrome (SMAS) can arise due to rapid weight loss, which results in the depletion of mesenteric fat, or in the presence of spinal deformities such as excessive curvature of the lower spine (vertebral hyperlordosis), spinal trauma, or spinal surgery, including scoliosis correction. Additionally, anatomical irregularities like a short or hypertrophied ligament of Treitz, a low origin of the superior mesenteric artery on the aorta, certain systemic disorders like scleroderma, aortic surgery, and cerebral palsy, the presence of mesenteric adenopathy, abdominal aortic aneurysm, and ileoanal anastomosis can contribute to the development of SMAS [8]. However, 40.4% of cases have no obvious triggering factor [9], and our observation falls into this category.

SMAS is a diagnosis that must be evoked in the presence of signs of acute upper intestinal obstruction, such as early post-prandial bile vomiting, abdominal pain and satiety, or in cases of chronic non-specific intermittent issues, characterized by recurring post-meal fullness and occasional vomiting. A key characteristic of SMAS is that symptoms worsen when lying flat and improve when in a left lateral decubitus or sitting position [1-6]. Definitive diagnosis is typically achieved through medical imaging: standard radiography confirms the presence of upper obstruction, while an abdominal angioscan reveals gastroduodenal dilation upstream of the aortomesenteric constriction. It enables accurate measurement of the aortomesenteric space [1], which is reduced and measures between 2-8 mm, whereas the normal distance is 10 to 28mm, and the aortomesenteric angle, which is reduced from  $7^\circ$  to  $22^\circ$ , whereas it is normally between  $25^\circ$  and  $60^\circ$ .

For the majority of children, medical management of SMAS is often effective, and involves implementing proper dietary measures, relieving stomach and duodenal pressure through the insertion of a nasogastric tube, positioning the patient on their left side, and addressing any hydrolytic imbalances. Additionally, initiating a combination of parenteral and enteral hypercaloric nutritional supplementation is crucial. However, if conservative treatment fails or symptoms recur, surgical intervention may be necessary to alleviate the obstruction [3].

Due to the rarity of SMAS, determining the most suitable surgical technique can be challenging.

There are various surgical options available, each with different complexities. One option is performing a duodenojejunostomy, which involves creating a bypass around the obstructed third part of the duodenum. Alternatively, If the stomach and duodenum are significantly dilated, or if there is ulceration of the duodenum, making duodenojejunostomy unsafe, a gastrojejunostomy is recommended. In certain cases, Strong's procedure, which has been widely discussed in the literature, is considered the preferred treatment for children. This procedure entails modifying the anatomical conditions to avoid the need for digestive anastomosis resection. In this procedure, the ligament of Treitz is surgically cut, and the third and fourth parts of the duodenum are released from the distal pancreas and retroperitoneum. Furthermore, the duodenojejunal angle is derotated by repositioning the jejunum to the right side of the superior mesenteric artery. With reported success rates for symptom resolution ranging from 67% to 96% [2-10], similar to the success rates reported for duodenojejunostomy [2]. Strong's recurrence rate after the procedure often cited in the literature 10 to 25% [3-10]. A more conservative version of Strong's procedure is described in a series of six cases, where the duodenum is incompletely derotated such that it lies to the right of midline, but is lowered just enough to relieve the obstruction produced by the aortomesenteric clamp. With this approach, mobilization of the duodenum is minimized, enabling patients to adopt a normal diet from the early postoperative period, while maintaining success and recurrence rates comparable to those of the traditional Strong procedure [3].

## CONCLUSIONS

Considering the potential benefits of a less invasive approach and to facilitate a rapid recovery while minimizing the risk of complications associated with more complex procedures involving intestinal resection and anastomosis, releasing the ligament of Treitz and performing duodenal derotation, as described in Strong's procedure, may be considered for patients with superior mesenteric artery syndrome (SMAS).

### Declarations:

#### Consent to publication:

We have received written consent from the patient's legal guardian for the publication of this case report. A copy of this consent form is available upon request.

#### Availability of data and materials:

Data and materials supporting our conclusions are available upon request. We are committed to providing all necessary data and materials to interested parties for the purpose of replicating results and continuing research.

#### Competing interests:

We declare that there are no potential competing interests that could influence the impartial

evaluation of our manuscript. All authors involved in this work have disclosed any financial or non-financial interests that could be perceived as a conflict of interest.

#### Funding:

No specific funding was provided for this study. All costs associated with research, data collection and manuscript preparation were borne by the authors.

#### Author's contributions:

Saad Annattah:

Performed clinical evaluation of patient.  
Participated in the surgical and medical interventions.  
Contributed to literature review and case presentation.  
Participated in data collection and analysis.  
Wrote initial manuscript.

Abdelkarim Haita:

Participated in data collection and analysis.  
Assisted in interpretation of clinical data.  
Reviewed and edited the manuscript for medical accuracy and clarity.

Younes Hajjaji:

Contributed to literature review and case presentation.  
Reviewed and edited the manuscript for medical accuracy and clarity.

Saad Andaloussi:

Participated in initial patient assessment and diagnosis.  
Contributed to the discussion and conclusion of the manuscript.  
Reviewed and corrected the manuscript for content and critical ideas.

Aziz El Madi:

Performed surgery and medical interventions.  
Contributed to surgical techniques and results.  
Reviewed and edited the manuscript for grammar, style and overall structure.  
Ensured that ethical considerations and patient confidentiality were appropriately addressed.

**Acknowledgements:** Not applicable

## REFERENCES

1. Welsch, T., Büchler, M. W., & Kienle, P. (2007). Recalling superior mesenteric artery syndrome. *Digestive surgery*, 24(3), 149-156. Doi: 10.1159/000102097
2. Shiu, J. R., Chao, H. C., Luo, C. C., Lai, M. W., Kong, M. S., Chen, S. Y., ... & Wang, C. J. (2010). Clinical and nutritional outcomes in children with idiopathic superior mesenteric artery syndrome. *Journal of pediatric gastroenterology and nutrition*, 51(2), 177-182. Doi: 10.1097/MPG.0b013e3181c7bdda
3. Dekonenko, C., Hill, J. A., Sobrino, J. A., Snyder, C. L., Peter, S. D. S., & Oyetunji, T. A. (2020). Ligament of Treitz release with duodenal lowering

- for pediatric superior mesenteric artery syndrome. *Journal of Surgical Research*, 254, 91-95. Doi: 10.1016/j.jss.2020.04.006
4. Von Rokitsansky, C. (1861). Lehrburch der pathologische Anatomie. TEd. 1.. Braumüller (ed): Universität de Gand, 3, 187.
  5. Wilkie, D. P. D. (1921). Chronic duodenal ileus. *The British Medical Journal*, 793-795.
  6. Lorentziadis, M. L. (2011). Wilke's syndrome. A rare cause of duodenal obstruction. *Annals of Gastroenterology: Quarterly Publication of the Hellenic Society of Gastroenterology*, 24(1), 59-61.
  7. Niasse, A., Faye, P. M., Kuadjovi, S. R., Leye, A., Diack, N. D., Gueye, M. L., ... & Dieng, M. (2022). Syndrome de la pince aorto-mésentérique sur cancer gastrique: à propos d' un cas. *Pan African Medical Journal*, 42(1), 217. Doi: 10.11604/pamj.2022.42.217.27281
  8. Loeb, T., Loubert, G., Morsly, R., Gabillet, J. M., & Pasteyer, J. (1999, November). Syndrome de l'artère mésentérique supérieure. In *Annales françaises d'anesthésie et de réanimation* (Vol. 18, No. 9, pp. 1000-1004). Elsevier Masson. Doi: 10.1016/S0750-7658(00)87950-2
  9. Andaloussi, S., Mahmoudi, A., Khattala, K., & Bouabdallah, Y. (2019). Le syndrome de la pince aorto-mésentérique: une cause rare d'obstruction duodénale. *PAMJ-Clinical Medicine*, 1(66). Doi: 10.11604/pamj-cm.2019.1.66.20988
  10. Ha, C. D., Alvear, D. T., & Leber, D. C. (2008). Duodenal derotation as an effective treatment of superior mesenteric artery syndrome: a thirty-three year experience. *The American Surgeon*, 74(7), 644-653. Doi: 10.1177/000313480807400712