



**HAL**  
open science

## Misplacement of transjugular intrahepatic portosystemic shunts: A surgical challenge for liver transplantation?

Pietro Addeo, Caroline Schaaf, François Faitot, Alfonso Terrone, Olivier Julliard, Camille Besch, Lawrence Serfaty, Philippe Bachellier

### ► To cite this version:

Pietro Addeo, Caroline Schaaf, François Faitot, Alfonso Terrone, Olivier Julliard, et al.. Misplacement of transjugular intrahepatic portosystemic shunts: A surgical challenge for liver transplantation?. *Surgery*, 2021, 169 (2), pp.447-454. 10.1016/j.surg.2020.07.028 . hal-04544617

**HAL Id: hal-04544617**

**<https://hal.science/hal-04544617v1>**

Submitted on 22 Jul 2024

**HAL** is a multi-disciplinary open access archive for the deposit and dissemination of scientific research documents, whether they are published or not. The documents may come from teaching and research institutions in France or abroad, or from public or private research centers.

L'archive ouverte pluridisciplinaire **HAL**, est destinée au dépôt et à la diffusion de documents scientifiques de niveau recherche, publiés ou non, émanant des établissements d'enseignement et de recherche français ou étrangers, des laboratoires publics ou privés.



Distributed under a Creative Commons Attribution - NonCommercial 4.0 International License

## **Misplacement of transjugular intrahepatic portosystemic shunts:**

### **A surgical challenge for liver transplantation?**

Pietro Addeo<sup>1</sup>, Caroline Schaaf<sup>1</sup>, François Faitot<sup>1</sup>, Alfonso Terrone<sup>1</sup>, Olivier Julliard<sup>1</sup>, Camille Besch<sup>2</sup>, Lawrence Serfaty<sup>2</sup>, Philippe Bachellier<sup>1</sup>

(1)Hepato-Pancreato-Biliary Surgery and Liver transplantation, Pôle des Pathologies Digestives, Hépatiques et de la Transplantation, Hôpital de Hautepierre-Hôpitaux Universitaires de Strasbourg, Université de Strasbourg, Strasbourg, France

(2) Hepatology Department, Pôle des Pathologies Digestives, Hépatiques et de la Transplantation, Hôpital de Hautepierre-Hôpitaux Universitaires de Strasbourg, Université de Strasbourg, Strasbourg, France

#### **Correspondence to:**

Pietro Addeo, MD

Hepato-Pancreato-Biliary Surgery and Liver Transplantation, Pôle des Pathologies Digestives, Hépatiques et de la Transplantation, Hôpital de Hautepierre-Hôpitaux Universitaires de Strasbourg, 1, Avenue Molière, 67098

Université de Strasbourg, Strasbourg, France

**E-mail:** [pietrofrancesco.addeo@chru-strasbourg.fr](mailto:pietrofrancesco.addeo@chru-strasbourg.fr)

**Tel:** 0033388127265; **Fax:** 0033388127286

**Running Head:** Transjugular intrahepatic portosystemic shunt misplacement

## **Abstract**

**Background:** The impact of transjugular intrahepatic portosystemic shunt (TIPS) misplacement on outcomes of liver transplantation (LT) remains controversial. We systematically reviewed the literature on the outcomes of LT with TIPS misplacement.

**Methods:** This systematic review was conducted according to the Preferred Reporting Items for Systematic Reviews and Meta-Analyses (PRISMA) guidelines. The Cochrane library, PUBMED, and Embase were searched (January 1990 –April 2020) for studies reporting patients undergoing LT with TIPS misplacement.

**Results:** Thirty-six studies reporting 181 patients who underwent LT with TIPS misplacement were identified. TIPS was misplaced with a variable degree of extension toward the inferior vena cava/right heart in 63 patients (34%), the spleno/portal/superior mesenteric venous confluence in 105 patients (58%), and both in 15 patients (8%). TIPS thrombosis was also present in 21 cases (12%). The median interval between TIPS placement and LT ranged from 1 day to 6 years. Complete TIPS removal was successful performed in all but 12 (7%) patients in whom part of the TIPS was left *in situ*. Open heart surgery under cardiopulmonary bypass was necessary to remove TIPS from the right heart in four patients (2%) and a venous graft interposition was necessary for a portal anastomosis in five patients (3%). Postoperative mortality (90 days) was 1,1% (two patients) and portal vein thrombosis developed postoperatively in four patients (2%).

**Conclusions:** Misplaced TIPS removal is possible in most cases during LT with extremely low mortality and good postoperative outcomes. Preoperative surgical strategy and intraoperative tailored surgical technique reduces the potential consequences of TIPS misplacement.

**Keywords:** transjugular intrahepatic portosystemic shunts; liver transplantation; caval vein; portal vein; veno-venous bypass; cardiopulmonary bypass.

## **Introduction**

A transjugular intrahepatic portosystemic shunt (TIPS) is commonly placed in cirrhotic patients who are on the waiting list for liver transplantation (LT) either to treat chronic ascites and/or for recurrent acute gastrointestinal bleeding(1). The large caliber of TIPS also allows repeat calibration, reproduces the size of a surgical portocaval shunt, and achieves high hemodynamic efficacy in decompressing the portal system(2, 3). The placement of TIPS using the endovascular approach avoids the challenge of major abdominal surgery in cirrhotic patients with inherent mortality and morbidity. Moreover, the presence of a previous surgically created portosystemic shunt has been associated with increased technical complexity during LT(4), while the presence of a TIPS does not to jeopardize the outcome(5, 6).

However, TIPS misplacement and/or migration can occur especially early after insertion before the stent wall is integrated by the vascular endothelium through neointimal proliferation(7). The misplaced or migrated TIPS can be replaced or sometimes removed using an endovascular approach, especially if this complication is detected early, but if not, removal is performed during LT(6). TIPS misplacement can be theoretically associated with increased technical complexity during LT(8). A recent study suggested that that malposition of TIPS was associated with a decreased 1-year patient and graft survival(9). However, the reason for this inferior survival remains unclear. We aimed to systematically review the literature on the outcomes of LT in the presence of misplaced TIPSs, and provide technical details that are helpful in managing misplaced TIPS during LT.

## **Patients and methods**

### ***Search strategy***

The EMBASE, MEDLINE, and Cochrane central databases were systematically searched from January 1990 to 30 April 2020 for articles describing cases of TIPS misplacement in LT. The search was conducted in accordance with the Preferred Reporting Items for Systematic Reviews and Meta-Analyses (PRISMA) guidelines, and it was limited to manuscripts that were written in English. The following phrases were used as search terms: “transjugular intrahepatic portosystemic shunts”, “TIPS”, “migration”, “malpositioning”, “malposition”, and “misplacement”, and each phrase was combined with “liver transplantation” or “orthotopic liver transplantation.”

### ***Article selection and data extraction***

Potentially eligible articles were screened by two independent investigators (PA, AT). Exclusion criteria included: 1) duplicated articles; and 2) articles that were not in English or that described animal studies. Discrepancies between the two investigators were resolved via consensus. The full text of the selected articles was analyzed for eligibility. References of selected articles were checked for additional cases. The primary outcomes of the review were technical details and mortality of LT in the presence of misplaced TIPS. Secondary outcomes were the rate of TIPS extraction and 1-year survival. Data regarding the study period, number of patients, patient characteristics, surgical complications, morbidity, and mortality of LT were extracted from the included articles. All the data were extracted using a standardized extraction form.

### ***Statistical analysis***

The methodological limitations and the volume of incomplete data hampered the meta-analysis. Continuous data were expressed as the mean  $\pm$  standard deviation (SD) and as the range or the median and range, as appropriate. Categorical variables were presented as numbers and

percentages. Differences between groups were assessed using the chi-squared or Fisher's exact test (categorical variables) and the Wilcoxon rank sum test or the Student's *t*-test (continuous variables). This review is largely descriptive because of the small sample size.

## Results

The initial search identified 685 studies. However, only 36 studies (5-40) matched the inclusion criteria (Figure 1). Sixteen studies were reported before 2000. A misplaced TIPS was identified in 181 patients. The rate of TIPS misplacement ranged between 10.1% and 66% in the different series (except for TIPS used to recanalize a thrombosed portal vein-100%)(40), and it was increasingly reported after 2000 (141 cases after vs. 40 cases before) (Table 1). TIPS was misplaced with a variable degree of extension toward the inferior vena cava/right heart in 63 patients (34%), the spleno/portal/superior mesenteric venous confluence in 105 patients (58%), and both in 15 patients (8%). TIPS thrombosis was also present in 21 patients (12%). The median interval between TIPS placement and LT ranged from 1 day to 6 years. During LT, an intrapericardial approach to the inferior vena cava was performed in 11 patients with highly misplaced TIPS(9, 14, 16, 17, 23, 27, 29-31, 33), and the use a veno-venous bypass and a caval replacement was inconstantly reported. A venous graft was necessary for the portal anastomosis in five patients (7, 12, 15, 16). Complete TIPS removal was successfully performed in all but 12 (7%) patients in whom a part of the stent was left *in situ* (6, 8, 11, 13, 15, 18, 21, 23, 24) (Table 2). Open heart surgery under cardiopulmonary bypass was necessary to remove cardiac tips in four patients (17, 23, 30, 31). Postoperative mortality (90 days) was 1,1% (two patients)(14, 15) and portal vein thrombosis developed postoperatively in four patients(6, 8, 9, 19). The first death was attributable to a venous disruption of the IVC during an attempted TIPS extraction, which led to massive intraoperative bleeding that was successful controlled, but led to death from complications related to the bleeding(14). The second death was a result of sepsis after liver retransplantation for hepatic artery

thrombosis in a patient with misplaced TIPS into the SMP confluence(15). The venous anastomosis required a jump venous graft between the recipient SMV and the graft PV, which was reused during liver retransplantation. The 1-year survival rate ranged from 50 to 100%.

## **Discussion**

### *Literature review*

The results of the current review suggest that TIPS misplacement is not uncommonly seen in patients undergoing LT. However complete extraction of misplaced TIPS was almost possible in all patients, with a low mortality rate and acceptable operative outcomes. Only some cases of high misplaced TIPS necessitated open heart surgery for extraction and showed major intraoperative bleeding.

The high hemodynamic efficacy in decompressing the portal system that is shown by TIPS along with the reduced invasiveness of the procedure has led to its use as a bridge to liver transplantation(3). The advantages of TIPS before LT include maintained high portal flow through the TIPS toward the caval system (which, in turn, will supplies blood to the transplanted liver upon its removal), complete removal of TIPS within the recipient hepatectomy, and a progressive suppression of the collateral circulation, which could reduce bleeding during recipient hepatectomy(6). The rate of TIPS misplacement/migration is highly variable, but it has been correlated to the radiologist's experience and the liver size(7). In addition, TIPS can be deliberately placed lower into the porto-mesenteric system as described by the Northwestern group for recanalization of thrombosed portal vein before LT(40). The exact definition of misplaced TIPS could not be precisely assessed because of high heterogeneity of definitions used by different authors. Ideally, beside the case of TIPS placement for portal vein thrombosis recanalization(40), the proximal end of the TIPS should be in one portal branch and the distal end in one hepatic vein. In this review, TIPS misplacement occurred at a higher rate toward the SMP confluence and was

increasingly reported after 2000, probably because of the increased use in candidates for LT. Complete extraction of these misplaced TIPS was almost always possible (93%) by clamping above or below the upper edge or the lower edge of the misplaced TIPS. For an intraoperative strategy, a thoracic approach to the inferior vena cava(41) was necessary in some patients to achieve safe control of a TIPS that had a high location. Lack of homogeneous data hampered the analysis of methods that were used to achieve portal and caval decompression during extraction procedures, while some authors reported a high number of extractions with short total caval clamping(5) and others preferred the use of veno-venous bypass(6, 14, 30). However, the theoretical suppression of collateral circulation that was achieved by TIPS before LT was, in some studies, associated with an increased need for a portocaval shunt(5).

When complete shunt removal was not feasible, some authors reported good results even when performing caval or portal anastomoses over TIPS embedded into the venous wall(24). Caval thromboses were not observed in this review and portal thromboses remained rare, although intimal injuries by TIPS are always seen. These low rates of portal vein thrombosis after TIPS extraction are probably related to the increased flow rate that is achieved by TIPS, which can reduce the risk of portal vein thrombosis(9). However, in some extreme cases a venous graft was used to prolong the native portal vein to achieve safe venous reconstruction. A jump graft over the superior mesenteric and splenic vein was also described in patients with severely injured veins by TIPS(7). Postoperative survival of the patients with misplaced TIPS compared favorably with LT patients without TIPS, which confirmed the results of previous comparative studies(4, 6).



## ***Preoperative and intraoperative management of patients with TIPS undergoing LT***

### *Preoperative surgical planning*

The most recent axial computed tomography or magnetic resonance image of the recipient of LT with TIPS should be available. The patency and the positioning of the TIPS should be assessed preoperatively. The positioning of the TIPS in relation to the suprahepatic inferior vena cava and the splenomesentericoportal venous confluence should be identified. It could be described four different patterns of TIPS in relation to the caval system, as follows: the upper edge of the TIPS can be well located in one hepatic vein (Fig. 2A); just at the level of entry of the hepatic vein into the inferior vena cava (Fig. 2B); into the inferior vena cava above the liver (Fig. 2C); and into the right atrium (Fig. 2D). The TIPS can be patent or thrombosed, and the thrombus can extend toward the right heart beyond the TIPS (Figure 3).

There are different patterns of TIPS positioning in relation to the splenomesentericoportal venous confluence, in which the lower edge of the TIPS can be normally located in one portal branch (Fig. 4A); into the portal trunk (Fig. 4B); or into the superior mesenteric vein (Fig. 4D). The TIPS can be patent or thrombosed (Fig. 4C) and the thrombus can extend toward the superior mesenteric vein beyond the TIPS.

### *Intraoperative strategy*

#### Temporary portal vein decompression

The presence of a TIPS has been associated with major hemodynamic variations and bowel edema when the portal vein is clamped during LT that is expressed by an increased need for a portocaval shunt(5, 9). This is because of the high hemodynamic efficiency of TIPS, which progressively abolishes collateral circulation of the cirrhotic patients diverting the portal flow directly into the caval system. Thus, as we and other authors suggest that in patients with

TIPS, temporary portal decompression should be systematically performed during the anhepatic phase(42). The type of portal decompression can vary according to the placement and the efficacy of TIPS. In patients with well-placed TIPS a classical portocaval shunt should be performed. In patients with well-placed but obstructed TIPS and in patients with mispositioned TIPS toward the SMP confluence, the preference can be directed toward passive shunts (mesenterico-saphenous shunt) or an active veno-venous bypass (Fig. 3)<sup>(43)</sup>.

#### *How to deal with TIPS misplacement?*

A well-positioned intrahepatic TIPS does not modify the technique of LT. Progressive migration toward the inferior vena cava represents an increasing technical challenge (Fig. 2B, C, D). When the edge of the TIPS just arrives at the junction of the hepatic vein and the IVC, lower IVC partial caval clamping (a classical piggy-back technique) can be enough to remove the TIPS (Fig. 1B, Fig. 5B). Alternatively, closure of the hepatic vein with a side-to-side caval anastomosis can be also performed(44). Several technical challenges could be seen based on how high the TIPS migrate. First trapping of the metallic spire in between vascular clamps can be a source of clamp slippage with consequent profuse bleeding and/or this can make vascular clamping impossible(29). Second, complete integration of the metallic spire into the venous wall can be associated with venous wall break-out when attempting the removal. Third, TIPS breakout during a removal attempt can be associated to endovascular migration(28). Fourth, the damaged endothelium with part of the TIPS left inside can make it challenging to perform caval anastomoses, which theoretically increases the risk of thrombosis.

Thus, when TIPS migrates toward the right heart (Fig. 1C,D) the IVC should be isolated systematically below and above the liver to anticipate a total clamping. An intrapericardial

approach to the IVC using a transdiaphragmatic abdominal approach without the need for sternotomy may be required for a very highly placed TIPS (Fig. 3)(41). Once control of the IVC is obtained, two options are available. For incorporation of the TIPS into the caval wall, IVC conventional LT with caval replacement under a veno-venous bypass is probably the most rapid and safe option. Alternatively, using short total caval clamping, TIPS extraction can be made for a shorter extent of displacement into the IVC. One alternative could be to transect the TIPS and perform venous anastomoses over the embedded TIPS. This option has been reported by some authors with good results(23, 24). A TIPS that is embedded into the right atrium can require cardiac surgery(17, 23, 30).

For TIPS misplacement toward the SMP, venous confluence portal clamping should be performed at the lower edge of the TIPS<sup>(43)</sup>. This can require separate isolation of the superior mesenteric vein and the splenic vein for separate clamping(7). A venous jump graft over the SMV can be required in some patients with reduced portal flow<sup>(7)</sup>.

Care should be taken when performing TIPS extraction from the hepatic or the portal system. Just pulling on the TIPS can be a source of venous disruption. We found it useful to extract the TIPS is as done for common portal thrombosis using an eversion technique and removing the intima along with the tips such as in a tromboarterectomy(8) (Fig. 4A,B). This will ensure optimal vascular tissue for a safe venous reconstruction.

### **Limitations**

This study presents several limitations which deserve comments. First there was a selection bias in analyzing these retrospective studies which reported high rate of successful TIPS extraction at the time of LT. Likewise most of cases with unsuccessful outcomes were never reported. A multicentric study could probably give a real picture of this operative scenario.

Second, there was high heterogeneity in defining TIPS misplacement across the different studies and we also included cases with “deliberate” low placement of TIPS for portal vein thrombosis recanalization. A uniform definition should be used among different centers to better clarify the outcomes in presence of TIPS misplacement in relationship to portal and/or hepatic veins system. Third, there was a lack of comprehensiveness of data regarding the interval of time between TIPS placement and the technical difficulties encountered during LT. It is more probably that long-term placement of TIPS was associated with higher reendothelization rate and increased difficulty in its extraction, but this must be defined in a multicentric study.

### **Conclusions**

Misplaced TIPS removal is possible in most cases during LT with extremely low mortality and good postoperative outcomes. Intrathoracic isolation of the inferior vena cava, total vascular exclusion, caval replacement under veno-venous bypass, and simultaneous associated open heart surgery have been described for highly misplaced TIPSs. Preoperative surgical planning and an accurate intraoperative strategy can mitigate the consequences of an intraoperative discovery of TIPS misplacement.

**Acknowledgement:** The authors would like to express their sincere gratitude to Eduardo Fernandes MD PhD and Marina Gitman MD from University of Illinois at Chicago for their help in collecting the

**COI/Disclosure:** None

**Funding/Support:** None

## Figure legends

**Figure 1.** PRISMA diagram for study selection

**Figure 2.** Patterns of TIPS placement in relation to the hepatic and caval veins. (A) normal placement; (B) misplacement into the hepatic-caval vein confluence; (C) misplacement into the suprahepatic inferior vena cava; (D) misplacement into the right atrium.

**Figure 3.** Intraoperative images showing a thrombosed TIPS extending to the suprahepatic inferior vena cava (A); the thrombosis was confirmed at intraoperative ultrasound (B); the inferior vena cava was isolated and clamped using an intrapericardial transdiaphragmatic transabdominal approach (C); caval replacement was achieved under veno-venous bypass (D).

**Figure 4.** Patterns of TIPS placement in relation to splenomesentericoportal confluence. (A) normal placement; (B) misplacement into the portal vein; (C) misplacement into the portal vein with thrombosis; (D) misplacement into the superior mesenteric vein.

**Figure 5.** Intraoperative pictures showing the details of a “TIPS- thromboendarterectomy” that is used to extract the shunt from the portal (A) or the hepatic veins (B).

## References

1. Garcia-Pagan JC, Caca K, Bureau C, Laleman W, Appenrodt B, Luca A, et al. Early use of TIPS in patients with cirrhosis and variceal bleeding. *N Engl J Med*. 2010; 362:2370-9.
2. Lv Y, Qi X, He C, Wang Z, Yin Z, Niu J, et al. Covered TIPS versus endoscopic band ligation plus propranolol for the prevention of variceal rebleeding in cirrhotic patients with portal vein thrombosis: a randomised controlled trial. *Gut*. 2018; 67:2156-68.
3. Henderson JM, Boyer TD, Kutner MH, Galloway JR, Rikkers LF, Jeffers LJ, et al. Distal splenorenal shunt versus transjugular intrahepatic portal systematic shunt for variceal bleeding: a randomized trial. *Gastroenterology*. 2006; 130:1643-51.
4. Dell'Era A, Grande L, Barros-Schelotto P, Turnes J, Fuster J, Charco R, et al. Impact of prior portosystemic shunt procedures on outcome of liver transplantation. *Surgery*. 2005; 137:620-5.
5. Barbier L, Hardwigsen J, Borentain P, Biance N, Daghfous A, Louis G, et al. Impact of transjugular intrahepatic portosystemic shunting on liver transplantation: 12-year single-center experience. *Clin Res Hepatol Gastroenterol*. 2014; 38:155-63.
6. Guerrini GP, Pleguezuelo M, Maimone S, Calvaruso V, Xirouchakis E, Patch D, et al. Impact of tips preliver transplantation for the outcome posttransplantation. *Am J Transplant*. 2009; 9:192-200.
7. Clavien PA, Selzner M, Tuttle-Newhall JE, Harland RC, Suhocki P. Liver transplantation complicated by misplaced TIPS in the portal vein. *Ann Surg*. 1998; 227:440-5.
8. Valdivieso A, Ventoso A, Gastaca M, Bustamante J, Aguinaga A, Ruiz P, et al. Does the transjugular intrahepatic portosystemic influence the outcome of liver transplantation? *Transplant Proc*. 2012; 44:1505-7.
9. Matsushima H, Fujiki M, Sasaki K, Cywinski JB, D'Amico G, Uso TD, et al. Can pretransplant TIPS be harmful in liver transplantation? A propensity score matching analysis. *Surgery*. 2020.
10. Abouljoud MS, Levy MF, Rees CR, Diamond NG, Lee SP, Mulligan DC, et al. A comparison of treatment with transjugular intrahepatic portosystemic shunt or distal splenorenal shunt in the management of variceal bleeding prior to liver transplantation. *Transplantation*. 1995; 59:226-9.
11. da Silva RF, Arroyo PC, Jr., Duca WJ, da Silva AA, Reis LF, Miquelin DG, et al. Migration of transjugular intrahepatic portosystemic shunt to the right atrium: complications in the intraoperative period of liver transplantation. *Transplant Proc*. 2008; 40:3778-80.
12. Farney AC, Gamboa P, Payne WD, Gruessner RW. Donor iliac vein interposition during liver transplantation in a patient with a migrated transjugular intrahepatic portosystemic shunt. *Transplantation*. 1998; 65:572-4.
13. Fehervari I, Szonyi L, Fazakas J, Gerlei Z, Lazar I. TIPS stent migration into the heart with 6-year follow-up. *Ann Transplant*. 2011; 16:109-12.
14. Freeman RB, Jr., FitzMaurice SE, Greenfield AE, Halin N, Haug CE, Rohrer RJ. Is the transjugular intrahepatic portocaval shunt procedure beneficial for liver transplant recipients? *Transplantation*. 1994; 58:297-300.
15. Gilbo N, Ceulemans LJ, Maleux G, Nevens F, Laleman W, Jochmans I, et al. How to Deal With a Nonextractable Transjugular Intrahepatic Portosystemic Shunt Complicating Liver Transplantation. *Liver Transpl*. 2018; 24:1293-7.
16. Goldberg MS, Weppler D, Khan FA, DeFaria W, Khan RT, Webb MG, et al. Does transjugular intrahepatic portosystemic shunting facilitate or complicate liver transplantation? *Transplant Proc*. 1997; 29:557-9.
17. Hayashi PH, Mao J, Slater K, Liao R, Durham JD, Carroll J, et al. Atrial septal perforation from TIPS stent migration. *J Vasc Interv Radiol*. 2004; 15:629-32.
18. Hutchins RR, Patch D, Tibballs J, Burroughs A, Davidson BR. Liver transplantation complicated by embedded transjugular intrahepatic portosystemic shunt: a new method for portal anastomosis- a surgical salvage procedure. *Liver Transpl*. 2000; 6:237-8.
19. Jabbour N, Zajko AB, Orons PD, Irish W, Bartoli F, Marsh WJ, et al. Transjugular intrahepatic portosystemic shunt in patients with end-stage liver disease: results in 85 patients. *Liver Transpl Surg*. 1996; 2:139-47.

20. John TG, Jalan R, Stanley AJ, Redhead DN, Sanfey HA, Hayes PC, et al. Transjugular intrahepatic portosystemic stent-shunt (TIPSS) insertion as a prelude to orthotopic liver transplantation in patients with severe portal hypertension. *Eur J Gastroenterol Hepatol*. 1996; 8:1145-9.
21. Lerut JP, Laterre PF, Goffette P, Cicarelli O, Donataccio M, Mazza D, et al. Transjugular intrahepatic portosystemic shunt and liver transplantation. *Transpl Int*. 1996; 9:370-5.
22. Mazziotti A, Morelli MC, Grazi GL, Jovine E, Masetti M, Pierangeli F, et al. Beware of TIPS in liver transplant candidates. *Transjugular Intrahepatic Portosystemic Shunt*. *Hepatogastroenterology*. 1996; 43:1606-10.
23. Merdrignac A, Jeddou H, Houssel-Debry P, Flecher E, Rayar M, Boudjema K. Venous stent in liver transplant candidates: Dodging the top tip traps. *Liver Transpl*. 2017; 23:972-5.
24. Meyer C, Odeh M, Herrera JJ, Resende A, Perarnau JM, Ellero B, et al. Orthotopic liver transplantation with a suprahepatic vena caval anastomosis over a transjugular intrahepatic portosystemic shunt. *J Am Coll Surg*. 1998; 187:217-20.
25. Millis JM, Martin P, Gomes A, Shaked A, Colquhoun SD, Jurim O, et al. Transjugular intrahepatic portosystemic shunts: impact on liver transplantation. *Liver Transpl Surg*. 1995; 1:229-33.
26. Moreno A, Meneu JC, Moreno E, Fraile M, Garcia I, Loinaz C, et al. Liver transplantation and transjugular intrahepatic portosystemic shunt. *Transplant Proc*. 2003; 35:1869-70.
27. Ogura Y, Kanazawa H, Yoshizawa A, Nitta T, Ikeda T, Uemoto S. Supradiaphragmatic approach for Budd-Chiari syndrome with transjugular intrahepatic portosystemic shunt stent in combination with inferior vena cava reconstruction during living donor liver transplantation: a case report. *Transplant Proc*. 2011; 43:2093-6.
28. Rumi MN, Schumann R, Freeman RB, Rohrer RJ, Fairchild RB. Acute transjugular intrahepatic portosystemic shunt migration into pulmonary artery during liver transplantation. *Transplantation*. 1999; 67:1492-4.
29. Salvalaggio PR, Koffron AJ, Fryer JP, Abecassis MM. Liver transplantation with simultaneous removal of an intracardiac transjugular intrahepatic portosystemic shunt and a vena cava filter without the utilization of cardiopulmonary bypass. *Liver Transpl*. 2005; 11:229-32.
30. Te HS, Jeevanandam V, Millis JM, Cronin DC, Baker AL. Open cardiectomy for removal of migrating transjugular intrahepatic portosystemic shunt stent combined with liver transplantation. *Transplantation*. 2001; 71:1000-3.
31. Tivener D, Vannucci A, Fagley RE, Doyle M, Shenoy S, Chapman W, et al. Atrial laceration caused by removal of a transjugular intrahepatic portosystemic shunt necessitates emergent cardiopulmonary bypass during liver transplant: a case report. *Transplant Proc*. 2011; 43:2810-3.
32. Tripathi D, Therapondos G, Redhead DN, Madhavan KK, Hayes PC. Transjugular intrahepatic portosystemic stent-shunt and its effects on orthotopic liver transplantation. *Eur J Gastroenterol Hepatol*. 2002; 14:827-32.
33. Wilson MW, Gordon RL, LaBerge JM, Kerlan RK, Radosevich PM, Roberts JP, et al. Liver transplantation complicated by malpositioned transjugular intrahepatic portosystemic shunts. *J Vasc Interv Radiol*. 1995; 6:695-9.
34. Woodle ES, Darcy M, White HM, Perdrizet GA, Vesely TM, Picus D, et al. Intrahepatic portosystemic vascular stents: a bridge to hepatic transplantation. *Surgery*. 1993; 113:344-51.
35. LaBerge JM, Ring EJ, Gordon RL, Lake JR, Doherty MM, Somberg KA, et al. Creation of transjugular intrahepatic portosystemic shunts with the wallstent endoprosthesis: results in 100 patients. *Radiology*. 1993; 187:413-20.
36. Suc B, Vinel JP, Rousseau H, Maquin P, Holmiere F, Fourtanier G, et al. Intrahepatic portocaval shunt in patients waiting for transplantation. *Transplant Proc*. 1995; 27:1715-6.
37. Zhou GW, Cai WY, Li HW, Zhu Y, Dodson F, Fung JJ. Transjugular intrahepatic portosystemic shunt for liver transplantation. *Hepatobiliary Pancreat Dis Int*. 2002; 1:179-82.

38. Khan TT, Reddy KS, Johnston TD, Lo FK, Shedlofsky S, Grubb S, et al. Transjugular intrahepatic portosystemic shunt migration in patients undergoing liver transplantation. *Int Surg.* 2002; 87:279-81.
39. Chui AK, Rao AR, Waugh RC, Mayr M, Verran DJ, Koorey D, et al. Liver transplantation in patients with transjugular intrahepatic portosystemic shunts. *Aust N Z J Surg.* 2000; 70:493-5.
40. Thornburg B, Desai K, Hickey R, Hohlastos E, Kulik L, Ganger D, et al. Pretransplantation Portal Vein Recanalization and Transjugular Intrahepatic Portosystemic Shunt Creation for Chronic Portal Vein Thrombosis: Final Analysis of a 61-Patient Cohort. *J Vasc Interv Radiol.* 2017; 28:1714-21 e2.
41. Chen TW, Tsai CH, Chou SJ, Yu CY, Shih ML, Yu JC, et al. Intrapericardial isolation of the inferior vena cava through a transdiaphragmatic pericardial window for tumor resection without sternotomy or thoracotomy. *Eur J Surg Oncol.* 2007; 33:239-42.
42. Addeo P, Locicero A, Faitot F, Bachellier P. Temporary Right Portocaval Shunt During Piggyback Liver Transplantation. *World J Surg.* 2019; 43:2612-5.
43. Faitot F, Addeo P, Besch C, Michard B, Oncioiu C, Ellero B, et al. Passive mesenterico-saphenous shunt: An alternative to portocaval anastomosis for tailored portal decompression during liver transplantation. *Surgery.* 2019; 165:970-7.
44. Belghiti J, Panis Y, Sauvanet A, Gayet B, Fekete F. A new technique of side to side caval anastomosis during orthotopic hepatic transplantation without inferior vena caval occlusion. *Surg Gynecol Obstet.* 1992; 175:270-2.



1.IDENTIFICATION

2.SCREENING

3.ELIGIBILITY

4.INCLUDED

STUDIES IDENTIFIED THROUGH DATABAS SEARCH  
(N=685)

RECORDS EXCLUDED ON A TITLE  
ABSTRACT BASIS  
(N=637)

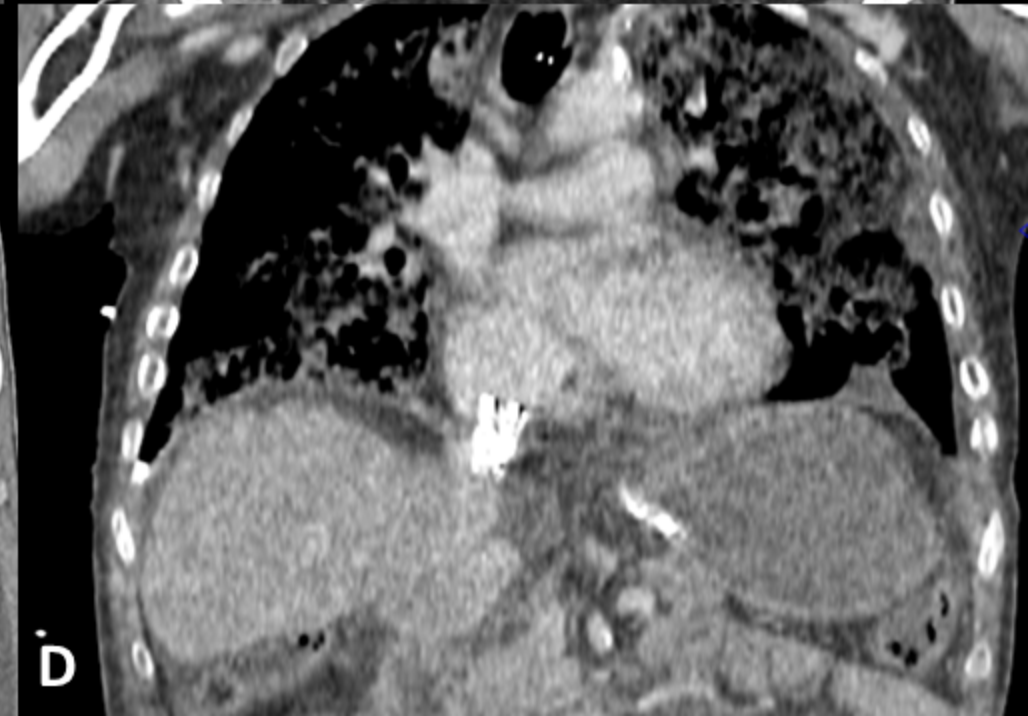
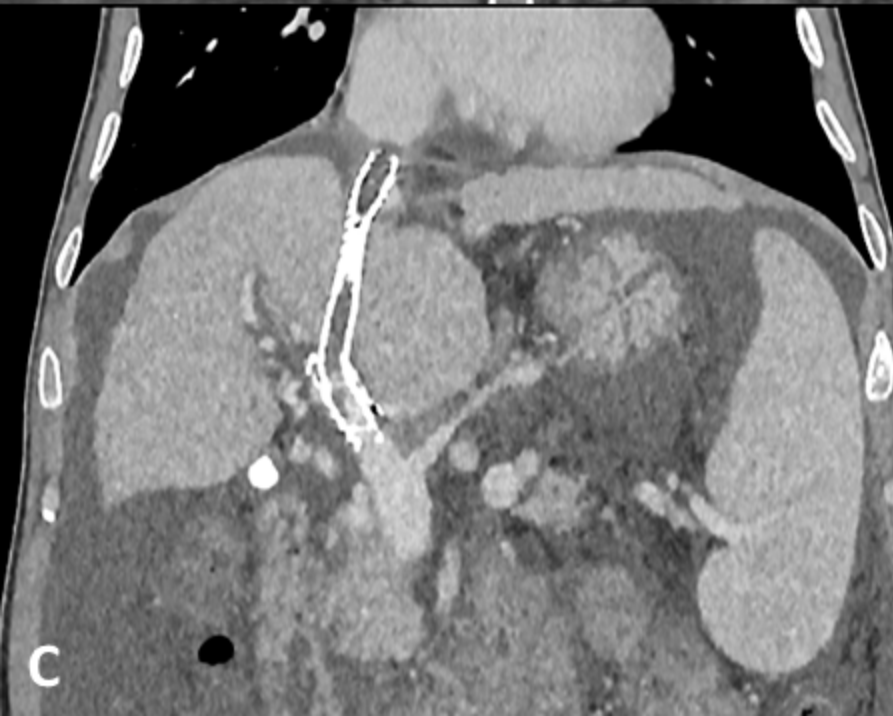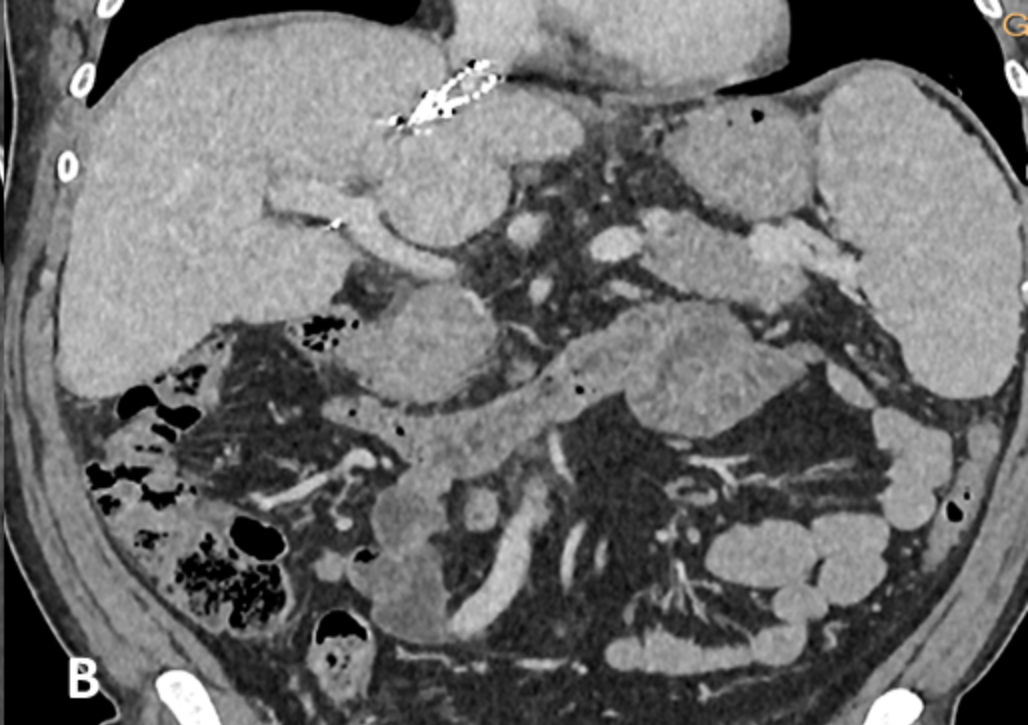
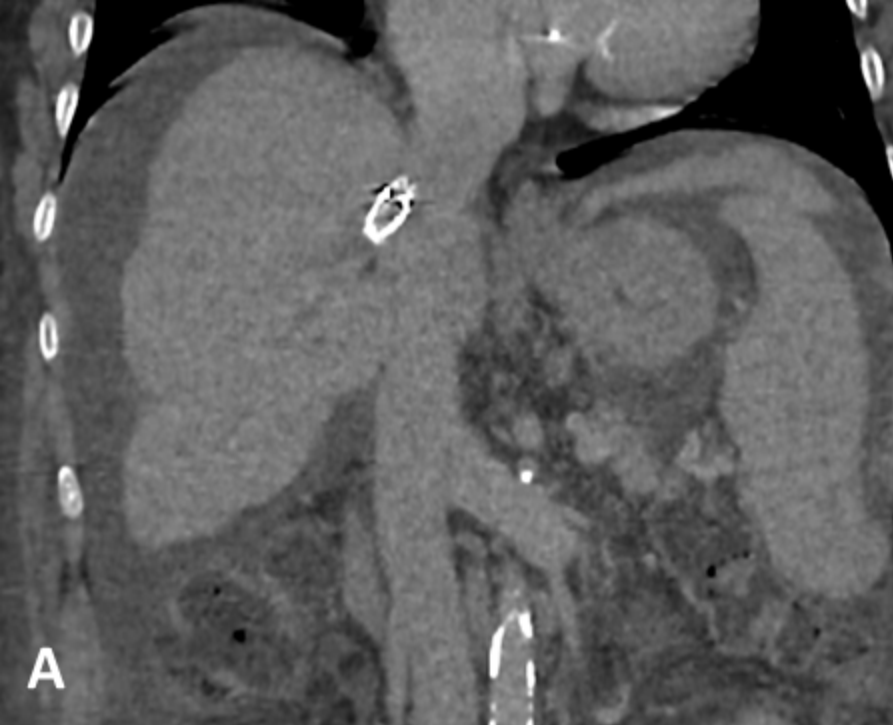RECORDS SCREENED  
(N=48)

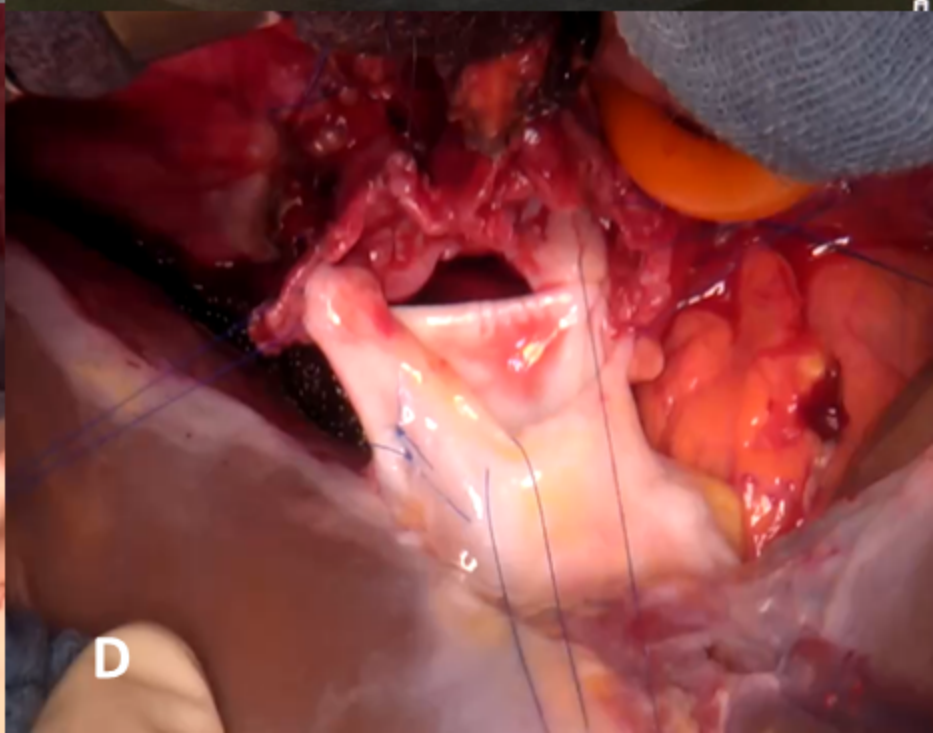
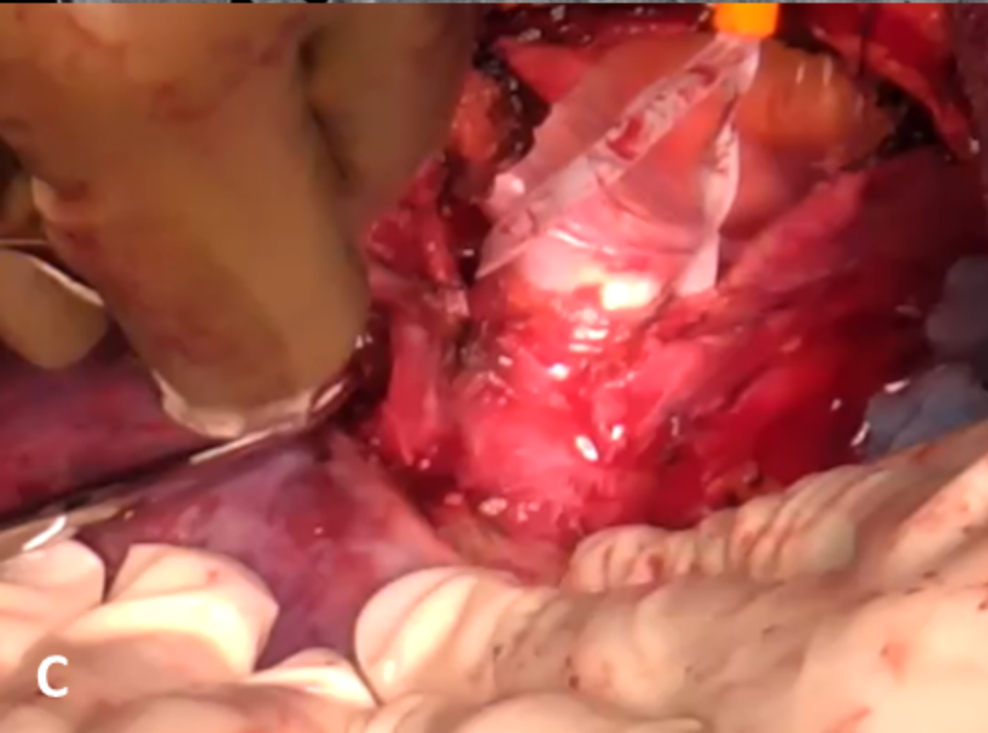
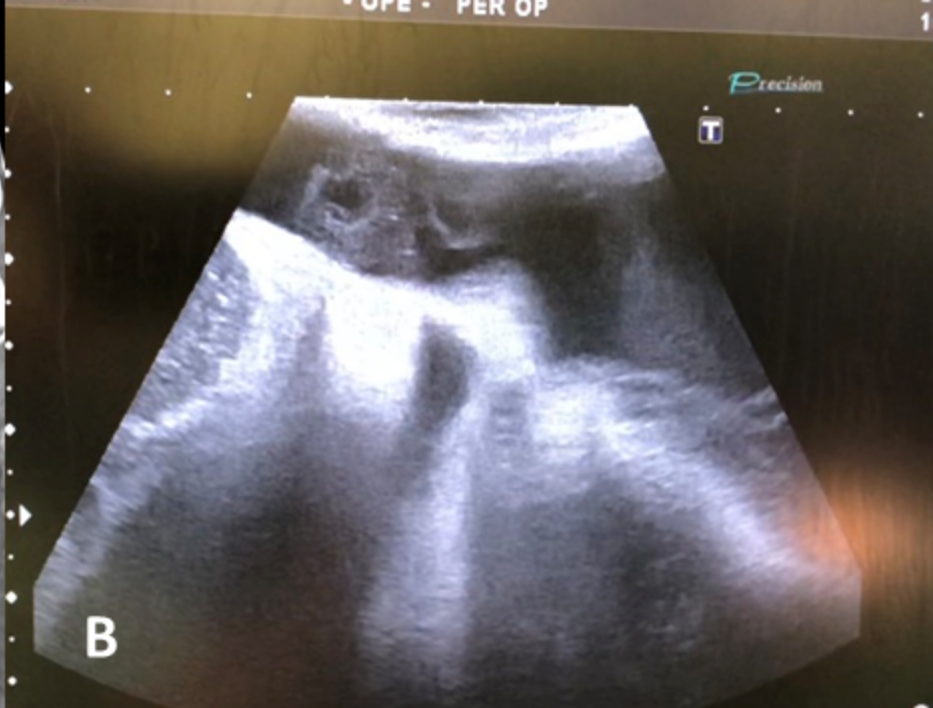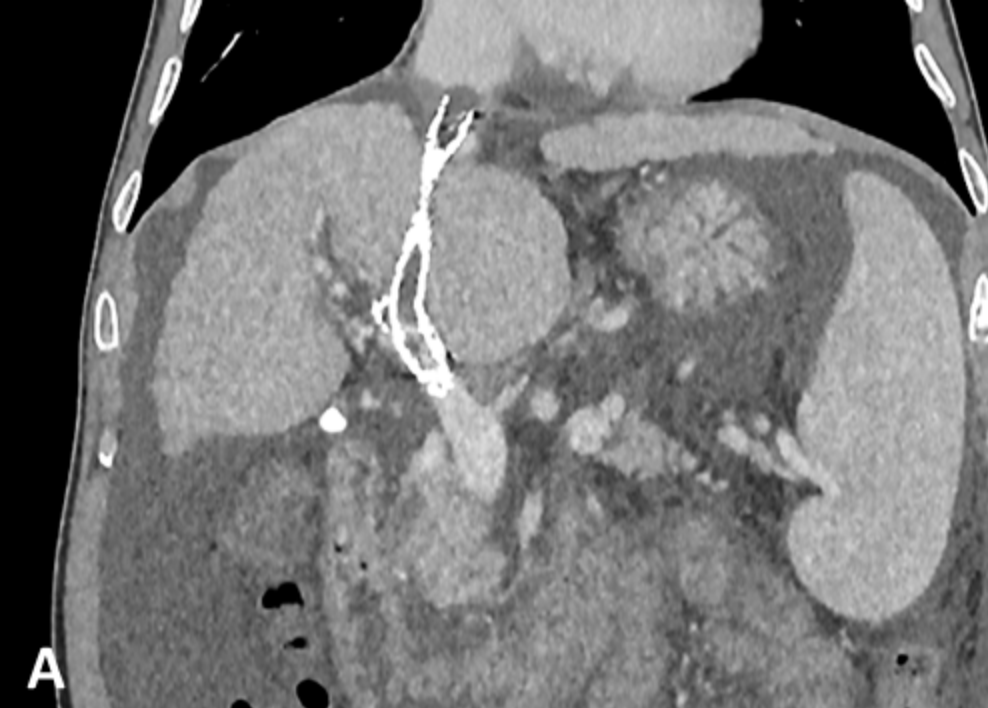
RECORDS EXCLUDED  
(N=10)

FULL TEXT ARTICLES ASSESSED  
FOR ELIGIBILITY  
(N=38)

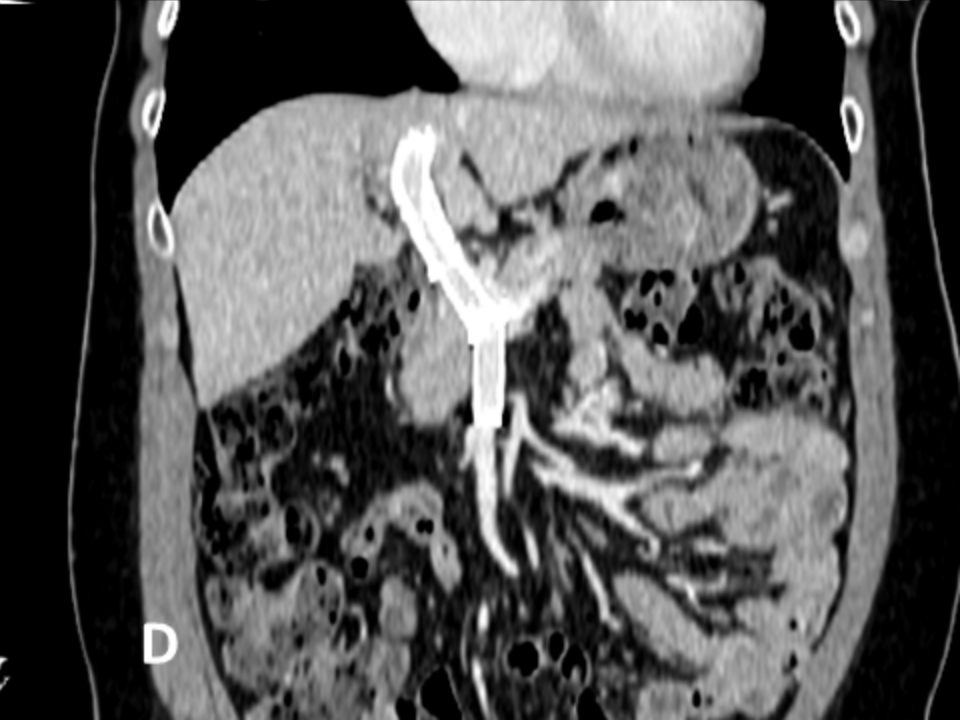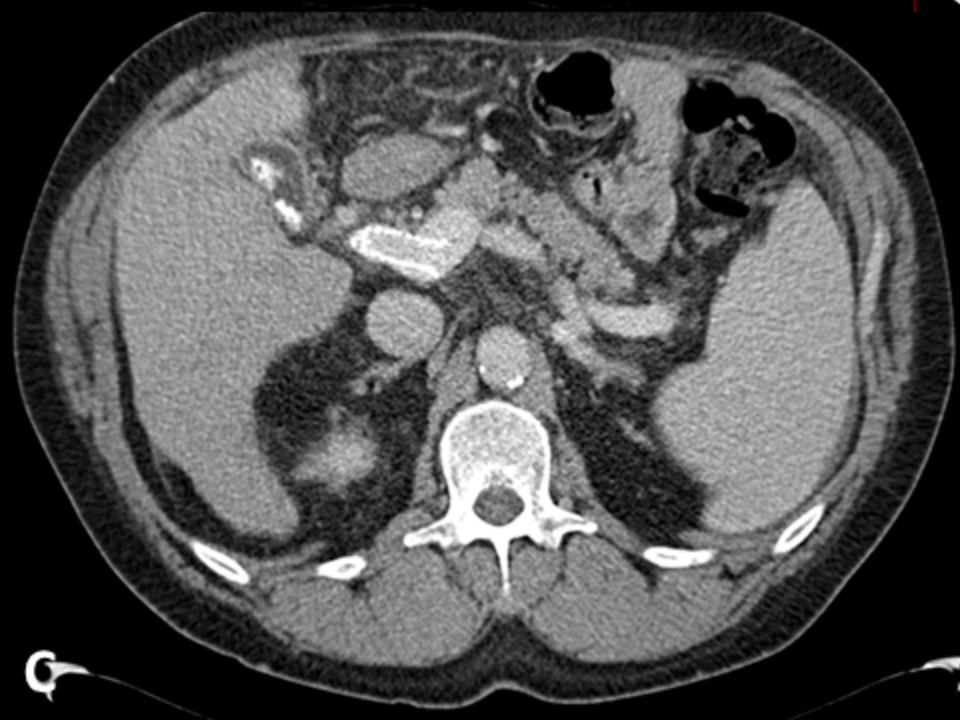
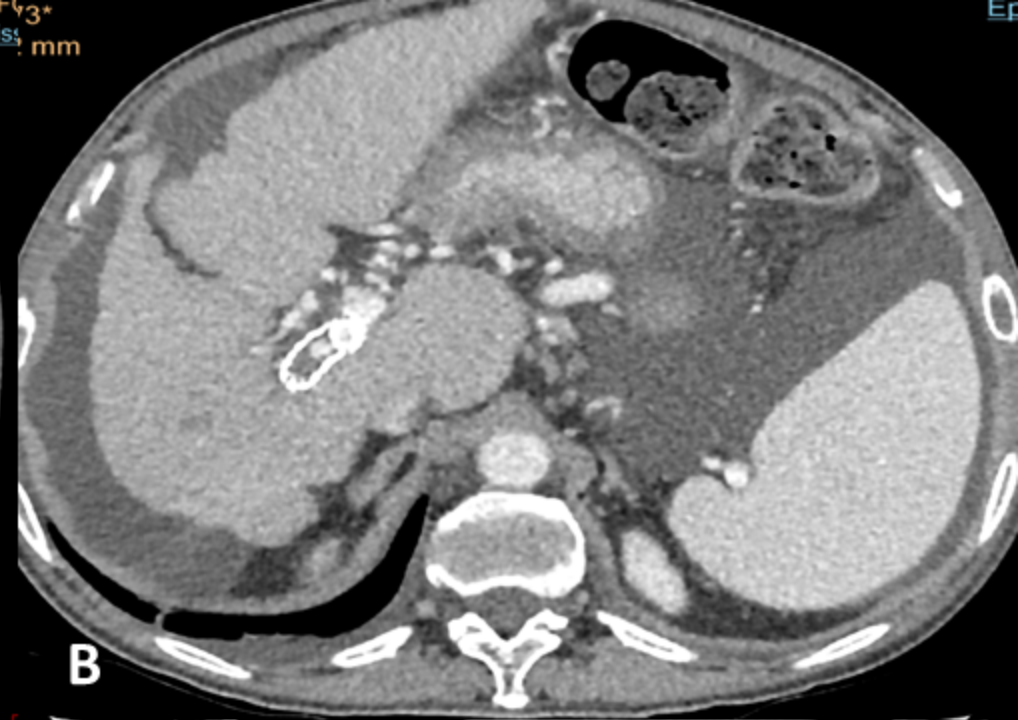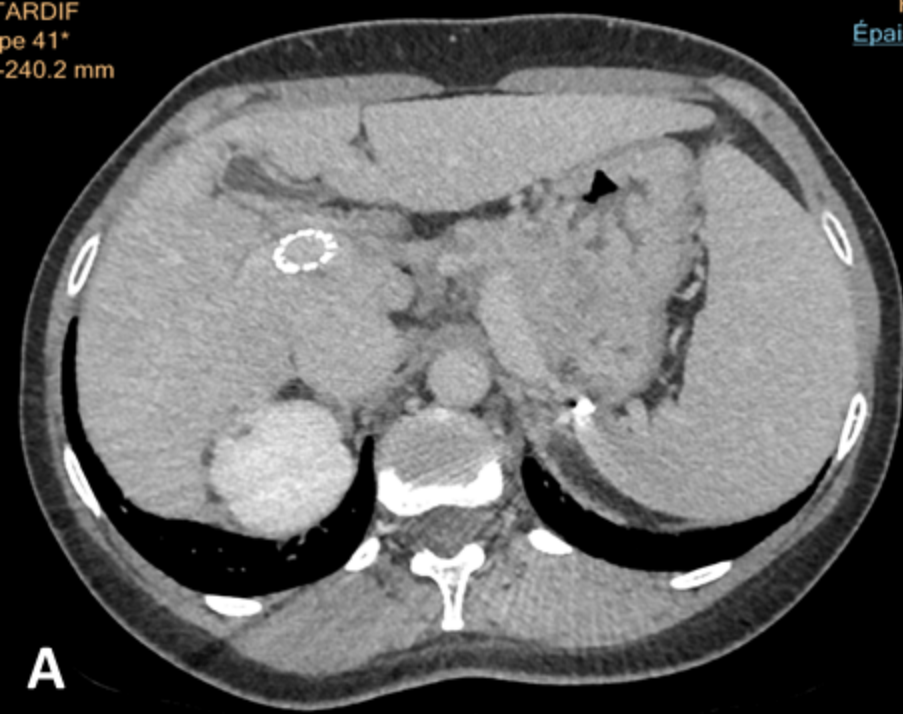
DUPLICATED RECORDS EXCLUDED  
(N=2)

STUDIES INCLUDED IN  
QUALITATIVE SYNTHESIS  
(N=36)







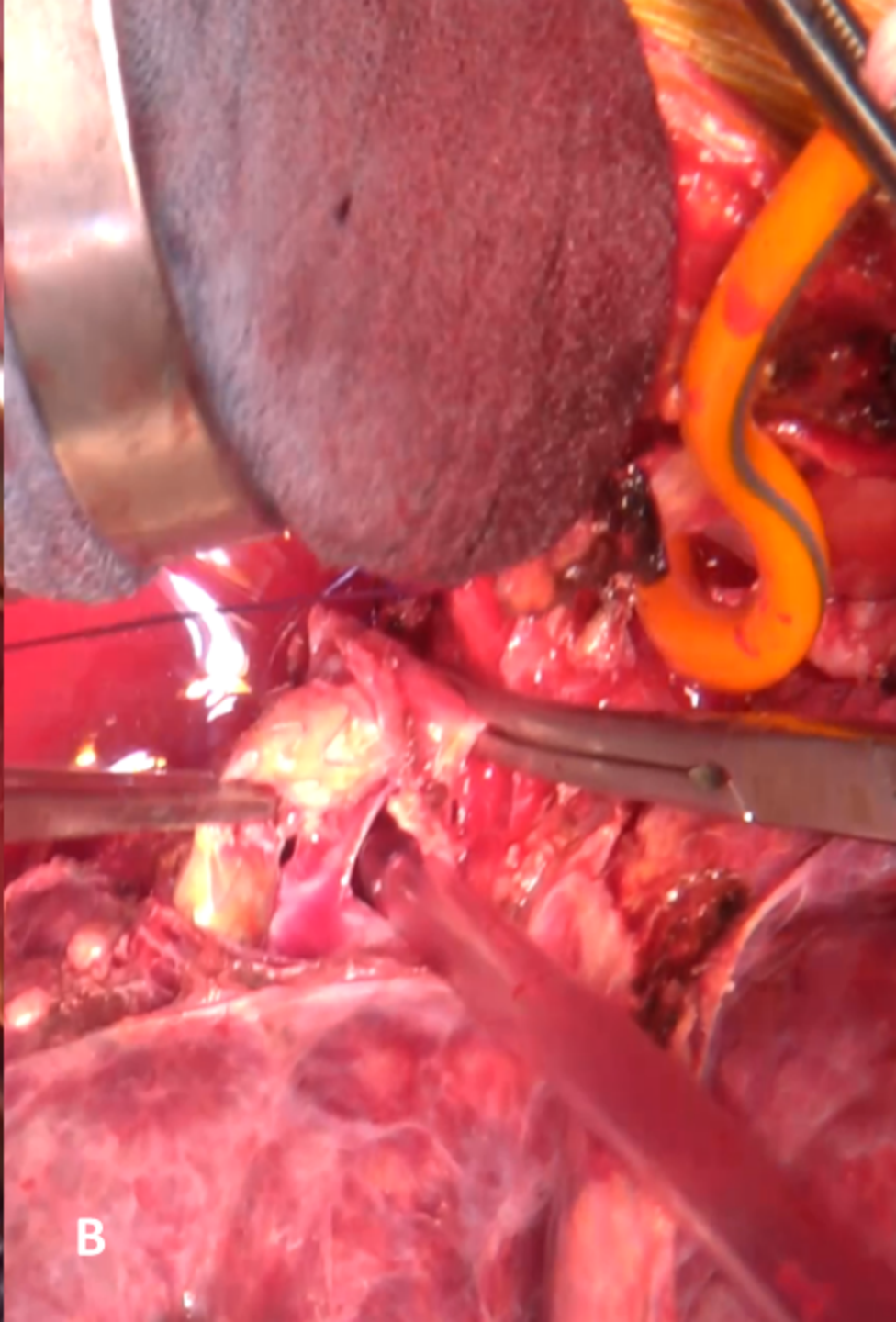
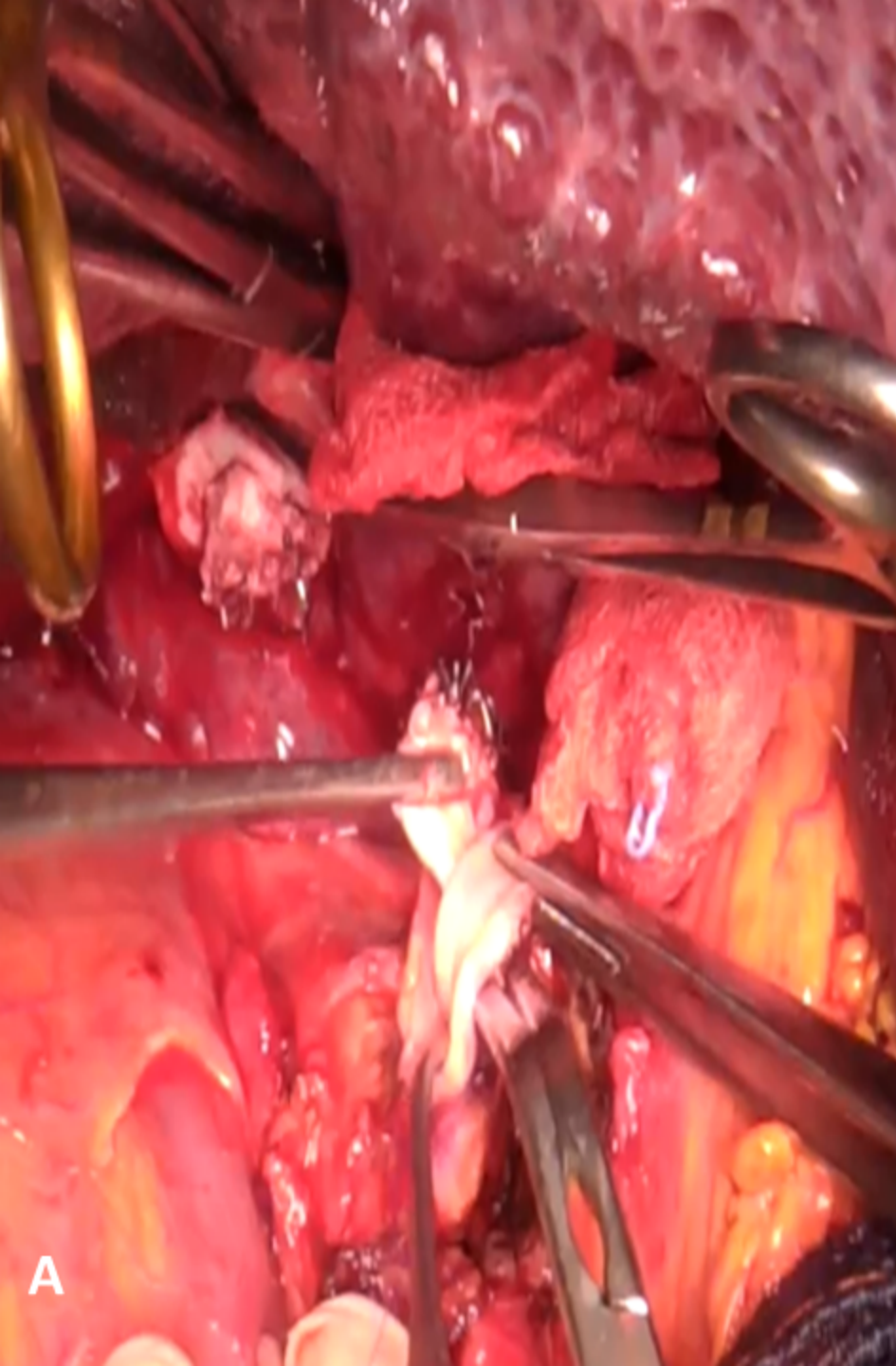


A

B

C

D





**Table 1:** Studies reporting cases of liver transplantation in presence of misplaced TIPS

Author	Country	Year	Number of all patients with TIPS having LT	Number of Misplaced TIPS (%)	Misplaced vs well positioned TIPS	Months from TIPS to LT	Caval TIPS/portal TIPS/both	Thrombosed TIPS
Woodle ES	US	1993	2	1	NA	NA	0/1(100%)/0	1
LaBerge JM	US	1993	22	1	NA	NA	1(50%)/1(50%)/0	NA
Freeman RB	US	1994	6	2(33%)	2 vs 4	NA	2(100%)/0/0	0
Suc B	France	1995	12	1(8,3%)	1 vs 11	NA	0/1(100%)/0	0
Abouljoud MS	US	1995	18	4(22%)	4 vs 14	NA	3(75%)/1(25%)/0	1
Wilson MW	US	1995	NA	3	NA	2.7/2/1	2/1/0	0
Millis JM	US	1995	23	4(17%)	4 vs 19	5 (1-8)	2(50%)/2(50%)/0	0
Jabbour N	US	1996	35	3(8.5%)	3 vs 32	2.6(0.03-24)	2/1/0	1
Mazziotti A	Italy	1996	NA	1	NA	NA	0/1/0	NA
Lerut JP	Belgium	1996	23	5(21%)	5 vs 17	NA	4(75%)/ 1(25%)/0	NA
Goldberg MS	US	1997	24	5(20.8%)	5 vs 19	NA	4(80%)/1(20%)/0	NA
Farney A	US	1997	NA	1	NA	6	0/1/0	0

<b>Meyer C</b>	France	1998	NA	2	NA	NA	2(100%)/0/0	0
<b>Clavien PA</b>	US	1998	12	4(33%)	4 vs 8	5, 7, 13, 24	0/3(75%), 1(25%)	0
<b>John TG</b>	UK	1999	12	2(16,6%)	2 vs 10	2.5(0.3-2.7)	1(50%)/1(50%)/0	0
<b>Rumi M</b>	US	1999	NA	1	NA	1	1/0/0	0
<b>Chui AKK</b>	Australia	2000	9	6(66%)	6 vs 9	13.3 (0.3-53.8)	1(16%), 5(55%), 0	1
<b>Hutchins R</b>	UK	2000	NA	1	NA	16	0/1/0	0
<b>Te HS</b>	US	2001	NA	1	NA	5	1/0/0	0
<b>Zhou GW</b>	China	2002	5	1	5 vs 1	NA	0/1/0	0
<b>Khan TT</b>	US	2002	21	8(38%)	8 vs 13	NA	1/7/0	0
<b>Triapthi D</b>	UK	2002	29	3(10.3%)	3 vs 26	2.7±0.5	2/1/0	4
<b>Moreno A</b>	Spain	2003	26	14 (53.8%)	14 vs 26	NA	4/9/1	1
<b>Hayashi P</b>	US	2004	NA	1	NA	72	1/0/0	0
<b>Salvalaggio PR</b>	US	2005	NA	1	NA	NA	0/0/1	1
<b>da Silva RF</b>	Brazil	2008	NA	1	NA	1	1/0/0	0
<b>Guerrini GP</b>	UK	2009	61	17(27,8%)	17 vs 44	9(0.4-52)	1(6%)/16(94%)/0	0
<b>Tivener D</b>	US	2011	NA	1	NA	1	1/0/0	0

<b>Ogura Y</b>	Japan	2011	NA	1	NA	NA	1(100%)/0/0	NA
<b>Fehervari I</b>	Hungary	2011	NA	1	NA	1.2	0/0/1(100%)	NA
<b>Valdivieso</b>	Spain	2012	49	16(32.5%)	16 vs 33	NA	4(25%)/8(50%)/4(25%)	NA
<b>Barbier L</b>	France	2014	66	23(32%)	23 vs 49	7.9 (0.2-74,5)	7(30%)/10(44%)/6(26%)	7(10%)
<b>Merdrignac A</b>	France	2017	NA	2	NA	NA	2(100%)	0
<b>Thornburg B</b>	US	2017	24	24(100%)	24 vs 0	1.8(0.1-44.9)	0/24(100%)/0	0
<b>Gilbo N</b>	Belgium	2018	NA	2	NA	60/6	0/2(100%)/0	1(50%)
<b>Matsushima H</b>	US	2020	130	17(13%)	17 vs 113	13.06 (0.13-169)	12 (9,8%)/5(3.8%)/0	3(2.3%)

NA= not available



**Table 2 :** Intraoperative and postoperative outcomes of patients undergoing LT in presence of misplaced TIPS

Author	Number of Misplaced TIPS	Portocaval shunt	Intrapericardial contro IVC	Veno-venous bypass	Caval replacement /Portal Graft	Blood Loss	Mortality	Morbidity	Portal vein Thrombosis	1-year Survival
Woodle ES	1	NA	0	1	2/0	700/1500	0	NA	0	NA
LaBerge JM	1	NA	NA	NA	NA/0	NA	0	NA	0	NA
Suc B	1	NA	NA	NA	NA/0	NA	0	NA	0	NA
Freeman RB	2	NA	1(50%)	(2)100%	100%/0	26±26	50%	NA	0	79%
Abouljoud MS	4	NA	0	NA	NA/0	NA	0%	NA	0	NA
Wilson MW	3	NA	1(33%)	NA	NA/0	NA	0%	no	0	NA
Millis JM	4	NA	0	NA	NA/0	NA	NA	NA	0	NA
Jabbour N	3	NA	NA	NA	NA/0	NA	NA	NA	1	NA
Mazziotti A	1	NA	0	NA	NA/0	NA	0	NA	0	NA
Lerut JP	5	0	0	NA	0%	NA	NA	NA	NA	NA
Goldberg MS	5	0	2	NA	0/1	NA	NA	NA	0	NA
Farney A	1	0	0	1	NA/1	NA	0	NA	0	100%
Meyer C	2	NA	0	0	0/0	NA	0	NA	0	100%

<b>John TG</b>	2	0	0	100%	0/0	na	0	NA	0	NA
<b>Clavien PA</b>	4	0%	0	0%	100%/1	Increased	0	ND	0	100%
<b>Rumi M</b>	1	NA	0	0	0/0	NA	0	1	0	NA
<b>Chui AKK</b>	6	NA	0	NA	NA	ND	0	0	0	100%
<b>Hutchins R</b>	1	0%	0	1(100%)	100%/0	NA	0	0	0	100%
<b>Te HS</b>	1	0	1	1(100%)	NA/0	NA	0	1	0	NA
<b>Zhou GW</b>	1	NA	NA	NA	NA	NA	0	NA	0	100%
<b>Khan TT</b>	8	NA	0	7	NA/NA	9.5	0	0	0	81%
<b>Triapthi D</b>	3	NA	NA	NA	NA/0	34±10.5	0	NA	NA	90%
<b>Moreno A</b>	14	0%	0	NA	NA/0	NA	NA	NA	0	NA
<b>Hayashi P</b>	1	NA	1	1 (100%)	NA/0	NA	NA	NA	0	NA
<b>Salvalaggio PR</b>	1	0%	1	1(100%)	1(100%)/0	NA	0	1(pleu ral effusi on, abdo minal collec tion)	0	NA
<b>da Silva RF</b>	1	NA	0	NA	NA/0	8	0	0	0	100%

<b>Guerrini GP</b>	17	NA	0	5(29,4%)	NA/0	6.3±4.9	NA	NA	1(5,9%)	88.2%
<b>Tivener D</b>	1	1	1	1(arterial)	0/0	75	0	1	0	0%
<b>Ogura Y</b>	1	No	1	1	1(Gore-tex)/0	NA	0%	0	0	100%
<b>Fehervari I</b>	1	NA	0	NA	NA/0	NA	0%	0	0	100%
<b>Valdivieso A</b>	16	NA	0	0	2(12%)/0	Increased	NA	NA	1	NA
<b>Barbier L</b>	23	NA	0	0	0/0	NA	NA	NA	NA	NA
<b>Merdrignac A</b>	2	NA	1	1	1(50%)/0	NA	0	0	0	NA
<b>Thornburg B</b>	24	NA	NA	NA	NA	NA	NA	NA	0%	NA
<b>Gilbo N</b>	2	NA	0	0	0/1	0	50%	0	0	50%
<b>Matsushima H</b>	17	0%	1	0(0)	30(26.6%)	7.2±3.4	NA	NA	1	70.6

NA= not available